

We are IntechOpen, the world's leading publisher of Open Access books Built by scientists, for scientists

6,900

Open access books available

186,000

International authors and editors

200M

Downloads

Our authors are among the

154

Countries delivered to

TOP 1%

most cited scientists

12.2%

Contributors from top 500 universities



WEB OF SCIENCE™

Selection of our books indexed in the Book Citation Index
in Web of Science™ Core Collection (BKCI)

Interested in publishing with us?
Contact book.department@intechopen.com

Numbers displayed above are based on latest data collected.
For more information visit www.intechopen.com



Cognitive Features of Vascular Dementia

Oh Dae Kwon

*Department of Neurology, Daegu Catholic University Medical Center,
and School of Medicine, Catholic University of Daegu
South Korea*

1. Introduction

A lot of studies have focused on cerebrovascular disease as an independent cause of dementia. In a study with consecutive stroke patients aged sixty and older, 26.3% of patients were demented three months after the stroke (Desmond et al., 2000). Within the demented patients, 57.1% had dementia directly related with stroke and 38.7% had dementia due to the combined effects of stroke and Alzheimer's disease. Considering high prevalence of stroke, the prevalence of vascular dementia should be substantially high. Therefore early accurate diagnosis is crucial to the effective management of patients with vascular dementia. Recognizing a specific pattern of neuropsychological impairment could be a good diagnostic tool of vascular dementia. However, Cognitive features of vascular dementia are not homogenous because of various features, pathophysiology, and location of cerebrovascular diseases. Adopting the cognitive criteria of Alzheimer's disease, which requires early prominent memory impairment, for use in vascular dementia could be erroneous in many cases of vascular dementia. Memory impairment has been an essential component of the operational criteria of dementia such as Diagnostic and Statistical Manual of Mental Disorders, Fourth Edition (DSM-IV) criteria (American Psychiatric Association, 1994) and even in National Institute of Neurological Disorders and Stroke and the Association Internationale pour La Recherche et l'Enseignement en Neurosciences (NINDS-AIREN) criteria (McKhann G et al., 1994). On the other hand, in the Alzheimer's Disease Diagnostic and Treatment Center (ADDTC) criteria (Chui et al., 1992) they do not require memory impairment as crucial element but need deterioration of intellectual function sufficient to interfere with customary affairs of life. Until now, many reports showed that frontal executive dysfunction is a prominent symptom of vascular dementia as well as less prominent memory impairment (Bowler et al., 1994, Tatemichi et al., 1992). It could be more appropriate omitting memory impairment as an essential component of the criteria of vascular dementia because of various locations of cerebrovascular lesion and of specified functional areas of human brain. In accordance with such ideas, impairment of two or more cognitive domains, not essentially include memory Impairment, was suggested as the diagnostic requirement of vascular dementia (Bowler & Hachinski, 2003). In this chapter we will focus on subcortical mild cognitive impairment and subcortical ischemic vascular dementia because of the relative homogeneity, higher prevalence (Roman et al., 2002; Erkinjuntti et al., 2000), and distinctive clinical features similar to Alzheimer's disease.

2. Cognitive features of each subtypes of vascular cognitive impairment

2.1 Mild cognitive impairment of vascular origin

Mild cognitive impairment refers to a transitional state between normal cognitive state and dementia (Petersen et al., 1999). In general, neurodegenerative dementia like Alzheimer's disease has insidious onset, slowly progressive cognitive deterioration with few or no focal neurological signs. Mild cognitive impairment in Alzheimer's disease, which shows memory impairment without significant impairment of activities of daily living, may precede clinical stages of dementia. On the other hand, vascular dementia may not be a slowly progressive dementia but could be an abrupt onset cognitive decline followed by stroke. It has long been thought that there was no preceding cognitive impairment, like Mild Cognitive Impairment to Alzheimer's disease, before the beginning of vascular dementia. However, more and more reports support the existence of mild cognitive impairment stages of vascular dementia (Frisoni et al., 2002), which shows less memory impairment and severe executive dysfunction (Kim et al., 2011). Both patients with Parkinson disease and mild cognitive impairment (PD-MCI) and patients with subcortical vascular mild cognitive impairment (svMCI) are known to have cognitive dysfunction especially in frontal lobe function (Caviness et al., 2007; Mckinlay et al., 2009; Frisoni et al., 2002) .

Kim et al (2011) compared the cognitive function of PD-MCI and svMCI to differentiate one from the other (Table 1). Twenty-two PD-MCI and 22 svMCI patients were seen in a neurodegenerative disease clinic and 22 normal controls were also recruited. Every participant took brain magnetic resonance imaging which reveals no significant findings in PD-MCI and in normal controls compared with severe ischemic cerebral white matter lesion in svMCI. Mild cognitive impairment was diagnosed according to the criteria of Petersen (1999). All the patients had subjective cognitive complaint and neuropsychological tests showed cognitive decline in one or more domains. However the cognitive deficits did not result in significant functional decline. svMCI should also meet the criteria of Erkinjuntti et al (2000) which mandates minor neurological symptoms and diffuse cerebral white matter lesion demonstrated on magnetic resonance imaging. These three groups were matched in terms of age, gender, and education. The Seoul Neuropsychological Screening Battery (SNSB) (Kang & Na, 2003), a standardized neuropsychological battery, was performed in svMCI and PD-MCI subjects. The battery contains tests for attention, language, praxis, four elements of Gerstmann syndrome, visuoconstructive function, verbal and visual memory, and frontal/executive function. Only several important tests among SNSB were performed in controls. svMCI should meet the criteria modified from those of Erkinjuntti (2000).

2.1.1 Frontal executive function

Frontal executive dysfunction was prominent in both MCI groups after analysis of covariance with depression adjustment. The svMCI group performed lower in word fluency and stroop test than the PD-MCI group.

2.1.2 Memory

Both groups showed decreased performance in verbal and visuospatial memory tests. The PD-MCI group performed lower in the verbal recognition test than the svMCI group, which showed lower visuospatial memory

Variables	PD-MCI(n=22)	svMCI(n=22)	NC(n=22)	F	LSD
Word Fluency					
Animal	11.00(2.98)	10.82(2.89)	14.50(3.91)	6.86*	1=2, 1<3, 2<3
Supermarket	11.09(3.13)	10.05(4.45)	16.45(4.55)	13.53*	1=2, 1<3, 2<3
Spelling	13.64(6.93)	8.14(5.51)	17.73(6.17)	11.70*	2<1, 1=3, 2<3
K-CWST					
Word reading(C)	94.55(22.23)	95.23(21.32)	108.14(14.85)	1.40	1=2=3
Word reading(E)	.68(.99)	1.05(1.84)	.14 (.35)	3.23*	1=2, 1=3, 3<2
Word reading(T)	108.73(17.78)	114.64(7.12)	94.32(21.24)	6.46*	1=2, 1=3, 3<2
Color reading(C)	57.32(31.09)	49.59(19.77)	79.32(26.69)	4.90*	1=2, 1=3, 2<3
Color reading(E)	3.45(4.40)	5.64(9.50)	2.27(5.93)	1.41	1=2=3
Color reading(T)	118.86(5.33)	120.00(.00)	118.50(4.92)	.92	1=2=3
Color reading(I)	1.28(1.18)	1.13(.93)	.76 (.64)	.40	1=2=3
K-MMSE					
Registration	3.00(.00)	2.91(.29)	3.00(.00)	2.07	1=2=3
Recall	1.54(1.06)	1.45(1.10)	2.22(.87)	3.93*	1=2, 1<3, 2<3
SVLT					
Immediate recall	15.32(4.48)	14.82(4.27)	18.77(4.17)	3.39*	1=2, 1=3, 2<3
Delayed recall	3.77(2.14)	3.14(1.78)	5.59(2.24)	9.96*	1=2, 1<3, 2<3
Recognition	18.23(2.09)	19.32(1.78)	20.05(2.19)	4.85*	1<2, 1<3, 2=3
RCFT					
Immediate recall	9.93(4.51)	7.30(3.56)	13.59(5.89)	7.85*	2<1, 1=3, 2<3
Delayed recall	9.82(4.53)	7.34(3.07)	13.05(5.55)	6.97*	2<1, 1=3, 2<3
Recognition	18.68(2.10)	18.36(1.99)	20.00(2.39)	2.09	1=2, 1=3, 2<3
Digit Span					
Forward	5.32(1.29)	4.82(1.47)	5.55(1.26)	1.78	1=2=3
Backward	2.86(1.17)	3.18(.85)	3.64(.90)	1.33	1=2=3
RCFT					
Copy	25.63(7.10)	22.41(7.89)	28.50(5.93)	3.59*	2<1, 1=3, 2<3
ILP	.77(.43)	.64(.49)	.91(.29)	2.08	1=2=3
K-BNT	37.68(9.34)	33.68(10.69)	45.54(7.79)	7.65*	1=2, 1<3, 2<3

(Reprinted from J Korean Neurol Assoc with permission from Korean Neurological Association (J Korean Neurol Assoc,2011))

Table 1. Neuropsychological performances of PD-MCI, svMCI, and normal control. Values shown are mean (SD). 1=PD-MCI (Parkinson disease and mild cognitive impairment), 2=svMCI (subcortical vascular mild cognitive impairment), 3=NC (normal control), K-CWST=Korean color word stroop test, SVLT: Seoul verbal learning test, RCFT=Rey complex figure test, C=correct response, E=error response, T=time per item, ILP=Interlocking Pentagon/ *p<0.05 by analysis of covariance.

2.1.3 Attention

There was no difference between normal control and both patients group in forward and backward digit span test, and no difference between patient groups.

2.1.4 Visuospatial function

In interlocking pentagon drawing of mini-mental state examination, there was no significant difference between normal control and both patient groups and neither between patient groups. On the other hand, in copy of Rey complex figure test, svMCI showed decreased performance compared to the PD-MCI group and normal controls.

2.1.5 Language

Both patient groups showed decreased performance in Boston Naming Test and there was no difference between the two patient groups.

2.1.6 Depressive mood

The PD-MCI group was more depressive than the svMCI group in Geriatric Depression Scale (Yesavage et al., 1982).

Overall, both svMCI group and PD-MCI group showed multiple domains of cognitive impairment, prominent deficit in frontal executive function and memory function. svMCI group showed severe impairment in frontal executive function, which could be attributed by both white matter and gray matter lesion, compared to the PD-MCI group which displayed severe impairment in verbal memory function. These differences in cognitive function may help to differentiate PD-MCI from svMCI and to know their pathophysiology. Interestingly, PD-MCI group also showed severe depressive mood which opens the possibility of cognitive improvement through therapy of the symptom.

2.2 Subcortical vascular dementia

2.2.1 A case presentation of subcortical vascular dementia

The patient is a 66-year-old right-handed male high school graduate. He was diagnosed with hypertension 10 years ago without but did not have drug treatment. He smoked one pack of cigarettes per day for 30 years. His mother suffered a stroke in her sixties. He is a realtor and interested in stock market. Mountain climbing with colleagues has been a longstanding hobby for several decades. He suffered a stroke-like event at 63-years old, the symptom of the event was transient left side clumsiness. The symptoms lasted for two weeks and spontaneously improved. After that event he had difficulty of subway trip because he confused finding the right entrance of familiar subway station. Moreover, sometimes he was lost on the way to his daughter's house which he was used to. The other symptom was losing money in stock market. Before the event he was quite successful in the stock exchange and earned some amount of money for several decades in stock market. The money losing in stock market was getting bigger that his wife and daughter forced him to stop stock exchange. Since three months before the first visit to memory clinic, his gait became clumsy again, on both legs, and sometimes fell on the ground during mountain climbing, which made him stop the hobby. In addition to such symptoms, mild memory deficit developed which resulted in poor management of bank account. Neuropsychological examination noted behavioral features of frontal lobe dysfunction such as aggressiveness, depressive mood, apathy, irritability and poor

appetite. Magnetic resonance imaging demonstrated diffuse white matter hyperintensity prominent in frontal white matter with multiple subcortical lacunar old infarctions bilaterally on T2-weighted images. His mini-mental state examination (Folstein et al., 1975) score was 25 followed by 19 and 14 during consecutive two years. During eight years after first visit, the patient has been managed with antiplatelet agents, antihypertensive agents and atypical antipsychotics. Stroke-like symptoms did not recur but the frontal features of cognitive symptoms and gait disturbance, mild dysarthria and urinary incontinence were slowly progressing. His neuropsychological test revealed increasing deficits in multiple cognitive domains, especially in frontal executive functions. His brain MRI revealed multiple lacunar infarctions on both basal ganglia including bilateral caudate nucleus heads, globus pallidus, putamen, thalamus, and centrum semiovale on the T2 view. Diffuse white matter hyperintensities were seen, prominent in frontal lobe white matter, on the fluid attenuated inversion recovery (FLAIR) view(Figure 2). There also was frontal lobe atrophy which is severe than his age. At last contact, he became mute, urinary and fecal incontinent, bound to wheelchair and spitting to everywhere with mini-mental state examination score of 16.

This patient is a typical case of subcortical vascular dementia. He suffered several episodes of stroke-like symptoms which initiated and aggravated the cognitive symptoms and neurologic symptoms. Those symptoms improved slowly after each event, but not to the level of normal state. The pattern of cognitive decline was a stepwise pattern and antiplatelet agents and antihypertensive medication seemed to prevent further stroke-like episodes. The mini-mental state examination score showed steady state after falling to 14 during first two years which is not usual for Alzheimer’s disease. However, his neurological and behavioral symptoms declined slowly to being wheelchair bound and mute.

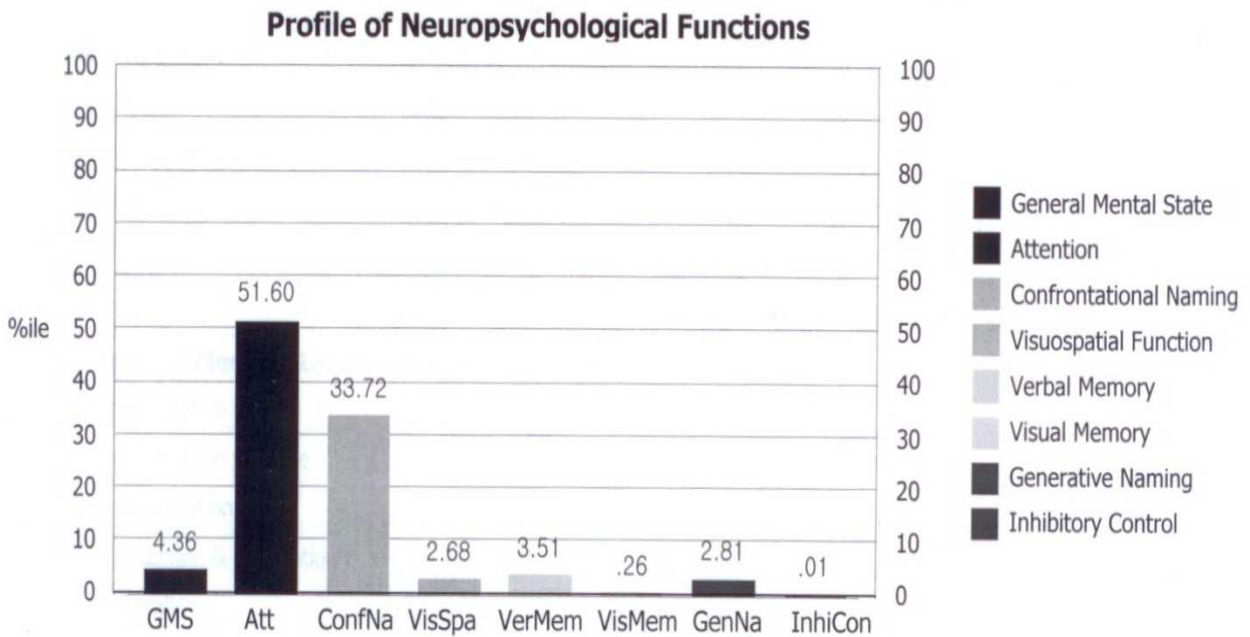


Fig. 1. Neuropsychological performance of a patient with subcortical vascular dementia. Attention and Naming were relatively preserved. Visual memory is more impaired than verbal memory. Severe impairment of frontal inhibitory function is noted.

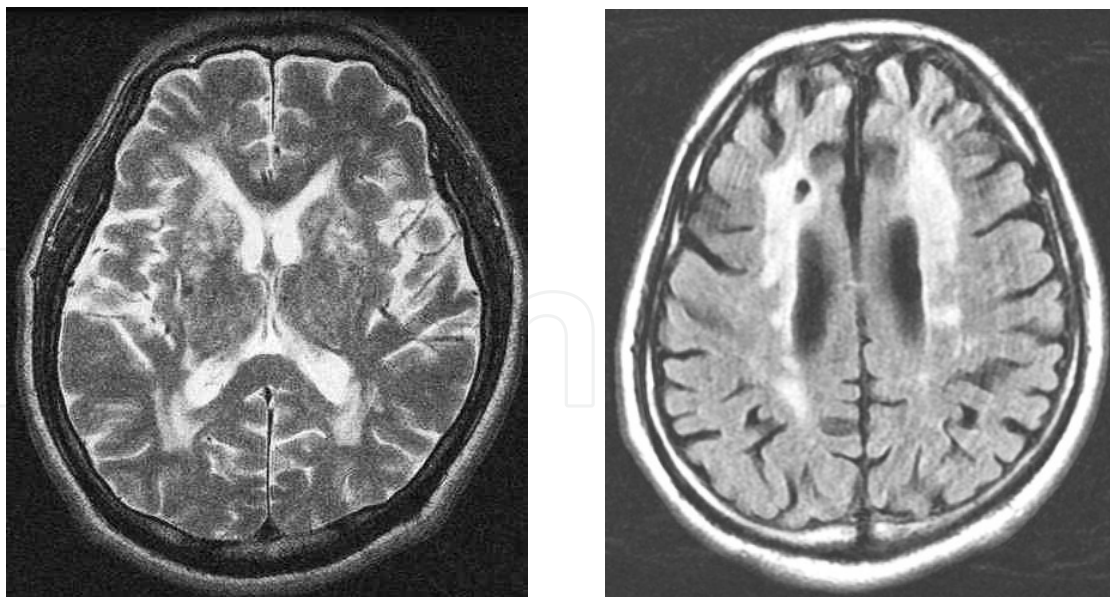


Fig. 2. Characteristic brain MRI appearances in a patient with subcortical vascular dementia. Note multiple lacunar infarctions on both basal ganglia(left, T2 image) and diffuse white matter hyperintensities(right, FLAIR image).

2.2.2 Cognitive features of subcortical vascular dementia

It has recently been proposed that patients with subcortical form of vascular dementia represent a highly prevalent and homogeneous group (Erkinjuntti et al., 2000). The primary clinical manifestation is a subcortical syndrome comprising progressive cognitive impairment with frontal features and parkinsonism poorly responsive to dopaminergic therapy (Erkinjuntti et al., 2000). Though the clinical features of subcortical vascular dementia may not show apparent stepwise deterioration, essentially the cognitive deterioration will show stepwise pattern, because of repetitive subcortical ischemic event, like lacunar infarction or other ischemic changes of subcortical structures (Loeb et al., 1992). These subcortical ischemic events including lacunar infarction frequently occur in subcortical gray matter and white matter which connect cognitive connecting pathways, like frontal-subcortical circuits, that cause frontal executive dysfunction and other cognitive deficits (Wolfe et al., 1990) and often produce a clinical syndrome like Parkinson's disease which also affect subcortical structures (Frisoni GB et al., 2002). Cerebral autosomal dominant arteriopathy with subcortical infarcts and leukoencephalopathy (CADASIL) is a genetic disorder that exhibits ischemic event as well as migraine. The cognitive symptoms of CADASIL include frontal executive dysfunction due to their subcortical involvement (Chabriat et al., 1995).

When we compare neuropsychological scores between subcortical vascular dementia and Alzheimer's disease, we can see less memory impairment and severe executive dysfunction in the patients with subcortical vascular dementia, which is exactly consistent with the results of subcortical vascular mild cognitive impairment (Table 2, Unpublished data). The two groups were matched with respect to age, sex, education, and severity of dementia (Ryu et al., 2012). The study comprised 61 patients with subcortical vascular dementia and 112 patients with Alzheimer's disease matched with respect to age, sex, education, and dementia severity. The diagnosis of dementia was based on DSM-IV criteria. The diagnosis

Neuropsychological tests (maximum possible score)	AD(n=61)	SCVD(n=112)	P-value* *
Attention			
Digit span			
forward	4.28(1.51)	4.36(1.32)	NS
backward	1.95(1.52)	2.00(1.23)	NS
Language & related disorders			
K-BNT (60)	24.78(12.26)	23.97(10.91)	NS
Calculation (12)	6.50(3.99)	5.95(3.51)	NS
Ideomotor limb apraxia (5)	3.78(1.37)	4.16(1.20)	NS
SVLT			
sum of three free recall (36)	8.98(4.49)	9.59(4.61)	NS
delayed recall (12)	0.58(1.42)	1.36(1.99)	≤ 0.05
recognition*	2.78(2.92)	4.28(3.12)	≤ 0.05
Visuospatial function			
RCFT (36)	13.95(10.88)	12.66(7.76)	NS
RCFT			
immediate recall (36)	3.07(3.45)	3.51(3.03)	NS
delayed recall(36)	2.20(3.16)	2.91(3.06)	NS
recognition*	2.68(2.60)	2.80(2.69)	NS
Frontal/Executive function			
COWAT			
Semantic : animal items	7.62(3.86)	7.11(3.17)	NS
Semantic : supermarket items	7.92(4.67)	7.22(3.97)	NS
phonemic: sum of three letters	7.41(8.40)	4.45(5.11)	≤ 0.05
Stroop test			
letter reading (112)	83.40(29.12)	69.06(30.46)	≤ 0.05
colour reading (112)	37.66(26.48)	29.12(22.44)	NS

Table 2. Results of neuropsychological tests of AD group and SCVD group. Values shown are mean(SD). AD, Alzheimer’s disease; SCVD, subcortical vascular dementia; NS, Not-significant; K-BNT, Korean version of the Boston Naming Test; RCFT, Rey-Osterrieth Complex Figure Test; SVLT, Seoul Verbal Learning Test; COWAT, Controlled Oral Word Association Test, *true positive-false positive. * *P values by Independent T-test (Unpublished data)

of subcortical vascular dementia was also based on modified NINDS-AIREN criteria proposed by Erkinjuntti et al (2000) which requires minor neurologic symptoms and diffuse cerebral white matter lesions demonstrated on magnetic resonance imaging. The diagnosis of Alzheimer’s disease was also based on NINCDS-ADRDA criteria. The Seoul Neuropsychological Screening Battery, a standardized neuropsychological battery (Kang & Na, 2003), was performed in subcortical vascular dementia and Alzheimer’s disease subjects and part of the battery was performed in controls. Clinical assessments include Clinical dementia rating (CDR) (Morris, 1993), Barthel activities of daily living (B-ADL) (Mahoney & Barthel, 1965), Geriatric depression scale, and modified Hachinski ischemia

scales (Rosen et al., 1980). Frontal executive dysfunction was prominent in subcortical vascular dementia in phonemic part on Controlled Oral Word Association test (COWAT) and the letter reading part on the Stroop test. Semantic COWAT and color reading on Stroop test did not show a difference between the two groups. Memory tests showed decreased performance in verbal and visuospatial memory tests for both groups. The Alzheimer's disease group showed significantly worse results on delayed recall test and recognition test in verbal learning test. Net scores of Rey complex figure test also showed worse results in Alzheimer's group but this was not significant. Ideomotor limb apraxia tests showed worse performance in Alzheimer's disease group. Boston naming test and forward and backward test of Digit span did not show significant differences between the two groups. Interestingly, both groups showed similar grade of depressive moods on the Geriatric depression scale.

2.2.3 Strategic single infarct dementia

Strategic single infarct dementia is a type of vascular dementia and could be considered a type of subcortical vascular dementia (Bogousslavsky et al., 1988), more specifically lacunar type by the modified NINDS-AIREN criteria introduced by Erkinjuntti et al. (2000). However, it has some distinctive characteristics. The first is that a patient with strategic single infarct dementia develops dementia after one episode of stroke, not involving the cerebral cortex. Second, the lesion involved in this kind of vascular dementia is specified, like thalamus, head of caudate nucleus (Benisty et al., 2009), genu of internal capsule, posterior limb of internal capsule. Third, the cognitive deficit does not decline sharply but shows steady state as long as vascular risk factors are well controlled. Sometimes the cognitive decline aggravates even though the vascular risk factors are in good control and there is no stroke after the first episode. This could be accounted for by Wallerian degeneration of neurons as in the case of traumatic brain injury (Berker, 1996). The cognitive domains disturbed in strategic single infarct dementia depend on the location of the lesion. In the case of head of caudate nucleus infarction, dominant symptoms are frontal executive dysfunction. In thalamic infarction, there are memory symptoms as well as frontal executive dysfunction which is explained by thalamic involvement of frontal subcortical circuit and Papez circuit (Nishio et al., 2011).

2.3 Multi-infarct dementia

Multi-infarct dementia (Hachinski et al., 1974) is a common cause of dementia in patients with poorly controlled hypertension. Repeated thrombo-embolic cerebral infarctions cause typical stepwise deterioration of cognitive function as well as motor function. Main cause of cognitive dysfunction in multi-infarct dementia has been considered as large areas of cortical damage (Cummings, 1987). The cognitive features of multi-infarct dementia vary greatly with the location of strokes. The neuropsychological dysfunction may be patchy like distribution of cognitive domain which develops a dementia syndrome (Emery et al., 2000). Cerebral infarctions along the language areas frequently exhibit speaking and comprehension while infarctions of posterior cerebrum show visual agnostic symptoms and problems of reading and writing. Unless there are lesions in prefrontal lobe, there is no executive dysfunction. Therefore the cognitive symptoms of multi-infarct dementia are too various and hard to describe as one criteria of dementia.

2.4 Hemorrhagic dementia

The incidence and prevalence of hemorrhagic dementia is decreasing with better control of hypertension. However, it needs persistent attention. Multiple lobar hemorrhages, due to hypertension and/or cerebral amyloid angiopathy, may cause similar course and consequences as those of multi-infarct dementia (Itoh et al., 1993). Other causes of hemorrhagic dementia are bleeding from aneurismal rupture, amyloid angiopathy, cerebral arterio-venous malformation and chronic subdural hematoma.

3. Course of cognitive impairment in vascular dementia

The stepwise and fluctuating course of decline has been thought to result from multiple recurrent strokes in patients with vascular dementia. Each stroke may cause an acute change in the patient's level of cognitive function and may have a period of stability or partial recovery (Desmond et al., 2003). Subcortical vascular dementia typically exhibits frontal executive dysfunction and some of them show mild to moderate degree of memory impairment. When we compare memory decline of subcortical vascular dementia with Alzheimer's disease, we can notice improved recognition function than delayed recall of memory. It could be explained that memory impairments in subcortical vascular dementia were developed due to retrieval deficit, which is related to decreased attention from the frontal dysfunction compared to consolidation deficit due to direct hippocampal dysfunction of Alzheimer's disease. However this phenomenon may be dimmed when the patients with subcortical vascular dementia suffer moderate to severe degree of dementia.

In an informative study of the course of cognitive decline of multi-infarct dementia, 54% of the patients with multi-infarct dementia showed insidious onset and 50% of the patient exhibited gradually progressive course of memory decline (Fisher et al., 1990). The stereotypic cognitive decline of vascular dementia occurred in only 34% of the patients, which means two thirds of multi-infarct dementia does not show typical stepwise features. It suggests that there are many exceptions to the typical stepwise course of cognitive decline in vascular dementia and there is a large need to do brain imaging in patients with cognitive decline.

4. Summary and conclusions

There are various features of cognitive impairment in dementia syndrome. For the vascular dementia, the cognitive symptoms are mainly dependent on the ischemic or hemorrhagic lesions and severity and duration of the lesions. The course of cognitive decline may roughly match that of neurologic decline in each type of vascular dementia (Figure 3).

Figure 3 shows typical form of a time course of each type of vascular dementia. However, we should acknowledge that there could be many exceptions to such a typical form of clinical course. Moreover, a patient with multiple strokes may show cognitive characteristics of one type and later may show the other type of vascular dementia. In subcortical vascular dementia, gray matter lesions provoke more serious damage and sequela than white matter lesions. White matter lesion, mainly axonal and myelin sheath damage, may be recovered by cerebral recovering mechanism. However, gray matter damage, mainly neuronal body lesion, have little potential to be regenerated.

Multi-infarct dementia and strategic single infarct dementia was noted easily due to dramatic episode of stroke and serious neurologic deficit. However, with the introduction of

skills and drugs for management of vascular risk factors such as hypertension and diabetes mellitus, the clinical importance of subcortical vascular dementia is increased. Subcortical vascular dementia shows slowly progressive cognitive decline without a dramatic stroke event such that it is difficult to distinguish subcortical vascular dementia from Alzheimer's disease. With comprehensive neuropsychological tests, predominant frontal executive dysfunction and lesser memory decline, particularly in verbal memory could be the clue to subcortical vascular dementia. Before reaching the diagnosis of vascular dementia, we should be careful to distinguish it from Alzheimer's disease because many patients with Alzheimer's disease have ischemic changes and patients with vascular dementia also may have Alzheimer's pathology in quite large proportion of such patients (Desmond et al., 2000). We could differentiate pure vascular dementia from mixed type dementia when a patient with suspected vascular dementia shows a steady cognitive state for more than several years only with management of vascular factors.

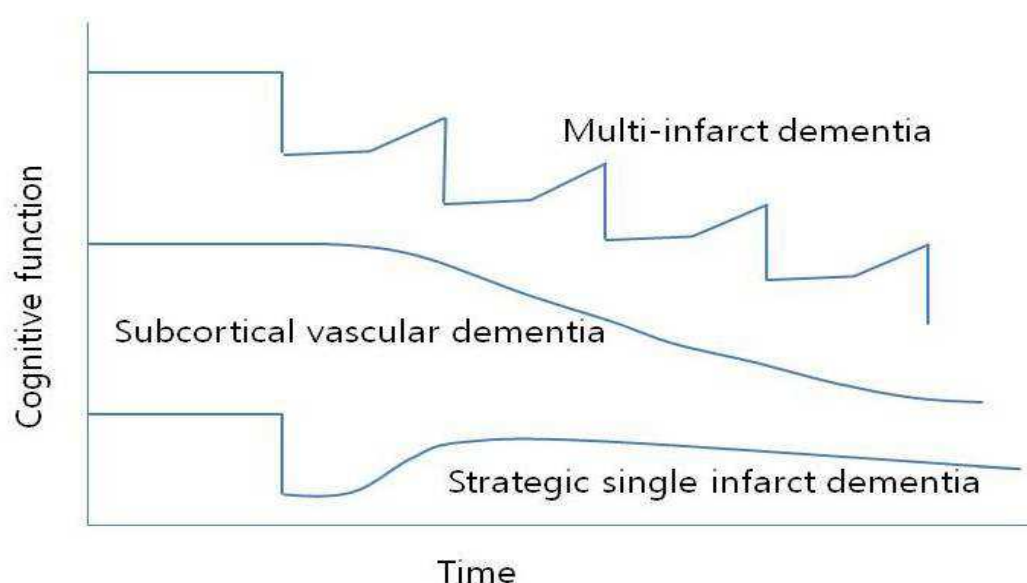


Fig. 3. Clinical course of each subtypes of vascular dementia. Multi-infarct dementia shows typical stepwise deterioration which improved a little after an acute episode until the next stroke happens. Subcortical vascular dementia shows slow, progressive decline during long periods which is similar with that of Alzheimer's disease. Strategic single infarct dementia has one serious event followed by partial recovery and steady state.

5. Acknowledgements


I wish to express my gratitude to Mrs. HJ Kim for the nice tables and figures and Ms. SY Choi, Ms. JH Kim, and Ms. JY Kim for the excellent neuropsychological tests administered to the patients. And I also thank Mr. HG Ryu for the data processing and statistical support.

6. References

American Psychiatric Association. 1994. Diagnostic and statistical manual of mental disorders : DSM-IV. Washington, D.C.: American Psychiatric Association.

- Benisty S, Gouw AA, Porcher R, Madureira S, Hernandez K, Poggesi A, van der Flier WM, Van Straaten EC, Verdelho A, Ferro J, et al. 2009. Location of lacunar infarcts correlates with cognition in a sample of non-disabled subjects with age-related white-matter changes: The LADIS study. *J Neurol Neurosurg Psychiatry* 80(5):478-83.
- Berker E. 1996. Diagnosis, physiology, pathology and rehabilitation of traumatic brain injuries. *Int J Neurosci* 85(3-4):195-220.
- Bogousslavsky J, Regli F, Uske A. 1988. Thalamic infarcts: Clinical syndromes, etiology, and prognosis. *Neurology* 38(6):837-48.
- Bowler JV and Hachinski V. 2003. Vascular cognitive impairment-a new concept. In: *Vascular cognitive impairment*. Bowler JV and Hachinski V, editors. New York, United States: Oxford University Press. 321 p.
- Bowler JV, Hadar U, Wade JP. 1994. Cognition in stroke. *Acta Neurol Scand* 90(6):424-9.
- Caviness JN, Driver-Dunckley E, Connor DJ, Sabbagh MN, Hentz JG, Noble B, Evidente VG, Shill HA, Adler CH. 2007. Defining mild cognitive impairment in parkinson's disease. *Mov Disord* 22(9):1272-7.
- Chabriat H, Vahedi K, Iba-Zizen MT, Joutel A, Nibbio A, Nagy TG, Krebs MO, Julien J, Dubois B, Ducrocq X. 1995. Clinical spectrum of CADASIL: A study of 7 families. cerebral autosomal dominant arteriopathy with subcortical infarcts and leukoencephalopathy. *Lancet* 346(8980):934-9.
- Chui HC, Victoroff JL, Margolin D, Jagust W, Shankle R, Katzman R. 1992. Criteria for the diagnosis of ischemic vascular dementia proposed by the state of california alzheimer's disease diagnostic and treatment centers. *Neurology* 42(3 Pt 1):473-80.
- Cummings JL. 1987. Multi-infarct dementia: Diagnosis and management. infarctions produce 20% to 35% of severe dementia cases. *Psychosomatics* 28(3):117,9, 123-6.
- Desmond DW. 2000. The evaluation of mood and behavior in patients with focal brain lesions. In: *Behavior and mood disorders in focal brain lesions*. Bogousslavsky J and Cummings JL, editors. Cambridge, England: Cambridge University Press. 21 p.
- Emery VO, Gillie EX, Smith JA. 2000. Interface between vascular dementia and alzheimer syndrome. nosologic redefinition. *Ann N Y Acad Sci* 903:229-38.
- Erkinjuntti T, Inzitari D, Pantoni L, Wallin A, Scheltens P, Rockwood K, Roman GC, Chui H, Desmond DW. 2000. Research criteria for subcortical vascular dementia in clinical trials. *Journal of Neural Transmission. Supplementum* 59:23-30.
- Fischer P, Gatterer G, Marterer A, Simanyi M, Danielczyk W. 1990. Course characteristics in the differentiation of dementia of the alzheimer type and multi-infarct dementia. *Acta Psychiatr Scand* 81(6):551-3.
- Folstein MF, Folstein SE, McHugh PR. 1975. "Mini-mental state". A practical method for grading the cognitive state of patients for the clinician. *J Psychiatr Res* 12(3):189-98.
- Frisoni GB, Galluzzi S, Bresciani L, Zanetti O, Geroldi C. 2002. Mild cognitive impairment with subcortical vascular features: Clinical characteristics and outcome. *J Neurol* 249(10):1423-32.
- Hachinski VC, Lassen NA, Marshall J. 1974. Multi-infarct dementia. A cause of mental deterioration in the elderly. *Lancet* 2(7874):207-10.
- Itoh Y, Yamada M, Hayakawa M, Otomo E, Miyatake T. 1993. Cerebral amyloid angiopathy: A significant cause of cerebellar as well as lobar cerebral hemorrhage in the elderly. *J Neurol Sci* 116(2):135-41.

- Kang YW and Na DL. 2003. Seoul neuropsychological screening battery. Seoul, Korea: Human Brain Research & Consulting Co.
- Kim JH, Jin YS, Chang MS, Choi SY, Kwon OD. 2011. Neuropsychological characteristics of mild cognitive impairment in parkinson's disease and subcortical vascular mild cognitive impairment. *J Korean Neurol Assoc* 29:311-6.
- Kittner B, De Deyn PP, Erkinjuntti T. 2000. Investigating the natural course and treatment of vascular dementia and alzheimer's disease. parallel study populations in two randomized, placebo-controlled trials. *Ann N Y Acad Sci* 903:535-41.
- Loeb C, Gandolfo C, Croce R, Conti M. 1992. Dementia associated with lacunar infarction. *Stroke* 23(9):1225-9.
- Mahoney FI and Barthel DW. 1965. Functional evaluation: The barthel index. *Md State Med J* 14:61-5.
- McKhann G, Drachman D, Folstein M, Katzman R, Price D, Stadlan EM. 1984. Clinical diagnosis of alzheimer's disease: Report of the NINCDS-ADRDA work group under the auspices of department of health and human services task force on alzheimer's disease. *Neurology* 34(7):939-44.
- McKinlay A, Grace RC, Dalrymple-Alford JC, Roger D. 2009. Cognitive characteristics associated with mild cognitive impairment in parkinson's disease. *Dement Geriatr Cogn Disord* 28(2):121-9.
- Morris JC. 1993. The clinical dementia rating (CDR): Current version and scoring rules. *Neurology* 43(11):2412-4.
- Nishio Y, Hashimoto M, Ishii K, Mori E. 2011. Neuroanatomy of a neurobehavioral disturbance in the left anterior thalamic infarction. *J Neurol Neurosurg Psychiatry* .
- Petersen RC, Smith GE, Waring SC, Ivnik RJ, Tangalos EG, Kokmen E. 1999. Mild cognitive impairment: Clinical characterization and outcome. *Arch Neurol* 56(3):303-8.
- Roman GC, Erkinjuntti T, Wallin A, Pantoni L, Chui HC. 2002. Subcortical ischaemic vascular dementia. *Lancet Neurol* 1(7):426-36.
- Rosen WG, Terry RD, Fuld PA, Katzman R, Peck A. 1980. Pathological verification of ischemic score in differentiation of dementias. *Ann Neurol* 7(5):486-8.
- Ryu HG, Youn SW, Kwon OD. 2012. Lack of association between apolipoprotein E polymorphism with age at onset of subcortical vascular dementia. *Dement Geriatr Cogn Disord Extra* 2:1-9.
- Tatemichi TK, Desmond DW, Mayeux R, Paik M, Stern Y, Sano M, Remien RH, Williams JB, Mohr JP, Hauser WA. 1992. Dementia after stroke: Baseline frequency, risks, and clinical features in a hospitalized cohort. *Neurology* 42(6):1185-93.
- Wolfe N, Linn R, Babikian VL, Knoefel JE, Albert ML. 1990. Frontal systems impairment following multiple lacunar infarcts. *Arch Neurol* 47(2):129-32.
- Yesavage JA, Brink TL, Rose TL, Lum O, Huang V, Adey M, Leirer VO. 1982. Development and validation of a geriatric depression screening scale: A preliminary report. *J Psychiatr Res* 17(1):37-49.



Neuroscience

Edited by Dr. Thomas Heinbockel

ISBN 978-953-51-0617-3

Hard cover, 138 pages

Publisher InTech

Published online 23, May, 2012

Published in print edition May, 2012

If one asks what neuroscience is, the answer can be found in this book. Neuroscience embraces not only anatomical and physiological studies but also cell biology, computer science, and biochemistry. Equally important for neuroscientific research are other disciplines, such as psychology, psychiatry, neurology and additional recent ones, such as neuroeconomics and social neuroscience. This book comprises chapters on diverse topics in neuroscience ranging from cellular, computational, cognitive, and clinical neuroscience. Individual chapters focus on recent advances in specific areas including social neuroscience, which is a relatively new field that studies the neural basis of social interactions. Other chapters focus on technological developments such as optical tools to study the function of the brain. All chapters represent recent contributions to the rapidly developing field of neuroscience and illustrate the range of research conducted under the umbrella of the truly interdisciplinary neurosciences.

How to reference

In order to correctly reference this scholarly work, feel free to copy and paste the following:

Oh Dae Kwon (2012). Cognitive Features of Vascular Dementia, Neuroscience, Dr. Thomas Heinbockel (Ed.), ISBN: 978-953-51-0617-3, InTech, Available from: <http://www.intechopen.com/books/neuroscience/cognitive-features-of-vascular-dementia>

INTech
open science | open minds

InTech Europe

University Campus STeP Ri
Slavka Krautzeka 83/A
51000 Rijeka, Croatia
Phone: +385 (51) 770 447
Fax: +385 (51) 686 166
www.intechopen.com

InTech China

Unit 405, Office Block, Hotel Equatorial Shanghai
No.65, Yan An Road (West), Shanghai, 200040, China
中国上海市延安西路65号上海国际贵都大饭店办公楼405单元
Phone: +86-21-62489820
Fax: +86-21-62489821

© 2012 The Author(s). Licensee IntechOpen. This is an open access article distributed under the terms of the [Creative Commons Attribution 3.0 License](https://creativecommons.org/licenses/by/3.0/), which permits unrestricted use, distribution, and reproduction in any medium, provided the original work is properly cited.

IntechOpen

IntechOpen