

# We are IntechOpen, the world's leading publisher of Open Access books Built by scientists, for scientists

6,900

Open access books available

186,000

International authors and editors

200M

Downloads

Our authors are among the

154

Countries delivered to

TOP 1%

most cited scientists

12.2%

Contributors from top 500 universities



WEB OF SCIENCE™

Selection of our books indexed in the Book Citation Index  
in Web of Science™ Core Collection (BKCI)

Interested in publishing with us?  
Contact [book.department@intechopen.com](mailto:book.department@intechopen.com)

Numbers displayed above are based on latest data collected.  
For more information visit [www.intechopen.com](http://www.intechopen.com)



# Investigation of Experimental Wound Closure Techniques in Voice Microsurgery

C.B. Chng<sup>1</sup>, D.P.C. Lau<sup>2</sup>, J.Q. Choo<sup>1</sup> and C.K. Chui<sup>1</sup>

<sup>1</sup>*Department of Mechanical Engineering,  
National University of Singapore*

<sup>2</sup>*Department of Otolaryngology,  
Singapore General Hospital  
Singapore*

## 1. Introduction

Microsurgery on human vocal folds typically involves the removal of benign lesions, often results in the creation of wounds in the form of epithelial micro-flaps (Benninger, Alessi et al. 1996). Conventionally, these micro-flaps are left to epithelialize without formal closure, which can result in healing by secondary intention and increased scar tissue formation (Woo 1995; Thekdi and Rosen 2002). Scar tissue in the lamina propria of the vocal fold affects its visco-elastic and vibrational properties (Bless and Welham 2010), disrupting the mucosal wave and often manifesting as hoarseness and a reduction in the phonatory capabilities of the patient (Thibeault, Gray et al. 2002). Since the precision of epithelial approximation accomplished during the surgical procedure and retained during the healing process affects the amount of scar tissue formation (Woo 1995), wound closure is of particular interest in voice microsurgery.

Extensive work has focused on improving wound closure methods to minimize scar tissue formation, ranging from micro-suturing which allows for primary healing (Woo 1995; Tsuji, Nita et al. 2009), to the use of tissue adhesives like fibrin glue (Bleach, Milford et al. 1997; Flock 2005; Kitahara, Masuda et al. 2005; Finck, Harmegnies et al. 2010; Skodacek, Arnold et al. 2011), and the use of chemical agents (Campagnolo, Tsuji et al. 2010) like Mitomycin-C (Branski, Verdolini et al. 2006; Fonseca, Malafaia et al. 2010) or stem cells (Hong, Lee et al.) to enhance the healing process of vocal fold wounds. However, various challenges faced in the execution of voice microsurgery add to the complexity of wound closure. These include limitations in instrument movement imposed by the laryngoscope, reduced tactile feedback in surgical instruments and loss of stereopsis. These are just some of the common challenges that can add to the intricacy of the closure of a simple wound, resulting in an increase in operation duration and associated risks under general anesthesia.

With this in mind, experimental evaluations of proposed microsurgical techniques are a necessary step in their development and optimization. Due to the rarity of human specimens for experimentation, different animal and synthetic models have been utilized instead. In this chapter, we discuss various vocal fold wound closure techniques as well as the models and methods used to evaluate them experimentally.

## 2. Background

Common causes of voice problems include benign vocal fold lesions such as nodules, polyps and cysts. While these lesions are non-cancerous, they may result in impaired vocal fold closure and vibration, and reduction of voice quality. Removal of these lesions is often carried out surgically using microlaryngoscopic techniques.

### 2.1 Structure of the vocal fold

Current voice microsurgery techniques are based on Hirano's discovery of the layered structure of the vocal folds (Hirano 1974; Bleach, Milford et al. 1997; James B. Snow and Ballenger 2003). Based on his microscopic work, the vocal fold was found to have three well defined layers - the epithelium, lamina propria and vocalis muscle. The lamina propria was further subdivided into 3 layers, the superficial layer of the lamina propria (SLLP), intermediate layer and deep layer.

In the SLLP, elastin and collagen fibres are loosely arranged within a matrix, whereas dense elastin fibres make up most of the intermediate layer. Collagen is densely packed in the deep layer, providing most of the support for the lamina propria (James B. Snow and Ballenger 2003). Hirano also proposed a cover-body concept, providing an explanation for the vibratory characteristics of the vocal fold. Based on his theory, the cover (consisting of stratified squamous epithelium and the underlying SLLP) is attached to the body (consisting of the vocalis and thyroarytenoid muscles) by an elastic interface or ligament (composed of the intermediate and deep layers of the lamina propria), with an increasing stiffness from superficial to deep. This allows the cover to oscillate independently due to its elastic characteristics, resulting in the mucosal wave seen on stroboscopy and most of the vibratory dynamics required for good voice production and phonation (Hirano 1974).

### 2.2 Wound creation

Early treatments for benign vocal fold lesions consisted of stripping (de-epithelialization) of the entire vocal fold (Sataloff, Spiegel et al. 1995). The healing process after this method of treatment often resulted in significant vocal fold scar formation which causes a change in the stiffness and viscoelastic layered structure of the lamina propria. This inhibits normal vibration of the vocal fold, and can cause significant dysphonia and possible glottic incompetence. However with the discovery by Hirano of the layered structure of the vocal fold and its implications on healing, treatment is now focused on preserving as much of the normal vocal fold structures as possible (Hochman and Zeitels 2000; Fleming, McGuff et al. 2001; Thekdi and Rosen 2002; Burns, Hillman et al. 2009). Avoiding injury to the deeper structures is important during voice microsurgery to minimize vocal fold scarring and persistent post-operative hoarseness.

Current methods in voice microsurgery are divided into two main categories based on the surgical instruments used - either laser surgery or cold surgery. In laser surgery, a CO<sub>2</sub> laser is used to ablate tissue and for coagulation of the target region (Yan, Olszewski et al. 2010). Together with a micro-manipulator for precise cutting, the reduced blood loss during laser surgery enables a relatively clear view of the surgical field. Although studies have found no significant difference in surgical outcomes between laser and cold surgery (Zeitels 1996; Hormann, Baker-Schreyer et al. 1999; Benninger 2000), risk of thermal damage to surrounding tissues is still dependent on familiarity with the equipment and surgical

technique. This coupled with the increased cost of equipments, maintenance, additional personnel and their training (Yan, Olszewski et al. 2010), has driven the continued use of traditional “cold” voice microsurgery techniques.

Access to the vocal folds for microsurgery typically utilizes suspension laryngoscopy (Zeitels, Burns et al. 2004), where a rigid laryngoscope inserted via the patient’s oral cavity provides a direct view of the vocal folds. The laryngoscope is suspended over the patient’s chest, freeing the surgeon’s hands for operating. A binocular operating microscope is used to provide magnification. Due to the prohibitive space constraints of laryngoscopes, microlaryngeal instruments are thin and long to access the lesion while maximizing of the surgical field. A significant level of dexterity is needed to handle the microlaryngeal tools, especially considering the fragile structure of the vocal fold. However cold surgery allows for tactile feedback and is better utilized in techniques like the micro-flap excision of benign vocal fold lesions (Zeitels 1996), which we will focus on for the course of this chapter.

### 2.2.1 Microflap technique

The microflap technique has been accepted as the standard approach for cold surgical removal of benign vocal fold lesions (Ford 1999; Hochman and Zeitels 2000; Lee and Chiang 2009), achieving the main principles of vocal fold surgery by minimal tissue excision, minimal trauma to SLLP and epithelium. This technique typically involves the initial creation of an epithelial incision beside the lesion. Blunt dissection is used to elevate the microflap while taking care to minimise trauma to the deeper layers of the lamina propria. Only pathologic tissue is excised and the microflap is then reapproximated (Sataloff, Spiegel et al. 1995) as seen in Figure 1.

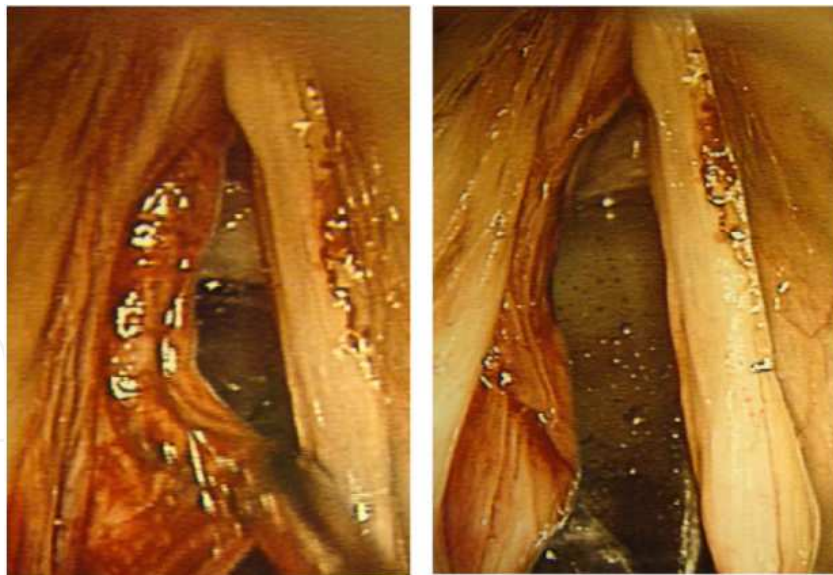


Fig. 1. Microflap technique in practise, (Left) after removal of benign lesion and (right) redraping of microflap.

### 2.3 Wound closure

Following excision of the lesion, the microflap is redraped to promote primary healing (Hochman and Zeitels 2000). If there is loss of epithelium or dislodgement of the microflap,

then healing can occur by secondary intention. In this case granulation tissue formation and epithelial migration occur (Woo 1995), and there is correspondingly more scar tissue formation. Voice rest is usually prescribed after surgery (Ishikawa and Thibeault 2010), but even with a totally compliant patient, apposition of epithelial flaps edges can be difficult to maintain. Thus various methods like micro-sutures and fibrin glue (Bleach, Milford et al. 1997; Flock 2005; Kitahara, Masuda et al. 2005; Finck, Harmegnies et al. 2010; Skodacek, Arnold et al. 2011) have been used to improve wound closure and minimize scar tissue formation.

### 2.3.1 Microsutures

The use of microsutures in vocal fold wound closure was proposed by Woo et al in 1995, hypothesizing that microsutures would allow precise positioning of wound edges and maintenance of the approximation (Woo 1995). This would reduce exposure of the wound site and permit primary healing to occur. They carried out the procedure in 18 patients, finding improved voice results after surgery. As there was no control group and basis for comparison in Woo et al's study, Fleming et al attempted to compare the amount of scar formation with and without microsutures in a canine model (Fleming, McGuff et al. 2001). A small sample group of 4 dogs were used, with bilateral microflap defects created in each dog. 6-0 fast absorbing gut sutures were used to close the microflap on only one side, leaving the contralateral side unclosed. The amount of scar was evaluated between 39 and 49 days post surgery. Un-sutured vocal folds were found to have at around 75% larger scar formation than sutured vocal folds, concurring with Woo et al's hypothesis that the use of microsutures improves postoperative wound healing.

Fleming et al also identified the length of time required for suture placement as the main disadvantage of this technique, suggesting that practice and familiarization with the technique using larger sutures before actual surgery could help mitigate the learning curve.

Tsuji et al recently proposed an improvement to the microsuture technique (Tsuji, Nita et al. 2009) by pre-tying a small length of 4-0 non-absorbable nylon suture to the free end of a 7-0 absorbable suture. The nylon acted as an anchor at the epithelial surface, preventing the thread from escaping and removing the need for an assistant surgeon to maintain tension on the free end of the suture. This improved the ease of performing the technique. Their new technique was tested on human cadaveric larynges for a total of 10 sutures and they reported a placement time of 5 to 7 minutes per suture.

### 2.3.2 Tissue adhesives

Despite good wound healing results demonstrated by micro-sutures, many surgeons prefer using adhesives to hold down epithelial flaps to achieve wound closure. Tissue adhesives such as cyanoacrylates and fibrin glue have been used (Flock 2005) and may be easier to apply than that of sutures. A potential limitation of tissue adhesives includes increased scar tissue formation if glue accumulates between the epithelial edges preventing proper approximation, or by adhering the epithelium to the underlying connective tissue without proper reformation of the intervening layered structure. Rapid curing can also restrict the surgeon from re-apposing malpositioned flaps. Lack of tensile strength of the adhesive is another concern. Fibrin glue can take several minutes for initiation of curing and several hours to develop its full strength. Especially during the curing phase it may not possess



sufficient tensile strength to withstand rupture of its bond (Woo 1995). As the vocal folds vibrate at high frequencies during speech, constant shearing against the adhesive glue causes wear and the resultant debris may impede the vibratory properties of the vocal fold or result in secondary intention healing and a broader scar.

### 3. Selection of animal models

Experimentation on live humans is not possible or ethical in most situations. Cadaveric human larynges are also difficult or expensive to obtain. Hence, when studying a new technique or device, an animal model can provide a systematic platform for the experimentation and validation. However due to differences in vocal fold size and structure, one animal may not suit all research requirements.

Depending on the research question to be addressed and the methodological approach, these differences can limit applicability of experimental results. Selection of an appropriate animal model needs careful consideration. Practical issues like size, availability of animal, availability of the facilities to house or carry out the procedures, procurement cost and maintenance of the animal for the duration of the study can restrict researchers from acquiring their ideal animal model.

Characteristics of particular interest when considering operative techniques include the size, shape and position of the larynx and other upper airway structures to simulate surgical access. Similarity of vocal fold shape and location is essential for testing microsurgical techniques, while similar tissue composition is necessary when assessing in-vivo behaviour of implanted materials and tissue responses.

Various animal models have been used extensively in vocal fold studies with their results compared across models (Garrett, Coleman et al. 2000; Jiang, Raviv et al. 2001; Titze and Alipour 2006; Alipour and Jaiswal 2007; Alipour and Jaiswal 2008; Bless and Welham 2010; Alipour, Jaiswal et al. 2011). Three of the more commonly used models in operative studies are rabbits (Thibeault, Gray et al. 2002; Thibeault, Bless et al. 2003; Branski, Rosen et al. 2005; Carneiro and Scapini 2009; Campagnolo, Tsuji et al. 2010), dogs (Garrett, Coleman et al. 2000; Fleming, McGuff et al. 2001; Rousseau, Hirano et al. 2003; Karajanagi, Lopez-Guerra et al. 2011) and pigs (Blakeslee, Banks et al. 1995; Garrett, Coleman et al. 2000; Jiang, Raviv et al. 2001; Alipour and Jaiswal 2008; Fonseca, Malafaia et al. 2010).

#### 3.1 Rabbit models

Due to their docile nature, relatively abundant numbers, ease of housing and management, rabbits are popular animal models. Rabbits are often used in immunological studies and exhibit similar vocal fold histology to humans. However access to rabbit vocal folds by standard suspension laryngoscopy is limited due to the smaller size of the rabbit larynx. Carneiro et al (Carneiro and Scapini 2009) used rabbits to study vocal fold grafts by exposing their vocal folds via a neck incision and laryngofissure. Branski et al (Branski, Rosen et al. 2005) studied the healing process of rabbit vocal fold after injury, using a neonatal laryngoscope to access the vocal fold. Campagnolo et al (Campagnolo, Tsuji et al. 2010) studied the healing effects of injectable corticosteroids after vocal fold surgery using a custom made laryngoscope for access.

### 3.2 Canine models

Canine models are used extensively in phonation studies. Comparing vocal fold structure across dogs, monkeys, pigs and human models using histology and laryngeal videostroboscopy, Garrett et al (Garrett, Coleman et al. 2000) found that unlike the human vocal fold, which has a higher elastin concentration in the deeper layers of the lamina propria, both pig and dog had a thin band of elastin concentrated just deep to the epithelial basement membrane zone. Just deep to this thin band, collagen and the elastin were less concentrated as in humans. The mucosal wave on stroboscopy was most similar between humans and canines and it was concluded that dog vocal folds were the most ideal for use in surgical studies due to its similarity in size, histology and mucosal wave. However, Fleming et al (Fleming, McGuff et al. 2001) noted that the slight differences in vocal fold structure like the thicker lamina propria and the lack of a well defined vocal ligament would have implications on its vibratory characteristics. Also, the higher cost and ethical considerations of using a companion animal for experimental studies are practical issues that need to be decided upon. Nevertheless, Fleming et al argued that as canine vocal fold healing was found to be similar to humans and similar human pathological conditions have been found to occur in canine models, they are still suitable for use in vocal fold microsurgery. Hahn et al (Hahn, Kobler et al. 2005; Hahn, Kobler et al. 2006; Hahn, Kobler et al. 2006) also compared collagen and elastin distribution in human, dog, pig and ferret larynges. They found that canine lamina propria collagen levels were most similar to those of humans, but on quantitative histology, elastin and collagen distribution in the human lamina propria was best matched by the porcine vocal fold.

### 3.3 Porcine models

Pigs are also common models for vocal fold studies. Based on our experience with pig models, the dimensions of the larynx in a 30 to 40 kg pig are similar to that of the adult human (Garrett, Coleman et al. 2000; Jiang, Raviv et al. 2001). The vocal folds have a similar configuration, and the intrinsic muscles and distribution of the recurrent laryngeal nerve is similar as demonstrated by detailed dissections of cadaveric porcine laryngeal neuromuscular anatomy (Knight, McDonald et al. 2005). Other phonatory characteristics such as rotational mobility of the cricothyroid joint, and relative size and innervation of the cricothyroid muscle have also been studied and found to be similar to that of humans (Jiang, Raviv et al. 2001); although these features are not of direct relevance to endoscopic laryngeal microsurgery.

An important difference between the pig and human vocal folds is that the pig has an additional fold in the vertical plane separated by a ventricle. The presence of a superior and inferior fold could relate to the thyroarytenoid muscle having two separate bellies (Knight, McDonald et al. 2005). It has been suggested that the inferior fold is the true vocal fold and the superior fold is akin to the ventricular fold in humans. However this remains a subject for debate as there is a further ventricle above the superior fold. It is suggested that vibration occurs at both folds as well as in the supraglottic structures during phonation (Kurita, Nagata et al. 1983; Alipour and Jaiswal 2008).

The pig larynx also differs in the structure of the arytenoid complex. The arytenoid cartilages have been described as fused across the posterior commissure, making laryngoscopic exposure more difficult (Garrett, Coleman et al. 2000). In addition to this, the arytenoids are also positioned more superiorly resulting in a steeper angle to the vocal folds.

However, from our experience with intubated animals, neither of these features created a significant hindrance to exposure or access to the vocal folds.

Regner used high-speed digital imaging to compare the vocal fold vibratory characteristics of ex-vivo bovine, canine, ovine, and porcine larynges with human vocal folds. By measuring amplitude, oscillation frequency, and phase difference of vocal fold vibration, it was concluded that canine and porcine larynges are the most appropriate models for vibratory or kinetic studies on phonation (Regner, Robitaille et al. 2010). Alipour also studied vibratory characteristics of excised pig, cow and sheep larynges, and concluded that the porcine larynx had the highest range of phonation frequencies, making it a good candidate for animal studies (Alipour and Jaiswal 2008).

In a similar study, Jiang et al. (Jiang, Raviv et al. 2001) concluded that pigs models provided the most similarity in vocal fold stiffness and was a reasonable alternative for phonation studies. As pigs are a common livestock, the high availability of pig larynges from local abattoirs poses less of an ethical concern for sacrificing animals for research purposes.

## **4. Ex-vivo experimental setups**

### **4.1 Using animal models**

Extensive ex-vivo experiments have been carried out for phonation studies (Regner and Jiang ; Jiang, Zhang et al. 2003; Skodacek, Arnold et al. 2011), for modeling the vibratory dynamics of the vocal folds. These experiments allow precise and independent control of various parameters affecting phonation, enabling systematic investigation and measurements of vocal fold vibrations.

A typical setup of such experimental systems consists of a mounting assembly, a pseudo lung, humidifiers, thermometers, flow and pressure meters. The mounting assembly where the excised larynx is housed consists of one lateral pronged micromanipulator sutured to the anterior tip of the thyroid cartilage and two other micromanipulators attached bilaterally to the arytenoid cartilages. This allows the elongation of the vocal folds to be controlled precisely. Airflow is generated by either an internal building source or a conventional compressor and is conditioned by heaters/humidifiers in order to prevent the larynges from drying out. The excised larynx is clamped directly to a tube from the pseudo lung and flowmeters and pressure meters are used to measure subglottal airflow and pressure before entry to the larynx. This experimental system can be easily adapted for use in ex-vivo surgical experimentation and can provide a platform to assess the effects of surgical procedures on vocal fold vibration.

### **4.2 Mechanical models**

Alternatively, a mechanical model was proposed by Choo et al (Choo, Lau et al. 2010) specifically for the simulation of experiments on the vocal fold. In their design, they proposed the use of agarose as a material substitute for human vocal folds, mapping the mechanical properties of agar concentrations to that of vocal fold cover and ligament. By repeated casting of different concentrations of agarose into a mould, the phantom vocal folds were designed to mimic the layered structure of the vocal fold. In addition, vocal fold vibration was actuated externally with the use of vibrators, allowing the control of the vocal fold vibration frequency. Glottal gap and airflow could also be customized.



Using stroboscopy, Choo et al observed vibratory dynamics in their mechanically driven model similar to that of the mucosal wave in human vocal folds. After simulating a microflap and then subjecting the vocal fold phantom to vibration, cracks were found propagating radially outwards. Both these features suggested that the setup had potential for surgical experimentation.

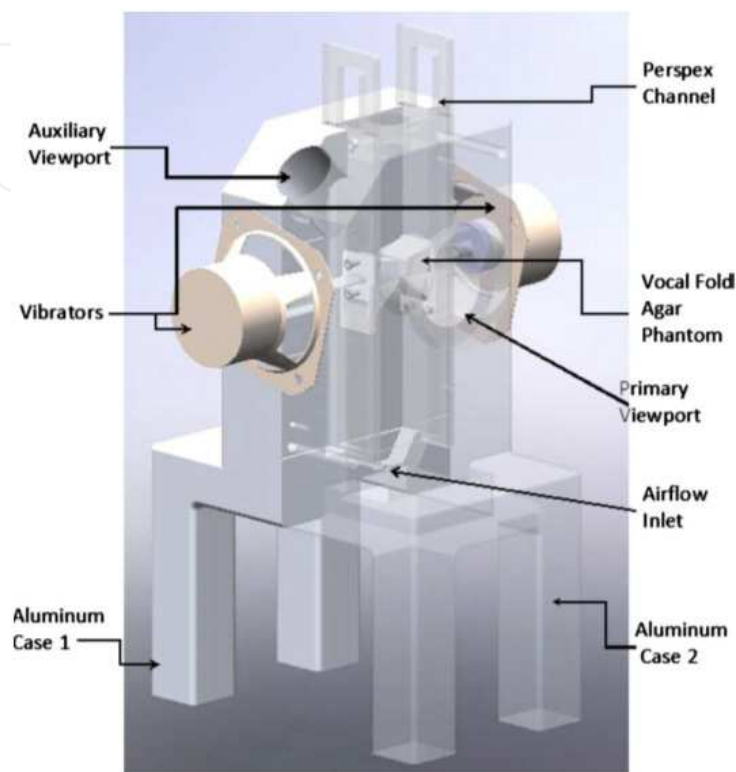


Fig. 2. Mechanical larynx setup courtesy of Choo et al (Choo, Lau et al. 2010).

## 5. New vocal fold wound closure device – Bioabsorbable microclips

A large part of our work is focused on the development of bioabsorbable surgical microclips for vocal fold wound closure. Based on combining the ease and efficiency of using fibrin glue with the precision of microsutures, such surgical microclips have the potential to reduce vocal fold scar and procedure time, cumulating in cost savings and reduced morbidity for patients.

Surgical clips have been used in various areas of the body but have not been described previously for use on the vocal folds. This may be due to challenges facing the design of a surgical clip for application in this area, including the need for extremely small size, ability to withstand high vibration frequencies and shearing stresses during phonation, and the need for bio-absorbability. A number of materials have been studied in the design of surgical clips in other areas. Stainless steel clips and materials such as titanium and tantalum have been used for example to ligate the cystic duct and artery in laparoscopic cholecystectomy (Charara, Dion et al. 1994) However, some limitations of these materials include significant foreign body reaction, poor holding power and significant interference with roentgenologic studies like computerized tomography (CT) and magnetic resonance imaging (Klein, Jessup et al. 1994; Min Tan and Okada 1999; Pietak, Staiger et al. 2006; Rosalbino, De Negri et al. 2010). The

introduction of ligating clips manufactured from novel polymers such as polydioxanone in laparoscopic cholecystectomy helped to address these limitations. These clips are completely absorbed in the process of ester bond hydrolysis over a period of 180 days and the by-products are excreted by urine. Moreover, these clips produce minimal tissue reactivity with good adhesion and are radiolucent (Klein, Jessup et al. 1994).

Earlier investigations using clips constructed from such polymers proved unsuitable for our requirements, as they could not provide adequate structural strength due to the minute size of the clips. As such, we are investigating the potential of using magnesium as the main bioabsorbable material to construct such microclips.

There are many reviews on the potential and viability of magnesium as a biomaterial (Pietak, Staiger et al. 2006; Witte, Hort et al. 2008; Zeng, Dietzel et al. 2008). Most of these studies focused on the use of magnesium in orthopaedic implants and bio-absorbable vascular stents, concentrating on improving its mechanical properties by alloying with various elements. Zhang et al. (Zhang and Yang 2008) reported significant improvement of both biocompatibility and mechanical properties with use of Zn as an additional alloying element to Mg-Si. Gu et al. (Gu, Zheng et al. 2009) reported good biocompatibility of magnesium with various alloying elements, recommending Al and Y for stents and Al, Ca, Zn, Sn, Si and Mn for orthopaedic implants. Drynda et al. (Drynda, Hassel et al. 2010) developed and evaluated fluoride coated Mg-Ca alloys for cardiovascular stents, reporting good biocompatibility and better degradation behaviour. However, as pure magnesium has been found to corrode too quickly in the low pH environment of physiological systems, much effort has also been placed into developing alloys or coatings to limit its degradation behaviour (Zeng, Dietzel et al. 2008). Rosalbino et al. (Rosalbino, De Negri et al. 2010) reported improved corrosion behaviour of Mg-Zn-Mn alloys for orthopaedic implants. Kannan et al. (Kannan and Raman 2008) studied the corrosion of AZ series (Al and Zn) magnesium alloys with the further addition of Ca, reporting significantly improved corrosion resistance with a reduction in mechanical properties (15% ultimate tensile strength and 20% elongation before fracture). Zhang et al. (Zhang, Zhang et al. 2009) reported the use of dual layer coatings of hydroxyapatite to considerably slow down the degradation of 99.9% pure magnesium substrates without heat treatment.

Based on the good biocompatibility and healing results demonstrated by these previous studies, we hypothesized that a bio-absorbable magnesium clip will be able to hold the wound site more securely and facilitate better healing as compared to surgical glue adhesives. Furthermore, with a design specifically aimed to reduce technical complexity in achieving apposition of epithelial flaps, a specifically designed prototype applicator could improve the ease of handling and speed of insertion, possibly translating to improved surgical outcomes. Due to the difficulty of simulating the vocal fold environment for both mechanical and bioabsorbability studies, in-vivo experiments were carried out to evaluate the feasibility of the clips in accordance to an approved protocol.

### 5.1 In-vivo evaluation of microclips

A 30-40 kg pig has upper airway dimensions that provide reasonable approximation to that of an adult human. Using this in-vivo model we were able to approach the larynx

using a standard adult operating laryngoscope (Promed 222mm operating laryngoscope, Tuttlingen, Germany). To simulate endoscopic laryngeal microsurgery, the pig was positioned supine with the cervical spine slightly flexed. The laryngoscope was passed trans-orally following intubation with a size 5 endotracheal tube. As in most mammals, the epiglottis is intra-nasal and must therefore be drawn down into the oropharynx in order to access the vocal folds during laryngoscopy; if per-oral intubation is performed, this is usually accomplished during intubation. The laryngoscope was suspended on a custom made frame that enabled adjustments to be made to the position of the scope's tip, so as to optimize visualization of the vocal folds. By combining this with a 400mm focal-length binocular microscope, the setup as seen in Figure 3 was close to that expected during surgery in an adult human.

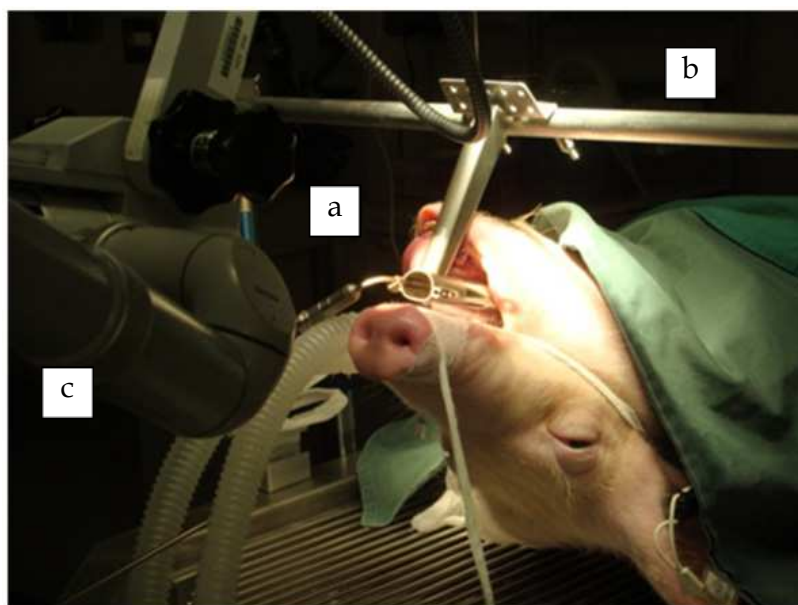


Fig. 3. Setup for endoscopic laryngeal microsurgery in the anaesthetized pig. (a) Operating laryngoscope. (b) Suspension device. (c) Binocular microscope.

A longitudinal incision was made on one or both vocal folds using a sickle knife. An epithelial flap was elevated using micro-forceps and a dissector. The flap was then replaced and secured with either micro-clips (3-6 clips on one side), microsuture or fibrin glue. The animal was monitored daily until the end of the three weeks study, after which the animal was sacrificed and its vocal fold excised for histological evaluation.

Feedback on the surgical procedure for the microclips was generally positive. Implantation time was found to be less than a minute per microclip due to the straightforward nature of the application technique. Due to the limited workspace within the laryngoscope, microsuturing was found to be more complex than applying the microclips, which greatly simplified approximation of the vocal fold wound edges. From preliminary results of the excised vocal folds after sacrificing the pigs, there was no damage found on the contralateral vocal folds, demonstrating the safety of the microclips. We are still awaiting histological results, but scar formation is comparable to that of using sutures based on visual inspection.

## 6. Conclusion

We have given an overview of the current techniques used clinically for vocal fold wound closure and an update on the potential of some microsurgical techniques proposed in current literature. Animal and artificial models have been discussed, highlighting the complexities of selecting appropriate experimental models and methods for evaluation of vocal fold microsurgery. We shared our experience in experimental microsurgery with respect to wound closure, specifically addressing the vocal fold microclip, which is a new wound closure device. The methods for testing the integrity and bio-absorption properties of such devices in vivo and the technical challenges of applying such devices accurately during microsurgery in the larynx were also discussed.

## 7. References

- Alipour, F. and S. Jaiswal (2008). "Phonatory characteristics of excised pig, sheep, and cow larynges." *J Acoust Soc Am* 123 (6): 4572-4581.
- Alipour, F., S. Jaiswal, et al. (2011). "Vocal Fold Elasticity in the Pig, Sheep, and Cow Larynges." *Journal of Voice* 25 (2): 130-136.
- Alipour, J. and S. Jaiswal (2007). "Glottal airflow resistance in excised pig, sheep and cow larynges." *Journal of Voice*.
- Benninger, M. S. (2000). "Microdissection or Microspot CO2 Laser for Limited Vocal Fold Benign Lesions: A Prospective Randomized Trial." *The Laryngoscope* 110 (S92): 1-1.
- Benninger, M. S., D. Alessi, et al. (1996). "Vocal fold scarring: Current concepts and management." *Otolaryngology - Head and Neck Surgery* 115 (5): 474-482.
- Blakeslee, D. B., R. E. Banks, et al. (1995). "Analysis of Vocal Fold Function in the Miniswine Model." *Journal of Investigative Surgery* 8 (6): 409-424.
- Bleach, N., C. Milford, et al., Eds. (1997). *Operative Otorhinolaryngology*, Blackwell Science Ltd.
- Bless, D. and N. Welham. (2010). "Characterization of vocal fold scar formation, prophylaxis, and treatment using animal models." 6. Retrieved 9417024, 18, from <http://ovidsp.ovid.com/ovidweb.cgi?T=JS&PAGE=reference&D=ovftl&NEWS=N&AN=00020840-201012000-00003>.
- Branski, R. C., C. A. Rosen, et al. (2005). "Acute vocal fold wound healing in a rabbit model." *Ann Otol Rhinol Laryngol* 114 (1 Pt 1): 19-24.
- Branski, R. C., K. Verdolini, et al. (2006). "Vocal Fold Wound Healing: A Review for Clinicians." *Journal of Voice* 20 (3): 432-442.
- Burns, J. A., R. E. Hillman, et al. (2009). "Phonomicrosurgical treatment of intracordal vocal-fold cysts in singers." *The Laryngoscope* 119 (2): 419-422.
- Campagnolo, A. M., D. H. Tsuji, et al. (2010). "Histologic study of acute vocal fold wound healing after corticosteroid injection in a rabbit model." *Ann Otol Rhinol Laryngol* 119 (2): 133-139.
- Carneiro, C. d. G. and F. Scapini (2009). "The Rabbit as an Experimental Model in Laryngology." *Arq. Int. Otorrinolaringol.* 13 (2): 146-150.
- Charara, J., Y. M. Dion, et al. (1994). "Mechanical characterization of endoscopic surgical staples during an experimental hernia repair." *Clinical Materials* 16 (Compendex): 81-89.

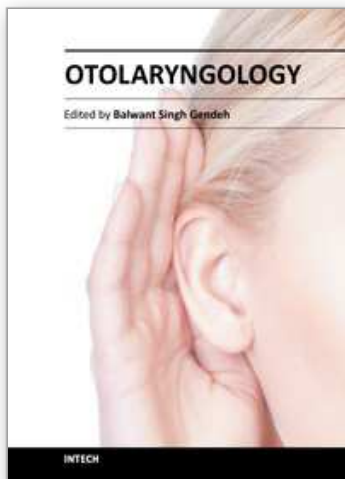


- Choo, J. Q., D. P. Lau, et al. (2010). "Design of a mechanical larynx with agarose as a soft tissue substitute for vocal fold applications." *J Biomech Eng* 132 (6): 065001.
- Drynda, A., T. Hassel, et al. (2010). "Development and biocompatibility of a novel corrodible fluoride-coated magnesium-calcium alloy with improved degradation kinetics and adequate mechanical properties for cardiovascular applications." *Journal of Biomedical Materials Research - Part A* 93 (Compendex): 763-775.
- Finck, C. L., B. Harmegnies, et al. (2010). "Implantation of Esterified Hyaluronic Acid in Microdissected Reinke's Space After Vocal Fold Microsurgery: Short- and Long-Term Results." *Journal of Voice* 24 (5): 626-635.
- Fleming, D. J., S. McGuff, et al. (2001). "Comparison of microflap healing outcomes with traditional and microsuturing techniques: initial results in a canine model." *Ann Otol Rhinol Laryngol* 110 (8): 707-712.
- Flock, S., Marchitto, KS (2005). "Progress toward seamless tissue fusion for wound closure." 38 (2005).
- Fonseca, V. R., O. Malafaia, et al. (2010). "Angiogenesis, fibrinogenesis and presence of synechiae after exeresis of a swine vocal fold mucosal microflap and use of topical mitomycin-C." *Acta Cir Bras* 25 (1): 80-85.
- Ford, C. N. (1999). "Advances and Refinements in Phonosurgery." *The Laryngoscope* 109 (12): 1891-1900.
- Garrett, C. G., J. R. Coleman, et al. (2000). "Comparative histology and vibration of the vocal folds: implications for experimental studies in microlaryngeal surgery." *Laryngoscope* 110 (5 Pt 1): 814-824.
- Gu, X., Y. Zheng, et al. (2009). "In vitro corrosion and biocompatibility of binary magnesium alloys." *Biomaterials* 30 (Compendex): 484-498.
- Hahn, M. S., J. B. Kobler, et al. (2006). "Quantitative and comparative studies of the vocal fold extracellular matrix. I: Elastic fibers and hyaluronic acid." *Ann Otol Rhinol Laryngol* 115 (2): 156-164.
- Hahn, M. S., J. B. Kobler, et al. (2005). "Midmembranous vocal fold lamina propria proteoglycans across selected species." *Ann Otol Rhinol Laryngol* 114 (6): 451-462.
- Hahn, M. S., J. B. Kobler, et al. (2006). "Quantitative and comparative studies of the vocal fold extracellular matrix II: collagen." *Ann Otol Rhinol Laryngol* 115 (3): 225-232.
- Hirano, M. (1974). "Morphological structure of the vocal cord as a vibrator and its variations." *Folia Phoniatr (Basel)* 26 (2): 89-94.
- Hochman, I. I. and S. M. Zeitels (2000). "Phonomicrosurgical management of vocal fold polyps: The subepithelial microflap resection technique." *Journal of Voice* 14 (1): 112-118.
- Hong, S. J., S. H. Lee, et al. "Vocal fold wound healing after injection of human adipose-derived stem cells in a rabbit model." *Acta Oto-laryngologica* 0 (0): 1-7.
- Hormann, K., A. Baker-Schreyer, et al. (1999). "Functional results after CO2 laser surgery compared with conventional phonosurgery." *J Laryngol Otol* 113 (2): 140-144.
- Ishikawa, K. and S. Thibeault (2010). "Voice Rest Versus Exercise: A Review of the Literature." *Journal of voice : official journal of the Voice Foundation* 24 (4): 379-387.
- James B. Snow, J. and J. J. Ballenger (2003). *Ballenger's Otorhinolaryngology Head and Neck Surgery*, BC Decker Inc.



- Jiang, J. J., J. R. Raviv, et al. (2001). "Comparison of the phonation-related structures among pig, dog, white-tailed deer, and human larynges." *Ann Otol Rhinol Laryngol* 110 (12): 1120-1125.
- Jiang, J. J., Y. Zhang, et al. (2003). "Nonlinear dynamics of phonations in excised larynx experiments." *J Acoust Soc Am* 114 (4 Pt 1): 2198-2205.
- Kannan, M. B. and R. K. S. Raman (2008). "In vitro degradation and mechanical integrity of calcium-containing magnesium alloys in modified-simulated body fluid." *Biomaterials* 29 (Compendex): 2306-2314.
- Karajanagi, S. S., G. Lopez-Guerra, et al. (2011). "Assessment of canine vocal fold function after injection of a new biomaterial designed to treat phonatory mucosal scarring." *Ann Otol Rhinol Laryngol* 120 (3): 175-184.
- Kitahara, S., Y. Masuda, et al. (2005). "Vocal fold injury following endotracheal intubation." *J Laryngol Otol* 119 (10): 825-827.
- Klein, R., G. Jessup, et al. (1994). "Comparison of titanium and absorbable polymeric surgical clips for use of laparoscopic cholecystectomy." *Surgical Endoscopy* 8 (1994).
- Knight, M. J., S. E. McDonald, et al. (2005). "Intrinsic muscles and distribution of the recurrent laryngeal nerve in the pig larynx." *Eur Arch Otorhinolaryngol* 262 (4): 281-285.
- Kurita, S., K. Nagata, et al. (1983). *A comparative study of the layer structure of the vocal fold*. San Diego, College Hill.
- Lee, K. W. and F. Y. Chiang (2009). "Current practice and feasibility in microlaryngeal surgery: microsurgical pressing excision technique." *Curr Opin Otolaryngol Head Neck Surg* 17 (6): 431-435.
- Min Tan, T. and M. Okada (1999). "The efficiency of absorbable clips in minimally invasive surgery." *Surgery Today* 29 (8): 828-831.
- Pietak, A. M., M. P. Staiger, et al. (2006). "Magnesium and its alloys as orthopedic biomaterials: A review." *Biomaterials* 27 (Copyright 2006, IEE): 1728-1734.
- Regner, M. F. and J. J. Jiang "Phonation Threshold Power in Ex Vivo Laryngeal Models." *Journal of Voice* In Press, Corrected Proof.
- Regner, M. F., M. J. Robitaille, et al. (2010). "Interspecies comparison of mucosal wave properties using high-speed digital imaging." *Laryngoscope* 120 (6): 1188-1194.
- Rosalbino, F., S. De Negri, et al. (2010). "Bio-corrosion characterization of Mg-Zn-X (X = Ca, Mn, Si) alloys for biomedical applications." *Journal of Materials Science: Materials in Medicine* 21 (Compendex): 1091-1098.
- Rousseau, B., S. Hirano, et al. (2003). "Characterization of vocal fold scarring in a canine model." *Laryngoscope* 113 (4): 620-627.
- Sataloff, R. T., J. R. Spiegel, et al. (1995). "Laryngeal mini-microflap: A new technique and reassessment of the microflap saga." *Journal of Voice* 9 (2): 198-204.
- Skodacek, D., U. Arnold, et al. (2011). "Chondrocytes suspended in modified fibrin glue for vocal fold augmentation: An in vitro study in a porcine larynx model." *Head & Neck*: n/a-n/a.
- Thekdi, A. A. and C. A. Rosen (2002). "Surgical treatment of benign vocal fold lesions." *Current Opinion in Otolaryngology & Head and Neck Surgery* 10 (6): 492-496.
- Thibeault, S. L., D. M. Bless, et al. (2003). "Interstitial protein alterations in rabbit vocal fold with scar." *Journal of Voice* 17 (3): 377-383.
- Thibeault, S. L., S. D. Gray, et al. (2002). "Histologic and Rheologic Characterization of Vocal Fold Scarring." *Journal of Voice* 16 (1): 96-104.

- Titze, I. and F. Alipour (2006). *The myoelastic aerodynamic theory of phonation*, National Center for Voice and Speech.
- Tsuji, D. H., L. M. Nita, et al. (2009). "T-Shaped Microsuture: A New Suture Technique for Laryngeal Microsurgery." *Journal of Voice* 23 (6): 739-742.
- Witte, F., N. Hort, et al. (2008). "Degradable biomaterials based on magnesium corrosion." *Current Opinion in Solid State & Materials Science* 12 (Copyright 2009, The Institution of Engineering and Technology): 63-72.
- Woo, P. (1995). "Endoscopic Microsuture Repair of Vocal Fold Defects." *Journal of Voice* 9 (3): 332-339.
- Yan, Y., A. E. Olszewski, et al. (2010). "Use of Lasers in Laryngeal Surgery." *Journal of Voice* 24 (1): 102-109.
- Zeitels, S. M. (1996). "Laser Versus Cold Instruments for Microlaryngoscopic Surgery." *The Laryngoscope* 106 (5): 545-552.
- Zeitels, S. M., J. A. Burns, et al. (2004). "Suspension laryngoscopy revisited." *Ann Otol Rhinol Laryngol* 113 (1): 16-22.
- Zeng, R., W. Dietzel, et al. (2008). "Progress and challenge for magnesium alloys as biomaterials." *Advanced Engineering Materials* 10 (Copyright 2008, The Institution of Engineering and Technology): B3-B14.
- Zhang, E. and L. Yang (2008). "Microstructure, mechanical properties and bio-corrosion properties of Mg-Zn-Mn-Ca alloy for biomedical application." *Materials Science and Engineering A* 497 (Compendex): 111-118.
- Zhang, Y., G. Zhang, et al. (2009). "Controlling the biodegradation rate of magnesium using biomimetic apatite coating." *Journal of Biomedical Materials Research - Part B Applied Biomaterials* 89 (Compendex): 408-414.



## **Otolaryngology**

Edited by Prof. Balwant Singh Gendeh

ISBN 978-953-51-0624-1

Hard cover, 198 pages

**Publisher** InTech

**Published online** 23, May, 2012

**Published in print edition** May, 2012

This book emphasizes on different aspects of otolaryngology - the medical sciences of diagnosis and treatment of ENT disorders. "Otolaryngology" is divided into various clinical sub-specialities, namely otology, rhinology, laryngology, and head and neck. This book incorporates new developments, as well as future perspectives in otolaryngology. I would like to dedicate this book to those of you who will pick up the torch and by continued research, close clinical observation and the highest quality of clinical care, as well as by publication and selfless teaching, further advance knowledge in otolaryngology from this point forward. It is intended to be a guide to other books to follow. Otolaryngologists, researches, specialists, trainees, and general practitioners with interest in otolaryngology will find this book interesting and useful.

### **How to reference**

In order to correctly reference this scholarly work, feel free to copy and paste the following:

C.B. Chng, D.P.C. Lau, J.Q. Choo and C.K. Chui (2012). Investigation of Experimental Wound Closure Techniques in Voice Microsurgery, Otolaryngology, Prof. Balwant Singh Gendeh (Ed.), ISBN: 978-953-51-0624-1, InTech, Available from: <http://www.intechopen.com/books/otolaryngology/experimental-investigation-of-wound-closure-techniques-for-voice-microsurgery>

**INTECH**  
open science | open minds

### **InTech Europe**

University Campus STeP Ri  
Slavka Krautzeka 83/A  
51000 Rijeka, Croatia  
Phone: +385 (51) 770 447  
Fax: +385 (51) 686 166  
[www.intechopen.com](http://www.intechopen.com)

### **InTech China**

Unit 405, Office Block, Hotel Equatorial Shanghai  
No.65, Yan An Road (West), Shanghai, 200040, China  
中国上海市延安西路65号上海国际贵都大饭店办公楼405单元  
Phone: +86-21-62489820  
Fax: +86-21-62489821

© 2012 The Author(s). Licensee IntechOpen. This is an open access article distributed under the terms of the [Creative Commons Attribution 3.0 License](https://creativecommons.org/licenses/by/3.0/), which permits unrestricted use, distribution, and reproduction in any medium, provided the original work is properly cited.

IntechOpen

IntechOpen