

# We are IntechOpen, the world's leading publisher of Open Access books Built by scientists, for scientists

6,900

Open access books available

186,000

International authors and editors

200M

Downloads

Our authors are among the

154

Countries delivered to

TOP 1%

most cited scientists

12.2%

Contributors from top 500 universities



WEB OF SCIENCE™

Selection of our books indexed in the Book Citation Index  
in Web of Science™ Core Collection (BKCI)

Interested in publishing with us?  
Contact [book.department@intechopen.com](mailto:book.department@intechopen.com)

Numbers displayed above are based on latest data collected.  
For more information visit [www.intechopen.com](http://www.intechopen.com)



# Endoscopic Dacryocystorhinostomy

Chris de Souza<sup>1</sup>, Rosemarie de Souza<sup>2\*</sup> and Jayesh Nisar<sup>3</sup>

<sup>1</sup>*Lilavati Hospital, Holy Family Hospital and Tata Memorial Hospital*

<sup>2</sup>*TNMC Medical College and the BYL Nair Hospital*

<sup>3</sup>*Gala Eye Hospital and Jain Health Center*

*Mumbai*

*India*

## 1. Introduction

Early cases of dacryocystitis occur because of inflammation of the mucous membrane with resulting malfunction in the subepithelial cavernous body with occlusion of the lacrimal passage. Repeated attacks of dacryocystitis leads to structural epithelial changes, with loss of mucin, loss of TFF peptide producing goblet cells and columnar epithelial cells. Remodeling of the helical arrangement of the subepithelial connective tissue fibers leads to total fibrous closure. This then leads to epiphora. Primary acquired nasolacrimal duct obstruction (PANDO) is a syndrome of unknown origin.

## 2. Diagnostics

Two basic causes of tearing exist. Epiphora that is associated with blockage of the lacrimal system and excessive lacrimation (hyperlacrimation) which is a less common cause. Hyperlacrimation is caused by corneal irritation. Unilateral hyper lacrimation is caused by trigeminal sensory nerve stimulation.

Epiphora is tearing caused by a reduced tear transport mechanism or a defective tear drainage outflow. Epiphora can on occasion be caused by a combination of both.

### 2.1 Goals of diagnostics are the following

1. To distinguish epiphora from hyperlacrimation.
2. Determine pathological process that is the cause.
3. To distinguish anatomical and functional disorders.
4. To evaluate the location of the block, its extent and to decide on the appropriate approach which is usually surgical.

### 2.2 The diagnostic tests are divided into the following

- a. Anatomical tests for investigation of morphological disorders and location of the site of obstruction as in punctal and canalicular pathologies, nasolacrimal duct obstruction (PANDO) and nasal pathologies.

---

\* Corresponding Author

- b. Functional (physiological) tests for drainage of tears under normal conditions as in lacrimal pump insufficiency due to incorrect eyelid closure,, ectropion , enteropion etc.
- c. Secretion: tests for assessment of secretion.

### **2.3 The clinical tests are the following**

Anatomical tests include palpation of the lacrimal sac, examination of the eyelids and condition of the puncta, syringing (irrigation), diagnostic probing, dacrycystography, nasal examination, and CT scanning and MRI.

Physiological tests are:- Fluorescein dye disappearance, scintigraphy Jones dye I, saccharin test.

Tests of secretion include:- Schirmirs tests, Bengal rose test, tear film break up and tear lysozyme test.

## **3. Surgery**

### **3.1 Endoscopic DCR surgery versus external DCR?**

Endoscopic DCR has gained wide spread acceptance and is now considered the surgical approach of choice (1), (2).

The reasons why the external approach has declined is because (a) There is a facial scar following External DCR and (b) It is difficult to revise.

Endoscopic DCR is attractive because

1. The results are equal to if not better than External DCR.
2. There is no facial scar.
3. It can be revised easily.
4. It can be performed on patients of all ages.
5. It can easily be learnt and can be done safely and reliably.
6. Small fibrotic lacrimal sacs which cannot be operated upon by the external approach can be operated upon using the endoscopic approach.
7. Complications like bleeding are much less.
8. Endoscopic DCRs take much less operating time.

### **3.2 The role of stents**

Stents can be used for small fibrotic lacrimal sacs to make sure that the neo-ostium remains patent (3). The authors prefer to reserve stents for this situation only because (1) Removal causes the opening to close, (2) The possibility of corneal opacity should the stent move its position. Surgery was successful as long as the stent was in situ. When stents were removed the sac obstructed again. Therefore the authors decided to leave the stents in situ indefinitely as long as there were no problems caused by the stent. An exact time frame for removal of the stents could not be given to patients.

## **4. The use of 5 fluorouracil and mitomicin**

The authors have found that these substances do not add to the success of patency in their series.

The authors in their series of over one thousand consecutive endoscopic DCRs found that the best technique for achieving consistently good reliable results was the removal of the medial wall of the lacrimal sac allowing it to heal in close conjunction with the mucosa of the nasal cavity. This was possible in a majority of cases as the lacrimal sac was large. When the lacrimal sac was small fibrosed and cicatrized stents were needed to maintain patency.

#### 4.1 Surgical technique

The surgeons preferred to operate under local anesthesia. An external block was given with .5% bupivacaine. The nasal cavity was anesthetized and decongested with 4% xylocaine cotton patties.

The area of the Agger Nasi air cells was infiltrated with 2% xylocaine with 1 in 200,000 adrenaline solution.

The flap anterior to the Middle turbinate was elevated. The periosteum was also elevated.

The lacrimal bone was drilled out with a large diamond polishing burr. A large osteotomy was performed until the entire limits of the lacrimal sac was seen and clearly identified. Once the lacrimal sac was clearly identified its medial wall was excised. Methyline blue was carefully and gently flushed from both puncta to ascertain clear passage through both puncta.

Once this was achieved then the medial wall of the lacrimal sac was removed. The medial wall was removed in such a way that it lies flush with the osteotomy. The nasal mucosa was then trimmed so that no bone was left bare. This step in particular is important because it has reduced the formation of granulomas. Care was taken such that the nasal flap did not cover the opening created in the lacrimal sac.

A pack was placed which can be removed 12 hours later.

The patient is instructed not to blow his nose. Careful nasal toilette ensures removal of crusts/ debris. This nasal toilette also prevents the occurrence of synechiae. The puncta are not flushed as the authors believe that this could result in trauma to the puncta which in turn could result in stenosis of the puncta.

#### 4.2 Goals of surgery

1. Cessation of Epiphora
2. Patency of the neo-ostium
3. There should be no further attacks of dacryocystitis.

#### 4.3 Results

The authors reported their results in a series of 1450 consecutive endoscopic DCRs using 4 different techniques from January 1994 to December 2007 (4).

In one set of patients they merely incised and drained the lacrimal sacs, in another they inserted grommets. In a third set they removed the medial wall of the LS and in a fourth set they inserted stents. All the data was then analyzed statistically.

It was found that the best results were achieved with removal of the medial wall allowing the LS to get marsupialized. Stenting the LS also provided good results but had the disadvantage of causing corneal opacities especially if the stent moved from its position(5).

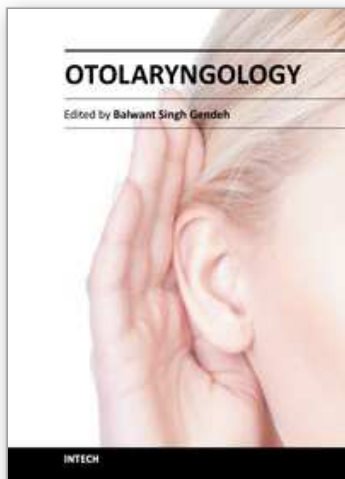
Inserting grommets or incising and draining the LS gave poor results. Removal of the medial wall of the LS allowing it to fistulize into the nasal cavity was statistically more successful and was found to be statistically significant.

## 5. Conclusions and summary

1. Endoscopic DCR is a safe and valid procedure
2. Results with endoscopic DCRs are excellent.
3. It can be revised easily.
4. It is cost effective
5. It is not associated with major complications.
6. Removal of the medial wall allowing the lacrimal sac to marsupialize into the nasal cavity is the best way to ensure long term patency.
7. Stenting is also effective but on occasion can cause corneal opacities especially when it is loosened.

## 6. References

- Feretis M, Newton JR, Ram B et al: Comparison of external and endonasal dacryocystorhinostomy. *Journal of Laryngology and Otology* 2008;20:1-5.
- Yigit O, Samancioglu M, Taskin U et al: External and endoscopic dacryocystorhinostomy in chronic dacryocystitis; comparison of results. *European Archives of Otorhinolaryngology* 2007; 264:879-885.
- Welsh MG, Katowitz JA: Timing of silastic tubing removal after intubation for congenital nasolacrimal duct obstruction. *Opthal Plastic Reconstr Surger.* 1989;5:43-48.
- De Souza CE, Nissar J: Experience with endoscopic dacryocystorhinostomy using four methods. *Otolaryngology- Head and Neck Surgery* 2010;142:389-393.
- Smirnov G, Tuomilehto H, Terasvirta M et al; Silicone tubing is not necessary after primary endoscopic dacryocystorhinostomy: a prospective randomized study. *American Journal of Rhinology* 2008; 22: 214-217.



## **Otolaryngology**

Edited by Prof. Balwant Singh Gendeh

ISBN 978-953-51-0624-1

Hard cover, 198 pages

**Publisher** InTech

**Published online** 23, May, 2012

**Published in print edition** May, 2012

This book emphasizes on different aspects of otolaryngology - the medical sciences of diagnosis and treatment of ENT disorders. "Otolaryngology" is divided into various clinical sub-specialities, namely otology, rhinology, laryngology, and head and neck. This book incorporates new developments, as well as future perspectives in otolaryngology. I would like to dedicate this book to those of you who will pick up the torch and by continued research, close clinical observation and the highest quality of clinical care, as well as by publication and selfless teaching, further advance knowledge in otolaryngology from this point forward. It is intended to be a guide to other books to follow. Otolaryngologists, researches, specialists, trainees, and general practitioners with interest in otolaryngology will find this book interesting and useful.

### **How to reference**

In order to correctly reference this scholarly work, feel free to copy and paste the following:

Chris de Souza, Rosemarie de Souza and Jayesh Nisar (2012). Endoscopic Dacryocystorhinostomy, Otolaryngology, Prof. Balwant Singh Gendeh (Ed.), ISBN: 978-953-51-0624-1, InTech, Available from: [http://www.intechopen.com/books/otolaryngology/endoscopic\\_dacryocystorhinostomy](http://www.intechopen.com/books/otolaryngology/endoscopic_dacryocystorhinostomy)

**INTech**  
open science | open minds

### **InTech Europe**

University Campus STeP Ri  
Slavka Krautzeka 83/A  
51000 Rijeka, Croatia  
Phone: +385 (51) 770 447  
Fax: +385 (51) 686 166  
[www.intechopen.com](http://www.intechopen.com)

### **InTech China**

Unit 405, Office Block, Hotel Equatorial Shanghai  
No.65, Yan An Road (West), Shanghai, 200040, China  
中国上海市延安西路65号上海国际贵都大饭店办公楼405单元  
Phone: +86-21-62489820  
Fax: +86-21-62489821

© 2012 The Author(s). Licensee IntechOpen. This is an open access article distributed under the terms of the [Creative Commons Attribution 3.0 License](#), which permits unrestricted use, distribution, and reproduction in any medium, provided the original work is properly cited.

IntechOpen

IntechOpen