

# We are IntechOpen, the world's leading publisher of Open Access books Built by scientists, for scientists

6,900

Open access books available

186,000

International authors and editors

200M

Downloads

Our authors are among the

154

Countries delivered to

TOP 1%

most cited scientists

12.2%

Contributors from top 500 universities



WEB OF SCIENCE™

Selection of our books indexed in the Book Citation Index  
in Web of Science™ Core Collection (BKCI)

Interested in publishing with us?  
Contact [book.department@intechopen.com](mailto:book.department@intechopen.com)

Numbers displayed above are based on latest data collected.  
For more information visit [www.intechopen.com](http://www.intechopen.com)



# Endometriosis-Associated Ovarian Cancer: The Role of Oxidative Stress

Yoriko Yamashita and Shinya Toyokuni  
*Nagoya University Graduate School of Medicine,  
Japan*

## 1. Introduction

Recent studies indicated that oxidative stress has a causal role in the carcinogenesis of mainly two histological subtypes of ovarian cancer, namely, clear cell carcinoma and endometrioid adenocarcinoma. Because of recurrent hemorrhage in endometrial cysts, excess of reactive oxygen species are produced due to iron deposition, which results in direct genomic mutation of the epithelial cells and exaggeration of oxidative stress by stromal cells such as macrophages. In endometriosis-associated ovarian cancer, genomic mutations in specific genes such as ARID1A, p53, K-ras, PTEN, PI3CA and Met have been reported. Mechanism of carcinogenesis, especially focusing on the precise role of oxidative stress, remains to be clarified. Development of novel drugs and methods for therapy or prevention of endometriosis-associated ovarian cancer is necessary.

## 2. Risk of cancer development in endometriosis

Endometriosis is a common disease affecting 10 to 15% of women of reproductive age (Irving, 2011). An association between endometriosis and cancer was reported as early as the 1920s in English publications. Sampson (Sampson, 1925) proposed that endometrial carcinoma of the ovary develops from endometrial tissue, based on classic microscopic observation using several strict criteria (i.e., the coexistence of benign and malignant tissue with a shared histologic relationship in the same organ and evidence against invasion from other sites or sources). Further studies were interrupted by World War II; however, in the late 1940s and 1950s, several groups published case reports that met Sampson's criteria (Scott, 1953; Postoloff & Rodenberg, 1955). Although none of the studies demonstrated any direct evidence, the consensus of the major researchers in the field at that time was that malignant transformation or transition occurred in ovarian endometriosis.

In 1990, Heaps et al. analyzed 195 cases that mostly fulfilled Sampson's criteria (Heaps, 1990). They found that the primary endometriosis site was most frequently the ovary (78.7%), followed by various other sites such as the pelvis, rectovaginal septum, colon or rectum, or the vagina. The most frequent histologic subtype was endometrioid adenocarcinoma in either of the primary sites, ovarian (69%) or extragonadal (66%), followed by clear cell carcinoma and sarcoma in 13.5% and 11.6% of ovarian tumors, respectively, and sarcomas in 25% of extragonadal tumors. More recently, an elevated risk of ovarian cancer development in endometriosis has been shown by statistical analyses. A

direct prospective study of 20,686 Swedish patients hospitalized with endometriosis between 1969 and 1983 with a mean follow-up period of 11.4 years demonstrated a standardized incidence ratio (SIR) of 1.9 and a 95% confidence interval [CI] of 1.3 to 2.8 (Brinton, 1997). Similar results were reported in a case-control study analyzing patients from the United States, in which the relative risk for ovarian cancer development in endometriosis patients was 1.7 (Ness, 2000). A nationwide case-control study of Australian patients with ovarian cancer revealed that endometriosis increased the risks of both endometrioid adenocarcinoma and clear cell carcinoma, with odds ratios of 3.0 and 2.2, respectively (Nagle, 2008). A recent retrospective study from Canada also showed a significant increase in the relative risk (rate ratio [RR], 1.6; 95% CI, 1.12 to 2.09) of ovarian cancer in patients with endometriosis (Aris, 2010). In line with these reports, a recent prospective study from Japan showed a significant and much greater elevation in the relative risk (SIR, 8.95; CI, 4.12 to 115.3) of cancer development in Japanese patients with endometrioma, or endometrial cyst of the ovary (Kobayashi, 2007). The reason for this discrepancy is unclear, but one possibility is that the endometriosis patients in the Japanese study included only those with clinically detectable ovarian endometrial cysts. It is also important to note that Danazol (17- $\alpha$ -ethinyltestosterone), a synthetic androgen that has been used to treat endometriosis, has been revealed to be an independent risk factor for the development of ovarian cancer. A negative correlation between oral contraceptive use and ovarian cancer, regardless of histologic type other than mucinous tumors, was recently shown by a collaboration of various groups worldwide (Cottreau, 2003). These factors may also influence the relative risk of ovarian cancer development.

In addition to an epidemiologic approach, the retrospective pathological analysis of samples from ovarian cancer patients is also useful to confirm the presence of endometriosis associated with ovarian cancers of various histological types. A comprehensive review of 2,807 ovarian cancer patients from 15 independent publications from western countries from the 1970s to 1990s, including 3 articles from Japan, revealed that endometriosis was incidentally found in 14.1% of ovarian cancer patients (39.2%, 21.2%, 3.3% and 3.0% of clear cell, endometrioid, serous and mucinous carcinoma patients, respectively), with a tendency toward a higher incidence of endometriosis in Japanese patients with clear cell carcinoma (Yoshikawa, 2000).

### **3. Pathogenesis of endometriosis-associated ovarian cancer; the role of iron overload-induced oxidative stress**

Endometrial cysts, or so-called chocolate cysts, are well-known lesions in endometriosis that contain fluid with an excess of free iron because of recurring hemorrhage in the cyst. It is interesting to note that Sampson mentioned in his first report of endometriosis-associated cancer that old hemorrhages should be considered additional evidence that meets his criteria (Sampson, 1925). Hemosiderin, heme, or iron deposition in endometriotic lesions have been assumed to trigger oxidative damage and chronic inflammation (Van Langendonck, 2002a; Van Langendonck, 2002b; Van Langendonck, 2004; Toyokuni, 2009). In particular, iron storage in macrophages is significantly increased in patients with endometriosis; and intracellular iron activates the nuclear factor- $\kappa$ B pathway and exaggerates chronic inflammation (Lousse, 2009; Lousse, 2008). As a result, prominent oxidative stress, or an excess of reactive oxygen species, is consistently produced. This

process is thought to have a causative role in endometriosis development and progression, leading to carcinogenesis (Murphy, 1998; Ness & Cottréau, 1999; Ngo, 2009). Alternatively, the high concentration of free iron in endometrial cysts may directly provide oxidative stress that induces genomic mutation in epithelial cells (Yamaguchi, 2008), and whether the direct pathway or the indirect pathway involving macrophages has a major role in carcinogenesis remains to be resolved. Iron overload in experimental animals enhances epithelial cell proliferation (Defrere, 2006) and causes malignant tumors with genomic abnormalities (Hu, 2010), which suggests a similar mechanism leading to carcinogenesis in human endometriosis (Fig. 1). However, further studies are awaited to elucidate the precise role of iron-deposition induced oxidative stress in carcinogenesis of endometriosis-associated cancer.

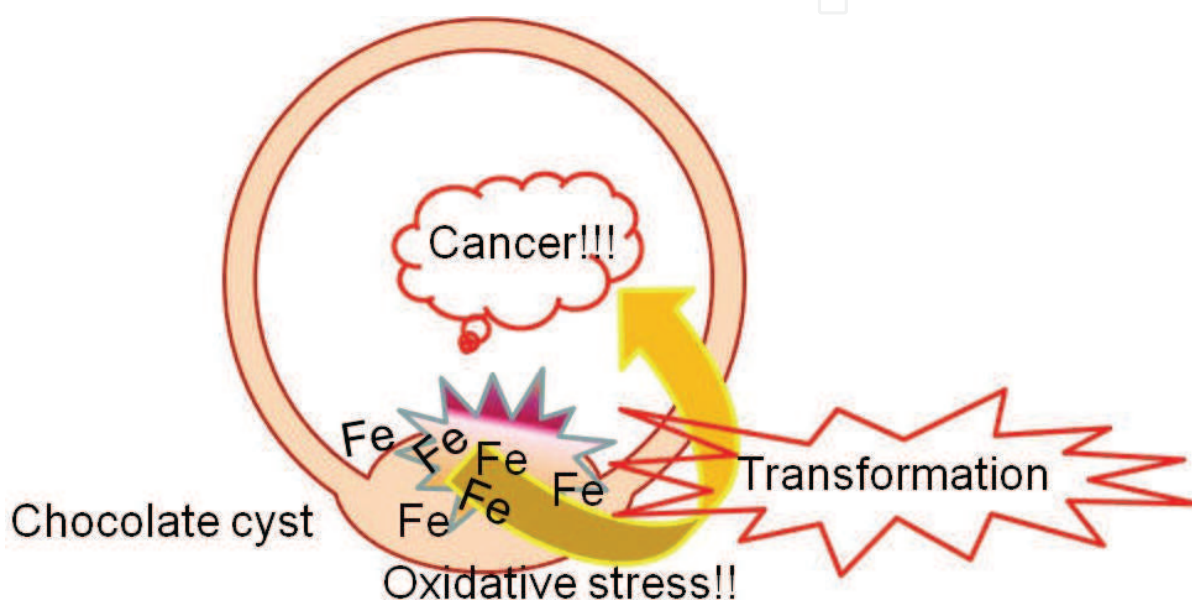


Fig. 1. A proposed mechanism of carcinogenesis in endometriotic (chocolate) cysts

#### 4. Precancerous lesions in endometriosis

Endometriosis itself is generally considered a benign disease; however, endometriosis shares certain features with cancer, including the ability of cells from different lineages (i.e., epithelial cells, stromal cells, and the vasculature) to proliferate in ectopic sites. Thus, earlier studies have focused on the clonal or malignant potential of endometriosis by analyzing the loss of heterozygosity (LOH) at several candidate tumor suppressor gene loci. Positive results, such as the detection of LOH at the p53, p16 or PTEN gene, were observed in the majority of the endometriosis samples ((Jiang, 1996; Jiang, 1998; Sato, 2000), for review of other studies with similar results, see (Prowse, 2005)). Another approach, which assesses the clonality of endometriosis samples by analyzing methylation-related marker genes, also demonstrated the clonal nature of endometriosis (Jimbo, 1997). The findings, together with the LOH analysis, led to the conclusion that endometriosis was a neoplasm that may even have malignant potential. However, recent studies deny the malignant or neoplastic potential of endometriosis, demonstrating that most endometriosis tissues are not monoclonal (Mayr, 2003). Furthermore, neither LOH of

tumor suppressor genes, promoter methylation of oncogenes, nor oncogenic mutations of known tumor-related genes was frequently observed in the majority of the cases, further denying the neoplastic theory (Prowse, 2005; Vestergaard AL, 2011). In contrast with these results, a third approach (fluorescent in situ hybridization [FISH]) used to investigate chromosomal aberrations in endometriosis samples revealed a significantly elevated proportion of aneusomic (monosomic > trisomic) cells in endometriosis in multiple groups (Koerner, 2006) (Bischoff, 2002). However, both endometriosis tissue and normal endometrium also contain a certain proportion of aneusomic cells (Koerner, 2006), and telomerase expression, telomere elongation, higher expression of DNA replication markers and lower expression of DNA damage response markers are all observed in endometriosis tissue, but not in normal endometrium (Hapangama, 2008; Hapangama, 2009). Thus, it may be reasonable to conclude that although endometriosis is generally considered non-neoplastic, the relative rates of abnormal cells are higher in endometriosis than in normal endometrium.

In this case, then, which cells are premalignant? Is there a focal area representing the precancerous state of endometriosis that is morphologically distinguishable from other, presumably benign, areas? "Atypical endometriosis" is the term used to describe this state, which has been found in cases of extraovarian and ovarian cancer as atypical epithelium showing hyperchromatism and stratification continuous with the malignant tumor (Brooks&Wheeler, 1977; Lagrenade&Silverberg, 1988). Fukunaga et al. found atypical endometriosis in 61% of endometriosis-associated ovarian cancers, in contrast with 1.7% of benign endometriosis samples (Fukunaga, 1997). Immunohistochemical markers distinguishing atypical endometriosis from benign endometriosis have not been fully established, but staining patterns of Ki67, Bcl-2, and p53 have been reported as useful markers (Nezhat, 2002; Ogawa, 2000). Extraovarian endometriosis may also show atypical changes. Hyperplastic changes, including atypical hyperplasia and malignant changes, were observed in more than half of the adenomyosis cases associated with endometrioid adenocarcinoma arising from the endometrium (Jacques&Lawrence, 1990; Kucera, 2011), and histologically atypical hyperplasia has been reported in some cases of gastrointestinal endometriosis (Yantiss, 2000).

## 5. Histological characteristics of endometriosis-associated malignancies

Clear cell carcinoma (Fig. 2) and endometrioid adenocarcinoma are well-known histological subtypes in ovarian cancer associated with endometriosis (Fukunaga, 1997; Heaps, 1990; Modesitt, 2002; Ogawa, 2000; Yoshikawa, 2000). Endometrioid adenocarcinoma is the most frequently observed phenotype in western countries (Heaps, 1990; Modesitt, 2002); however, clear cell carcinoma predominates in the Japanese cases (Ogawa, 2000; Yoshikawa, 2000). Veras et al. recently subdivided clear cell carcinoma into 3 groups (cystic, adenofibromatous, and indeterminate clear cell carcinoma) to further reveal the association between endometriosis and cystic clear cell carcinoma subtypes (Veras, 2009). Endometrioid adenocarcinomas arising in endometriotic lesions are often Grade 1 at presentation (Horiuchi, 2003), mostly showing typical morphology with various degrees of squamous differentiation (Heaps, 1990; Staats, 2007), similar to endometrioid adenocarcinoma without endometriosis. Sarcomas are the second and third most frequent endometriosis-associated

extraovarian and ovarian tumors, respectively. Adenosarcoma and endometrial stromal sarcoma are the major histological types of sarcomas (Baiocchi, 1990; Heaps, 1990; Slavin, 2000). At least partially, differences in the incidences of tumor types (carcinoma versus sarcoma) depend on the tumor site, and further studies are needed to elucidate this mechanism. Other rare malignant tumors, such as squamous cell carcinoma, malignant mesodermal mixed tumor, and yolk sac tumor, are also reported to develop from endometriosis (Irving, 2011). Although its incidence is very low compared with endometrioid adenocarcinoma or clear cell carcinoma, serous adenocarcinoma has also been associated with endometriosis (Fukunaga, 1997; Modesitt, 2002; Yoshikawa, 2000). Much more rarely, mucinous carcinomas with unusual morphology resembling Mullerian mucinous borderline tumors have also been reported in association with endometriosis (Lee&Nucci, 2003).

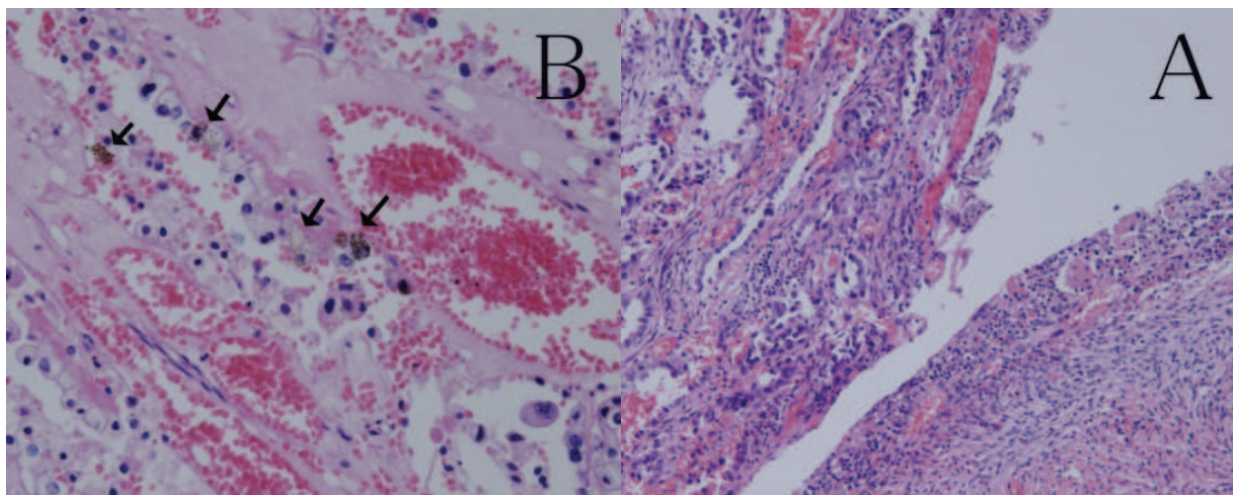


Fig. 2. A. Clear cell carcinoma (left) arising in a endometriotic cyst. B. Hemosiderin deposition (arrows) is observed in the stroma of clear cell carcinoma.

## 6. Genetic abnormalities and phenotypes of endometriosis-associated ovarian cancer

Genetic mutations specifically associated with ovarian cancer subtypes have been reported (reviewed by (Kurman&Shih, 2011)). Focusing on endometrioid adenocarcinomas, genetic mutations of K-ras, p53, PTEN, beta-catenin, and ATR have been reported (Mizuuchi, 1992; Milner, 1993; Palacios&Gamallo, 1998; Tashiro, 1997; Zigelboim, 2009). Mouse models of endometrioid adenocarcinoma have been reported, either with oncogenic K-ras and conditional PTEN deletion (Dinulescu, 2005) or dysfunction of both the Wnt/beta-catenin and PI3CA/PTEN pathways (Wu, 2007). However, specific genetic alterations of clear cell carcinoma were mostly unknown. Recently, a frequently activated mutation of the PI3CA gene was observed in clear cell carcinoma samples (Kuo, 2009). Most recently, several studies based on novel sequencing technology have elucidated that a significant proportion of clear cell carcinomas harbor a mutation of the ARID1A gene, which encodes the chromatin-remodeling complex protein BAF250A (Jones, 2010; Wiegand, 2010). ARID1A mutation and the consequent loss of BAF250A expression were found not only in clear cell carcinoma samples, but also in endometrioid adenocarcinomas, especially high-grade types

(Wiegand 2010; Wiegand, 2011). Whether ARID1A mutation is an early or late event in endometriosis-associated ovarian cancers related to atypical endometriosis remains to be elucidated. Alterations of other genes, such as p53, p16, and PTEN, have been detected in a low percentage of endometriotic lesions (Martini, 2002; Nezhat, 2008). hMLH, a DNA mismatch repair gene, is another candidate for the malignant transformation of endometriosis (Nyiraneza, 2010 ; Ren F, 2011). hMLH is the causal gene of Lynch syndrome, in which the risk of developing endometrial and ovarian cancers is significantly increased (Schmeler&Lu, 2008). K-ras may also be important because mutated K-ras promotes endometriosis in a mouse model, suggesting that K-ras mutation may be an early event in the carcinogenesis of endometriosis-associated cancers (Cheng, 2011). Finally, a single-nucleotide polymorphism in the intron of ANRIL, a non-coding RNA that regulates p16 expression, has been recently reported to have a strong association with endometriosis (Uno, 2010). The molecular steps from endometriosis development to carcinogenesis remain to be further clarified.

Recent studies have proposed classifying ovarian cancers into two categories: Type I tumors, which rarely harbor the p53 mutation and have an indolent clinical course, and Type II tumors, which feature the p53 mutation and are aggressive (Kurman&Shih, 2010). Within endometriosis-associated ovarian cancers, low-grade endometrioid adenocarcinoma and clear cell carcinomas are considered Type I, while high-grade endometrioid adenocarcinoma is included in the Type II category. However, p53 mutations are detected in both low- and high-grade endometriosis-associated ovarian endometrioid adenocarcinomas (Okuda, 2003), and PI3CA, PPP2R1A, and K-ras mutations are commonly detected in both endometrioid adenocarcinoma and clear cell carcinoma (Campbell, 2004; Jones, 2010 ; Kuo, 2009; McConechy, 2011 ; Mizuuchi, 1992). Recent evidence indicates that ovarian cancers arise from different cell lineages, such as preexisting cystadenomas, ectopic endometrium in endometriotic lesions, and epithelial cells of the Fallopian tubes (Bell, 2005; Kurman&Shih, 2011). Thus, it may be an oversimplification to divide all ovarian cancers into two groups. It may more accurate to categorize endometriosis-associated cancers into the same group, regardless of the histological subtype or tumor grade.

Numerous studies of expression microarray analyses have been published. Cytokines and chemokines, such as interleukin-1 and its downstream factor cyclooxygenase (COX)-2, interleukin-8, TNF- $\alpha$  and its downstream VEGF, TGF- $\alpha$ , and interleukin-6 have been reported to be involved in endometriosis and endometriosis-associated carcinoma (reviewed by (Nezhat, 2008)). An interesting study by Banz et al. revealed that SICA2, CCL14, and TDGF1 were specifically upregulated in both endometriosis samples and endometriosis-associated endometrioid adenocarcinomas, in contrast with serous adenocarcinomas or normal ovarian tissues (Banz, 2010). Another microarray study focusing on endometriosis-associated clear cell carcinoma showed upregulation of hepatocyte nuclear factor (HNF)-1 $\beta$ , versican, and other markers related to oxidative stress (Yamaguchi, 2010). HNF-1 $\beta$  is a transcription factor, involved in the regulation of glucose homeostasis and glycogen accumulation, normally expressed in the liver and other organs, which is assumed to have some role in the pathogenesis of clear cell carcinoma of the ovary (Kobayashi, 2009). Recently, a novel attempt to classify

histological subtypes using a small number of biomarkers has been applied to ovarian cancers. A tissue microarray-based analysis selected 21 markers, including CA125, estrogen receptor (ER), insulin-like growth factor 2 (IGF2), Ki-67, p21, p53, progesterone receptor (PGR), and Wilms tumor 1 (WT1), to distinguish histological subtypes; however, only three of the 21 markers could predict outcomes in only high-grade serous carcinoma patients (Koebel, 2008). More recently, however, Kalloger et al. succeeded in reproductively diagnosing five major subtypes of ovarian cancers (high-grade serous, clear cell, endometrioid, mucinous, and low-grade serous) using only nine markers: p16, DKK1 (a Wnt antagonist), HNF-1 $\beta$ , MDM2, PGR, trefoil factor 3 (TFF3), p53, vimentin, and WT1 (Kalloger, 2011). Immunohistochemical analysis of 155 cases by De Lair et al demonstrated that 89% of clear cell carcinoma had HNF-1 $\beta$  positive, ER, PGR, and WT1 negative phenotype (DeLair, 2011).

## 7. Prognosis of endometriosis-associated ovarian cancer

Clear cell adenocarcinoma is known to be associated with chemoresistance and a poor prognosis (Itamochi, 2008). However, most reports analyzing the prognosis of endometriosis-associated ovarian carcinomas (including mostly endometrioid adenocarcinoma and few clear cell carcinoma samples) have shown that endometriosis-associated ovarian carcinomas presented at younger ages, in lower grades and stages, and had significantly better overall survival compared with age-matched controls without endometriosis (Erzen, 2001; Kumar, 2011; Melin, 2011 ; Orezza, 2008). However, recent studies from various countries indicate that clear cell carcinomas consist of heterogeneous tumors with gene alterations, such as HER2 or Met gene amplification (Tan, 2011 ; Yamamoto, 2011; Yamashita, 2011). Therefore, clear cell carcinomas as a subtype are considered to have a worse prognosis than endometrioid adenocarcinomas, especially in Asian cases (Lee, 2011). Recently, the first international symposium of ovarian clear cell carcinoma concluded that although patients with low-stage clear cell carcinoma had a better prognosis than matched controls with high-grade serous carcinoma, high-stage clear cell carcinoma cases had the worst prognosis (Anglesio, 2010). Thus, alternative therapy, such as molecular targeted therapy, should be applied to these aggressive tumors, and a further understanding of the basic biology of the endometriosis-cancer progression, especially the role of oxidative stress, is necessary to prevent carcinogenesis in endometriosis patients (Aris, 2010).

## 8. Conclusion

We have reviewed the literature on endometriosis-associated ovarian cancer. Further studies are awaited to clarify the exact role of oxidative stress in carcinogenesis.

## 9. References

- Anglesio, M. S., Carey, M. S., Koebel, M., MacKay, H. and Huntsman, D. G. (2010). Clear cell carcinoma of the ovary: A report from the first Ovarian Clear Cell Symposium, June 24th, 2010. *Gynecologic Oncology* 121, 407-415.
- Aris, A. (2010). Endometriosis-associated ovarian cancer: A ten-year cohort study of women living in the Estrie Region of Quebec, Canada. *Journal of Ovarian Research* 3, 2.

- Baiocchi, G., Kavanagh, J. J. and Wharton, J. T. (1990). Endometrioid Stromal Sarcomas Arising from Ovarian and Extraovarian Endometriosis - Report of 2 Cases and Review of the Literature. *Gynecologic Oncology* 36, 147-151.
- Banz, C., Ungethuem, U., Kuban, R.-J., Diedrich, K., Lengyel, E. and Hornung, D. (2010). The molecular signature of endometriosis-associated endometrioid ovarian cancer differs significantly from endometriosis-independent endometrioid ovarian cancer. *Fertility and Sterility* 94, 1212-1217.
- Bell, D. A. (2005). Origins and molecular pathology of ovarian cancer. *Modern Pathology* 18, S19-S32.
- Bischoff, F. Z., Heard, M. and Simpson, J. L. (2002). Somatic DNA alterations in endometriosis: high frequency of chromosome 17 and p53 loss in late-stage endometriosis. *Journal of Reproductive Immunology* 55, 49-64.
- Brinton, L. A., Gridley, G., Persson, I., Baron, J. and Bergqvist, A. (1997). Cancer risk after a hospital discharge diagnosis of endometriosis. *American Journal of Obstetrics and Gynecology* 176, 572-579.
- Brooks, J. J. and Wheeler, J. E. (1977). Malignancy Arising in Extra-Gonadal Endometriosis - Case-Report and Summary of World Literature. *Cancer* 40, 3065-3073.
- Campbell, I. G., Russell, S. E., Choong, D. Y. H., Montgomery, K. G., Ciavarella, M. L., Hooi, C. S. F., Cristiano, B. E., Pearson, R. B. and Phillips, W. A. (2004). Mutation of the PIK3CA gene in ovarian and breast cancer. *Cancer Research* 64, 7678-7681.
- Cheng, C.-w., Licence, D., Cook, E., Luo, F., Arends, M. J., Smith, S. K., Print, C. G. and Charnock-Jones, D. S. (2011). Activation of mutated K-ras in donor endometrial epithelium and stroma promotes lesion growth in an intact immunocompetent murine model of endometriosis. *Journal of Pathology* 224, 261-269.
- Cottreau, C. M., Ness, R. B., Modugno, F., Allen, G. O. and Goodman, M. T. (2003). Endometriosis and its treatment with danazol or lupron in relation to ovarian cancer. *Clinical Cancer Research* 9, 5142-5144.
- Defrere, S., Van Langendonckt, A., Vaesen, S., Jouret, M., Ramos, R. G., Gonzalez, D. and Donnez, J. (2006). Iron overload enhances epithelial cell proliferation in endometriotic lesions induced in a murine model. *Human Reproduction* 21, 2810-2816.
- DeLair, D., Oliva, E., Koebel, M., Macias, A., Gilks, C. B. and Soslow, R. A. (2011). Morphologic Spectrum of Immunohistochemically Characterized Clear Cell Carcinoma of the Ovary: A Study of 155 Cases. *American Journal of Surgical Pathology* 35, 36-44.
- Dinulescu, D. M., Ince, T. A., Quade, B. J., Shafer, S. A., Crowley, D. and Jacks, T. (2005). Role of K-ras and Pten in the development of mouse models of endometriosis and endometrioid ovarian cancer. *Nature Medicine* 11, 63-70.
- Erzen, M., Rakar, S., Klancar, B. and Syrjanen, K. (2001). Endometriosis-associated ovarian carcinoma (EAOC): An entity distinct from other ovarian carcinomas as suggested by a nested case-control study. *Gynecologic Oncology* 83, 100-108.
- Fukunaga, M., Nomura, K., Ishikawa, E. and Ushigome, S. (1997). Ovarian atypical endometriosis: Its close association with malignant epithelial tumours. *Histopathology* 30, 249-255.
- Hapangama, D. K., Turner, M. A., Drury, J. A., Quenby, S., Hart, A., Maddick, M., Martin-Ruiz, C. and von Zglinicki, T. (2009). Sustained replication in endometrium of

- women with endometriosis occurs without evoking a DNA damage response. *Human Reproduction* 24, 687-696.
- Hapangama, D. K., Turner, M. A., Drury, J. A., Quenby, S., Saretzki, G., Martin-Ruiz, C. and Von Zglinicki, T. (2008). Endometriosis is associated with aberrant endometrial expression of telomerase and increased telomere length. *Human Reproduction* 23, 1511-1519.
- Heaps, J. M., Nieberg, R. K. and Berek, J. S. (1990). Malignant Neoplasms Arising in Endometriosis. *Obstetrics and Gynecology* 75, 1023-1028.
- Horiuchi, A., Itoh, K., Shimizu, M., Nakai, I., Yamazaki, T., Kimura, K., Suzuki, A., Shiozawa, I., Ueda, N. and Konishi, I. (2003). Toward understanding the natural history of ovarian carcinoma development: a clinicopathological approach. *Gynecologic Oncology* 88, 309-317.
- Hu, Q., Akatsuka, S., Yamashita, Y., Ohara, H., Nagai, H., Okazaki, Y., Takahashi, T. and Toyokuni, S. (2010). Homozygous deletion of CDKN2A/2B is a hallmark of iron-induced high-grade rat mesothelioma. *Laboratory Investigation* 90, 360-373.
- Irving, J. A., Clement, P. B. (2011). Diseases of the Peritoneum. *Blaustein's Pathology of the Female Genital Tract. Sixth Edition*.
- Itamochi, H., Kigawa, J. and Terakawa, N. (2008). Mechanisms of chemoresistance and poor prognosis in ovarian clear cell carcinoma. *Cancer Science* 99, 653-658.
- Jacques, S. M. and Lawrence, W. D. (1990). Endometrial Adenocarcinoma with Variable-Level Myometrial Involvement Limited to Adenomyosis - a Clinicopathological Study of 23 Cases. *Gynecologic Oncology* 37, 401-407.
- Jiang, X. X., Hitchcock, A., Bryan, E. J., Watson, R. H., Englefield, P., Thomas, E. J. and Campbell, I. G. (1996). Microsatellite analysis of endometriosis reveals loss of heterozygosity at candidate ovarian tumor suppressor gene loci. *Cancer Research* 56, 3534-3539.
- Jiang, X. X., Morland, S. J., Hitchcock, A., Thomas, E. J. and Campbell, I. G. (1998). Allelotyping of endometriosis with adjacent ovarian carcinoma reveals evidence of a common lineage. *Cancer Research* 58, 1707-1712.
- Jimbo, H., Hitomi, Y., Yoshikawa, H., Yano, T., Momoeda, M., Sakamoto, A., Tsutsumi, O., Taketani, Y. and Esumi, H. (1997). Evidence for monoclonal expansion of epithelial cells in ovarian endometrial cysts. *American Journal of Pathology* 150, 1173-1178.
- Jones, S., Wang, T.-L., Shih, I.-M., Mao, T.-L., Nakayama, K., Roden, R., Glas, R., Slamon, D., Diaz, L. A., Jr., Vogelstein, B., Kinzler, K. W., Velculescu, V. E. and Papadopoulos, N. (2010). Frequent Mutations of Chromatin Remodeling Gene ARID1A in Ovarian Clear Cell Carcinoma. *Science* 330, 228-231.
- Kalloger, S. E., Koebel, M., Leung, S., Mehl, E., Gao, D., Marcon, K. M., Chow, C., Clarke, B. A., Huntsman, D. G. and Gilks, C. B. (2011). Calculator for ovarian carcinoma subtype prediction. *Modern Pathology* 24, 512-521.
- Kobayashi, H., Sumimoto, K., Moniwa, N., Imai, M., Takakura, K., Kuromaki, T., Morioka, E., Arisawa, K. and Terao, T. (2007). Risk of developing ovarian cancer among women with ovarian endometrioma: a cohort study in Shizuoka, Japan. *International Journal of Gynecological Cancer* 17, 37-43.
- Kobayashi, H., Yamada, Y., Kanayama, S., Furukawa, N., Noguchi, T., Haruta, S., Yoshida, S., Sakata, M., Sado, T. and Oi, H. (2009). The Role of Hepatocyte Nuclear Factor-1

- beta in the Pathogenesis of Clear Cell Carcinoma of the Ovary. *International Journal of Gynecological Cancer* 19, 471-479.
- Koebel, M., Kalloger, S. E., Boyd, N., McKinney, S., Mehl, E., Palmer, C., Leung, S., Bowen, N. J., Ionescu, D. N., Rajput, A., Prentice, L. M., Miller, D., Santos, J., Swenerton, K., Gilks, C. B. and Huntsman, D. (2008). Ovarian Carcinoma Subtypes Are Different Diseases: Implications for Biomarker Studies. *PLoS Medicine* 5, 1749-1760.
- Koerner, M., Burckhardt, E. and Mazzucchelli, L. (2006). Higher frequency of chromosomal aberrations in ovarian endometriosis compared to extragonadal endometriosis: a possible link to endometrioid adenocarcinoma. *Modern Pathology* 19, 1615-1623.
- Kucera, E., Hejda, V., Dankovcik, R., Valha, P., Dudas, M. and Feyereisl, J. (2011). Malignant changes in adenomyosis in patients with endometrioid adenocarcinoma. *European Journal of Gynaecological Oncology* 32, 182-184.
- Kumar, S., Munkarah, A., Arabi, H., Bandyopadhyay, S., Semaan, A., Hayek, K., Garg, G., Morris, R. and Ali-Fehmi, R. (2011). Prognostic analysis of ovarian cancer associated with endometriosis. *American Journal of Obstetrics and Gynecology* 204, 7.
- Kuo, K. T., Mao, T. L., Jones, S., Veras, E., Ayhan, A., Wang, T. L., Glas, R., Slamon, D., Velculescu, V. E., Kuman, R. J. and Shih, I. M. (2009). Frequent Activating Mutations of PIK3CA in Ovarian Clear Cell Carcinoma. *American Journal of Pathology* 174, 1597-1601.
- Kurman, R. J. and Shih, I.-M. (2010). The Origin and Pathogenesis of Epithelial Ovarian Cancer: A Proposed Unifying Theory. *American Journal of Surgical Pathology* 34, 433-443.
- Kurman, R. J. and Shih, I. M. (2011). Molecular pathogenesis and extraovarian origin of epithelial ovarian cancer-Shifting the paradigm. *Human Pathology* 42, 918-931.
- Lagrenade, A. and Silverberg, S. G. (1988). Ovarian-Tumors Associated with Atypical Endometriosis. *Human Pathology* 19, 1080-1084.
- Lee, K. R. and Nucci, M. R. (2003). Ovarian mucinous and mixed epithelial carcinomas of mullerian (endocervical-like) type: A clinicopathologic analysis of four cases of an uncommon variant associated with endometriosis. *International Journal of Gynecological Pathology* 22, 42-51.
- Lee, Y.-Y., Kim, T.-J., Kim, M.-J., Kim, H.-J., Song, T., Kim, M. K., Choi, C. H., Lee, J.-W., Bae, D.-S. and Kim, B.-G. (2011). Prognosis of ovarian clear cell carcinoma compared to other histological subtypes: A meta-analysis. *Gynecologic Oncology* 122, 541-547.
- Lousse, J.-C., Defrere, S., Van Langendonckt, A., Gras, J., Gonzalez-Ramos, R., Colette, S. and Donnez, J. (2009). Iron storage is significantly increased in peritoneal macrophages of endometriosis patients and correlates with iron overload in peritoneal fluid. *Fertility and Sterility* 91, 1668-1675.
- Lousse, J.-C., Van Langendonckt, A., Gonzalez-Ramos, R., Defrere, S., Renkin, E. and Donnez, J. (2008). Increased activation of nuclear factor-kappa B (NF-kappa B) in isolated peritoneal macrophages of patients with, endometriosis. *Fertility and Sterility* 90, 217-220.
- Martini, M., Ciccarone, M., Garganese, G., Maggiore, C., Evangelista, A., Rahimi, S., Zannoni, G., Vittori, G. and Larocca, L. M. (2002). Possible involvement of hMLH1, p16(INK4a) and PTEN in the malignant transformation of endometriosis. *International Journal of Cancer* 102, 398-406.


- Mayr, D., Amann, G., Siefert, C., Diebold, J. and Anderegg, B. (2003). Does endometriosis really have premalignant potential? A clonal analysis of laser-microdissected tissue. *Faseb Journal* 17, 693-+.
- McConechy, M. K., Anglesio, M. S., Kalloger, S. E., Yang, W., Senz, J., Chow, C., Heravi-Moussavi, A., Morin, G. B., Mes-Masson, A.-M., Carey, M. S., McAlpine, J. N., Kwon, J. S., Prentice, L. M., Boyd, N., Shah, S. P., Gilks, C. B. and Huntsman, D. G. (2011). Subtype-specific mutation of PPP2R1A in endometrial and ovarian carcinomas. *Journal of Pathology* 223, 567-573.
- Melin, A., Lundholm, C., Malki, N., Swahn, M. L., Sparen, P. and Bergqvist, A. (2011). Endometriosis as a prognostic factor for cancer survival. *International Journal of Cancer* 129, 948-955.
- Milner, B. J., Allan, L. A., Eccles, D. M., Kitchener, H. C., Leonard, R. C. F., Kelly, K. F., Parkin, D. E. and Haites, N. E. (1993). P53 Mutation Is a Common Genetic Event in Ovarian-Carcinoma. *Cancer Research* 53, 2128-2132.
- Mizuuchi, H., Nasim, S., Kudo, R., Silverberg, S. G., Greenhouse, S. and Garrett, C. T. (1992). Clinical Implications of K-Ras Mutations in Malignant Epithelial Tumors of the Endometrium. *Cancer Research* 52, 2777-2781.
- Modesitt, S. C., Tortoler-Luna, G., Robinson, J. B., Gershenson, D. M. and Wolf, J. K. (2002). Ovarian and extraovarian endometriosis-associated cancer. *Obstetrics and Gynecology* 100, 788-795.
- Murphy, A. A., Santanam, N. and Parthasarathy, S. (1998). Endometriosis: A disease of oxidative stress? *Seminars in Reproductive Endocrinology* 16, 263-273.
- Nagle, C. M., Olsen, C. M., Webb, P. M., Jordan, S. J., Whiteman, D. C. and Green, A. C. (2008). Endometrioid and clear cell ovarian cancers - A comparative analysis of risk factors. *European Journal of Cancer* 44, 2477-2484.
- Ness, R. B. and Cottreau, C. (1999). Possible role of ovarian epithelial inflammation in ovarian cancer. *Journal of the National Cancer Institute* 91, 1459-1467.
- Ness, R. B., Grisso, J. A., Cottreau, C., Klapper, J., Vergona, R., Wheeler, J. E., Morgan, M. and Schlesselman, J. J. (2000). Factors related to inflammation of the ovarian epithelium and risk of ovarian cancer. *Epidemiology* 11, 111-117.
- Nezhat, F., Cohen, C., Rahaman, J., Gretz, H., Cole, P. and Kalir, T. (2002). Comparative immunohistochemical studies of bcl-2 and p53 proteins in benign and malignant ovarian endometriotic cysts. *Cancer* 94, 2935-2940.
- Nezhat, F., Datta, M. S., Hanson, V., Pejovic, T., Nezhat, C. and Nezhat, C. (2008). The relationship of endometriosis and ovarian malignancy: a review. *Fertility and Sterility* 90, 1559-1570.
- Ngo, C., Chereau, C., Nicco, C., Weill, B., Chapron, C. and Batteux, F. (2009). Reactive Oxygen Species Controls Endometriosis Progression. *American Journal of Pathology* 175, 225-234.
- Nyiraneza, C., Marbaix, E., Smets, M., Galant, C., Sempoux, C. and Dahan, K. (2010). High risk for neoplastic transformation of endometriosis in a carrier of lynch syndrome. *Familial Cancer* 9, 383-387.
- Ogawa, S., Kaku, T., Amada, S., Kobayashi, H., Hirakawa, T., Ariyoshi, K., Kamura, T. and Nakano, H. (2000). Ovarian endometriosis associated with ovarian carcinoma: A clinicopathological and immunohistochemical study. *Gynecologic Oncology* 77, 298-304.

- Okuda, T., Otsuka, J., Sekizawa, A., Saito, H., Makino, R., Kushima, M., Farina, A., Kuwano, Y. and Okai, T. (2003). p53 mutations and overexpression affect prognosis of ovarian endometrioid cancer but not clear cell cancer. *Gynecologic Oncology* 88, 318-325.
- Orezzoli, J. P., Russell, A. H., Oliva, E., Del Carmen, M. G., Eichhorn, J. and Fuller, A. F. (2008). Prognostic implication of endometriosis in clear cell carcinoma of the ovary. *Gynecologic Oncology* 110, 336-344.
- Palacios, J. and Gamallo, C. (1998). Mutations in the beta-catenin gene (CTNNB1) in endometrioid ovarian carcinomas. *Cancer Research* 58, 1344-1347.
- Postoloff, A. V. and Rodenberg, T. A. (1955). Malignant Transition in Ovarian Endometriosis. *American Journal of Obstetrics and Gynecology* 69, 83-86.
- Prowse, A. H., Fakis, G., Manek, S., Churchman, M., Edwards, S., Rowan, A., Koninckx, P., Kennedy, S. and Tomlinson, I. P. M. (2005). Allelic loss studies do not provide evidence for the "endometriosis-as-tumor" theory. *Fertility and Sterility* 83, 1134-1143.
- Ren F, W. D., Jiang Y, Ren F (2011). Epigenetic inactivation of hMLH1 in the malignant transformation of ovarian endometriosis. *Archives of Gynecology and Obstetrics*. [Epub ahead of print].
- Sampson, J. A. (1925). Endometrial carcinoma of the ovary, arising in endometrial tissue in that organ. *Archives of Surgery* 10, 1-72.
- Sato, N., Tsunoda, H., Nishida, M., Morishita, Y., Takimoto, Y., Kubo, T. and Noguchi, M. (2000). Loss of heterozygosity on 10q23.3 and mutation of the tumor suppressor gene PTEN in benign endometrial cyst of the ovary: Possible sequence progression from benign endometrial cyst to endometrioid carcinoma and clear cell carcinoma of the ovary. *Cancer Research* 60, 7052-7056.
- Schmeler, K. M. and Lu, K. H. (2008). Gynecologic cancers associated with Lynch syndrome/HNPCC. *Clinical & Translational Oncology* 10, 313-317.
- Scott, R. B. (1953). Malignant Changes in Endometriosis. *Obstetrics and Gynecology* 2, 283-289.
- Slavin, R. E., Krum, R. and Van Dinh, T. (2000). Endometriosis-associated intestinal tumors: A clinical and pathological study of 6 cases with a review of the literature. *Human Pathology* 31, 456-463.
- Staats, P. N., Clement, P. B. and Young, R. H. (2007). Primary endometrioid adenocarcinoma of the vagina - A clinicopathologic study of 18 cases. *American Journal of Surgical Pathology* 31, 1490-1501.
- Tan, D. S. P., Iravani, M., McCluggage, W. G., Lambros, M. B. K., Milanezi, F., Mackay, A., Gourley, C., Geyer, F. C., Vatcheva, R., Millar, J., Thomas, K., Natrajan, R., Savage, K., Fenwick, K., Williams, A., Jameson, C., El-Bahrawy, M., Gore, M. E., Gabra, H., Kaye, S. B., Ashworth, A. and Reis-Filho, J. S. (2011). Genomic Analysis Reveals the Molecular Heterogeneity of Ovarian Clear Cell Carcinomas. *Clinical Cancer Research* 17, 1521-1534.
- Tashiro, H., Blazes, M. S., Wu, R., Cho, K. R., Bose, S., Wang, S. I., Li, J., Parsons, R. and Ellenson, L. H. (1997). Mutations in PTEN are frequent in endometrial carcinoma but rare in other common gynecological malignancies. *Cancer Research* 57, 3935-3940.
- Toyokuni, S. (2009). Role of iron in carcinogenesis: Cancer as a ferrotoxic disease. *Cancer Science* 100, 9-16.

- Uno, S., Zembutsu, H., Hirasawa, A., Takahashi, A., Kubo, M., Akahane, T., Aoki, D., Kamatani, N., Hirata, K. and Nakamura, Y. (2010). A genome-wide association study identifies genetic variants in the CDKN2BAS locus associated with endometriosis in Japanese. *Nature Genetics* 42, 707-U788.
- Van Langendonckt, A., Casanas-Roux, F., Dolmans, M.-M. and Donnez, J. (2002a). Potential involvement of hemoglobin and heme in the pathogenesis of peritoneal endometriosis. *Fertility and Sterility* 77, 561-570.
- Van Langendonckt, A., Casanas-Roux, F. and Donnez, J. (2002b). Iron overload in the peritoneal cavity of women with pelvic endometriosis. *Fertility and Sterility* 78, 712-718.
- Van Langendonckt, A., Casanas-Roux, F., Eggermont, J. and Donnez, J. (2004). Characterization of iron deposition in endometriotic lesions induced in the nude mouse model. *Human Reproduction* 19, 1265-1271.
- Veras, E., Mao, T.-L., Ayhan, A., Ueda, S., Lai, H., Hayran, M., Shih, I.-M. and Kurman, R. J. (2009). Cystic and Adenofibromatous Clear Cell Carcinomas of the Ovary Distinctive Tumors That Differ in Their Pathogenesis and Behavior: A Clinicopathologic Analysis of 122 Cases. *American Journal of Surgical Pathology* 33, 844-853.
- Vestergaard AL, T. K., Knudsen UB, Munk T, Rosbach H, Poulsen JB, Guldberg P, Martensen PM. (2011). Oncogenic events associated with endometrial and ovarian cancers are rare in endometriosis. *Molecular Human Reproduction* [Epub ahead of print].
- Wiegand, K. C., Lee, A. F., Al-Agha, O. M., Chow, C., Kalloger, S. E., Scott, D. W., Steidl, C., Wiseman, S. M., Gascoyne, R. D., Gilks, B. and Huntsman, D. G. (2011). Loss of BAF250a (ARID1A) is frequent in high-grade endometrial carcinomas. *Journal of Pathology* 224, 328-333.
- Wiegand, K. C., Shah, S. P., Al-Agha, O. M., Zhao, Y., Tse, K., Zeng, T., Senz, J., McConechy, M. K., Anglesio, M. S., Kalloger, S. E., Yang, W., Heravi-Moussavi, A., Giuliany, R., Chow, C., Fee, J., Zayed, A., Prentice, L., Melnyk, N., Turashvili, G., Delaney, A. D., Madore, J., Yip, S., McPherson, A. W., Ha, G., Bell, L., Fereday, S., Tam, A., Galletta, L., Tonin, P. N., Provencher, D., Miller, D., Jones, S. J. M., Moore, R. A., Morin, G. B., Oloumi, A., Boyd, N., Aparicio, S. A., Shih, I.-M., Mes-Masson, A.-M., Bowtell, D. D., Hirst, M., Gilks, B., Marra, M. A. and Huntsman, D. G. (2010). ARID1A Mutations in Endometriosis-Associated Ovarian Carcinomas. *New England Journal of Medicine* 363, 1532-1543.
- Wu, R., Hendrix-Lucas, N., Kuick, R., Zhai, Y., Schwartz, D. R., Akyol, A., Hanash, S., Misek, D. E., Katabuchi, H., Williams, B. O., Fearon, E. R. and Cho, K. R. (2007). Mouse model of human ovarian endometrioid adenocarcinoma based on somatic defects in the Wnt/beta-catenin and PI3K/Pten signaling pathways. *Cancer Cell* 11, 321-333.
- Yamaguchi, K., Mandai, M., Oura, T., Matsumura, N., Hamanishi, J., Baba, T., Matsui, S., Murphy, S. K. and Konishi, I. (2010). Identification of an ovarian clear cell carcinoma gene signature that reflects inherent disease biology and the carcinogenic processes. *Oncogene* 29, 1741-1752.
- Yamaguchi, K., Mandai, M., Toyokuni, S., Hamanishi, J., Higuchi, T., Takakura, K. and Fujii, S. (2008). Contents of endometriotic cysts, especially the high concentration of free

- iron, are a possible cause of carcinogenesis in the cysts through the iron-induced persistent oxidative stress. *Clinical Cancer Research* 14, 32-40.
- Yamamoto, S., Tsuda, H., Miyai, K., Takano, M., Tamai, S. and Matsubara, O. (2011). Gene amplification and protein overexpression of MET are common events in ovarian clear-cell adenocarcinoma: their roles in tumor progression and prognostication of the patient. *Modern Pathology* 24, 1146-1155.
- Yamashita, Y., Yatabe, Y., Akatsuka, S., Kajiyama, H., Kikkawa, F., Takahashi, T., and Toyokuni, S. (2011) MET amplification is a molecular hallmark in endometriosis-associated ovarian clear cell carcinoma and correlates with worse prognosis. *European Journal of Cancer* 47, S529-S529
- Yantiss, R. K., Clement, P. B. and Young, R. H. (2000). Neoplastic and pre-neoplastic changes in gastrointestinal endometriosis - A study of 17 cases. *American Journal of Surgical Pathology* 24, 513-524.
- Yoshikawa, H., Jimbo, H., Okada, S., Matsumoto, K., Onda, T., Yasugi, T. and Taketani, Y. (2000). Prevalence of endometriosis in ovarian cancer. *Gynecologic and Obstetric Investigation* 50, 11-15.
- Zigheboim, I., Schmidt, A. P., Gao, F., Thaker, P. H., Powell, M. A., Rader, J. S., Gibb, R. K., Mutch, D. G. and Goodfellow, P. J. (2009). ATR Mutation in Endometrioid Endometrial Cancer Is Associated With Poor Clinical Outcomes. *Journal of Clinical Oncology* 27, 3091-3096.

IntechOpen



## **Endometriosis - Basic Concepts and Current Research Trends**

Edited by Prof. Koel Chaudhury

ISBN 978-953-51-0524-4

Hard cover, 490 pages

**Publisher** InTech

**Published online** 09, May, 2012

**Published in print edition** May, 2012

This book provides an insight into the emerging trends in pathogenesis, diagnosis and management of endometriosis. Key features of the book include overviews of endometriosis; endometrial angiogenesis, stem cells involvement, immunological and hormonal aspects related to the disease pathogenesis; recent research reports on infertility, endometrial receptivity, ovarian cancer and altered gene expression associated with endometriosis; various predictive markers, and imaging modalities including MRI and ultrasound for efficient diagnosis; as well as current non-hormonal and hormonal treatment strategies. This book is expected to be a valuable resource for clinicians, scientists and students who would like to have an improved understanding of endometriosis and also appreciate recent research trends associated with this disease.

### **How to reference**

In order to correctly reference this scholarly work, feel free to copy and paste the following:

Yoriko Yamashita and Shinya Toyokuni (2012). Endometriosis-Associated Ovarian Cancer: The Role of Oxidative Stress, Endometriosis - Basic Concepts and Current Research Trends, Prof. Koel Chaudhury (Ed.), ISBN: 978-953-51-0524-4, InTech, Available from: <http://www.intechopen.com/books/endometriosis-basic-concepts-and-current-research-trends/endometriosis-associated-ovarian-cancer-the-role-of-oxidative-stress>

**INTeCH**  
open science | open minds

#### **InTech Europe**

University Campus STeP Ri  
Slavka Krautzeka 83/A  
51000 Rijeka, Croatia  
Phone: +385 (51) 770 447  
Fax: +385 (51) 686 166  
[www.intechopen.com](http://www.intechopen.com)

#### **InTech China**

Unit 405, Office Block, Hotel Equatorial Shanghai  
No.65, Yan An Road (West), Shanghai, 200040, China  
中国上海市延安西路65号上海国际贵都大饭店办公楼405单元  
Phone: +86-21-62489820  
Fax: +86-21-62489821

© 2012 The Author(s). Licensee IntechOpen. This is an open access article distributed under the terms of the [Creative Commons Attribution 3.0 License](https://creativecommons.org/licenses/by/3.0/), which permits unrestricted use, distribution, and reproduction in any medium, provided the original work is properly cited.

IntechOpen

IntechOpen