

We are IntechOpen, the world's leading publisher of Open Access books Built by scientists, for scientists

6,900

Open access books available

186,000

International authors and editors

200M

Downloads

Our authors are among the

154

Countries delivered to

TOP 1%

most cited scientists

12.2%

Contributors from top 500 universities



WEB OF SCIENCE™

Selection of our books indexed in the Book Citation Index
in Web of Science™ Core Collection (BKCI)

Interested in publishing with us?
Contact book.department@intechopen.com

Numbers displayed above are based on latest data collected.
For more information visit www.intechopen.com



Endometrial Tumors in Postoperative Scars- Pathogenesis, Diagnostics and Treatment

Stanisław Horák and Anita Olejek
*Chair and Clinical Department of Gynecology,
Obstetrics and Gynecological Oncology,
Silesian Medical University
Poland*

1. Introduction

Endometriosis is defined as the presence of endometrial glands and stroma in another places of the female body than the uterine cavity. Despite of being a relatively common disease it still remains a diagnostic and therapeutic enigma, mainly thanks to its variable presentations. When endometriosis is localized intraperitoneally, the major problem in young women is involuntary sterility, whereas by extraperitoneal localization they suffer predominantly of bothersome pain.

In 1903 Robert Mayer was the first, who described the presence of endometriosis in the postoperative scar, as mentioned in Bytom study (43), and from this time the number of publications in this field is slowly rising, but still a lot of problems ought to be satisfactory elucidated. An investigation of this disease and making firm conclusions is not easy because of inconsistent and small series of patients, often casuistic (2, 5, 6, 8, 11, 12, 13, 16, 19, 22, 30, 36, 39, 42, 46, 48, 52). Up to now only one large systemic review (29) was published and two biggest single retrospective studies (57, 41) included 81 and 72 patients appropriately.

2. Pathogenesis

Endometriosis is doubtless a multifactorial disease.

The most widely accepted theory of arising of the endometriosis is an implantation of endometrial fragments brought by retrograde menstrual flow in a peritoneal surface (50). This should be typical for intraperitoneal lesions.

Meyer's theory explains the origin of endometriosis by celomic metaplasia mainly in the ovaries, peritoneum and urinary bladder due to their common development from the celomic epithelium. Mesenchymal cells with retained multi-potential under the properties circumstances undergo metaplasia into endometriotic cells. This theory may explain the incidence of endometriosis in women with uterine agenesis or in males treated by estrogens (3).

Vascular dissemination theory (27), in turn, with endometrial cells spread into blood or lymphatic circulation may explain distal locations of endometriosis. Very interesting was one of cases described by Agarwal and Fong (1). This Chinese woman suffering from sterility and a lump in right inguinal region had twice laparoscopy and ablation of endometriotic intraperitoneal lesions without managing of the lump. Third laparoscopy revealed endometriotic deposits along the right round ligament contiguous with this lump which was after excision diagnosed as an endometrioma. It may be speculated, that in some conditions endometriotic cells can infiltrate per continuitatem like a malignant tumour.

The etiopathogenetic mechanism of endometriosis localized in surgical scars would be related to iatrogenic transplantation of endometrium during delivery or surgery, mostly gynecological.

All the mentioned above theories could only elucidate mainly the way on which endometrial cells or fragments could be transported to their improper localizations. But still remains unclear why in these places the endometrial cells survive and proliferate.

Endometriosis is defined as a steroid-dependent condition with a particular genetic background (37). It is well known, that estrogens promote the development of endometriotic lesions and anti-estrogen or gestagen therapy can diminish the symptoms.

There is substantial evidence that not only hormonal but first of all immunologic factors play a role in the pathogenesis of endometriosis (3, 54, 56). Immune alterations include increased number and activation of macrophages, decreased T cells reactivity and NK cells cytotoxicity, increased circulating antibodies and changes in the cytokine system. These alterations are responsive for implantation and survival of the ectopic endometrial cells and concomitant inflammatory reaction and pain. Increased oxidative stress appears to be a common contributory factor in the pathogenesis of endometriosis (3). Wicherek et al. (56) in discussion consider that endometrial cells are implanted in ectopic places usually during the maintenance of higher immunotolerance, including pregnancy. The ectopic endometrium preserves the ability to undergo reversible decidualization. Once implanted develops further when estrogens level raise with a concomitant lack of adequate progesterone level.

The next factor, playing a potent role are endometrial stromal cells themselves. When stimulated by estrogens the endometriotic cells may proliferate until they become symptomatic. Moreover, endometriotic lesions can thanks to aromatase activity produce estrogens locally themselves (9).

It is known, that in patients suffering from endometriosis higher activity of integrins and cadherin E on surface of endometrial and mesothelial cells is expressed (24). This may explain the better ability of adhesion of these cells in another places than uterine cavity. The invasion of them is enhanced by metalloproteinases. It was shown, that in patients with endometriotic lesions even eutopic endometrium expresses higher activity of matrix metalloproteinase -2 (MMP-2) whereas lower of tissue matrix metalloproteinase inhibitor - 2 (TIMP-2) (14). The ability of endometrial cells to regulate the cytotoxic immune activity by expression of factors such as RCAS 1 or metallothionein enables their survival in ectopic

localizations (56). After invasion the endometrial cells are producing growth factors and cytokinins, such as vascular endothelial growth factor (VEGF), macrophage colony stimulating factor (MCSF) and a lot of others, what stimulates neovascularization of the lesions and further development (25).

The role of genetics (32) and exogenous environmental pollutants (47) as contributing factors is also considered.

3. Occurrence and diagnostics

The disease is uncommon but not so rare. The extraperitoneal localization of the lesion is mainly the abdominal wall scar, but should be also in episiotomy scar, bowel, bladder, lung, kidneys, brain, umbilicus, groin (29) and even in male urinary tract (51). Leite et al. (38) mentioning except those liver, extremities and pericardium, confirm the opinion that extrapelvic endometrioma occurs mainly as a complication of cesarean section, hysterectomy and episiotomy. Akagi et al. (2) reported an asymptomatic case of endometriosis of the appendix. Endometriosis in the inguinal channel usually occurs on the right side (90%) and in 32% may be associated with an hernia (15, 20). This feature seems to be due to the clockwise circulation of the peritoneal fluid and to the presence of sigmoid colon that shields the left inguinal ring (20). Vulvar involvement of endometriosis is extremely rare. Buda et al. (8) described a case of endometriosis in a scar after excision of the Bartholin gland.

According to Chatterjee (11) endometriosis of the abdominal wall occurs in 0,03 – 1,08% of women with previous history of obstetric or gynecologic procedures. Leite et al. (38) reviewing bibliography estimates the incidence of abdominal wall endometrioma on 0,03 – 3,5%. Nominato et al. (41) in their large series report the incidence of scar endometrioma in 0,2% women submitted former to cesarean section but only in 0,06% when episiotomy was made. Singh et al. (52) reported three cases, considering that the true incidence of this disease (0,8%) is underestimated because a lot of cases remains undetected. Agarwal and Fong (1) reporting 10 cases (among them six in Pfannenstiel scar) estimate the frequency of cutaneous localization of disease 1,1%. Unusually high percent (5,2%) of cutaneous localization of endometriosis was reported from Glasgow (18).

Concerning the coincidence of peritoneal and abdominal wall endometriosis das Chagas Medeiros et al. (10) basing on literature data estimates the frequency of abdominal wall endometriosis on about 0,5 – 1% in women with pelvic endometriosis. According to another data in 13% both of the forms of disease are present (29), more often by spontaneous abdominal wall endometriosis without any previous surgery (1).

The diagnosis of endometriosis in the postoperative scars is usually established basing on characteristic clinical symptoms as the presence of slowly developing immobile lump, which seems to be attached to the anterior fascia, in the scar or near of them, often swelling during menstruation and painful, especially in this period in most of cases. Sometimes occurs periodical bleeding from the superficial lesions and lower abdominal pain (1, 4, 29). The boundary of the mass is not clear usually. Incision of it looks grey or slightly yellowish (59). Leite et al. (38) in turn, describe it as whitish fibrous tumor with thick chocolate-like colored liquid areas.

Horton et al. (29) summarized their review of 445 cases from 29 reports till 2006 as follows (table 1):

Data	Result	95% CI
Mean age (years)	31,4	29,1 – 33,8
Mean interval to symptoms (years)	3,6	2,5 – 4,8
Presenting with mass	96%	93 – 99,7%
Presenting with pain	87%	80 – 93%
Cyclic symptoms	57%	44 – 70%
Concurrent pelvic endometriosis	13%	5,6 – 20%
Mean size of mass (cm)*	2,7	2,1 – 3,2
Recurrence rate	4,3%	1,2 – 7,4%
Associated with a cesarean section scar	57%	NC
Associated with a hysterectomy scar	11%	NC
Associated with other surgeries	13%	NC
Spontaneous abdominal wall endometriosis	20%	NC

* largest single dimension

NC = not calculated

Table 1. Summary of review data of cases of abdominal wall endometriosis

No other diagnostic tools are necessary if the anamnesis and physical examination are classical. In another cases, especially if the lesion is large, further investigation should be very useful (29).

The preoperative diagnosis should be confirmed by ultrasound scan of the lesion (21, 52, 59). Francica et al. (21) described extensionally ultrasonographic picture of small (0,7 – 2,6 cm) and large (3 – 6 cm) lesions. The most typical ultrasound pattern was that of a solid nonhomogenous hypoechoic nodule with infiltrating margins, echogenic rim and increased vascularity in the musculocutaneous planes of the abdominal wall near the cesarean section incision. In large lesion there was significantly higher grey-scale, higher incidence of cystic areas and fistulous tracts, loss of round or oval shape, multiple vascular pedicles and central vascularity comparing to small lesions.

Very useful should be a computerized tomography or magnetic resonance imaging. The data from these diagnostic procedures may be helpful even during planning a reconstructional operation of the abdominal wall (29, 39), though Francica et al. (21) consider that they often are nonspecific.

Sometimes, if the lesion is very superficial, epiluminescence microscopy should be used (23) to exclude melanoma.

Fine-needle aspiration cytology (10, 26) in suspicious cases is very good and cheap diagnostic tool if an incisional hernia is ruled out, of course. Epithelial endometrial-like cells, stromal cells or hemosiderin-laden macrophages are essential to confirm endometriosis on

cytology. Some authors (12) consider, that needle biopsy may be dangerous, because of dissemination of endometrial or even neoplastic cells.

The diagnostic pitfalls are more common among general surgeons, who are very often first contact physicians (5, 13, 34), especially when no palpable masses are present. Sometimes are misleading the age of the patient (4) or enormously long time between the cesarean section and occurrence of the first symptoms. The disease most often occurs in adult young women in their twenties till forties but Attia et al. (4) also reported a case of 15 years old girl.

Abdominal wall endometriosis is often misdiagnosed as a hernia, hematoma, lymphadenopathy, lymphoma, lipoma, abscess, subcutaneous cyst, suture granuloma, neuroma, soft tissue sarcoma, desmoid tumours and metastatic cancer, particularly as many endometrial tumours of the abdominal wall are not related to prior surgical procedures (29). Even cellulites is mentioned as a possible misdiagnostic condition (1). Gajjar et al. (22) and Khoo (33) described a case of cesarean scar endometriosis presenting as an acute abdomen. Umbilical endometriosis can pose a next diagnostic dilemma (1, 48) simulating malignant melanoma or the "sister Mary Joseph nodule" – a manifestation of intraabdominal malignancy. Endometriosis should mimic hernia recurrence in the inguinal region, especially if it is painless (19). On the other hand not only endometrial tissue can implant into postoperative scars. Neumann et al. (40) reported a rare case of implantation of adenosquamous cervical carcinoma in an episiotomy scar mentioning 13 another cases reported to date.

The occurrence of the endometriosis in an postoperative scar is usually the result of a previous caesarean section or abdominal hysterectomy but any other surgery might be a cause of this disease. Harry et al. (28) presented a case of the scar endometriosis converting in a clear cell adenocarcinoma more than 30 years after an open tubal sterilization. Zhu et al. (59) basing on another reports, are of opinion, that tubal mucosa after simply tubal ligation brought into the incision is able to transform to the endometrial tissue. Kaunitz and Di Saint' Agnese reported about endometriosis as a complication of amniocentesis (30). One of the cases presented by Agarwal and Fong (1) had an endometriotic lesion after appendectomy. Kurotsuchi et al. (36) described a case of abdominal scar endometriosis as a complication of laparotomy performed because of uterine perforation during dilatation and curettage. Aydin (4) mentioned about rising incidence of endometriomas in port sites after laparoscopy.

4. Surgical treatment

A surgical resection with complete and wide negative margins is the treatment of choice of endometriotic lesions in the abdominal wall, taking into account the risk of recurrence and the potential for their malignant transformation (1, 8, 12, 13, 28, 29, 43, 59). If the endometriosis is incorporated into the musculature, en bloc resection of all the myofascial elements is recommended and often mesh repair of the abdominal wall is necessary (1, 29, 43, 59). Figures 1 – 6 illustrate the procedure in such a case of 15 cm endometrioma in Bytom clinical centre.

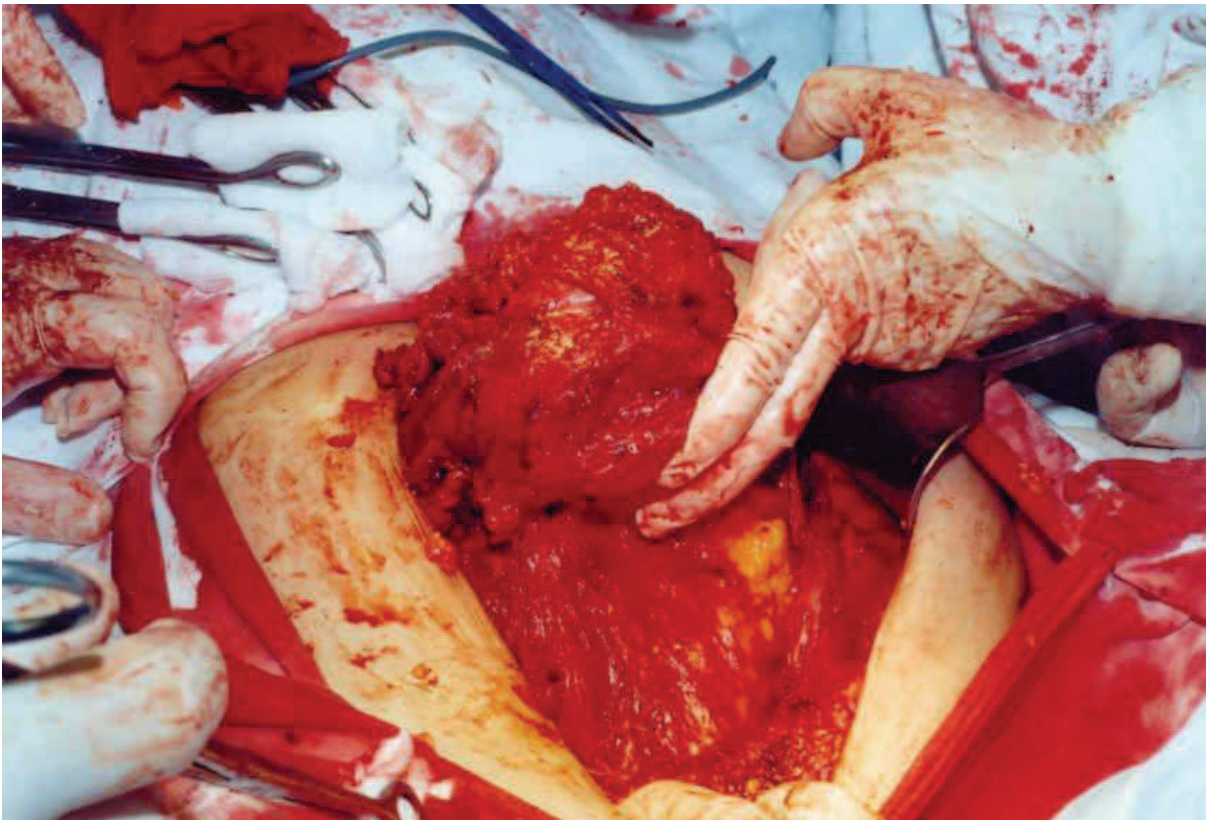


Fig. 1. Large endometrioma penetrating abdominal wall.

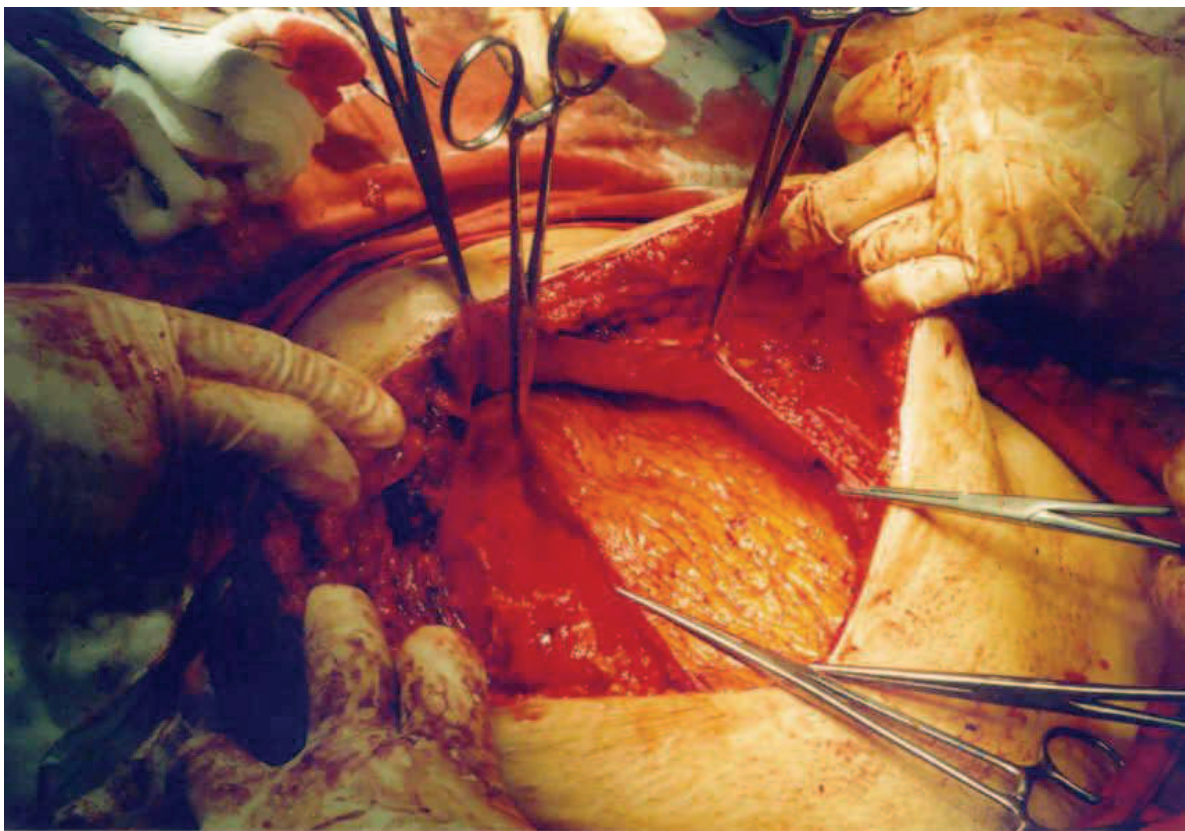


Fig. 2. Endometrioma is totally excised with wide margins including peritoneum




Fig. 3. The polypropylene mesh ready to use

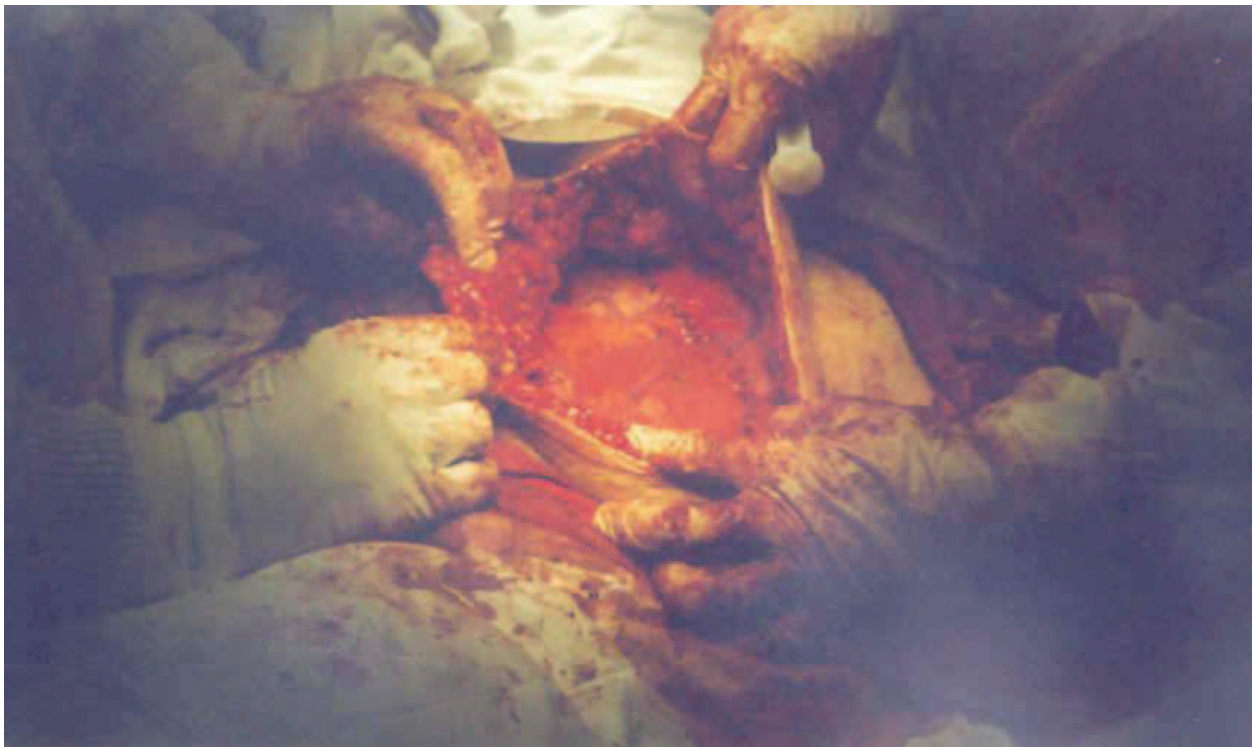


Fig. 4. Abdominal wall thoroughly repaired by mesh

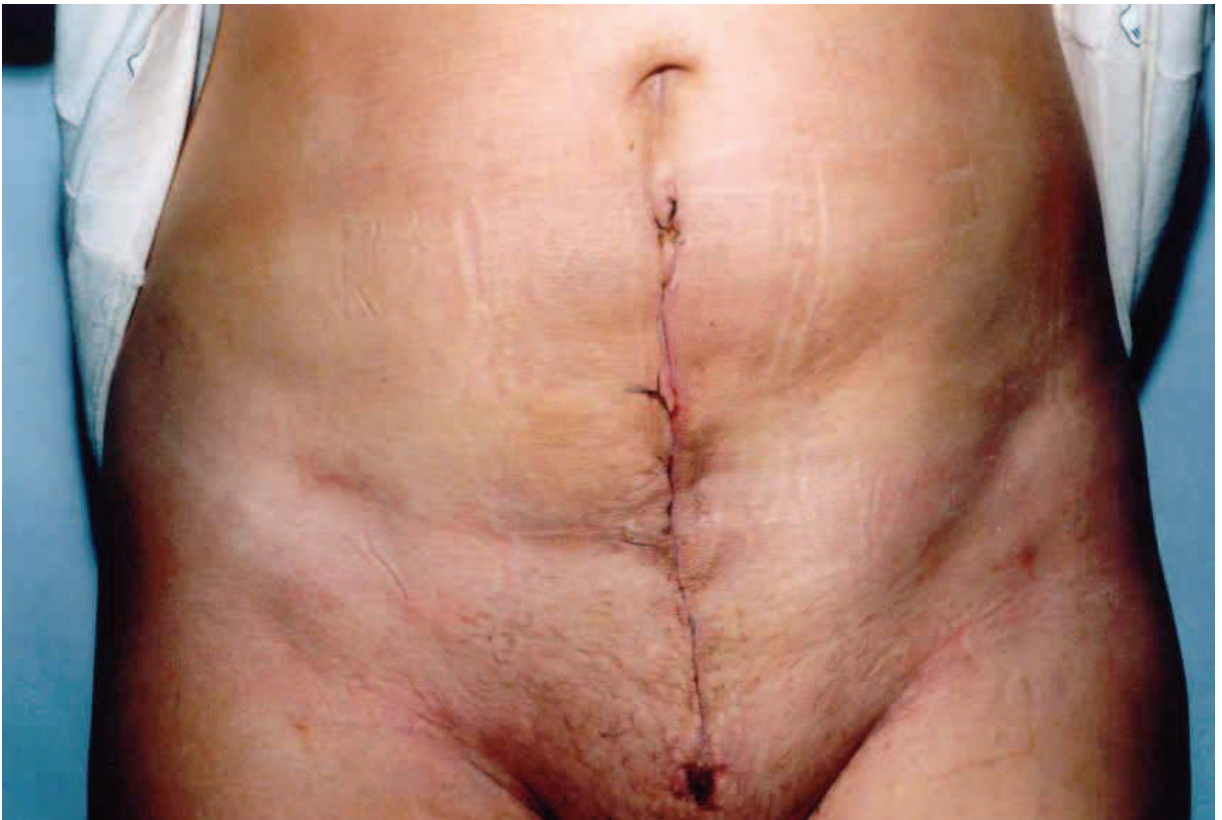

Fig. 5. The skin is sutured.




Fig. 6. The excised endometrioma of size 15 cm.

A large use of coagulation is advised to diminish bleeding and a risk of recurrences (35).

A wide surgical resection is also the therapy of choice when the endometrioma is localized in perineal scars (8, 11, 41, 51). If necessary, even anal sphincter reconstruction ought to be performed (6). Dougherty and Hull (11) clearly demonstrated in their series of patients that narrow excision only gives a very high rate of recurrences whereas wide excision does not.

Fedele et al. (20) advise in cases of inguinal endometriosis also the removal of the extraperitoneal portion of the round ligament to avoid recurrences.

5. Histopathology

All the excised specimen must be examined histopathologically because of mentioned above reasons (12, 38, 43). The frozen section is advisable (59). Histopatological examination reveals usually ectopic endometrial glands with surrounding cellular stroma, occasionally associated with extravasation of erythrocytes and some inflammatory infiltrates around the glands (5, 33, 38).

Recently, the largest and exhausting study on histopatology of cutaneous endometriosis basing on 73 patients presented Kazakov et al. (31). The excised nodules looked out macroscopically as a gray-white scar-like tissue with or without an evidence of hemorrhage containing tiny cysts when viewed under a magnifying glass. Two cases were excluded from study because of fibrotic granulation tissue in the first and cutaneous endosalpingiosis in the second one with a complete lack of endometriotic tissue in both. The resting cases showed typical endometriotic glands with a characteristic stroma. The müllerian epithelium is apt to show a broad spectrum of metaplastic changes. The authors discovered in glandular component in most of cases tubal metaplasia (61%), less often reactive atypia (23%), oxyphilic metaplasia (15%), hobnail metaplasia (10%), atypical mitoses in glands (6%), mucinous metaplasia (4%), papillary syncytial metaplasia in two cases and hyperplasia in one. The stromal component revealed mostly myxoid changes (69%), less often smooth muscle metaplasia (31%) and in single cases decidual changes, stromal endometriosis, micronodular stromal endometriosis and elastosis. In $\frac{3}{4}$ of specimens were observed large granular CD56 positive lymphocytes. Quite frequently occurred lipoblast like cells (15%), intranuclear inclusions in adipocytes (10%), atypically appearing myocytes (10%) and spiral arteries (4%). Perineural invasion was present in one case. The authors also advertised, that endometrioid or clear cell cancer can occur in the skin lesions.

Zhang et al. (58) evidenced that bothersome pain caused usually by endometriotic lesion is caused by sensory nerve fibres which are present mainly in deeply infiltrating endometriosis.

6. Pharmacological treatment

Medical management of the endometriosis by drugs as danazol, GnRH-analogues, progestagens or oral contraceptives, results usually in the temporary relief of pain (53). Opinions concerning combined therapy are different. According to Horton et al. (29) there are no data to support postoperative hormonal therapy. Sometimes might be useful preoperative treatment by GnRH-analogues for three months to diminish the tumour size

(1). On the other hand Zhu et al. (59) in a part of their patients administered postoperative analogues of GnRH. Ding and Hsu (16) prescribed danazol for six months postoperatively. Korczyński and Sobkiewicz (35) are of opinion, that pharmacological treatment can be applied in some cases as a complementary therapy. Kurotsuchi et al. (36) suggest that GnRH-agonist therapy might be an alternative to surgical treatment.

The presence of aromatase activity in endometriotic lesions might be a new target of therapeutical actions. Oner et al. (45) in an animal model showed significant regression of endometriotic implants by letrozol and metformin. Moreover, in the metformin group thanks to its antiproliferative and anti-inflammatory properties the authors observed less adhesions.

Basing on the results from animal studies it seems be effective in future to treat and prevent endometriosis by vaccination using immunomodulators like RESAN, DETOX or BCG (54).

New therapeutical options mentioned by Skrzypczak (53) may represent statins and selective progesterone receptor modulators.

Antioxidants and nonsteroidal antiinflammatory drugs are considered as a possible additive therapeutical options (3).

7. Risk factors

The most evident risk factor for the scar endometriosis are obstetrical surgical procedures, especially cesarean section (38,41). It is believed that the opening of uterine cavity mainly during cesarean section causes the risk of decidualized endometrium implantation (10,29,53,57). The risk of scar endometriosis is significantly higher, when the cesarean section is performed before the term (44,56,57), though Nominato et al. (41) does not confirm this suggestion. There is no correlation between the parity, number of cesarean sections and the disease prevalence (38) but de Oliveira et al. (44) are of opinion that low parity may increase the risk.

The risk of scar endometrioma is augmented when not proper operative techniques are used (not closing the visceral and parietal peritoneum, using of the same surgical material during opening and closing uterus and abdominal wall, failure to shielding the wound during lack of placenta extraction with subsequent curettage and thorough washing before definitive closure) (38,55).

On the other hand, as it is mentioned by Zhu et al. (59) endometriosis in the postoperative scar may occur not only after operations that need not open the uterus (for example tubal operations).

Pelvic endometriosis seems to be the risk factor of arising scar endometriosis when treated by laparoscopy (10,29). The laparoscopic procedure may cause transportation of endometrial cells in the abdominal wall in women with a predisposition to endometriosis. Agarwal and Fong (1) found that spontaneous cutaneous endometriosis was associated with more severe pelvic disease.

Non-surgical risk factors of scar endometrioma are also alcohol consumption and increased menstrual flow (44).

Hyperestrogenismus, even relative, seems to be also a risk factor of endometriosis, though there is a lack of valuable literature data confirming it in relation to scar endometriomas.

The important risk factor is the genetic one. Lattuada et al. (37) reported that the frequency of the PROGINS allele T2 in affected women was 17,2% compared with 11% in controls. They are of opinion that the progesterone receptor mutation increases the risk of endometriosis morbidity two fold. Teng et al. (56) discussing their results mentioned that the antiapoptotic function of the survivin gene may play an important role in endometriotic implant survival and invasion.

8. Prophylaxis

First of all one should avoid unnecessary cesarean sections (41, 59). To prevent the iatrogenic inoculation of the endometrium into the surgical wound during the cesarean section it is strongly recommended to protect the abdominal wall by a quadrangular bandage during curettage of an uterine cavity after removal of the placenta, discard immediately after cleaning the uterine cavity swabs or sponges, not to reuse the suture material used to suturing of the uterus during the closure of the abdominal wall. The surgical wound should be thoroughly cleaned and irrigated by saline before final closure, especially at the operators side in Pfannenstiel incision (16, 55). Zhu et al. (59) recommend during suturing the myometrium to avoid penetration of endometrium.

Performing another surgical procedures lifting the uterus outside of the pelvis before making uterine incision and removing a functional corpus luteum during hysterectomy may reduce the likelihood of arising the scar endometriosis (11,29). Before endometrial cystectomy all the cystic content should be sucked out, the incision of the abdominal wall covered by swabs and before closure abdominal cavity and incision thoroughly flushed by saline (59).

Wicherek et al. (57) clearly demonstrated, that cesarean section performed before spontaneous onset of labor significantly increases the risk of abdominal wall scar endometriosis thanks to higher immunotolerance. This might also explain higher rate of endometriomas in scars after cesarean section comparing to episiotomy.scars. Thus, if it is possible, the decision on cesarean section should be delayed till the natural onset of the labour.

It should be avoided estrogen monotherapy in obese patients, because such treatment augments the risk of rising and malignant degeneration of endometriotic lesions (7).

A prolonged breast feeding is well known protecting factor because of causing hypoestrogenic status that does not support endometriosis development.

Administering of antioxidant agents and proper diet (3) seem to be to some extent helpful, so as endometriosis coexists with local inflammatory reaction.

9. Complications

The typical complications of scar endometriosis are relatively high recurrence rate, malignancy and anatomical defects. Olejek et al. (43) reported a very high recurrence rate – 8

from 33 (over 24%) operated patients during on an average 19 months. It might be caused by larger size of endometriomas and no medical therapy after their excision. Leite et al. (38) described only two cases (6,0%).

Sampson (49) was the first to document the possibility of malignant changes in ectopic endometrial tissue. Chene et al. (12) consider that 0,3 – 1% of scar endometriosis undergo malignant degeneration reporting a case of serous papillary cystadenocarcinoma. In our clinical material (43) also in one patient after two surgical removals of the cesarean scar endometriosis preformed in other centers (where endometrioma was diagnosed) papillary adenocarcinoma was recognized. Matsuo et al. (39) described primary clear cell carcinoma developed in previous abdominal scar post endometriosis surgery. Authors mentioned that endometrioid adenocarcinoma, clear cell adenocarcinoma and adenosarcoma are also common enough in extragenital localization. Razzouk et al. (46) reported a case of mixed clear cell and endometrioid carcinoma arising in a recurrent cesarean section scar endometrioma.

10. Closing remarks

All the menstruating women or postmenopausal, especially using hormone replacement therapy, in whose cases any lesion in any postoperative scar or nearby them appear, should be suspected of endometriosis. It should be kept in mind that lesions of an abdominal wall or another regions of the body even without operation in past might be of endometriotic origin. In unclear cases additional proper diagnostic examinations are advised preoperatively.

The wide excision of the lesion with possible fascial or muscular repair should be offered in these cases and histopatological examination ought to be performed by an experienced histopathologist because of a possibility of malignancy. One should remember that diagnostic pitfalls, particularly among general surgeons often occur.

Medical treatment being less invasive than the surgical one, may be developed and seems to be promising in the future.

Unnecessary operations, especially cesarean sections, should be avoided and if performed, one should be aware of the transmission of endometrial cells in the wound.

Further systematic investigations in the field of scar endometriosis are still needed.

11. References

- [1] Agarwal A. & Fong Y.F.: *Cutaneous endometriosis*. Singapore Med J 2008, 49, 704-9.
- [2] Akagi T., Yamamoto S., Kobayashi Y., Fujita S., Akadu T., Moria Y. & Kato T.: *A case of endometriosis of the appendix with adhesion to right ovarian cyst presenting as intussusception of a mucocoele of the appendix*. Surg Laparosc Endosc Percutan Tech 2008, 18, 622-5.
- [3] Alpay Z., Saed G.M. & Diamond M.P.: *Female infertility and free radicals: potential role in adhesions and endometriosis*. J Soc Gynecol Investig 2006, 13, 390-8.


- [4] Attia L., Ben Temime R., Sidhom J., Sahli A., Makhlouf T., Chachia A., Koubaa A. & Zermani R.: *A case of cutaneous endometriosis developed on an abdominal scar*. Tunis Med 2010, 88, 841-3.
- [5] Aydın Ö.: *Scar endometriosis – a gynecologic pathology often presented to the general surgeon rather than the gynaecologist: report of two cases*. Langenbecks Arch Surg 2007, 392, 105-9.
- [6] Barisić G., Krivokapić Z. & Jovanović D.: *Perineal endometriosis in episiotomy scar with anal sphincter involvement: report of two cases and review of the literature*. Int Urogynecol J 2006, 17, 646-9.
- [7] Benoit L., Arnould L., Cheynel N., Diane B., Causeret A., Machado A., Collin F., Fraisse J. & Cuisenier J.: *Malignant extraovarian endometriosis: a review*. Eur J Surg Oncol 2006, 32, 6-11.
- [8] Buda A., Ferrari L., Marra C., Passoni P., Perego P. & Milani R.: *Vulvar endometriosis in surgical scar after excision of the Bartholin gland: report of a case*. Arch Gynecol Obstet 2008, 277, 255-6.
- [9] Bulun S.E., Imir G., Utsunomyia H., Thung S., Gurates B., Tamura M. & Lin Z.: *Aromatase in endometriosis and uterine leiomyomata*. J Steroid Biochem Mol Biol 2005, 95, 57-62.
- [10] das Chagas Medeiros F., Magno Cavalcante D.I., da Silva Medeiros M.A. & Eleutério J.: *Fine-needle aspiration cytology of scar endometriosis: study of seven cases and literature review*. Diagn Cytopathol 2011, 39, 18-21.
- [11] Chatterjee S.K.: *Scar endometriosis: a clinicopathologic study of 17 cases*. Obstet Gynecol 1980, 56, 81-4.
- [12] Chene G., Darcha C., Dechelotte P., Mage G. & Canis M.: *Malignant degeneration of perineal endometriosis in episiotomy scar, case report and review of the literature*. Int J Gynecol Cancer 2007, 17, 709-14.
- [13] Chiang D.T. & The W.T.: *Cutaneous endometriosis – surgical presentations of a gynecological condition..* Aust Fam Physician 2006, 35, 887-8.
- [14] Chung H.W., Lee J.Y., Moon H.S., Hur S.E., Park M.H., Wen Y. & Polan M.L.: *Matrix metalloproteinase-2, membranous type 1 matrix metalloproteinase, and tissue inhibitor of metalloproteinase-2 expression in ectopic and eutopic endometrium*. Fertil Steril 2002, 78, 787-95.
- [15] Clausen I. & Nielsen K.T.: *Endometriosis in the groin*. Int J Gynaecol Obst 1987, 25, 469-71.
- [16] Ding D.C. & Hsu S.: *Scar endometriosis at the site of cesarean section*. Taiwan J Obstet Gynecol 2006, 45, 247-9.
- [17] Dougherty L.S. & Hull T.: *Perineal endometriosis with anal sphincter involvement*. Dis Colon Rectum 2000, 43, 1157-60.
- [18] Douglas C. & Rotimi O.: *Extragenital endometriosis – a clinicopathological review of a Glasgow hospital experience with case illustrations*. J Obstet Gynaecol 2004, 24, 804-8.
- [19] Ducarme G., Uzan M. & Poncelet C.: *Endometriosis mimicking hernia recurrence*. Hernia 2007, 11, 175-7.
- [20] Fedele L., Bianchi S., Frontino G., Zanconato G. & Rubino T.: *Radical excision of inguinal endometriosis*. Obstet Gynecol 2007, 110, 530-3.
- [21] Francica G., Scarano F., Scotti L., Angelone G. & Giardiello C.: *Endometriomas in the region of a scar from cesarean section: sonographic appearance and clinical presentation vary with the size of the lesion*. J Clin Ultrasound 2009, 37, 215-20.

- [22] Gajjar K.B., Mahendru A.A. & Khaled M.A.: *Caesarean scar endometriosis presenting as an acute abdomen: a case report and review of literature*. Arch Gynecol Obstet 2008, 277, 167-9.
- [23] de Giorgi V., Massi D., Mannone F., Stante M. & Carli P.: *Cutaneous endometriosis: non invasive analysis by epiluminescence microscopy*. Clin Exp Dermatol 2003, 28, 315-7.
- [24] Groothuis P.G., Koks C.A. & de Goeij A.F.: *Adhesion of human endometrial fragments to peritoneum in vitro*. Fertil Steril 1999, 71, 1119-23.
- [25] Grümmer R., Schwarzer F., Balczyk K., Hess-Stumpp H., Regidor P.A., Schindler A.E. & Winterhager E.: *Peritoneal endometriosis: validation of an in-vivo model*. Hum Reprod 2001, 16, 1736-43.
- [26] Gupta R.K.: *Fine-needle aspiration cytodiagnosis of endometriosis in cesarean section scar and rectus sheath mass lesions – a study of seven cases*. Diagn Cytopathol 2008, 36, 224-6.
- [27] Halban J.: *Metastatic hysteroadenosis*. Wien Klin Wochenschr 1924, 37, 1205-6.
- [28] Harry V.N., Shanbhag S., Lyall M., Narayansingh G.V. & Parkin D.E.: *Isolated clear cell adenocarcinoma in scar endometriosis mimicking an incisional hernia*. Obstet Gynecol 2007, 110, 469-71.
- [29] Horton J.D., DeZee K.J., Ahnfeldt E.P. & Wagner M.: *Abdominal wall endometriosis: a surgeon's perspective and review of 445 cases*. Am J Surg 2008, 196, 207-12.
- [30] Kaunitz A. & Di Saint' Agnese P.A.: *Needle tract endometriosis: an unusual complication of amniocentesis*. Obstet Gynecol 1979, 54, 753-5.
- [31] Kazakov D.V., Ondič O., Zámečník M., Shelekhova K.V., Mukenšnábl P., Hes O., Dvořák V. & Michal M.: *Morphological variations of scar-related and spontaneous endometriosis of the skin and superficial soft tissue: a study of 71 cases with emphasis on atypical features and types of müllerian differentiations*. J Am Acad Dermatol 2007, 57, 134-46.
- [32] Kennedy S.: *The genetics of endometriosis*. J Reprod Med 1998, 43, 263-8.
- [33] Khoo J.J.: *Scar endometriosis presenting as an acute abdomen*. Aust N Z J Obstet Gynaecol 2003, 43, 164-5.
- [34] Kocakusak A., Arpinar E., Arikan S., Demirbag N., Tarlaci A. & Kabaca C.: *Abdominal wall endometriosis: a diagnostic dilemma for surgeons*. Med Princ Pract 2005, 14, 434-7.
- [35] Korczyński J. & Sobkiewicz S.: *Diagnostyka i postępowanie lecznicze w przypadkach endometriozy powłok brzusznych*. Ginekol Pol 2001, 73, 358-72.
- [36] Kurotsuchi S., Iwase A., Goto M., Hariyama Y. & Kikkawa F.: *Scar endometriosis after a laparotomy for uterine perforation as a complication of dilatation and curettage*. Arch. Gynecol Obstet 2009, 279, 941-3.
- [37] Lattuada D., Somigliana E., Viganò P., Candiani M., Pardi G., Di Blasio A.M.: *Genetics of endometriosis: a role for the progesterone receptor gene polymorphism PROGINS?* Clinical Endocrinology 2004, 61, 190-4.
- [38] Leite G.K.C., de Carvalho L.F.P., Koreks H., Guazzelli T.F., Kenj G. & de Toledo V.: *Scar endometrioma following obstetric surgical incisions: retrospective study on 33 cases and review of the literature*. Sao Paulo Med J 2009, 127, 270-7.
- [39] Matsuo K., Alonsozana E.L.C., Eno M.L., Rosenhein N.B. & Im D.D.: *Primary peritoneal clear cell adenocarcinoma arising in previous abdominal scar for endometriosis surgery*. Arch Gynecol Obstet 2009, 280, 637-41.

- [40] Neumann G., Rasmussen K.L. & Petersen L.K.: *Cervical adenosquamous carcinoma. Tumor implantation in an episiotomy scar*. *Obstet Gynecol* 2007, 110, 467-9.
- [41] Nominato N.S., Prates L.F.V.S., Lauar I., Morais J., Maia L. & Geber S.: *Caesarean section greatly increases risk of scar endometriosis*. *Eur J Obstet Gynecol Reprod Biol* 2010, 152, 83-5.
- [42] Odobasić A., Pasić A., Iljazović-Latifagić E., Arnautalić L., Odobasić Ad., Idrizović E., Dervisefendić M. & Dedić L.: *Perineal endometriosis: A case report and review of the literature*. *Tech Coloproctol* 2010, 14 (Suppl), S25-7.
- [43] Olejek A., Zamłyński J., Podwińska E., Horák S., Paliga-Żytniewska M. & Kellas-Ślęczka S.: *Guzy endometrialne w bliznach po cięciu cesarskim. [Abdominal Wall endometrioma in the cesarean section scar]*. *Ginekol Pol* 2008, 79, 612-5.
- [44] de Oliveira M.A., de Leon A.C., Freire E.C., de Oliveira H.C. & Study S.O.: *Risk factors for abdominal scar endometriosis after obstetrics hysterotomies: a case control study*. *Acta Obstet Gynecol Scand* 2007, 86, 73-80.
- [45] Oner G., Oczelik B., Ozgun M.T., Serin I.S., Ozturk F. & Basbug M.: *The effects of metformin and letrozole on endometriosis and comparison of the two treatment agents in a rat model*. *Hum Reprod* 2010, 25, 932-7.
- [46] Razzouk K., Roman H., Chanavaz-Lacheray I., Scotté M., Verspyck E. & Marpeau L.: *Mixed clear cell and endometrioid carcinoma arising in parietal endometriosis*. *Gynecol Obstet Invest* 2007, 63, 140-2.
- [47] Rier S.E., Martin D.C., Bowman R.E., Dmowski W.P. & Becker J.L.: *Endometriosis in rhesus monkeys (Macaca mulatta) following chronic exposure to 2,3,7,8-tetrachlorodibenzo-p-dioxin*. *Fundam Appl Toxicol* 1993, 21, 433-41.
- [48] Rosina P., Pugliarello S., Colato C. & Girolomoni G.: *Endometriosis of umbilical cicatrix: Case report and review of the literature*. *Acta Dermatovenerol Croat* 2008, 16, 218-21.
- [49] Sampson J.A.: *Endometrial carcinoma of the ovary arising in endometrial tissue in that organ*. *Arch Surg* 1925, 10, 1-72.
- [50] Sampson J.A.: *The development of the implantation theory for the origin of peritoneal endometriosis*. *Am J Obstet Gynecol* 1940, 40, 549
- [51] Schrodtt G.R., Alcorn M.O. & Ibanez J.: *Endometriosis in the male urinary system: a case report*. *J Urol* 1980, 124, 722-3.
- [52] Singh M., Sivanesan K., Ghani R. & Granger K.: *Caesarean scar endometriosis*. *Arch Gynecol Obstet* 2009, 279, 217-9.
- [53] Skrzypczak J.: *Farmakologiczne leczenie endometriozy*. In: *Endometrioza*. (red. Wielgoś M.), Ed: *Via Medica*, Gdańsk, 2010, 24-38.
- [54] Szymanowski K., Chmaj-Wierzchowska K., Yatzenko A., Niepsuj-Biniaś J., Florek E., Opala T. & Murawski M.: *Endometriosis prophylaxis and treatment with the newly developed xenogenic immunomodulator RESAN in an animal model*. *Eur J Obstet Gynecol Reprod Biol* 2009, 142, 145-8.
- [55] Teng C.C., Yang H.M., Chen K.F., Yang C.J., Chen L.S. & Kuo C.L.: *Abdominal wall endometriosis: an overlooked but possibly preventable complication*. *Taiwan J Obstet Gynecol* 2008, 47, 42-8.
- [56] Wicherek Ł., Dutsch-Wicherek M., Gałązka K., Banaś T., Popiela T., Lazar A. & Kleinrok-Podsiadło B.: *Comparison of RCAS 1 and metallothionein expression and the*

- presence and activity of immune cells in human ovarian and abdominal wall endometriomas.* Reprod Biol Endocrinol 2006, 4, 41-9.
- [57] Wicherek Ł., Klimek M., Skręt-Magierło J., Czekierdowski A., Banaś T., Popiela T.J., Kraczkowski J., Sikora J., Oplawski M., Nowak A., Skręt A. & Basta A.: *The obstetrical history in patients with Pfannenstiel scar endometriomas – an analysis of 81 patients.* Gynecol Obstet Invest 2007, 63, 107-13.
- [58] Zhang X., Yao H., Huang X., Lu B., Xu H. & Zhou C.: *Nerve fibres in ovarian endometriotic lesions in women with ovarian endometriosis.* Hum Reprod 2010, 25, 392-7.
- [59] Zhu Z., Al-Beiti M.A.M., Tang L., Liu X. & Lu X.: *Clinical characteristic analysis of 32 patients with abdominal incision endometriosis.* J Obstet Gynaecol 2008, 28, 742-5.

IntechOpen



Endometriosis - Basic Concepts and Current Research Trends

Edited by Prof. Koel Chaudhury

ISBN 978-953-51-0524-4

Hard cover, 490 pages

Publisher InTech

Published online 09, May, 2012

Published in print edition May, 2012

This book provides an insight into the emerging trends in pathogenesis, diagnosis and management of endometriosis. Key features of the book include overviews of endometriosis; endometrial angiogenesis, stem cells involvement, immunological and hormonal aspects related to the disease pathogenesis; recent research reports on infertility, endometrial receptivity, ovarian cancer and altered gene expression associated with endometriosis; various predictive markers, and imaging modalities including MRI and ultrasound for efficient diagnosis; as well as current non-hormonal and hormonal treatment strategies. This book is expected to be a valuable resource for clinicians, scientists and students who would like to have an improved understanding of endometriosis and also appreciate recent research trends associated with this disease.

How to reference

In order to correctly reference this scholarly work, feel free to copy and paste the following:

Stanislaw Horak and Anita Olejek (2012). Endometrial Tumors in Postoperative Scars-Pathogenesis, Diagnostics and Treatment, Endometriosis - Basic Concepts and Current Research Trends, Prof. Koel Chaudhury (Ed.), ISBN: 978-953-51-0524-4, InTech, Available from:

<http://www.intechopen.com/books/endometriosis-basic-concepts-and-current-research-trends/endometrial-tumours-in-postoperative-scars-pathogenesis-diagnostics-and-treatment>

INTech
open science | open minds

InTech Europe

University Campus STeP Ri
Slavka Krautzeka 83/A
51000 Rijeka, Croatia
Phone: +385 (51) 770 447
Fax: +385 (51) 686 166
www.intechopen.com

InTech China

Unit 405, Office Block, Hotel Equatorial Shanghai
No.65, Yan An Road (West), Shanghai, 200040, China
中国上海市延安西路65号上海国际贵都大饭店办公楼405单元
Phone: +86-21-62489820
Fax: +86-21-62489821

© 2012 The Author(s). Licensee IntechOpen. This is an open access article distributed under the terms of the [Creative Commons Attribution 3.0 License](#), which permits unrestricted use, distribution, and reproduction in any medium, provided the original work is properly cited.

IntechOpen

IntechOpen