

We are IntechOpen, the world's leading publisher of Open Access books Built by scientists, for scientists

6,900

Open access books available

186,000

International authors and editors

200M

Downloads

Our authors are among the

154

Countries delivered to

TOP 1%

most cited scientists

12.2%

Contributors from top 500 universities



WEB OF SCIENCE™

Selection of our books indexed in the Book Citation Index
in Web of Science™ Core Collection (BKCI)

Interested in publishing with us?
Contact book.department@intechopen.com

Numbers displayed above are based on latest data collected.
For more information visit www.intechopen.com



Diagnosis of the Muscular Dystrophies

Leigh B. Waddell, Frances J. Evesson, Kathryn N. North,
Sandra T. Cooper and Nigel F. Clarke

*Institute for Neuroscience and Muscle Research,
Children's Hospital at Westmead and Discipline of Paediatrics & Child Health,
University of Sydney,
Australia*

1. Introduction

The diagnosis of muscular dystrophies (MDs) has advanced considerably since these disorders were first described in the 1800s, due to characterisation of phenotypes and advances in biochemical and molecular analyses. Over the last ten years in particular, there has been a rapid expansion in the list of genes that are known to cause MD. Providing a specific genetic diagnosis to a patient is important for many reasons. It resolves many uncertainties for families, enables accurate genetic counselling and options for prevention and prenatal diagnosis, and provides doctors and families with information about prognosis, which allows medical care to be individualised. In some cases, a genetic diagnosis prompts the clinician to begin surveillance and/or interventions that may be life-saving, such as aggressive cardiac surveillance in disorders associated with cardiac arrhythmias or cardiomyopathy. In addition, knowledge of the primary genetic cause will be an essential prerequisite to prescribe specific gene-based or biochemical therapies when they are developed in the future. Making a genetic diagnosis should now be the universal goal for all patients with MD.

Diagnosis of the three most common forms of MD, Duchenne muscular dystrophy (DMD), myotonic dystrophy and Facioscapulohumeral muscular dystrophy (FSHD) MD, is now straightforward in most patients, as clinical features guide the appropriate genetic tests to be requested. However, establishing the specific diagnosis in many patients with other forms of MD remains difficult. The main reasons are the large number of potential genetic causes in several subgroups of MD, a lack of specific features to guide diagnosis and the wide range of phenotypes that are possible with many genetic forms. These combine to make it a challenge for the clinician to predict the correct genetic cause from the patient's clinical presentation and history, or from standard clinical tests alone. Laboratory investigations, including muscle histopathology and protein analysis (immunohistochemistry and Western blotting), are useful to guide genetic testing in many situations. However, even in well-resourced diagnostic services, the genetic cause remains unknown in a large proportion of MD patients. It is likely that many of these patients have as yet undiscovered genetic forms of MD.

This chapter summarises the most important clinical and laboratory information to consider when diagnosing MDs, and the approach to diagnosing the different forms. This includes an appreciation of clinical presentations, the use of specialised muscle imaging, muscle histopathology, laboratory protein analysis and specific genetic tests. We also discuss the challenges when diagnosing many rare forms of MD, and how new technologies may aid this process.

2. The different forms of muscular dystrophy

The MDs are a genetically and phenotypically diverse group of disorders. In children, the most common form of MD is Duchenne MD (DMD), caused by mutations in the *DMD* gene that encodes dystrophin, with an estimated prevalence of 1 in 3000 males (Jones and North 1997). Most affected boys lose ambulation around 10 years of age and die from respiratory or cardiac complications in the third or fourth decades of life. Becker MD (BMD) is a less severe condition associated with a later age of onset and slower disease progression that is also caused by mutations in the dystrophin protein.

In adults, the most common forms of MD are myotonic dystrophy type 1 (DM1) and facioscapulohumeral MD (FSHD). The average estimated prevalence of DM1 is ~1 in 10,000 (Norwood, Harling et al. 2009; Turner and Hilton-Jones 2010) and for FSHD it is 1 in 20,000 (Norwood, Harling et al. 2009; Statland and Tawil 2011). DM1 is a multi-system disorder caused by a trinucleotide repeat expansion (CTG) in the *DMPK* gene on chromosome 19 and there is a wide range of severity that partially correlates with the size of the repeat expansion (McNally and Pytel 2007; Turner and Hilton-Jones 2010). The classical form of DM1 is characterised by progressive muscle weakness that begins in the muscles of the face, ankle, hands and neck and myotonia, a delayed relaxation of muscles after contraction. Patients also have an increased risk of cardiac conduction defects, cataracts, type 2 diabetes, daytime somnolence and balding (males especially). Congenital onset DM1 is strongly associated with respiratory difficulties at birth and intellectual disability (Turner and Hilton-Jones 2010). A second form of myotonic dystrophy (DM2) is due to mutations in the *ZNF9* gene, does not have a congenital onset form, and is probably less common. FSHD is characterised by weakness of the facial, scapular, ankle and upper arm muscles and is caused by deletions of large D4Z4 DNA repeats in the sub-telomeric region of chromosome 4q (McNally and Pytel 2007; Pandya, King et al. 2008).

Disease	Gene	Chromosome	Protein	Year Identified
FSHD	<i>DUX4</i>	4q35	Double homeobox 4	1990 ¹
Myotonic Dystrophy (DM1)	<i>DMPK</i>	19q13	Expansion of non-coding triplet (CTG) repeat	1992 ^{2,3}
Myotonic Dystrophy (DM2)	<i>ZNF9</i>	3q21	Expansion of non-coding quadruplet (CCTG) repeat	2001 ^{4,5}
Oculopharyngeal MD	<i>PABPN1</i>	14q11.2-q13	Poly(A) binding protein, nuclear 1	1998 ⁶⁻⁸
MD with Lipodystrophy	<i>PTRF</i>	17q21-23	Cavin-1	2009 ⁹
DMD/BMD	<i>DMD</i>	Xp21.2	Dystrophin	1986/87 ¹⁰⁻¹⁴

Disease	Gene	Chromosome	Protein	Year Identified
EDMD	<i>EMD</i>	Xq28	Emerin	1994 ¹⁵
	<i>FHL1</i>	Xq27.2	Four and a half LIM domain 1	2009 ¹⁶
	<i>LMNA</i>	1q21.2	Lamin A/C	1999 ¹⁷
	<i>SYNE1</i>	6q25	Nesprin-1	2007 ¹⁸
	<i>SYNE2</i>	14q23	Nesprin-2	2007 ¹⁸
LGMD1A	<i>MYOT</i>	5q31	Myotilin	2000 ¹⁹
LGMD1B	<i>LMNA</i>	1q22	Lamin A/C	2000 ²⁰
LGMD1C	<i>CAV3</i>	3p25	Caveolin-3	1998 ^{21,22}
LGMD1D	*	7q36.3		²³
LGMD1E	*	6q23		²⁴
LGMD1F	*	7q32		²⁵
LGMD1G	*	4q21		²⁶
LGMD2A	<i>CAPN3</i>	15q15.1	Calpain-3	1995 ^{27,28}
LGMD2B	<i>DYSF</i>	2p13	Dysferlin	1998 ^{29,30}
LGMD2C	<i>SGCG</i>	13q12	γ -sarcoglycan	1995 ³¹
LGMD2D	<i>SGCA</i>	17q12-21.33	α -sarcoglycan	1994 ³²
LGMD2E	<i>SGCB</i>	4q12	β -sarcoglycan	1996 ³³
LGMD2F	<i>SGCD</i>	5q33	δ -sarcoglycan	1996 ³⁴
LGMD2G	<i>TCAP</i>	17q12	Telethonin	2000 ³⁵
LGMD2H	<i>TRIM32</i>	9q31-34	Tripartite motif-containing 32	2002 ^{36,37}
LGMD2I	<i>FKRP</i>	19q13.3	Fukutin related protein	2001 ^{38,39}
LGMD2J	<i>TTN</i>	2q31	Titin	2002 ⁴⁰
LGMD2K	<i>POMT1</i>	9q34	Protein O-mannosyl-transferase 1	2005 ⁴¹
LGMD2L	<i>ANO5</i>	11p14.3	Anoctamin 5	2010 ⁴²
LGMD2M	<i>FKTN</i>	9q31-33	Fukutin	2006 ^{43,44}
LGMD2N	<i>POMT2</i>	14q24	Protein O-mannosyl-transferase 2	2007 ⁴⁵
LGMD2O	<i>POMGnT1</i>	1p34	Protein O-linked mannose beta 1,2-N-acetylglucosaminyl transferase 1	2007 ⁴⁶
MDC1A	<i>LAMA2</i>	6q2	Laminin α 2 chain of merosin	1995 ⁴⁷⁻⁴⁹
MDC1B	*	1q42		⁵⁰
MDC1C	<i>FKRP</i>	19q13	Fukutin related protein	2001 ⁵¹
MDC1D	<i>LARGE</i>	22q12	Like-glycosyltransferase	2003 ⁵²
FCMD	<i>FCMD</i>	9q31-33	Fukutin	1998 ^{53,54}
WWS	<i>FCMD</i>	9q31-33	Fukutin	2003 ⁵⁵
	<i>POMT1</i>	9q34	Protein O-mannosyl-transferase 1	2002 ⁵⁶
	<i>POMT2</i>	14q24.3	Protein O-mannosyl-transferase 2	2005 ⁵⁷
	<i>FKRP</i>	19q13	Fukutin related protein	2005 ⁵⁸
	<i>POMGnT1</i>	1p3	Protein O-linked mannose beta 1,2-N-acetylglucosaminyl transferase 1	2003 ⁵⁹

Disease	Gene	Chromosome	Protein	Year Identified
MEB	<i>POMGnT1</i>	1p3	Protein O-linked mannose beta 1,2-N- acetylglucosaminyl transferase 1	2001 ⁶⁰
	<i>FKRP</i>	19q13	Fukutin related protein	2005 ⁵⁸
	<i>POMT2</i>	14q24.3	Protein O-mannosyl- transferase 2	2006 ⁶¹
Rigid Spine Syndrome	<i>SEPN1</i>	1p36	Selenoprotein N1	2001 ^{62,63}
UCMD	<i>COL6A1</i>	21q22.3	Collagen VI, subunit α 1	2003 ^{64,65}
	<i>COL6A2</i>	21q22.3	Collagen VI, subunit α 2	2001 ^{66,67}
	<i>COL6A3</i>	2q37	Collagen VI, subunit α 3	2002 ⁶⁸
Bethlem myopathy	<i>COL6A1</i>	21q22.3	Collagen VI, subunit α 1	1996 ⁶⁹
	<i>COL6A2</i>	21q22.3	Collagen VI, subunit α 2	1996 ⁶⁹
	<i>COL6A3</i>	2q37	Collagen VI, subunit α 3	1998 ^{70,71}
CMD integrin defect	<i>ITGA7</i>	12q13	Integrin α 7	1998 ⁷²
CMD dynamin 2 defect	<i>DNM2</i>	19p13.2	Dynamin 2	2008 ⁷³
CMD joint hyperlaxity	*	3p23-21		74

Adapted from the NMD Gene Table 2011 (Kaplan 2010). * = no gene discovered yet. **Abbreviations:** FSHD: Facio-scapulo-humeral MD, MD: muscular dystrophy, DMD: Duchenne MD, BMD: Becker MD, EDMD: Emery-Dreifuss MD, LGMD: limb-girdle MD, MDC: MD congenital, FCMD: Fukuyama congenital MD, WWS: Walker-Warburg Syndrome, MEB: Muscle-eye-brain disease, UCMD: Ullrich congenital MD and CMD: congenital MD. References: 1(Wijmenga, Frants et al. 1990), 2(Brook, McCurrach et al. 1992), 3(Renwick, Bunday et al. 1971), 4(Liquori, Ricker et al. 2001), 5(Ranum, Rasmussen et al. 1998), 6(Brais, Bouchard et al. 1998), 7(Brais, Xie et al. 1995), 8(Robinson, Hammans et al. 2005), 9(Hayashi, Matsuda et al. 2009), 10(Burghes, Logan et al. 1987), 11(Hoffman, Brown et al. 1987), 12(Koenig, Hoffman et al. 1987), 13(Koenig, Monaco et al. 1988), 14(Monaco, Neve et al. 1986), 15(Bione, Maestrini et al. 1994), 16(Gueneau, Bertrand et al. 2009), 17(Bonne, Di Barletta et al. 1999), 18(Zhang, Bethmann et al. 2007), 19(Hauser, Horrigan et al. 2000), 20(Muchir, Bonne et al. 2000), 21(McNally, de Sa Moreira et al. 1998), 22(Minetti, Sotgia et al. 1998), 23(Speer, Vance et al. 1999), 24(Messina, Speer et al. 1997), 25(Palenzuela, Andreu et al. 2003), 26(Starling, Kok et al. 2004), 27(Richard, Brenguier et al. 1997), 28(Richard, Broux et al. 1995), 29(Bashir, Britton et al. 1998), 30(Liu, Aoki et al. 1998), 31(Noguchi, McNally et al. 1995), 32(Roberds, Leturcq et al. 1994), 33(Bonnemann, Passos-Bueno et al. 1996), 34(Nigro, de Sa Moreira et al. 1996), 35(Moreira, Wiltshire et al. 2000), 36(Frosk, Weiler et al. 2002), 37(Weiler, Greenberg et al. 1998), 38(Brockington, Blake et al. 2001), 39(Driss, Amouri et al. 2000), 40(Hackman, Vihola et al. 2002), 41(Balci, Uyanik et al. 2005), 42(Bolduc, Marlow et al. 2010), 43(Godfrey, Escolar et al. 2006), 44(Murakami, Hayashi et al. 2006), 45(Biancheri, Falace et al. 2007), 46(Godfrey, Clement et al. 2007), 47(Helbling-Leclerc, Zhang et al. 1995), 48(Hillaire, Leclerc et al. 1994), 49(Tome, Evangelista et al. 1994), 50(Brockington, Sewry et al. 2000), 51(Brockington, Blake et al. 2001), 52(Longman, Brockington et al. 2003), 53(Kobayashi, Nakahori et al. 1998), 54(Toda, Segawa et al. 1993), 55(de Bernabe, van Bokhoven et al. 2003), 56(Beltran-Valero de Bernabe, Currier et al. 2002), 57(van Reeuwijk, Janssen et al. 2005), 58(Beltran-Valero de Bernabe, Voit et al. 2004), 59(Taniguchi, Kobayashi et al. 2003), 60(Yoshida, Kobayashi et al. 2001), 61(Mercuri, D'Amico et al. 2006), 62(Moghadaszadeh, Desguerre et al. 1998), 63(Moghadaszadeh, Petit et al. 2001), 64(Giusti, Lucarini et al. 2005), 65(Pan, Zhang et al. 2003), 66(Camacho Vanegas, Bertini et al. 2001), 67(Higuchi, Shiraishi et al. 2001), 68(Demir, Sabatelli et al. 2002), 69(Jobsis, Keizers et al. 1996), 70(Pan, Zhang et al. 1998), 71(Speer, Tandan et al. 1996), 72(Hayashi, Chou et al. 1998), 73(Susman, Quijano-Roy et al. 2010), 74(Tetreault, Duquette et al. 2006) and 75(Kaplan 2010).

Table 1. Table of muscular dystrophy genes and proteins.

The other major forms of MD are grouped by age of onset or clinical phenotype (see Table 1). Each specific genetic form of MD has a characteristic pattern of disease onset, severity, clinical course and involvement of particular muscle groups, although there is marked overlap between phenotypes (see Table 2). The congenital MDs (CMD) are characterised by onset of muscle weakness within the first year of life (often at birth) and usually have a slowly progressive disease course. In the limb girdle MDs (LGMD), patients can present during childhood or adulthood with weakness that is most prominent in proximal limb or shoulder and/or pelvic girdle muscles. They are subdivided based on mode of inheritance into LGMD type 1 (autosomal dominant) and LGMD type 2 (autosomal recessive); DMD and BMD can be considered as X-linked forms of LGMD. Emery Dreifuss MD (EDMD) is a clinical syndrome with several possible genetic causes characterised by prominent weakness in the upper arm and ankle dorsiflexor muscles, early contractures of the elbows, ankles and neck and cardiac involvement. Other forms of MD with notable phenotypes are oculopharyngeal MD, where mainly the muscles of the eye and throat are affected, and the distal myopathies which mainly affect the muscles of the hands and feet.

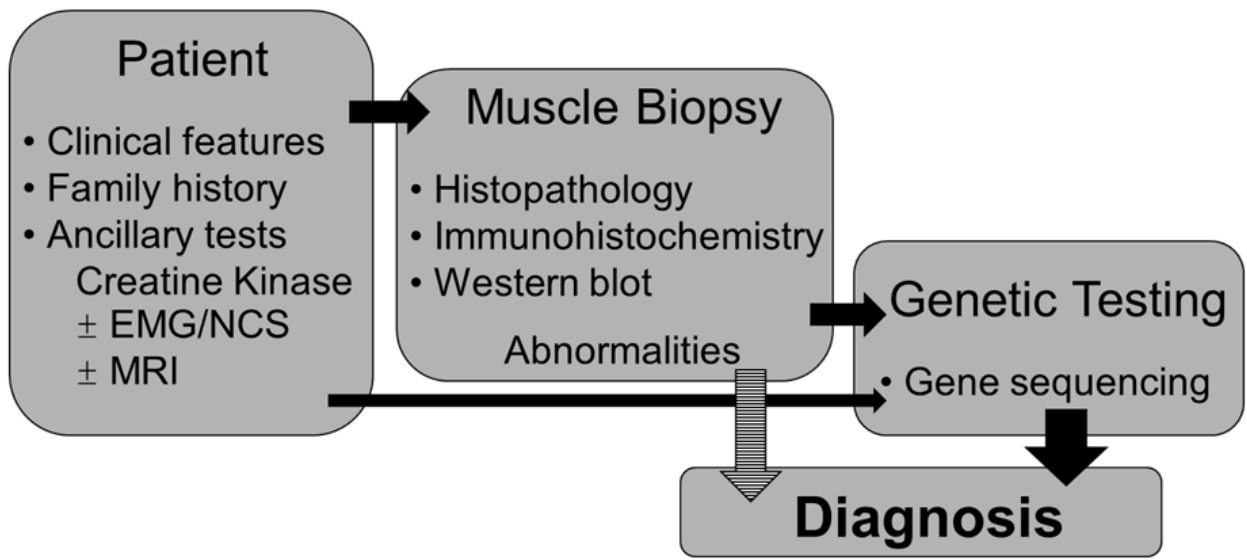
In addition to the different forms of MD listed so far, a wide range of muscle conditions have clinical and histological features that overlap with the MDs and these should be kept in mind whenever a diagnosis of a MD is considered. The most important differential diagnoses are the myofibrillar myopathies (characterised by desmin-positive inclusions in muscle fibres, prominent distal limb muscle involvement, cardiomyopathy and peripheral neuropathy) and some severe forms of congenital myopathy (especially those due to *RYR1* and *DNM2* mutations).

3. Overview of the approach to diagnosis

A diagnosis of MD usually begins with a patient presenting with muscle weakness, muscle pain, reduced stamina; or in children, delayed motor development. Occasionally a raised serum creatine kinase (CK) level is the first sign of a MD and an incidental finding during investigation of other symptoms. A detailed clinical history and examination can provide important clues about the diagnosis and the most appropriate path of investigation. Muscle imaging is a non-invasive option that may be helpful in particular situations. A muscle biopsy is still required for the diagnosis of many types of MD. In most children and some adults a skin biopsy is taken for fibroblast cell culture at this time. Standard muscle histopathology provides information about muscle architecture and frozen portions of the muscle biopsy can be used for a range of protein analyses. Information from all of these sources is used to direct genetic testing, which usually provides the definitive diagnosis. This process is outlined in Figure 1.

3.1 Clinical information

Clinical information remains of paramount importance in the diagnostic process, even with recent advances in genetics (Bushby, Norwood et al. 2007; Norwood, de Visser et al. 2007; Guglieri and Bushby 2008). Each MD has a characteristic clinical pattern in terms of age of onset, rate of progression, severity and range of muscles involved. In some forms of MD, the pattern of clinical features is sufficiently distinct for a relatively accurate provisional



Abbreviations: EMG: Electromyography, NCS: nerve conduction studies, MRI: magnetic resonance imaging.

Fig. 1. Overview of MD diagnostic process.

diagnosis to be made on the basis of clinical history, examination and some basic clinical tests. This is the case for the three most common forms of MD - myotonic dystrophy, FSHD and DMD. It is recommended that clinician spends time familiarising themselves with these three disorders in particular, as they are the most common conditions encountered. Genetic testing is widely available for these conditions and many patients no longer require a muscle biopsy, so long as the clinician can make an accurate provisional diagnosis from clinical features.

Age of disease onset is a key feature that is used to classify major subgroups of MD. The congenital muscular dystrophies (CMDs) present in the first two years of life, most often at birth. The limb girdle MDs (LGMDs) begin after age 2 years. Onset can vary between the first decade of life to old age depending on the specific form of LGMD and its severity.

The pattern of weakness may also provide clues to the MD subtype. For example while LGMDs are characterised by proximal weakness, some subtypes may also have significant involvement of scapular stabilisers or distal limb muscles (see Table 2). Other important variables include the presence or absence of brain, cardiac or respiratory muscle involvement, calf muscle hypertrophy, contractures and skin abnormalities (see Table 2).

The level of creatine kinase (CK) in blood, which is thought to be a marker of ongoing muscle necrosis or damage, can also help to differentiate between forms of MD. While some fluctuation in CK levels from day to day occurs and there is a tendency for CK levels to drop with disease progression, categorising CK results into broad ranges such as normal, mildly raised, moderately raised and markedly elevated is useful.

Disease	Gene	Prevalence*	Age of onset (yrs)	CK	Distal	Cardiac	Respiratory	Muscle hypertrophy	Spine	Contractures	Useful diagnostic information	References
FSHD	<i>DUX4</i>	Common	10-50	↑-↑↑							CE, FHx, GT	1,2
Myotonic Dystrophy (DM1)	<i>DMPK</i>	Common	0-80	↑-↑↑	✓	✓	✓				CE, FHx, EMG, GT	3
Myotonic Dystrophy (DM2)	<i>ZNF9</i>	Probably uncommon	10-60	↑-↑↑	✓	✓		✓			CE, FHx, EMG, GT	3
DMD-BMD	<i>DMD</i>	Common	DMD: 2-6 BMD:>5	↑↑-↑↑↑		✓	✓	✓	✓	✓	CE, FHx, IHC, WB, GT, SEQ	4,5
EDMD	<i>EMD</i>	Uncommon	>3	↑-↑↑		✓		✓	✓	✓✓	IHC, WB, SEQ	6,7
	<i>FHL1</i>	Rare	4-48	N-↑↑		✓			✓	✓	SEQ	8
	<i>LMNA</i>	Uncommon	>3	N-↑↑		✓✓			✓	✓✓	SEQ	
LGMD1A	<i>MYOT</i>	Rare	>25	↑-↑↑	✓	✓					SEQ	9
LGMD1B	<i>LMNA</i>	Uncommon	>3	↑-↑↑	✓	✓✓			✓		SEQ	10
LGMD1C	<i>CAV3</i>	Uncommon	>4	↑↑-↑↑↑				✓			IHC, WB, SEQ	11
LGMD2A	<i>CAPN3</i>	Common	2-40	↑-↑↑↑			✓		✓	✓	± WB, SEQ	12,13
LGMD2B	<i>DYSF</i>	Moderately common^	12-25	↑↑↑	✓						IHC, WB, SEQ	14-16
LGMD2C	<i>SGCG</i>	Rare	>3	↑↑-↑↑↑		✓	✓	✓	✓	✓	IHC, WB, SEQ	17-21
LGMD2D	<i>SGCA</i>	Rare	>3	↑↑-↑↑↑		✓	✓	✓	✓	✓	IHC, WB, SEQ	17-21
LGMD2E	<i>SGCB</i>	Rare	>3	↑↑-↑↑↑		✓	✓	✓	✓	✓	IHC, WB, SEQ	17-21
LGMD2F	<i>SGCD</i>	Rare	>3	↑↑-↑↑↑		✓	✓	✓	✓	✓	IHC, WB, SEQ	17-21
LGMD2G	<i>TCAP</i>	Rare	9-20	↑-↑↑↑	✓	?		✓	✓		IHC, SEQ	22,23
LGMD2H	<i>TRIM32</i>	Rare‡	8-30	↑↑-↑↑↑				✓			SEQ	24
LGMD2I	<i>FKRP</i>	Common	2-40	↑↑-↑↑↑		✓	✓	✓	✓	✓	IHC+, WB+, SEQ	25
LGMD2J	<i>TTN</i>	Rare	8-30	N-↑	✓						MRI, (SEQ)	26
LGMD2L	<i>ANO5</i>	Common	>17	↑↑↑	✓			✓			SEQ	27,28
MDC1A	<i>LAMA2</i>	Common	0	↑↑-↑↑↑			✓		✓	✓	IHC, WB, SEQ	29-32
MDC1C	<i>FKRP</i>	Rare	0	↑↑↑		✓	✓	✓	✓	✓	IHC+, WB+, SEQ	33
FCMD	<i>FKTN</i>	Common†	0	↑↑-↑↑↑		✓	✓	✓	✓	✓	IHC+,	34

Disease	Gene	Prevalence*	Age of onset (yrs)	CK	Distal	Cardiac	Respiratory	Muscle hypertrophy	Spine	Contractures	Useful diagnostic information	References
											WB+, SEQ	
Rigid Spine Syndrome	SEPN1	Uncommon	0-2	N-↑			✓✓		✓✓		SEQ	35
UCMD	COL6A1-3	Common	0	N-↑↑			✓		✓	✓✓	IHC, FIBS, SEQ	36-38
Bethlem myopathy	COL6A1-3	Common	2-20	N-↑↑			✓		✓	✓✓	FIBS, SEQ	36,38

This table does not include the rarest forms of muscular dystrophy. Brain involvement can be seen in congenital myotonic dystrophy (DM1), DMD, the α -dystroglycanopathies and MDC1A. * = Prevalence varies for some disorders in different populations. Distal = prominent distal limb muscle involvement. CK = creatine kinase. Spine = prominent scoliosis or spinal rigidity. N = CK within normal range, ↑ = CK level 1 to 4 times upper limit of normal, ↑↑ = CK 4 to 15 times upper limit of normal, ↑↑↑ = CK > 15 times upper limit of normal. ✓ = commonly associated, ✓✓ = key feature for diagnosis and/or management. ^ = in Indian subcontinent especially, ‡ = mainly reported in Manitoba Hutterites, † = mainly reported in Japanese. CE = important clinical examination findings, FHx = clues from family history, GT = specific genetic test (other than full gene sequencing), EMG = Electromyography, IHC = immunohistochemistry, WB = Western blot, SEQ = direct gene sequencing, MRI = magnetic resonance imaging, FIBS = fibroblast culture, + = protein studies assess levels of glycosylated α -dystroglycan. References: 1(Statland and Tawil 2011), 2(Sorrel-Dejerine and Fardeau 1982), 3(Turner and Hilton-Jones 2010), 4(Bushby, Finkel et al. 2010), 5(Jones and North 1997), 6(Bonne, Mercuri et al. 2000), 7(Emery 1989), 8(Gueneau, Bertrand et al. 2009), 9(Hauser, Horrigan et al. 2000), 10(van der Kooi, van Meegen et al. 1997), 11(Minetti, Sotgia et al. 1998), 12(Fardeau, Hillaire et al. 1996), 13(Piluso, Politano et al. 2005), 14(Bushby, Bashir et al. 1996), 15(Guglieri, Magri et al. 2008), 16(Zatz, de Paula et al. 2003), 17(Azibi, Bachner et al. 1993), 18(Bonnemann, Passos-Bueno et al. 1996), 19(Jones, Kim et al. 1998), 20(Lim, Duclos et al. 1995), 21(Passos-Bueno, Moreira et al. 1996), 22(Moreira, Vainzof et al. 1997), 23(Moreira, Wiltshire et al. 2000), 24(Borg, Stucka et al. 2009), 25(Brockington, Yuva et al. 2001), 26(Udd, Partanen et al. 1993), 27(Bolduc, Marlow et al. 2010), 28(Hicks, Sarkozy et al. 2011), 29(Allamand and Guicheney 2002), 30(Jones, Morgan et al. 2001), 31(North, Specht et al. 1996), 32(Tome 1999), 33(Brockington, Blake et al. 2001), 34(Toda and Kobayashi 1999), 35(Moghadaszadeh, Petit et al. 2001), 36(Bertini and Pepe 2002), 37(Nadeau, Kinali et al. 2009), and 38(Peat, Smith et al. 2008).

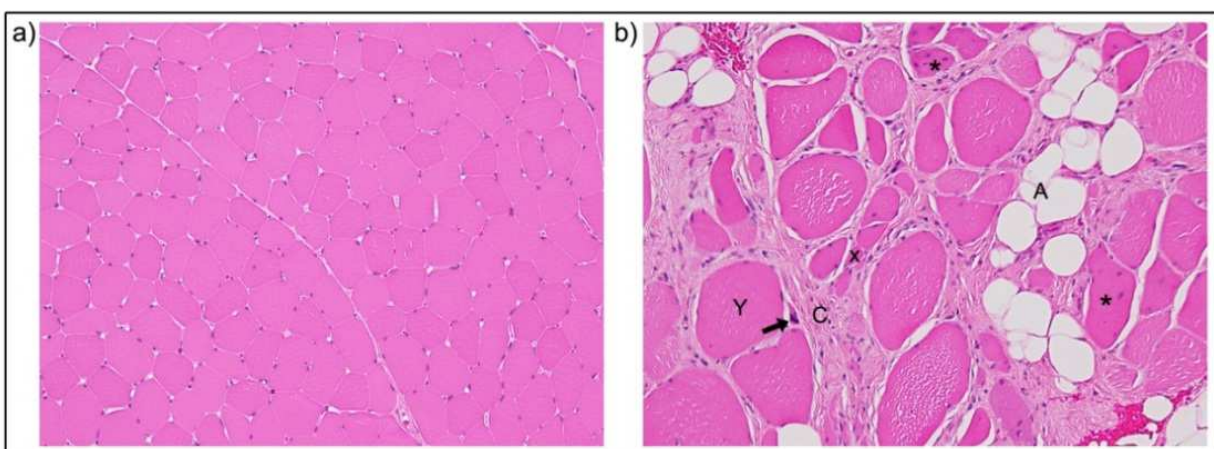
Table 2. Discriminating clinical features in genetically characterised muscular dystrophies.

3.2 Muscle pathology

The MDs are characterised by the presence of ‘dystrophic’ changes on muscle biopsy and one should be cautious about making a diagnosis of a MD if these are not present. The specific pathological features that in combination signify a dystrophy include variation in fibre size, increased internal nuclei, increased connective and adipose tissue, (Norwood, de Visser et al. 2007) and the presence of regenerating and degenerating fibres (see Figure 2). In addition, fibre splitting and inflammatory cell infiltrates are sometimes seen in MDs but are less specific for these disorders. These histological features likely arise from recurrent episodes of muscle fibres necrosis and regeneration that occur because fibres are more prone to damage than normal during muscle contraction (Jones and North 1997; Voit 2001). The

relative prominence of different dystrophic features varies depending on the specific type of dystrophy, the age of the patient and the muscle biopsied (since the degree of involvement varies among different muscle groups in different dystrophies).

It is rarely possible to define the genetic cause of a MD from biopsy features alone but the pattern of dystrophic features can provide clues about the diagnosis. For example, dystrophic changes are often mild in the caveolinopathies (Minetti, Sotgia et al. 1998; Waddell, Lemckert et al. 2011), and the laminopathies (Quijano-Roy, Mbieleu et al. 2008; Rankin, Auer-Grumbach et al. 2008) compared to the dystrophinopathies and sarcoglycanopathies (Bonnemann, Passos-Bueno et al. 1996; Eymard, Romero et al. 1997). LGMD2B (dysferlin) (Norwood, de Visser et al. 2007) and LGMD2L (anoctamin-5) (Hicks, Sarkozy et al. 2011) often have an infiltration of inflammatory cells as an additional feature, and patients can be initially misdiagnosed with polymyositis (Norwood, de Visser et al. 2007). Young patients with Ullrich congenital muscular dystrophy (UCMD) (collagen VI) may only show non-specific myopathic changes or congenital fibre type disproportion (CFTD) (Peat, Smith et al. 2008; Schessl, Goemans et al. 2008). Mutations in *SEPN1* can cause various changes on muscle pathology including those resembling CMD, multiminiore disease or CFTD (Ferreiro, Quijano-Roy et al. 2002; Clarke, Kidson et al. 2006). The presence of other pathological abnormalities can be a clue to specific disorders, such as rimmed vacuoles which are associated with LGMD2G (telethonin) (Moreira, Vainzof et al. 1997) and LGMD2J (Udd, Partanen et al. 1993).



Human muscle in cross section stained with Haematoxylin and Eosin. a) Normal muscle. b) Dystrophic muscle showing a large variation in fibre size with both atrophic (X) and hypertrophic (Y) fibres, increased internal nuclei (*), increased connective (C) and adipose tissue (A) and the presence of regenerating and degenerating fibres (arrow pointing to likely degenerating fibre).

Fig. 2. Healthy and dystrophic human muscle.

3.3 Muscle imaging – MRI and ultrasound

Muscle magnetic resonance imaging has long been used as an adjunct to the diagnosis of inflammatory myopathies, but its usefulness in other neuromuscular disorders is increasingly recognized (Himmrich, Popov et al.). MRI is able to define the pattern of muscle involvement more precisely than clinical examination. Some dystrophies are associated with consistent and relatively specific patterns of abnormality on T1-weighted MRI scans of the thighs, calves and pelvis. For example, muscle MRI of patients with LGMD2I (*FKRP*) and LGMD2A (calpain-3) show marked signal changes in the adductor muscles, posterior thigh muscles and posterior

calf muscles, with additional signal changes of medial gastrocnemius and soleus muscles in LGMD2A patients, differentiating these disorders from the other forms of LGMD (Fischer, Walter et al. 2005). Muscle MRI in combination with detailed clinical information and biochemical analysis is now being used increasingly to guide genetic investigations (Mercuri, Pichiecchio et al. 2002; Mercuri, Jungbluth et al. 2005).

Relatively distinct patterns of muscle involvement have also been described for the dystrophinopathies (Lamminen 1990; Lamminen, Tanttú et al. 1990), the sarcoglycanopathies (α , β and γ) (Eymard, Romero et al. 1997; Lodi, Muntoni et al. 1997), dysferlinopathy (Meola, Sansone et al. 1996; Cupler, Bohlega et al. 1998; Suzuki, Aoki et al. 2004; Paradas, Llauger et al. 2010), Bethlem myopathy (Mercuri, Cini et al. 2002; Mercuri, Cini et al. 2003; Mercuri, Lampe et al. 2005), and for mutations in *ANO5* (Hicks, Sarkozy et al. 2011), *LMNA*, *EMD* (Mercuri, Counsell et al. 2002), and *TTN* (Udd, Vihola et al. 2005).

Muscle MRI has been used to direct investigations in older patients with CMD, since distinctive patterns of muscle involvement are described for Ullrich CMD (Mercuri, Cini et al. 2002; Mercuri, Cini et al. 2003; Mercuri, Lampe et al. 2005) and *SEPN1*-related myopathies (Flanigan, Kerr et al. 2000; Mercuri, Talim et al. 2002; Mercuri, Clements et al. 2010). The need for a general anaesthetic to perform an MRI scan on patients less than age 5 years makes it a less attractive investigation for young patients.

Muscle MRI can also assist in choosing an appropriate muscle to biopsy, so that muscles that are affected by the disease process but not completely atrophied are targeted (Norwood, de Visser et al. 2007).

3.4 Protein analysis

While the specific type of MD can rarely be defined from routine histological stains, immunohistochemistry (IHC) and Western blot (WB) analysis of the expression of several MD proteins can be extremely useful to identify the likely genetic cause (Vogel and Zamecnik 2005; Bushby, Norwood et al. 2007). It is important that these studies are performed in a laboratory with expertise in these techniques (Norwood, de Visser et al. 2007). IHC is used to identify whether the protein is present or absent and whether it is normally localised. WB is generally more sensitive to reductions in protein expression but is technically more challenging. IHC has well-established roles in the diagnosis of the CMDs (Peat, Smith et al. 2008), the dystrophinopathies (Bonilla, Samitt et al. 1988; Hoffman, Fischbeck et al. 1988; Jones, Kim et al. 1998) and the sarcoglycanopathies (Vainzof, Passos-Bueno et al. 1996; Bonnemann, Wong et al. 2002) in particular. However, IHC is not helpful in all forms of MD. For example, in some dominant LGMDs such as LGMD1B, lamin A/C staining usually appears normal by IHC (Lo, Cooper et al. 2008). Mild to moderate 'secondary' staining abnormalities can arise in association with a primary abnormality in another protein or due to the disease process itself. Therefore the results of a single stain should always be considered in the context of other IHC results, the clinical situation and ideally protein quantification on Western blot (Ohlendieck, Matsumura et al. 1993; Mizuno, Yoshida et al. 1994; Vainzof, Passos-Bueno et al. 1996; Jones, Kim et al. 1998 (Lo, Cooper et al. 2008). For example, absence of dystrophin in DMD often results in partial loss of staining of other components of the dystrophin-associated protein complex (e.g. the sarcoglycans) and merosin. Reduced or abnormal localisation of dysferlin by IHC occurs in ~45% of all dystrophic muscle biopsies (Lo, Cooper et al. 2008), and it is only the absence of dysferlin by IHC and WB that indicates a primary dysferlinopathy.

Obtaining a muscle biopsy from a patient is an invasive procedure and biopsies are precious resources for both diagnosis and research. The single section WB technique (Cooper, Lo et al. 2003) has been an important advance on traditional methods by significantly reducing the amount of muscle biopsy used for each blot, from 20 - 100 mg down to one 8 μ m cryosection. WB analysis has been found to be more effective for diagnosis than IHC for several forms of LGMD, such as LGMD2B (dysferlin) (Vainzof, Anderson et al. 2001; Nguyen, Bassez et al. 2005; Lo, Cooper et al. 2008), LGMD1C (caveolin-3) (Minetti, Sotgia et al. 1998; Carbone, Bruno et al. 2000; Herrmann, Straub et al. 2000; Lo, Cooper et al. 2008), Becker MD (dystrophin) (Voit, Stuetzgen et al. 1991) and arguably the alpha-dystroglycanopathies (Peat, Smith et al. 2008). However the sensitivity and specificity of WB is relatively poor for LGMD2A (calpain-3) (Fanin, Fulizio et al. 2004; Saenz, Leturcq et al. 2005; Groen, Charlton et al. 2007; Lo, Cooper et al. 2008) and the laminopathies (Menezes et al. 2011).

3.5 Genetic analysis

A provisional diagnosis can often be made by considering the clinical information, muscle pathology and protein studies, which can then be confirmed by direct gene sequencing (Bushby, Norwood et al. 2007; Norwood, de Visser et al. 2007). Even with recent advances, it is often difficult to correctly predict the correct LGMD sub-type and several genes may need to be tested before a definitive diagnosis is made. If genetic testing identifies mutations previously published or listed in on-line databases, a firm diagnosis can be made. However, if previously unreported genetic changes are found, then further functional protein studies may be useful to differentiate pathogenic mutations from rare harmless sequence variants.

Even in the best diagnostic centres, establishing a genetic cause for MD is only possible in around 90% of patients. Likely reasons are that the full phenotypic spectrum of many known genes is still being clarified and many MD genes likely remain unidentified. Whole exome or whole genome sequencing and other techniques that capitalise on recent advances in gene sequencing are likely to provide new opportunities to diagnose patients with MD. These approaches also have the capacity to identify new MD disease genes, which may account for many of the currently undiagnosed patients worldwide.

4. Diagnosis in specific forms of muscular dystrophy

4.1 Myotonic dystrophy

Myotonic dystrophy can usually be suspected from clinical examination and family history (see Section 2) and the clinician should have a low threshold for requesting genetic testing for DM1 since it is so common. Electromyography (EMG) is useful for showing characteristic myotonic discharges although these may not be present in young children with DM1 and in the occasional adult patient with DM2. Both DM1 and DM2 are multi-system disorders and involve predisposition to cataracts, cardiac conduction defects, cardiomyopathy, testicular failure and diabetes, as well as myotonia and muscle weakness. In myotonic dystrophy, muscle biopsy histopathology lacks specific diagnostic features but common features include smallness of a particular fibre type (type 1 atrophy in DM1 and type 2 atrophy in DM2), prominent internal nuclei and mild dystrophic changes. Genetic testing for DM1 is widely available and involves assessment of the size of a triplet repeat (CTG) in the *DMPK* gene (normal 5-34 repeats, asymptomatic/premutation 35-49 repeats, mild DM1

phenotype 50~150, classical DM1 ~100-1000, congenital DM1 > 2000 repeats), (2000; Turner and Hilton-Jones 2010). Repeat numbers correlate only approximately with the severity of the phenotype and a normal genetic test excludes this condition. There is a tendency for the disease severity of DM1 to worsen when inherited by descendants due to further expansion in the size of the *DMPK* gene CTG repeat, a phenomenon called *anticipation*.

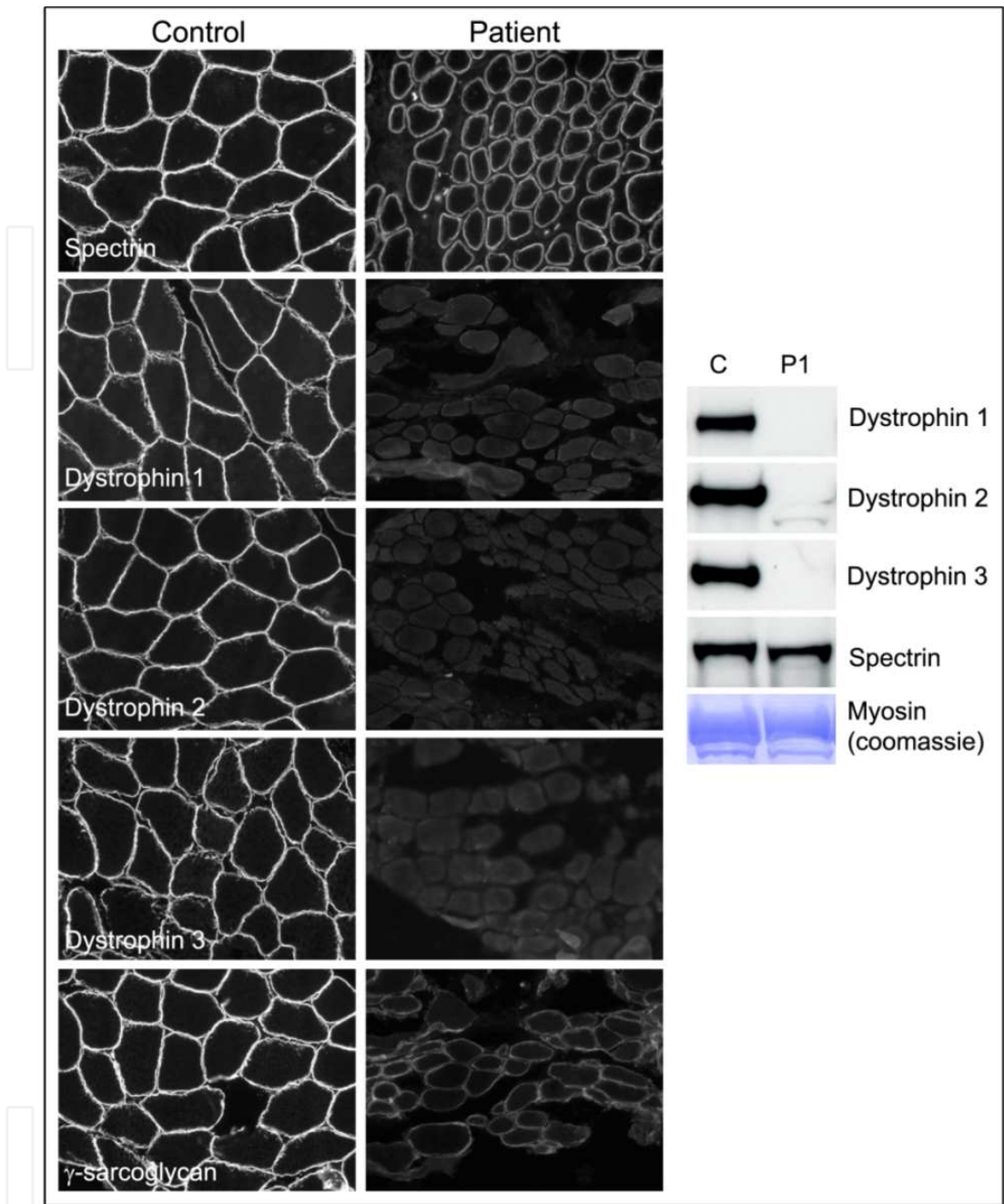
DM2 should be considered as a diagnosis if there are strong clinical clues for DM1 in an adult but genetic testing for DM1 is normal. In DM2, proximal limb weakness is more prominent than in DM1, weakness of facial and ankle dorsiflexor muscles may be less prominent and a congenital-onset form has not been described (Turner and Hilton-Jones 2010). Genetic testing for DM2, which is caused by an expansion of a quadruplet repeat (CCTG) the *ZNF9* gene, is technically more challenging and is less widely performed.

4.2 Facioscapulohumeral MD (FSHD)

A diagnosis of FSHD should be suspected when there is prominent (often asymmetric) weakness of muscles of the face, scapular stabilisers, upper arms and ankle dorsiflexor muscles that begins in late childhood to young adulthood on clinical examination (Sorrel-Dejerine and Fardeau 1982). With disease progression many other muscle groups become involved such as neck extensors, abdominal and pelvic muscles. Although FSHD follows an autosomal dominant pattern of inheritance, a negative family history does not exclude the condition as reduced penetrance (~10% especially in women) and *de novo* mutations (~20%) are relatively common. If a diagnosis of FSHD is considered possible on the basis of a clinical examination, genetic testing is the first investigation of choice since muscle biopsy usually shows non-specific dystrophic abnormalities and no protein studies are helpful. FSHD has a complex genetic cause that is not yet fully understood, but is associated with reduced numbers of large scale D4Z4 repeats in the subtelomeric region of chromosome 4. Genetic testing for the 4q deletion is technically challenging and is only 95% sensitive for the condition with the possibility of intermediate results, which are often difficult to interpret. As a result, testing is best conducted in an experienced laboratory, and family studies and the input of a clinical geneticist may assist when results are unclear.

4.3 Duchenne muscular dystrophy (DMD)

The diagnosis of DMD can usually be suspected on the basis of family history, age of onset, and clinical examination. DMD is an X-linked disorder that usually only affects males. Serum CK levels are markedly elevated in all male patients from birth. DMD gene testing using multiplex ligation-dependent probe amplification (MLPA) is a useful preliminary test that detects exon deletions or duplications and is diagnostic in about 75% of DMD patients (and in around 90% of BMD patients). If MLPA is negative, a muscle biopsy is often requested for protein studies. Marked dystrophic features are usually present and absence of dystrophin protein using IHC and/or WB is also diagnostic for DMD (Figure 3). These methods can also be used to detect reduced protein levels or the presence of a truncated protein product in patients with the milder form of the condition, Becker MD (BMD). Dystrophin sequencing may be required to determine point mutations that cannot be detected with MLPA. Around two-thirds of women who have a son with DMD are carriers of the mutation and gonadal mosaicism is relatively common in women who test negative for the mutation in DNA from blood leukocytes. Identifying the mutation causing DMD in



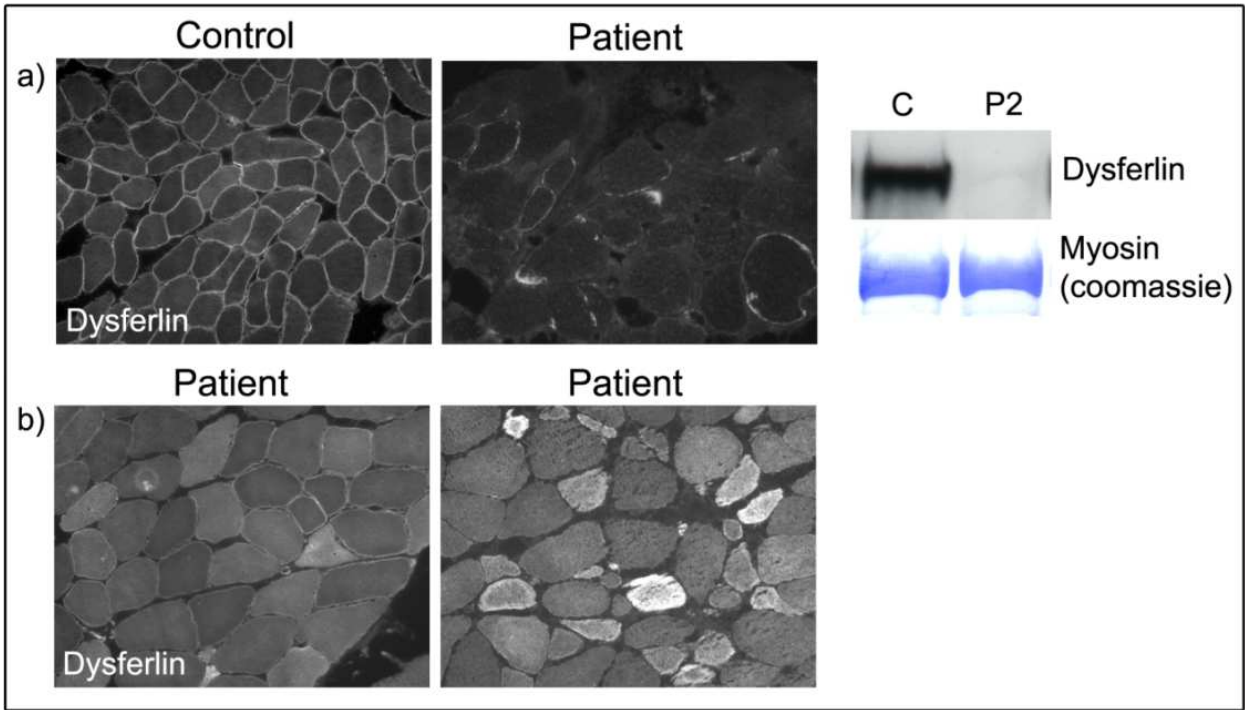
IHC and WB confirm dystrophin-deficiency in a patient with suspected DMD (P1). All patient muscle is stained with spectrin (NCL-SPEC1, Leica Microsystems, Wetzlar, Germany) as a control for membrane integrity. Three antibodies raised to different epitopes spanning the large dystrophin protein are used to help distinguish between total absence of dystrophin (DMD) and reduction or truncation of dystrophin (BMD) (NCL-Dys1, 2 & 3, Leica Microsystems, Wetzlar, Germany). Primary loss of dystrophin can result in secondary reductions in other members of the dystrophin-protein complex (sarcoglycans, dystroglycans) as shown here by a secondary reduction in γ -sarcoglycan (NCL- γ SARC, Leica Microsystems, Wetzlar, Germany), compared to control muscle. Western blot confirms absence of dystrophin protein when probed with the three dystrophin antibodies, strongly suggesting a primary abnormality in dystrophin which was confirmed by DMD gene analysis. Coomassie staining of myosin is used to show that equal amounts of protein are loaded for both patient and control in the WB.

Fig. 3. Immunohistochemistry and Western blot analysis of dystrophin and γ -sarcoglycan in the diagnosis of a patient with DMD.

each family is extremely useful so that highly accurate genetic testing is available for other women in the family who may be at risk of having affected sons. Approximately 10% of females with *DMD* gene mutations will show signs of muscle weakness (manifesting carriers) due to skewing of their ratio of X-chromosome inactivation, but most only become symptomatic during adulthood with mild muscle weakness and/or cardiomyopathy.

4.4 LGMD2B (dysferlinopathy)

A diagnosis of LGMD2B, due to autosomal recessive mutations in the *DYSF* gene, should be considered in patients with muscle weakness that begins in the late teenage years or early adulthood. It is common for *DYSF* patients to present with early involvement of calf muscles (also called Miyoshi myopathy) and difficulty standing on tip-toes. However, some *DYSF* patients present with a classical LGMD pattern of weakness involving the hip and shoulder girdles. Early calf wasting markedly raised serum CK levels (often 5000 – 20 000 U/ml) are distinguishing features of a primary dysferlinopathy, in contrast to many other forms of MD with calf hypertrophy. *DYSF* patient biopsy samples often display a prominent inflammatory cell infiltrate, sometimes leading to misdiagnosis of polymyositis. A range of abnormal dysferlin staining patterns are seen in many types of MD as non-specific secondary abnormalities (see Figure 4b), but complete absence of staining by IHC and WB (Figure 4a) is specific for LGMD2B.

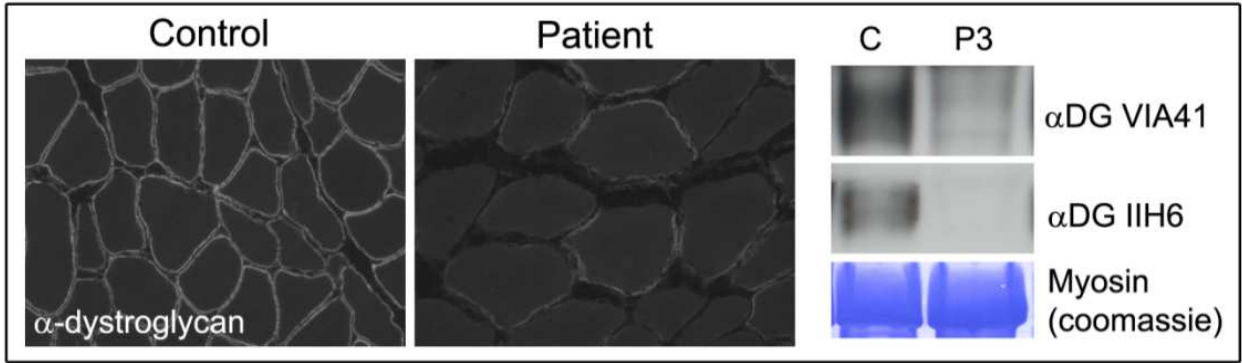


a) IHC of LGMD2B patient muscle shows a severe reduction in dysferlin (NCL-Hamlet, Leica Microsystems) staining at the muscle membrane compared to control muscle, and a corresponding loss of dysferlin by WB (P2). Genetic analysis of this patient confirmed mutations in the *DYSF* gene.
b) Secondary reductions and abnormal dysferlin protein localisation by IHC occur commonly as secondary abnormalities in many dystrophies but absence on WB is specific to dysferlinopathies.

Fig. 4. Immunohistochemistry and Western blot analysis of dysferlin in the diagnosis of LGMD2B.

4.5 LGMD2I

Patients with LGMD2I, due to autosomal recessive mutations in *FKRP*, usually present with a classical LGMD pattern of weakness, often with greater involvement of the lower limbs, and calf hypertrophy. Some patients also have macroglossia (an enlarged tongue) and ankle contractures. α -dystroglycan staining by IHC is usually reduced in LGMD2I patients (see Figure 5), although the reduction may be subtle and is rarely absent. WB can be used to look for reduction of glycosylated α -dystroglycan, which usually appears as a smeared band at ~156 kDa due to variable glycosylation of the core protein which results in a range of final molecular weights (Figure 5). Almost all LGMD2I patients have at least one copy of the c.826C>A (L276I) mutation, a founder mutation that is particularly common in Northern European populations (Walter, Petersen et al. 2004). Severe reductions in α -dystroglycan by IHC and WB can also be associated with other mutations in *FKRP*, or with mutations in the other ‘alpha-dystroglycanopathy’ genes encoding glycosylation enzymes that result in CMD, WWS or MEB phenotypes (see Table 1).



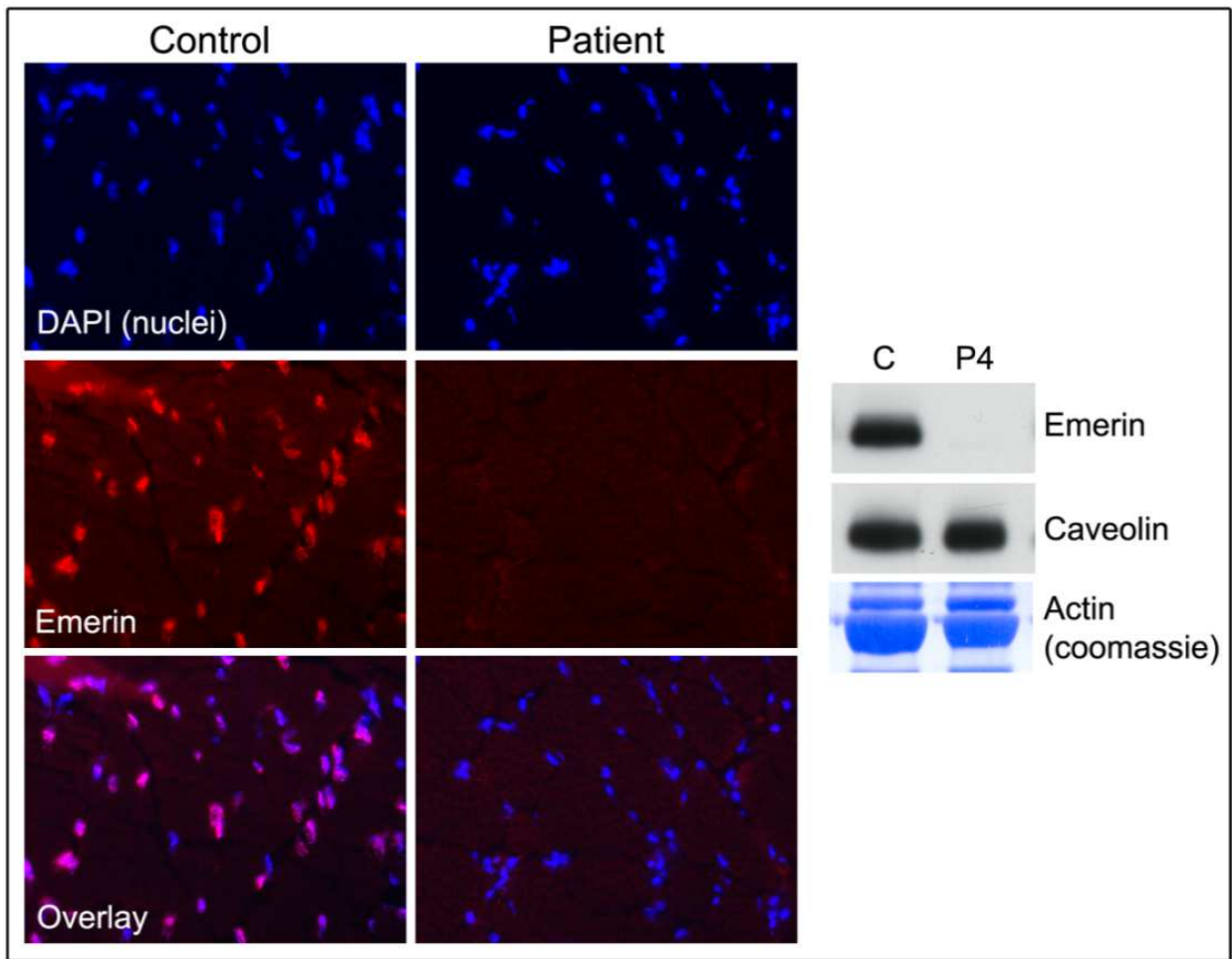
α -dystroglycan levels are reduced by IHC and WB (using both VIA41 (Millipore, CA, USA) and IIH6 (kind gift from Dr Kevin Campbell) antibodies that recognize glycosylated α -dystroglycan, in a number of glycosyltransferase disorders. Specific genetic testing is required to determine the particular genetic cause. In this case the patient was found to have recessive mutations in the *FKRP* gene, causing LGMD2I.

Fig. 5. Immunohistochemistry and Western blot analysis of α -dystroglycan in a patient with LGMD2I.

4.6 Emery-Dreifuss muscular dystrophy (EDMD)

EDMD should be suspected in patients who develop early joint contractures, particularly of the elbows, neck extensors and tendo-Achilles. Patients present with progressive muscle weakness and wasting particularly of the upper arm and ankle dorsiflexor muscles, and often develop cardiac abnormalities (heart block, arrhythmias or cardiomyopathy). Mutations in three genes are associated with this phenotype, *LMNA* (which follows autosomal dominant inheritance), *EMD* and *FHL1* (both X-linked genes), but further genetic causes are likely. IHC for emerin in skeletal muscle shows from the nuclear envelope in X-linked EDMD due to *EMD* mutations and is specific for this condition (see Figure 6). Emerin is also completely absent by WB in these patients (Figure 6). Finding mutations on *EMD* gene sequencing confirms the diagnosis and allows for carrier testing of at-risk females. There are no robust protein-based screening tests for *LMNA* mutations and direct sequencing is required to exclude the diagnosis. Clinicians should have a low threshold for testing both the *EMD* and *LMNA* genes if a diagnosis of EDMD is possible, due to the risk of

developing potentially lethal cardiac arrhythmias. Early diagnosis allows for introduction of close cardiac surveillance by electrocardiogram (ECG), Holter ambulatory ECG monitoring, echocardiography and the early use of implantable cardiac defibrillators to reduce morbidity and mortality.

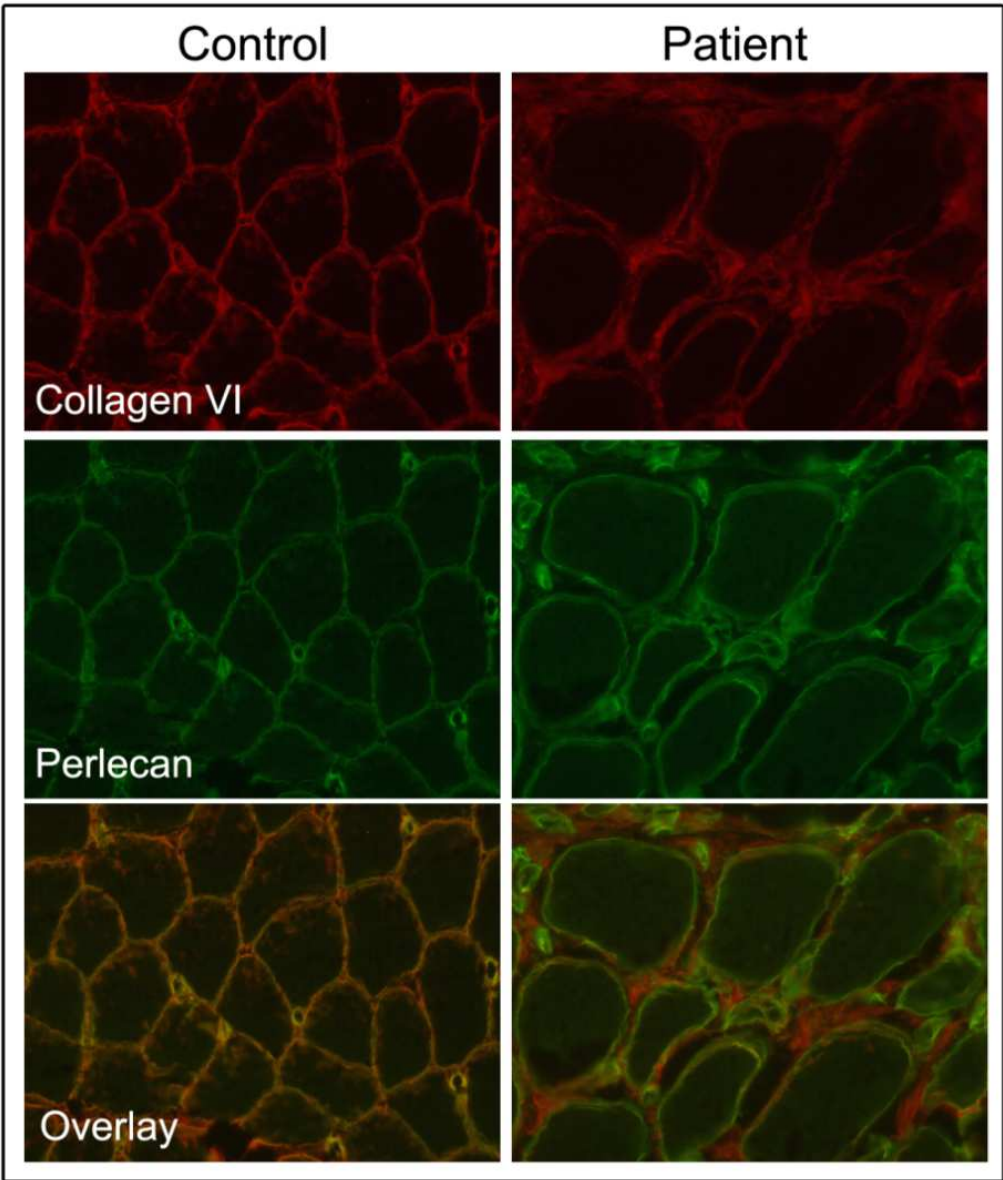


Examples of Emerin immunostaining is absent from the nuclear envelope in muscle from a patient with X-linked EDMD (nuclei are stained by DAPI (4',6-diamidino-2-phenylindole, dihydrochloride), Invitrogen, CA, USA). WB analysis shows absent staining for emerin (P4), and a genetic mutation (c.651_655dupGGGCC) was later identified. Immunoblot for caveolin-3 and coomassie staining of actin are used to show equal protein loading.

Fig. 6. Immunohistochemistry and Western blot analysis of emerin in the diagnosis of EDMD.

4.7 Ullrich congenital muscular dystrophy (UCMD) and Bethlem myopathy

Patients with UCMD usually present with generalised muscle weakness, wasting, hypotonia and marked distal laxity from birth (Nonaka, Une et al. 1981; De Paillette, Aicardi et al. 1989; Mercuri, Yuva et al. 2002). Clinically, patients often have a distinctive sandpaper-like skin rash, congenital hip dislocation, scoliosis, a high arched palate and prominent heels. IHC is a useful diagnostic test, and staining of muscle sections with collagen VI in combination with a muscle membrane marker, e.g. perlecan or collagen IV, can highlight a characteristic loss of collagen VI at the muscle membranes even though collagen VI staining may be retained in connective tissue between fibres (Figure 7). Reduced secretion of collagen VI by cultured



In UCMD and Bethlem myopathy, collagen VI is reduced or lost at the plasma membrane of muscle fibres but may be present in interstitial connective tissue. After carefully optimising conditions to achieve equal intensity of collagen VI (70-XR95, Fitzgerald Industries International Inc, MA, USA) and perlecan (A7L6, MAB1948, Miilipore, CA, USA) staining in control muscle, an overlay image can identify a reduction in collagen VI, relative to perlecan, at the muscle sarcolemmal membrane. In this example, an overlay image from control muscle appears mostly yellow/orange, with broadly equal intensities of perlecan (green) and collagen VI (red) staining. In contrast, an overlay image from a UCMD patient, reveals a dominance of perlecan (green labelling), indicating a relative deficiency of collagen VI (red label) at the muscle membrane. These results are consistent with a primary collagenopathy, and a dominant mutation was identified in the *COL6A2* gene.

Fig. 7. Immunohistochemistry analysis of collagen VI in the diagnosis of UCMD.

patient fibroblasts strongly supports a diagnosis of UCMD or Bethlem myopathy but genetic testing of the three genes that code for collagen VI chains (see Table 1) is required to confirm the diagnosis. Collagen VI gene mutations that do not result in severe protein abnormalities usually present in childhood with a less severe phenotype called Bethlem myopathy.

Progressive joint contractures are major sources of morbidity in both UCMD and Bethlem myopathy and close monitoring for scoliosis and respiratory insufficiency is important, particularly in UCMD.

5. Frequency of diagnosis of less common types of MD

The frequency of some forms of MD varies widely in different parts of the world, which can influence the most appropriate diagnostic approach to follow in different countries.

LGMD2A accounted for 50% of all LGMD patients in a Turkish study (Dincer, Leturcq et al. 1997), around 25% of patients in Italy (Guglieri, Magri et al. 2008; Fanin, Nascimbeni et al. 2009) and the United Kingdom (UK) (Norwood, Harling et al. 2009) but only 5-8% in American (Moore, Shilling et al. 2006), Brazilian (Vainzof, Passos-Bueno et al. 1999) and Australian (Lo, Cooper et al. 2008) studies. Although different diagnostic techniques may account for some of the variability, this finding points to major regional differences in the frequency of CAPN3 gene mutations in different populations. Similarly LGMD2I seems particularly prevalent in Scandinavia (Sveen, Schwartz et al. 2006) and the UK (Norwood, Harling et al. 2009) compared with other populations (see Table 3). High rates of known genetic forms of LGMD likely contribute to a high overall rate of LGMD diagnosis in Turkey (Dincer, Leturcq et al. 1997), the UK (Norwood, Harling et al. 2009) and Denmark (Sveen, Schwartz et al. 2006). The rates identified for many forms of LGMD are similar in Australia (Lo, Cooper et al. 2008) to the USA (Moore, Shilling et al. 2006) and it is interesting that both populations are comprised of a mixture of ethnicities.

	LGMD								Total Diagnosis
	1A	1B	1C	2A	2B	2C,D,E,F	2G	2I	
Denmark ¹	NA	NA	NA	12%	2%	22%	NA	37%	73%
Turkey ²	NA	NA	NA	50%	5%	20%	NA	NA	75%
Italy ³	0%	0%	1.3%	28%	19%	18%	0%	6%	73%
Northern England ⁴		9%		26%	6%	12%		19%	72%
USA ⁵	0.6%	7%	0%	9%	3%	19%	NA	7%	46%
Italy ⁶	NA	1%	1.5%	19%	8%	11%	NA	3%	43%
Brazil ⁷	NA	NA	NA	5%	3%	17%	NA	NA	24%
Australia ⁸	NA	1%	2.6%	8%	5%	2.6%	NA	2.6%	23%
Brazil ⁹	NA	NA	NA	32%	22%	32%	3%	11%	N/A

LGMD = limb-girdle muscular dystrophy. NA = not assessed, N/A = retrospective review, no total diagnosis stated. References: 1(Sveen, Schwartz et al. 2006), 2(Dincer, Leturcq et al. 1997), 3(Guglieri, Magri et al. 2008), 4(Norwood, Harling et al. 2009), 5(Moore, Shilling et al. 2006), 6(Fanin, Nascimbeni et al. 2009), 7(Vainzof, Passos-Bueno et al. 1999), 8(Lo, Cooper et al. 2008) and 9(Zatz, de Paula et al. 2003).

Table 3. Diagnoses in LGMD cohort studies.

As for LGMD, the proportions of some forms of CMD have varied widely between studies in different countries. A Brazilian study diagnosed merosin-deficiency in around 40% of CMD patients (Ferreira, Marie et al. 2005), while this diagnosis accounted for only 8% of CMD patients in an Australian study (Peat, Smith et al. 2008). Differences in CMD

ascertainment criteria may be partly responsible but it is likely there are true differences in disease incidence in different populations. Similarly, different rates of collagen VI diagnoses have been observed, ranging from 8% in Australia (Peat, Smith et al. 2008) to 1.7% in Brazil (Ferreira, Marie et al. 2005).

6. Future directions

In the past, genetic testing for MD has involved the sequencing of individual genes that were considered likely causes based on clinical presentation and screening tests. The large number of possible genetic causes with overlapping phenotypes has made it difficult to predict the correct genetic cause in many MD patients and consequently, finding the causative mutation in many families has often been a prolonged, expensive exercise. Recent advances in gene sequencing are likely to have a major impact on the diagnosis of MD in the near future. It is now possible to sequence multiple muscle disease genes and even the whole genome relatively cheaply in a single experiment (Metzker 2010). Next generation sequencing technologies will also facilitate the discovery of new MD genes, leading to increased rates of patient diagnosis. As these technologies become more routinely used and costs reduce, the approach to diagnosing forms of MD such as, LGMD, that have many possible genetic causes is likely to move from the sequencing of individual candidate genes towards a multi-gene or genome-wide sequencing approach. Some diagnostic centres worldwide are already implementing this technology for the diagnosis of MDs. These methods bring new challenges, such as distinguishing genetic sequence variants that are the primary cause of the disease from variants that modify a phenotype or are harmless polymorphisms. It is likely that there will always be a need for centres with expertise in clinical phenotyping and protein studies to clarify the diagnosis when genetic analysis alone cannot confirm whether a sequence variant in a gene is truly disease-causing or not.

7. Glossary

BMD	Becker muscular dystrophy
CK	Creatine kinase
CMD	Congenital muscular dystrophy
DMD	Duchenne muscular dystrophy
DM	Myotonic dystrophy (DM1 Type 1, DM2 Type 2)
ECG	Electrocardiogram
EDMD	Emery Dreifuss muscular dystrophy
FCMD	Fukuyama congenital muscular dystrophy
FSHD	Facioscapulohumeral muscular dystrophy
IHC	Immunohistochemistry
LGMD	Limb girdle muscular dystrophy (Type 1 dominant, Type 2 recessive)
MD	Muscular dystrophy
MEB	Muscle-eye-brain disease
MLPA	Multiplex Ligation-dependent Probe Amplification
MRI	Magnetic resonance imaging
UCMD	Ullrich congenital muscular dystrophy
UK	United Kingdom
WB	Western blot
WWS	Walker-Warburg Syndrome

8. References

- (2000). "New nomenclature and DNA testing guidelines for myotonic dystrophy type 1 (DM1). The International Myotonic Dystrophy Consortium (IDMC)." *Neurology* 54(6): 1218-1221.
- Allamand, V. and P. Guicheney (2002). "Merosin-deficient congenital muscular dystrophy, autosomal recessive (MDC1A, MIM#156225, LAMA2 gene coding for alpha2 chain of laminin)." *Eur J Hum Genet* 10(2): 91-94.
- Azibi, K., L. Bachner, et al. (1993). "Severe childhood autosomal recessive muscular dystrophy with the deficiency of the 50 kDa dystrophin-associated glycoprotein maps to chromosome 13q12." *Hum Mol Genet* 2(9): 1423-1428.
- Balci, B., G. Uyanik, et al. (2005). "An autosomal recessive limb girdle muscular dystrophy (LGMD2) with mild mental retardation is allelic to Walker-Warburg syndrome (WWS) caused by a mutation in the POMT1 gene." *Neuromuscul Disord* 15(4): 271-275.
- Bashir, R., S. Britton, et al. (1998). "A gene related to *Caenorhabditis elegans* spermatogenesis factor fer-1 is mutated in limb-girdle muscular dystrophy type 2B." *Nat Genet* 20(1): 37-42.
- Beltran-Valero de Bernabe, D., S. Currier, et al. (2002). "Mutations in the O-mannosyltransferase gene POMT1 give rise to the severe neuronal migration disorder Walker-Warburg syndrome." *Am J Hum Genet* 71(5): 1033-1043.
- Beltran-Valero de Bernabe, D., T. Voit, et al. (2004). "Mutations in the FKRP gene can cause muscle-eye-brain disease and Walker-Warburg syndrome." *J Med Genet* 41(5): e61.
- Bertini, E. and G. Pepe (2002). "Collagen type VI and related disorders: Bethlem myopathy and Ullrich scleroatonic muscular dystrophy." *Eur J Paediatr Neurol* 6(4): 193-198.
- Biancheri, R., A. Falace, et al. (2007). "POMT2 gene mutation in limb-girdle muscular dystrophy with inflammatory changes." *Biochem Biophys Res Commun* 363(4): 1033-1037.
- Bione, S., E. Maestrini, et al. (1994). "Identification of a novel X-linked gene responsible for Emery-Dreifuss muscular dystrophy." *Nat Genet* 8(4): 323-327.
- Bolduc, V., G. Marlow, et al. (2010). "Recessive mutations in the putative calcium-activated chloride channel Anoctamin 5 cause proximal LGMD2L and distal MMD3 muscular dystrophies." *Am J Hum Genet* 86(2): 213-221.
- Bonilla, E., C. E. Samitt, et al. (1988). "Duchenne muscular dystrophy: deficiency of dystrophin at the muscle cell surface." *Cell* 54(4): 447-452.
- Bonne, G., M. R. Di Barletta, et al. (1999). "Mutations in the gene encoding lamin A/C cause autosomal dominant Emery-Dreifuss muscular dystrophy." *Nat Genet* 21(3): 285-288.
- Bonne, G., E. Mercuri, et al. (2000). "Clinical and molecular genetic spectrum of autosomal dominant Emery-Dreifuss muscular dystrophy due to mutations of the lamin A/C gene." *Ann Neurol* 48(2): 170-180.
- Bonnemann, C. G., M. R. Passos-Bueno, et al. (1996). "Genomic screening for beta-sarcoglycan gene mutations: missense mutations may cause severe limb-girdle muscular dystrophy type 2E (LGMD 2E)." *Hum Mol Genet* 5(12): 1953-1961.
- Bonnemann, C. G., J. Wong, et al. (2002). "Primary gamma-sarcoglycanopathy (LGMD 2C): broadening of the mutational spectrum guided by the immunohistochemical profile." *Neuromuscul Disord* 12(3): 273-280.
- Borg, K., R. Stucka, et al. (2009). "Intragenic deletion of TRIM32 in compound heterozygotes with sarcotubular myopathy/LGMD2H." *Hum Mutat*.

- Brais, B., J. P. Bouchard, et al. (1998). "Short GCG expansions in the PABP2 gene cause oculopharyngeal muscular dystrophy." *Nat Genet* 18(2): 164-167.
- Brais, B., Y. G. Xie, et al. (1995). "The oculopharyngeal muscular dystrophy locus maps to the region of the cardiac alpha and beta myosin heavy chain genes on chromosome 14q11.2-q13." *Hum Mol Genet* 4(3): 429-434.
- Brockington, M., D. J. Blake, et al. (2001). "Mutations in the fukutin-related protein gene (FKRP) cause a form of congenital muscular dystrophy with secondary laminin alpha2 deficiency and abnormal glycosylation of alpha-dystroglycan." *Am J Hum Genet* 69(6): 1198-1209.
- Brockington, M., C. A. Sewry, et al. (2000). "Assignment of a form of congenital muscular dystrophy with secondary merosin deficiency to chromosome 1q42." *Am J Hum Genet* 66(2): 428-435.
- Brockington, M., Y. Yuva, et al. (2001). "Mutations in the fukutin-related protein gene (FKRP) identify limb girdle muscular dystrophy 2I as a milder allelic variant of congenital muscular dystrophy MDC1C." *Hum Mol Genet* 10(25): 2851-2859.
- Brook, J. D., M. E. McCurrach, et al. (1992). "Molecular basis of myotonic dystrophy: expansion of a trinucleotide (CTG) repeat at the 3' end of a transcript encoding a protein kinase family member." *Cell* 68(4): 799-808.
- Burghes, A. H., C. Logan, et al. (1987). "A cDNA clone from the Duchenne/Becker muscular dystrophy gene." *Nature* 328(6129): 434-437.
- Bushby, K., R. Bashir, et al. (1996). "The molecular biology of LGMD2B--towards the identification of the LGMD gene on chromosome 2p13." *Neuromuscul Disord* 6(6): 491-492.
- Bushby, K., R. Finkel, et al. (2010). "Diagnosis and management of Duchenne muscular dystrophy, part 1: diagnosis, and pharmacological and psychosocial management." *Lancet Neurol* 9(1): 77-93.
- Bushby, K., F. Norwood, et al. (2007). "The limb-girdle muscular dystrophies--diagnostic strategies." *Biochim Biophys Acta* 1772(2): 238-242.
- Camacho Vanegas, O., E. Bertini, et al. (2001). "Ullrich scleroatonic muscular dystrophy is caused by recessive mutations in collagen type VI." *Proc Natl Acad Sci U S A* 98(13): 7516-7521.
- Carbone, I., C. Bruno, et al. (2000). "Mutation in the CAV3 gene causes partial caveolin-3 deficiency and hyperCKemia." *Neurology* 54(6): 1373-1376.
- Clarke, N. F., W. Kidson, et al. (2006). "SEPN1: associated with congenital fiber-type disproportion and insulin resistance." *Ann Neurol* 59(3): 546-552.
- Cooper, S. T., H. P. Lo, et al. (2003). "Single section Western blot: improving the molecular diagnosis of the muscular dystrophies." *Neurology* 61(1): 93-97.
- Cupler, E. J., S. Bohlega, et al. (1998). "Miyoshi myopathy in Saudi Arabia: clinical, electrophysiological, histopathological and radiological features." *Neuromuscul Disord* 8(5): 321-326.
- de Bernabe, D. B., H. van Bokhoven, et al. (2003). "A homozygous nonsense mutation in the fukutin gene causes a Walker-Warburg syndrome phenotype." *J Med Genet* 40(11): 845-848.
- De Paillette, L., J. Aicardi, et al. (1989). "Ullrich's congenital atonic sclerotic muscular dystrophy. A case report." *J Neurol* 236(2): 108-110.
- Demir, E., P. Sabatelli, et al. (2002). "Mutations in COL6A3 cause severe and mild phenotypes of Ullrich congenital muscular dystrophy." *Am J Hum Genet* 70(6): 1446-1458.

- Dincer, P., F. Leturcq, et al. (1997). "A biochemical, genetic, and clinical survey of autosomal recessive limb girdle muscular dystrophies in Turkey." *Ann Neurol* 42(2): 222-229.
- Driss, A., R. Amouri, et al. (2000). "A new locus for autosomal recessive limb-girdle muscular dystrophy in a large consanguineous Tunisian family maps to chromosome 19q13.3." *Neuromuscul Disord* 10(4-5): 240-246.
- Emery, A. E. (1989). "Emery-Dreifuss syndrome." *J Med Genet* 26(10): 637-641.
- Eymard, B., N. B. Romero, et al. (1997). "Primary adhalinopathy (alpha-sarcoglycanopathy): clinical, pathologic, and genetic correlation in 20 patients with autosomal recessive muscular dystrophy." *Neurology* 48(5): 1227-1234.
- Fanin, M., L. Fulizio, et al. (2004). "Molecular diagnosis in LGMD2A: mutation analysis or protein testing?" *Hum Mutat* 24(1): 52-62.
- Fanin, M., A. C. Nascimbeni, et al. (2009). "Frequency of LGMD gene mutations in Italian patients with distinct clinical phenotypes." *Neurology* 72(16): 1432-1435.
- Fardeau, M., D. Hillaire, et al. (1996). "Juvenile limb-girdle muscular dystrophy. Clinical, histopathological and genetic data from a small community living in the Reunion Island." *Brain* 119 (Pt 1): 295-308.
- Ferreira, L. G., S. K. Marie, et al. (2005). "Dystrophin-glycoproteins associated in congenital muscular dystrophy: immunohistochemical analysis of 59 Brazilian cases." *Arq Neuropsiquiatr* 63(3B): 791-800.
- Ferreiro, A., S. Quijano-Roy, et al. (2002). "Mutations of the selenoprotein N gene, which is implicated in rigid spine muscular dystrophy, cause the classical phenotype of multimimicore disease: reassessing the nosology of early-onset myopathies." *Am J Hum Genet* 71(4): 739-749.
- Fischer, D., M. C. Walter, et al. (2005). "Diagnostic value of muscle MRI in differentiating LGMD2I from other LGMDs." *J Neurol* 252(5): 538-547.
- Flanigan, K. M., L. Kerr, et al. (2000). "Congenital muscular dystrophy with rigid spine syndrome: a clinical, pathological, radiological, and genetic study." *Ann Neurol* 47(2): 152-161.
- Frosk, P., T. Weiler, et al. (2002). "Limb-girdle muscular dystrophy type 2H associated with mutation in TRIM32, a putative E3-ubiquitin-ligase gene." *Am J Hum Genet* 70(3): 663-672.
- Giusti, B., L. Lucarini, et al. (2005). "Dominant and recessive COL6A1 mutations in Ullrich scleroatonic muscular dystrophy." *Ann Neurol* 58(3): 400-410.
- Godfrey, C., E. Clement, et al. (2007). "Refining genotype phenotype correlations in muscular dystrophies with defective glycosylation of dystroglycan." *Brain* 130(Pt 10): 2725-2735.
- Godfrey, C., D. Escolar, et al. (2006). "Fukutin gene mutations in steroid-responsive limb girdle muscular dystrophy." *Ann Neurol* 60(5): 603-610.
- Groen, E. J., R. Charlton, et al. (2007). "Analysis of the UK diagnostic strategy for limb girdle muscular dystrophy 2A." *Brain* 130(Pt 12): 3237-3249.
- Gueneau, L., A. T. Bertrand, et al. (2009). "Mutations of the FHL1 gene cause Emery-Dreifuss muscular dystrophy." *Am J Hum Genet* 85(3): 338-353.
- Guglieri, M. and K. Bushby (2008). "How to go about diagnosing and managing the limb-girdle muscular dystrophies." *Neurol India* 56(3): 271-280.
- Guglieri, M., F. Magri, et al. (2008). "Clinical, molecular, and protein correlations in a large sample of genetically diagnosed Italian limb girdle muscular dystrophy patients." *Hum Mutat* 29(2): 258-266.

- Hackman, P., A. Vihola, et al. (2002). "Tibial muscular dystrophy is a titinopathy caused by mutations in TTN, the gene encoding the giant skeletal-muscle protein titin." *Am J Hum Genet* 71(3): 492-500.
- Hauser, M. A., S. K. Horrigan, et al. (2000). "Myotilin is mutated in limb girdle muscular dystrophy 1A." *Hum Mol Genet* 9(14): 2141-2147.
- Hayashi, Y. K., F. L. Chou, et al. (1998). "Mutations in the integrin alpha7 gene cause congenital myopathy." *Nat Genet* 19(1): 94-97.
- Hayashi, Y. K., C. Matsuda, et al. (2009). "Human PTRF mutations cause secondary deficiency of caveolins resulting in muscular dystrophy with generalized lipodystrophy." *J Clin Invest* 119(9): 2623-2633.
- Helbling-Leclerc, A., X. Zhang, et al. (1995). "Mutations in the laminin alpha 2-chain gene (LAMA2) cause merosin-deficient congenital muscular dystrophy." *Nat Genet* 11(2): 216-218.
- Herrmann, R., V. Straub, et al. (2000). "Dissociation of the dystroglycan complex in caveolin-3-deficient limb girdle muscular dystrophy." *Hum Mol Genet* 9(15): 2335-2340.
- Hicks, D., A. Sarkozy, et al. (2011). "A founder mutation in Anoctamin 5 is a major cause of limb-girdle muscular dystrophy." *Brain* 134(Pt 1): 171-182.
- Higuchi, I., T. Shiraishi, et al. (2001). "Frameshift mutation in the collagen VI gene causes Ullrich's disease." *Ann Neurol* 50(2): 261-265.
- Hillaire, D., A. Leclerc, et al. (1994). "Localization of merosin-negative congenital muscular dystrophy to chromosome 6q2 by homozygosity mapping." *Hum Mol Genet* 3(9): 1657-1661.
- Himmerich, E., S. Popov, et al. (2000). "[Hidden intracardiac conduction disturbances and their spontaneous course in patients with progressive muscular dystrophy]." *Z Kardiol* 89(7): 592-598.
- Hoffman, E. P., R. H. Brown, Jr., et al. (1987). "Dystrophin: the protein product of the Duchenne muscular dystrophy locus." *Cell* 51(6): 919-928.
- Hoffman, E. P., K. H. Fischbeck, et al. (1988). "Characterization of dystrophin in muscle-biopsy specimens from patients with Duchenne's or Becker's muscular dystrophy." *N Engl J Med* 318(21): 1363-1368.
- Jobsis, G. J., H. Keizers, et al. (1996). "Type VI collagen mutations in Bethlem myopathy, an autosomal dominant myopathy with contractures." *Nat Genet* 14(1): 113-115.
- Jones, K. J., S. S. Kim, et al. (1998). "Abnormalities of dystrophin, the sarcoglycans, and laminin alpha2 in the muscular dystrophies." *J Med Genet* 35(5): 379-386.
- Jones, K. J., G. Morgan, et al. (2001). "The expanding phenotype of laminin alpha2 chain (merosin) abnormalities: case series and review." *J Med Genet* 38(10): 649-657.
- Jones, K. J. and K. N. North (1997). "Recent advances in diagnosis of the childhood muscular dystrophies." *J Paediatr Child Health* 33(3): 195-201.
- Kaplan, J. C. (2010). "The 2011 version of the gene table of neuromuscular disorders." *Neuromuscul Disord* 20(12): 852-873.
- Kobayashi, K., Y. Nakahori, et al. (1998). "An ancient retrotransposal insertion causes Fukuyama-type congenital muscular dystrophy." *Nature* 394(6691): 388-392.
- Koenig, M., E. P. Hoffman, et al. (1987). "Complete cloning of the Duchenne muscular dystrophy (DMD) cDNA and preliminary genomic organization of the DMD gene in normal and affected individuals." *Cell* 50(3): 509-517.
- Koenig, M., A. P. Monaco, et al. (1988). "The complete sequence of dystrophin predicts a rod-shaped cytoskeletal protein." *Cell* 53(2): 219-228.


- Lamminen, A. E. (1990). "Magnetic resonance imaging of primary skeletal muscle diseases: patterns of distribution and severity of involvement." *Br J Radiol* 63(756): 946-950.
- Lamminen, A. E., J. I. Tantt, et al. (1990). "Magnetic resonance of diseased skeletal muscle: combined T1 measurement and chemical shift imaging." *Br J Radiol* 63(752): 591-596.
- Lim, L. E., F. Duclos, et al. (1995). "Beta-sarcoglycan: characterization and role in limb-girdle muscular dystrophy linked to 4q12." *Nat Genet* 11(3): 257-265.
- Liquori, C. L., K. Ricker, et al. (2001). "Myotonic dystrophy type 2 caused by a CCTG expansion in intron 1 of ZNF9." *Science* 293(5531): 864-867.
- Liu, J., M. Aoki, et al. (1998). "Dysferlin, a novel skeletal muscle gene, is mutated in Miyoshi myopathy and limb girdle muscular dystrophy." *Nat Genet* 20(1): 31-36.
- Lo, H. P., S. T. Cooper, et al. (2008). "Limb-girdle muscular dystrophy: diagnostic evaluation, frequency and clues to pathogenesis." *Neuromuscul Disord* 18(1): 34-44.
- Lodi, R., F. Muntoni, et al. (1997). "Correlative MR imaging and 31P-MR spectroscopy study in sarcoglycan deficient limb girdle muscular dystrophy." *Neuromuscul Disord* 7(8): 505-511.
- Longman, C., M. Brockington, et al. (2003). "Mutations in the human LARGE gene cause MDC1D, a novel form of congenital muscular dystrophy with severe mental retardation and abnormal glycosylation of alpha-dystroglycan." *Hum Mol Genet* 12(21): 2853-2861.
- McNally, E. M., E. de Sa Moreira, et al. (1998). "Caveolin-3 in muscular dystrophy." *Hum Mol Genet* 7(5): 871-877.
- McNally, E. M. and P. Pytel (2007). "Muscle diseases: the muscular dystrophies." *Annu Rev Pathol* 2: 87-109.
- Menezes, M.P., L.B. Waddell, et al. (2011) "The importance and challenge of making an early diagnosis in LMNA-related muscular dystrophy." *Neurol.* (Accepted 14th Dec 2011).
- Meola, G., V. Sansone, et al. (1996). "Computerized tomography and magnetic resonance muscle imaging in Miyoshi's myopathy." *Muscle Nerve* 19(11): 1476-1480.
- Mercuri, E., C. Cini, et al. (2002). "Muscle MRI findings in a three-generation family affected by Bethlem myopathy." *Eur J Paediatr Neurol* 6(6): 309-314.
- Mercuri, E., C. Cini, et al. (2003). "Muscle magnetic resonance imaging in patients with congenital muscular dystrophy and Ullrich phenotype." *Neuromuscul Disord* 13(7-8): 554-558.
- Mercuri, E., E. Clements, et al. (2010). "Muscle magnetic resonance imaging involvement in muscular dystrophies with rigidity of the spine." *Ann Neurol* 67(2): 201-208.
- Mercuri, E., S. Counsell, et al. (2002). "Selective muscle involvement on magnetic resonance imaging in autosomal dominant Emery-Dreifuss muscular dystrophy." *Neuropediatrics* 33(1): 10-14.
- Mercuri, E., A. D'Amico, et al. (2006). "POMT2 mutation in a patient with 'MEB-like' phenotype." *Neuromuscul Disord* 16(7): 446-448.
- Mercuri, E., H. Jungbluth, et al. (2005). "Muscle imaging in clinical practice: diagnostic value of muscle magnetic resonance imaging in inherited neuromuscular disorders." *Curr Opin Neurol* 18(5): 526-537.
- Mercuri, E., A. Lampe, et al. (2005). "Muscle MRI in Ullrich congenital muscular dystrophy and Bethlem myopathy." *Neuromuscul Disord* 15(4): 303-310.
- Mercuri, E., A. Pichiecchio, et al. (2002). "A short protocol for muscle MRI in children with muscular dystrophies." *Eur J Paediatr Neurol* 6(6): 305-307.

- Mercuri, E., B. Talim, et al. (2002). "Clinical and imaging findings in six cases of congenital muscular dystrophy with rigid spine syndrome linked to chromosome 1p (RSMD1)." *Neuromuscul Disord* 12(7-8): 631-638.
- Mercuri, E., Y. Yuva, et al. (2002). "Collagen VI involvement in Ullrich syndrome: a clinical, genetic, and immunohistochemical study." *Neurology* 58(9): 1354-1359.
- Messina, D. N., M. C. Speer, et al. (1997). "Linkage of familial dilated cardiomyopathy with conduction defect and muscular dystrophy to chromosome 6q23." *Am J Hum Genet* 61(4): 909-917.
- Metzker, M. L. (2010). "Sequencing technologies - the next generation." *Nat Rev Genet* 11(1): 31-46.
- Minetti, C., F. Sotgia, et al. (1998). "Mutations in the caveolin-3 gene cause autosomal dominant limb-girdle muscular dystrophy." *Nat Genet* 18(4): 365-368.
- Moghadaszadeh, B., I. Desguerre, et al. (1998). "Identification of a new locus for a peculiar form of congenital muscular dystrophy with early rigidity of the spine, on chromosome 1p35-36." *Am J Hum Genet* 62(6): 1439-1445.
- Moghadaszadeh, B., N. Petit, et al. (2001). "Mutations in SEPN1 cause congenital muscular dystrophy with spinal rigidity and restrictive respiratory syndrome." *Nat Genet* 29(1): 17-18.
- Monaco, A. P., R. L. Neve, et al. (1986). "Isolation of candidate cDNAs for portions of the Duchenne muscular dystrophy gene." *Nature* 323(6089): 646-650.
- Moore, S. A., C. J. Shilling, et al. (2006). "Limb-girdle muscular dystrophy in the United States." *J Neuropathol Exp Neurol* 65(10): 995-1003.
- Moreira, E. S., M. Vainzof, et al. (1997). "The seventh form of autosomal recessive limb-girdle muscular dystrophy is mapped to 17q11-12." *Am J Hum Genet* 61(1): 151-159.
- Moreira, E. S., T. J. Wiltshire, et al. (2000). "Limb-girdle muscular dystrophy type 2G is caused by mutations in the gene encoding the sarcomeric protein telethonin." *Nat Genet* 24(2): 163-166.
- Muchir, A., G. Bonne, et al. (2000). "Identification of mutations in the gene encoding lamins A/C in autosomal dominant limb girdle muscular dystrophy with atrioventricular conduction disturbances (LGMD1B)." *Hum Mol Genet* 9(9): 1453-1459.
- Murakami, T., Y. K. Hayashi, et al. (2006). "Fukutin gene mutations cause dilated cardiomyopathy with minimal muscle weakness." *Ann Neurol* 60(5): 597-602.
- Nadeau, A., M. Kinali, et al. (2009). "Natural history of Ullrich congenital muscular dystrophy." *Neurology* 73(1): 25-31.
- Nguyen, K., G. Bassez, et al. (2005). "Dysferlin mutations in LGMD2B, Miyoshi myopathy, and atypical dysferlinopathies." *Hum Mutat* 26(2): 165.
- Nigro, V., E. de Sa Moreira, et al. (1996). "Autosomal recessive limb-girdle muscular dystrophy, LGMD2F, is caused by a mutation in the delta-sarcoglycan gene." *Nat Genet* 14(2): 195-198.
- Noguchi, S., E. M. McNally, et al. (1995). "Mutations in the dystrophin-associated protein gamma-sarcoglycan in chromosome 13 muscular dystrophy." *Science* 270(5237): 819-822.
- Nonaka, I., Y. Une, et al. (1981). "A clinical and histological study of Ullrich's disease (congenital atonic-sclerotic muscular dystrophy)." *Neuropediatrics* 12(3): 197-208.
- North, K. N., L. A. Specht, et al. (1996). "Congenital muscular dystrophy associated with merosin deficiency." *J Child Neurol* 11(4): 291-295.

- Norwood, F., M. de Visser, et al. (2007). "EFNS guideline on diagnosis and management of limb girdle muscular dystrophies." *Eur J Neurol* 14(12): 1305-1312.
- Norwood, F. L., C. Harling, et al. (2009). "Prevalence of genetic muscle disease in Northern England: in-depth analysis of a muscle clinic population." *Brain* 132(Pt 11): 3175-3186.
- Palenzuela, L., A. L. Andreu, et al. (2003). "A novel autosomal dominant limb-girdle muscular dystrophy (LGMD 1F) maps to 7q32.1-32.2." *Neurology* 61(3): 404-406.
- Pan, T. C., R. Z. Zhang, et al. (1998). "CA repeat polymorphism of the COL6A3 gene on chromosome 2q37." *Hum Hered* 48(4): 235-236.
- Pan, T. C., R. Z. Zhang, et al. (2003). "New molecular mechanism for Ullrich congenital muscular dystrophy: a heterozygous in-frame deletion in the COL6A1 gene causes a severe phenotype." *Am J Hum Genet* 73(2): 355-369.
- Pandya, S., W. M. King, et al. (2008). "Facioscapulohumeral dystrophy." *Phys Ther* 88(1): 105-113.
- Paradas, C., J. Llauger, et al. (2010). "Redefining dysferlinopathy phenotypes based on clinical findings and muscle imaging studies." *Neurology* 75(4): 316-323.
- Passos-Bueno, M. R., E. S. Moreira, et al. (1996). "Linkage analysis in autosomal recessive limb-girdle muscular dystrophy (AR LGMD) maps a sixth form to 5q33-34 (LGMD2F) and indicates that there is at least one more subtype of AR LGMD." *Hum Mol Genet* 5(6): 815-820.
- Peat, R. A., J. M. Smith, et al. (2008). "Diagnosis and etiology of congenital muscular dystrophy." *Neurology* 71(5): 312-321.
- Piluso, G., L. Politano, et al. (2005). "Extensive scanning of the calpain-3 gene broadens the spectrum of LGMD2A phenotypes." *J Med Genet* 42(9): 686-693.
- Quijano-Roy, S., B. Mbieleu, et al. (2008). "De novo LMNA mutations cause a new form of congenital muscular dystrophy." *Ann Neurol* 64(2): 177-186.
- Rankin, J., M. Auer-Grumbach, et al. (2008). "Extreme phenotypic diversity and nonpenetrance in families with the LMNA gene mutation R644C." *Am J Med Genet A* 146A(12): 1530-1542.
- Ranum, L. P., P. F. Rasmussen, et al. (1998). "Genetic mapping of a second myotonic dystrophy locus." *Nat Genet* 19(2): 196-198.
- Renwick, J. H., S. E. Bunday, et al. (1971). "Confirmation of linkage of the loci for myotonic dystrophy and ABH secretion." *J Med Genet* 8(4): 407-416.
- Richard, I., L. Brenguier, et al. (1997). "Multiple independent molecular etiology for limb-girdle muscular dystrophy type 2A patients from various geographical origins." *Am J Hum Genet* 60(5): 1128-1138.
- Richard, I., O. Broux, et al. (1995). "Mutations in the proteolytic enzyme calpain 3 cause limb-girdle muscular dystrophy type 2A." *Cell* 81(1): 27-40.
- Roberds, S. L., F. Leturcq, et al. (1994). "Missense mutations in the adhalin gene linked to autosomal recessive muscular dystrophy." *Cell* 78(4): 625-633.
- Robinson, D. O., S. R. Hammans, et al. (2005). "Oculopharyngeal muscular dystrophy (OPMD): analysis of the PABPN1 gene expansion sequence in 86 patients reveals 13 different expansion types and further evidence for unequal recombination as the mutational mechanism." *Hum Genet* 116(4): 267-271.
- Saenz, A., F. Leturcq, et al. (2005). "LGMD2A: genotype-phenotype correlations based on a large mutational survey on the calpain 3 gene." *Brain* 128(Pt 4): 732-742.
- Schessl, J., N. M. Goemans, et al. (2008). "Predominant fiber atrophy and fiber type disproportion in early ullrich disease." *Muscle Nerve* 38(3): 1184-1191.

- Sorrel-Dejerine, Y. and M. Fardeau (1982). "[Birth and metamorphosis of Landouzy-Dejerine progressive atrophic myopathy]." *Rev Neurol (Paris)* 138(12): 1041-1051.
- Speer, M. C., R. Tandan, et al. (1996). "Evidence for locus heterogeneity in the Bethlem myopathy and linkage to 2q37." *Hum Mol Genet* 5(7): 1043-1046.
- Speer, M. C., J. M. Vance, et al. (1999). "Identification of a new autosomal dominant limb-girdle muscular dystrophy locus on chromosome 7." *Am J Hum Genet* 64(2): 556-562.
- Starling, A., F. Kok, et al. (2004). "A new form of autosomal dominant limb-girdle muscular dystrophy (LGMD1G) with progressive fingers and toes flexion limitation maps to chromosome 4p21." *Eur J Hum Genet* 12(12): 1033-1040.
- Statland, J. M. and R. Tawil (2011). "Facioscapulohumeral muscular dystrophy: molecular pathological advances and future directions." *Curr Opin Neurol*.
- Susman, R. D., S. Quijano-Roy, et al. (2010). "Expanding the clinical, pathological and MRI phenotype of DNM2-related centronuclear myopathy." *Neuromuscul Disord* 20(4): 229-237.
- Suzuki, N., M. Aoki, et al. (2004). "Novel dysferlin mutations and characteristic muscle atrophy in late-onset Miyoshi myopathy." *Muscle Nerve* 29(5): 721-723.
- Sveen, M. L., M. Schwartz, et al. (2006). "High prevalence and phenotype-genotype correlations of limb girdle muscular dystrophy type 2I in Denmark." *Ann Neurol* 59(5): 808-815.
- Taniguchi, K., K. Kobayashi, et al. (2003). "Worldwide distribution and broader clinical spectrum of muscle-eye-brain disease." *Hum Mol Genet* 12(5): 527-534.
- Tetreault, M., A. Duquette, et al. (2006). "A new form of congenital muscular dystrophy with joint hyperlaxity maps to 3p23-21." *Brain* 129(Pt 8): 2077-2084.
- Toda, T. and K. Kobayashi (1999). "Fukuyama-type congenital muscular dystrophy: the first human disease to be caused by an ancient retrotransposal integration." *J Mol Med* 77(12): 816-823.
- Toda, T., M. Segawa, et al. (1993). "Localization of a gene for Fukuyama type congenital muscular dystrophy to chromosome 9q31-33." *Nat Genet* 5(3): 283-286.
- Tome, F. M. (1999). "The Peter Emil Becker Award lecture 1998. The saga of congenital muscular dystrophy." *Neuropediatrics* 30(2): 55-65.
- Tome, F. M., T. Evangelista, et al. (1994). "Congenital muscular dystrophy with merosin deficiency." *C R Acad Sci III* 317(4): 351-357.
- Turner, C. and D. Hilton-Jones (2010). "The myotonic dystrophies: diagnosis and management." *J Neurol Neurosurg Psychiatry* 81(4): 358-367.
- Udd, B., J. Partanen, et al. (1993). "Tibial muscular dystrophy. Late adult-onset distal myopathy in 66 Finnish patients." *Arch Neurol* 50(6): 604-608.
- Udd, B., A. Vihola, et al. (2005). "Titinopathies and extension of the M-line mutation phenotype beyond distal myopathy and LGMD2J." *Neurology* 64(4): 636-642.
- Vainzof, M., L. V. Anderson, et al. (2001). "Dysferlin protein analysis in limb-girdle muscular dystrophies." *J Mol Neurosci* 17(1): 71-80.
- Vainzof, M., M. R. Passos-Bueno, et al. (1996). "The sarcoglycan complex in the six autosomal recessive limb-girdle muscular dystrophies." *Hum Mol Genet* 5(12): 1963-1969.
- Vainzof, M., M. R. Passos-Bueno, et al. (1999). "Sarcoglycanopathies are responsible for 68% of severe autosomal recessive limb-girdle muscular dystrophy in the Brazilian population." *J Neurol Sci* 164(1): 44-49.

- van der Kooi, A. J., M. van Meegen, et al. (1997). "Genetic localization of a newly recognized autosomal dominant limb-girdle muscular dystrophy with cardiac involvement (LGMD1B) to chromosome 1q11-21." *Am J Hum Genet* 60(4): 891-895.
- van Reeuwijk, J., M. Janssen, et al. (2005). "POMT2 mutations cause alpha-dystroglycan hypoglycosylation and Walker-Warburg syndrome." *J Med Genet* 42(12): 907-912.
- Vogel, H. and J. Zamecnik (2005). "Diagnostic immunohistology of muscle diseases." *J Neuropathol Exp Neurol* 64(3): 181-193.
- Voit, T. (2001). Congenital Muscular Dystrophies. *Disorders of voluntary muscle*. H.-J. D. Karpate G, Griggs RC. Cambridge, UK, Press Syndicate of the University of Cambridge: 503-524.
- Voit, T., P. Stuetgen, et al. (1991). "Dystrophin as a diagnostic marker in Duchenne and Becker muscular dystrophy. Correlation of immunofluorescence and western blot." *Neuropediatrics* 22(3): 152-162.
- Waddell, L. B., F. A. Lemckert, et al. (2011). "Dysferlin, annexin A1, and mitsugumin 53 are upregulated in muscular dystrophy and localize to longitudinal tubules of the T-system with stretch." *J Neuropathol Exp Neurol* 70(4): 302-313.
- Walter, M. C., J. A. Petersen, et al. (2004). "FKRP (826C>A) frequently causes limb-girdle muscular dystrophy in German patients." *J Med Genet* 41(4): e50.
- Weiler, T., C. R. Greenberg, et al. (1998). "A gene for autosomal recessive limb-girdle muscular dystrophy in Manitoba Hutterites maps to chromosome region 9q31-q33: evidence for another limb-girdle muscular dystrophy locus." *Am J Hum Genet* 63(1): 140-147.
- Wijmenga, C., R. R. Frants, et al. (1990). "Location of facioscapulohumeral muscular dystrophy gene on chromosome 4." *Lancet* 336(8716): 651-653.
- Yoshida, A., K. Kobayashi, et al. (2001). "Muscular dystrophy and neuronal migration disorder caused by mutations in a glycosyltransferase, POMGnT1." *Dev Cell* 1(5): 717-724.
- Zatz, M., F. de Paula, et al. (2003). "The 10 autosomal recessive limb-girdle muscular dystrophies." *Neuromuscul Disord* 13(7-8): 532-544.
- Zhang, Q., C. Bethmann, et al. (2007). "Nesprin-1 and -2 are involved in the pathogenesis of Emery Dreifuss muscular dystrophy and are critical for nuclear envelope integrity." *Hum Mol Genet* 16(23): 2816-2833.



Muscular Dystrophy

Edited by Dr. Madhuri Hegde

ISBN 978-953-51-0603-6

Hard cover, 544 pages

Publisher InTech

Published online 09, May, 2012

Published in print edition May, 2012

With more than 30 different types and subtypes known and many more yet to be classified and characterized, muscular dystrophy is a highly heterogeneous group of inherited neuromuscular disorders. This book provides a comprehensive overview of the various types of muscular dystrophies, genes associated with each subtype, disease diagnosis, management as well as available treatment options. Though each different type and subtype of muscular dystrophy is associated with a different causative gene, the majority of them have overlapping clinical presentations, making molecular diagnosis inevitable for both disease diagnosis as well as patient management. This book discusses the currently available diagnostic approaches that have revolutionized clinical research. Pathophysiology of the different muscular dystrophies, multifaceted functions of the involved genes as well as efforts towards diagnosis and effective patient management, are also discussed. Adding value to the book are the included reports on ongoing studies that show a promise for future therapeutic strategies.

How to reference

In order to correctly reference this scholarly work, feel free to copy and paste the following:

Leigh B. Waddell, Frances J. Evesson, Kathryn N. North, Sandra T. Cooper and Nigel F. Clarke (2012). Diagnosis of the Muscular Dystrophies, Muscular Dystrophy, Dr. Madhuri Hegde (Ed.), ISBN: 978-953-51-0603-6, InTech, Available from: <http://www.intechopen.com/books/muscular-dystrophy/molecular-diagnosis-of-the-muscular-dystrophies>

INTECH
open science | open minds

InTech Europe

University Campus STeP Ri
Slavka Krautzeka 83/A
51000 Rijeka, Croatia
Phone: +385 (51) 770 447
Fax: +385 (51) 686 166
www.intechopen.com

InTech China

Unit 405, Office Block, Hotel Equatorial Shanghai
No.65, Yan An Road (West), Shanghai, 200040, China
中国上海市延安西路65号上海国际贵都大饭店办公楼405单元
Phone: +86-21-62489820
Fax: +86-21-62489821

© 2012 The Author(s). Licensee IntechOpen. This is an open access article distributed under the terms of the [Creative Commons Attribution 3.0 License](#), which permits unrestricted use, distribution, and reproduction in any medium, provided the original work is properly cited.

IntechOpen

IntechOpen