

We are IntechOpen, the world's leading publisher of Open Access books Built by scientists, for scientists

6,900

Open access books available

185,000

International authors and editors

200M

Downloads

Our authors are among the

154

Countries delivered to

TOP 1%

most cited scientists

12.2%

Contributors from top 500 universities



WEB OF SCIENCE™

Selection of our books indexed in the Book Citation Index
in Web of Science™ Core Collection (BKCI)

Interested in publishing with us?
Contact book.department@intechopen.com

Numbers displayed above are based on latest data collected.
For more information visit www.intechopen.com



Current Trends of fMRI in Vision Science: A Review

Nasser H. Kashou

*Department of Radiology, Children's Radiological Institute,
Nationwide Children's Hospital*

*Department of Radiology, Department of Ophthalmology,
The Ohio State University Medical Center*

*Department of Biomedical, Industrial and Human Factors Engineering,
Wright State University
USA*

1. Introduction

Studying brain functional activities is an area that is experiencing rapid interest in the field of neuroimaging. Functional magnetic resonance imaging (fMRI) has provided vision science researchers a powerful and noninvasive tool to understand eye function and correlate it with brain activities. In this chapter, we focus on the physiological aspects followed by a literature review. More specifically, to motivate and appreciate the complexity of the visual system, we will begin with a description of specific stages the visual pathway, beginning from the distal stimulus and ending in the visual cortex. More importantly, the development of ascending visual pathway will be discussed in order to help in understanding various disorders associated with it such as monochromacy, albinism, amblyopia (refractive, strabismic). In doing so we will divide the first half into two main sections, the visual pathway and the development of the ascending pathway. The first of these sections will be mostly an anatomy review and the latter will discuss the development of this anatomy with specific examples of disorders as a result of abnormal development. We will then discuss fMRI studies with focus on vision science applications. The remaining sections of this chapter will be highlighting the work done on mainly oculomotor function, some perception and visual dysfunction with fMRI and investigate the differences and similarities in their findings. We will then conclude with a discussion on how this relates to neurologists, neuroscientists, ophthalmologists and other specialists.

2. Background

To motivate the discussion we begin by asking, what is the problem in visual perception? This will be answered briefly. In visual perception, we have both a distal and a proximal stimulus. The distal stimulus is what the subject is looking at, usually at a distance. In the case of vision, it determines the pattern of light arriving at the cornea. The proximal stimulus hits the sense organs directly. In the case of vision, it is the pattern of light arriving at the retina, for instance as a result of looking at the distal stimulus. There are several features that distinguish

the distal and proximal stimuli. The distal stimulus is 3-dimensional, independent of point of view, upright, and has no lens blur or filter. An example of the latter two is that when we look at a person their head is on top and their feet are on the bottom and the physical person does not get blurred. The proximal on the other hand is 2-dimensional, depends on point of view, inverted, blurred and filtered by the lens. So the main problem in visual perception becomes clearer; that is to retrieve information about the distal stimulus with only the proximal stimulus to work with. This is important because it affects the perceptual representation which is the endpoint of the perceptual process. Perceptual representation is the state of the visually-guided motor behavior (keeps us from bumping into things), visual pattern recognition, visual understanding, and memory. Basically, as the subject sees an object (distal stimulus), the input falls on the retina (proximal stimulus) and an output of the distal stimulus is perceived via perceptual representations. Note, that this is not the same as the distal stimulus, because there are two kinds of perception, veridical and illusory. There are many examples of visual illusions, in which the perceptual representation suggests an incorrect distal stimulus. That is, the apparent distal stimulus differs from the veridical distal stimulus. With this concept, we can now refine the problem in visual perception, as trying to understand how the visual system creates a perceptual representation of the distal stimulus with only the proximal stimulus as an input. Why is this a problem? Because the relationship of distal to proximal is not one to one, that is a distal stimulus can be seen as many proximal stimuli and proximal stimuli can be many distal stimuli. This leads to the inverse problem of trying to recover a visual representation from the input, even when many representations are consistent with the proximal stimulus. Thus, this is a motivation to begin discussing the visual pathway and understand the retinal (proximal) input to the brain.

3. Visual pathway

The visual pathway consists of many stages. We will focus on the ganglion cells, lateral geniculate nucleus (LGN), and the primary visual cortex (V1). The ascending visual pathway begins when light hits the back of the retina and stimulates the photoreceptors (rods and cones). These photoreceptors transform radiant energy into electrical activity, which is transmitted to retinal bipolar cells and then into retinal ganglion cells. The retina has several layers and sub-layers with corresponding cells, such as ganglion, amacrine, bipolar and horizontal. Each of these cells play a role in the visual system and have their own receptive fields. Again, in this chapter we choose to focus and discuss the ganglion cells.

3.1 Ganglion cells

There are two major classes of ganglion cells. The smaller midget, or parvo, cells comprise about 80 percent of these cells and the larger parasol, or magno, cells about 10 percent (Lennie et al., 1990). As with other cells in the retina, these ganglion cells have their own receptive fields known as center surround with either on-center (off-surround) or off-center (on-surround). There are several differences between these two types of cells. Parvo cells are dominant in the fovea as opposed to the magno cells, which are dominant in the periphery. The parvo cells are also characterized as having a sustained response while the magno have a transient response (Purpura et al., 1990; Schiller & Malpeli, 1978). At any given eccentricity, parvo cells have a higher spatial resolution, lower contrast sensitivity, slower conduction velocity, and a more sustained response than do magno cells (Shapley et al., 1981). The parvo cells have low contrast sensitivity and detect color and form, while the magno have high

contrast sensitivity and detect motion. Parvo cells rarely respond well to luminance contrasts below 10%, whereas magno cells often respond to stimuli with contrasts as low as 2% (Purpura et al., 1988; Sclar et al., 1990; Shapley et al., 1981). In addition to these two, there are other types of ganglion axons that exist; the more common of these are the konio cells which are small bistratified cells (Kaas et al., 1978). They are common in the parafovea, have low contrast sensitivity, and detect color. The major difference between the konio cells and the other two is that the konio have a uniform receptive field and thus have no spatial opponency. To many investigators the term konio has become synonymous with the blue-yellow pathway, just as parvo is now equated, too simplistically, with the red-green pathway (Sincich & Horton, 2005). But this is not always the case because, konio cells constitute a heterogeneous population of cells, some lacking blue-yellow color opponency (Hendry & Reid, 2000). The axons of all these ganglion cells exit the eye, forming the optic nerve and synapse in the midbrain. Since the diameter of the optic nerve and the number of the ganglion cell axons it contains are limited by the structure of the skull, not all the information that falls upon the retina is transmitted to the brain proper (Schwartz, 2004). Although there are more than 100 million photoreceptors within the retina, there are only 1 million ganglion cells, revealing an extensive degree of neural convergence (Curcio & Allen, 1990; Osterberg, 1935). At the optic chiasm, ganglion cell fibers from the nasal retina of each eye cross over to join the temporal fibers of the fellow eye to form the optic tract (Schwartz, 2004). The long axons of the retinal ganglion cells leave the eye, form the second cranial nerve (the optic nerve), and synapse in the dorsal lateral geniculate nucleus (dLGN), a midbrain structure (Schwartz, 2004). We will now discuss the LGN.

3.2 Lateral geniculate nucleus (LGN)

The primary target of the optic tract is the dorsal lateral geniculate nucleus (dLGN), a thalamic nucleus. In higher vertebrates, such as carnivores and primates, axons from the two eyes converge onto their primary target, the dorsal lateral geniculate nucleus (dLGN), but occupy distinct regions (the eye-specific layers) within this target (Guillery, 1970; Kaas et al., 1972; Linden et al., 1981). In primates (Rakic, 1976; 1977), the axonal terminals of ganglion cells of the two eyes initially share common territories within the dLGN, but through a process that eliminates inappropriately placed branches, projections from the two eyes become restricted to their appropriate layer. Most, but not all, retinal ganglion cells synapse in the six-layered structure. Layers 2, 3, and 5 receive input from the ipsilateral eye, whereas layers 1, 4, and 6 receive input from the contralateral eye, Fig. 1. The dorsal four layers, which are constituted of comparatively small neurons called parvo, or P-cells, are the parvocellular layers (layers 3,4,5,6). Larger neurons, commonly called magno or M-cells, comprise the two ventral magnocellular layers (layers 1,2). Axons from midget ganglion cells synapse on P-cells in the dLGN to form the parvo pathway, while axons from the parasol cells synapse on dLGN M-cells to form the magno pathway. The layers between the parvocellular and magnocellular layers contain very small neurons (konio cells). Studies have shown that konio cells provide the only direct geniculate input to layers 1-3 (Hendry & Yoshioka, 1994). The subcortical projection from the retina to cerebral cortex is strongly dominated by the two pathways (M and P pathways) the magnocellular and parvocellular subdivisions of the lateral geniculate nucleus (Shapley & Perry, 1986). The parvo layers receive input from color-opponent midget ganglion cells, whereas the magno layers are supplied by broadband parasol ganglion cells (Perry et al., 1984). Parvo pathway neurons show color opponency of either the red/green or blue/yellow type, which means that they respond to color change regardless of the relative luminance of the colors (Derrington & Lennie, 1984). The blue-yellow ganglion cells project to

the konio layers just ventral to the third and fourth parvocellular layers (Calkins & Hendry, 1996). Layers 5 and 6 have on-center receptive fields, and layers 3 and 4 have off-center receptive fields. Layers 1 and 2 have both on- and off-center receptive fields. These projections from the retina to the LGN then lead to the visual cortex.

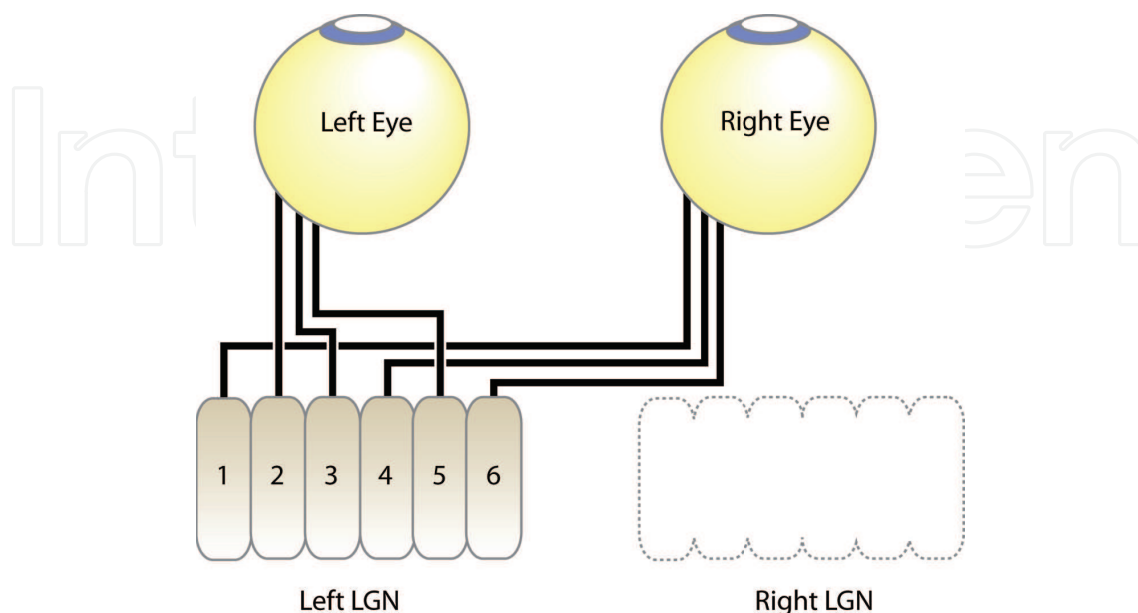


Fig. 1. Retinal ganglion cell projections to the lateral geniculate nucleus (LGN) of the thalamus. Note that layers 1, 4, and 6 of the LGN receive visual information from the contralateral retina, whereas layers 2, 3, and 5 receive visual information from the ipsilateral retina.

3.3 Primary visual cortex (V1)

The cells of dLGN send most of their axons to the cerebral cortex, specifically, the primary visual cortex (V1) along with the visual field representation in the retina and primary cortex. Inputs to V1, which are stratified by magno, parvo, and konio, become thoroughly intermingled by passage through the elaborate circuitry of V1 (Sincich & Horton, 2005). There are about 8 or 9 layers in V1. Layer 4 consists of three sublayers, 4A, 4B, and 4C. Layer 4C also is subdivided into $4C\alpha$, and $4C\beta$. The projections from the LGN go specifically to layer 4C and the information flows up and down from there (Merigan & Maunsell, 1993). The projections from parvocellular layers terminate primarily in layers 4A and $4C\beta$, whereas those from magnocellular geniculate terminate in layer $4C\alpha$ (Fitzpatrick et al., 1985). Layer 4B receives direct input from $4C\alpha$ (M pathway), but not $4C\beta$ (P pathway) (Lund & Boothe, 1975; Lund et al., 1979). Layer $4C\beta$ projects to the blobs and interblobs (Horton & Hubel, 1981; Humphrey & Hendrickson, 1980). The blobs also receive major inputs from the M pathway by way of layers 4B and $4C\alpha$ (Blasdel et al., 1985; Fitzpatrick et al., 1985; Lachica et al., 1992; Lund, 1988). Fig. 2 gives the details of these connections.

More recently, Yazar et al. (2004) have found that some geniculate fibers terminate in both layers $4C\beta$ and 4A, implying either a direct parvo input to 4A or a konio input to $4C\beta$. In layer 3B the cells in blobs and interblobs receive input from parvo ($4C\beta$), magno ($4C\alpha$), konio (4A), or mixed (4B) layers, in a range of relative synaptic strengths (Sawatari & Callaway, 2000). Cells in both $4C\alpha$ and $4C\beta$ project to layers 5 and 6 (Callaway & Wiser, 1996; Lund & Boothe, 1975). Feedback from layer 6 to the LGN is segregated only partially with respect to magno

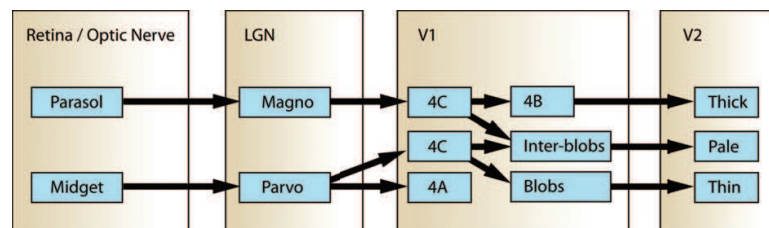


Fig. 2. Block diagram of ganglion cell mapping from retina through LGN, V1, and other cortical areas.

and parvo, thus mixing the geniculate channels (Fitzpatrick et al., 1994). There are two main types of cells in V1, stellate and pyramidal. The stellate cells are small interneurons found in layers 2-6 and the pyramidal cells are large relay neurons found in layers 2, 3, 5, and 6. The stellate cells are simple cells because of their receptive fields. The pyramidal cells are complex cells. The simple cells' receptive fields are of a certain size, are oriented in a certain way, and are sensitive to phase. They increase their rate of firing when stimulated in some places, and reduce it when stimulated in other places. The simple cells respond to a single spot of light and are additive and linear. The complex cells do not respond to a single spot of light, rather they respond to edges and bars, and are not sensitive to spatial phase. Many of the complex cells respond best to stimuli that move in one direction. So, if the stimulus is stationary, in the opposite direction, or a spot of light then the complex cells' receptive field will have no response. The complex cells are non-additive and are non-linear. Both the simple and complex cells respond to most proximal stimuli. All together, these cortical cells are tuned for spatial frequency, position, and orientation. This distinction is important in designing visual stimuli for fMRI studies to understand normal and abnormal visual function.

4. Development of the ascending pathway

We now describe how the visual pathway develops and the effects of abnormal development. During development anatomical projection patterns are restructured and functional reorganization takes place (Campbell & Shatz, 1992; Hubel & Wiesel, 1977; Shatz & Kirkwood, 1984; Wiesel, 1982). There are at least two ways by which neurons can be wired up accurately: connections may be specified from the outset, or synapse formation may initially follow an approximate wiring diagram, with precision achieved by the elimination of inappropriate inputs and the stabilization and growth of appropriate connections (Goodman & Shatz, 1993; Purves & Lichtman, 1985). The ganglion cells, LGN, and V1 are all wired up in a "retinotopic" fashion; meaning that the order of points on the retina (proximal stimulus) are preserved. In this mapping, the points that are further away from each other on the retina will be further away on the brain. It is easy to see that the proximal image is retinotopically related to the distal stimulus, simply because of the optics of the eye. However the retinotopic mapping from the retina to the LGN and from the LGN to V1 is harder to appreciate. Studies of patients with localized cortical damage showed that the receptive fields of neurons within area V1 are retinotopically organized (Holmes, 1918; 1944; Horton & Hoyt, 1991). As a matter of fact, the development of the retinotopic map is a general process for the central nervous system. Cell bodies are born early in embryogenesis; axons and dendrites come later. The nerve growth is then guided mechanically, probably by glial cells, to their overall destination. The patterns of activity of the neurons themselves determine the exact position of the synapses that are formed. Ganglion cells travel up the concentration gradient to the LGN. Target cells send guiding chemical messages, giving crude directions to the cells' overall destination by

their concentration gradient. These chemical signposts act like beacons that attract the cells to project to approximately the correct part of the target tissue. At the same time the chemical signposts repel growth cones from the wrong axons. These guidance molecules also govern the decussation at the optic chiasm by signaling the retinal ganglion cells to either cross or not to cross. The activity of adjacent retinal ganglion cells is correlated (Galli & Maffei, 1988), and "waves" of activity sweep across the retina during early life (Meister et al., 1991). Although the waves could potentially underlie the refinement of many retinal projection patterns, activity may not be required for establishing the M and P pathways of the primate retina that develop prenatally, and which show no apparent gross structural refinement with ensuing development (Meissirel et al., 1997). The immature and light-insensitive retina spontaneously generates a pattern of rhythmic bursting activity during the period when the connectivity patterns of retinal ganglion cells are shaped (Wong, 1999.). After the cells find a region, the wave then enforces precise ordering at the target. Thus the retinotopic map is finalized via the wave. Prenatal refinement of the retinotopic projections is achieved by these spontaneous waves of activation that propagate across the retina. Here ganglion cells are linked together by means of electrical synapses in a rough network and charge fluctuates randomly. The random response of one cell starts a wave of activity and the cells that fire together will eventually wire together. These spontaneous waves cause neighboring retinal regions to fire at about the same time. In fact, the correlation between the responses of cells is directly related to their separation on the retina (Wong, 1999.). So, the first principle of refinement is that cells that are neighbors tend to respond together. The second principle of refinement is that cells that fire together wire together. If there are two cells, 1 and 2, that are close to each other on the retina then when they fire together they will form neighboring synapses at the LGN. But cell 3, which is far from the first two on the retina will fire separately and thus synapse at the LGN separately. This is how the LGN is retinotopically wired up at birth along with V1 and other retinotopic cortical areas. Hence, the waves in the prenatal retina setup the relation between retina and brain. As for the postnatal retina, responses to stimuli set up the relation between the proximal stimulus and the brain. The postnatal wave may help guide the formation of synapses and determine which erroneous synapses are cut out for the normal mapping. When they arrive at their destinations, each process synapses over a relatively large area. Since target cells have lots of cells synapsing onto them, there are a lot more synapses present in V1 at 6 months and 1 year than in an adult. The process of the synapse starts as each axon from different cell bodies tries to take over a large piece of visual cortex and inevitably overlap occurs. At these regions of overlap a competition occurs, and the cell with the most or strongest synapse claims that region and the other synapses pull back. This synaptic elimination is a key element in the refinement of connectivity in both the central and peripheral nervous systems (Cowan et al., 1984; Goodman & Shatz, 1993; Lichtman et al., 1999; Nguyen & Lichtman, 1996; Purves & Lichtman, 1985). This produces a retinotopic map that has less overlap than before, and has many fewer synapses. If there is a vacant area then other nearby cells synapse onto it without meeting any competition and in turn increase their synaptic field. This process of being able to change as a result of experience is called plasticity, and is required for normal development. It determines how the visual system is wired up during normal development. The synaptic development occurs at different time scales across the brain. For V1 the development ends from about 8 to 16 years and culling happens at about 1-2 years. If there is any difficulty or blur in one eye or an eye turn while these synapses are being formed and refined, the subject will develop a visual disorder. This leads us into the next section.

4.1 Disorders of the ascending pathway

We will now discuss several visual disorders associated with the ascending pathway before reviewing fMRI research in vision science. The disorders are: rod monochromacy, albinism, refractive amblyopia, and strabismic amblyopia.

4.1.1 Rod monochromat

Rod monochromat, also known as complete achromatopsia, is an autosomal recessive disease. The rod vision is normal but cone vision is completely absent, meaning there is no fovea. In a normal subject, the fovea is what projects to V1, so what happens to the foveal representation in this case? In a rod monochromat, the visual acuity is about 20/200 and the spectral sensitivity is that of rhodopsin, meaning there are big losses in the red compared to normal. As a result of not having cones, there is no color vision and the patient has photophobia and severe visual impairment due to glare. The fovea is grossly abnormal with no reflex and may have a few cones which may contain rhodopsin. As a result of this abnormality, pendular nystagmus forms. With respect to the ascending pathway, the vacant space of the part of V1 that normally receives signals from the fovea is occupied during the synaptic development stage by synapses originating in the parafoveal retina of the achromat.

4.1.2 Albinism

Albinism is characterized by a systematic misrouting of the connections between the retina and the visual cortex. The ascending projection in an albino is almost entirely crossed. Note the normal projection that is crossed is about 55%. This miswiring can produce nystagmus and strabismus. The clinical features of albinism include hypopigmentation of the fundus, and iris. There are variable degrees of pigmentation of the iris, hair, skin. Tyrosinase negative albino (oculocutaneous) individuals may be completely white with a visual acuity range from 20/60 - 20/400, but is usually worse than 20/200. Tyrosinase positive albino may look hypopigmented or even essentially normal with visual acuity range from 20/60 - 20/400, but is usually better than 20/200. More clinical features related to the eye include a very light fundus because there is no melanin in the retinal pigment epithelium (RPE). There is little differentiation of the fovea from the surrounding retina. Albinos also have high myopia or high hyperopia. In the albino system there is more than 90% decussation at the optic chiasm. This means that the guidance molecules during development failed to stop the neurons from going the opposite direction. For a better understanding of the ascending pathway abnormalities in albinos we will do a comparison with normals. If a distal stimulus is presented on the right hand side of a normal subject then the expected pathway from the right eye nasal retina would cross the optic chiasm and end up in the contralateral visual cortex (left visual cortex). For the same stimulus on an albino subject, the resulting signal would be the same as the normal. If the distal stimulus is changed to the left hand side for the normal, and looking at the right eye temporal retina, then the signal would not cross the optic chiasm and would end up in ipsilateral visual cortex (right visual cortex). The same repeated for the albino reveals the opposite since the majority of the neurons cross the optic chiasm and end up in the contralateral visual cortex again. The primary lesion in albinism is a genetically determined lack of melanin or melanosomes as mentioned earlier. As a side point, melanin is very important for many aspects of neurological development. For instance, the neural crests pigment and its location on the embryo is determined by melanin. Melanin is also involved in production of dopamine and serotonin and many other neurotransmitters related to neuroendocrine function.

4.1.3 Refractive amblyopia

Refractive/deprivation amblyopia is a result of the receptive fields not being used early in life. Thus, the culling at about 1 year postnatal removes their synaptic connections because lack of function. Specifically, the proximal stimulus is blurred during the critical period, meaning the high spatial frequencies are reduced or eliminated from the visual image, causing high spatial frequency tuned channels to either never develop, or be lost. In this case, the low spatial frequencies pass unattenuated, so the low spatial frequency tuned channels develop normally. The effect of this blur in refractive amblyopia is the direct loss of contrast sensitivity at high spatial frequencies, which is equivalent to a loss of visual resolution acuity. As for the remaining spatial frequency channels, they stay relatively normal because they are stimulated normally during the critical period. This illustrates the principle that the receptive fields must be used if they are to be maintained. If the proximal stimuli do not stimulate the receptive fields effectively, the cells tend to stop responding to the intended stimulus even if it is presented occasionally. The cell may begin to respond to other stimuli, and therefore develop a new receptive field. The input from the other eye is likely to grab the synapse area because of competition. As a result there is anisometropia, an unequal refractive error in the two eyes. Thus, the eye with the larger refractive error continues to experience chronic blur. Dominance of the good eye becomes exaggerated during development, because of competition between incoming signals. Most cells in the primary visual cortex come to have predominant input from the good eye. If one eye is handicapped during the competition, it tends to lose its synaptic connections. Thus, the development of ocular dominance columns in amblyopia is distorted, and depends on the age at which deprivation begins. The most dangerous periods of refractive amblyopia are in the first 6 months.

4.1.4 Strabismic amblyopia

The cells in the ascending pathway are labeled lines. Labels relate to position on the retina and therefore position in the proximal stimulus. Labels also relate to spatial frequency and orientation. Labeled lines are important because the brain only knows what the ascending pathway tells it. If the labels are abnormal, vision is also abnormal. In strabismic amblyopia, the lines are mislabeled, which leads to distorted vision. In normal retinotopic organization, labels relate position in the distal stimulus to position upon the retina. Strabismic amblyopia is thought to be due to disordered (scrambled) retinotopic mapping between the LGN and V1 of the signals from one eye; therefore, leading to abnormal visual experience. The waves that happen after birth are not normal because the eye is not always pointing in the right direction. Recall that cells fire together after birth because of the wave of activity produced by the usual retinal stimulus. This postnatal wave may help guide the formation of synapses and determines which erroneous synapses are cut out for the normal mapping. This eye turn in early childhood produces an abnormal wave. The connection between the retina and the LGN remains normal because it is wired up prenatally, but the connection between the LGN and V1 is not. When cortical cells fire together abnormally they wire together abnormally. Clinical consequences of this disorder at the primary visual cortex are impaired visual recognition, crowding (nearby stimulus information obscures attended item), poor vernier acuity, poor stereo acuity, poor grating orientation identification acuity, and often near normal grating resolution acuity. The high spatial frequency gratings do not look like uniform gray, so they can be detected, but they are badly distorted, so the amblyope cannot discriminate between vertical and horizontal.

5. fMRI vision science studies

With a basic understanding of the visual pathway and its development we can now review fMRI literature. As a result of the increase in general fMRI studies, there has also been an increase of studies investigating many aspects of the vision science. These studies include normal eye movements such as optokinetic nystagmus (OKN) (Bense et al., 2006a;b; Bucher et al., 1997; Dieterich et al., 1998; 2000; 2003; Kashou et al., 2006; Kashou, 2008; Kashou et al., 2010; Konen et al., 2005; Petit & Haxby, 1999; Schraa-Tam et al., 2008), saccades (Berman et al., 1999; Bodis-Wollner et al., 1997; Connolly et al., 2005; Cornelissen et al., 2002; Darby et al., 1996; Ettinger et al., 2008; Haller et al., 2008; Hayakawa et al., 2002; Kimmig et al., 2001; Konen et al., 2004; Luna et al., 1998; Merriam et al., 2001; Miller et al., 2005; Mort et al., 2003; Müri et al., 1996; 1998; Petit et al., 1997; Rosano et al., 2002), smooth pursuit (Barton et al., 1996; Berman et al., 1999; Freitag et al., 1998; Ohlendorf et al., 2010; Petit et al., 1997; Petit & Haxby, 1999; Rosano et al., 2002; Tanabe et al., 2002), and gaze (Andersson et al., 2007; Deutschländer et al., 2005). There have also been studies that look at varying aspects of visual perception such as: effect of age (Lewis et al., 2003; 2004), retinotopic mapping (Conner et al., 2004; Engel & Furmanski, 1997; Hadjikhani et al., 1998; Morland et al., 2001; Murray et al., 2006; Tootell et al., 1997; Warnking et al., 2002), magnocellular (M) and parvocellular (P) pathways (Kleinschmidt et al., 1996; Liu et al., 2006), ocular dominance (Cheng et al., 2001; Goodyear & Menon, 2001; Miki et al., 2001a), binocular rivalry (Lee et al., 2005), illusory contours (Mendola et al., 1999; Seghier et al., 2000), contrast detection (Leguire et al., 2011a; Ress & Heeger, 2003), visual attention (Büchel et al., 1998; Ress et al., 2000), perceptual filling-in (Mendola et al., 2006), lateral geniculate nucleus (LGN) (Büchel et al., 1997; Chen et al., 1998a;b; Chen & Zhu, 2001; Chen et al., 1999; Engel & Furmanski, 1997; Kleinschmidt et al., 1994; Miki et al., 2000; 2001b;c; Morita et al., 2000; Mullen et al., 2010), superior colliculus (SC) (Schneider & Kastner, 2005), motion perception (Paradis et al., 2000; Pelphrey et al., 2005), and illusory perception of real motion (Sterzer et al., 2006). There have also been fMRI studies undertaken for abnormal visual functions such as: amblyopia (Algaze et al., 2002; 2005; Choi et al., 2001; Goodyear et al., 2000; Lee et al., 2001; Leguire et al., 2004a;b; 2011a; Lerner et al., 2006; Lewis et al., 2003; 2004; Muckli et al., 2006; Rogers, 2003; Yang et al., 2003), albinism (Schmitz et al., 2004), infantile nystagmus syndrome (INS) (Leguire et al., 2011b), downbeat nystagmus (DBN) (Hüfner et al., 2007; Kalla et al., 2006), opsoclonus (Helmchen et al., 2003a;b), unilateral vestibular failure (UVF) (Deutschländer et al., 2008), convergence insufficiency (CI) (Alvarez et al., 2010), optic neuritis (ON) (Gareau et al., 1999; Langkilde et al., 2002; Levin et al., 2006; Rombouts et al., 1998; Toosy et al., 2002; 2005; Werring et al., 2000), Autism (Baron-Cohen et al., 2006; Hadjikhani et al., 2004a;b), and macular degeneration (Little et al., 2008; Sunness et al., 2004). Other studies include looking at callosal agenesis and colpocephaly (Bittar et al., 2000), vascular lesions and therapeutic intervention (Schlosser et al., 1997), ischemic lesions (Nyffeler et al., 2011), migraine aura (Hadjikhani et al., 2001), idiopathic Parkinsons disease (Holroyd & Wooten, 2006), Tourette syndrome (Mazzone et al., 2010), bipolar disorder (Martin et al., 2011), and schizophrenia (Nagel et al., 2007; Tregellas et al., 2004; 2005). This is not an exhaustive but a brief list of fMRI studies related to vision science. We will now discuss some of the results of these studies in normal vision then in pathologies.

6. fMRI and oculomotor function

fMRI studies of the oculomotor function have been mostly limited to normal subjects and have concentrated on voluntary pursuit, saccadic eye movements and optokinetic nystagmus (OKN). Table 1 summarizes the details of these studies, imaging parameters and visual

stimuli. Tanabe et al. (2002) have noted that fMRI studies of oculomotor function have employed few subjects and the reliability of mapping-out brain sites involved in oculomotor control have not been established. This statement was made almost 10 years ago and a lot has been accomplished since then. Overall, there appears to be two parallel cortical oculomotor systems for pursuit and saccadic eye movements. Both pursuit and saccadic eye movements appear to activate the same cortical areas including the frontal eye fields (FEF, precentral cortex), supplementary eye fields (SEF, superior frontal cortex), parietal eye fields (PEF, intraparietal cortex), precuneus, and MT/V5. However, pursuit or saccadic eye movements may selectively activate subregions of these cortical areas. Petit & Haxby (1999) found that the pursuit related activation areas were usually smaller than and consistently inferior to and/or posterior to the saccadic related activation areas. Dieterich et al. (2000) have shown that small field horizontal OKN as well as voluntary saccadic eye movements activate areas of both cerebellar hemispheres including the superior semilunar lobule, simple lobule, quadrangular lobule and inferior semilunar lobule. In addition, activation was found in the middle cerebellar peduncle, dentate nucleus, culmen (medially), and uvula of the cerebellar nuclei. Fixation during OKN suppressed activation in the uvula and culmen. Dieterich et al. (1998) also found OKN to activate subcortical areas including the caudate nucleus, putamen, globus pallidus and paramedian thalamus. Fixation increased activity in the FEF and anterior cingulate gyrus. (Dieterich et al., 2000) used a rotating drum that contained "colored figures" to stimulate OKN amplitude that ranged from 2 – 13° visual angle, suggesting a mixture of voluntary and involuntary OKN or only voluntary OKN. Most recently it has been shown that voluntary OKN generates more cortical activation than does involuntary OKN (Kashou et al., 2006; 2010; Konen et al., 2005). Specifically, Kashou et al. (2010) showed that activation sites for OKN studies are dependent on subject instruction which influence the type of OKN generated. Bense et al. (2006a) found that there was no direction dependent activation in cortical eye fields, but there was asymmetry in the paramedian visual cortex areas. Also they found stronger activation in the hemisphere contralateral to slow OKN phase (pursuit). Bense et al. (2006b) found cerebellar activation was localized in the oculomotor vermis. In a comparison of gratings versus dots to stimulate an optokinetic response, the gratings evoked more activation in FEF, PEF, MT/V5 and the cerebellar area VI (Schraa-Tam et al., 2008). Saccades in humans have been found to activate the precentral sulcus in FEF and in the precuneus along the intraparietal sulcus (IPS), extending in both superior and inferior parietal lobules (Luna et al., 1998). Saccades are traditionally divided into "reflexive" and "voluntary" saccade. Mort et al. (2003), demonstrated that voluntary saccades produced greater activation within FEF and the saccade related area of IPS. In an oculomotor study on oscillatory, predictable and unpredictable saccade, Konen et al. (2004) showed that predictable saccades with the shortest saccadic latency led to the most pronounced cerebral activity both in terms of cortical areas involved and signal intensity. The activation of FEF has also been found to be correlated with saccade reaction time (Connolly et al., 2005). Saccades are also distinguished as either pro or anti if they are made toward or away a stimulus respectively. Cornelissen et al. (2002) found similar BOLD activation in FEF during both pro- and antisaccades. It was suggested in a study looking at functional interactions between pro- and antisaccades that the presupplementary motor area (pre-SMA) coordinates with the FEF to maintain a controlled, preparatory set for task appropriate oculomotor execution (Miller et al., 2005). Saccade frequency and amplitude was varied (Kimmig et al., 2001) and high correlation between frequency and BOLD signal was found along with higher BOLD activation in antisaccades over prosaccades. Merriam et al. (2001) found that comparison of visually guided saccades with fixation revealed activation in all three cortical eye fields: SEF, FEF, and PEF. In

Reference	Type	Resolution	Slices	TR(s)	TE(ms)	Tesla	Stimuli	θ	Shot
Luna et al 1998	Saccade	3.125x3.125x5 gap=1	7	1.5	50	1.5	Circle	90°	1
Kimmig et al 2001	Saccade	2x2x4	16	4	66	1.5	Square	90°	1
Merriam et al 2001	Saccade	3.125x3.125x5 gap=1	7	1.5	50	1.5	Circle	90°	1
Hayakawa et al 2002	Saccade	2.5x2.5x5	25	10	56.05	1.5	Balloon-shaped	90°	1
Mort et al 2003	Saccade	3.75x3.75x4	24	3	50	1.5	Circle	90°	1
Konen et al 2004	Saccade	3x3x4.4	30	4	66	1.5	Square	90°	1
Cornelissen et al 2002	Pro-anti saccade	2x2x4	6	1.5	66	1.5	Spot	90°	1
Connolly et al 2005	Pro-anti saccade	3x3x6	6	0.5	28	4	Cross	30°	1
Miller et al 2005	Pro-anti saccade	3.5x3.5x5 gap=0.5	18	2	28	4	Circle	20°	2
Ettinger et al 2008	Pro-anti saccade	3.75x3.75x5 gap=0.5	–	2	40	1.5	Dot	80°	1
Haller et al 2008	Corrective saccade	3x3x4 gap=1	25	2.5	50	1.5	Dot	90°	1
Petit et al 1997	SPeM, saccade	3.75x3.75x5	26	3	40	1.5	Dot	90°	1
Petit & Haxby 1999	SPeM, saccade	3.75x3.75x5	26	3	40	1.5	Dot	90°	1
Rosano et al 20002	SPeM, saccade	0.8x1.3x3 gap=1	6	4.2	25	3	Spot	90°	2
Freitag et al 1998	SPeM	1.95x1.95x4	10/12/11	5	70	1.5	Dot (Random)	90°	1
Tanabe et al 2002	SPeM	3.75x3.75x6 gap=1	20	2.5	50	1.5	Dot	90°	1
Ohlendorf et al 2010	SPeM	3x3x3	36	2.5	30	3	Dot	90°	1
Konen et al 2005	OKN, SPeM	3x3x4.4	30	4	66	1.5	Gratings, dot	90°	1
Dieterich et al 2003	OKN	1.88x1.88x5	20	5	66	1.5	Rotating drum	90°	1
Bense et al 2006	OKN	3x3x4	40	4.2	60	1.5	Gratings	90°	1
Schraa-Tam et al 2008	OKN	–x–x5 gap=1	22	3	40	1.5	Gratings, dot	90°	1
Kashou et al 2010	OKN	3.75x3.75x5	23	1.5	35	3	Gratings	90°	1
Dieterich et al 1998	h/vOKN	1.95x1.95x5	17	5	40	1.5	Rotating drum	90°	1
Bense et al 2006a	h/vOKN	3x3x4	40	4.31	60	1.5	Gratings	90°	1
Andersson et al 1998	Fixation, gaze	3.75x3.75x5	21	3	60	1.5	Checkerboard	90°	1
Deuschlaender et al 2008	Fixation, gaze	3.75x3.75x3.75	32	4.5	60	1.5	LED	90°	1

Table 1. Specifications of fMRI studies performed on normal eye movements.

addition, the cerebellar vermis (declive and folium) and the bilateral cerebellar hemispheres (superior semilunar lobule) were associated with visually guided saccades (Hayakawa et al., 2002). In differentiating saccade inhibition from generation, the right supramarginal gyrus was responsible for inhibition and the right lateral FEF and bilateral intraparietal sulcus were responsible for antisaccade generation (Ettinger et al., 2008). Unlike pro- and anti-, corrective saccades may also occur, specifically during saccades, pursuit and fixation. This eye movement activated the anterior inferior cingulate, bilateral middle and inferior frontal gyri, bilateral insula and cerebellar areas (Haller et al., 2008).

FEF activation during smooth pursuit performance was found to be smaller than during saccades (Petit et al., 1997). The performance of pursuit eye movements induced activations in the cortical eye fields also activated during the execution of visually guided saccadic eye movements, namely in the precentral cortex [FEF], the medial superior frontal cortex [SEF], the intraparietal cortex [PEF], and the precuneus, and at the junction of occipital and temporal cortex (MT/MST) cortex (Petit & Haxby, 1999). Rosano et al. (2002) localized the saccade-related area to the upper portion of the anterior wall of the precentral sulcus and the pursuit-related area to a deeper region along the anterior wall, extending in some subjects to the fundus or deep posterior wall. It was suggested that the lateral occipitotemporal cortex has extraretinal signals during pursuit (Barton et al., 1996). Significant activation in V1 and V2 in both hemispheres as well as additional bilateral activation in the lateral extent of Brodmann’s area 19 and 37 (BA 19/37) was evident during smooth pursuit (Freitag et al., 1998). Pursuit performance, relative to visual fixation, elicited activation in three areas known to contribute to eye movements in humans and in nonhuman primates: the frontal eye field, supplementary eye field, and intraparietal sulcus. It also activated three medial regions

not previously identified in human neuroimaging studies of pursuit: the precuneus and the anterior and posterior cingulate cortices. All six areas were also activated during saccades (Berman et al., 1999). Tanabe et al. (2002) found activation consistently in dorsal cortical eye fields and cerebellum. Many studies are still being pursued on normal eye movements with hopes of mapping out or isolating specific anatomical areas responsible with the goal of future diagnostic and therapeutic interventions.

Before moving on to visual dysfunction we want to briefly mention a few visual perception studies. Goodyear & Menon (2001) were the first to demonstrate reproducible high resolution (0.55 mm x 0.55 mm) capabilities of fMRI in humans when using short duration (<6 sec) visual stimuli. Mullen et al. (2010) studied how the responses of the visual pathway to temporal frequency are modified as signals are transferred between the LGN and V1 to the dorsal and ventral streams (V2, V3, VP, V3A, VA, and MT). They concluded that the dorsal and ventral pathways develop characteristic differences in temporal processing that affect chromatic and achromatic stimuli. Differentiation between the magnocellular and parvocellular visual pathways has been recently demonstrated (Liu et al., 2006). Conner et al. (2004) compared retinotopic maps of children with adults in hopes that the study would be useful reference for studies of children with visual disorder, such as amblyopia. Retinotopic mapping is of importance in understanding visual field; a step by step study on this process has been summarized (Warnking et al., 2002). Studying the effects of age showed that the volume and degree of fMRI activation decreased with increasing age, particularly over the age of 40 years (Lewis et al., 2003; 2004).

7. fMRI and visual dysfunction

fMRI studies have been undertaken in normal subjects and in patients with amblyopia, commonly known as lazy-eye (Algaze et al., 2002; 2005; Goodyear et al., 2000; Leguire et al., 2004a,b; 2011a; Lewis et al., 2003; 2004; Rogers, 2003). Goodyear et al. (2000) showed that there were always fewer activated fMRI voxels during amblyopic stimulation than during normal eye stimulation. Algaze et al. (2002) also showed that the volume and level of occipital visual cortical activation was less from the amblyopic eye compared to the dominant eye of amblyopes or to normal eyes. Rogers (2003) and Algaze et al. (2005) have shown that L-dopa, a drug used in the treatment of Parkinson's disease, caused a reduction in volume of activation of occipital visual cortex while it improved visual acuity - a counterintuitive finding. (Yang et al., 2003) showed that the volume ratio between the amblyopic and sound eye stimulation significantly increased after L-dopa treatment. More recently, the amblyopic eye showed marked reduction in activation in the fusiform gyrus, with normal activation in the collateral sulcus (Lerner et al., 2006). Responses to grating stimuli showed reduced responses in higher areas on the central visual pathway (Muckli et al., 2006).

In albinism, there is an abnormal chiasmic projection system which favors the contralateral hemisphere (Schmitz et al., 2004). For example, in oculocutaneous albinism and in ocular albinism, monocular stimulation yields a greater fMRI response in the contralateral hemisphere than the ipsilateral hemisphere because of misrouting of the eye's afferents favoring the contralateral hemisphere. After using standard fMRI statistical analysis tools, the number of voxels activated in each hemisphere were counted for each subject. A crossing ratio was then computed by subtracting the voxels activated contralaterally from the ipsilateral ones and dividing by the total number activated. The mean of these ratios for left and right eyes were then calculated for correlations.

Reduced signal and greater asymmetry in the visual cortex has been shown in optic neuritis (ON) patients, compared with controls (Langkilde et al., 2002). They also showed that the volume of visual cortical activation was significantly correlated to the result of the contrast sensitivity test. They used an asymmetry index I_a to calculate the relative difference between size of activated area in the left and right hemisphere, in a similar fashion to the above study. This was done by simply counting the number of voxels in each hemisphere and taking the absolute value of the difference and dividing by the total number of voxels in both hemispheres. A value of $I_a = 1$ meant 100% asymmetry while a value of $I_a = 0$ meant no asymmetry. Toosy et al. (2002) showed that visual cortex activation is reduced during photic stimulation, whilst extra-occipital areas are extensively activated with a peak blood oxygen level dependent response during the OFF phase of the stimulus paradigm. More recently they suggested a genuine adaptive role for cortical reorganization within extrastriate visual areas early after optic neuritis (Toosy et al., 2005). Reduced activation was seen in V1 during stimulation of the affected eye, compared to the normal eye (Levin et al., 2006).

Parents of children with autism or Asperger Syndrome (AS) showed atypical brain function during both visual search and emotion recognition (Baron-Cohen et al., 2006). Hadjikhani et al. (2004a) found that retinotopic maps of individuals with autism were similar to normal subjects, indicating that low level visual processing is normal. A case study by Sunness et al. (2004) illustrated that retinotopic mapping can be performed successfully in patients with central scotomas from macular disease. An increase in the activation of the prefrontal cortex and intraparietal sulci and decrease in the visual cortex was reported in patients with macular degeneration (Little et al., 2008). The ability to look at anatomical reorganization of the visual cortex was demonstrated in a case of callosal agenesis and colpocephaly (Bittar et al., 2000), and in alteration by vascular lesions (Schlosser et al., 1997). Analyzing oculomotor recovery from ischemic lesions in frontal and parietal eye fields using visually triggered saccades has been recently implemented (Nyffeler et al., 2011).

In an eye blink inhibition study, patients with Tourette syndrome showed higher activation in the middle frontal gyrus, dorsal anterior cingulate and temporal cortices compared to controls (Mazzone et al., 2010). Most recently the decline of the cerebellum has been shown to be associated with INS (Leguire et al., 2011b). Similarly the cerebellar vermis, also has been found to be active in patients with bipolar disorder while performing SPEM (Martin et al., 2011). fMRI activation during downward smooth pursuit was less in both flocculi of the cerebellum for patients with DBN than controls (Kalla et al., 2006). Reduced activation in the parafloccular lobule and in the ponto-medullary brainstem of the patients was also seen (Hüfner et al., 2007). Saccadic oscillations in patients with opsoclonus may be a result of disinhibition of the cerebellar fastigial nuclei (Helmchen et al., 2003a;b). Monitoring vision therapy using fMRI for patients with CI revealed increase in activity in the frontal areas, cerebellum and brainstem (Alvarez et al., 2010). Understanding SPEM is also of interest in schizophrenia where greater activity in both posterior hippocampi and the right fusiform gyrus have been reported (Tregellas et al., 2004). The same investigators also found that nicotine was associated with greater activity in the anterior and posterior cingulate gyri, precuneus and area MT/MST and less activity in the hippocampus and parietal eye fields in patients with schizophrenia (Tregellas et al., 2005).

Data from Hadjikhani et al. (2001) suggested that an electrophysiological event such as cortical spreading depression (CSD) generates migraine aura in the visual cortex. This was determined using a standard *t* statistic computing the difference between activation amplitude during off period preceding aura. The time courses for independent voxels were then extracted from specific visual areas. A reference baseline (mean) and standard deviation was

computed on the first 6 cycles and the pixels that exhibited a higher mean plus standard deviation and a standard deviation less than the reference standard deviation for at least 2 cycles were considered as activated. The visual cortex of patients with idiopathic Parkinsons disease with and without visual hallucinations were examined by Holroyd & Wooten (2006). They found that patients with visual hallucinations had increased activation in the visual association cortex and deficits in the primary visual cortex. Again these are samples of the fMRI studies published in literature. Table 2 lists a few pathologies related to vision investigated using fMRI.

Pathology
Albinism
Amblyopia
Autism
Bipolar Disorder
Callosal Agenesis & Colpocephaly
Convergence Insufficiency
Downbeat Nystagmus
Glaucoma
Infantile Nystagmus Syndrome
Ischemic Lesions
Macular Degeneration
Migrane Aura
Opsoclonus
Optic Neuritis
Parkinsons Disease
Schizophrenia
Tourette Syndrome
Vascular Lesions

Table 2. Pathologies investigated using fMRI.

8. Discussion

In this chapter we aimed to discuss the basics of visual development and then review fMRI vision science research. To recap, there are three main principles in visual development: labeled lines, cells firing together wire together, and synaptic competition. In summary, sensory cells send the same kind of signal, regardless of how, or how strongly, they are stimulates (labeled lines). The relations between the retina and the LGN, and between the LGN and the cortex, are crudely wired up at birth, by prenatal "visual" experience of the wave. That wire up is refined and related to the proximal stimulus by genuine postnatal visual experience and synaptic competition. This refinement includes creation of new synapses and culling of old ones.

Abnormalities early in life can cause disorders in the visual pathway. Rod monochromats do not have the normal photoreceptor connections from the retina and thus the rods take over the synaptic fields where the fovea usually falls in V1. Albinos seem to have a dysfunction in the chemical signposts that separate the nasal and temporal retina projections. In refractive amblyopia, there is a blur in the proximal stimuli of one eye and high frequency cells are not fully developed in V1 because they are cut out during the refinement process. Strabismic

amblyopes suffer from an eye turn early on that causes an abnormal wave which leads to miswiring between the LGN and V1.

The use of functional MRI has proved to be a successful imaging modality in understanding the visual development process and for basic research in vision science of controls and patients. Currently, neuroscientists, neurologists, ophthalmologists and others are using this imaging modality extensively to study vision science related problems. Further development of these studies will allow noninvasive diagnostic, pre-, and post- surgical techniques with the aim of improving the clinical sensitivity and specificity for visual cortex diagnosis.

9. Limitations of fMRI interpretation

The key to interpreting fMRI data is to understand the problem being studied. In this chapter some applications from vision science were discussed to show the extensiveness of the field. The more one knows about vision science in general the better they will be able to make an informed interpretation of the fMRI activation. However it is essential to have this knowledge before designing an fMRI study. It is also necessary to have firm knowledge of the MR technology and physics in order to appreciate the complexities and intricacies of the process. This in turn would help minimize errors and confounds in the results. The main limitations of interpretation lies in the knowledge of the user. Unfortunately, some believe that this is a pushbutton technology and whatever comes out is perfect. On the contrary, a good understanding of the field, in this case vision science, the technology, and the art of designing an fMRI experiment, will allow for respect and caution when interpreting and analyzing the data.

10. Future developments in fMRI

The advancement in technology will have the biggest influence on the future developments in fMRI. Most of the studies presented here were on 1.5 or 3 Tesla systems but ultra high field (UHF) 7 and 8 Tesla systems are now regularly being used for human research. The limiting factor for UHF MRI are the head coils, however continuous effort is being made for optimization and improvement. In the next few years 1.5 and even 3 Tesla systems will seem old in the field of research as the new UHF magnets have superior resolution (down to the μm). This will enhance the visualization of cortical areas and allow the parcellation of smaller anatomical regions such as the LGN and allow the functional localization of subregions that otherwise would be bulked into one region in the current scanners. Clinical imaging developments in the short term are focusing on enhancing the 3 Tesla technology by transition from 8 channel head coils to 32 channels so there will be a delay before the UHF systems make their way into hospitals.

11. References

- Algaze, A., Roberts, C., Leguire, L., Schmalbrock, P. & Rogers, G. (2002). Functional magnetic resonance imaging as a tool for investigating amblyopia in the human visual cortex: a pilot study., *J AAPOS* 6(5): 300–308.
- Algaze, A., Leguire, L. E., Roberts, C., Ibinson, J. W., Lewis, J. R. & Rogers, G. (2005). The effects of l-dopa on the functional magnetic resonance imaging response of patients with amblyopia: a pilot study., *J AAPOS* 9(3): 216–223.
URL: <http://dx.doi.org/10.1016/j.jaapos.2005.01.014>

- Alvarez, T. L., Vicci, V. R., Alkan, Y., Kim, E. H., Gohel, S., Barrett, A. M., Chiaravalloti, N. & Biswal, B. B. (2010). Vision therapy in adults with convergence insufficiency: clinical and functional magnetic resonance imaging measures., *Optom Vis Sci* 87(12): E985–1002.
URL: <http://dx.doi.org/10.1097/OPX.0b013e3181fef1aa>
- Andersson, F., Joliot, M., Perchey, G. & Petit, L. (2007). Eye position-dependent activity in the primary visual area as revealed by fmri., *Hum Brain Mapp* 28(7): 673–680.
URL: <http://dx.doi.org/10.1002/hbm.20296>
- Baron-Cohen, S., Ring, H., Chitnis, X., Wheelwright, S., Gregory, L., Williams, S., Brammer, M. & Bullmore, E. (2006). fmri of parents of children with asperger syndrome: a pilot study., *Brain Cogn* 61(1): 122–130.
URL: <http://dx.doi.org/10.1016/j.bandc.2005.12.011>
- Barton, J. J., Simpson, T., Kiriakopoulos, E., Stewart, C., Crawley, A., Guthrie, B., Wood, M. & Mikulis, D. (1996). Functional mri of lateral occipitotemporal cortex during pursuit and motion perception., *Ann Neurol* 40(3): 387–398.
URL: <http://dx.doi.org/10.1002/ana.410400308>
- Büchel, C., Josephs, O., Rees, G., Turner, R., Frith, C. D. & Friston, K. J. (1998). The functional anatomy of attention to visual motion. a functional mri study., *Brain* 121 (Pt 7): 1281–1294.
- Büchel, C., Turner, R. & Friston, K. (1997). Lateral geniculate activations can be detected using intersubject averaging and fmri., *Magn Reson Med* 38(5): 691–694.
- Bense, S., Janusch, B., Schlindwein, P., Bauermann, T., Vucurevic, G., Brandt, T., Stoeter, P. & Dieterich, M. (2006). Direction-dependent visual cortex activation during horizontal optokinetic stimulation (fmri study)., *Hum Brain Mapp* 27(4): 296–305.
URL: <http://dx.doi.org/10.1002/hbm.20185>
- Bense, S., Janusch, B., Vucurevic, G., Bauermann, T., Schlindwein, P., Brandt, T., Stoeter, P. & Dieterich, M. (2006). Brainstem and cerebellar fmri-activation during horizontal and vertical optokinetic stimulation., *Exp Brain Res* 174(2): 312–323.
URL: <http://dx.doi.org/10.1007/s00221-006-0464-0>
- Berman, R. A., Colby, C. L., Genovese, C. R., Voyvodic, J. T., Luna, B., Thulborn, K. R. & Sweeney, J. A. (1999). Cortical networks subserving pursuit and saccadic eye movements in humans: an fmri study., *Hum Brain Mapp* 8(4): 209–225.
- Bittar, R. G., Ptito, A., Dumoulin, S. O., Andermann, F. & Reutens, D. C. (2000). Reorganisation of the visual cortex in callosal agenesis and colpocephaly., *J Clin Neurosci* 7(1): 13–15.
URL: <http://dx.doi.org/10.1054/jocn.1998.0105>
- Blasdel, G. G., Lund, J. S. & Fitzpatrick, D. (1985). Intrinsic connections of macaque striate cortex: axonal projections of cells outside lamina 4c., *J Neurosci* 5(12): 3350–3369.
- Bodis-Wollner, I., Bucher, S. F., Seelos, K. C., Paulus, W., Reiser, M. & Oertel, W. H. (1997). Functional mri mapping of occipital and frontal cortical activity during voluntary and imagined saccades., *Neurology* 49(2): 416–420.
- Bucher, S. F., Dieterich, M., Seelos, K. C. & Brandt, T. (1997). Sensorimotor cerebral activation during optokinetic nystagmus. a functional mri study., *Neurology* 49(5): 1370–1377.
- Calkins, D. & Hendry, S. (1996). A retinogeniculate pathway expresses the alpha subunit of cam ii kinase in the primate, *Soc. Neurosci. Abstr.* 22: 1447.
- Callaway, E. M. & Wiser, A. K. (1996). Contributions of individual layer 2-5 spiny neurons to local circuits in macaque primary visual cortex., *Vis Neurosci* 13(5): 907–922.
- Campbell, G. & Shatz, C. J. (1992). Synapses formed by identified retinogeniculate axons during the segregation of eye input., *J Neurosci* 12(5): 1847–1858.

- Chen, W., Kato, T., Zhu, X. H., Ogawa, S., Tank, D. W. & Ugurbil, K. (1998). Human primary visual cortex and lateral geniculate nucleus activation during visual imagery., *Neuroreport* 9(16): 3669–3674.
- Chen, W., Kato, T., Zhu, X. H., Strupp, J., Ogawa, S. & Ugurbil, K. (1998). Mapping of lateral geniculate nucleus activation during visual stimulation in human brain using fmri., *Magn Reson Med* 39(1): 89–96.
- Chen, W. & Zhu, X. H. (2001). Correlation of activation sizes between lateral geniculate nucleus and primary visual cortex in humans., *Magn Reson Med* 45(2): 202–205.
- Chen, W., Zhu, X. H., Thulborn, K. R. & Ugurbil, K. (1999). Retinotopic mapping of lateral geniculate nucleus in humans using functional magnetic resonance imaging., *Proc Natl Acad Sci U S A* 96(5): 2430–2434.
- Cheng, K., Waggoner, R. A. & Tanaka, K. (2001). Human ocular dominance columns as revealed by high-field functional magnetic resonance imaging., *Neuron* 32(2): 359–374.
- Choi, M. Y., Lee, K. M., Hwang, J. M., Choi, D. G., Lee, D. S., Park, K. H. & Yu, Y. S. (2001). Comparison between anisometropic and strabismic amblyopia using functional magnetic resonance imaging., *Br J Ophthalmol* 85(9): 1052–1056.
- Conner, I. P., Sharma, S., Lemieux, S. K. & Mendola, J. D. (2004). Retinotopic organization in children measured with fmri., *J Vis* 4(6): 509–523.
URL: <http://dx.doi.org/10.1167/4.6.10>
- Connolly, J. D., Goodale, M. A., Goltz, H. C. & Munoz, D. P. (2005). fmri activation in the human frontal eye field is correlated with saccadic reaction time., *J Neurophysiol* 94(1): 605–611.
URL: <http://dx.doi.org/10.1152/jn.00830.2004>
- Cornelissen, F. W., Kimmig, H., Schira, M., Rutschmann, R. M., Maguire, R. P., Broerse, A., Boer, J. A. D. & Greenlee, M. W. (2002). Event-related fmri responses in the human frontal eye fields in a randomized pro- and antisaccade task., *Exp Brain Res* 145(2): 270–274.
URL: <http://dx.doi.org/10.1007/s00221-002-1136-3>
- Cowan, W. M., Fawcett, J. W., O'Leary, D. D. & Stanfield, B. B. (1984). Regressive events in neurogenesis., *Science* 225(4668): 1258–1265.
- Curcio, C. A. & Allen, K. A. (1990). Topography of ganglion cells in human retina., *J Comp Neurol* 300(1): 5–25.
URL: <http://dx.doi.org/10.1002/cne.903000103>
- Darby, D. G., Nobre, A. C., Thangaraj, V., Edelman, R., Mesulam, M. M. & Warach, S. (1996). Cortical activation in the human brain during lateral saccades using epistar functional magnetic resonance imaging., *Neuroimage* 3(1): 53–62.
URL: <http://dx.doi.org/10.1006/nimg.1996.0006>
- Derrington, A. M. & Lennie, P. (1984). Spatial and temporal contrast sensitivities of neurones in lateral geniculate nucleus of macaque., *J Physiol* 357: 219–240.
- Deutschländer, A., Hübner, K., Kalla, R., Stephan, T., Dera, T., Glasauer, S., Wiesmann, M., Strupp, M. & Brandt, T. (2008). Unilateral vestibular failure suppresses cortical visual motion processing., *Brain* 131(Pt 4): 1025–1034.
URL: <http://dx.doi.org/10.1093/brain/awn035>
- Deutschländer, A., Marx, E., Stephan, T., Riedel, E., Wiesmann, M., Dieterich, M. & Brandt, T. (2005). Asymmetric modulation of human visual cortex activity during 10 degrees lateral gaze (fmri study)., *Neuroimage* 28(1): 4–13.
URL: <http://dx.doi.org/10.1016/j.neuroimage.2005.06.001>

- Dieterich, M., Bucher, S. F., Seelos, K. C. & Brandt, T. (1998). Horizontal or vertical optokinetic stimulation activates visual motion-sensitive, ocular motor and vestibular cortex areas with right hemispheric dominance. an fmri study., *Brain* 121 (Pt 8): 1479–1495.
- Dieterich, M., Bucher, S. F., Seelos, K. C. & Brandt, T. (2000). Cerebellar activation during optokinetic stimulation and saccades., *Neurology* 54(1): 148–155.
- Dieterich, M., Bense, S., Stephan, T., Yousry, T. A. & Brandt, T. (2003). fmri signal increases and decreases in cortical areas during small-field optokinetic stimulation and central fixation., *Exp Brain Res* 148(1): 117–127.
URL: <http://dx.doi.org/10.1007/s00221-002-1267-6>
- Engel, S. & Furmanski, C. (1997). Neural activity in human lateral geniculate nucleus measured with functional mri., *Invest Ophthalmol Vis Sci* 38(Suppl): 1689.
- Ettinger, U., Ffytche, D. H., Kumari, V., Kathmann, N., Reuter, B., Zelaya, F. & Williams, S. C. R. (2008). Decomposing the neural correlates of antisaccade eye movements using event-related fmri., *Cereb Cortex* 18(5): 1148–1159.
URL: <http://dx.doi.org/10.1093/cercor/bhm147>
- Fitzpatrick, D., Lund, J. S. & Blasdel, G. G. (1985). Intrinsic connections of macaque striate cortex: afferent and efferent connections of lamina 4c., *J Neurosci* 5(12): 3329–3349.
- Fitzpatrick, D., Usrey, W. M., Schofield, B. R. & Einstein, G. (1994). The sublaminar organization of corticogeniculate neurons in layer 6 of macaque striate cortex., *Vis Neurosci* 11(2): 307–315.
- Freitag, P., Greenlee, M. W., Lacina, T., Scheffler, K. & Radü, E. W. (1998). Effect of eye movements on the magnitude of functional magnetic resonance imaging responses in extrastriate cortex during visual motion perception., *Exp Brain Res* 119(4): 409–414.
- Galli, L. & Maffei, L. (1988). Spontaneous impulse activity of rat retinal ganglion cells in prenatal life., *Science* 242(4875): 90–91.
- Gareau, P. J., Gati, J. S., Menon, R. S., Lee, D., Rice, G., Mitchell, J. R., Mandelfino, P. & Karlik, S. J. (1999). Reduced visual evoked responses in multiple sclerosis patients with optic neuritis: comparison of functional magnetic resonance imaging and visual evoked potentials., *Mult Scler* 5(3): 161–164.
- Goodman, C. S. & Shatz, C. J. (1993). Developmental mechanisms that generate precise patterns of neuronal connectivity., *Cell* 72 Suppl: 77–98.
- Goodyear, B. G. & Menon, R. S. (2001). Brief visual stimulation allows mapping of ocular dominance in visual cortex using fmri., *Hum Brain Mapp* 14(4): 210–217.
- Goodyear, B. G., Nicolle, D. A., Humphrey, G. K. & Menon, R. S. (2000). Bold fmri response of early visual areas to perceived contrast in human amblyopia., *J Neurophysiol* 84(4): 1907–1913.
- Guillery (1970). The laminar distribution of retinal fibers in the dorsal lateral geniculate nucleus of the cat: a new interpretation, *J. Comp. Neurol.* 138: 339–68.
- Hadjikhani, N., Liu, A. K., Dale, A. M., Cavanagh, P. & Tootell, R. B. (1998). Retinotopy and color sensitivity in human visual cortical area v8., *Nat Neurosci* 1(3): 235–241.
URL: <http://dx.doi.org/10.1038/681>
- Hadjikhani, N., Rio, M. S. D., Wu, O., Schwartz, D., Bakker, D., Fischl, B., Kwong, K. K., Cutrer, F. M., Rosen, B. R., Tootell, R. B., Sorensen, A. G. & Moskowitz, M. A. (2001). Mechanisms of migraine aura revealed by functional mri in human visual cortex., *Proc Natl Acad Sci U S A* 98(8): 4687–4692.
URL: <http://dx.doi.org/10.1073/pnas.071582498>
- Hadjikhani, N., Joseph, R. M., Snyder, J., Chabris, C. F., Clark, J., Steele, S., McGrath, L., Vangel, M., Aharon, I., Feczko, E., Harris, G. J. & Tager-Flusberg, H. (2004).

- Activation of the fusiform gyrus when individuals with autism spectrum disorder view faces., *Neuroimage* 22(3): 1141–1150.
URL: <http://dx.doi.org/10.1016/j.neuroimage.2004.03.025>
- Hadjikhani, N., Chabris, C. F., Joseph, R. M., Clark, J., McGrath, L., Aharon, I., Feczko, E., Tager-Flusberg, H. & Harris, G. J. (2004). Early visual cortex organization in autism: an fmri study., *Neuroreport* 15(2): 267–270.
- Haller, S., Fasler, D., Ohlendorf, S., Radue, E. W. & Greenlee, M. W. (2008). Neural activation associated with corrective saccades during tasks with fixation, pursuit and saccades., *Exp Brain Res* 184(1): 83–94.
URL: <http://dx.doi.org/10.1007/s00221-007-1077-y>
- Hayakawa, Y., Nakajima, T., Takagi, M., Fukuhara, N. & Abe, H. (2002). Human cerebellar activation in relation to saccadic eye movements: a functional magnetic resonance imaging study., *Ophthalmologica* 216(6): 399–405.
URL: <http://dx.doi.org/10.1159/000067551>
- Helmchen, C., Rambold, H., Sprenger, A., Erdmann, C., & Binkofski, F. (2003). Cerebellar activation in opsoclonus: an fmri study., *Neurology* 61(3): 412–415.
- Helmchen, C., Rambold, H., Erdmann, C., Mohr, C., Sprenger, A. & Binkofski, F. (2003). The role of the fastigial nucleus in saccadic eye oscillations., *Ann N Y Acad Sci* 1004: 229–240.
- Hendry, S. H. & Reid, R. C. (2000). The koniocellular pathway in primate vision., *Annu Rev Neurosci* 23: 127–153.
URL: <http://dx.doi.org/10.1146/annurev.neuro.23.1.127>
- Hendry, S. H. & Yoshioka, T. (1994). A neurochemically distinct third channel in the macaque dorsal lateral geniculate nucleus., *Science* 264(5158): 575–577.
- Hüfner, K., Stephan, T., Kalla, R., Deutschländer, A., Wagner, J., Holtmannspötter, M., Schulte-Altdorneburg, G., Strupp, M., Brandt, T. & Glasauer, S. (2007). Structural and functional mris disclose cerebellar pathologies in idiopathic downbeat nystagmus., *Neurology* 69(11): 1128–1135.
URL: <http://dx.doi.org/10.1212/01.wnl.0000276953.00969.48>
- Holmes, G. (1918). Disturbances of vision by cerebral lesions., *Br J Ophthalmol* 2(7): 353–384.
- Holmes, G. (1944). The organization of the visual cortex in man., *Proc. R. Soc. London Ser. B* 132: 348–61.
- Holroyd, S. & Wooten, G. F. (2006). Preliminary fmri evidence of visual system dysfunction in parkinson's disease patients with visual hallucinations., *J Neuropsychiatry Clin Neurosci* 18(3): 402–404.
URL: <http://dx.doi.org/10.1176/appi.neuropsych.18.3.402>
- Horton, J. C. & Hoyt, W. F. (1991). The representation of the visual field in human striate cortex. a revision of the classic holmes map., *Arch Ophthalmol* 109(6): 816–824.
- Horton, J. C. & Hubel, D. H. (1981). Regular patchy distribution of cytochrome oxidase staining in primary visual cortex of macaque monkey., *Nature* 292(5825): 762–764.
- Hubel, D. H. & Wiesel, T. N. (1977). Ferrier lecture. functional architecture of macaque monkey visual cortex., *Proc R Soc Lond B Biol Sci* 198(1130): 1–59.
- Humphrey, A. L. & Hendrickson, A. E. (1980). Radial zones of high metabolic activity in squirrel monkey striate cortex., *Soe.Neurosci. Abstr.* 6: 315.
- Kaas, J. H., Guillery, R. W. & Allman, J. M. (1972). Some principles of organization in the dorsal lateral geniculate nucleus., *Brain Behav Evol* 6(1): 253–299.
- Kaas, J. H., Huerta, M. F., Weber, J. T. & Harting, J. K. (1978). Patterns of retinal terminations and laminar organization of the lateral geniculate nucleus of primates., *J Comp Neurol*

- 182(3): 517–553.
URL: <http://dx.doi.org/10.1002/cne.901820308>
- Kalla, R., Deutschlander, A., Hufner, K., Stephan, T., Jahn, K., Glasauer, S., Brandt, T. & Strupp, M. (2006). Detection of floccular hypometabolism in downbeat nystagmus by fmri., *Neurology* 66(2): 281–283.
URL: <http://dx.doi.org/10.1212/01.wnl.0000194242.28018.d9>
- Kashou, N., Leguire, L. & Roberts, C. (2006). fmri on look vs stare optokinetic nystagmus (okn), *Invest Ophthal and Vis Sci* 47: 5873.
- Kashou, N. H. (2008). *Development of Functional Studies and Methods to Better Understand Visual Function.*, PhD thesis, The Ohio State University.
- Kashou, N. H., Leguire, L. E., Roberts, C. J., Fogt, N., Smith, M. A. & Rogers, G. L. (2010). Instruction dependent activation during optokinetic nystagmus (okn) stimulation: An fmri study at 3t., *Brain Res* 1336: 10–21.
URL: <http://dx.doi.org/10.1016/j.brainres.2010.04.017>
- Kimmig, H., Greenlee, M. W., Gondan, M., Schira, M., Kassubek, J. & Mergner, T. (2001). Relationship between saccadic eye movements and cortical activity as measured by fmri: quantitative and qualitative aspects., *Exp Brain Res* 141(2): 184–194.
URL: <http://dx.doi.org/10.1007/s002210100844>
- Kleinschmidt, A., Merboldt, K. D., Hänicke, W., Steinmetz, H. & Frahm, J. (1994). Correlational imaging of thalamocortical coupling in the primary visual pathway of the human brain., *J Cereb Blood Flow Metab* 14(6): 952–957.
- Kleinschmidt, A., Obrig, H., Requardt, M., Merboldt, K. D., Dirnagl, U., Villringer, A. & Frahm, J. (1996). Simultaneous recording of cerebral blood oxygenation changes during human brain activation by magnetic resonance imaging and near-infrared spectroscopy., *J Cereb Blood Flow Metab* 16(5): 817–826.
URL: <http://dx.doi.org/10.1097/00004647-199609000-00006>
- Konen, C. S., Kleiser, R., Seitz, R. J. & Bremmer, F. (2005). An fmri study of optokinetic nystagmus and smooth-pursuit eye movements in humans., *Exp Brain Res* 165(2): 203–216.
URL: <http://dx.doi.org/10.1007/s00221-005-2289-7>
- Konen, C. S., Kleiser, R., Wittsack, H.-J., Bremmer, F. & Seitz, R. J. (2004). The encoding of saccadic eye movements within human posterior parietal cortex., *Neuroimage* 22(1): 304–314.
URL: <http://dx.doi.org/10.1016/j.neuroimage.2003.12.039>
- Lachica, E. A., Beck, P. D. & Casagrande, V. A. (1992). Parallel pathways in macaque monkey striate cortex: anatomically defined columns in layer iii., *Proc Natl Acad Sci U S A* 89(8): 3566–3570.
- Langkilde, A. R., Frederiksen, J. L., Rostrup, E. & Larsson, H. B. W. (2002). Functional mri of the visual cortex and visual testing in patients with previous optic neuritis., *Eur J Neurol* 9(3): 277–286.
- Lee, K. M., Lee, S. H., Kim, N. Y., Kim, C. Y., Sohn, J. W., Choi, M. Y., Choi, D. G., Hwang, J. M., Park, K. H., Lee, D. S., Yu, Y. S. & Chang, K. H. (2001). Binocularity and spatial frequency dependence of calcarine activation in two types of amblyopia., *Neurosci Res* 40(2): 147–153.
- Lee, S.-H., Blake, R. & Heeger, D. J. (2005). Traveling waves of activity in primary visual cortex during binocular rivalry., *Nat Neurosci* 8(1): 22–23.
URL: <http://dx.doi.org/10.1038/nn1365>

- Leguire, L., Algaze, A., Murakami, J., Rogers, G. & Roberts, C. (2004). fmri more closely follows contrast sensitivity than visual acuity., *Invest Ophthalmol and Vis Sci*.
- Leguire, L., Algaze, A., Murakami, J., Rogers, G., Lewis, J. & Roberts, C. (2004). Relation among fmri, visual acuity and csf., *American Association of Pediatric Ophthalmology and Strabismus*.
- Leguire, L. E., Algaze, A., Kashou, N. H., Lewis, J., Rogers, G. L. & Roberts, C. (2011). Relationship among fmri, contrast sensitivity and visual acuity., *Brain Res* 1367: 162–169.
URL: <http://dx.doi.org/10.1016/j.brainres.2010.10.082>
- Leguire, L. E., Kashou, N. H., Fogt, N., Smith, M. A., Lewis, J. R., Kulwin, R. & Rogers, G. L. (2011). Neural circuit involved in idiopathic infantile nystagmus syndrome based on fmri., *J Pediatr Ophthalmol Strabismus* pp. 1–10.
URL: <http://dx.doi.org/10.3928/01913913-20110118-03>
- Lennie, P., Krauskopf, J. & Sclar, G. (1990). Chromatic mechanisms in striate cortex of macaque., *J Neurosci* 10(2): 649–669.
- Lerner, Y., Hendler, T., Malach, R., Harel, M., Leiba, H., Stolovitch, C. & Pianka, P. (2006). Selective fovea-related deprived activation in retinotopic and high-order visual cortex of human amblyopes., *Neuroimage* 33(1): 169–179.
URL: <http://dx.doi.org/10.1016/j.neuroimage.2006.06.026>
- Levin, N., Orlov, T., Dotan, S. & Zohary, E. (2006). Normal and abnormal fmri activation patterns in the visual cortex after recovery from optic neuritis., *Neuroimage* 33(4): 1161–1168.
URL: <http://dx.doi.org/10.1016/j.neuroimage.2006.07.030>
- Lewis, J., Algaze, A., Leguire, L., Rogers, G., Murakami, J. & Roberts, C. (2003). Age effects on fmri using grating stimuli, *Association for Research in Vision and Ophthalmology*.
- Lewis, J., Algaze, A., Leguire, L., Rogers, G., Murakami, J. & Roberts, C. (2004). Age effect on fmri using grating stimuli., *American Association of Pediatric Ophthalmology and Strabismus*.
- Lichtman, J. W., Burden, S. J., Culican, S. M. & Wong, R. O. L. (1999). *Fundamental Neuroscience*, Acad. Press, chapter Synapse formation and elimination., pp. 547–580.
- Linden, D. C., Guillery, R. W. & Cucchiari, J. (1981). The dorsal lateral geniculate nucleus of the normal ferret and its postnatal development., *J Comp Neurol* 203(2): 189–211.
URL: <http://dx.doi.org/10.1002/cne.902030204>
- Little, D. M., Thulborn, K. R. & Szlyk, J. P. (2008). An fmri study of saccadic and smooth-pursuit eye movement control in patients with age-related macular degeneration., *Invest Ophthalmol Vis Sci* 49(4): 1728–1735.
URL: <http://dx.doi.org/10.1167/iovs.07-0372>
- Liu, C.-S. J., Bryan, R. N., Miki, A., Woo, J. H., Liu, G. T. & Elliott, M. A. (2006). Magnocellular and parvocellular visual pathways have different blood oxygen level-dependent signal time courses in human primary visual cortex., *AJNR Am J Neuroradiol* 27(8): 1628–1634.
- Luna, B., Thulborn, K. R., Strojwas, M. H., McCurtain, B. J., Berman, R. A., Genovese, C. R. & Sweeney, J. A. (1998). Dorsal cortical regions subserving visually guided saccades in humans: an fmri study., *Cereb Cortex* 8(1): 40–47.
- Lund, J. & Boothe, R. (1975). Interlaminar connections and pyramidal neuron organization in the visual cortex, area 17, of the macaque monkey., *J. Comp. Neurology* 159: 305–334.

- Lund, J. S. (1988). Anatomical organization of macaque monkey striate visual cortex., *Annu Rev Neurosci* 11: 253–288.
URL: <http://dx.doi.org/10.1146/annurev.ne.11.030188.001345>
- Lund, J. S., Henry, G. H., MacQueen, C. L. & Harvey, A. R. (1979). Anatomical organization of the primary visual cortex (area 17) of the cat. a comparison with area 17 of the macaque monkey., *J Comp Neurol* 184(4): 599–618.
URL: <http://dx.doi.org/10.1002/cne.901840402>
- Martin, L. F., Olincy, A., Ross, R. G., Du, Y. P., Singel, D., Shatti, S. & Tregellas, J. R. (2011). Cerebellar hyperactivity during smooth pursuit eye movements in bipolar disorder., *J Psychiatr Res* 45(5): 670–677.
URL: <http://dx.doi.org/10.1016/j.jpsychires.2010.09.015>
- Mazzone, L., Yu, S., Blair, C., Gunter, B. C., Wang, Z., Marsh, R. & Peterson, B. S. (2010). An fmri study of frontostriatal circuits during the inhibition of eye blinking in persons with tourette syndrome., *Am J Psychiatry* 167(3): 341–349.
URL: <http://dx.doi.org/10.1176/appi.ajp.2009.08121831>
- Meissirel, C., Wikler, K. C., Chalupa, L. M. & Rakic, P. (1997). Early divergence of magnocellular and parvocellular functional subsystems in the embryonic primate visual system., *Proc Natl Acad Sci U S A* 94(11): 5900–5905.
- Meister, M., Wong, R. O., Baylor, D. A. & Shatz, C. J. (1991). Synchronous bursts of action potentials in ganglion cells of the developing mammalian retina., *Science* 252(5008): 939–943.
- Mendola, J. D., Conner, I. P., Sharma, S., Bahekar, A. & Lemieux, S. (2006). fmri measures of perceptual filling-in in the human visual cortex., *J Cogn Neurosci* 18(3): 363–375.
URL: <http://dx.doi.org/10.1162/089892906775990624>
- Mendola, J. D., Dale, A. M., Fischl, B., Liu, A. K. & Tootell, R. B. (1999). The representation of illusory and real contours in human cortical visual areas revealed by functional magnetic resonance imaging., *J Neurosci* 19(19): 8560–8572.
- Merigan, W. H. & Maunsell, J. H. (1993). How parallel are the primate visual pathways?, *Annu Rev Neurosci* 16: 369–402.
URL: <http://dx.doi.org/10.1146/annurev.ne.16.030193.002101>
- Merriam, E. P., Colby, C. L., Thulborn, K. R., Luna, B., Olson, C. R. & Sweeney, J. A. (2001). Stimulus-response incompatibility activates cortex proximate to three eye fields., *Neuroimage* 13(5): 794–800.
URL: <http://dx.doi.org/10.1006/nimg.2000.0742>
- Miki, A., Raz, J., Haselgrove, J. C., van Erp, T. G., Liu, C. S. & Liu, G. T. (2000). Functional magnetic resonance imaging of lateral geniculate nucleus at 1.5 tesla., *J Neuroophthalmol* 20(4): 285–287.
- Miki, A., Liu, G. T., Fletcher, D. W., Hunter, J. V. & Haselgrove, J. C. (2001). Ocular dominance in anterior visual cortex in a child demonstrated by the use of fmri., *Pediatr Neurol* 24(3): 232–234.
- Miki, A., Liu, G., Modestino, E., Liu, C. & Englander, S. (2001). Functional magnetic resonance imaging of lateral geniculate nucleus and visual cortex at 4 tesla in a patient with homonymous hemianopia., *Neuro-ophthalmology* 25: 109–14.
- Miki, A., Liu, G. T., Raz, J., Englander, S. A., Bonhomme, G. R., Aleman, D. O., Modestino, E. J., Liu, C. S. & Haselgrove, J. C. (2001). Visual activation in functional magnetic resonance imaging at very high field (4 tesla)., *J Neuroophthalmol* 21(1): 8–11.
- Miller, L. M., Sun, F. T., Curtis, C. E. & D’Esposito, M. (2005). Functional interactions between oculomotor regions during prosaccades and antisaccades., *Hum Brain Mapp*

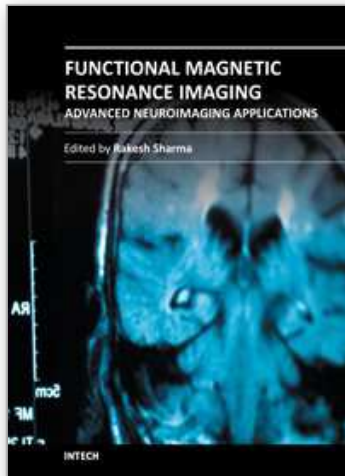
- 26(2): 119–127.
URL: <http://dx.doi.org/10.1002/hbm.20146>
- Morita, T., Kochiyama, T., Yamada, H., Konishi, Y., Yonekura, Y., Matsumura, M. & Sadato, N. (2000). Difference in the metabolic response to photic stimulation of the lateral geniculate nucleus and the primary visual cortex of infants: a fmri study., *Neurosci Res* 38(1): 63–70.
- Morland, A. B., Baseler, H. A., Hoffmann, M. B., Sharpe, L. T. & Wandell, B. A. (2001). Abnormal retinotopic representations in human visual cortex revealed by fmri., *Acta Psychol (Amst)* 107(1-3): 229–247.
- Mort, D. J., Perry, R. J., Mannan, S. K., Hodgson, T. L., Anderson, E., Quest, R., McRobbie, D., McBride, A., Husain, M. & Kennard, C. (2003). Differential cortical activation during voluntary and reflexive saccades in man., *Neuroimage* 18(2): 231–246.
- Müri, R. M., Iba-Zizen, M. T., Derosier, C., Cabanis, E. A. & Pierrot-Deseilligny, C. (1996). Location of the human posterior eye field with functional magnetic resonance imaging., *J Neurol Neurosurg Psychiatry* 60(4): 445–448.
- Müri, R. M., Heid, O., Nirkko, A. C., Ozdoba, C., Felblinger, J., Schroth, G. & Hess, C. W. (1998). Functional organisation of saccades and antisaccades in the frontal lobe in humans: a study with echo planar functional magnetic resonance imaging., *J Neurol Neurosurg Psychiatry* 65(3): 374–377.
- Muckli, L., Kiess, S., Tonhausen, N., Singer, W., Goebel, R. & Sireteanu, R. (2006). Cerebral correlates of impaired grating perception in individual, psychophysically assessed human amblyopes., *Vision Res* 46(4): 506–526.
URL: <http://dx.doi.org/10.1016/j.visres.2005.10.014>
- Mullen, K. T., Thompson, B. & Hess, R. F. (2010). Responses of the human visual cortex and lgn to achromatic and chromatic temporal modulations: an fmri study., *J Vis* 10(13): 13.
URL: <http://dx.doi.org/10.1167/10.13.13>
- Murray, S. O., Olman, C. A. & Kersten, D. (2006). Spatially specific fmri repetition effects in human visual cortex., *J Neurophysiol* 95(4): 2439–2445.
URL: <http://dx.doi.org/10.1152/jn.01236.2005>
- Nagel, M., Sprenger, A., Nitschke, M., Zapf, S., Heide, W., Binkofski, F. & Lencer, R. (2007). Different extraretinal neuronal mechanisms of smooth pursuit eye movements in schizophrenia: An fmri study., *Neuroimage* 34(1): 300–309.
URL: <http://dx.doi.org/10.1016/j.neuroimage.2006.08.025>
- Nguyen, Q. T. & Lichtman, J. W. (1996). Mechanism of synapse disassembly at the developing neuromuscular junction., *Curr Opin Neurobiol* 6(1): 104–112.
- Nyffeler, T., Hubl, D., Wurtz, P., Wiest, R., Hess, C. W. & Müri, R. M. (2011). Spontaneous recovery of visually-triggered saccades after focal lesions of the frontal and parietal eye fields: a combined longitudinal oculomotor and fmri study., *Clin Neurophysiol* 122(6): 1203–1210.
URL: <http://dx.doi.org/10.1016/j.clinph.2010.08.026>
- Ohlendorf, S., Sprenger, A., Speck, O., Glauche, V., Haller, S. & Kimmig, H. (2010). Visual motion, eye motion, and relative motion: A parametric fmri study of functional specializations of smooth pursuit eye movement network areas., *J Vis* 10(14): 21.
URL: <http://dx.doi.org/10.1167/10.14.21>
- Osterberg, G. (1935). Topography of the layer of rods and cones in the human retina, *Acta Ophthalmol Suppl* 6: 1–103.

- Paradis, A. L., Cornilleau-Pérès, V., Droulez, J., Moortele, P. F. V. D., Lobel, E., Berthoz, A., Bihan, D. L. & Poline, J. B. (2000). Visual perception of motion and 3-d structure from motion: an fmri study., *Cereb Cortex* 10(8): 772–783.
- Pelphrey, K. A., Morris, J. P., Michelich, C. R., Allison, T. & McCarthy, G. (2005). Functional anatomy of biological motion perception in posterior temporal cortex: an fmri study of eye, mouth and hand movements., *Cereb Cortex* 15(12): 1866–1876.
URL: <http://dx.doi.org/10.1093/cercor/bhi064>
- Perry, V. H., Oehler, R. & Cowey, A. (1984). Retinal ganglion cells that project to the dorsal lateral geniculate nucleus in the macaque monkey., *Neuroscience* 12(4): 1101–1123.
- Petit, L., Clark, V. P., Ingeholm, J. & Haxby, J. V. (1997). Dissociation of saccade-related and pursuit-related activation in human frontal eye fields as revealed by fmri., *J Neurophysiol* 77(6): 3386–3390.
- Petit, L. & Haxby, J. V. (1999). Functional anatomy of pursuit eye movements in humans as revealed by fmri., *J Neurophysiol* 82(1): 463–471.
- Purpura, K., Kaplan, E. & Shapley, R. M. (1988). Background light and the contrast gain of primate p and m retinal ganglion cells., *Proc Natl Acad Sci U S A* 85(12): 4534–4537.
- Purpura, K., Tranchina, D., Kaplan, E. & Shapley, R. M. (1990). Light adaptation in the primate retina: analysis of changes in gain and dynamics of monkey retinal ganglion cells., *Vis Neurosci* 4(1): 75–93.
- Purves, D. & Lichtman, J. (1985). *Principles of Neural Development*, Sinauer.
- Rakic, P. (1976). Prenatal genesis of connections subserving ocular dominance in the rhesus monkey., *Nature* 261(5560): 467–471.
- Rakic, P. (1977). Prenatal development of the visual system in rhesus monkey., *Philos Trans R Soc Lond B Biol Sci* 278(961): 245–260.
- Ress, D., Backus, B. T. & Heeger, D. J. (2000). Activity in primary visual cortex predicts performance in a visual detection task., *Nat Neurosci* 3(9): 940–945.
URL: <http://dx.doi.org/10.1038/78856>
- Ress, D. & Heeger, D. J. (2003). Neuronal correlates of perception in early visual cortex., *Nat Neurosci* 6(4): 414–420.
URL: <http://dx.doi.org/10.1038/nn1024>
- Rogers, G. L. (2003). Functional magnetic resonance imaging (fmri) and effects of l-dopa on visual function in normal and amblyopic subjects., *Trans Am Ophthalmol Soc* 101: 401–415.
- Rombouts, S. A., Lazeron, R. H., Scheltens, P., Uitdehaag, B. M., Sprenger, M., Valk, J. & Barkhof, F. (1998). Visual activation patterns in patients with optic neuritis: an fmri pilot study., *Neurology* 50(6): 1896–1899.
- Rosano, C., Krisky, C. M., Welling, J. S., Eddy, W. F., Luna, B., Thulborn, K. R. & Sweeney, J. A. (2002). Pursuit and saccadic eye movement subregions in human frontal eye field: a high-resolution fmri investigation., *Cereb Cortex* 12(2): 107–115.
- Sawatari, A. & Callaway, E. M. (2000). Diversity and cell type specificity of local excitatory connections to neurons in layer 3b of monkey primary visual cortex., *Neuron* 25(2): 459–471.
- Schiller, P. H. & Malpeli, J. G. (1978). Functional specificity of lateral geniculate nucleus laminae of the rhesus monkey., *J Neurophysiol* 41(3): 788–797.
- Schlosser, M. J., McCarthy, G., Fulbright, R. K., Gore, J. C. & Awad, I. A. (1997). Cerebral vascular malformations adjacent to sensorimotor and visual cortex. functional magnetic resonance imaging studies before and after therapeutic intervention., *Stroke* 28(6): 1130–1137.

- Schmitz, B., Käsmann-Kellner, B., Schäfer, T., Krick, C. M., Grön, G., Backens, M. & Reith, W. (2004). Monocular visual activation patterns in albinism as revealed by functional magnetic resonance imaging., *Hum Brain Mapp* 23(1): 40–52.
URL: <http://dx.doi.org/10.1002/hbm.20046>
- Schneider, K. A. & Kastner, S. (2005). Visual responses of the human superior colliculus: a high-resolution functional magnetic resonance imaging study., *J Neurophysiol* 94(4): 2491–2503.
URL: <http://dx.doi.org/10.1152/jn.00288.2005>
- Schraa-Tam, C. K. L., van der Lugt, A., Smits, M., Frens, M. A., van Broekhoven, P. C. A. & van der Geest, J. N. (2008). fmri of optokinetic eye movements with and without a contribution of smooth pursuit., *J Neuroimaging* 18(2): 158–167.
URL: <http://dx.doi.org/10.1111/j.1552-6569.2007.00204.x>
- Schwartz (2004). *Visual perception: a clinical orientation*, McGraw-Hill.
- Sclar, G., Maunsell, J. H. & Lennie, P. (1990). Coding of image contrast in central visual pathways of the macaque monkey., *Vision Res* 30(1): 1–10.
- Seghier, M., Dojat, M., Delon-Martin, C., Rubin, C., Warnking, J., Segebarth, C. & Bullier, J. (2000). Moving illusory contours activate primary visual cortex: an fmri study., *Cereb Cortex* 10(7): 663–670.
- Shapley, R., Kaplan, E. & Soodak, R. (1981). Spatial summation and contrast sensitivity of x and y cells in the lateral geniculate nucleus of the macaque., *Nature* 292(5823): 543–545.
- Shapley, R. & Perry, V. (1986). Cat and monkey ganglion cells and their visual functional roles., *Trends Neuroscience* 9: 229–235.
- Shatz, C. J. & Kirkwood, P. A. (1984). Prenatal development of functional connections in the cat's retinogeniculate pathway., *J Neurosci* 4(5): 1378–1397.
- Sincich, L. C. & Horton, J. C. (2005). The circuitry of v1 and v2: integration of color, form, and motion., *Annu Rev Neurosci* 28: 303–326.
URL: <http://dx.doi.org/10.1146/annurev.neuro.28.061604.135731>
- Sterzer, P., Haynes, J.-D. & Rees, G. (2006). Primary visual cortex activation on the path of apparent motion is mediated by feedback from hmt+/v5., *Neuroimage* 32(3): 1308–1316.
URL: <http://dx.doi.org/10.1016/j.neuroimage.2006.05.029>
- Sunness, J. S., Liu, T. & Yantis, S. (2004). Retinotopic mapping of the visual cortex using functional magnetic resonance imaging in a patient with central scotomas from atrophic macular degeneration., *Ophthalmology* 111(8): 1595–1598.
URL: <http://dx.doi.org/10.1016/j.opthta.2003.12.050>
- Tanabe, J., Tregellas, J., Miller, D., Ross, R. G. & Freedman, R. (2002). Brain activation during smooth-pursuit eye movements., *Neuroimage* 17(3): 1315–1324.
- Toosy, A. T., Werring, D. J., Bullmore, E. T., Plant, G. T., Barker, G. J., Miller, D. H. & Thompson, A. J. (2002). Functional magnetic resonance imaging of the cortical response to photic stimulation in humans following optic neuritis recovery., *Neurosci Lett* 330(3): 255–259.
- Toosy, A. T., Hickman, S. J., Miszkiel, K. A., Jones, S. J., Plant, G. T., Altmann, D. R., Barker, G. J., Miller, D. H. & Thompson, A. J. (2005). Adaptive cortical plasticity in higher visual areas after acute optic neuritis., *Ann Neurol* 57(5): 622–633.
URL: <http://dx.doi.org/10.1002/ana.20448>

- Tootell, R. B., Mendola, J. D., Hadjikhani, N. K., Ledden, P. J., Liu, A. K., Reppas, J. B., Sereno, M. I. & Dale, A. M. (1997). Functional analysis of v3a and related areas in human visual cortex., *J Neurosci* 17(18): 7060–7078.
- Tregellas, J. R., Tanabe, J. L., Miller, D. E., Ross, R. G., Olincy, A. & Freedman, R. (2004). Neurobiology of smooth pursuit eye movement deficits in schizophrenia: an fmri study., *Am J Psychiatry* 161(2): 315–321.
- Tregellas, J. R., Tanabe, J. L., Martin, L. F. & Freedman, R. (2005). Fmri of response to nicotine during a smooth pursuit eye movement task in schizophrenia., *Am J Psychiatry* 162(2): 391–393.
URL: <http://dx.doi.org/10.1176/appi.ajp.162.2.391>
- Warnking, J., Dojat, M., Guérin-Dugué, A., Delon-Martin, C., Olympieff, S., Richard, N., Chéhikian, A. & Segebarth, C. (2002). fmri retinotopic mapping—step by step., *Neuroimage* 17(4): 1665–1683.
- Werring, D., Bullmore, E., Toosy, A., Miller, D., Barker, G., MacManus, D., Brammer, M., Giampietro, V., Brusa, A., Brex, P., Moseley, I., Plant, G., McDonald, W. & Thompson, A. (2000). Recovery from optic neuritis is associated with a change in the distribution of cerebral response to visual stimulation: a functional magnetic resonance imaging study., *J Neurol Neurosurg Psychiatry* 68: 441–9.
- Wiesel, T. N. (1982). Postnatal development of the visual cortex and the influence of environment., *Nature* 299(5884): 583–591.
- Wong, R. (1999.). Retinal waves and visual system development., *Annu. Rev. Neurosci.* 22: 29–47.
- Yang, C.-I., Yang, M.-L., Huang, J.-C., Wan, Y.-L., Tsai, R. J.-F., Wai, Y.-Y. & Liu, H.-L. (2003). Functional mri of amblyopia before and after levodopa., *Neurosci Lett* 339(1): 49–52.
- Yazar, F., Mavity-Hudson, J., Ding, Y., Oztas, E. & Casagrande, V. (2004). Layer iiib-beta of primary visual cortex (v1) and its relationship to the koniocellular (k) pathway in macaque., *Soc.Neurosci. Abstr.* 34: 300.

IntechOpen



Functional Magnetic Resonance Imaging - Advanced Neuroimaging Applications

Edited by Prof. Rakesh Sharma

ISBN 978-953-51-0541-1

Hard cover, 206 pages

Publisher InTech

Published online 09, May, 2012

Published in print edition May, 2012

"Functional Magnetic Resonance Imaging - Advanced Neuroimaging Applications" is a concise book on applied methods of fMRI used in assessment of cognitive functions in brain and neuropsychological evaluation using motor-sensory activities, language, orthographic disabilities in children. The book will serve the purpose of applied neuropsychological evaluation methods in neuropsychological research projects, as well as relatively experienced psychologists and neuroscientists. Chapters are arranged in the order of basic concepts of fMRI and physiological basis of fMRI after event-related stimulus in first two chapters followed by new concepts of fMRI applied in constraint-induced movement therapy; reliability analysis; refractory SMA epilepsy; consciousness states; rule-guided behavioral analysis; orthographic frequency neighbor analysis for phonological activation; and quantitative multimodal spectroscopic fMRI to evaluate different neuropsychological states.

How to reference

In order to correctly reference this scholarly work, feel free to copy and paste the following:

Nasser H Kashou (2012). Current Trends of fMRI in Vision Science: A Review, Functional Magnetic Resonance Imaging - Advanced Neuroimaging Applications, Prof. Rakesh Sharma (Ed.), ISBN: 978-953-51-0541-1, InTech, Available from: <http://www.intechopen.com/books/functional-magnetic-resonance-imaging-advanced-neuroimaging-applications/current-trends-of-fmri-in-vision-science-a-review>

INTECH
open science | open minds

InTech Europe

University Campus STeP Ri
Slavka Krautzeka 83/A
51000 Rijeka, Croatia
Phone: +385 (51) 770 447
Fax: +385 (51) 686 166
www.intechopen.com

InTech China

Unit 405, Office Block, Hotel Equatorial Shanghai
No.65, Yan An Road (West), Shanghai, 200040, China
中国上海市延安西路65号上海国际贵都大饭店办公楼405单元
Phone: +86-21-62489820
Fax: +86-21-62489821

© 2012 The Author(s). Licensee IntechOpen. This is an open access article distributed under the terms of the [Creative Commons Attribution 3.0 License](https://creativecommons.org/licenses/by/3.0/), which permits unrestricted use, distribution, and reproduction in any medium, provided the original work is properly cited.

IntechOpen

IntechOpen