

# We are IntechOpen, the world's leading publisher of Open Access books Built by scientists, for scientists

6,900

Open access books available

186,000

International authors and editors

200M

Downloads

Our authors are among the

154

Countries delivered to

TOP 1%

most cited scientists

12.2%

Contributors from top 500 universities



WEB OF SCIENCE™

Selection of our books indexed in the Book Citation Index  
in Web of Science™ Core Collection (BKCI)

Interested in publishing with us?  
Contact [book.department@intechopen.com](mailto:book.department@intechopen.com)

Numbers displayed above are based on latest data collected.  
For more information visit [www.intechopen.com](http://www.intechopen.com)



# Stereotactic Brachytherapy for Brain Tumors

Maximilian I. Ruge<sup>1</sup>, Stefan Grau<sup>2</sup>,  
Harald Treuer<sup>1</sup> and Volker Sturm<sup>1</sup>

<sup>1</sup>*Department of Stereotaxy and Functional Neurosurgery,*

<sup>2</sup>*Department of Neurosurgery, University of Cologne,  
Germany*

## 1. Introduction

Brachytherapy for the treatment of brain tumors has a very long history and for selected indications still represents a safe, minimally invasive and effective local treatment option, offered by specialized centers. In the following chapter we review stereotactic brachytherapy (SBT) for brain tumors, including the history, physical aspects, surgical procedure, and indications, which are introduced and discussed in the context of the available literature.

## 2. History of brachytherapy for brain tumors

In 1901, on Pierre Curie's suggestion, Danlos inserted a radium isotope directly into a tumor. This is the first known use of interstitial irradiation, and was published later in 1905 in *Journal de la Physiothérapie* (Bernstein & Gutin, 1981; Danlos, 1905).

Around the same time, in 1908 Horsley and Clarke introduced a 3D targeting stereotaxis apparatus to study a monkey's brain (Horsley & Clarke, 1908). The development of stereotactic techniques had begun. The first use of this apparatus in humans was performed in 1918 by Mussen (Picard et al., 1983). This technique allowed precise targeting of brain structures for neurosurgical purposes.

The first implantation of a radioactive source into a structure of the CNS, more precisely into a tumor of the pituitary gland, was described by Hirsch in 1912 (Hirsch et al., 1912). Two years later, in 1914, Frazier reported for the first time the implantation of radioactive material into glioma (Frazier, 1920).

Further development of this technology took place in the 1930s by introducing new techniques to improve accuracy in dosimetry for multiple implants (Patterson, 1934).

In the 1950's stereotactic guidance for the implantation of radioactive sources was used to precisely treat inoperable brain tumors. (Mundinger et al., 1956; Talairach et al., 1955)

In the 1970-80s implementing image-guided stereotactic surgery continuously improved the preciseness of placing the radioactive material into (malignant) brain tumors (McDermott et al., 1998).

Since then, multiple studies have been published for the treatment of various intrinsic brain tumors, establishing (stereotactic) brachytherapy as a safe, minimally invasive, and effective neurosurgical technique for selected indications.

### 3. Physical aspects

Most frequently, Iodine-125-seeds (I-125) are used for stereotactic brachytherapy in brain tumors. Among a variety of possible radioactive sources used for brachytherapy, seeds containing I-125 are preferred for several reasons.

- i. The energy of the emitted  $\gamma$ -rays (35.5 keV) and characteristic X-rays (27.2 – 31.7 keV) during the decay of I-125 is low (National Nuclear Data Center). This is advantageous, since such low energy photons are strongly absorbed in brain tissue (half-value layer: 2 cm) (Hubbell and Seltzer), yielding very high dose values inside the tumor, but additionally sparing surrounding healthy tissue. Thus the resulting dose gradient in brachytherapy with I-125-seeds is superior compared to stereotactic radiosurgery with external photon beams.  
Furthermore, radiation emitted by I-125 is strongly absorbed in cortical bone (half-value layer: 3 mm) and can easily be shielded with lead (half-value layer: 0.02 mm). Thus radiation exposure of the patient's family and health care staff can be kept low.
- ii. The half-life of I-125 is rather long, 59.4 days (National Nuclear Data Center); hence the dose rate decreases by only 1.16% per day during irradiation. This allows extension of irradiation times to several weeks or longer, with only slowly decreasing dose rates. For example, a total dose of 60 Gy accumulated in 42 days equals a dose rate of as high as 1.8 Gy/day at the beginning and still 1.1 Gy/day at the end of treatment. Long-term irradiation regimens appear favorable, especially for slow-growing tumors.
- iii. I-125-seeds of different type and source strength are readily available on the market (Heintz et al., 2001). The option to select seeds with activities ranging from 0.5 mCi – 10 mCi is a prerequisite for creating conformal treatment plans for brain tumors with a low number of seed-catheters. In fact, with I-125-seeds highly conformal treatment plans with conformity indices ranging from 48% – 79% (mean 70%) can be created for brain tumors by applying as few as 1 – 3 catheters (mean 1.8) and 1 – 6 seeds per catheter (mean 2.4) (Treuer et al., 2005). Implanting a low number of catheters in the brain minimizes the operative risks of bleeding and infections, and reduces operation time, and thus problems due to brain shift (Hunsche et al., 2009).

The use of seeds with radio-opaque markers (such as Model 6711, Amersham Health) facilitates accurate intra-operative stereotactic localization of the seeds with X-rays or CT (Treuer et al., 2004). Thus the actual seed location during implantation can be determined and compared with the planned position. An accuracy of 1.5 mm in positioning of I-125-seeds was shown to be required in order to not inadequately compromise dose conformity (Treuer et al., 2005). With stereotactic guidance techniques such an accuracy requirement can be met.

Unlike other isotopes with low quantum energy, the dosimetry of I-125-seeds appears to be well understood. The main principles of the dosimetry of interstitial brachytherapy sources were defined in the report of the Task Group 43 of the American Association of Physicists in Medicine (AAPM) in 1995 (Nath et al., 1995). Recent recommendations of the AAPM, especially for the Amersham Model 6711 I-125-seed,

state that “changes in delivered dose from the introduction of the Model 6711 seed to the present have been less than 0.5% and can safely be ignored” (Willimson et al., 2005). The value of accurate and common standards in dosimetry is obvious.

#### 4. Surgical procedure

The radioactive seed(s) can be implanted in different ways. Some authors describe the placement of seeds without stereotactic guidance (“free hand”) into the tumor or the cavity after microsurgical debulking of the tumor. This procedure has been described for metastasis and gliomas (Fernandez et al., 1995; Halligan et al., 1996; Patel et al., 2000; Schulder et al., 1997; Zamorano et al., 1992). This procedure, however, makes calculation of the dose distribution in the tissue very challenging, because seed location might shift over time when the resection cavity is changing its configuration. Furthermore, a later calculation of the prescribed dose might also be challenging.

To date, the majority of groups place the seed(s) using stereotactic guidance. For this procedure a stereotactic computed tomography (CT) compatible frame is adjusted on the patient’s head after inducing general or local anesthesia (Fig. 1a). We use both CT and magnetic resonance imaging (MRI) for the planning procedure: CT-imaging has the advantage of being less susceptible to distortions, while MR imaging provides better structural resolution of brain and tumor tissue. After CT imaging using a stereotactic localizer, CT scans are fused with MR images. Depending on the planning software, image fusion can be performed either automatically or by using anatomical landmarks (i.e. vessels) (Fig. 2a, CT scan; Fig 2b, MRI T1 weighed contrast). In some cases functional imaging such as functional MRI (fMRI) and/or positron emission tomography (PET) imaging can be added (C-11-methionine, F-18-FET, F-18-FDG).

The next step is defining the target volume. Using MR (T2-, T1 contrast-, and in some cases FLAIR-weighted images), CT as well as - in specific cases - PET imaging, the visible margins of the tumor are outlined manually (Fig. 2c). The objective of radiation treatment planning for brain tumors is always to determine a seed configuration with as few seed catheters as possible (to minimize operative risk) and to achieve an optimal conformation of the therapeutic isodose with respect to the surface of the target volume (Treuer et al., 2005). Inverse treatment planning is used. The desired surface dose, implantation time, and trephination point(s) are selected manually and a seed configuration yielding optimal coverage of the tumor with the prescribed dose is calculated automatically by minimization of an appropriate objective function (Bauer-Kirpes et al., 1988) (Fig. 4).

In the operation room, the stereotactic arc is adjusted on a phantom according to the calculated coordinates, and then mounted on the patient’s stereotactic frame.

The <sup>125</sup>Iodine seeds (Amersham Buchler GmbH & CoKG, Braunschweig, Germany) are introduced into celcon nylon or silicon catheters (Best Industries Inc., Springfield, VA, USA / Phoenix-Biomedical Corp., Ontario, Canada; Fig. 1b, c). After skin incision and placement of an 8 mm burr hole, the catheters are inserted into the tumor (Fig. 1d). In case histology is requested, a stereotactic biopsy can be taken and evaluated during the operation. To ensure correct placement of the seed(s) intraoperatively we perform X-ray imaging in two planes (anterior/posterior and lateral) with a stationary stereotactic X-ray source, and match these images with images of the calculated trajectory (Fig. 3a, b).



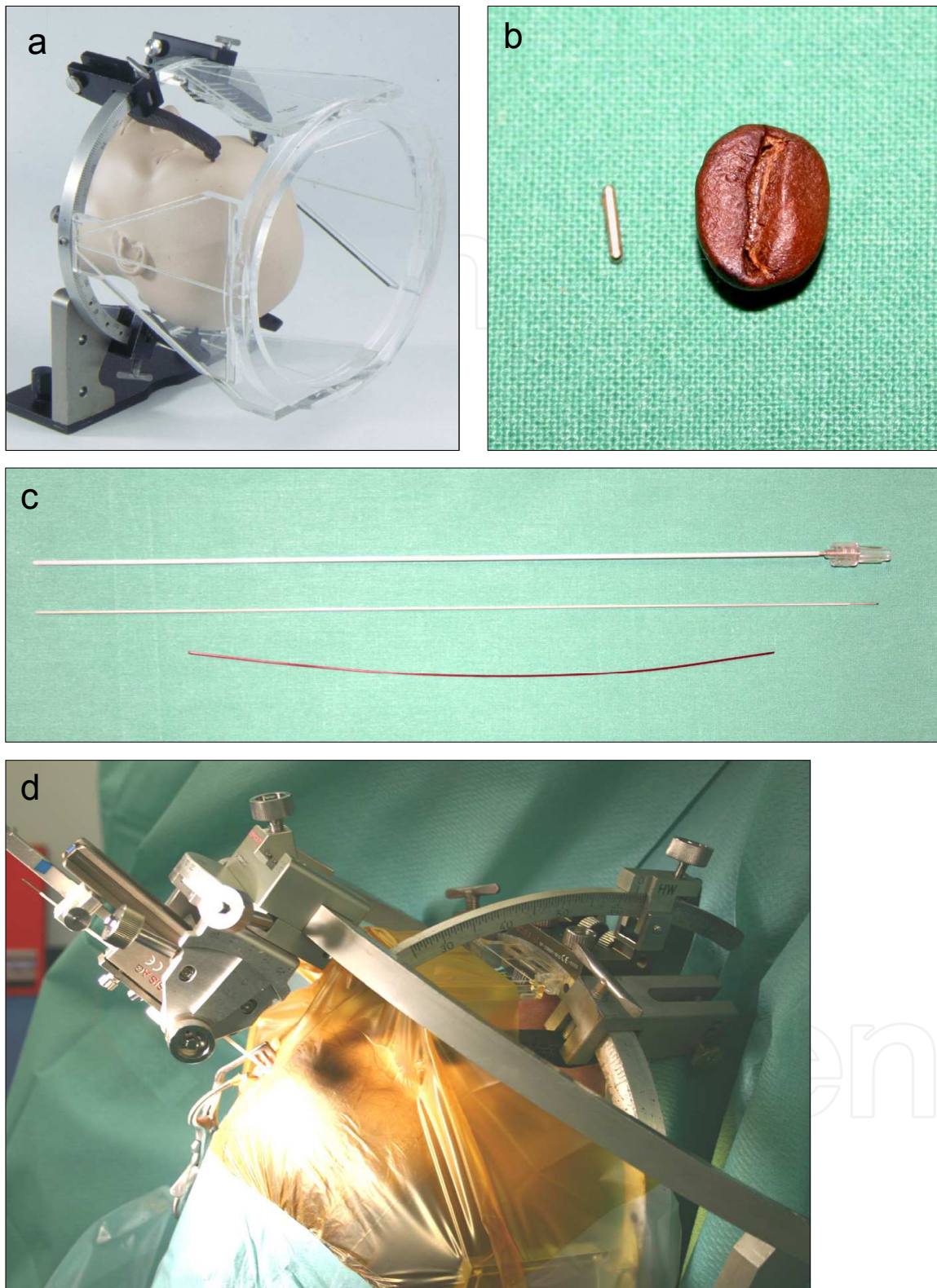


Fig. 1. Steps involved in stereotactic brachytherapy. a) Stereotactic frame with localizer. b) Iodine-125 seed compared to a coffee bean. c) The first catheter is placed stereotactically in the target volume (above). The second catheter is filled with the calculated seed(s) (middle) which are fixed by insertion of a thin tube (below) and then placed in the first catheter. d) Operative setting with the stereotactic frame, the stereotactic arc and the inserted seed catheter.

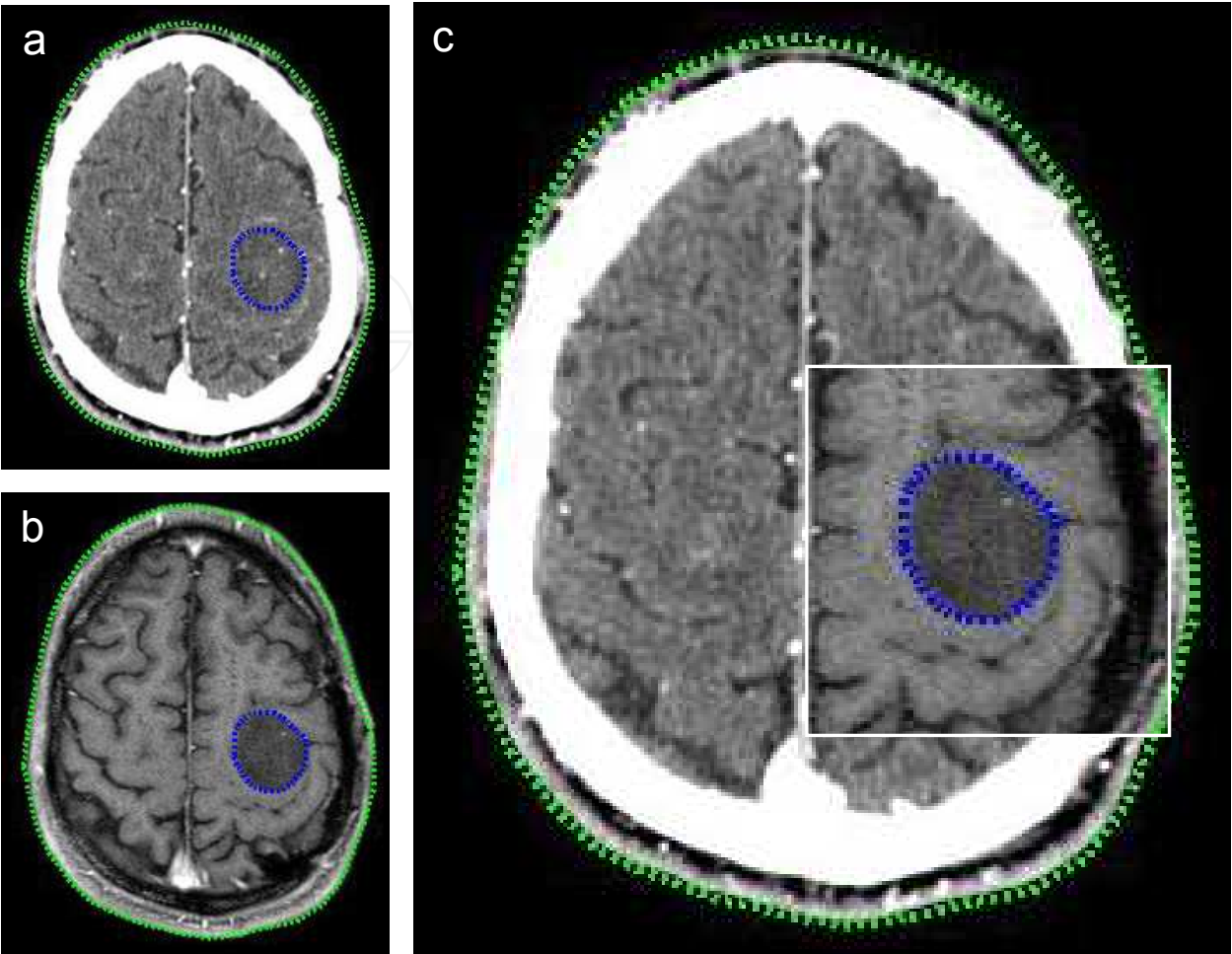


Fig. 2. Image fusion of CT and MRI scans. a) CT image; b) MRI image. c) The blue dotted line represents the manually outlined tumor margin.

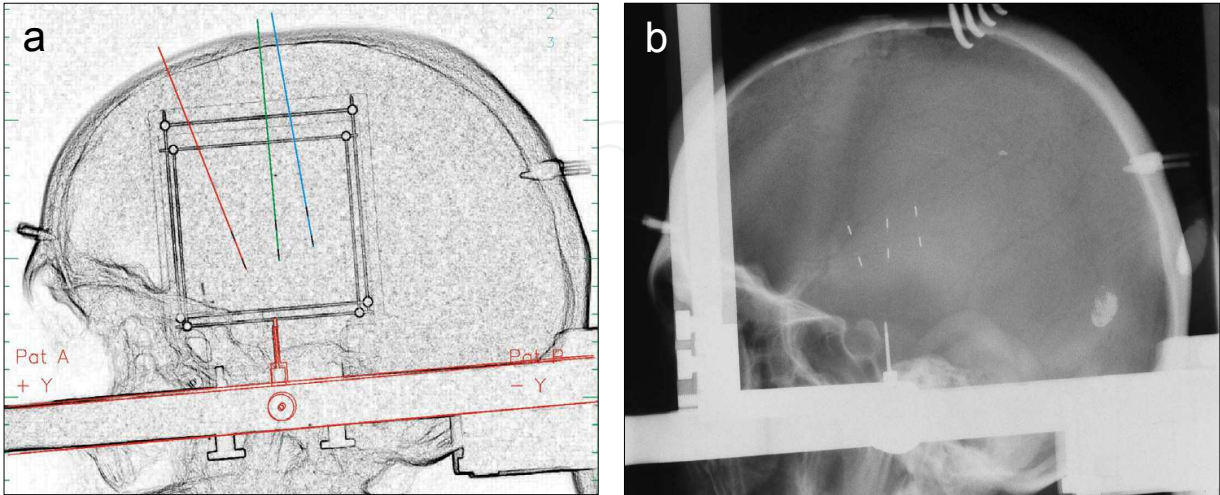


Fig. 3. The stereotactic treatment plan. a) Positioning of the catheters and seeds, which is then compared with b) the two plane X-ray images performed after final placement of the seeds-catheters by over-laying.



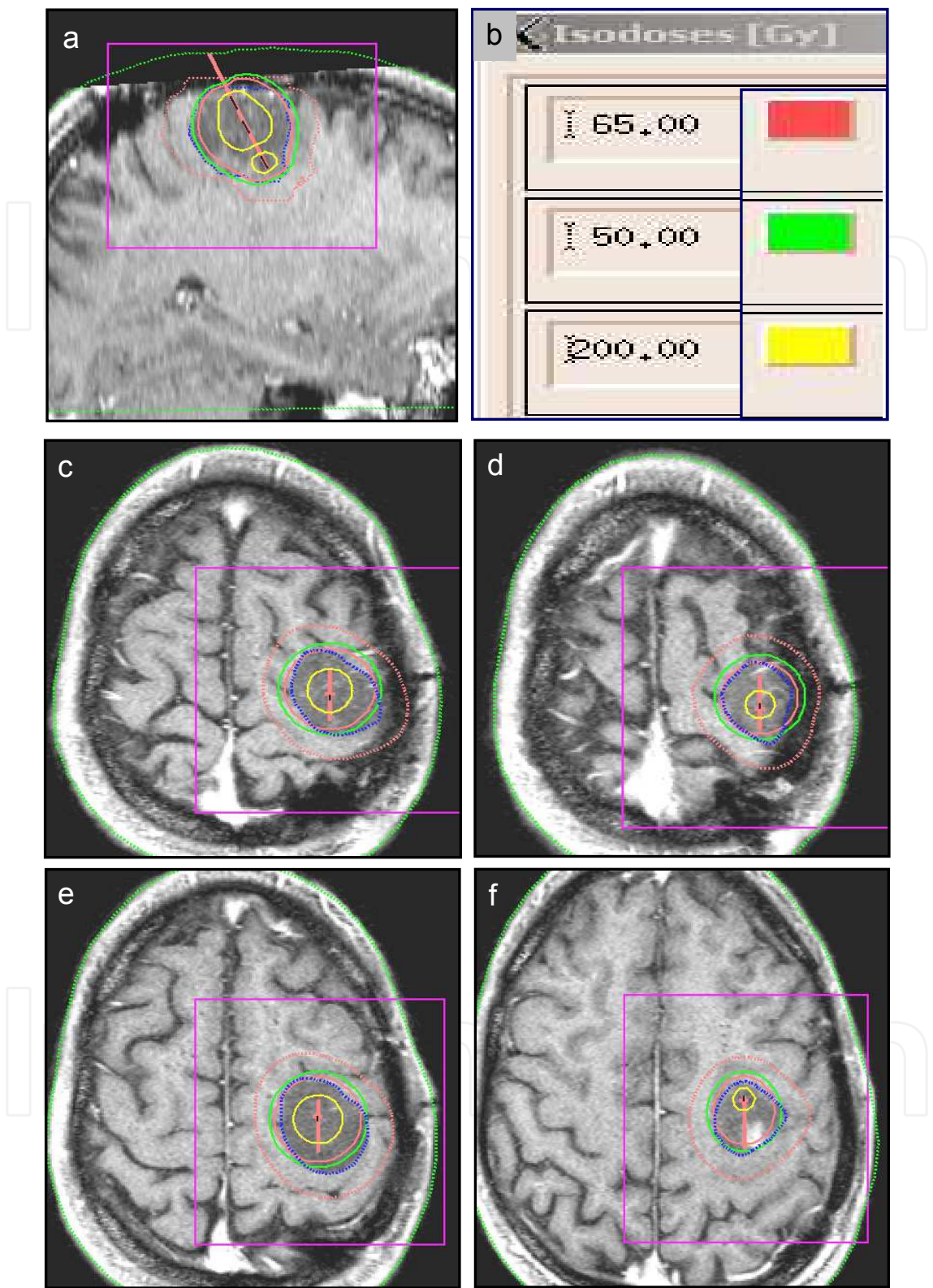


Fig. 4. An irradiation plan of an anaplastic astrocytoma WHO III in the left central sulcus area (see also case report in Fig. 5). Isodose lines are displayed on MR T1 weighed contrast enhanced images in a) sagittal, and c-f) axial orientation. The dark blue dotted line represents the manually outlined tumor surface, the green line represents the 50 Gy isodose, the red line the 65 Gy isodose and yellow the 200 Gy isodose line. b) The straight red line in a) shows the simulated catheter containing the I-125 seeds.

Compared to intraoperative CT or MRI scanning used by some groups to monitor laser thermal therapy or placement of DBS electrodes, this technique does not require movement of the patient or a time-consuming imaging session. Furthermore, it is comparatively fast, repeatable, and even allows monitoring of the (re-)positioning of the catheters containing the I-125 seeds with high precision and with a comparatively low radiation burden for the patient (Treuer et al., 2005, Ruge et al, 2011a;b;c;d). For stabilization, the catheters are fixed within the burr hole using bone cement. In addition, the catheter tip, protruding out of the cement by approximately 3-5 mm, is fixed with a vessel clip to further avoid displacement.

In the rare cases of intraoperatively detected incorrect placement of the implanted seeds, we primarily revise the catheter position. If this revision is not satisfactory, the isodose plan is recalculated and the irradiation time adjusted accordingly.

Finally, the emitted radiation is measured at 1 m and 2 m distances from the patient's head. In cases where the dose rate exceeds 2  $\mu\text{Sv/h}$  at 1 m distance, the patient has to temporarily wear a lead cap (Voges et al., 1999).

The duration of the surgical procedure is usually between 40 minutes and 1.5 hours, depending on the number of catheters used. The patient's hospital stay varies between 3–5 days.

Seed catheters if implanted temporarily are removed under local anesthesia by removing the vessel clip and extracting the catheter, leaving the cement within the burr hole. This procedure requires a hospital stay of one day in most cases. At this time every patient receives a follow-up MRI using the same imaging protocol as in the SBT planning to ensure comparability.

## 5. Indications for Stereotactic Brachytherapy (SBT)

SBT was initially considered to be indicated for patients with a circumscribed tumor with a maximum diameter of 5 cm on CT or MRI scans. Based on available risk analysis (Kreth et al., 1997), the treatment is now widely restricted to well circumscribed tumors with a diameter not larger than 4 cm. Kreth et al. demonstrated that beyond a cut-off of approximately 3.5 cm tumor diameter (or a tumor volume of 22.4 ml) radiogenic complications increase exponentially (Kreth et al., 1997). Furthermore, the volume of the high dose irradiation zone (200 Gy isodose) also correlates directly with radiation induced tissue damage.

Patients with non-circumscribed (diffuse) tumors, or with tumors of the corpus callosum, hypothalamus, fornices, or optical system (optical nerve, chiasm) are not considered suitable for this treatment.

Among the variety of intracranial neoplasms, data from larger series exist for intracranial gliomas and metastatic brain tumors. Therefore, indication for brachytherapy should focus on these entities, while application of brachytherapy for other, rare indications, which are only mentioned briefly, should be carefully considered.

### 5.1 SBT for high-grade gliomas (WHO III & IV)

Malignant gliomas are non-curable intrinsic tumors of the central nervous system with a rate of almost 100% recurrence and intracranial spread. Despite improvements in different therapeutic modalities, glioblastoma still bear an overall survival rate of 12-15 months (Oertel



et al., 2005; Salcman, 2001). On MRI/CT scans they usually present as a heterogeneously contrast enhancing lesion with central necrosis. With respect to treatment, radiotherapy has turned out to have the biggest impact on tumor control, time to progression, and overall survival in patients with malignant gliomas (Walker et al., 1978; 1980). To date, a multimodal approach has shown prolonged overall survival and improved quality of life (Brem et al., 1995; Stupp et al., 2005).

The extent of surgical removal of the contrast-enhancing mass has been correlated with improved overall survival (Stummer et al., 2006). However, surgical treatment is frequently limited due to the location and extension of the tumor into eloquent brain areas.

For deep-seated, non-resectable tumors, brachytherapy may theoretically be an interesting treatment alternative, affording low surgical risk and limited, local application of an effective radiation dose (Fig. 5). However, the fact that these tumors show highly invasive behavior limits this theoretically attractive approach.

Several larger studies were published predominantly in the 1980s and 1990s on brachytherapy for malignant gliomas as a primary treatment modality, or in combination with surgical removal, external beam radiation therapy (EBRT) and chemotherapy (Fernandez et al., 1995; Gutin et al., 1991; Kreth et al., 1994; Malkin et al., 1994; Scharfen et al., 1992; Sneed et al., 1998; Videtic et al., 2001; Wen et al., 1994; Zamorano et al., 1992). After thorough analysis, these studies have failed to show significant benefits in terms of time to progression (TTP) or overall survival (OS) in these patients, including patients in two randomized controlled trials (Laperriere et al., 1998; Selker et al., 2002). Furthermore, a relevant number of radiation-induced necroses requiring subsequent surgical resection were described, which is attributed to the predominantly high activity/high dose rate implantation regimens chosen due to the high proliferation rate of these tumors.

Notably, all these data were retrieved in an era prior to temozolomide, and were frequently based on CT rather than MRI findings, a fact that may further compound the derived conclusions. In the light of more recent data demonstrating the efficacy of surgery and radio-chemotherapy, brachytherapy for newly diagnosed malignant glioma does not represent a standard therapy and should not be favored over standard therapy. There is also no recent evidence supporting a combined approach with brachytherapy after surgical resection and in combination with EBRT.

Novel approaches combining brachytherapy with EBRT and chemotherapy for deep-seated, non-respectable tumors as a first line treatment are under clinical investigation, but data are not available yet.

As mentioned above, malignant gliomas show extremely high recurrence rates despite intensive and combined therapy. Therefore, the first studies on brachytherapy for intracranial tumors were performed on recurrent gliomas. In this particular setting, a series of permanent or temporary implants with different dose rates were reported to have variable outcomes in terms of overall survival and progression free survival (Gutin et al., 1984; 1987; Halligan et al., 1996; Julow et al., 2007; Kitchen et al., 1994; Larson et al., 2004; Patel et al., 2000; Ryken et al., 1994; Tselis et al., 2007). The published studies showed no evidence for a significant benefit from brachytherapy in recurrent glioblastoma, although probably a subset of patients may benefit from this treatment. Nevertheless, the method still may be applied as a salvage option in selected patients.

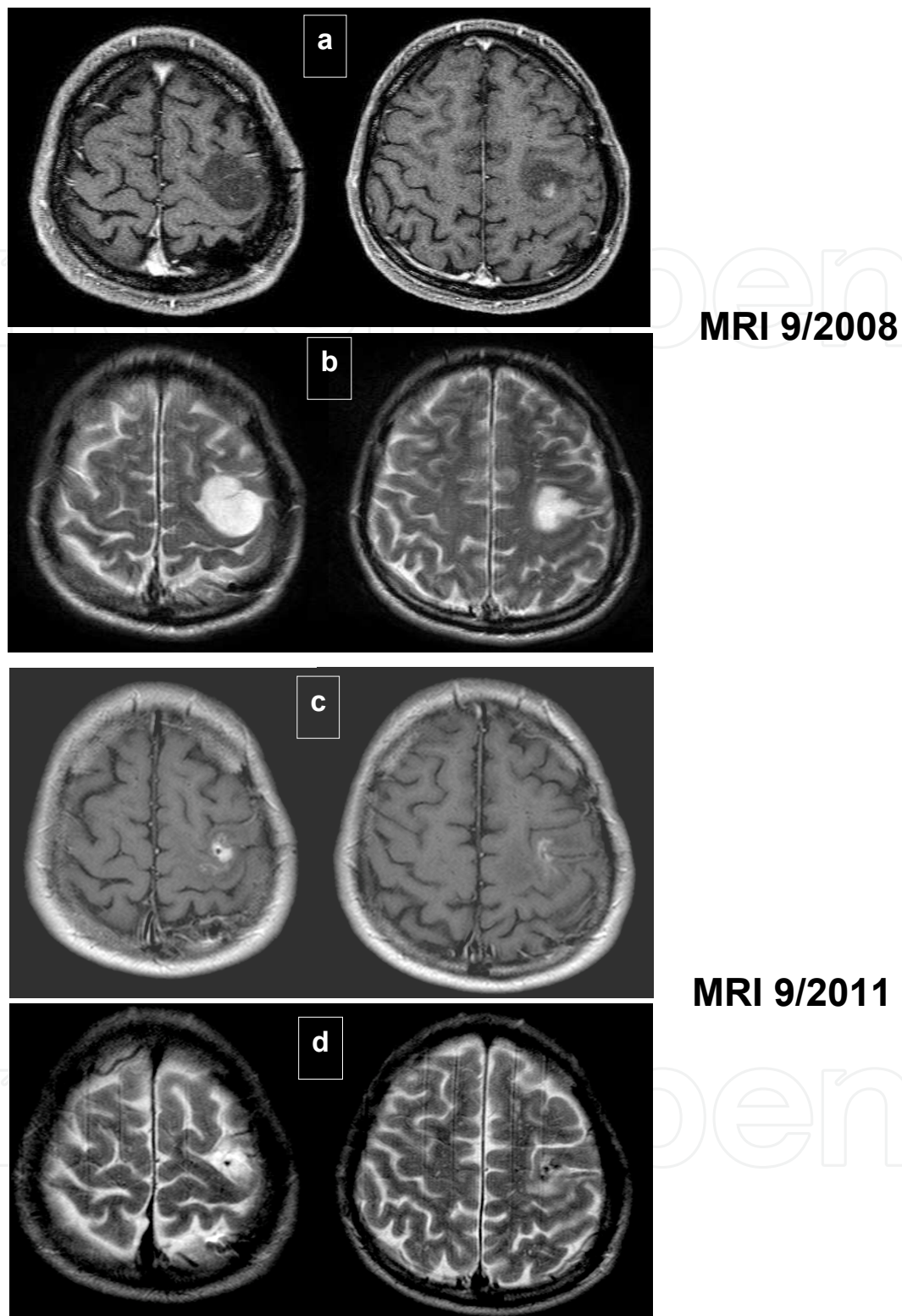


Fig. 5. MRI of a patient with anaplastic astrocytoma WHO III. MRI scans of an 41 year old patient diagnosed by stereotactic biopsy with an anaplastic astrocytoma WHO III in September 2008; a) T1- with contrast, b) T2-weighted images. According to our protocol he underwent stereotactic brachytherapy (I-125, 50 Gy cumulative tumor surface dose, permanent implantation) followed by 25 Gy EBRT boost. c, d) Follow-up MRI shows partial response of the tumor two years later. The patient's initial paresis of the right hand resolved completely.

## 5.2 SBT for low-grade gliomas (WHO I & II)

Considerable data exist for brachytherapeutic treatment of low-grade gliomas (WHO I pilocytic astrocytomas, WHO II astrocytomas, oligoastrocytomas and oligodendrogliomas), both in children and adults (Julow et al., 2007; Korinthenberg et al., 2010; Kreth et al., 1995; 2006; Mehrkens et al., 2004; Mundinger et al., 1991; Ostertag et al., 1993; Ruge et al., 2011a; Schatz et al., 1994; Suchorska et al., 2011).

The biology of these tumors diverges from malignant gliomas, with a much lower proliferation index and cellular density. They may occur in a diffuse manner, but are frequently diagnosed as rather well delineated, circumscribed lesions usually lacking contrast enhancement. For the latter form, brachytherapy has been applied in a large number of patients.

The role of surgery for these tumors remains to be clarified, although the tendency is a positive impact of gross total resection upon overall survival and time to progression (Frappaz et al., 2002; Nunez et al., 2009; Sanai et al., 2008).

The theoretical background for brachytherapy in low-grade gliomas is different from that in malignant gliomas. In accordance with the low proliferation index and presumed co-existence of still functioning healthy brain tissue within the tumor, most stereotactic neurosurgeons used low activity implants, either temporary or permanent, which also resulted in very low dose rates.

The reported 5- and 10-year survival rates ranged from 61% and 51% for grade II (with the exception of gemistocytic gliomas) up to 85% and 83% for pilocytic gliomas (Kreth et al., 1995; Ruge et al., 2011a; Suchorska et al., 2011). These data represent an at least equal outcome compared to other frequently used therapies such as surgery and EBRT (Rock, 1999). Furthermore, procedure-related risk is low (<5%), and long and short-term complications of brachytherapy using low dose rate implants are lower than those associated with tumor resection and/or EBRT (Kreth et al., 1995; Sarkaria et al., 1995; Shrieve et al., 1995).

Important to point out is the fact that SBT can be successfully combined with up-front neurosurgical partial resection of safely accessible portions of the tumor (Ruge et al., 2011a; Schnell et al., 2008; Suchorska et al., 2011).

As a consequence, according to data, brachytherapy may represent an adequate treatment option for WHO I & II gliomas. However, all these data were retrieved from retrospective analyses and large, controlled prospective trials are still lacking.

Pilocytic astrocytomas (WHO I) are the most benign lesions among intrinsic brain tumors. They most frequently occur in children and may be cured by total surgical removal. The underlying reason for this is their limited invasion into surrounding nervous tissue, which makes even histologically complete removal possible. Therefore in these tumors surgery is still considered the treatment of choice in cases where complete removal can be performed without impairment for the patient (Burkhard et al., 2003; Kayama, 1996; Morreale et al., 1997). As might be expected, incomplete resection reduced overall survival and time to progression significantly (Morreale et al., 1997).

However, pilocytic astrocytomas frequently occur in deep-seated locations adjacent to vital nervous structures, which can make removal of these tumors extremely dangerous or even



impossible. In such cases, brachytherapy may be an effective and safe treatment option, especially due to the histological setting mentioned above. Two recent studies of a large series of children treated with SBT for pilocytic astrocytoma reported five-year progression free survival of 91% and 92% (Korinthenberg et al., 2011; Ruge et al., 2011a). Treatment-related complications were as low as 5.4% (Ruge et al., 2011a). For extensive pilocytic astrocytomas, combined treatment approaches using surgery and brachytherapy have been used and are under clinical investigation (Peraud et al., 2007; Ruge et al., 2011a).

Again, it should be mentioned that these data concerning grade I gliomas are also retrospective, and there is no collected evidence based on prospective, controlled trials.

In summary, to date there is no evidence that patients with malignant gliomas benefit from brachytherapy, and this treatment should not be considered a first line option. However, all data were retrieved in an era before temozolomide, and molecular markers were available. Therefore, a subset of patients may still benefit from brachytherapy, and they need to be defined in future trials.

To a similar extent, data on low-grade gliomas have to be interpreted carefully, since no prospective controlled trials have been carried out, and data derives exclusively from retrospective studies. Nevertheless, time to progression and overall survival were equal or even superior to other treatment modalities, with a lower level of treatment-related morbidity and mortality, and shortened hospital stay. Furthermore, the use of SBT does not limit the use of EBRT in cases of tumor progression or relapse.

### 5.3 SBT for metastatic disease

Apart from intrinsic brain tumors, brachytherapy has been used as an adjuvant treatment modality for metastatic brain tumors. Although there are more, high level data concerning the primary treatment of brain metastasis (i.e. EBRT, radiosurgery, surgery), brachytherapy may be a treatment option for recurrent or *de novo* metastasis that cannot be treated by evidence-based conventional modalities.

In these cases it has been shown that brachytherapy may lead to good local tumor control with low morbidity and no treatment related mortality. Furthermore, due to the low surgical burden the procedure may even be performed on patients in a generally reduced condition as a salvage treatment (Bogart et al., 1999; Kreth et al., 1995; Ostertag et al., 1995; Ruge et al., 2011c). Furthermore, SBT allows histological diagnosis within the same surgical procedure, which is useful in newly occurring cerebral lesions without a proven systemic tumor, so-called CUP syndrome (CUP, cancer of unknown primary) or in cases of new or progressive local tissue changes after stereotactic radiosurgery (Ruge et al., 2011b)

In summary, defining a selection of patients who may benefit from brachytherapy will remain one of the most challenging tasks. In this context, brachytherapy may represent a useful tool in children and adults with deep-seated and non-resectionable WHO I and II tumors, as well as in patients with cerebral metastatic tumors in limited numbers, which are not amenable to other therapies (salvage treatment).

Only for low-grade gliomas WHO I and II, as well as metastatic brain tumors is there substantial evidence for a beneficial effect in terms of time to progression and overall survival. However, also for these populations larger, prospective, randomized and controlled

trials are still lacking, thus available data remain limited in their message due to their retrospective nature.

#### 5.4 Rare indications

The use of brachytherapy has been reported in atypical meningiomas, pineal gland tumors and medulloblastomas (Maarouf et al., 2010; El Majdoub et al., 2011; von Hoff et al., 2009; Ware et al., 2004).

For meningiomas, besides surgical removal, radio-surgery has gained considerable importance over the past few decades. In the light of technical advances in radiosurgical devices and more widespread availability, brachytherapy does not play a role in the management of intracranial meningiomas.

For medulloblastoma, a highly malignant tumor entity that primarily occurs in children, brachytherapy may only have its place as a salvage option due to the aggressively spreading nature of these tumors. There are no data showing any superiority of brachytherapy over evidence-based approaches such as surgery followed by radiation and chemotherapy.

#### 6. Conclusion

SBT represents a safe, minimally invasive and highly effective local treatment concept always aiming for the treatment of the entire tumor. It can be repeated and does not hinder or limit the use of EBRT in cases of further tumor progression. The possibility of combining SBT with partial tumor resection represents a feasible concept that has already been described in a subsets of patients. To further establish SBT as a ubiquitously available local treatment concept equal to open microneurosurgery or stereotactic radiosurgery, prospective randomized trials, especially for low-grade gliomas, are warranted.

#### 7. References

- Bauer-Kirpes B, Sturm V, Schlegel W, Lorenz WJ. Computerized optimization of 125I implants in brain tumours. *Int J Radiat Oncol Biol Phys.* 1988;14:1013–23.
- Bernstein M, Gutin PH. Interstitial irradiation of brain tumors: a review. *Neurosurgery.* 1981;9(6):741-50.
- Bogart JA, Ungureanu C, Shihadeh E et al. Resection and permanent I-125 brachytherapy without whole brain irradiation for solitary brain metastasis from non-small cell lung carcinoma. *J Neurooncol.* 1999;44(1): 53-57.
- Brem H, Piantadosi S, Burger PC, Walker M, Selker R, Vick NA, Black K, Sisti M, Brem S, Mohr G; Placebo-controlled trial of safety and efficacy of intraoperative controlled delivery by biodegradable polymers of chemotherapy for recurrent gliomas. The Polymer Brain Tumor Treatment Group. *Lancet.* 1995;345:1008–1012.
- Brem H, Ewend MG, Piantadosi S, Greenhoot J, Burger PC, Sisti M. The safety of interstitial chemotherapy with BCNU-loaded polymer followed by radiation therapy in the treatment of newly diagnosed malignant gliomas: phase I trial. *J Neurooncol.* 1995;26:111–123.

- Burkhard C, Di Patre PL, Schüler D, Schüler G, Yasargil G, Yonekawa Y, Lütolf UM, Kleihues P, Ohgaki H. A population-based study of incidence and survival rates in patients with pilocytic astrocytoma. *J Neurosurg.* 2003;98:1170-1174.
- Danlos H. Quelques considerations sur le traitement des dermatoses par le radium. *J Physiotherapie (Paris).* 1905;3: 98-106.
- El Majdoub F, Simon T, Hoevels M, Berthold F, Sturm V, Maarouf M. Interstitial brachytherapy using stereotactic implanted (125)iodine seeds for recurrent medulloblastoma. *Clin Oncol (R Coll Radiol).* 2011;23(8):532-7.
- Fernandez P, Zamorano L, Yakar D, Gaspar L, Warmelink C. Permanent Iodine-125 implants in the up-front treatment of malignant gliomas. *Neurosurgery.* 1995;36: 467-73.
- Frappaz D, Chinot O, Bataillard A, Ben Hassel M, Capelle L, Chanalet S, Chatel M, Figarella-Branger D, Guegan Y, Guyotat J, Hoang-Xuan K, Jouanneau E, Keime-Guibert F, Laforet C, Linassier C, Loiseau H, Maire JP, Menei P, Rousmans S, Sanson M, Sunyach MP. Summary version of the Standards, Options and Recommendations for the management of adult patients with intracranial glioma. *Br J Cancer.* 2002;89: 73-83.
- Frazier CH The effects of radium emanations upon brain tumors. *Surg Gyn Obstet.* 1920;31: 236-239.
- Gutin PH, Prados MD, Phillips TL, Wara WM, Larson DA, Leibel SA, Sneed PK, Levin VA, Weaver KA, Silver P, et al. External irradiation followed by an interstitial high activity iodine-125 implant "boost" in the initial treatment of malignant gliomas: NCOG study 6G-82-2. *Int J Radiat Oncol Biol Phys.* 1991;21(3):601-6.
- Gutin PH, Leibel SA, Wara WM, Choucair A, Levin VA, Philips TL, Silver P, Da Silva V, Edwards MS, Davis RL, et al. Recurrent malignant gliomas: survival following interstitial brachytherapy with high-activity iodine-125 sources. *J Neurosurg.* 1987;67(6):864-73. Review.
- Halligan JB, Stelzer KJ, Rostomily RC, Spence AM, Griffin TW, Berger MS. Operation and permanent low activity 125I brachytherapy for recurrent high-grade astrocytomas. *Int J Radiat Oncol Biol Phys.* 1996;35: 541-547.
- Heintz B H, Wallace R E, Hevezi J M. Comparison of I-125 sources used for permanent interstitial implants. *Med. Phys.* 2001;28: 671-82.
- Hirsch O. Die operative Behandlung von Hypophysentumoren: Nach endonasalen Methoden. *Arch Laryngol Rhinol.* 1912;26:529-686.
- Horsley V, Clarke RH. On a method of investigating the deep ganglia and tracts of the central nervous system (cerebellum). *Br Med J.* 1906;1799-1800.
- Hubbell J H, Seltzer S M. Tables of X-Ray Mass Attenuation Coefficients and Mass Energy-Absorption Coefficients from 1 keV to 20 MeV for Elements Z = 1 to 92 and 48 Additional Substances of Dosimetric Interest.  
<http://www.nist.gov/pml/data/xraycoef/index.cfm>, accessed 08-09-2011
- Hunsche S, Sauner D, Maarouf M, Poggenborg J, Lackner K, Sturm V, Treuer H. Intraoperative X-ray detection and MRI-based quantification of brain shift effects subsequent to implantation of the first electrode in bilateral implantation of deep brain stimulation electrodes. *Stereotact. Funct. Neurosurg.* 2009; 87: 322-9.



- Julow J, Viola A, Bálint K, Szeifert GT. Image fusion-guided stereotactic iodine-125 interstitial irradiation of inoperable and recurrent gliomas. *Prog Neurol Surg*. 2007;20:303-11.
- Kayama T, Tominaga T, Yoshimoto T. Management of pilocytic astrocytoma. *Neurosurg Rev*. 1996;19: 217-220.
- Kitchen ND, Hughes SW, Taub NA, Sofat A, Beaney RP, Thomas DG. Survival following interstitial brachytherapy for recurrent malignant glioma. *J Neurooncol*. 1994;18(1):33-9.
- Korinthenberg R, Neuburger D, Trippel M, Ostertag C, Nikkhah G. Long-term results of brachytherapy with temporary iodine-125 seeds in children with low-grade gliomas. *Int J Radiat Oncol Biol Phys*. 2011;79: 1131-8.
- Kreth FW, Warnke PC, Ostertag CB. Long-term follow-up results of 175 patients with malignant glioma. *Acta Neurochir (Wien)*. 1994;131(1-2):164-6.
- Kreth FW, Faist M, Warnke PC, Rossner R, Volk B, Ostertag CB. Interstitial radiosurgery of low-grade gliomas. *J Neurosurg*. 1995;82: 418-29.
- Kreth FW, Faist M, Rossner R, Birg W, Volk B, Ostertag CB. The risk of interstitial radiotherapy of low-grade gliomas. *Radiother Oncol*. 1997;43(3):253-60.
- Kreth FW, Faist M, Grau S, Ostertag CB. Interstitial 125 radiosurgery of supratentorial de novo WHO Grade 2 astrocytoma and oligoastrocytoma in adults: long-term results and prognostic factors. *Cancer*. 2006;106:1372-81.
- Laperriere NJ, Leung PMK, McKenzie S, Miloevic M, Wong S, Glen J, Pintilie M, Bernstein M. Randomized study of brachytherapy in the initial management of patients with malignant astrocytoma. *Int J Radiat Oncol Biol Phys*. 1998;41: 1005-1011.
- Larson DA, Suplica JM, Chang SM, Lamborn KR, McDermott MW, Sneed PK, Prados MD, Wara WM, Nicholas MK, Berger MS. Permanent iodine 125 brachytherapy in patients with progressive or recurrent glioblastoma multiforme. *Neuro Oncol*. 2004;6(2):119-26.
- Leksell, L. A stereotaxic apparatus for intracerebral surgery. *Acta Chir Scand*. 1949;99: 229-233.
- Maarouf M, El Majdoub F, Bührle C, Voges J, Lehrke R, Kocher M, Hunsche S, Treuer H, Sturm V. Pineal parenchymal tumors. Management with interstitial iodine-125 radiosurgery. *Strahlenther Onkol*. 2010;186(3):127-34.
- Malkin MG. Interstitial brachytherapy of malignant gliomas: the Memorial Sloan-Kettering Cancer Center experience. *Recent Results Cancer Res*. 1994;135: 117-25.
- McDermott MW, Sneed PK, Gutin PH. Interstitial brachytherapy for malignant brain tumors. *Semin Surg Oncol*. 1998;14(1):79-87.
- Morreale VM, Ebersold MJ, Quast LM, et al. Cerebellar astrocytoma: experience with 54 cases surgically treated at the Mayo Clinic, Rochester, Minnesota, from 1978 to 1990. *J Neurosurg*. 1997;87: 257-261.
- Mehrkens JH, Kreth FW, Muacevic A, Ostertag CB. Long term course of WHO grade II astrocytomas of the Insula of Reil after I-125 interstitial irradiation. *J Neurol*. 2004;251(12):1455-64.
- Mundinger, F. Eine einfache Methode der lokalisierten Bestrahlung von Großhirnswülsten mit radioaktivem Gold. *Münch Med Wschr*. 1956;98:23-25.
- Mundinger, F (1958) Beitrag zur Dosimetrie und Applikation von Radio-Tantal (182Ta) zur Langzeitbestrahlung von Hirnsgeschwülsten. *Fortsch. Röntgenstr*. 1958;89: 86-91.

- Mundinger F, Braus DF, Krauss JK, Birg W. Long-term outcome of 89 low-grade brain-stem gliomas after interstitial radiation therapy. *J Neurosurg.* 1991;75:740-6.
- Narabayashi H, Okuma R. Procain oil blocking of the globus pallidus for the treatment of rigidity and tremor of parkinsonisma (preliminary report). *Proc Jap Acad.* 1953;29: 134-137.
- National Nuclear Data Center, Brookhaven National Laboratory.  
<http://www.nndc.bnl.gov/chart/>, accessed 08-09-2011.
- Nath R, Anderson L L, Luxton G, Weaver K A, Williamson J F, Meigooni A S. Dosimetry of interstitial brachytherapy sources: recommendations of the AAPM Radiation Therapy Committee Task Group No. 43. *Med. Phys.* 1995;22:209-36.
- Nunez OM, Seol HJ, Rutka JT. The role of surgery in the management of intracranial gliomas: current concepts. *Indian J Cancer.* 2009;46(2):120-6.
- Oertel J, von Buttlar E, Schroeder HWS, Gaab MR Prognosis of gliomas in the 1970s and today. *Neurosurg Focus*, 2005;18:12.
- Ostertag CB. Brachytherapy--interstitial implant radiosurgery. *Acta Neurochir Suppl (Wien).* 1993;58:79-84.
- Ostertag CB, Kreth FW. Interstitial iodine-125 radiosurgery for cerebral metastases. *Br J Neurosurg.* 1995;9:593-603.
- Patel S, Breneman JC, Warnick RE, Albright RE Jr, Tobler WD, van Loveren HR, Tew JM Jr. Permanent iodine-125 interstitial implants for the treatment of recurrent glioblastoma multiforme. *Neurosurgery.* 2000;46: 1123-8.
- Patterson R. A dosage system for gamma ray therapy: Part I. *Br J Radiol* 1934;7:592-612
- Peraud A, Goetz C, Siefert A, Tonn JC, Kreth FW. Interstitial iodine-125 radiosurgery alone or in combination with microsurgery for pediatric patients with eloquently located low-grade glioma: a pilot study. *Childs Nerv Syst.* 2007;23(1):39-46. Epub 2006 Sep 14.
- Picard C, Olivier A, Bertrand G. The first human stereotaxic apparatus. The contribution of Aubrey Mussen to the field of stereotaxis. *J Neurosurg.* 1983;59(4):673-6.
- Riechert T, Mundinger F. Beschreibung und Anwendung eines Zielgerätes für stereotaktische Hirnoperationen. *Acta Neurochir (Wien).* 1955;3: 308-337.
- Ruge MI, Simon T, Suchorska B, Lehrke R, Hamisch C, Koerber F, Maarouf M, Treuer H, Berthold F, Sturm V, Voges J. Stereotactic Brachytherapy With Iodine-125 Seeds for the Treatment of Inoperable Low-Grade Gliomas in Children: Long-Term Outcome. *J Clin Oncol.* 2011a.
- Ruge MI, Kickingreder P, Grau S, Hoevels M, Treuer H, Sturm V. Stereotactic biopsy combined with stereotactic (125)iodine brachytherapy for diagnosis and treatment of locally recurrent single brain metastases. *J Neurooncol.* 2011b;105:109-18.
- Ruge MI, Suchorska B, Maarouf M, Runge M, Treuer H, Voges J, Sturm V. Stereotactic 125iodine brachytherapy for the treatment of singular brain metastases: closing a gap? *Neurosurgery.* 2011c;68:1209-18.
- Ruge MI, Kocher M, Maarouf M, Hamisch C, Treuer H, Voges J, Sturm V. Comparison of stereotactic brachytherapy (125 iodine seeds) with stereotactic radiosurgery (LINAC) for the treatment of singular cerebral metastases. *Strahlenther Onkol.* 2011d;187:7-14.

- Ryken TC, Hitchon PW, VanGilder JC, Wen BC, Jani S. Interstitial brachytherapy versus cytoreductive surgery in recurrent malignant glioma. *Stereotact Funct Neurosurg.* 1994;63(1-4):241-5.
- Salcman, M, Glioblastoma multiforme and anaplastic astrocytoma, In: Kaye AH, Laws ER Jr, ed *Brain Tumors* London Churchill Livingstone, 2001;493-523.
- Sanai N, Berger MS. Glioma extent of resection and its impact on patient outcome. *Neurosurgery.* 2008;62:753-64.
- Sarkaria JN, Mehta MP, Loeffler JS, Buatti JM, Chappell RJ, Levin AB, Alexander E 3rd, Friedman WA, Kinsella TJ. Radiosurgery in the initial management of malignant gliomas: survival comparison with the RTOG recursive partitioning analysis. Radiation Therapy Oncology Group. *Int J Radiat Oncol Biol Phys.* 1995;32(4):931-41.
- Scharfen CO, Sneed PK, Wara WM, Larson DA, Phillips TL, Prados MD, Weaver KA, Malec M, Acord P, Lamborn KR et al. High activity iodine-125 interstitial implant for gliomas. *Int J Radiat Oncol Biol Phys.* 1992;24:583-591.
- Schätz CR, Kreth FW, Faist M, Warnke PC, Volk B, Ostertag CB. Interstitial 125-iodine radiosurgery of low-grade gliomas of the insula of Reil. *Acta Neurochir (Wien).* 1994;130:80-9.
- Selker RG, Shapiro WR, Burger P, Blackwood MS, Arena VC, Gilder JC, Malkin MG, Mealey JJ Jr, Neal JH, Olson J, Robertson JT, Barnett GH, BloomWeld S, Albright R, Hochberg FH, Hiesiger E, Green S. The Brain Tumor Cooperative Group NIH Trial 87-01: a randomized comparison of surgery, external radiotherapy, and carmustine versus surgery, interstitial radiotherapy boost, external radiation therapy, and carmustine. *Neurosurgery.* 2002;51:343-355.
- Shrieve DC, Loeffler JS. Advances in radiation therapy for brain tumors. *Neurol Clin.* 1995;13(4):773-93. Review.
- Schnell O, Schöller K, Ruge M, Siefert A, Tonn JC, Kreth FW. Surgical resection plus stereotactic 125I brachytherapy in adult patients with eloquently located supratentorial WHO grade II glioma - feasibility and outcome of a combined local treatment concept. *J Neurol.* 2008;255(10):1495-502.
- Schulder M, Black PM, Shrieve DC, Alexander E 3rd, Loeffler JS. Permanent low-activity iodine-125 implants for cerebral metastases. *J Neurooncol.* 1997, 33: 213-21. Schurr PH, Merrington WR. The Horsley-Clarke stereotaxic apparatus. *Br J Surg.* 1978;65(1):33-6.
- Spiegel EA, Wycis HT, Marks M, Lee AJ. Stereotaxic apparatus for operations on the human brain. *Science.* 1947;106: 349-350.
- Sneed PK, StauVer PR, McDermott MW, Diederich CJ, Lamborn KR, Prados MD, Chang S, Weaver KA, Spry L, Malec MK, Lamb SA, Voss B, Davis RL, Wara WM, Larson DA, Phillips TL, Gutin PH. Survival benefit of hyperthermia in a prospective randomized trial of brachytherapy boost & hyperthermia for glioblastoma multiforme. *Int J Radiat Oncol Biol Phys.* 1998;40:287-295.
- Stummer W, Pichlmeier U, Meinel T, et al. Fluorescence-guided surgery with 5-aminolevulinic acid for resection of malignant glioma: a randomised controlled multicentre phase III trial. *Lancet Oncol.* 2006;7:392-401.




- Stupp R, Mason WP, van den Bent MJ, Weller M, Fisher B, Taphoorn MJ, et al. Radiotherapy plus concomitant and adjuvant temozolomide for glioblastoma. *N Engl J Med*. 2005;352:987-996.
- Suchorska B, Ruge M, Treuer H, Sturm V, Voges J. Stereotactic brachytherapy of low-grade cerebral glioma after tumor resection. *Neuro Oncol*. 2011;13:1133-42. Epub 2011 Aug 25.
- Talairach J, Ruggiero G, Aboulker J, David M. A method of treatment of inoperable brain tumours by stereotaxic implantation of radioactive gold. *Br J Radiol*. 1955;28: 62-74.
- Tselis N, Kolotas C, Birn G, Roddiger S, Filipowicz I, Kontova M, Fountzilias G, Selviaridis P, Baltas D, Heyd R, Anagnostopoulos G, Zamboglou N (2007) CT-guided interstitial HDR brachytherapy for recurrent glioblastoma multiforme. Long-term results. *Strahlenther Onkol*. 2007;183:563-570.
- Treuer H, Hunsche S, Hoevels M, Luyken K, Maarouf M, Voges J, V Sturme. The influence of head frame distortions on stereotactic localization and targeting. *Phys. Med. Biol*. 2004; 49: 3877-87.
- Treuer H, Klein D, Maarouf M, Lehrke R, Voges J, Sturm V. Accuracy and conformity of stereotactically guided interstitial brain tumor therapy using I-125 seeds. *Radiother. Oncol*. 2005; 77(2):202-9.
- Videtic GM, Gaspar LE, Zamorano L, et al.: Implant volume as a prognostic variable in brachytherapy decisionmaking for malignant gliomas stratified by the RTOG recursive partitioning analysis. *Int J Radiat Oncol Biol Phys*. 2001;51:963-968.
- Voges J, Sturm V. Interstitial irradiation with stereotactically implanted I-125 seeds for the treatment of cerebral glioma. *Crit Rev Neurosurg*. 1999;9(4):223-233.
- von Hoff K, Hinkes B, Gerber NU, Deinlein F, Mittler U, Urban C, Benesch M, Warmuth-Metz M, Soerensen N, Zwiener I, Goette H, Schlegel PG, Pietsch T, Kortmann RD, Kuehl J, Rutkowski S. Long-term outcome and clinical prognostic factors in children with medulloblastoma treated in the prospective randomised multicentre trial HIT'91. *Eur J Cancer*. 2009;45(7):1209-17. Epub 2009 Feb 26.
- Walker MD, Alexander E Jr, Hunt WE, MacCarty CS, Mahaley MS Jr, Mealey J Jr, Norrell HA, Owens G, Ransohoff J, Wilson CB, Gehan EA, Strike TA. Evaluation of BCNU and/or radiotherapy in the treatment of anaplastic gliomas. A cooperative clinical trial. *J Neurosurg*. 1978;49(3):333-43.
- Walker MD, Green SB, Byar DP, Alexander E Jr, Batzdorf U, Brooks WH, et al. Randomized comparisons of radiotherapy and nitrosoureas for the treatment of malignant glioma after surgery. *N Engl J Med*. 1980;303:1323-1329.
- Ware ML, Larson DA, Sneed PK, Wara WW, McDermott MW. Surgical resection and permanent brachytherapy for recurrent atypical and malignant meningioma. *Neurosurgery*. 2004;54(1):55-63.
- Wen PY, Alexander E 3rd, Black PM, Fine HA, Riese N, Levin JM, Coleman CN, Loeffler JS: Long term results of stereotactic brachytherapy used in the initial treatment of malignant glioblastoma. *Cancer*. 1994;73: 3029-3036.
- Williamson J F, Butler W, DeWerd L A, Saiful Huq M, Ibbott G S, Li Z, Mitch M G, Nath R, Rivard M J, Todor D. Recommendations of the American Association of Physicists in Medicine regarding the Impact of Implementing the 2004 Task Group 43 Report on Dose Specification for 103Pd and 125I Interstitial Brachytherapy. *Med Phys*. 2005;32:1424-39.

Zamorano L, Yakar D, Dujovny M, Sheehan M, Kim J. Permanent iodine-125 implant and external beam radiation therapy for the treatment of malignant brain tumors. *Stereotact Funct Neurosurg.* 1992;59:183-92.

IntechOpen

IntechOpen



## **Brachytherapy**

Edited by Dr. Kazushi Kishi

ISBN 978-953-51-0602-9

Hard cover, 128 pages

**Publisher** InTech

**Published online** 25, April, 2012

**Published in print edition** April, 2012

Importance of brachytherapy is currently increasing in cancer therapy. In brachytherapy each treatment is best fitted by physician's hand, and appropriate arrangement and selection of radiation sources facilitates the fitting. This book is full of essences to make a breakthrough in radiation oncology by brachytherapy. I hope this book will encourage all people related. Contents 1: problem of currently popular dosimetric method; 2: Monte Carlo dose simulation of ruthenium-106/rhodium-106 eyes applicators; 3. Progress in Californium-252 neutron brachytherapy; 4. Clinical aspect of endobronchial brachytherapy in central airway tumor obstruction; 5. Review from principle and techniques of Iodine-125 production at nuclear reactor plant to their clinical practice in prostate cancer treatment; 6. Stereotactic Brachytherapy for Brain Tumors using Iodine-125 seed; 7. A brachytherapy procedure with organ-sparing hyaluronate gel injection for safe and eradicated reirradiation.

### **How to reference**

In order to correctly reference this scholarly work, feel free to copy and paste the following:

Maximilian I. Ruge, Stefan Grau, Harald Treuer and Volker Sturm (2012). Stereotactic Brachytherapy for Brain Tumors, Brachytherapy, Dr. Kazushi Kishi (Ed.), ISBN: 978-953-51-0602-9, InTech, Available from: <http://www.intechopen.com/books/brachytherapy/stereotactic-brachytherapy-for-brain-tumors>

**INTech**  
open science | open minds

### **InTech Europe**

University Campus STeP Ri  
Slavka Krautzeka 83/A  
51000 Rijeka, Croatia  
Phone: +385 (51) 770 447  
Fax: +385 (51) 686 166  
[www.intechopen.com](http://www.intechopen.com)

### **InTech China**

Unit 405, Office Block, Hotel Equatorial Shanghai  
No.65, Yan An Road (West), Shanghai, 200040, China  
中国上海市延安西路65号上海国际贵都大饭店办公楼405单元  
Phone: +86-21-62489820  
Fax: +86-21-62489821



© 2012 The Author(s). Licensee IntechOpen. This is an open access article distributed under the terms of the [Creative Commons Attribution 3.0 License](https://creativecommons.org/licenses/by/3.0/), which permits unrestricted use, distribution, and reproduction in any medium, provided the original work is properly cited.

IntechOpen

IntechOpen