

# We are IntechOpen, the world's leading publisher of Open Access books Built by scientists, for scientists

6,900

Open access books available

186,000

International authors and editors

200M

Downloads

Our authors are among the

154

Countries delivered to

TOP 1%

most cited scientists

12.2%

Contributors from top 500 universities



WEB OF SCIENCE™

Selection of our books indexed in the Book Citation Index  
in Web of Science™ Core Collection (BKCI)

Interested in publishing with us?  
Contact [book.department@intechopen.com](mailto:book.department@intechopen.com)

Numbers displayed above are based on latest data collected.  
For more information visit [www.intechopen.com](http://www.intechopen.com)



# Ultrasonography of the Stomach

Laurence Trahair and Karen L. Jones

*University of Adelaide, Discipline of Medicine, Royal Adelaide Hospital  
Adelaide, South Australia,  
Australia*

## 1. Introduction

Ultrasound is a versatile imaging modality with the potential to provide much quantitative and qualitative information in both clinical and research settings. Ultrasound has the capacity to provide both anatomical and physiological information in real-time, and also offers images with high temporal and spatial resolution. Furthermore, ultrasound is relatively non-invasive and is not associated with a radiation burden to the patient. These advantages, as well as the capacity to provide this information in a simple, fast and pain free examination has meant that there has been a huge increase in the number of applications of ultrasound since its introduction in the early 1960s. It was not until the 1980s that ultrasonographic assessment of the stomach and its contents were explored, and, since that time, a number of new techniques have been developed which can provide more comprehensive information in a single ultrasonographic exam.

This chapter will describe a number of these techniques, specifically, ultrasound imaging of the fundus and antrum (including area and volume), 2D and 3D assessment of gastric emptying, measurement of antropyloroduodenal motility and transpyloric flow as well as gastric strain rate imaging. Within each of these sections both clinical and research applications will be discussed. Strengths and limitations of the techniques, as well as comparisons with other methodological or diagnostic techniques will also be addressed.

## 2. Scanning techniques

Generally, no specific patient preparation is necessary (Nylund *et al.*, 2009). Fasting for a period of time prior to the examination will minimise the fluid and air present in the stomach and small intestine, resulting in better quality images (Folvik *et al.*, 1999; Nylund *et al.*, 2009), this is, however, not strictly necessary. If air is present, the ultrasonographer can apply gentle pressure with the transducer to move the air away from the area being scanned (Tarjan *et al.*, 2000). Additionally, it is important to minimise respiration effects when scanning, and this can be achieved by taking images at a constant point throughout the respiration cycle, or by asking patients to hold their breath as images are acquired (Jones *et al.*, 1997).

The patient should be positioned comfortably, in a supine position; however, measurement of gastric emptying (with both 2D and 3D ultrasound) should be performed seated or

semirecumbent position, to allow better visualisation of the entire stomach, and to reflect gastric emptying in a physiological situation (Hveem *et al.*, 1996; Gilja *et al.*, 1997a; Gilja *et al.*, 2005). Scanning should be performed with a 3.5 – 5 MHz transducer, allowing for complete visualisation of the area of interest (Nylund *et al.*, 2009).

The transducer should be placed on the surface of the skin in such a way as to acquire an image of the entirety of the region being examined, as this varies from individual to individual, and is easily modified throughout the exam. This location is normally in the region of the epigastrium, down to the subcostal margins, or over the umbilicus (Hveem *et al.*, 1996; Gilja *et al.*, 1997a; Gilja *et al.*, 2005).

The use of colour and power Doppler should be considered, as well as duplex ultrasonography. These can add additional anatomical information, particularly relating to the vasculature, which can be impossible to see with B-mode ultrasonography (Nylund *et al.*, 2009).

### 3. Imaging of the antrum

The way in which the stomach regulates the emptying of food to optimise digestion and absorption is complex. The function of the proximal stomach is generally recognised as a storage facility relaxing to accommodate food which is then passed down into the antrum where it is ground down into particles <1mm in size before emptying into the small intestine. Several techniques have been used to provide insights into the mechanisms regulating this process. Ultrasonographic imaging of the antrum can be used to provide information relating to the volume or area of the distal stomach both in the fasted state and postprandially, thereby providing information about distension of this region.

Imaging should ideally be performed with the subject seated, and the transducer positioned vertically to obtain a sagittal image of the antrum, with the superior mesenteric vein and the abdominal aorta in a longitudinal section (Hveem *et al.*, 1996) (Figure 1). Images should be taken at the end of inspiration to minimise the effects of the normal motion of the stomach which occurs with regular breathing (Jones *et al.*, 1997). The area of the antrum is defined by a region of interest drawn around the cross section of the antrum and is expressed in cm<sup>2</sup>.

The use of ultrasound to assess the antrum is appealing in both the clinical and research setting due to the ease and simplicity with which it can be applied, especially in favour of other imaging modalities that are more expensive and time consuming.

The ability to assess gastric distension is of particular relevance in patients with diabetes mellitus and functional dyspepsia in whom the prevalence of upper gastrointestinal symptoms is substantial (Hausken & Berstad, 1992; Undeland *et al.*, 1996). Studies using 2D ultrasound have demonstrated in these patient populations that antral area is increased; both in the fasted and postprandial state (Hausken & Berstad, 1992; Undeland *et al.*, 1996).

The use of ultrasound to assess gastric distension can also be applied to evaluate mechanisms relating to appetite regulation. For example, in both healthy young (Jones *et al.*, 1997), and older (Sturm *et al.*, 2004) subjects, antral distension (as measured by antral area on a 2D ultrasound image) following a meal has been shown to correlate with perceptions of fullness and energy intake indicating the importance of antral distension in appetite regulation (Figure 2).

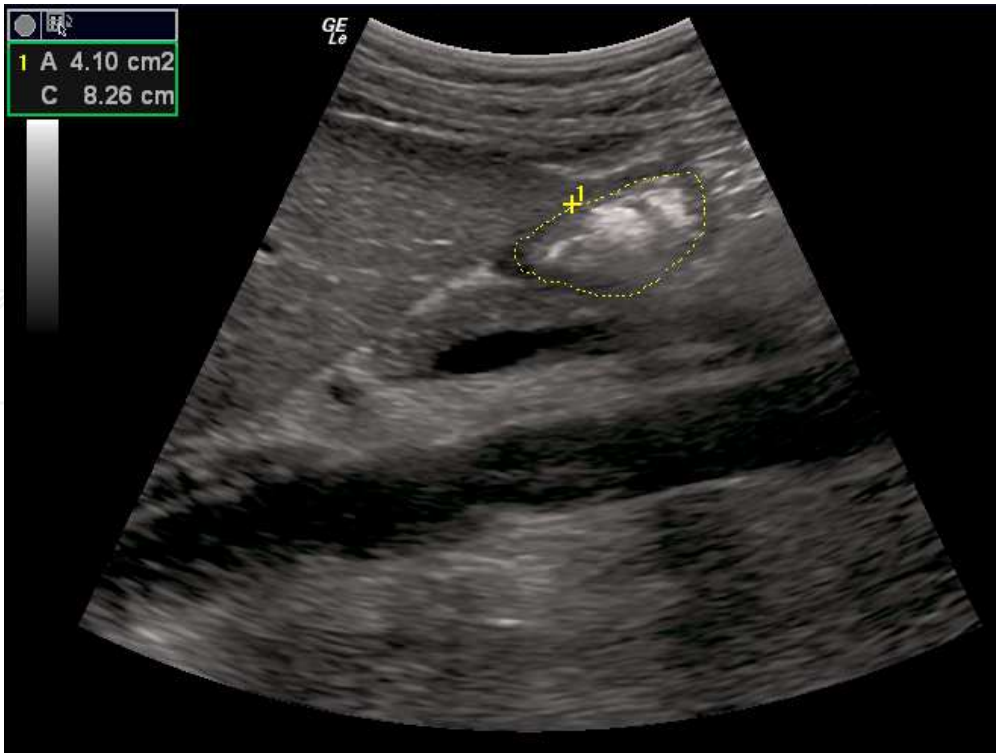


Fig. 1. 2D image of the antrum, with area calculation. The abdominal aorta and superior mesenteric vein are visible in the longitudinal section of the image.

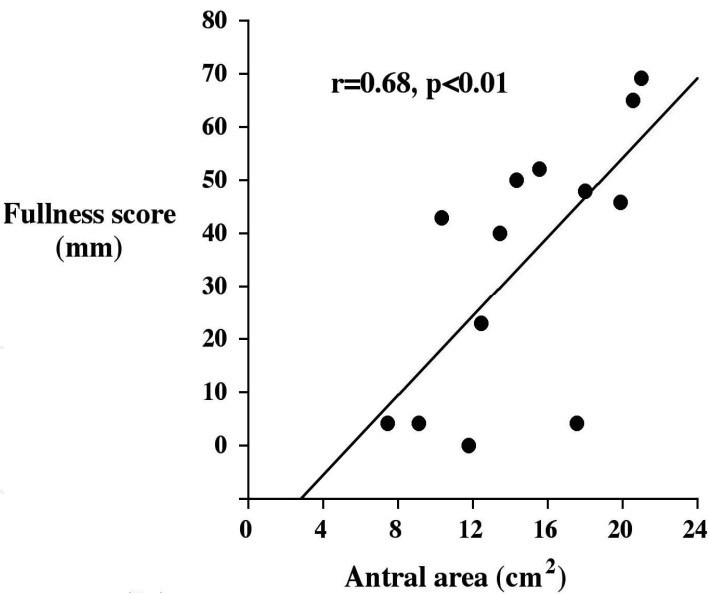


Fig. 2. Relationship between fullness score as measured by a visual questionnaire and antral area, measured by 2D ultrasound, 45 minutes after the consumption of a high-nutrient dextrose drink (75g dextrose dissolved in 350mL water) (n=14 healthy, young volunteers). (Am. J. Clin. Nutr. (1997;66:127-32), American Society for Nutrition).

Ultrasonographic assessment of the antrum has also been used pre-operatively to assess the likelihood of perioperative complications arising from the aspiration of gastric contents during surgery (Perlas *et al.*, 2009). Physicians acquiring a single image of the antrum were

able to distinguish between a fasted and fed stomach 2 hours following the ingestion of either a solid or a liquid meal (Bouvet *et al.*, 2009).

#### 4. Imaging of the proximal stomach

Ultrasonographic imaging of the proximal stomach was first described in 1995 (Gilja *et al.*, 1995). With the patient seated, leaning backwards slightly, the transducer is placed on the epigastrium, by the left subcostal margin, and tilted cranially (Gilja *et al.*, 2007). Two images are acquired, the first being a sagittal slice of the proximal stomach, with the left renal pelvis in the longitudinal section of the image, using the left lobe of the liver and pancreas as anatomical landmarks. The area of the fundus is defined as a region from the top margin of the fundus to a point 7 cm downward, along the axis of the stomach (Gilja *et al.*, 1995). A second image, taken in the oblique plane can be acquired with the transducer in the same location. The top margin of the fundus should remain clearly visible in this image. The diameter of the fundus can be calculated on this image and is defined as the maximum diameter of the fundus kept within 7 cm along the axis of the proximal stomach (Gilja *et al.*, 1995). Proximal stomach volume can be derived using these measurements. In addition to measurements of diameter, area and volume, this ultrasound technique also enables the calculation of the initial emptying fractions of the proximal stomach, if imaging is performed soon after ingestion of a meal (Gilja *et al.*, 1995).

Imaging of the proximal stomach and estimation of fundic accommodation was traditionally performed with either a gastric barostat or scintigraphy. Currently, the 'gold standard' for assessment of proximal stomach accommodation is the use of a barostat device, a thin, plastic, inflatable balloon attached to an orogastric catheter, which, when positioned correctly and inflated in the proximal stomach, can measure gastric wall relaxation, and from this the tone of the muscle can be inferred (Azpiroz & Malagelada, 1987). Unlike ultrasonographic assessment, the barostat technique only measures the volume of a sealed balloon, therefore it offers no information about the size or true muscle tone of the stomach (Szarka & Camilleri, 2009). The barostat device can be uncomfortable, is highly invasive and has been shown to influence gastric motor patterns (Moragas *et al.*, 1993; Parys *et al.*, 1993). The barostat bag has also been shown to cause dilation of the antrum due to its placement, which may affect gastric emptying (Mundt *et al.*, 2002), an effect clearly overcome with ultrasound. Ultrasound enables the accommodation of the proximal stomach to be assessed with high inter- and intra-observer agreement (De Schepper *et al.*, 2004) with the added advantage of also assessing gastric emptying, antral motility and transpyloric flow, if desired, in a single examination (De Schepper *et al.*, 2004).

Scintigraphic single photon emission computed tomography (SPECT) scanning has the capacity to non-invasively provide information about gastric volume (Vasavid *et al.*, 2010), without interfering with gastric motor patterns. The technique requires intravenous administration of radioactive technetium pertechnetate which is taken up by the gastric mucosa to facilitate imaging. Gastric accommodation can be assessed using this technique in a reproducible fashion, however, there is evidence that SPECT is not very sensitive in detecting fundic relaxation when compared to the gastric barostat (van den Elzen *et al.*, 2003). Ultrasonographic imaging of the proximal stomach has similar advantages to that of imaging of the antrum, in that its cost, absence of radiation burden, accessibility and simplicity makes it more approachable than other imaging modalities. In addition,



ultrasound imaging is performed in the sitting position, which is more reflective of the 'physiological' way one would be positioned when eating as opposed to SPECT, which requires the patient to be scanned in the supine position (De Schepper *et al.*, 2004; Hausken & Gilja, 2006).

While ultrasound has several advantages over the barostat technique, there remains some controversy as to whether measurements acquired by ultrasound, or even SPECT, can be compared directly to those acquired with a barostat device. The barostat, when inflated, can adjust to the changes in gastric pressure by adjusting the intrabag volume, therefore, changes in intrabag volume are said to reflect changes in muscle tone (Azpiroz & Malagelada, 1987). Ultrasound and scintigraphic imaging methods, however, measure the physical size of the proximal stomach, which can only be used to infer movements of contraction and relaxation of the stomach (Hausken & Gilja, 2006). Whilst this information is not directly comparable, both changes in gastric volume, as well as the contraction and relaxation of the stomach provide valuable information about disordered motility (Hausken & Gilja, 2006).

Ultrasonographic imaging of the fundus has largely been used in the research setting while clinical applications of this type of imaging remain to be explored. Patients with functional dyspepsia and diabetes studied with ultrasound have demonstrated reduced proximal stomach accommodation (Gilja *et al.*, 1996b; Undeland *et al.*, 1998) when compared to healthy subjects. In patients with functional dyspepsia, glyceryl trinitrate (an exogenous donor of NO, a key neurotransmitter in mediating the relaxation of the smooth muscle of the stomach), administered sublingually has been shown to improve the accommodation of the proximal stomach, as measured by ultrasound, and reduce the postprandial symptoms associated with this condition (Gilja *et al.*, 1997b). In patients with reflux esophagitis, the area of the fundus has been shown to be significantly greater after a meal when compared to healthy controls, and these patients experienced greater epigastric fullness (Tefera *et al.*, 2001; Tefera *et al.*, 2002).

## 5. 2D assessment of gastric emptying

Scintigraphy is currently the 'gold standard' for clinical measurement of gastric emptying (Collins *et al.*, 1983; Collins *et al.*, 1991); however, it requires access to expensive equipment and carries a radiation burden to the patient and operator. Other techniques involve the use of an orogastric catheter, which is invasive and associated with a high degree of discomfort (Sheiner, 1975), or stable radioisotopes such as C<sup>14</sup>-octanoic acid, which are not as readily available as ultrasound and requires specialised equipment to analyse (Vantrappen, 1994). Ultrasonography of the stomach has the ability to overcome these disadvantages. It provides an indirect measurement of gastric emptying by quantifying changes in antral area over time (Holt *et al.*, 1980; Bolondi *et al.*, 1985; Holt *et al.*, 1986).

The skills to acquire 2D ultrasound images are relatively easy to learn from an experienced operator. To optimise measurement, the subject should remain seated in approximately the same position for the duration of the examination, and ultrasound images of antral area should be taken at consistent times through the respiration cycle (Jones *et al.*, 1997). A variety of both liquid and semi-solid test meals, including low-nutrient beef soup, beans, pasta, orange juice and dextrose (Holt *et al.*, 1980; Bolondi *et al.*, 1985; Holt *et al.*, 1986; Brown

*et al.*, 1993; Benini *et al.*, 1994; Hveem *et al.*, 1996) have been used to assess gastric emptying. The rate of gastric emptying, or gastric emptying half time (T50), defined as the time it takes for 50% of a given meal to empty from the stomach, can be calculated (Collins *et al.*, 1983) and the retention of a meal, expressed as a percentage of the total meal, at any given time, is defined as in equation (1) below.

$$\text{Retention (\%)} = \frac{AA(t) - AA(f)}{AA(\text{max}) - AA(f)} \times 100 \tag{1}$$

Where AA(t) is the antral area measured at any given time point, AA(f) is the fasting antral area and AA(max) is the maximum antral area recorded after drink ingestion (Hveem *et al.*, 1996).

Ultrasonographic assessment of gastric emptying has been validated against scintigraphy. Studies comparing emptying of a low nutrient beef soup (Holt *et al.*, 1986) and high nutrient dextrose drink (Hveem *et al.*, 1996; Jones *et al.*, 1997) demonstrate good correlation and agreement between techniques (Figure 3).

Studies using 2D ultrasonography in the research setting are particularly attractive as several measurements can be taken over a given time frame or in a single exam. Research studies have shown an overall delayed rate of gastric emptying in functional dyspepsia, with occasional, more rapid initial emptying (Lunding *et al.*, 2006) and an overall delayed rate of gastric emptying in patients with longstanding type 1 (Darwiche *et al.*, 1999) and type 2 (Bian *et al.*, 2011) diabetes.

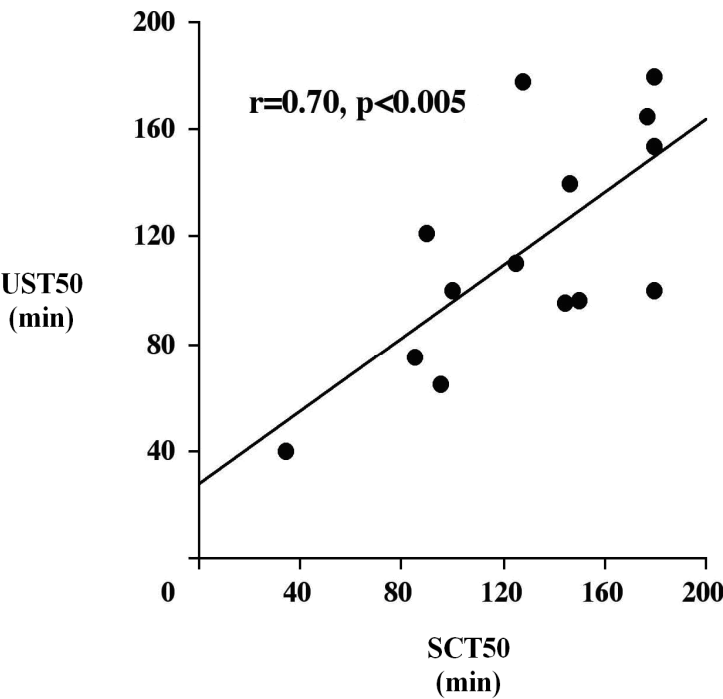


Fig. 3. Relationship between the gastric emptying half times (T50) of a high-nutrient dextrose drink (75g dextrose dissolved in 350mL water) as measured by 2D ultrasound and scintigraphy (n=14 healthy, young volunteers). (Am. J. Clin. Nutr. (1997;66:127-32), American Society for Nutrition).

Despite numerous advantages, 2D ultrasonographic assessment of gastric emptying is associated with some limitations. It is not a direct measure of gastric emptying but rather an assessment of changes in antral area (Holt *et al.*, 1980; Bolondi *et al.*, 1985; Holt *et al.*, 1986). Additionally, it does not take into account the full geometrical shape or distribution of the contents of the stomach (Gilja *et al.*, 2005).

### 6. 3D assessment of gastric emptying

Initially, assessment of gastric emptying with ultrasound was limited to the abovementioned 2D technique; however, 3D examinations of the stomach, including the emptying and distribution of its contents, have been developed with the increasing availability of suitable technology (Gilja *et al.*, 2005).

The concept was originally pioneered in the 1980s (Snyder *et al.*, 1986), and further developed by the Bergen group in Norway. 3D volume estimation of organs by ultrasound was originally only possible with a transducer mechanically tilted through 90° with a motor device whilst scanning continuously, with the ultrasonographic data transferred to a separate workstation for 3D reconstruction and processing (Hausken *et al.*, 1994; Gilja *et al.*, 1996a; Thune *et al.*, 1996; Gilja *et al.*, 1998). Obviously limited by the pre-determined scanning range and position of the sensor, a magnetometer based position and orientation measurement (POM) device was developed (Detmer *et al.*, 1994) providing precision mapping of points in space (Detmer *et al.*, 1994) and was validated as an accurate method of volume estimation (Hodges *et al.*, 1994; Matre *et al.*, 1999).

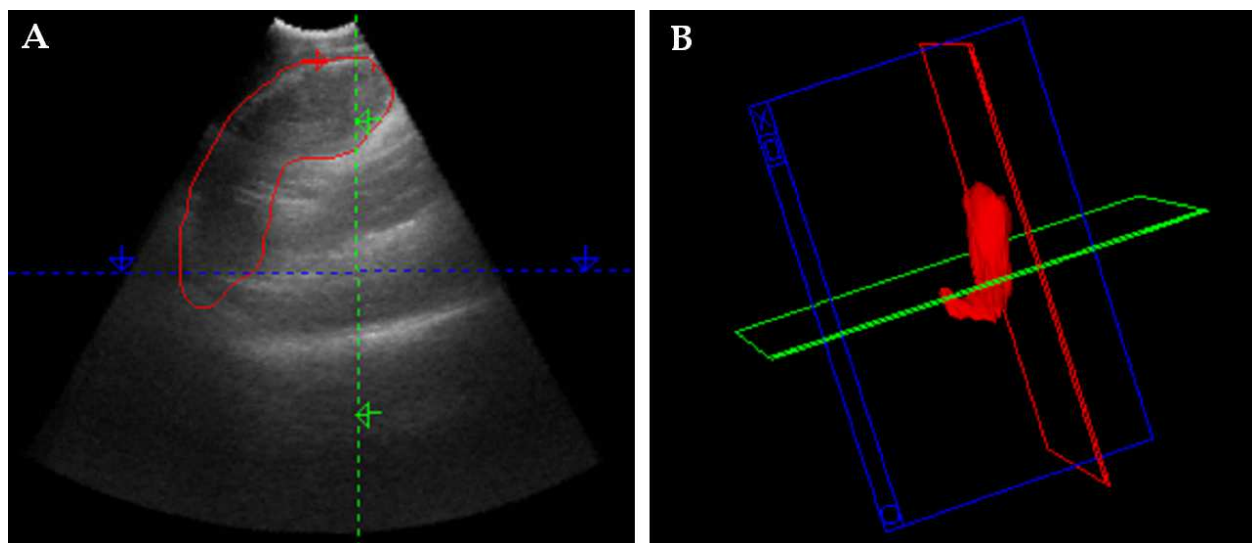


Fig. 4. 3D ultrasound to measure gastric emptying (A) a region of interest drawn around the stomach (B) reconstructed volumetric image of the stomach.

A series of sagittal slices are acquired with a continuous sweeping motion towards the midline, beginning with the transducer at the left subcostal margin, tilted cranially, to image the most proximal part of the stomach, through to the distal stomach and ceasing at the gastroduodenal junction (Gilja *et al.*, 1997a; Gilja *et al.*, 2005). The resulting images can be analysed with specialised software (EchoPAC-3D) to provide 3D reconstruction and volume estimation (Martens *et al.*, 1997) (Figure 4), this software also enables intragastric distribution to be studied by dividing the stomach into proximal and/or distal volumes (Gilja *et al.*, 1997a).



Currently, 3D ultrasound to measure gastric emptying is restricted to work in the research setting. This method has been applied to stomach volumes and validated against scintigraphy in both the healthy elderly (Gentilcore *et al.*, 2006) and in patients with diabetic gastroparesis (Stevens *et al.*, 2011) (Figure 5 and 6).

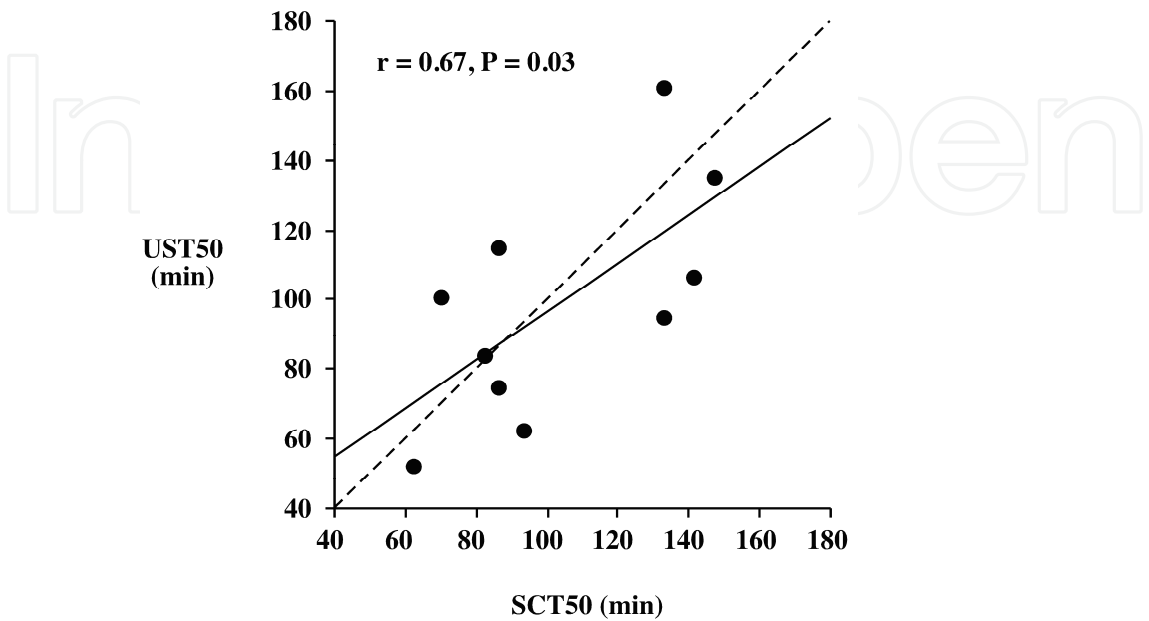


Fig. 5. Relationship between the gastric emptying half times ( $T_{1/2}$ ) of a high-nutrient dextrose drink (75g dextrose dissolved in 300mL water) as measured by 3D ultrasound and scintigraphy (n=10 diabetic patients with gastroparesis). (Neurogastroenterol Motil (2011;23:220-e114)).

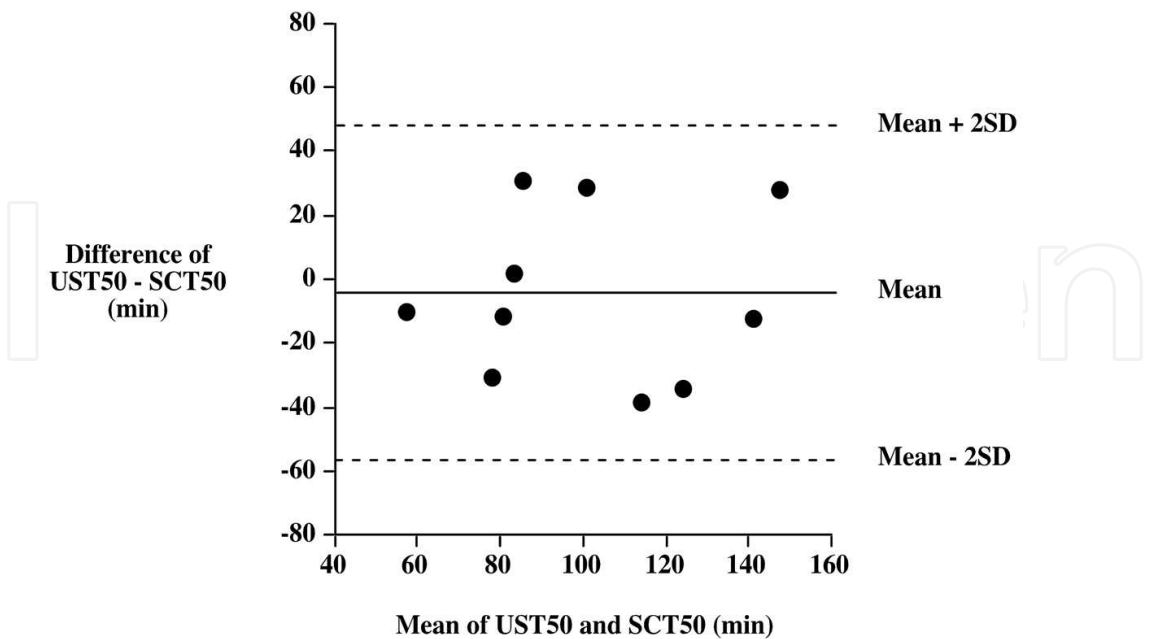


Fig. 6. Limits of agreement for scintigraphic (SCT50) and 3D ultrasonographic (UST50) 50 % emptying times ( $T_{50}$ s) for the drink (75 g dextrose in 300 mL water) (n=10 diabetic patients with gastroparesis). (Neurogastroenterol Motil (2011;23:220-e114)).

3D ultrasound has also been shown to have higher accuracy and less variability than 2D ultrasound of the stomach (Gilja *et al.*, 1997a) and in a study with a fluid-filled barostat bag, has correlated well with true stomach volumes with low inter-observer variation (Tefera *et al.*, 2002).

3D ultrasound is limited by the complexities of scanning technique and technological availability. Additionally, difficulties in imaging due to the presence of intragastric gas may limit accuracy.

## 7. Measurement of antropyloroduodenal motility

Gastric emptying in humans is predominantly a pulsatile phenomenon in which the contents of the stomach move across the pylorus in response to either a local increase in the pressure between the antrum and duodenum caused by an increase in local antropyloric pressure waves (i.e., peristaltic flow), or non-peristaltic flow caused by differences in pressure between the distal antrum and duodenum (Berstad *et al.*, 1994; Gilja *et al.*, 2007).

Much information about gastric emptying can be obtained by evaluating the physical contractions of the antropyloroduodenal region. While manometric apparatus have been traditionally used to assess antropyloric pressure changes during these events, the technique is limited to assessment of lumen occlusive contractions (Gilja *et al.*, 2007). Following ingestion of a low nutrient soup with simultaneous ultrasound, approximately 45% of pyloric contractions which were visible on ultrasound images were not correlated to manometric pressure changes (Hveem *et al.*, 2001; Hausken *et al.*, 2002). While providing more comprehensive information about the timing and magnitude of antropyloric pressure contractions, ultrasound has the added benefit of also providing visual information about the movement of gastric contents across the pylorus in relation to individual peristaltic contractions (King *et al.*, 1984; Hausken *et al.*, 1992). Additionally, intubation with a manometric catheter is invasive, associated with significant patient discomfort, and is not always practical.

Ultrasonographic measurement of antropyloroduodenal contractions, whilst beneficial in that it overcomes the limitations of manometry, is restricted in that it requires a well trained operator. Currently, use is restricted to the research setting (Gilja *et al.*, 2007).

## 8. Measurement of transpyloric flow

Ultrasonography can be used to both quantify and qualify the movement of the contents of the stomach across the pylorus, into the duodenum. This normal movement of the stomach contents into the duodenum is normally followed by a short period of duodenogastric reflux immediately prior to the closing of the pylorus (Berstad *et al.*, 1994; Hausken *et al.*, 2001; Gilja *et al.*, 2007).

Transpyloric imaging employs duplex ultrasonography (simultaneous Doppler and B-mode imaging) of the pylorus enabling the motion and velocity of gastric contents to be assessed (Hausken *et al.*, 1992; Berstad *et al.*, 1994; Hausken *et al.*, 1998a). Gastric emptying is said to occur when there is flow across the pylorus with a mean velocity of 10 cm/s or more, lasting for at least one second (Gilja *et al.*, 2007). Contraction of the antrum occurs when there is visible movement of the antral wall which propagates with time and is not caused by pulsation of nearby vessels or the adjacent intestine, or by respiration (Gilja *et al.*, 2007).

A technique involving 3D ultrasonography of transpyloric flow has been developed by Hausken *et al.* to assess flow during the abovementioned duodenogastric reflux period. This technique enables quantification of duodenogastric stroke volume (Hausken *et al.*, 2001). High intra and inter individual correlations of stroke volume have been shown (Hausken *et al.*, 2001).

Whilst there are substantial operational and technical demands of this type of ultrasound, the significant insight into the normal physiological movements involved in digestion it provides has proven invaluable in the research setting (King *et al.*, 1984; Hausken & Berstad, 1992; Hausken *et al.*, 1998a; Jones *et al.*, 2006). Transpyloric flow has been shown to be greater in a sitting position, compared to a supine position, with no effect on the overall emptying of a standardised drink consisting of 600mL of water and 75g of glucose (Jones *et al.*, 2006). Measurements of transpyloric flow have been shown to be decreased, along with the overall rate of gastric emptying, in older, when compared with young, subjects (O'Donovan *et al.*, 2005). In studies of patients with type 2 diabetes, with and without autonomic neuropathy, reduced transpyloric flow was shown (Kawagishi *et al.*, 1994). Additionally, altered movement of the contents of the stomach across the pylorus may be responsible for postprandial symptoms in patients with functional dyspepsia (Hausken *et al.*, 1998b).

## 9. Gastric strain rate imaging

The deformation of the gastric wall due to mechanical stress (strain) can be imaged with B-mode ultrasonography (Gilja *et al.*, 2002). Gastric strain is of interest for a number of reasons; mechanoreceptors respond to changes in stress in a muscular wall, not changes in pressure or volume so it allows these direct effects to be studied, it provides information on the elastic properties of the muscular walls of the stomach, it can differentiate phasic motions from passive changes in muscle tone (which is of particular importance in a research setting) and it allows the normal geometry of the stomach to be maintained while assessing these parameters (Gregersen *et al.*, 2002).

Gastric strain rate imaging (SRI) involves the recording of tissue velocity to obtain strain, and the strain rate is defined by the gradient of the velocity component of two points along the ultrasound beam (Gilja *et al.*, 2007; Ahmed *et al.*, 2009). SRI is able to distinguish between contraction of the circular and longitudinal muscle layers, even when not distinctly visible on the 2D ultrasound image (Gilja *et al.*, 2002).

Technically, continuous imaging is necessary and a small sample size (~2 mm) should be selected (Gilja *et al.*, 2007; Ahmed *et al.*, 2009). Cine imaging should be acquired over the antral lumen whenever a change in luminal cross-section or antral circularity is observed (Gilja *et al.*, 2007; Ahmed *et al.*, 2009).

SRI has been validated *in vivo* with a silicone phantom to mimic moving tissue (Matre *et al.*, 2003) and in an *in vitro* porcine model (Ahmed *et al.*, 2006). In a study involving the artificial distension of the antrum with a barostat device, there was a significant inverse correlation between balloon pressure and gastric strain (Gilja *et al.*, 2002).

The use of SRI has been applied in patients with functional dyspepsia (Ahmed *et al.*, 2008), and in these patients, divided into subgroups of 'epigastric pain syndrome' (EPS) and

‘postprandial distress syndrome’ (PDS), antral strain was shown to be higher in EPS patients, compared with PDS patients and normal controls, both in the fasting and postprandial state (Ahmed *et al.*, 2008; Ahmed *et al.*, 2009).

Due to the relatively novel nature of this type of imaging, and the requirement for a well trained operator, SRI imaging is still largely reserved for the research setting. Further studies would be required to assess potential clinical applications for this type of imaging.

## 10. Conclusion

Ultrasonography remains a safe and effective means by which the structure and function of the stomach can be assessed in an accurate and reproducible manner. Ultrasonography offers several advantages over other imaging modalities in that it is easy to perform, readily accessible, cheap and not associated with a radiation burden.

The techniques described in this chapter have been applied in a meaningful way in either the clinical or research setting, or in some cases, both. 2D ultrasonography of the stomach stands out as a simple and well-validated means by which antral area, proximal stomach accommodation and gastric emptying can be assessed, whereas 3D ultrasonography offers added information about the physiology of the stomach. New techniques involving the imaging of the flow of the stomach contents across the pylorus, motility of the pylorus, and the mechanical stress placed on the gastric wall, continue to be developed.

It should be recognised that for these techniques to be effective, they require the hand of a skilled, well trained operator, and are only applicable in situations where there is relevance or interest in the added information that ultrasonography of the stomach has to offer. Whilst at this time, this is often limited to the research setting, as these techniques are more widely adopted, clinical use will become more widespread.

Provided the limitations of each ultrasonographic technique discussed in this chapter are observed, ultrasound has the ability to provide significant anatomical and physiological information about the stomach and its contents in both the clinical and research setting.

## 11. References

- Ahmed AB, Gilja OH, Gregersen H, Odegaard S & Matre K. (2006). In vitro strain measurement in the porcine antrum using ultrasound doppler strain rate imaging. *Ultrasound Med Biol* 32, 513-522.
- Ahmed AB, Gilja OH, Hausken T, Gregersen H & Matre K. (2009). Strain measurement during antral contractions by ultrasound strain rate imaging: influence of erythromycin. *Neurogastroenterol Motil* 21, 170-179.
- Ahmed AB, Matre K, Hausken T, Gregersen H & Gilja OH. (2008). T1326 ROME III Subgroups of Functional Dyspepsia Exhibit Different Characteristics of Antral Strain Measured By Strain Rate Imaging. *Gastroenterology* 134, A-531.
- Azpiroz F & Malagelada JR. (1987). Gastric tone measured by an electronic barostat in health and postsurgical gastroparesis. *Gastroenterology* 92, 934-943.

- Benini L, Brighenti F, Castellani G, Brentegani MT, Casiraghi MC, Ruzzenente O, Sembenini C, Pellegrini N, Caliarì S, Porrini M & et al. (1994). Gastric emptying of solids is markedly delayed when meals are fried. *Dig Dis Sci* 39, 2288-2294.
- Berstad A, Hausken T, Gilja OH, Thune N, Matre K & Odegaard S. (1994). Volume measurements of gastric antrum by 3-D ultrasonography and flow measurements through the pylorus by duplex technique. *Dig Dis Sci* 39, 975-1005.
- Bian RW, Lou QL, Gu LB, Kong AP, So WY, Ko GT, Ouyang XJ, Mo YZ, Ma RC, Chan JC & Chow CC. (2011). Delayed gastric emptying is related to cardiovascular autonomic neuropathy in Chinese patients with type 2 diabetes. *Acta Gastroenterol Belg* 74, 28-33.
- Bolondi L, Bortolotti M, Santi V, Calletti T, Gaiani S & Labo G. (1985). Measurement of gastric emptying time by real-time ultrasonography. *Gastroenterology* 89, 752-759.
- Bouvet L, Miquel A, Chassard D, Boselli E, Allaouchiche B & Benhamou D. (2009). Could a single standardized ultrasonographic measurement of antral area be of interest for assessing gastric contents? A preliminary report. *Eur J Anaesthesiol* 26, 1015-1019.
- Brown BP, Schulze-Delrieu K, Schrier JE & Abu-Yousef MM. (1993). The configuration of the human gastroduodenal junction in the separate emptying of liquids and solids. *Gastroenterology* 105, 433-440.
- Collins PJ, Horowitz M, Cook DJ, Harding PE & Shearman DJ. (1983). Gastric emptying in normal subjects--a reproducible technique using a single scintillation camera and computer system. *Gut* 24, 1117-1125.
- Collins PJ, Houghton LA, Read NW, Horowitz M, Chatterton BE, Heddle R & Dent J. (1991). Role of the proximal and distal stomach in mixed solid and liquid meal emptying. *Gut* 32, 615-619.
- Darwiche G, Almer LO, Bjorgell O, Cederholm C & Nilsson P. (1999). Measurement of gastric emptying by standardized real-time ultrasonography in healthy subjects and diabetic patients. *J Ultrasound Med* 18, 673-682.
- De Schepper HU, Cremonini F, Chitkara D & Camilleri M. (2004). Assessment of gastric accommodation: overview and evaluation of current methods. *Neurogastroenterol Motil* 16, 275-285.
- Detmer PR, Bashein G, Hodges T, Beach KW, Filer EP, Burns DH & Strandness DE, Jr. (1994). 3D ultrasonic image feature localization based on magnetic scanhead tracking: in vitro calibration and validation. *Ultrasound Med Biol* 20, 923-936.
- Folvik G, Bjerke-Larssen T, Odegaard S, Hausken T, Gilja OH & Berstad A. (1999). Hydrosonography of the small intestine: comparison with radiologic barium study. *Scand J Gastroenterol* 34, 1247-1252.
- Gentilcore D, Hausken T, Horowitz M & Jones KL. (2006). Measurements of gastric emptying of low- and high-nutrient liquids using 3D ultrasonography and scintigraphy in healthy subjects. *Neurogastroenterol Motil* 18, 1062-1068.
- Gilja OH, Detmer PR, Jong JM, Leotta DF, Li XN, Beach KW, Martin R & Strandness DE, Jr. (1997a). Intragastric distribution and gastric emptying assessed by three-dimensional ultrasonography. *Gastroenterology* 113, 38-49.




- Gilja OH, Hatlebakk JG, Odegaard S, Berstad A, Viola I, Giertsen C, Hausken T & Gregersen H. (2007). Advanced imaging and visualization in gastrointestinal disorders. *World J Gastroenterol* 13, 1408-1421.
- Gilja OH, Hausken T, Bang CJ & Berstad A. (1997b). Effect of glyceryl trinitrate on gastric accommodation and symptoms in functional dyspepsia. *Dig Dis Sci* 42, 2124-2131.
- Gilja OH, Hausken T, Odegaard S & Berstad A. (1995). Monitoring postprandial size of the proximal stomach by ultrasonography. *J Ultrasound Med* 14, 81-89.
- Gilja OH, Hausken T, Odegaard S & Berstad A. (1996a). Three-dimensional ultrasonography of the gastric antrum in patients with functional dyspepsia. *Scand J Gastroenterol* 31, 847-855.
- Gilja OH, Hausken T, Odegaard S & Berstad A. (2005). Ultrasonography and three-dimensional methods of the upper gastrointestinal tract. *Eur J Gastroenterol Hepatol* 17, 277-282.
- Gilja OH, Hausken T, Olafsson S, Matre K & Odegaard S. (1998). In vitro evaluation of three-dimensional ultrasonography based on magnetic scanhead tracking. *Ultrasound Med Biol* 24, 1161-1167.
- Gilja OH, Hausken T, Wilhelmsen I & Berstad A. (1996b). Impaired accommodation of proximal stomach to a meal in functional dyspepsia. *Dig Dis Sci* 41, 689-696.
- Gilja OH, Heimdal A, Hausken T, Gregersen H, Matre K, Berstad A & Odegaard S. (2002). Strain during gastric contractions can be measured using Doppler ultrasonography. *Ultrasound Med Biol* 28, 1457-1465.
- Gregersen H, Gilja OH, Hausken T, Heimdal A, Gao C, Matre K, Odegaard S & Berstad A. (2002). Mechanical properties in the human gastric antrum using B-mode ultrasonography and antral distension. *Am J Physiol Gastrointest Liver Physiol* 283, G368-375.
- Hausken T & Berstad A. (1992). Wide gastric antrum in patients with non-ulcer dyspepsia. Effect of cisapride. *Scand J Gastroenterol* 27, 427-432.
- Hausken T & Gilja OH. (2006). Functional Ultrasound of the Gastrointestinal Tract. *Ultrasound of the Gastrointestinal Tract* Springer.
- Hausken T, Gilja OH, Odegaard S & Berstad A. (1998a). Flow across the human pylorus soon after ingestion of food, studied with duplex sonography. Effect of glyceryl trinitrate. *Scand J Gastroenterol* 33, 484-490.
- Hausken T, Gilja OH, Undeland KA & Berstad A. (1998b). Timing of postprandial dyspeptic symptoms and transpyloric passage of gastric contents. *Scand J Gastroenterol* 33, 822-827.
- Hausken T, Li XN, Goldman B, Leotta D, Odegaard S & Martin RW. (2001). Quantification of gastric emptying and duodenogastric reflux stroke volumes using three-dimensional guided digital color Doppler imaging. *Eur J Ultrasound* 13, 205-213.
- Hausken T, Mundt M & Samsom M. (2002). Low antroduodenal pressure gradients are responsible for gastric emptying of a low-caloric liquid meal in humans. *Neurogastroenterol Motil* 14, 97-105.
- Hausken T, Odegaard S, Matre K & Berstad A. (1992). Antroduodenal motility and movements of luminal contents studied by duplex sonography. *Gastroenterology* 102, 1583-1590.

- Hausken T, Thune N, Matre K, Gilja OH, ØDegaard S & Berstad A. (1994). Volume estimation of the gastric antrum and the gallbladder in patients with non-ulcer dyspepsia and erosive prepyloric changes, using three-dimensional ultrasonography. *Neurogastroenterology & Motility* 6, 263-270.
- Hodges TC, Detmer PR, Burns DH, Beach KW & Strandness DE, Jr. (1994). Ultrasonic three-dimensional reconstruction: in vitro and in vivo volume and area measurement. *Ultrasound Med Biol* 20, 719-729.
- Holt S, Cervantes J, Wilkinson AA & Wallace JH. (1986). Measurement of gastric emptying rate in humans by real-time ultrasound. *Gastroenterology* 90, 918-923.
- Holt S, McDicken WN, Anderson T, Stewart IC & Heading RC. (1980). Dynamic imaging of the stomach by real-time ultrasound--a method for the study of gastric motility. *Gut* 21, 597-601.
- Hveem K, Jones KL, Chatterton BE & Horowitz M. (1996). Scintigraphic measurement of gastric emptying and ultrasonographic assessment of antral area: relation to appetite. *Gut* 38, 816-821.
- Hveem K, Sun WM, Hebbard G, Horowitz M, Doran S & Dent J. (2001). Relationship between ultrasonically detected phasic antral contractions and antral pressure. *Am J Physiol Gastrointest Liver Physiol* 281, G95-101.
- Jones KL, Doran SM, Hveem K, Bartholomeusz FD, Morley JE, Sun WM, Chatterton BE & Horowitz M. (1997). Relation between postprandial satiation and antral area in normal subjects. *Am J Clin Nutr* 66, 127-132.
- Jones KL, O'Donovan D, Horowitz M, Russo A, Lei Y & Hausken T. (2006). Effects of posture on gastric emptying, transpyloric flow, and hunger after a glucose drink in healthy humans. *Dig Dis Sci* 51, 1331-1338.
- Kawagishi T, Nishizawa Y, Okuno Y, Shimada H, Inaba M, Konishi T & Morii H. (1994). Antroduodenal motility and transpyloric fluid movement in patients with diabetes studied using duplex sonography. *Gastroenterology* 107, 403-409.
- King PM, Adam RD, Pryde A, McDicken WN & Heading RC. (1984). Relationships of human antroduodenal motility and transpyloric fluid movement: non-invasive observations with real-time ultrasound. *Gut* 25, 1384-1391.
- Lunding JA, Tefera S, Gilja OH, Hausken T, Bayati A, Rydholm H, Mattsson H & Berstad A. (2006). Rapid initial gastric emptying and hypersensitivity to gastric filling in functional dyspepsia: effects of duodenal lipids. *Scand J Gastroenterol* 41, 1028-1036.
- Martens D, Hausken T, Gilja OH, Steen E, Alker H & Odegaard S. (1997). 3D processing of ultrasound images using a novel EchoPac-3D® software. *Ultrasound Med Biol* 23 (suppl 1), 136.
- Matre K, Ahmed AB, Gregersen H, Heimdal A, Hausken T, Odegaard S & Gilja OH. (2003). In vitro evaluation of ultrasound Doppler strain rate imaging: modification for measurement in a slowly moving tissue phantom. *Ultrasound Med Biol* 29, 1725-1734.
- Matre K, Stokke EM, Martens D & Gilja OH. (1999). In vitro volume estimation of kidneys using three-dimensional ultrasonography and a position sensor. *Eur J Ultrasound* 10, 65-73.

- Moragas G, Azpiroz F, Pavia J & Malagelada JR. (1993). Relations among intragastric pressure, postcibal perception, and gastric emptying. *Am J Physiol* 264, G1112-1117.
- Mundt MW, Hausken T & Samsom M. (2002). Effect of intragastric barostat bag on proximal and distal gastric accommodation in response to liquid meal. *Am J Physiol Gastrointest Liver Physiol* 283, G681-686.
- Nylund K, Odegaard S, Hausken T, Folvik G, Lied GA, Viola I, Hauser H & Gilja OH. (2009). Sonography of the small intestine. *World J Gastroenterol* 15, 1319-1330.
- O'Donovan D, Hausken T, Lei Y, Russo A, Keogh J, Horowitz M & Jones KL. (2005). Effect of aging on transpyloric flow, gastric emptying, and intragastric distribution in healthy humans--impact on glycemia. *Dig Dis Sci* 50, 671-676.
- Parys V, Bruley des Varannes S, Ropert A, Roze C & Galmiche JP. (1993). [Use of an electronic barostat for measurement of motor response of the proximal stomach to feeding and different nervous stimuli in man]. *Gastroenterol Clin Biol* 17, 321-328.
- Perlas A, Chan VW, Lupu CM, Mitsakakis N & Hanbidge A. (2009). Ultrasound assessment of gastric content and volume. *Anesthesiology* 111, 82-89.
- Sheiner HJ. (1975). Gastric emptying tests in man. *Gut* 16, 235-247.
- Snyder JE, Kisslo J & von Ramm O. (1986). Real-time orthogonal mode scanning of the heart. I. System design. *J Am Coll Cardiol* 7, 1279-1285.
- Stevens JE, Gilja OH, Gentilcore D, Hausken T, Horowitz M & Jones KL. (2011). Measurement of gastric emptying of a high-nutrient liquid by 3D ultrasonography in diabetic gastroparesis. *Neurogastroenterol Motil* 23, 220-225, e113-224.
- Sturm K, Parker B, Wishart J, Feinle-Bisset C, Jones KL, Chapman I & Horowitz M. (2004). Energy intake and appetite are related to antral area in healthy young and older subjects. *Am J Clin Nutr* 80, 656-667.
- Szarka LA & Camilleri M. (2009). Methods for measurement of gastric motility. *Am J Physiol Gastrointest Liver Physiol* 296, G461-475.
- Tarjan Z, Toth G, Gyorke T, Mester A, Karlinger K & Mako EK. (2000). Ultrasound in Crohn's disease of the small bowel. *Eur J Radiol* 35, 176-182.
- Tefera S, Gilja OH, Hatlebakk JG & Berstad A. (2001). Gastric accommodation studied by ultrasonography in patients with reflux esophagitis. *Dig Dis Sci* 46, 618-625.
- Tefera S, Gilja OH, Olafsdottir E, Hausken T, Hatlebakk JG & Berstad A. (2002). Intragastric maldistribution of a liquid meal in patients with reflux oesophagitis assessed by three dimensional ultrasonography. *Gut* 50, 153-158.
- Thune N, Gilja OH, Hausken T & Matre K. (1996). A practical method for estimating enclosed volumes using 3D ultrasound. *European journal of ultrasound : official journal of the European Federation of Societies for Ultrasound in Medicine and Biology* 3, 83-92.
- Undeland KA, Hausken T, Gilja OH, Aanderud S & Berstad A. (1998). Gastric meal accommodation studied by ultrasound in diabetes. Relation to vagal tone. *Scand J Gastroenterol* 33, 236-241.
- Undeland KA, Hausken T, Svebak S, Aanderud S & Berstad A. (1996). Wide gastric antrum and low vagal tone in patients with diabetes mellitus type 1 compared to patients with functional dyspepsia and healthy individuals. *Dig Dis Sci* 41, 9-16.

- van den Elzen BD, Bennink RJ, Wieringa RE, Tytgat GN & Boeckxstaens GE. (2003). Fundic accommodation assessed by SPECT scanning: comparison with the gastric barostat. *Gut* 52, 1548-1554.
- Vantrappen G. (1994). Methods to study gastric emptying. *Dig Dis Sci* 39, 91S-94S.
- Vasavid P, Chaiwatanarata T & Gonlachanvit S. (2010). The Reproducibility of Tc-Pertechnetate Single Photon Emission Computed Tomography (SPECT) for Measurement of Gastric Accommodation in Healthy Humans: Evaluation of the Test Results Performed at the Same Time and Different Time of the Day. *J Neurogastroenterol Motil* 16, 401-406.



## **Applied Aspects of Ultrasonography in Humans**

Edited by Prof. Philip Ainslie

ISBN 978-953-51-0522-0

Hard cover, 190 pages

**Publisher** InTech

**Published online** 25, April, 2012

**Published in print edition** April, 2012

Written by international experts, this publication provides the reader with the present knowledge and future research directions of diagnostic and therapeutic ultrasound and spectroscopy. Focused topics include Duplex ultrasound, transcranial color Duplex, MRA guided Doppler ultrasonography and near-infrared spectroscopy. New directions in the use and application of transcranial and color Duplex ultrasound are provided, as well as the use of ultrasound and arterial stiffness for measuring human vascular health and circulatory control. Novel use of ultrasound for the detection of intra-cardiac and intra-pulmonary shunts is also described along with its utility for the assessment of gastric regulation and emptying.

### **How to reference**

In order to correctly reference this scholarly work, feel free to copy and paste the following:

Laurence Trahair and Karen L. Jones (2012). Ultrasonography of the Stomach, Applied Aspects of Ultrasonography in Humans, Prof. Philip Ainslie (Ed.), ISBN: 978-953-51-0522-0, InTech, Available from: <http://www.intechopen.com/books/applied-aspects-of-ultrasonography-in-humans/ultrasonography-of-the-stomach>

**INTECH**  
open science | open minds

### **InTech Europe**

University Campus STeP Ri  
Slavka Krautzeka 83/A  
51000 Rijeka, Croatia  
Phone: +385 (51) 770 447  
Fax: +385 (51) 686 166  
[www.intechopen.com](http://www.intechopen.com)

### **InTech China**

Unit 405, Office Block, Hotel Equatorial Shanghai  
No.65, Yan An Road (West), Shanghai, 200040, China  
中国上海市延安西路65号上海国际贵都大饭店办公楼405单元  
Phone: +86-21-62489820  
Fax: +86-21-62489821



© 2012 The Author(s). Licensee IntechOpen. This is an open access article distributed under the terms of the [Creative Commons Attribution 3.0 License](https://creativecommons.org/licenses/by/3.0/), which permits unrestricted use, distribution, and reproduction in any medium, provided the original work is properly cited.

IntechOpen

IntechOpen