

We are IntechOpen, the world's leading publisher of Open Access books Built by scientists, for scientists

6,900

Open access books available

185,000

International authors and editors

200M

Downloads

Our authors are among the

154

Countries delivered to

TOP 1%

most cited scientists

12.2%

Contributors from top 500 universities



WEB OF SCIENCE™

Selection of our books indexed in the Book Citation Index
in Web of Science™ Core Collection (BKCI)

Interested in publishing with us?
Contact book.department@intechopen.com

Numbers displayed above are based on latest data collected.
For more information visit www.intechopen.com



Retinotomy/Retinectomy

Touka Banaee
*Eye Research Center,
 Mashhad University of Medical Sciences
 Iran*

1. Introduction

First described by Machemer¹ for relaxing the retina in proliferative vitreoretinopathy (PVR) and trauma, retinotomies have nowadays gained new indications. In many cases of proliferative vitreoretinopathy, the retina does not lend itself to reattachment intra operatively in spite of extensive dissection and removal of membranes². In these cases, there seems to be some intra retinal fibrosis causing shortening of the chronically detached retina. In other cases, the retina flattens under perfluorocarbon liquids or air, but suddenly air or Perfluorocarbon liquids (PFCL) tracks under the retina upon movements of the eye during operation. This is due to the presence of a break(s) with edges under traction. In these cases, if there are no visible membranes to be removed, the only option remaining is cutting or removing the shortened retina i.e.: retinotomy or retinectomy. Cutting or removing part of the retina to allow flattening or access to the subretinal space is part of advanced vitreoretinal surgical techniques.

2. Indications & strategies

Relaxing retinotomies:

There are several indications for doing a retinotomy. The first and best known is proliferative vitreoretinopathy (PVR). In this circumstance, retinotomy is done where there is retinal shortening or extensive epi- and subretinal fibrosis that do not lend itself to removal except for at the expense of formation of retinal breaks. This type of retinotomy is called a relaxing retinotomy. As previously noted, a relaxing retinotomy may be needed to stabilize a break edge. Another indication for performing a relaxing retinotomy is to release the retina that is incarcerated into a scleral wound or sclerotomy and cannot be flattened by either external or internal tamponade.

Access retinotomies:

Sometimes a retinotomy is done to have access to the subretinal space either for removal of substances from under the retina or for doing subretinal surgery. The substances to be removed may be:

- Fluids including subretinal fluid, perfluorocarbon liquids, or silicone oil
- Tissues including choroidal neovascularization, subretinal fibrosis or tumors

Indications for performing retinotomy:
1. Relaxing: <ul style="list-style-type: none">- Anterior PVR & intraretinal fibrosis- Stabilizing a retinal break- Retinal incarceration into sclerotomy or scleral wound
2. Access: <ul style="list-style-type: none">- Removing materials from subretinal space:<ul style="list-style-type: none">• Fluids: subretinal fluid, perfluorocarbon liquids, silicone oil• Tissues: choroidal neovascularization, fibrosis, tumors- Doing subretinal surgery e.g.: retinal pigment epithelial patch graft

Table 1.

3. Principles

- a. Relaxing retinotomies are usually done in a pathologic site of the retina. There are a few rules of thumb for performing a relaxing retinotomy:
 - i. Always extend the retinotomy into healthy retina usually for a clock hour from either side; do not fear of cutting too much retina, a large, stable retinotomy that provides the possibility of reattachment under long acting gas or silicone oil is always better than a small retinotomy with unstable edge that either leads to redetachment or requires stabilization by another procedure before removal of the silicone oil (Figure 1).
 - ii. When the retinotomy is circumferential, the edges must reach ora by an acute angle (Figure 1).

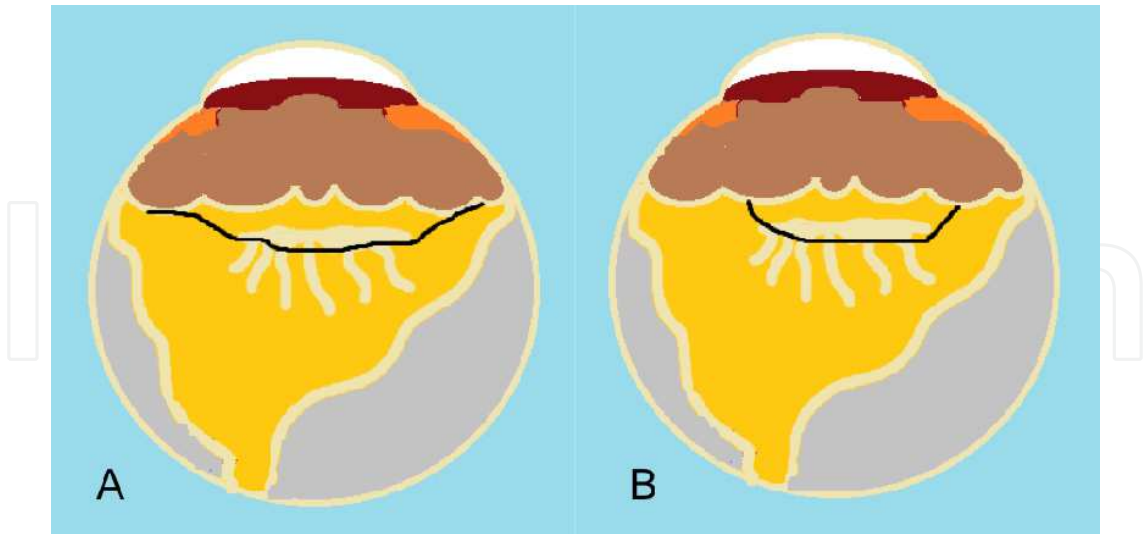


Fig. 1. Correct (A) and incorrect (B) circumferential retinotomies. Note that in the correct technique, the edges of retinotomy extend for a clock hour into normal retina and reach the ora with an acute angle.

- iii. Circumferential retinotomies are always more stable than radial retinotomies (Figure 2).

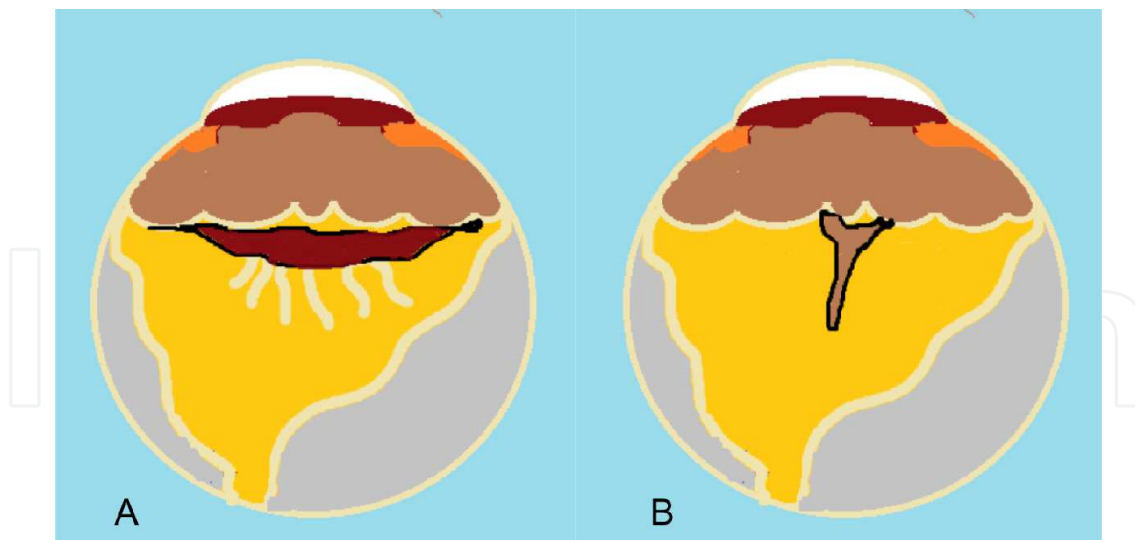


Fig. 2. Circumferential (A) and radial (B) relaxing retinotomies.

- iv. In case of retinal incarceration into a scleral wound, the type of retinotomy depends on how much retina is incarcerated and how peripheral is the incarceration. In posterior incarcerations due to perforating eye injuries or intraocular foreign bodies (IOFBs), there usually is the need to cut retina in a circle around the incarceration site. (Figure 4) In peripheral incarcerations, the retina must be cut flush to the sclera to preserve as much functional retina as possible. (Figure3)

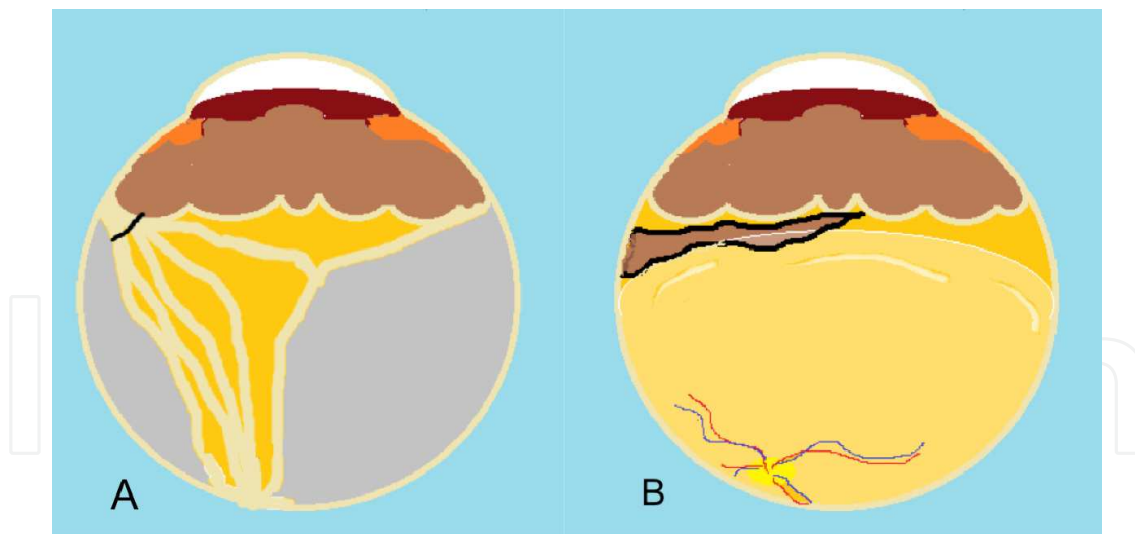


Fig. 3. Retinal incarceration into anterior sclera needs relaxing retinotomy with preservation of as much retina as possible (A). After flattening the retina with perfluorocarbon liquids, the posterior edge of the retinotomy may unexpectedly relax far posteriorly (B).

- b. Access retinotomies: Sometimes retinotomy is required to reach the subretinal space, to remove some material or tissues from underneath the retina, or to do subretinal surgery like implantation of tissue in this space^{3, 4}. I refer to these types of retinotomies as access retinotomies.



Fig. 4. When retina is incarcerated into a posterior impact site, usually a circular retinotomy around the impact site is needed.

In contrast to relaxing retinotomies, access retinotomies are usually done in a healthy portion of the retina. The size and location of this type of retinotomy, depends on the substance or tissue to be removed from under the retina or the type of subretinal surgery to be done. In these cases, there usually is a preferred site for doing the retinotomy. For example: for removal of subretinal tissues (fibrosis, CNV, and tumors) usually the retinotomy is done in a place to provide access for the surgeon for grasping the abnormal tissue (Figure 5). This may depend not only on the site of the abnormal tissue, but also on the type of instruments available, on the side of the dominant hand of the surgeon and on the sitting position of the surgeon. These retinotomies must be performed along the course of nerve fibers to reduce induction of visual field defects⁵. In cases that retinotomy is done to remove subretinal fluids, it is named drainage

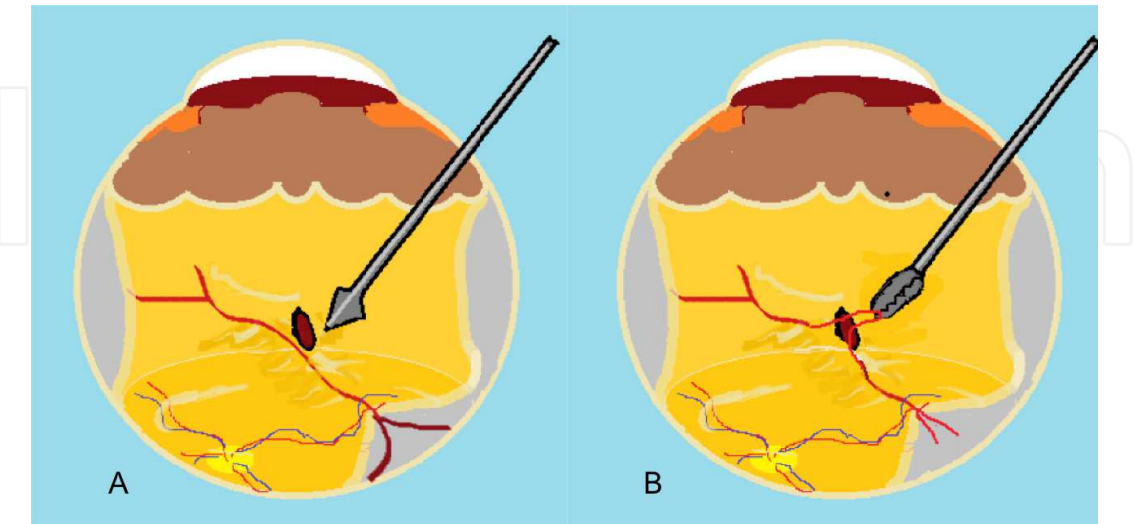


Fig. 5. Retinotomy for removal of subretinal bands (A) is usually done in the superior retina and where it makes access to the subretinal tissue possible. The subretinal band is grasped with a forceps through the retinotomy and gently pulled into the vitreous cavity (B).

retinotomy. This type of retinotomy is usually performed posteriorly to allow complete removal of the subretinal fluid or perfluorocarbon liquids under air⁶ or liquids. It is preferably done superiorly to be well tamponaded by routine intraocular tamponade agents, either long acting gases or silicone oil. For removal of subretinal silicone oil, as the oil is usually trapped in the superior and peripheral parts of the subretinal space, the retinotomy is best performed in the superior peripheral parts of the retina over the bubble of silicone oil.

4. Techniques

a. *Relaxing retinotomies:*

1. Anterior PVR:

Management of anterior PVR is usually done after removal of posterior membranes. The only exception is the central displacement type of anterior PVR that must be removed first to allow access to the more posterior parts of the retina. The circumferential contraction type of the anterior PVR is usually amenable to vitreous base trimming along with placement of radial cuts on the vitreous base without much complication. In this type of anterior PVR, dissection is usually successful and retinotomy is not needed.

The most difficult type of the anterior PVR to manage is the anterior displacement type. In this type of PVR, anterior-posterior contraction of the vitreous base, results in a circumferential fold of the retina at the site of the posterior border of the vitreous base, which is pulled anteriorly, sometimes up to the posterior surface of the iris. Dissection of vitreous base, which must be done circumferentially, is a difficult and delicate job needing a high degree of experience. In these cases some surgeons prefer to defer retinotomy until after extensive dissection of the vitreous base; then if the retina still does not relax enough to rest on the RPE with perfluorocarbon liquids, or by the pressure of air or if multiple retinal breaks have been formed during dissection, retinotomy will be done. Others do retinotomy from the outset with the proposition that dissection of the vitreous base is a time consuming procedure with poor results ending in the formation of multiple retinal breaks that finally necessitates performing a retinotomy. But in my opinion it is not an "all or not" rule. A cautious surgeon guides the operation by looking at the conditions. If the anterior displacement is not complete and the trough of the retinal fold is still visible, vitreous base is amenable to dissection without much complication. In this condition performing a retinotomy is more than needed. But in areas with extensive fibrosis of vitreous base that retinal folds have merged with the fibrous tissue, and the folded retina has formed a closed tunnel, the probability of formation of multiple retinal breaks during dissection is high and performing a retinotomy from the outset may be judicious as it saves time.

Conventionally, retinotomy is done anterior to 2 rows of endodiathermy to prevent bleeding from major retinal vessels. I myself place endodiathermy spots only over major retinal vessels coursing through the intended site of retinotomy and not as two continuous rows; because tissue injury of endodiathermy can enhance PVR formation and it is desirable to minimize it.

A vertical cutting scissors is used for cutting the retina. The vitrectomy probe can also be used to do the retinotomy which may be named "retinectomy". In both

techniques, if the retina is not elevated, there is the risk of damage to the underlying choroid with attendant bleeding. When using vitrectomy probe for retinectomy, this risk can be minimized by a high cutting rate and low aspiration.

In the era that perfluorocarbon liquids and wide angle viewing systems were not available, the surgeon was more confident of reattachment of the retina under air by performing a posterior retinotomy ^{7, 8}. With the advent of newer surgical instruments and devices, there is a preference to save as much retina as possible and retinotomy is usually performed as peripherally as possible. In cases with anterior PVR, the retina is anteriorly displaced and shortened so after performing the retinotomy, the posterior edge will relax posteriorly and will always rest more posterior than expected by the surgeon. For working so peripherally, usually use of wide angle viewing systems in combination with direct viewing through the microscope along with scleral depression results in a controlled operation. Use of panoramic viewing systems during the procedure encompassing peripheral retinotomy has been shown to reduce the operation time, allow more complete laser treatment posterior to the retinotomy edge and lessen the need for scleral depression⁹.

The extent of retinotomy depends on the extent of fibrosis. It must encompass at least one clock hour of uninvolved retina on either side (Figure 1) and must include any nearby iatrogenic retinal breaks. The end of retinotomy at either side must reach the ora with an acute angle (Figure 1). With time, fibrosis of the edge of the cut retina will result in rounding of the ends of the retinotomy. This is an unstable condition resulting in elevation of the edge and possibly redetachment of the retina. When edges of retinotomy reach the ora with an acute angle, this rounding is minimized and usually will not have enough force to elevate the retinotomy edge.

It is preferable to remove the anterior lip of the retinotomy as it is a hypoxic tissue and may cause neovascularization. Some have also proposed that it may redirect the intraocular fluid currents toward the retinotomy, which may enhance redetachment. Fibrosis and exertion of traction on edges of retinotomy is another argument that has been suggested to remove the anterior lip of the retinotomy.

In order to avoid another surgery, YAG laser has been used to perform a relaxing retinotomy in operated silicone filled eyes¹⁰ but has not gained wide acceptance.

2. Retinal incarceration in the scleral wound:

Ocular injuries can have a variety of presentations and cause various damages to the ocular structures.

Sometimes retina is incarcerated into the entrance wound (Figure 3). In this circumstance there is usually extensive damage to the retina, as parts of it had been damaged or cut during injury or primary repair of the wound. Usually there is dense vitreous hemorrhage that must first be removed to make the condition visible. If retinal incarceration is minimal and the condition can be managed safely by placement of a scleral buckle, it is preferable to do scleral buckling rather than a retinotomy. But an extensive incarceration can only be managed by retinotomy¹¹. Relaxing retinotomy in these cases must be done with sparing as much retina as possible. The surgeon must be cautious when cutting the retina near the wound as hitting the granulation tissue at the wound by instruments, may result in extensive

intraoperative bleeding. Deliberate use of endodiathermy may decrease bleeding from congested retina and surrounding tissues, but one must be cautious in use of cautery to the base of the scleral wound. It may result in the formation of a weak scar and staphyloma in the future.

Another scenario of retinal incarceration into scleral wound is incarceration of vitreous and retina into the sclerotomy of a previous vitrectomy surgery resulting in retinal (re)detachment. In these cases usually a small circumferential retinotomy suffices to relieve the traction. Because of the localized nature of the condition and low lying RD, risk of damage to the underlying choroid and resultant bleeding is high which can be minimized by using the high cut rate and low suction of a high speed vitrectomy system.

Retina may incarcerate at the exit wound, or at the site of the impact of a foreign body. In these cases, if there is no retinal detachment, and the incarceration is minimal the case can be managed by retinopexy around the wound.

But if the retina is detached the best management will be doing a retinotomy around the incarceration site to release the retina (Figure 4), because even if the retina is reattached under the weight of perfluorocarbon liquids, future fibrosis will certainly cause retinal traction and redetachment.

3. Macular translocation surgery:

First described by Machemer^{12, 13}, in this type of surgery, the retina is detached from RPE by injection of fluid in the subretinal space, peripheral 360 degrees retinotomy is performed and the retina is reattached with some rotation in relation to its natural position. The aim of this type of surgery is to displace the fovea onto a healthier RPE bed. Retinotomy is done for the relocation of the fovea to become possible. It can also be used as an access retinotomy for removal of subretinal CNV and blood.

b. *Access retinotomies:*

1. Drainage retinotomy for removal of subretinal fluid and perfluorocarbon liquids:

There are some cases of retinal detachment and no visible or small peripheral breaks. In these cases, the subretinal fluid does not drain to the vitreous cavity by injection of perfluorocarbon liquids or air. Facing this situation, some surgeons do not touch the subretinal fluid with the assumption that adequate tamponade of peripheral breaks with either scleral buckling or endotamponade will result in the reabsorption of the subretinal fluid by the RPE. If one is not to do scleral buckling, doing adequate retinopexy is mandatory which may be done with cryotherapy without the need for reattachment of peripheral retina. Successful endolaser needs flat peripheral retina and the only option remaining for the surgeon will be performing a drainage retinotomy and draining the subretinal fluid through it.

If the fluid is removed during air/fluid exchange under the pressure of air, fluid will be pushed posteriorly and a posterior retinotomy will be required. A small retinotomy the size to permit soft tip cannula to pass through is usually adequate. Retinotomy is done either by a single cut of the vitrectomy probe or by a sharp needle or MVR blade. Superior location is the preferred site because it ensures adequate tamponade by routine tamponade agents (long acting gasses and silicone oil).

In some cases of peripheral retinal detachment, the macula is attached and a complete air/fluid exchange pushes the subretinal fluid posteriorly which will result in detachment of the fovea. In these cases, doing a retinotomy and drainage of the subretinal fluid will help avoid foveal detachment. An alternative option in this scenario is to remove the perfluorocarbon liquid under BSS and perform a partial air/fluid exchange. If a complete air/fluid exchange is to be done, a small retinotomy is placed near the posterior margin of detachment and the subretinal fluid is drained through it during a slow air/fluid exchange.

This type of retinotomy has several complications including formation of choroidal neovascular membranes and re proliferation at the retinotomy site causing macular traction and redetachment. Damage to the RPE and Bruch's membrane during placement of retinotomy, drainage of subretinal fluid, or retinopexy might have predisposed to these complications¹⁴.

Perfluorocarbon liquids sometimes find way to the subretinal space. This usually occurs during complicated surgeries of anterior PVR with existence of a peripheral retinotomy or large break. The same retinotomy or break can usually be used to access the subretinal space for removal of the PFCL. Besides, subretinal tracking of PFCLs in these cases means that there is residual traction on the edges of the retinotomy or retinal breaks which mandates more dissections or retinotomy. The volume of the subretinal PFCL depends on many factors: the volume of PFCL injected into vitreous cavity and proximity of the causative break or retinotomy to the ora.

Sometimes the cause of tracking of PFCLs into the subretinal space is extensive manipulations and scleral depressions when the vitreous cavity is filled with PFCLs and there is a peripheral break or retinotomy. In this situation, the volume of the subretinal PFCL is small and there is limited access to the subretinal space. If drainage through a break or retinotomy is not possible, the only remaining option will be doing a posterior retinotomy. (Figure 6) It is desirable to do the retinotomy and drainage when the eye is still filled with the PFCL, because in PFCL filled eye, the elevation will usually remain peripheral and localized; but if intravitreal PFCL is removed, subretinal PFCL will settle posteriorly. Considering the location and the small volume of the subretinal PFCL, a retinotomy at posterior pole will be required which will be very dangerous due to the shallowness of elevation.

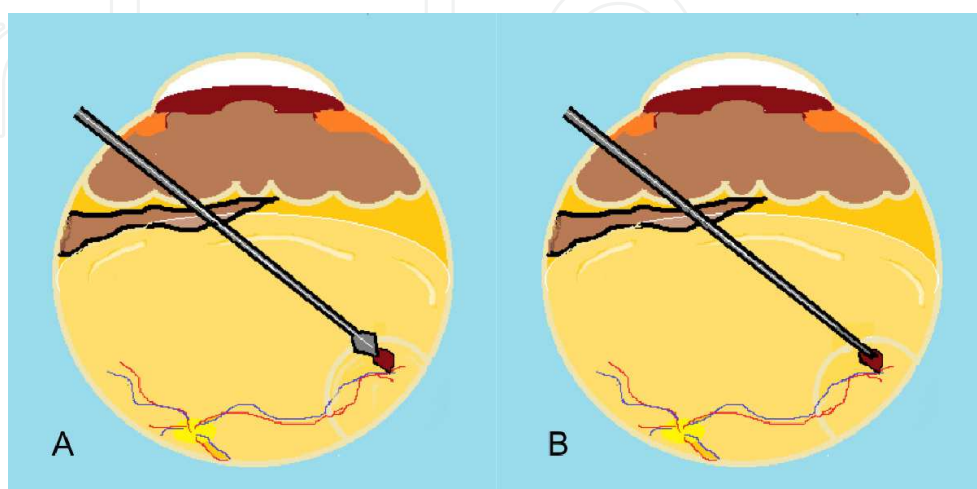


Fig. 6. Drainage retinotomy (A) for removal of subretinal PFCL with a flute needle (B).

Post-operatively with retinal reattachment, and the function of the RPE pump, the retained subretinal PFCL will assume the shape of a subretinal bubble. Retinal puncture with small gauge needle and active suction of the retained PFCL have been reported^{15, 16} Persistence of subretinal PFCLs will result in degeneration of photoreceptors over it¹⁷. This complication is especially important if the bubble gathers under the fovea. Air/fluid exchange and postoperative upright positioning to push the PFCL to inferior periphery has been proposed for these cases¹⁸.

When the surgeon is not sure about completeness of subretinal PFCL removal, he or she must insist on prone positioning of the patient during the first postoperative day(s) if regular tamponade agents have been used to force the subretinal PFCL migrate peripherally and be trapped as a peripheral bubble.

2. For removal of subretinal silicone oil

Usually these are cases encountered after removal of the silicone oil from within the vitreous cavity, so the vitreous cavity is filled with either aqueous solution or PFCLs and the silicone oil usually accumulates peripherally and superiorly. Removal usually needs a peripheral and superior circumferential retinotomy best done by scleral depression and direct view of the microscope.

3. For removal of subretinal fibrosis and napkin ring

Peripheral subretinal bands need removal only if they hinder retinal reattachment. If they are to be removed, a small radial retinotomy is placed over them and the membrane is grasped with a forceps and pulled through the retinotomy. This maneuver usually results in some small tears around the retinotomy resulting in irregular enlargement of the retinotomy. The best place to do the retinotomy depends on the extent of the membrane, and surgeon's evaluation of the strength and adhesion sites of the membrane. The preferred quadrant of retinotomy also depends on the site of existing breaks, and the tamponade agent that is considered for use. If a heavier than water tamponade agent is considered for use, inferior quadrants will be the preferred site. For regular tamponade agents, superior quadrants are the better choice. But if the site is not matched with the tamponade agent, use of a small segmental buckle to support the retinotomy is prudent.

Usually the membrane gapes away during removal and does not come out in toto. Total removal of the membrane is not the goal, if tractions are relieved enough to allow the retina to settle under PFCL or air, the procedure is considered enough.

A significant factor to be considered during removal of subretinal membranes is the delicacy of removal. If the membrane sweeps the outer retinal surface during removal through the retinotomy, photoreceptors will be damaged. This will be especially important during removal of membranes near fovea, which may make a good visual result out of reach despite anatomic reattachment. Pulling the membrane along its axis may somewhat prevent this complication.

One of the complications during removal of subretinal bands is subretinal migration of PFCLs. To prevent this, one must keep the level of PFCL well below the edge of the retinotomy. If this complication occurs, the same retinotomy can be used to remove the PFCL. If it is in a peripheral location, a more posterior drainage retinotomy may be needed.

Napkin ring is a fibrous tissue surrounding the optic nerve head preventing normal opposition of the posterior pole. As these eyes usually have extensive PVR and

have peripheral breaks or retinotomies, usually the same sites are used to enter the subretinal space to remove the napkin ring or a 360 degrees retinotomy may be used¹⁹. Extending the retinotomy circumferentially to have some view of the posterior lesion is usually necessary.

In cases without significant peripheral breaks or retinotomies, a small radial retinotomy can be placed nasally, superiorly or inferiorly near the optic nerve head and used to remove the subretinal fibrosis. But in this technique the surgeon does not have enough view of the membrane and controls the procedure with a view through the retina. In these cases, the risk of damage to the adjacent retina and optic disc components must be weighed against performing a large peripheral retinotomy with its consequences.

4. For removal of subfoveal CNV

Removal of subretinal CNV and blood has been tested in the Subretinal Surgery trials. Others have reported modest visual improvement after removal of massive subretinal blood secondary to CNV²⁰. This technique is useful mostly in type 2 CNVs i.e.: membranes over the RPE and under the retina. In type 1 CNVs, the membrane is below the RPE and the RPE must be sacrificed for its removal which will result in atrophy of the overlying fovea^{21,22}. To prevent this complication, multiple attempts have been done to transplant RPE with or without underlying choroid²³.

Retina is attached in these cases and for doing the procedure, the first step is induction of RD by injection of BSS into the subretinal space, a procedure called hydro-dissection of the retina. This step is usually done with small gauge needles or cannulas^{24,25}. (Figure 7)

The subretinal space can be reached through either a large peripheral retinotomy²⁶ (Figure 7) or a smaller posterior retinotomy²³. In cases with large peripheral retinotomies, one may choose to rotate the retina in order to relocate the fovea onto a healthier RPE (macular translocation surgery)²⁶.

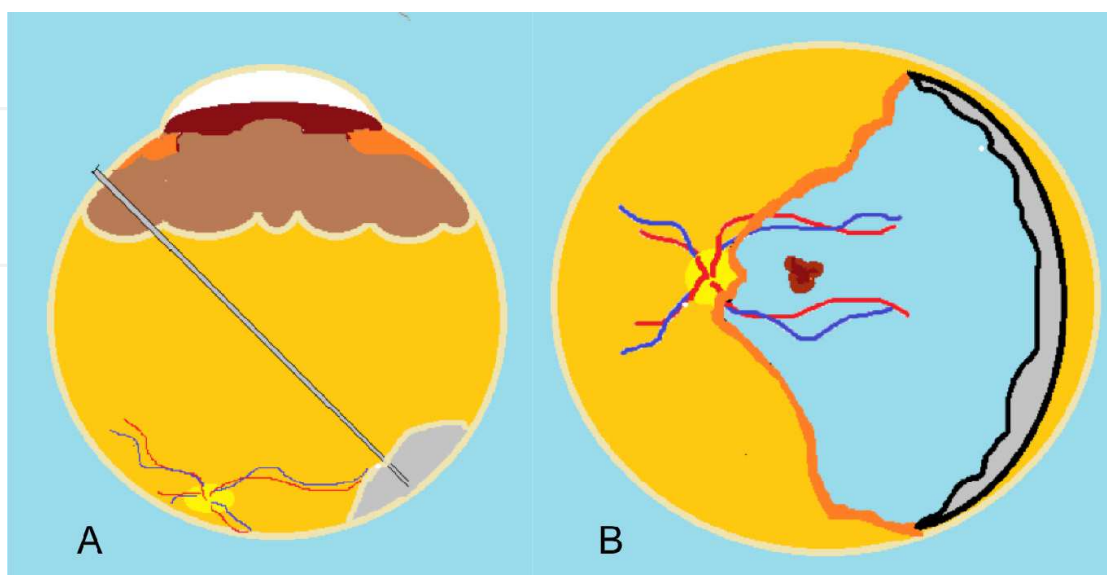


Fig. 7. Retina is detached by infusion of fluid into the subretinal space (A) and a large peripheral access retinotomy is done to reach the CNV (B).

5. For biopsy or removal of subretinal tumors
Retinotomies have been done to aspirate and biopsy choroidal tumors²⁷⁻³⁰. Intraocular tumor biopsy via a small retinotomy has been reported.³¹
6. For removal of other materials:
Sub macular hard exudates in diabetic eyes have been removed through a parafoveal small retinotomy³². Cysticercosis and other larvae³³⁻³⁵, and blood clot³⁶ (dissolved by tPA) have all been removed from subretinal space through a retinotomy.
Removal of subretinal blood loculated in the posterior pole is usually done through a parafoveal retinotomy³⁶, but removal of extensive subretinal blood, usually needs intravitreal tPA injection followed by vitrectomy surgery 12-24 hours later and peripheral retinotomy with intra-operative drainage of subretinal fluid using PFCLs. Tamponade with long acting gases is employed for further postoperative drainage of the subretinal blood³⁷.
7. For doing subretinal surgery:
Different techniques of RPE transplantation or neuroretinal transplantation have been performed after removal of a CNV^{21,22,38,39}. Subretinal visual prostheses must be implanted through a retinotomy⁴⁰.

5. Extent & determination of adequacy

In case of access retinotomies, the least amount of retinotomy that permits adequate access, view and successful performance without induction of undue complications is done. In cases of relaxing retinotomy, determination of adequacy depends on:

- a. adequate release of pathologic tractions to permit retinal reattachment under air or PFCLs
- b. stable edge design
- c. absence of nearby breaks

6. Management of retinotomy: Adjunctive scleral buckling, retinopexy, internal tamponade

Peripheral retinotomies usually need tamponade, either internal or external. When the site of retinotomy is judged to be inadequately supported by the internal tamponade agent, one may choose to use both.

Some studies have found similar results for silicone oil or gas tamponade⁴¹ in eyes undergoing retinotomy, but other studies advocate use of silicone oil⁴². Presence of relaxing retinotomy seems not to affect the initial outcome in gas filled eyes, but it reduces the need for reoperation if silicone oil is used for tamponade⁴². Inferior retinotomies may best be managed by heavy silicone oils, of which many newer agents are under development⁴³.

Retinopexy is needed for large peripheral relaxing retinotomies. It can be performed during operation or post-operatively if the retinotomy is adequately supported by silicone oil. Usually 3-4 rows of barrier laser spots are placed posterior to the retinotomy. Delayed completion of the barrage to 360 degrees prior to silicone oil removal, has been shown to

reduce redetachment rate after silicone oil removal in eyes that had underwent vitrectomy surgery for PVR⁴⁴.

Small posterior retinotomies may be left without retinopexy^{5,16}.

7. Staged operation

Staged operation have been proposed to improve the results of surgery in cases with severe PVR⁴⁵. In this strategy, one may do the least surgery that can reattach most of the retina under silicone oil. Then during the second procedure, retinotomy will be completed and a third procedure is planned for silicone oil removal.

8. Complications

a. Intraoperative

Intraoperative hemorrhage is one of the major complications⁴⁶ that can be prevented by placement of endodiathermy spots and avoiding damage to the choroid.

Migration of perfluorocarbon liquids into the subretinal space is a complication of large retinotomies (more than 120 degrees) especially frequent in 360 degrees retinotomies. In one series the authors did not find any difference between two different types of PFCL in terms of subretinal migration⁴⁷.

Another complication of large retinotomies is retinal slippage during air fluid exchange. This complication results from the fluid meniscus between PFCL and gas bubble tracking under the retina causing a shallow peripheral detachment, which under the pressure of air and continuous removal of the intravitreal fluid and PFCL will migrate posteriorly with attachment of the most peripheral parts under air. This reattached peripheral part does not sit on its real position due to the presence of a detached part of the retina posteriorly and sits on a more posterior location, a process called retinal slippage. To avoid this complication, slow air fluid exchange with complete removal of fluid layer over PFCL before removal of PFCL itself is advocated⁴⁸. Another resolution is direct exchange of PFCL with silicone oil. In this technique the fluid over PFCL must be totally removed first too, but because of a more clear view of the process, this goal may be easier to achieve.

b. Postoperative:

Redetachment due to reeproliferation is a major cause for failure of surgery. It depends on the extent of retinotomy and has been reported to occur in 18% to 100 % of cases.^{1,42, 46,49-51}

Reeproliferation has been reported in up to 50% of eyes with 360 degree retinotomy leading to redetachment in 30% of cases⁴⁶.

Hypotony is another frequent complication of retinotomy that has been reported in up to 43% of cases and is a cause for failure of surgery^{8, 51-54}. In eyes judged to be at high risk of hypotony, removal of lens and IOL and making the eye aphakic along with the use of silicone oil have been advocated⁵⁵.

Choroidal neovascularization has been reported to occur as a complication of access retinotomies^{56,57}.

Another unexpected complication of large retinotomies is earlier emulsification of silicone oil⁵⁸.

The need for performing relaxing retinotomy had been associated with worse visual results in one series⁵⁹. Although some reports have reported correlation between the extent of retinotomy and visual results⁴⁹, some others have found no such association^{42, 52, 53, 60}.

Visual prognosis is usually limited for cases undergoing relaxing retinotomies for PVR^{49, 52, 53, 59, 61, 62}. Superior retinotomies have been found to have better prognosis⁵², possibly due to more complete tamponade with conventional tamponade agents. Also circumferential retinotomies have been reported to be associated with a better visual outcome than radial retinotomies⁵³.

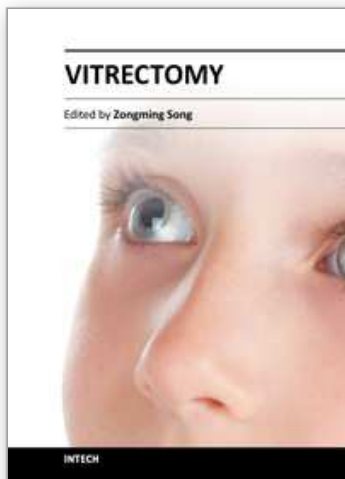9. References

- [1] Machemer R. Retinotomy. *Am J Ophthalmol* 1981;92(6):768-74.
- [2] Tsui I, Schubert HD. Retinotomy and silicone oil for detachments complicated by anterior inferior proliferative vitreoretinopathy. *Br J Ophthalmol* 2009;93(9):1228-33.
- [3] Kaplan HJ, Tezel TH, Berger AS, Wolf ML, Del Priore LV. Human photoreceptor transplantation in retinitis pigmentosa. A safety study. *Arch Ophthalmol* 1997;115(9):1168-72.
- [4] Augustin AJ, Grus FH, Koch F, Spitznas M. Detection of eicosanoids in epiretinal membranes of patients suffering from proliferative vitreoretinal diseases. *Br J Ophthalmol* 1997;81(1):58-60.
- [5] Verma LK, Peyman GA, Wafapoor H, Greve MD, Millsap CM, Adile SL. An analysis of posterior segment complications after vitrectomy using the perfluorocarbon perfluoroperhydrophenanthrene (Vitreon). Vitreon Collaborative Study. *Ophthalmic Surg* 1995;26(1):29-33.
- [6] Larrison WI, Frederick AR, Jr., Peterson TJ, Topping TM. Posterior retinal folds following vitreoretinal surgery. *Arch Ophthalmol* 1993;111(5):621-5.
- [7] Gremillion CM, Jr., Peyman GA. Posterior relaxing retinotomy. *Ophthalmic Surg* 1989;20(9):655-7.
- [8] Alturki WA, Peyman GA, Paris CL, Blinder KJ, Desai UR, Nelson NC, Jr. Posterior relaxing retinotomies: analysis of anatomic and visual results. *Ophthalmic Surg* 1992;23(10):685-8.
- [9] Lesnani G, Billi B, Rossi T, Stirpe M. The use of panoramic viewing system in relaxing retinotomy and retinectomy. *Retina* 1997;17(3):186-90.
- [10] Haut J, Le Mer Y, Monin C, Moulin F, Colliac JP. Twenty-five cases of relaxing retinotomy using a nanosecond Nd Yag laser (Yag-retinotomy). *Graefes Arch Clin Exp Ophthalmol* 1989;227(4):312-4.
- [11] Zhang MN, Jiang CH. 360-degree retinectomy for severe ocular rupture. *Chin J Traumatol* 2005;8(6):323-7.
- [12] Machemer R, Steinhorst UH. Retinal separation, retinotomy, and macular relocation: I. Experimental studies in the rabbit eye. *Graefes Arch Clin Exp Ophthalmol* 1993;231(11):629-34.
- [13] Machemer R, Steinhorst UH. Retinal separation, retinotomy, and macular relocation: II. A surgical approach for age-related macular degeneration? *Graefes Arch Clin Exp Ophthalmol* 1993;231(11):635-41.

- [14] Lewis H, Aaberg TM, Abrams GW, McDonald HR, Williams GA, Mieler WF. Subretinal membranes in proliferative vitreoretinopathy. *Ophthalmology* 1989;96(9):1403-14; discussion 14-5.
- [15] Roth DB, Sears JE, Lewis H. Removal of retained subfoveal perfluoro-n-octane liquid. *Am J Ophthalmol* 2004;138(2):287-9.
- [16] Garcia-Arumi J, Castillo P, Lopez M, Boixadera A, Martinez-Castillo V, Pimentel L. Removal of retained subretinal perfluorocarbon liquid. *Br J Ophthalmol* 2008;92(12):1693-4.
- [17] Tewari A, Elliott D, Singh CN, Garcia-Valenzuela E, Ito Y, Abrams GW. Changes in retinal sensitivity from retained subretinal perfluorocarbon liquid. *Retina* 2009;29(2):248-50.
- [18] Le Tien V, Pierre-Kahn V, Azan F, Renard G, Chauvaud D. Displacement of retained subfoveal perfluorocarbon liquid after vitreoretinal surgery. *Arch Ophthalmol* 2008;126(1):98-101.
- [19] Tabandeh H, Callejo SA, Rosa RH, Jr., Flynn HW, Jr. Subretinal "napkin-ring" membrane in proliferative vitreoretinopathy. *Arch Ophthalmol* 2000;118(9):1287-9.
- [20] Fine HF, Iranmanesh R, Del Priore LV, et al. Surgical outcomes after massive subretinal hemorrhage secondary to age-related macular degeneration. *Retina*;30(10):1588-94.
- [21] Cereda MG, Parolini B, Bellesini E, Pertile G. Surgery for CNV and autologous choroidal RPE patch transplantation: exposing the submacular space. *Graefes Arch Clin Exp Ophthalmol*;248(1):37-47.
- [22] Degenring RF, Cordes A, Schrage NF. Autologous translocation of the retinal pigment epithelium and choroid in the treatment of neovascular age-related macular degeneration. *Acta Ophthalmol*.
- [23] Williams DF, Grand MG, Thomas MA. Trans-pars plana vitrectomy in conjunction with scleral buckling procedures for complicated retinal detachment. *Int Ophthalmol Clin* 1992;32(2):165-71.
- [24] Loewenstein JI, Hogan RN, Jakobiec FA. Osseous metaplasia in a preretinal membrane. *Arch Ophthalmol* 1997;115(1):117-9.
- [25] Kubota A, Harino S, Ohji M, Tano Y. Modified technique to create retinal detachment during macular translocation surgery. *Am J Ophthalmol* 2003;135(1):105-6.
- [26] Ninomiya Y, Lewis JM, Hasegawa T, Tano Y. Retinotomy and foveal translocation for surgical management of subfoveal choroidal neovascular membranes. *Am J Ophthalmol* 1996;122(5):613-21.
- [27] Fastenberg DM, Finger PT, Chess Q, Koizumi JH, Packer S. Vitrectomy retinotomy aspiration biopsy of choroidal tumors. *Am J Ophthalmol* 1990;110(4):361-5.
- [28] Peyman GA. Vitrectomy retinotomy aspiration biopsy of choroidal tumors. *Am J Ophthalmol* 1991;111(1):121.
- [29] Garcia-Arumi J, Sararols L, Martinez V, Corcostegui B. Vitreoretinal surgery and endoresection in high posterior choroidal melanomas. *Retina* 2001;21(5):445-52.
- [30] Ahmadabadi MN, Karkhaneh R, Roohipoor R, Tabatabai A, Alimardani A. Clinical presentation and outcome of chorioretinitis sclopetaria: a case series study. *Injury*;41(1):82-5.
- [31] Akgul H, Otterbach F, Bornfeld N, Jurklies B. Intraocular biopsy using special forceps: a new instrument and refined surgical technique. *Br J Ophthalmol*;95(1):79-82.

- [32] Takaya K, Suzuki Y, Mizutani H, Sakuraba T, Nakazawa M. Long-term results of vitrectomy for removal of submacular hard exudates in patients with diabetic maculopathy. *Retina* 2004;24(1):23-9.
- [33] Lerdvitayasakul R, Lawtiantong T. Removal of submacular cysticercosis: a case report. *J Med Assoc Thai* 1991;74(12):675-8.
- [34] Aras C, Arici C, Akar S, et al. Peeling of internal limiting membrane during vitrectomy for complicated retinal detachment prevents epimacular membrane formation. *Graefes Arch Clin Exp Ophthalmol* 2009;247(5):619-23.
- [35] de Souza OF, Sakamoto T, Kimura H, et al. Inhibition of experimental proliferative vitreoretinopathy in rabbits by suramin. *Ophthalmologica* 1995;209(4):212-6.
- [36] Peyman GA, Nelson NC, Jr., Alturki W, et al. Tissue plasminogen activating factor assisted removal of subretinal hemorrhage. *Ophthalmic Surg* 1991;22(10):575-82.
- [37] Oshima Y, Ohji M, Tano Y. Pars plana vitrectomy with peripheral retinotomy after injection of preoperative intravitreal tissue plasminogen activator: a modified procedure to drain massive subretinal haemorrhage. *Br J Ophthalmol* 2007;91(2):193-8.
- [38] Das T, del Cerro M, Jalali S, et al. The transplantation of human fetal neuroretinal cells in advanced retinitis pigmentosa patients: results of a long-term safety study. *Exp Neurol* 1999;157(1):58-68.
- [39] MacLaren RE, Uppal GS, Balaggan KS, et al. Autologous transplantation of the retinal pigment epithelium and choroid in the treatment of neovascular age-related macular degeneration. *Ophthalmology* 2007;114(3):561-70.
- [40] Hegazy HM, Peyman GA, Liang C, Unal MH, Molinari LC, Kazi AA. Use of perfluorocarbon liquids, silicone oil, and 5-fluorouracil in the management of experimental PVR. *Int Ophthalmol* 1998;22(4):239-46.
- [41] Blumenkranz MS, Azen SP, Aaberg T, et al. Relaxing retinotomy with silicone oil or long-acting gas in eyes with severe proliferative vitreoretinopathy. Silicone Study Report 5. The Silicone Study Group. *Am J Ophthalmol* 1993;116(5):557-64.
- [42] Tseng JJ, Barile GR, Schiff WM, Akar Y, Vidne-Hay O, Chang S. Influence of relaxing retinotomy on surgical outcomes in proliferative vitreoretinopathy. *Am J Ophthalmol* 2005;140(4):628-36.
- [43] Rizzo S, Romagnoli MC, Genovesi-Ebert F, Belting C. Surgical results of heavy silicone oil HWS-45 3000 as internal tamponade for inferior retinal detachment with PVR: a pilot study. *Graefes Arch Clin Exp Ophthalmol*;249(3):361-7.
- [44] Laidlaw DA, Karia N, Bunce C, Aylward GW, Gregor ZJ. Is prophylactic 360-degree laser retinopexy protective? Risk factors for retinal redetachment after removal of silicone oil. *Ophthalmology* 2002;109(1):153-8.
- [45] Williamson TH, Gupta B. Planned delayed relaxing retinotomy for proliferative vitreoretinopathy. *Ophthalmic Surg Lasers Imaging*;41(1):31-4.
- [46] Federman JL, Eagle RC, Jr. Extensive peripheral retinectomy combined with posterior 360 degrees retinotomy for retinal reattachment in advanced proliferative vitreoretinopathy cases. *Ophthalmology* 1990;97(10):1305-20.
- [47] Garcia-Valenzuela E, Ito Y, Abrams GW. Risk factors for retention of subretinal perfluorocarbon liquid in vitreoretinal surgery. *Retina* 2004;24(5):746-52.
- [48] Li KK, Wong D. Avoiding retinal slippage during macular translocation surgery with 360 retinotomy. *Graefes Arch Clin Exp Ophthalmol* 2008;246(5):649-51.

- [49] Iverson DA, Ward TG, Blumenkranz MS. Indications and results of relaxing retinotomy. *Ophthalmology* 1990;97(10):1298-304.
- [50] Han DP, Rychwalski PJ, Mieler WF, Abrams GW. Management of complex retinal detachment with combined relaxing retinotomy and intravitreal perfluoro-n-octane injection. *Am J Ophthalmol* 1994;118(1):24-32.
- [51] Banaee T, Hosseini SM, Eslampoor A, Abrishami M, Moosavi M. Peripheral 360 degrees retinectomy in complex retinal detachment. *Retina* 2009;29(6):811-8.
- [52] Han DP, Lewis MT, Kuhn EM, et al. Relaxing retinotomies and retinectomies. Surgical results and predictors of visual outcome. *Arch Ophthalmol* 1990;108(5):694-7.
- [53] Morse LS, McCuen BW, 2nd, Machemer R. Relaxing retinotomies. Analysis of anatomic and visual results. *Ophthalmology* 1990;97(5):642-7; discussion 7-8.
- [54] Ichibe M, Yoshizawa T, Funaki S, et al. Severe hypotony after macular translocation surgery with 360-degree retinotomy. *Am J Ophthalmol* 2002;134(1):139-41.
- [55] Tseng JJ, Schiff WM, Barile GR, et al. Influence of postoperative lens status on intraocular pressure in proliferative vitreoretinopathy. *Am J Ophthalmol* 2009;147(5):875-85, 85 e1-2.
- [56] Richards SC, Maberley AL. Complications of retinotomies for subretinal fluid drainage. *Can J Ophthalmol* 1993;28(1):24-7.
- [57] McCannel CA, Syrquin MG, Schwartz SD. Submacular surgery complicated by a choroidal neovascular membrane at the retinotomy site. *Am J Ophthalmol* 1996;122(5):737-9.
- [58] Gungel H, Menceoglu Y, Yildiz B, Akbulut O. Fourier transform infrared and 1h nuclear magnetic resonance spectroscopic findings of silicone oil removed from eyes and the relationship of emulsification with retinotomy and glaucoma. *Retina* 2005;25(3):332-8.
- [59] McDonald HR, Johnson RN, Madeira D, Schatz H. Surgical results for proliferative vitreoretinopathy. *Eur J Ophthalmol* 1994;4(4):211-17.
- [60] Bovey EH, De Ancos E, Gonvers M. Retinotomies of 180 degrees or more. *Retina* 1995;15(5):394-8.
- [61] Scott IU, Murray TG, Flynn HW, Jr., Feuer WJ, Schiffman JC. Outcomes and complications associated with giant retinal tear management using perfluoro-n-octane. *Ophthalmology* 2002;109(10):1828-33.
- [62] Scott IU, Flynn HW, Jr., Murray TG, Feuer WJ. Outcomes of surgery for retinal detachment associated with proliferative vitreoretinopathy using perfluoro-n-octane: a multicenter study. *Am J Ophthalmol* 2003;136(3):454-63.



Vitrectomy

Edited by Dr. Zongming Song

ISBN 978-953-51-0546-6

Hard cover, 96 pages

Publisher InTech

Published online 20, April, 2012

Published in print edition April, 2012

This book is a comprehensive and systematic introduction to the basic theory, surgical techniques and the latest advances in vitrectomy. It focuses on vitreoretinal surgical indications and contraindications, surgical and operating techniques, surgery-related complications and their prevention, post-operation evaluation and prognosis. The book is divided into 6 chapters and has abundant content as well as a strong scientific and practical value. This book will be a valuable reference to ophthalmologists on all levels, especially vitreoretinal surgeons and researchers.

How to reference

In order to correctly reference this scholarly work, feel free to copy and paste the following:

Touka Banaee (2012). Retinotomy/Retinectomy, Vitrectomy, Dr. Zongming Song (Ed.), ISBN: 978-953-51-0546-6, InTech, Available from: <http://www.intechopen.com/books/vitrectomy/retinotomy-retinectomy>

INTECH
open science | open minds

InTech Europe

University Campus STeP Ri
Slavka Krautzeka 83/A
51000 Rijeka, Croatia
Phone: +385 (51) 770 447
Fax: +385 (51) 686 166
www.intechopen.com

InTech China

Unit 405, Office Block, Hotel Equatorial Shanghai
No.65, Yan An Road (West), Shanghai, 200040, China
中国上海市延安西路65号上海国际贵都大饭店办公楼405单元
Phone: +86-21-62489820
Fax: +86-21-62489821

© 2012 The Author(s). Licensee IntechOpen. This is an open access article distributed under the terms of the [Creative Commons Attribution 3.0 License](https://creativecommons.org/licenses/by/3.0/), which permits unrestricted use, distribution, and reproduction in any medium, provided the original work is properly cited.

IntechOpen

IntechOpen