

# We are IntechOpen, the world's leading publisher of Open Access books Built by scientists, for scientists

6,900

Open access books available

185,000

International authors and editors

200M

Downloads

Our authors are among the

154

Countries delivered to

TOP 1%

most cited scientists

12.2%

Contributors from top 500 universities



WEB OF SCIENCE™

Selection of our books indexed in the Book Citation Index  
in Web of Science™ Core Collection (BKCI)

Interested in publishing with us?  
Contact [book.department@intechopen.com](mailto:book.department@intechopen.com)

Numbers displayed above are based on latest data collected.  
For more information visit [www.intechopen.com](http://www.intechopen.com)



## A Case Based Approach to Severe Microcytic Anemia in Children

Andrew S. Freiberg  
*Pennsylvania State University*  
 USA

### 1. Introduction

Clinicians are traditionally taught that the differential diagnosis of microcytic anemia is limited to a very few causes, with iron deficiency anemia on top of that list. While this may be true, the specific etiology of these causes and specifically the exact cause of the iron deficiency in each case is of clinical importance, as treatment of the anemia is very different for each cause. Just as the most common reason for severe microcytic anemia at any age is iron deficiency, the most common reasons for that deficiency at any age involve the gastrointestinal tract. The gastrointestinal tract is both the site of iron uptake and the most common site of blood loss. Thus, the gastrointestinal specialist plays a key role in diagnosing and managing microcytic anemia and must understand the various etiologies of microcytic anemia that are likely or possible in the population seen, including those cases that do not have a GI cause. In this chapter we will explain in a case based format the proper workup of the child and adolescent with microcytic anemia, emphasizing the role of the GI tract in the mechanism and of the GI specialist in the diagnosis and management.

### 2. Overview of anemia

Anemia refers to a hemoglobin (Hgb) or hematocrit (Hct) level lower than adult range or the age-adjusted range for healthy children. Normal values also vary depending on the gender and race of the patient. Since the main physiological role of red blood cells (RBCs) is to deliver oxygen to tissues, anemia is a condition where the body's metabolic demands for oxygen may not be adequately achieved. The condition is usually secondary to various pathologic processes and is not considered a disease in itself.

The causes for anemia can be broadly categorized into three pathological processes: decreased or ineffective erythropoiesis, increased hemolysis, and blood loss. However, cases where anemia is multifactorial in origin can exist. Anemia can also be further classified as microcytic, normocytic or macrocytic, referring to the mean corpuscular volume (MCV) which measures RBCs size, ranging from small, normal and large, respectively. This chapter will focus on microcytic anemia in children. The cases and information given are applicable to the general practitioner, but are aimed specifically at the pediatric gastroenterologist, focusing specifically on *severe* anemias that are *severely* microcytic, because these are the cases that impact the gastroenterologist most. An effort will be made to clarify much of the commonly thought but vague and misleading information about this condition.

There have been numerous reviews on the evaluation of anemia and microcytic anemia in children (Jain & Kamat 2009, Janus & Moerschel 2010). Although these reviews attempt to be comprehensive, they tend to be overly simplistic and misleading. Specifically with regard to microcytic anemia, the impression given is that nutritional deficiency is the most frequent cause of iron deficiency and hence microcytic anemia. Although this may be true for mild anemia, it is certainly not true for severe anemia, where blood loss is far more common. While a child with a hemoglobin of 11 g/dL and mild microcytosis may have a lack of sufficient iron in his or her diet, a hemoglobin of 5 g/dL and MCV of 55 fL cannot be due to nutrition alone. Anyone at any age with such values requires investigation for a serious condition and should not be treated with iron supplementation alone. To assume that most cases of microcytosis should be treated with supplemental iron alone is to miss the opportunity and the necessity of the proper workup for significant pathology.

## 2.1 Epidemiology of iron deficiency in children

Iron deficiency and iron deficiency anemia affect a large proportion of people worldwide (Beard & Stoltzfus, 2001; Benoit 2001; Stoltzfus, 2001). According to the Fourth National Health and Nutrition Examination Survey (NHANES IV), iron deficiency without anemia exists in 7% of toddlers aged 1 to 2 years, 9% of adolescent girls, and 16% of women of childbearing age, (Looker, 2002) a true public health concern. Unfortunately, studies of the prevalence of iron deficiency anemia use arbitrary definitions of anemia and iron deficiency, such as a hemoglobin less than 11 (Eden & Mir, 1997). There is often no attempt to separate iron deficiency based on severity, so that the true incidence of *severe* iron deficiency anemia is unknown.

It must be remembered that iron deficiency and iron deficiency anemia are somewhat distinct, but overlapping and related disorders. Although confirmatory studies are lacking, it is probably true that the greatest cause of iron deficiency worldwide and in the United States is nutrition, i.e. lack of sufficient iron in the diet, and the greatest cause of iron deficiency *anemia* worldwide and in the United States is slow gastrointestinal bleeding. Statistics stating the leading causes of these conditions can easily mislead the practitioner, since the epidemiology of iron deficiency and iron deficiency are different, and also varies by age, gender, socioeconomic status and geography. Worldwide, and especially in poor countries, infestation by hookworm (mostly *Necator americanus* and *Ancylostoma duodenale*) is the leading cause of gastrointestinal blood loss leading to iron deficiency and iron deficiency anemia. Infestation by *Trichuris trichiura*, the cause of trichuriasis (whipworm) infection is common throughout many parts of the world, and symptomatic infestations leading to iron deficiency or growth retardation preferentially affect children between 2 and 10 years of age. By contrast, in the United States, parasitic infestation has become distinctly rare due to improved sanitation and the fact that most children in the U.S. now wear shoes when outdoors. In the United States, cultural differences in feeding practices affect the incidence of iron deficiency anemia (Kwiatowski, 1999)

## 2.2 Health effects of iron deficiency

The association between iron deficiency anemia and impaired neurocognitive function is well established, and is independent of psychosocial and environmental factors. The association is especially strong in young children and infants (Osiki, 1979). There is evidence

that iron deficiency that has not progressed to anemia is also associated with poor neurocognitive function (Akman et al., 2004; Cook & Lynch 1986; Grantham-McGregor & Ani, 2001; Oski, 1983, 1985; Pollitt et al., 1986). Many possible mechanisms for the association have been suggested and investigated, but the true etiology is unknown (Beard, 2001; Erikson et al., 2001; Ortiz et al., 2004). Whether and to what extent this poor neurocognitive function can be reversed by correcting the deficiency is debated (Akman et al., 2004; Lozoff et al., 1982, 1996, 2000; Oski, 1983; Walter et al., 1989)

Many types of anemia such as hemoglobinopathies, hemolytic anemias and iron deficiency lead to increased absorption of both iron and lead from the GI tract. Coupled with the increased incidence of pica in these anemias, one effect of anemia, including that due to iron deficiency, is the increased incidence of lead poisoning and its health effects.

### 3. Differential diagnosis of microcytic anemia

Students are traditionally taught that the differential diagnosis of microcytic anemia includes five possible conditions:

1. Iron deficiency anemia
2. Thalassemia trait
3. Lead poisoning
4. Chronic disease
5. Sideroblastic anemia

Figure 1 shows a general schema for distinguishing these disorders based on RBC size (MCV) and hemoglobin level. The figure is not meant to show the exact values for these disorders, but to emphasize the relative values and emphasizes their overlap. After considering some of the disorders that overlap with iron deficiency, this chapter will focus on the severe anemias that are severely microcytic, i.e. those that are most likely due to iron deficiency. Note that lead poisoning is not included in the figure because as explained below it is now considered more of a consequence than a cause of iron deficiency; sideroblastic anemia is also not seen because it is not a distinct condition and thus shows considerable heterogeneity in hemoglobin and MCV. Likewise, bone marrow failure syndromes such as Diamond-Blackfan anemia, the erythropoietin deficiency of end stage renal failure, transient erythroblastopenia of childhood, and leukemia encompass a wide variety of separate disorders with different combinations of MCV and hemoglobin, but none of these are microcytic.

It is important to keep in mind that the presence of one disorder does not exclude others. For example, iron deficiency may occur in patients with thalassemia, and patients may have concomitant acute and chronic bleeding. Also, the relationship is altered by therapy; hence patients who have been partially or inadequately treated may have values that do not fit the expected relationships.

From a practical sense, when considering the above five disorders, the severely microcytic anemias limit this differential for the most part to the top two, and further considering only those that are severely anemic to a large extent eliminates all but the first. As we shall see, a large part of microcytic anemia in children, as in adults, and certainly the severe clinically important cases, is due to iron deficiency anemia. As will be discussed, once iron deficiency

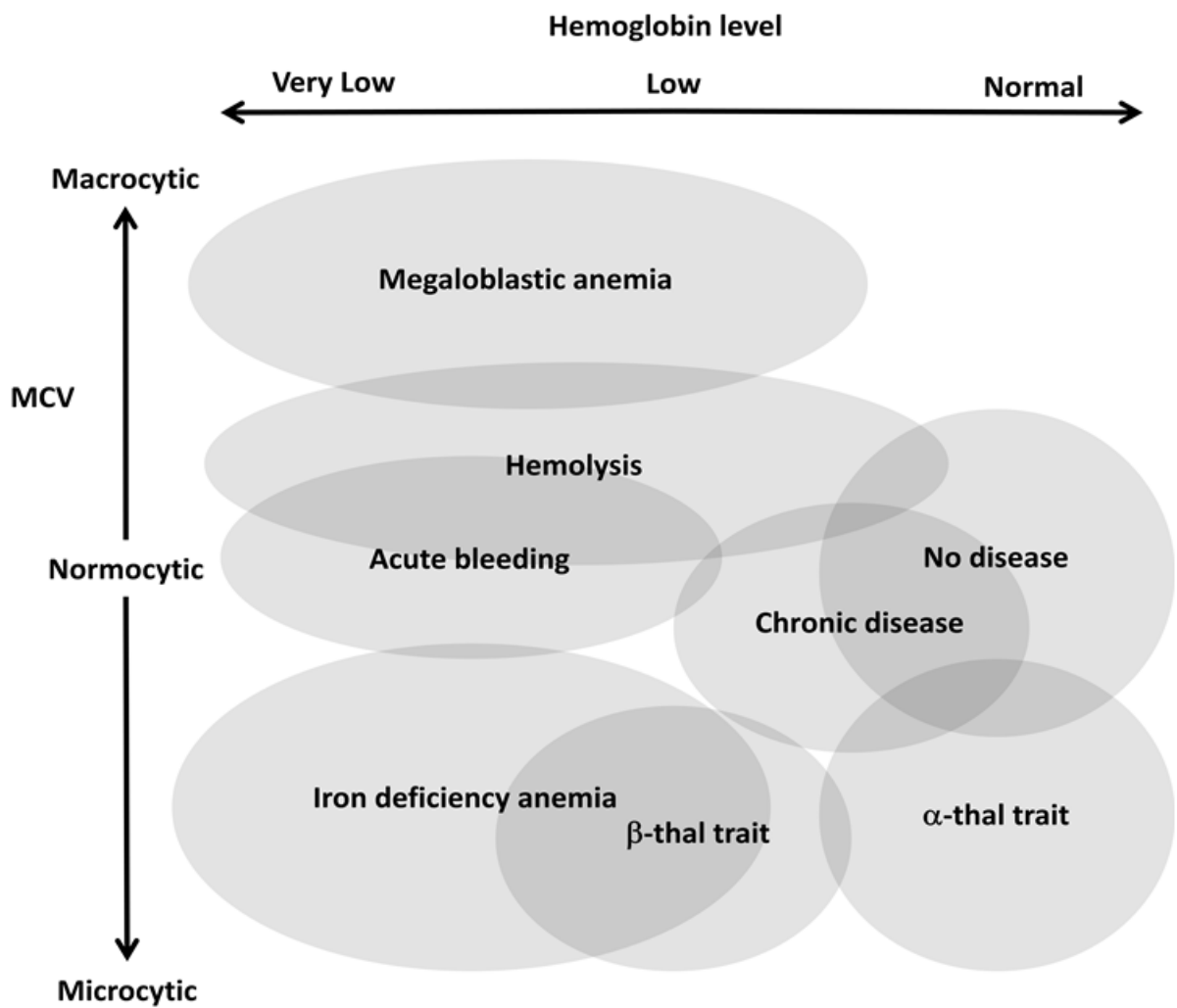


Fig. 1. Approximate relationship of anemias according to hemoglobin and red cell size (MCV)

is determined to be likely, the cause of the deficiency must be determined, and it is important for the clinician to distinguish blood loss from other causes. This list of causes varies depending on the age of the patient, the severity of the anemia and the severity of microcytosis. The chapter will outline a more thorough differential for all causes, leading towards a proper diagnosis before initiating treatment. We will emphasize that iron therapy alone is not adequate therapy; as such treatment alone will leave the cause of the anemia undiagnosed and untreated.

3.1 Acute blood loss

Since iron deficiency anemia is almost always due to chronic blood loss, the distinction between acute and chronic blood loss must be made. While both lead to anemia, the causes as well as the signs and symptoms are profoundly different between the two. As to the cause, acute blood loss can occur externally by any route or internally into practically any space, including intracranial, intrathoracic, retroperitoneal and abdominal. Isolated acute blood loss is normocytic, with a reticulocyte count that is not elevated until several days

after the event, providing the patient survives and has adequate iron stores, i.e. there is not coexistent chronic blood loss. Therefore the anemia of acute blood loss is due to blood loss, while the anemia of iron deficiency is due to iron loss, and is in fact a bone marrow failure syndrome limited to red cells due to lack of substrate (iron).

Signs and symptoms of acute blood loss are very different from those of chronic blood loss. Acute blood loss leads to volume depletion and can rapidly progress to tissue hypoperfusion and shock, while the slow onset of anemia that occurs with chronic blood loss allows hemodynamic compensation. Children especially can tolerate extremely low hemoglobins if gradual in onset, without cardiac decompensation and no end organ effects. These children will appear pale, and have compensatory tachycardia, and may have dyspnea and headache on exertion, but very small children may have no signs other than pallor and mild fussiness. Some children will appear “yellow” due to underlying skin pigmentation, especially if the diet includes yellow vegetables, but actual jaundice is easy to exclude due to the lack of scleral icterus.

We will now discuss in some detail the five traditional causes of microcytic anemia, using some specific cases to illustrate.

### 3.2 Sideroblastic anemia

The sideroblastic anemias are a heterogeneous group of congenital and acquired bone marrow disorders defined by the presence of pathologic iron deposits within the mitochondria of erythroid precursors. The anemia may be mild, moderate or severe and may be normocytic, microcytic, or macrocytic and is typically characterized by a relative reticulocytopenia (Flemming, 2009). There are several known and incompletely characterized congenital causes, but all are rare including atransferrinemia, hypotranferrinemia (Shamsian et al., 2009), and others (Iolascon et al., 2009). Acquired causes include a variety of toxic exposures, drugs, and myelodysplastic syndromes, as well as copper deficiency. Many of these, although included in a full discussion of anemia and microcytic anemia, do not need to be considered in this chapter because they only rarely present as a severe anemia that is severely microcytic. Copper deficiency, for example is extremely rare, is usually normocytic, and the major manifestations are neurologic rather than hematologic.

### 3.3 The anemia of “chronic disease” (Case 1)

A 10 year old boy was referred to pediatric hematology clinic for anemia occurring on a previous blood test. Two months earlier he had been hospitalized briefly for a high fever and rash. While in the hospital, a CBC showed a mild microcytic anemia (hgb 10.0 g/dL (normal 11.9-15.4 g/dL), MCV 75 fL (normal 80-95 fL). He recovered well and was subsequently discharged. He had since been well, with no subsequent fevers, and no weight loss or night sweats. He had had no increased fatigue or exercise intolerance. His family history was negative for any hematologic disorders or malignancies. He had no chronic medical conditions, took no medications, and had no known drug allergies.

In clinic, he appeared healthy, cooperative and in no distress. His skin showed no rash, bruises, jaundice, or pallor. He had no lymphadenopathy, scleral icterus, or conjunctival pallor. His lungs were clear with no wheezes, and his heart sounds were normal with no

murmur. His abdomen was soft and nontender with no organomegaly, although his liver was palpable and slightly tender to palpation, but his spleen was not palpable. His extremities were well perfused with no edema. Two months after his original CBC his hemoglobin had risen to 11 g/dL (normal 12-15 g/dL), and MCV was 72.9 fL (normal 74-82). His ferritin was 38 ng/mL (normal 10-200 ng/mL). Iron studies were normal as was his hemoglobin electrophoresis and blood smear.

### 3.3.1 Discussion

Typically the anemia of chronic disease, also called the anemia of inflammation, is a mild normocytic or mildly microcytic anemia. Usually it is associated with chronic conditions such as IBD, and the anemia resolves with effective treatment of the underlying condition. As this case illustrates however, the anemia of “chronic” disease can be associated with inflammatory conditions of shorter duration such as chronic strep infections, recurrent otitis media, or viral infections. The RDW is often slightly elevated as a result of slight anisocytosis, reflecting ineffective iron recycling. The anemia itself is mild and asymptomatic and will not respond to iron unless there is concomitant iron deficiency. Since ferritin is an acute phase reactant, an elevated level does not imply the patient has adequate iron stores, but a low level indicates inadequate stores. Again, this type of anemia is included in a full discussion of microcytic anemia in children, but will not be discussed further in this chapter because the anemia by itself does not have the features that would or should bring it to the attention of a gastroenterologist, i.e. by the severity of the anemia or the microcytosis, although the underlying inflammatory condition itself may involve the GI tract. Distinguishing iron deficiency from the anemia of inflammation is usually not difficult from the history and CBC, but serum transferrin receptor (sTfR) levels, if available, have been shown to help distinguish them (Oliveras et al., 2000; Skikne, 1998, Vazquez et al., 2006).

### 3.4 Lead poisoning

The association between lead poisoning and microcytic anemia has long been assumed to be a direct inhibition of lead on heme synthesis, leading to a sideroblastic effect. This mechanism is supported by the basophilic stippling present and the markedly elevated free erythrocyte protoporphyrin values in these patients. More likely, however, the lead poisoning is a secondary effect of severe iron deficiency. The mechanism is twofold, in that severe iron deficiency increases the incidence of pica (Buchanan, 1999, 2003; Eden, 1999), and increases the absorption of lead from the gut. The incidence of Pica may be higher than generally assumed (Corbett et al., 2003). The precise pathophysiology of Pica is unknown, but is probably related to CNS iron deficiency. Patients often consume laundry starch, ice, soil, or clay. Both clay and starch can bind iron in the gastrointestinal tract and exacerbate iron deficiency (Crosby, 1982; Gonzalez et al., 1982; Thomas et al., 1976). At any concentration of lead, inhibition of ferrochelatase is most marked when the iron concentration is lower (Piomelli et al., 1987), but the neurologic effects of lead may be severe in the absence of anemia in children. Thus, it is important to address both the lead poisoning and the anemia and to find and treat the cause of the bleeding rather than solely addressing the lead poisoning. There is evidence that replacing iron in patients with concomitant iron deficiency and lead poisoning helps the body eliminate lead (McGeehan, 2003; Rondó et al., 2006; Wright et al., 2003).

### 3.5 Thalassemia trait (Case 2)

A 23 month old girl was referred to Pediatric Hematology for investigation of anemia. Thalassemia was suspected due to a family history of "Mediterranean anemia." Her father and some of his family members were known to be a carrier for thalassemia. He had been treated with high dose iron, but said that it did not help and made him ill. His family was originally from Sicily, where he lived for 8 years. She had no siblings.

The patient had generally been healthy, with normal growth and development, except for a brief febrile seizure a few months earlier. Her diet included fruits, vegetables, pasta, and lentils. She took no medications. On exam, she appeared healthy and alert. She was engaging and playful. She was slightly pale but showed no signs of icterus, petechiae, or ecchymoses. She had no adenopathy or splenomegaly. Her heart rate was regular, and her lungs were clear.

Screening lab work was remarkable for a mild anemia that was severely microcytic with a hemoglobin of 11 g/dL (normal 10.5-14 g/dL), MCV 60.2 fL (normal 70-90 fL) a year earlier and more recently 9.6 g/dL and 54.9 fL. A hemoglobin electrophoresis was remarkable for an elevated hgb A2 of 5.5 percent. Molecular studies had been done and showed that she was a carrier of two separate thalassemia mutations.

#### 3.5.1 Discussion

This patient is a carrier of beta thalassemia, as is clear from the history as well as lab results. The clue is the relatively mild anemia with severe microcytosis. The blood smear in thalassemia trait typically has significant target cells present, and usually a hemoglobin electrophoresis shows an elevated hemoglobin A2 or F percentage. More quantitative ways to distinguish thalassemia trait from iron deficiency include the Mentzer index (Mentzer, 1973), as well as a variety of other methods of varying degrees of sensitivity and specificity (Demir et al. ,2002; Piomelli et al., 1976). The Mentzer index is calculated as the MCV divided by the RBC; a value over 13 is somewhat predictive of iron deficiency, while a value below 13 is more typical of beta thalassemia trait. Unfortunately in a practical sense, many cases fall near the line, especially those that are not clinically obvious one way or the other. The RDW is of limited use since it is increased in iron deficiency as well as a variety of hemoglobinopathies including thalassemia.

The presence of thalassemia trait does not exclude iron deficiency, which usually can be ruled out with a ferritin level and iron studies. Without iron deficiency, regular iron supplementation should not be given; not only will iron not improve the mild anemia, but over time could lead to iron overload, particularly because the mild anemia causes increased iron absorption from the gut. Thalassemia trait itself requires no therapy or follow-up, but genetic counseling should be considered because of the risk of having children with thalassemia major. To avoid unnecessary lab evaluations and therapy, the patient and family need to have a clear understanding of these points. Iron or folic acid deficiency, pregnancy or intercurrent illness may exacerbate the anemia in patients with thalassemia trait. The specific clinical phenotype depends on the precise genetic defect in heterozygous and especially homozygous individuals. In patients with microcytosis, hypochromia and erythrocytosis but without evidence of iron deficiency or elevated hgb A2 and Hgb F levels, one of the alpha thalassemia carrier states is likely. These too are benign conditions where proper genetic and medical counseling of the patient and family is imperative.

#### 4. Iron deficiency

As is evident above, cases of microcytic anemia that are NOT due to iron deficiency are usually easy to distinguish. The remaining cases in this chapter are all due to iron deficiency. With two notable exceptions, severely microcytic severe anemias in children are due to chronic gastrointestinal blood loss. Figure 2 shows the relative frequencies of the major causes of iron deficiency anemia to be explained in the following sections, illustrating the 2 major sites of blood loss (gastrointestinal and vaginal) and the two major gastrointestinal etiologies (blood loss and iron malabsorption).

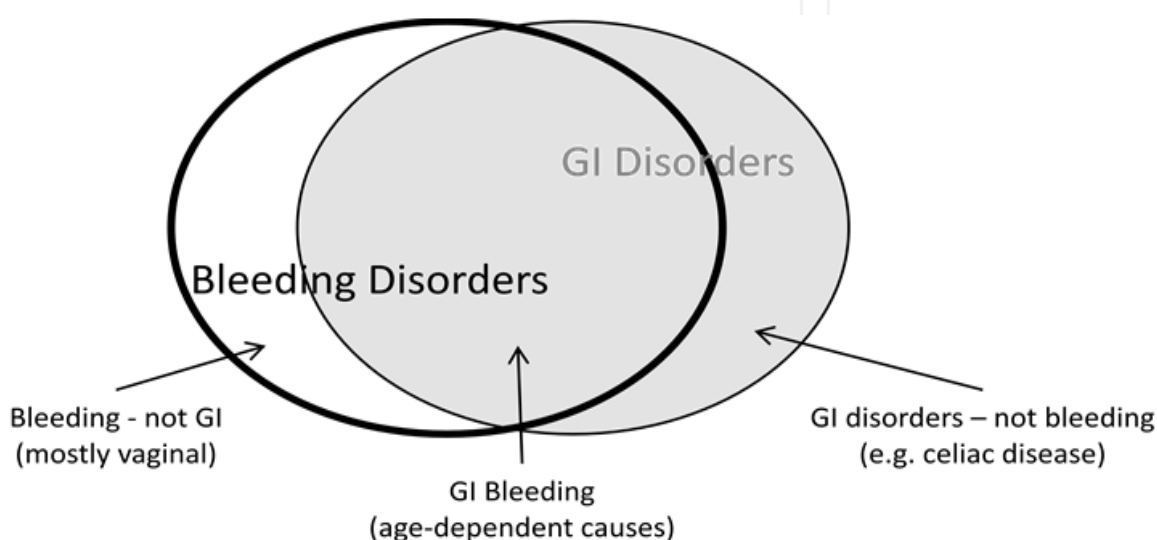


Fig. 2. Relative frequencies of causes of iron deficiency anemia (not to scale)

Because so much of the body's iron resides in hemoglobin, anemia is one of the first signs of iron deficiency, but anemia is actually a late stage of iron depletion. Iron deficiency leading to anemia is a continuum, but there are three recognized phases:

1. *Prelatent iron deficiency* occurs when tissue stores are depleted, without a change in hemoglobin level. The serum ferritin level will be low.
2. *Latent iron deficiency* occurs with depletion of iron from the reticuloendothelial system. TIBC increases and the serum iron level will fall as newly produced erythrocytes will be iron deficient, but the overall hemoglobin level and MCV remain normal.
3. *Iron deficiency anemia* occurs when a substantial portion of the erythrocyte population is affected, resulting in anemia, microcytosis and hypochromia.

With adequate treatment, these stages occur in reverse, i.e. the anemia resolves before adequate iron stores are replenished.

Several pediatric cases will be presented and discussed to illustrate the importance of the gastrointestinal tract in severe iron deficiency anemia. However, the initial case is of severe microcytic anemia occurring in an adult to make the connection between microcytic anemias and gastrointestinal blood loss clear.

### 4.1 Severe microcytic anemia in an adult (Case 3)

A 63 year old male presented to his physician with complaints of fatigue and shortness of breath, progressive over several weeks. The physician noted that the patient looked pale and ordered a complete blood count. The CBC revealed a hemoglobin of 5.9 g/dL and an MCV of 59 fL. The physician correctly interpreted this as a severe microcytic anemia, and that this anemia was of relatively recent onset. The physician considered transfusions and a prescription for oral iron as therapy for the anemia. However, upon considering the etiology of the anemia with the above history, he knows that the microcytosis is not consistent with a lesion leading to acute blood loss. Chronic blood loss is the only possibility, and that blood loss MUST be gastrointestinal. He referred the man to a gastroenterologist for a thorough investigation.

#### 4.1.1 Discussion

For this patient, while several more benign lesions leading to chronic blood loss can be responsible, the lesion must be found, as colon cancer must be considered highly likely until proven otherwise. The sequence of events is therefore clear: The patient has developed a lesion in his GI tract that has been losing blood slowly over at least several months. Since the blood loss is relatively slow, the patient's bone marrow easily makes up for the anemia at first, but eventually stores of iron are depleted from his liver and other sites. At that point his anemia becomes more severe and begins to be microcytic, until the anemia itself becomes severe enough to cause the complaints that lead him to seek help from his physician. In retrospect the patient may or may not have noticed the typically black or tarry stools, depending on the rate of bleeding, and in fact the stool may not even consistently test positive for blood since the bleeding is often intermittent. In fact, testing the stool for blood in such a case is not necessary, as there can be no other cause of this type of anemia in this man but gastrointestinal bleeding. A negative stool test is in no way reassuring; this man must be referred to find the specific lesion. Transfusion and iron therapy do not treat the bleeding. It should even be stated that in such a case of anemia the hematologist plays no role. At any age the more severe the anemia and the microcytosis, the more likely that blood loss rather than a nutritional cause is the responsible mechanism.

The following pediatric cases will use the same concepts illustrated in the above case to emphasize the role of the gastroenterologic system in the etiology and therapy of severe microcytic anemias.

### 4.2 Milk enteropathy (Case 4)

A 14 month old boy presented to his pediatrician for a one year well child checkup. At the visit however his parents explained to the pediatrician that he had been pale for about the last month or so, not feeding well, and had some pica like behaviors. He had recently been more fussy and was sleeping poorly. They denied any jaundice, change in bowel or urinary habits or breathing difficulties. They denied bloody or black stools. They reported poor feeding when offered a variety of foods, and until very recently his diet relied heavily on milk, and he would typically go through a gallon every other day. The family lived in an older apartment with chipping paint that the parents admitted the child sometimes peeled from the walls. His growth and development had otherwise been normal. He took no

medications and had no known allergies. He had three healthy half siblings. His mother was of German ancestry and had been anemic herself in the past. The father also denied any significant family history.

In clinic, the patient was alert and active but fussy during the exam. He was markedly pale, with no jaundice, bruising, petechiae, or rash. His tympanic membranes and oropharynx were clear. He had no adenopathy. His lungs were clear with no wheezes, and heart sounds were normal with no murmurs. His abdomen was soft and nontender with no hepatosplenomegaly. His extremities were well perfused with no edema.

Blood work was remarkable for a hemoglobin of 4.7 g/dL and MCV of 63 g/dL, a severe (and severely microcytic) anemia. His CBC was otherwise unremarkable except for red cell morphologic abnormalities consistent with severe iron deficiency. A serum lead level was only 4 mcg/dL.

The patient had a severe microcytic, hypochromic anemia, but was well compensated with no sign of heart failure. His parents were instructed to stop his milk entirely and he was started on therapeutic iron supplements. They were instructed that concomitant intake of orange juice would aid absorption of the iron. Follow-up labs were planned to assure his anemia was improving, but the plan was for him to continue taking the iron for several months after his anemia resolved, in order to replenish his iron stores. Milk could be added back to the diet, but only with meals, as soon as the anemia had begun to improve.

#### 4.2.1 Discussion

This child presents with a common cause of iron deficiency anemia in the 1-2 year old. Just as in the adult male in the first case above, he has an *acquired, severe* anemia that is *severely* microcytic, and by far the most likely cause is chronic gastrointestinal blood loss. And like the adult, this child requires a GI workup. However, in this case an adequate workup consists mostly of the history of excess milk consumption along with the physical exam and some simple labs to classify the severity and type of anemia, so no referral to a pediatric gastroenterologist is required, and endoscopic procedures are not needed. If the history of excessive milk consumption were not present, then such a referral would be required, and procedures such as a Meckel's scan or endoscopy would be needed to find another cause, i.e. a specific gastrointestinal lesion.

Consumption of cow's milk may contribute to iron deficiency through several mechanisms. Whole milk given to young infants under a year of age, especially under 6 months of age, leads to iron deficiency anemia (American Academy of Pediatrics, 1992; Chessare, 1988; Fomon et al., 1981; Tunnessen & Oski, 1987; Wilson et al., 1964). Cow's milk and human milk both have low iron content, but the bioavailability of iron in human milk is greater. (Picciano & Deering, 1980) Cow's milk also replaces iron-rich foods in the diet. In addition, components in cow's milk such as calcium and caseinophosphopeptide can directly interfere with iron absorption (Ani-Kibangou et al., 2005; Hallberg et al., 1992). For severe anemia, these mechanisms can exacerbate the anemia, along with increased demand from the neonatal growth spurt, but the major mechanism is direct gastrointestinal bleeding.

Whole milk protein causes an enteropathy in the immature gut that leads to GI bleeding. What is not generally understood however is that these same effects continue into the

second year of life for some children, so that *excessive* whole milk given to some toddlers causes an enteropathy with enough chronic blood loss to create severe iron deficiency anemia (Buchanan, 1999; Kwiatowski et al., 1999). For these severe anemias the cause is often misunderstood to be “nutritional” due to the above mechanisms of poor iron bioavailability and absorption. While inadequate iron in the diet might lead to a mild iron deficiency, the severe anemia in the case above can only be caused by chronic gastrointestinal bleeding. As for the adult, testing for occult blood is not needed. The etiology of the blood loss is exposure of the gut to the excessive milk protein. Treatment includes iron supplementation, but the enteropathy must be treated as well, by removing the excess milk from the diet. Transfusion therapy is usually not needed regardless of how low the hemoglobin, unless signs of decompensation such as heart failure are present, and in those cases must be done cautiously. A reasonable approach in these severe cases is to stop the milk entirely and provide therapeutic iron. After several weeks, when labs indicate improvement in the hemoglobin from the therapeutic iron, milk can be restarted, in moderate amounts with meals.

Compliance with iron therapy can be an issue, especially in this age group. Intravenous iron can be considered in these cases, or other forms of iron such as heme iron (Proferrin®, Colorado Biolabs, Inc.), (Nissenson et al. , 2003) that can be more palatable and well absorbed with fewer side effects, but efficacy studies in children are lacking.

#### 4.3 Crohn's disease (Case 4)

A 14-year-old male was seen in pediatric hematology clinic in consultation for anemia. A month earlier he had had two episodes of pneumonia and bronchitis that were treated with antibiotics. He then started complaining of fatigue, prompting a CBC that revealed microcytic anemia that was subsequently shown to be due to iron deficiency.

The patient reported a long history of diarrhea once or twice a day, associated with bloating and cramping, especially after eating but could not relate it to any particular food. He denied any history of bloody stools, hematuria, or mucosal bleeding. There was no history of fevers, weight loss, cough, or difficulty breathing, and the rest of the review of systems was negative. His development had been normal. He had had no previous hospitalizations or surgeries. His immunizations were up-to-date. His only current medication was iron 325 mg PO daily started a week prior.

The patient had four healthy sisters. His mother had a history of iron deficiency with heavy periods but there was no other history of anemia in the family. His paternal grandfather has a history of diverticulitis and a cousin of his father had a history of Crohn's disease.

On exam his weight was 59.5 kg, between the 25th and 50th percentiles for age. His exam was mostly normal, with some voluntary guarding but no obvious abdominal tenderness, masses or organomegaly. Abdomen was nondistended, soft, nontender, with active bowel sounds. His extremities showed full range of motion of all joints, nontender, and well perfused, and his neurologic exam was grossly intact.

His CBC was normal except for a microcytic anemia (hgb 10.2 g/dL, MCV 67.1 fL), and a mild thrombocytopenia, all consistent with iron deficiency anemia. Hemoglobin electrophoresis was normal and his blood smear was normal.

The patient was referred to Pediatric Gastroenterology where endoscopic exam showed mild esophagitis, chronic gastritis, a normal duodenum, lymphoid aggregates and a focal granuloma in his colon, consistent with Crohn’s disease. Medical treatment was successful in alleviating his symptoms and his anemia.

4.3.1 Discussion

This boy presented with an acquired moderate anemia that was severely microcytic. As with the previous two cases, chronic slow gastrointestinal bleeding is the likely cause, leading to iron loss, eventually leading to depletion of stores of iron and the characteristic anemia. A full discussion of the pathophysiology and therapy of Crohn’s disease and inflammatory bowel disease is beyond the scope of this chapter but the hematologic manifestations are likely due to the slow blood loss, although the anemia of inflammation may play a role as well.

4.4 Iron deficiency from gastrointestinal bleeding – Summary

In all three of these cases, the microcytic anemia was due to slow gastrointestinal blood loss, although the specific cause of the blood loss was different, and to a large extent age dependent. The approach to the underlying cause is therefore age dependent:

Toddler	Excessive whole milk ingestion
	Other causes, e.g. Meckel’s diverticulum
School age/Teen	Inflammatory bowel disease
	Menorrhagia
	Other causes, e.g. AV malformation, ulcer
Adult	Colon Cancer
	Other causes, e.g. ulcer

One common feature of the above cases is that although all presented with a severe microcytic anemia, none of the underlying causes were fundamentally hematologic in nature. Therefore in the overwhelming majority of cases of microcytic anemia, these patients have a gastrointestinal cause (slow gastrointestinal blood loss) and need to be referred to a gastroenterologist for diagnosis of the underlying cause. There are two exceptions to the above generalizations. One is a special case of non gastrointestinal blood loss, and the other is due to a defect in iron absorption, although even that cause is still gastrointestinal. These exceptions are illustrated in the two cases below:

5. Iron deficiency not due to gastrointestinal bleeding

5.1 Menorrhagia (Case 6)

A 12-year-old female was referred to pediatric hematology clinic for a possible bleeding disorder. She had had heavy menstrual periods since menarche 6 months previously. She had been admitted to a local community hospital 4 months earlier at which time she was

found to be profoundly anemic with a hemoglobin of 5.9 g/dL, MCV 68.2 fL with symptoms of anemia requiring several blood transfusions. She was started on oral birth control pills with resolution of her menorrhagia. She was also started on daily iron sulfate tablets.

Apart from dysfunctional uterine bleeding, the patient did not have a past medical history of bleeding problems, nosebleeds, easy bruising, petechiae or mucosal bleeding. She denied any loose, bloody, tarry stools or abdominal pain. She had no food allergies. She was healthy before the onset of menarche except for daily headaches which had been evaluated by CT. Her father said he experienced similar headaches as an adolescent. Her father denied a family history of bleeding disorders or menorrhagia. She was doing well in 7<sup>th</sup> grade and enjoyed cheerleading.

In clinic the patient was alert and in no apparent distress. She was afebrile, with normal vital signs. Skin was unremarkable with no petechiae or bruising. Her conjunctivae were pink without pallor. Abdomen was soft, nontender, nondistended without hepatosplenomegaly. A comprehensive coagulation workup showed no evidence of a systemic bleeding disorder. At the time of her visit to pediatric hematology clinic her hemoglobin was 12.5 g/dL, MCV 82.4, fL, both normal. A ferritin level was normal.

### 5.1.1 Discussion

As demonstrated by the first three cases above, acquired severe microcytic anemias are almost always due to chronic gastrointestinal blood (i.e. iron) loss. One notable exception is demonstrated in this case, in which the route of bleeding is vaginal. There is a common misconception that menstruating females have lower average hemoglobin levels because of normal menstrual bleeding. While there is overlap between the normal ranges of males and female hemoglobins, the lower average values in females are due to lower testosterone levels, not vaginal bleeding. Hence adults have higher hemoglobins than children, and males have higher values than females. Normal menstruation can lead to iron deficiency but not anemia; therefore actual anemia implies abnormal bleeding. Abnormal bleeding can be an acute vaginal hemorrhage from a single or a few heavy periods, but it is chronic bleeding from many heavy periods that leads to iron deficiency anemia, as in this case.

As most cases of severe microcytic anemia have a GI cause, a gastroenterologist rather than a hematologist should be involved. Dysfunctional uterine bleeding requires a gynecologic workup, but a proportion of these cases have an underlying bleeding disorder, so it is these cases that should also be referred to a hematologist for an adequate workup for conditions such as von Willebrand's disease and platelet function disorders. Women with menorrhagia, especially if present since menarche, have an incidence of von Willebrand's disease of around 13%, considerably higher than the general population incidence of 1% to 2% (Kadir et al., 1998; Lukes et. al., 2005). For the most part however, the management involves oral contraceptive pills. It should be noted that if there is not a convincing history of several heavy periods, a gastrointestinal cause should still be sought.

Other causes of chronic bleeding and iron loss leading to iron deficiency anemia are rare and usually obvious from the history. Iron deficiency and iron deficiency anemia can result from pulmonary hemosiderosis and from renal bleeding in Berger's disease. These rare

routes should be considered if the history is not consistent with the more common causes or if the patient does not respond adequately to therapy.

## 5.2 Celiac disease (Case 7)

A five year old boy presented to his primary care physician with pallor and was found to have a severe microcytic anemia. Stool was negative for occult blood. He was referred to a pediatric hematologist who diagnosed iron deficiency anemia. He had occasional complaints of abdominal pain but no vomiting, diarrhea or constipation. He had not lost any weight but had grown poorly over the past year, falling from the 60<sup>th</sup> to the 30<sup>th</sup> percentile for weight and the 50<sup>th</sup> to the 40<sup>th</sup> for height. He was referred to a pediatric gastroenterologist, where further studies were done, including an endoscopy showing villous atrophy with increased numbers of intraepithelial lymphocytes consistent with celiac disease. He was placed on a gluten free diet. Three months later his hemoglobin was normal and his weight had increased to the 50<sup>th</sup> percentile.

### 5.2.1 Discussion

Although chronic gastrointestinal bleeding is the major cause of severe iron deficiency anemia, there are notable exceptions that involve the GI tract, and lead to severe anemia due to poor iron absorption alone. The model disorders that fit into this category are celiac disease and tropical sprue (Lombardo, 2006). Celiac disease has been shown to be a relatively common cause of anemia in adults, and therefore may be underdiagnosed in children; it is increasingly recognized as presenting with a spectrum of severity (Van Heel, 2005). Genetics play a strong role in susceptibility but the full genetic pattern is incompletely understood.

Iron absorption may also be disrupted when substantial segments of bowel, particularly the proximal duodenum, are removed surgically. Intractable inflammatory bowel disease, traumatic abdominal injury, and structural defects such as intestinal volvulus or intussusception, as well as necrotizing enterocolitis and typhlitis may necessitate intestinal resection, leading to a defect in iron absorption that may take years to manifest clinically. There are also rare gastrointestinal disorders leading to either malabsorption of iron or chronic blood loss or both, such as collagenous gastritis (Suskind et al., 2009), epidermolysis bullosa (Fridge & Vichinsky, 1998) and short gut syndromes.

To the general practitioner however, it is enough to remember that unless dysfunctional uterine bleeding is elicited from the history, or for any male or prepubertal female, the cause of any *severe, acquired severely microcytic* anemia must be gastrointestinal, which should guide the appropriate referral.

## 6. Initial workup of suspected anemia in children

In a child with suspected anemia based on history and exam, a minimal workup should be obtained. The goal is to characterize the anemia, and to evaluate the other cell lines (platelets, granulocytes) that define bone marrow function. In most cases a CBC with differential, reticulocyte count, iron panel, ferritin level, and lead level give a strong indication as to the cause and define the therapy.

In general, the more cell lines that are depressed, and the lower the values, the more likely is an underlying marrow disease. Hence, pancytopenia (neutropenia, anemia, and thrombocytopenia) makes leukemia more likely while an isolated single cytopenia (neutropenia, anemia, or thrombocytopenia) makes a peripheral disorder outside the marrow more likely. If leukemia or a primary marrow failure is suspected, referral to a pediatric hematologist/oncologist should be made promptly for further testing, including a marrow evaluation. An isolated severe microcytic anemia is not consistent with leukemia and indicates slow blood (i.e. iron) loss (gastrointestinal or vaginal), or in the case of celiac disease, lack of iron absorption. The severe depletion of iron leads to marrow failure in a sense, in that the marrow is unable to complete heme synthesis. Despite the marrow "failure," further marrow evaluation of marrow function is not part of the evaluation, as the underlying cause is entirely outside the marrow.

In iron deficiency anemia a clue to otherwise normal marrow function is often provided by a "left shift" of the other cell lines; leukocytosis, elevated neutrophil count, increased bands and other immature forms, and an elevated platelet count with large platelets. The reticulocyte count is often only mildly elevated, reflecting the lack of iron substrate. Hemolytic anemias such as sickle cell disease, autoimmune hemolytic anemia and hereditary spherocytosis also shift cell lines to the left, but are not microcytic and present with a much higher reticulocyte count. A high reticulocyte count makes a hemolytic anemia likely, especially if the anemia is normocytic or mildly macrocytic. B12 and folate deficiency are not microcytic and are considerably rarer than iron deficiency. The iron panel is usually consistent with other studies, but serum iron may be misleading, as recent ingestion of iron may elevate the value. Ferritin, as an acute phase reactant, may also be elevated in a deficiency state, but low values always represent iron deficiency, and occur in no other condition. A lead level should be considered, not as a cause of microcytic anemia, but because of its association with iron deficiency due to pica and increased lead absorption, especially in small children.

Children, especially the very young tolerate chronic anemia extremely well. It is not unusual for a toddler with a hemoglobin well below five to act perfectly normal, with the very slow onset of pallor as the only manifestation of the anemia. Some fussiness and irritability might be noticed in retrospect. Often these children appear yellow due to underlying normal pigments. True jaundice can be ruled out if the sclerae are white, and lab evaluation of liver function is therefore not necessary. Hepatosplenomegaly is unusual, as is true decompensation e.g. heart failure, but shortness of breath on exertion and headache are common in older children and young adults.

## 7. Therapy of iron deficiency anemia

The therapy of iron deficiency anemia is strongly guided by the cause. Iron therapy is only part of the treatment. For mild anemias due to previous iron loss that has resolved, oral iron is all that is required. If bleeding is ongoing, iron may partially correct the anemia without affecting the underlying cause, leading to delay in diagnosis and therapy of the underlying cause. The most egregious example is the adult with colon cancer; Iron therapy alone would allow the cancer to progress without diagnosis.

Transfusions are usually not required, especially in children, but should be considered in cases of decompensation or heart failure. It is said that transfusions for chronic anemia in

children are given because of the elevated heart rate of the doctor, rather than the patient. If used, packed red cells should be given slowly under the direction of a pediatric hematologist or other experienced clinician to avoid the risk of fluid overload due to the hyperdynamic state of chronic severe anemia.

Response to therapy depends on the disorder, the severity of the deficiency and compliance, not only with the prescribed iron, but in removing the bleeding source. Especially in children whose bleeding is due to excess whole milk, the response to oral iron will be slow or nonexistent if the milk intake is not severely cut back or eliminated from the diet. Intake of acid foods such as orange juice aid iron absorption, and hypochlorhydric states, such as produced by proton pump inhibitors, has been reported to impair absorption (Sharma et al., 2004). The amount of iron in typical vitamin supplements (about 10 mg of elemental iron daily), while sufficient to prevent deficiency, is well below the 3-6 mg *per kg* required as treatment. If compliant with therapy, the hemoglobin should rise by 1 g/dL or more during the first week, along with an increased reticulocyte count, and the hemoglobin should be nearly normal by 4-6 weeks. Iron therapy should be continued for several weeks beyond normalization of the hemoglobin, as pointed out previously, in order to replenish iron stores in the body.

## 8. Conclusion

Iron deficiency anemia is the leading cause of microcytic anemia when both the anemia and the microcytosis are severe. Regardless of the age of the patient, gastrointestinal disorders are the most frequent causes, and most of these are due to chronic gastrointestinal bleeding. The frequency of the specific causes of the bleeding varies with age. In most cases of severe microcytic anemia in children, as in adults, referral to a gastroenterologist is appropriate or required.

## 9. Acknowledgment

I thank Eric Vargas for his help in initiating this project.

## 10. References


- Akman, M.; Cebeci, D.; Okur, V.; Angun, H.; Abali, O. & Akmun, A. (2004). The Effects of Iron Deficiency on Infants' Developmental Test Performance. *Acta Pædiatr*, Vol.93, No.10, pp. 1391-6, ISSN 0803-5253
- American Academy of Pediatrics Committee on Nutrition (1992). The Use of Whole Cow's Milk in Infancy. *Pediatrics*, Vol 89, No.6, pp. 1105-1109, ISSN 0031-4005
- Ani-Kibangou, B.; Bouhallab, S.; Mollé, D.; Henry, G; Bureau, F.; Neuville, D.; Arhan, P. P & Bouglé, D. (2005). Improved Absorption of Caseinophosphopeptide-bound Iron: Role of Alkaline Phosphatase. *J Nutr Biochem*, Vol 16, No.7, pp. 398-401, ISSN 0955-2863
- Beard, J. & Stoltzfus, R. (2001). Forward. *J. Nutr*, Vol.131, No.2, p563S, ISSN 0022-3166
- Beard, J. (2001). Iron Biology in Immune Function, Muscle Metabolism and Neuronal Functioning. *J Nutr*, Vol.131, No.2, pp. 568S-80S, ISSN 0022-3166
- Benoist, B. (2001) Introduction. *J. Nutr*, Vol.131, No.2, p564S, ISSN 0022-3166

- Buchanan, G. (1999). The Tragedy of Iron Deficiency During Infancy and early Childhood. *J Pediatr*, Vol.135, No.4, pp 413-5, ISSN 0022-3476
- Buchanan, G. (2003). Iron Deficiency and Blood Lead Levels. *J Pediatr*, Vol.143, No 2, p 281, ISSN 0022-3476
- Chessare, J. (1988). Whole Cow Milk versus Iron-Fortified Formula. *J Pediatr*. Vol.112, No.6, pp 1049-50, ISSN 0022-3476
- Cook, D. & Lynch, S. (1986). The Liabilities of Iron Deficiency. *Blood*. Vol.68, No.4, pp 803-9, ISSN 0006-4971
- Corbett, R; Ryan, C. & Weinrich, S. (2003). Pica in Pregnancy; does it Affect Pregnancy Outcomes? *Am J Matern Child Nurs*. Vol.28, No.3, pp183-9, ISSN 0361-929X
- Crosby, W. (1982). Clay Ingestion and Iron Deficiency Anemia. *Ann Intern Med*. Vol.97, No.3, p 456, ISSN 0003-4819
- Demir, A.; Yarali, N.; Fisgin, T.; Duru, F. & Kara, A. (2002) Most Reliable Indices in Differentiation between Thalassemia Trait and Iron Deficiency Anemia. *Pediatr Int*. Vol.44, No.6, pp. 612-6, ISSN 1328-8067
- Eden, A. & Mir, M. (1997). Iron Deficiency in 1- to 3-year-old Children A Pediatric Failure? *Arch Pediatr Adolesc Med*. Vol.151, No.10, pp 986-8, ISSN 1072-4710
- Eden. A. (2003). Iron Deficiency and Blood Lead Levels. *J Pediatr*. Vol.143, No.2, p 281-2 ISSN 0022-3476
- Erikson K.; Jones B.; Hess E.; Zhang, Q. & Beard, J. (2001). Iron Deficiency Decreases Dopamine D<sub>1</sub> and D<sub>2</sub> Receptors in Rat Brain. *Pharmacol Biochem Behav*. Vol.69, No.3-4, pp 409-18, ISSN 0091-3057
- Flemming, M. (2009). Sideroblastic Anemias, In: *Hematology of Infancy and Childhood*, 7<sup>th</sup> Edition. Okin, S.; Nathan, D.; Ginsburg, D.; Look, A.; Fisher, D. & Lux, S. pp 547-551, Saunders, ISBN 978-1-4160-3430-8, Philadelphia, PA
- Fomon, S.; Ziegler, E.; Nelson, S. & Edwards, B. (1981). Cow Milk Feeding in Infancy: Gastrointestinal Blood Loss and Iron Nutritional Status. *J. Pediatr*. Vol.98, No.4, pp 540-5, ISSN 0022-3476
- Fridge J. & Vichinsky, E. (1998). Correction of the Anemia of Epidermolysis Bullosa with Intravenous Iron and Erythropoietin. *J Pediatr*. Vol.132, No.5, pp 871-3, ISSN 0022-3476
- Gonzalez, J.; Owens, W.; Ungaro, P.; Werk, E. & Wentz, P. (1982). Clay Ingestion: A Rare Cause of Hypokalemia. *Ann Intern Med*. Vol.97, No.1, pp 65-6, ISSN 0003-4819
- Grantham-McGregor, S. & Ani, C. (2001). A Review of Studies on the Effect of Iron Deficiency on Cognitive Development in Children. *J Nutr*. Vol.131, No.2, pp 649S-68S, ISSN 0022-3166
- Hallberg, L.; Rossander-Hultén, L.; Brune, M. & Gleerup, A. (1992). Bioavailability in Man of Iron in Human Milk and Cow's Milk in Relation to Their Calcium Contents. *Pediatr Res*. Vol.31, No.5, pp 524-7, ISSN 0031-3998
- Iolascon, A.; De Falco, L. & Beaumont, C. (2009). Molecular Basis of Inherited Microcytic Anemia due to Defects in Iron Acquisition or Heme Synthesis. *Haematologica*. Vol.94, No.3, pp 395-408, ISSN 1592-8721
- Jain, S. & Kamat, D. (2009). Evaluation of Microcytic Anemia. *Clinical Pediatrics*. Vol.48, No.1, pp 7-13, ISSN 0009-9228

- Janus, J. & Moerschel, S. (2010). Evaluation of Anemia in Children. *American Family Physician*. Vol.81, No.12, pp 1462-71, ISSN 0002-838X
- Kadir, R.; Economides, D.; Sabin, C.; Owens, D. & Lee, C. (1998). Frequency of Inherited Bleeding Disorders in Women with Menorrhagia. *Lancet*. Vol.351, No.9101, pp 485-9, ISSN 0140-6736
- Kwiatowski, J.; West, T.; Heidary, N.; Smith-Whitney, K. & Cohen, A. (1999). Severe Iron Deficiency Anemia in Young Children. *J Pediatr*. Vol.135, No.4, pp 514-6, ISSN 0022-3476
- Lombardo, T.; Ximenes, B.; & Ferro, G. (2006). Hypochromic Microcytic Anemia as a Clinical Presentation of Celiac Disease. *Clin Lab*. Vol.52, No.5-6, pp 231-6, ISSN 1433-6510
- Looker, A. (2002). Iron deficiency – United States, 1999–2000. *MMWR Morb Mortal Wkly Rep*. Vol.51, No.40, pp 897-9, ISSN 0149-2195
- Lozoff, B.; Brittenham, G.; Viteri F.; Wolf, A. & Urrutia, J. (1982). Developmental Deficits in Iron-Deficient Infants: Effects of Age and Severity of Iron Lack. *J Pediatr*. Vol.101, No.6, pp 948-52, ISSN 0022-3476
- Lozoff, B.; Jimenez, E.; Hagen, J.; Mollen, E. & Wolf, A. (2000). Poorer Behavioral and Developmental Outcome More Than 10 Years after Treatment for Iron Deficiency in Infancy. *Pediatrics*, Vol.105, E51, ISSN 1098-4275
- Lozoff, B.; Wolf, A. & Jimenez, E. (1996). Iron-Deficiency Anemia and Infant Development: Effects of Extended Oral Iron Therapy. *J Pediatr*. Vol.129, No.3, pp 382-9, ISSN 0022-3476
- Lukes, A.; Kadir R.; Peyvandi F. & Kouides P. (2005). Disorders of Hemostasis and Excessive Menstrual Bleeding: Prevalence and Clinical Impact. *Fertil Steril*. Vol.84, No.5, pp 1338-44, ISSN 0015-0282
- McGeehan, M. (2003). Getting the Lead Out: Can Iron Help? *J. Pediatr*. Vol.142, No.1, pp 3-4, ISSN 0022-3476
- Mentzer, W. (1973). Differentiation of Iron Deficiency from Thalassemia Trait. *Lancet*. Vol.301, No.7808, p 882, ISSN 0140-6736
- Nissenson, A.; Berns, J.; Sakiewicz, P.; Gheddar, S.; Moore, G.; Schleicher, R. & Seligman, P. (2003). Clinical Evaluation of Heme Iron Polypeptide: Sustaining a Response to rHuEPO in Hemodialysis Patients. *Am J Kidney Dis*. Vol.42, No.2, pp 325-30, ISSN 0272-6386
- Olivares, M.; Walter, T.; Cook, J.; hertrampf, E. & Pizarro, F. (2000). Usefulness of Serum Transferrin Receptor and Serum Ferritin in Diagnosis of Iron Deficiency in Infancy. *Am J Clin Nutr*. Vol.72, No.5, pp 1191-5, ISSN 0002-9165
- Ortiz E.; Pasquini, J.; Thompson, K.; Felt, B.; Butkus, G.; Beard, J. & Connor, J. (2004). Effect of Manipulation of Iron Storage, Transport, or Availability on Myelin Composition and Brain Iron Content in Three Different Animal Models. *J Neurosci Res*. Vol.77, No.5, pp 681-689, ISSN 0360-4012
- Oski, F. (1979). The Nonhematologic Manifestations of Iron Deficiency. *Am J Dis Child*. Vol.133, No.3, pp 315-22, ISSN 0096-8994
- Oski, F. (1985). Is Bovine Milk a Health Hazard? *Pediatrics*. Vol.75(suppl), pp 182-6, ISSN 0031-4005

- Oski, F.; Honig, A.; Helu, B. & Howanitz, P. (1983). Effect of Iron Therapy on Behavior Performance in Nonanemic, Iron-Deficient Infants. *Pediatrics*. Vol.71, No.6, pp 877-80, ISSN 0031-4005
- Picciano, M. & Deering, R. (1980). The Influence of Feeding Regimens on Iron Status During Infancy. *Am J Clin Nutr*. Vol.33, No.4, pp 746-53, ISSN 0002-9165
- Piomelli, S.; Brickman, A. & Carlos, E. (1976). Rapid Diagnosis of iron Deficiency by Measurement of Free Erythrocyte Porphyrins and Hemoglobins: the FEP/Hemoglobin Ratio. *Pediatrics*. Vol.57, No.1, pp 136-41, ISSN 0031-4005
- Piomelli, S.; Seaman, C. & Kapoor S. (1987). Lead-Induced Abnormalities of Porphyrin Metabolism. The Relationship with Iron Deficiency. *Ann NY Acad Sci*. Vol.514, p 278-88, ISSN 0077-8923
- Pollitt, E.; Saco-Pollitt, C.; Leibel, R. & Viteri F. (1986). Iron Deficiency and Behavioral Development in Infants and Preschool Children. *Am J Clin Nutr*. Vol.43, No.4, pp 555-65, ISSN 0002-9165
- Rondó, P.; Carvalho, F.; Souza, M. & Moraes, F. (2006). Lead, Hemoglobin, Zinc Protoporphyrin and Ferritin Concentrations in Children. *Rev Saude Publica*. Vol.40, No.1, pp 71-6, ISSN 0034-8910
- Shamsian, B.; Rezaei, N.; Arzanian, M.; Alavi, S.; Khojasteh, O. & Eghbali, A. (2009). Severe Hypochromic Microcytic Anemia in a Patient with Congenital Atransferrinemia. *Pediatr Hematol Oncol*. Vol.26, No.5 pp 356-62, ISSN 0888-0018
- Sharma, V.; Brannon, M. & Carloss, E. (2004). Effect of Omeprazole on Oral Iron Replacement in Patients with Iron Deficiency Anemia. *Southern Medical Journal*. Vol.97, No.9, pp 887-9, ISSN 0038-4348
- Skikne, B. (1998). Circulating Transferrin Receptor Assay – Coming of Age. *Clin Chem*. Vol.44, No.1, pp 7-9, ISSN 0009-9147
- Stoltzfus, R. (2001). Defining Iron-Deficiency Anemia in Public Health Terms: A Time for Reflection. *J Nutr*. Vol.131(suppl), pp 565S-7S, ISSN 0022-3166
- Suskind, D.; Wahbeh, G.; Murray, K.; Christie, D. & Kapur, R. (2009). Collagenous Gastritis, a New Spectrum of Disease in Pediatric Patients: Two Case Reports. *Cases J*. Vol.2, No.7511, ISSN 1757-1626
- Thomas, F.; Falko, J. & Zuckerman, K. (1976). Inhibition of Intestinal Iron Absorption by Laundry Starch. *Gastroenterology*. Vol.71, No.6, pp 1028-32, ISSN 0016-5085
- Tunnessen, W. & Oski, F. (1987). Consequences of Starting Whole Cow Milk at 6 Months of Age. *J Pediatr*. Vol.111, No.6, pp 813-6, ISSN 0022-3476
- Van Heel, D. & West, J. (2006). Recent Advances in Coeliac Disease. *Gut*. Vol.55, No.7, pp 1037-46, ISSN 0017-5749
- Vazquez Lopez, M.; Carracedo, A.; Lendinez, F.; Muñoz, J.; Lopez, J. & Muñoz, A. (2006). The Usefulness of Serum Transferrin Receptor for Discriminating Iron Deficiency without Anemia in Children. *Haematologica*. Vol.91, No.2, pp 264-5, ISSN 1592-8721
- Walter, T.; De Andraca, I.; Chadud, P. & Perales, C. (1989). Iron Deficiency Anemia: Adverse Effects on Infant Psychomotor Development. *Pediatrics*. Vol.84, No.1, pp 7-17, ISSN 0031-4005

- Wilson, J.; Heiner, D. & Lahey, M. (1964). Milk-Induced Gastrointestinal Bleeding in infants with Hypochromic Microcytic Anemia. *JAMA*. Vol.189, No.7, pp 568-72, ISSN 0098-7484
- Wright, R.; Tsaih, S.; Schwartz, J.; Wright, R. & Hu, H. (2003). Association Between Iron Deficiency and Blood Lead Level in a Longitudinal Analysis of Children Followed in an Urban Primary Care Clinic. *J Pediatr*. Vol.142, No.1, pp 9-14, ISSN 0022-3476



## **New Advances in the Basic and Clinical Gastroenterology**

Edited by Prof. Tomasz Brzozowski

ISBN 978-953-51-0521-3

Hard cover, 546 pages

**Publisher** InTech

**Published online** 18, April, 2012

**Published in print edition** April, 2012

The purpose of this book was to present the integrative, basic and clinical approaches based on recent developments in the field of gastroenterology. The most important advances in the pathophysiology and treatment of gastrointestinal disorders are discussed including; gastroesophageal reflux disease (GERD), peptic ulcer disease, irritable bowel disease (IBD), NSAIDs-induced gastroenteropathy and pancreatitis. Special focus was addressed to microbial aspects in the gut including recent achievements in the understanding of function of probiotic bacteria, their interaction with gastrointestinal epithelium and usefulness in the treatment of human disorders. We hope that this book will provide relevant new information useful to clinicians and basic scientists as well as to medical students, all looking for new advancements in the field of gastroenterology.

### **How to reference**

In order to correctly reference this scholarly work, feel free to copy and paste the following:

Andrew S. Freiberg (2012). A Case Based Approach to Severe Microcytic Anemia in Children, New Advances in the Basic and Clinical Gastroenterology, Prof. Tomasz Brzozowski (Ed.), ISBN: 978-953-51-0521-3, InTech, Available from: <http://www.intechopen.com/books/new-advances-in-the-basic-and-clinical-gastroenterology/clinical-approach-to-microcytic-anemia-in-children>

**INTECH**  
open science | open minds

### **InTech Europe**

University Campus STeP Ri  
Slavka Krautzeka 83/A  
51000 Rijeka, Croatia  
Phone: +385 (51) 770 447  
Fax: +385 (51) 686 166  
[www.intechopen.com](http://www.intechopen.com)

### **InTech China**

Unit 405, Office Block, Hotel Equatorial Shanghai  
No.65, Yan An Road (West), Shanghai, 200040, China  
中国上海市延安西路65号上海国际贵都大饭店办公楼405单元  
Phone: +86-21-62489820  
Fax: +86-21-62489821

© 2012 The Author(s). Licensee IntechOpen. This is an open access article distributed under the terms of the [Creative Commons Attribution 3.0 License](https://creativecommons.org/licenses/by/3.0/), which permits unrestricted use, distribution, and reproduction in any medium, provided the original work is properly cited.

IntechOpen

IntechOpen