

We are IntechOpen, the world's leading publisher of Open Access books Built by scientists, for scientists

6,900

Open access books available

186,000

International authors and editors

200M

Downloads

Our authors are among the

154

Countries delivered to

TOP 1%

most cited scientists

12.2%

Contributors from top 500 universities



WEB OF SCIENCE™

Selection of our books indexed in the Book Citation Index
in Web of Science™ Core Collection (BKCI)

Interested in publishing with us?
Contact book.department@intechopen.com

Numbers displayed above are based on latest data collected.
For more information visit www.intechopen.com



Is Embolization Equal to Hysterectomy in Treating Uterine Fibroids?

Tomislav Strinic
Split University, School of Medicine,
University Hospital Split,
Croatia

1. Introduction

It is important for women to ensure that they make their own individual decision about whether to have a hysterectomy. Making this decision can be a difficult and emotional process. It is important for women to be well informed about the procedure so they can confidently discuss all available options with their gynaecologist. Because a hysterectomy involves the removal of the uterus, it is important that women realise they will no longer menstruate or be able to conceive after the procedure. For some women the prospect of no more periods and the removal of the fear of pregnancy will bring relief. Other women may find the finality of the ending of their reproductive capability distressing.

In November 1843, Charles Clay performed the first hysterectomy in Manchester, England. The earliest hysterectomies were supracervical, or subtotal hysterectomies. The body of the uterus was removed while the cervix remained intact. In 1929, Richardson, performed the first total abdominal hysterectomy (TAH), in which the entire uterus and cervix were removed (Johns, 1997). Total abdominal hysterectomy involves removal of the uterus and cervix through an abdominal incision. A hysterectomy can be performed in three different ways: abdominal, vaginal and endoscopic. The method chosen will depend on the surgeon's skills, expertise and preference. Also taken into account is the reason for the hysterectomy and characteristics such as a woman's weight, pelvic surgery history and if they have had children.

2. Hysterectomy

Hysterectomy is the most common non-pregnancy-related major surgery performed on women worldwide. This surgical procedure involves removal of the uterus and cervix, and for some conditions, the fallopian tubes and ovaries. Reasons for choosing this operation are treatment of genital malignancy and various common noncancerous uterine conditions. Primary indication for benign hysterectomy are uterine leiomyoma, endometriosis, uterine prolapse/incontinence, and abnormal uterine bleeding. Although this procedure is highly successful in curing the disease of concern, it is a surgical alternative with the accompanying risks, morbidity, and mortality that an operative procedure carries and it leads to sterility in women who are premenopausal. The patient may be hospitalized for several days and may

require 6-12 weeks of convalescence. Complications, such as excessive bleeding, infection, and injury to adjacent organs, also may occur (Jacobson et al., 2006; Gimbel, 2007).

Choosing the route of hysterectomy has been an important issue in gynecologic surgery for a number of years. In the past, many gynecologists believed that surgical indication determines the route of hysterectomy: abdominal, vaginal, laparoscopic or combined. However, suggests the factors may influence the route of hysterectomy for any surgical indication include uterine size, mobility, suspected adhesions, accessibility, and pathology confined to the uterus (ACOG Committee Opinion, 2009; Kovac et al., 2002). Physicians should take into consideration how the procedure may be performed safely and cost-effectively to fulfill the medical needs of the patient. However, analysis of recent surgical data shows that abdominal hysterectomy is performed in 66% of cases, vaginal hysterectomy in 22% of cases, and laparoscopic hysterectomy in 12% (ACOG Committee Opinion, 2009; Benassi et al., 2002; Kovac et al., 2002; Nieboer et al., 2009). Not all hysterectomies demand a specific operative approach; that is, some hysterectomies can be performed vaginally, laparoscopically, or abdominally for similar indications. For benign conditions requiring hysterectomy, surgeons should choose the approach depending on the feasibility of the procedure and the difficulties expected during surgery. These decisions would broadly comprise the traditional indications and contraindications for abdominal, laparoscopic, and vaginal hysterectomy. Surgical inexperience with vaginal hysterectomy should not be an indication for abdominal or laparoscopic hysterectomy. Technical feasibility may also mean that a surgeon is technically unable or unwilling to perform a vaginal hysterectomy because of his/her comfort, preference, training, capability, or experience with abdominal or laparoscopic methods. The most commonly reported indication for laparoscopic hysterectomy is menstrual disorders (ACOG Committee Opinion, 2009; Doderio et al., 2005). The most common indication for abdominal hysterectomy is leiomyoma. Because the majority of hysterectomies are safe and successful operations, and most patients recover well over time, surgical decision making is often only questioned when a complication occurs. Some authors also noted a 3 to 5 fold increase in subtotal hysterectomy worldwide (Johns, 1997; Benassi et al., 2002; Doderio et al., 2005; Nieboer et al., 2009). This change in preference is hard to explain, given the lack of evidence to support this practice. Most likely physician and patient perception of the merit of subtotal hysterectomy had a significant influence: women may believe subtotal hysterectomy may have less impact on sexuality, while physicians might consider the procedure less likely to effect bowel and bladder function and to have lower rates of infectious morbidity, be less likely to lead to prolapse, and have lower operative time and less blood loss than total abdominal hysterectomy. Given the lack of convincing evidence favoring this approach, the motivating reasons behind this change in practice pattern remain unclear (Johns, 1997; Benassi et al., 2002; Doderio et al., 2005; Nieboer et al., 2009).

Abdominal hysterectomy is the most invasive hysterectomy. Laparoscopic hysterectomy is moderately invasive. Vaginal hysterectomy is and has always been the most minimally invasive hysterectomy (ACOG Committee Opinion, 2009; Benassi et al., 2002; Doderio et al., 2007; Gimbel, 2005; Kovac et al., 2002; Nieboer et al., 2009). No amount of spin can deny this fact. It is time that proponents of laparoscopic hysterectomy are challenged about regarding laparoscopic hysterectomy, even performed robotically, as the minimally invasive hysterectomy (Holloway et al., 2009).

It is possible that increased use of laparoscopic and hysteroscopic procedures, development and acceptance of endometrial ablation devices, introduction of a progestin-based intrauterine device, and the emergence of uterine artery embolization have begun to substitute for hysterectomy in the general population (Farquhar & Steiner, 2002; Johns, 1997; Weber & Lee, 1996). The level of information available to patients on different treatment alternatives may also be greater among patients. Additionally, changes in patient preferences for hysterectomy or alternative treatments, as well as changes in provider preferences and counseling, could also contribute to decreasing hysterectomy rates (Benassi et al., 2002; Dodero et al., 2007; Farquhar & Steiner, 2002; Johns, 1997; Weber & Lee, 1996).

In recent years, there is an increasing need for conservative options to treat symptomatic uterine fibroids because of the wish to avoid major surgery, the desire to preserve fertility potential and the belief that the uterus plays a role in perceived sexual satisfaction. An ideal conservative treatment for uterine myomas should be safe, eliminate symptoms, decrease the size of myomas, preserve fertility and have long-term effects. Several procedures including endometrial ablation, uterine artery embolization, high-intensity focused ultrasound and myolysis have been suggested or developed as a conservative treatment to avoid hysterectomy or myomectomy (Guarnaccia & Rein, 2001; Myers et al., 2002).

3. Uterine fibroids

Uterine fibroids (also called myomas or leiomyomas) are the most common solid pelvic tumors in women and the leading indication for hysterectomy. Uterine fibroids may occur singly but most often are multiple and vary in size from an unnoticeable few millimetres to over 20 cm in diameter, significantly enlarging the abdominal cavity. They are named according to their location. Intramural fibroids lie wholly within the uterine walls, submucosal fibroids project into the uterine cavity and subserosal fibroids project from the outer surface of the uterus. They may also be pedunculated, where they are attached to the uterine wall by a stalk-like structure. Symptoms and treatment options are affected by the size, number, and location of the leiomyomas. Despite extensive research on the factors involved in the growth of leiomyomas, the precise causes of these tumors still remain unknown. Several predisposing factors have been identified, including age (late reproductive years), nulliparity, obesity, and African-American ethnicity. These tumors contain estrogen and progesterone receptors, and, typically develop in women at fertile age, increase with age, and shrink after the menopause. The growth of leiomyomas is ovarian hormones dependent. Growth factors with mitogenic activity also are elevated in leiomyomas, and, there is increasing evidence of genetic basis (Flake et al., 2003; Stewart, 2001). Although many women with uterine leiomyomas are asymptomatic and can be monitored without treatment, some will require more active measures. The two most common symptoms of uterine fibroids for which women seek treatment are abnormal uterine bleeding and pelvic pressure. The most common kind of abnormal uterine bleeding associated with leiomyomas is heavy or prolonged menstrual bleeding, which frequently results in iron deficiency anemia (Fraser et al., 2007). This heavy bleeding may result in significant disruption of a woman's daily activities. Some studies reporting leiomyomas in 70% of white women and more than 80% of black women by age 50 years (Day Baird et al.,

2003). Hysterectomy remains the most common surgical treatment for leiomyomas because it is the only definitive treatment and eliminates the possibility of recurrence. Many women seek an alternative to hysterectomy because they desire future childbearing or wish to retain their uteri even if they have completed childbearing. As alternatives to hysterectomy become increasingly available, the efficacies and risks of these treatments are important to delineate. The lack of a simple, inexpensive, and safe long-term medical treatment means that most symptomatic leiomyomas are still managed surgically.

4. Alternatives to hysterectomy in the management of leiomyomas

Although hysterectomy is often the definitive treatment for many pelvic pathologies, nonsurgical alternatives should always be attempted in elective cases. Hormonal therapy, gonadotropin-releasing hormone agonists and antagonists, progesterone-containing IUD, endometrial ablation, focused ultrasonographic surgery, and uterine artery embolization have been used with success. In choosing an alternative to hysterectomy, both safety and efficacy need to be considered for each treatment. It must be recognized that all alternatives to hysterectomy allow the possibility for new leiomyomas to form, and preexisting small or undetected leiomyomas may exhibit significant growth, necessitating another treatment. The risk of recurrence must be balanced against the potential benefits of uterine-sparing procedures, such as decreased rates of morbidity and continued fertility. However, procedural complications may rarely lead to an unanticipated hysterectomy (Manyonda et al., 2004). For example, gynecologists of United States of America perform approximately 250,000 surgeries for fibroids each year. According to a Wall Street Journal article (August 24, 2004), most women with symptomatic fibroids are not informed by their gynecologists that uterine artery embolization (UAE) is an option.

4.1 Medication

Although several small studies have shown a decrease in leiomyoma size during progestin therapy (Venkatachalam et al., 2004; Wallach & Vlahos, 2004), other studies using progestin therapy alone or in conjunction with a gonadotrophin-releasing hormone (GnRH) agonist identify an increase in uterine or leiomyoma volume (Friedman et al., 1992; Harrison-Woolrych & Robinson, 1995). Gonadotropin-releasing hormone agonists lead to amenorrhea in 70-80% of women and provide a 35-65% reduction in leiomyoma volume within 3 months of treatment. The effects of GnRH agonists are temporary, with gradual recurrent growth of leiomyomas to previous size within several months after cessation of treatment (Olive et al., 2004).

The levonorgestrel intrauterine system leads to minimal systemic effects, and the localized endometrial effect is beneficial for treatment of menorrhagia (Wallach & Vlahos, 2004). Small studies suggest that the levonorgestrel intrauterine system may be effective for treatment of heavy uterine bleeding in women with leiomyomas (Mercorio et al., 2003).

Several small studies and case reports have identified reductions in leiomyoma size and symptoms with the use of aromatase inhibitors (Attilakos & Fox 2005; Shozu et al., 2003; Varelas et al., 2007).

Antiprogesterone agents act at the level of the progesterone receptors found in high concentration in leiomyomatous uteri. Several studies of high-dose mifepristone have reported a reduction of leiomyoma volume of 26–74%. Leiomyomas appear to have a slower rate of recurrent growth after cessation of mifepristone treatment (Fiscella et al., 2006; Steinauer et al., 2004).

4.2 Myomectomy

Myomectomy may be an option for women who desire uterine preservation. This procedure is to remove the visible and accessible myomas and then reconstruct the uterus. Most myomectomies have been performed by laparotomy; however, endoscopic options increasingly are being used. However, women choosing myomectomy face the risk of recurrence of leiomyomas. Hysteroscopic myomectomy is an method for the management of abnormal uterine bleeding caused by submucous leiomyomas. Submucosal leiomyomas are estimated to be the cause of 5–10% of cases of abnormal uterine bleeding, pain, and subfertility and infertility (Guarnaccia & Rein, 2001; Narayan et al., 2010; Wallach & Vlahos, 2004). Laparoscopic myomectomy minimizes the size of the abdominal incision, resulting in a quicker postoperative recovery, a shorter time to hospital discharge, reduced analgesic requirements and less blood loss. Because of the complex nature of laparoscopic dissection and suturing, special surgical expertise typically is required (Altgassen et al., 2006; Sizzi et al., 2007). Robot-assisted laparoscopic surgery also has been used to perform myomectomy. It may have the advantage of improved optics, including a three-dimensional view, and enhanced surgeon dexterity. Disadvantages with robot-assisted surgery in general include diminished haptic (tactile) sensation, additional operating room time, and increased cost (Advincula et al., 2004).

4.3 Magnetic resonance imaging-guided focused ultrasound surgery

Since 2004 used a magnetic resonance imaging (MRI)-guided system for the localization and treatment of uterine leiomyomas with focused ultrasound therapy. This noninvasive approach uses high-intensity ultrasound waves directed into a focal volume of a leiomyoma. The ultrasound energy penetrates soft tissue and produces well defined regions of protein denaturation, irreversible cell damage, and coagulative necrosis. Whereas short-term studies show safety and efficacy, long-term studies are needed to discern whether the minimally invasive advantage of MRI-guided focused ultrasound surgery will lead to durable results (Fennessy et al., 2007; Morita et al., 2007; Stewart et al., 2006).

5. Uterine Artery Embolization (UAE)

UAE represents a relatively new, minimally invasive approach to the treatment of fibroids. It selectively blocks the feeding arteries that supply blood to the fibroids and causes ischemic necrosis and subsequent reduction, absorption or expulsion of leiomyoma (Franz et al., 2003). Unlike leiomyoma, the normal myometrium is supplied by multiple collateral arteries and it escapes the vascular deprivation resulting from UAE. Uterine fibroid embolization has several advantages over conventional hormone suppression (progestogens and GnRH analogues) and surgical procedures (myomectomy, hysterectomy), including avoidance of the side effects of drug therapy and postoperative complications resulting from

surgery (Pelage et al., 2000). There is neither need for the blood transfusion nor the abdominal incision. Recovery is shorter than recovery from hysterectomy or open myomectomy (seven to 10 days versus six weeks), and UAE results in long-term clinical success with outcomes comparable or superior to those of abdominal myomectomy (Narayan et al., 2010; Worthington-Kirsch et al., 1998) and early menopause-like symptoms are rarely induced as a result of UAE, as are often seen with gonadotrophin releasing hormone (GnRh) therapy. All fibroids are treated at once, which is not the case with myomectomy. UAE recurrence rates appear to be lower than those of myomectomy (Michael et al., 2002). The ideal candidates are women who no longer desire fertility but wish to avoid surgery and/or retain their uterus or are poor surgical risks. Embolization is also an excellent option for patients who will not accept blood transfusions and for those who are severely anaemic and require immediate intervention.

5.1 History of procedure

Embolization of the uterine arteries has been the standard of care for management of acute bleeding after childbirth or after gynecologic surgeries since the late 1970s (Heaston et al., 1979; Oliver & Lance, 1979). In the late 1980s, Jacques Ravina, a French gynecologist, became interested in the possible utility of embolization as a pre-emptive measure before gynecologic surgeries such as myomectomy. He was familiar with the utility of embolization for postoperative bleeding and decided to investigate preoperative embolization, hoping that this would decrease intraoperative bleeding as well as decrease the risk for postoperative hemorrhage. Preoperative embolization of the uterine arteries did indeed prove to be useful to decrease perioperative bleeding complications (Ravina et al., 1995). In some cases, there was a delay between the embolization and the planned surgery of at least a few days and in some cases a few weeks. Many of these patients experienced relief of their fibroid-related symptoms from the embolization alone and refused to go on with the planned surgery. Ravina et al. (Ravina et al., 1995) published their initial experience in 1995, and have since continued their studies of uterine artery embolization (UAE) as a primary treatment for fibroids (Ravina et al., 1999). UAE for fibroids was first reported in the United States by Goodwin (Goodwin et al., 1997) from University of California Los Angeles (UCLA) Medical Center in 1996. Since then, there has been rapid spread of the procedure across the United States, Europe, and worldwide.

However its use for management of uterine fibroids was reported by Ravina from France (Ravina et al., 1995). In the beginning they offered embolization as palliative management in 16 women who presented with high operative risks i.e. thromboembolic accidents, severe obesity, diabetes, and AIDS. It was discovered that with a mean follow-up of 20 months, symptoms resolved in 11 patients while three patients improved partially. The blockage of the blood supply caused degeneration of the fibroids and this resulted in resolution of their symptoms. This led to the use of this technique as a stand-alone treatment for symptomatic fibroids. Recently, the same group presented their findings in 243 patients with follow-up care ranging from 6 months to 7 years and cited an 83% rate of improvement in abnormal bleeding after embolization (Ravina et al., 2000). Since then UAE has become increasingly accepted as a minimally invasive, uterine-sparing procedure, and more than 200,000 procedures have been performed worldwide during the past decade (Committee on

Gynecologic Practice, American College of Obstetricians and Gynecologists, 2004). The advantages of embolization, including a significant reduction in the length of the hospital stay and 24-hour pain level, and a more rapid return to usual activities, need to be weighed against the risk of treatment failure requiring a second intervention and the possibility, although infrequent, of major late adverse events.

5.2 Preprocedure testing

Before UAE is performed in a patient, it is typically required that she has been seen by a gynaecologists and an interventional radiologist. It is important to obtain a complete history. Careful pre-procedure evaluation is essential to exclude pregnancy and genital tract malignancy, especially suspected leiomyosarcoma. In addition to the gynaecologic examination, Pap smear is required, and women with irregular periods should undergo endometrial sampling before UAE to exclude endometrial carcinoma or endometrial hyperplasia as the cause of bleeding. Patients with a history of pelvic inflammatory disease should have high cervical swabs and cultures for gonorrhoea and Chlamydia trachomatis. If pregnancy cannot be excluded by patient history and gynaecologic examination, a pregnancy test should be performed. Other absolute contraindications include comorbidities that may increase the risk for infectious complications (e.g. pelvic inflammatory disease, or active genitourinary infection), the presence of an adnexal mass and conditions that contraindicate any endovascular procedure (e.g. reduced immune status, severe coagulopathy, severe contrast medium allergy, or impaired renal function). To proceed with UAE, a full blood count should be taken. It is especially important to screen for anemia in patients with menorrhagia to have a baseline status for follow-up. Other blood tests are serum creatinine level, blood urea nitrogen and coagulation parameters. Furthermore, relative contraindications are presence severe endometriosis, presence of pelvic adhesions which distorts vascular anatomy, history of previous pelvic irradiation or surgery, and peripheral vascular occlusive disease. The desire to avoid a hysterectomy under any circumstances is also an absolute contraindication to UAE. There are no restrictions to the size and number of fibroids that can be treated with UAE (Volkers et al., 2006). Anatomic exclusion criteria only include submucosal fibroids that may be effectively treated with hysteroscopic resection, and pedunculated subserosal fibroids with a narrow stalk because of the potential risk and complications from infarction of the stalk and subsequent fibroid detachment from the uterus (Paxton et al., 2006). Clinical examination should confirm the diagnosis of leiomyomata supplemented by ultrasound and MRI. Imaging of the uterus and adnexa is vital for patient selection for UAE, both to confirm the diagnosis and to assess the extent of symptomatic leiomyomas. The diagnostic work-up is depending on local practice patterns, availability, and patient insurance coverage. Pelvic ultrasonography has been commonly used prior to and following UAE. In the majority of cases, ultrasonography examination can provide sufficient detail to determine a patient's suitability for embolization and to identify relative contraindications such as pregnancy, uterine anomalies, endometriosis, adenomyosis, pelvic malignancy, and pedunculated fibroids. MRI is currently considered to be the most accurate imaging technique for detection and localization of fibroids (Ruuskanen et al., 2010). MRI is more sensitive than ultrasonography in the detection of fibroids. MRI may also accurately assess an enlarged fibroid uterus, which is not possible with ultrasound because of the limited field of view. The capability of

MRI to demonstrate the uterine zonal anatomy allows accurate classification of individual masses as submucosal, intramural, or subserosal (Ruuskanen et al., 2010). Contrast material-enhanced MR imaging exceeds ultrasound's technical limitations in precise fibroid mapping and characterization. Thus, MR imaging may result in a change in management. However, neither size, localization or MR signal intensity characteristics have shown to be useful predictive factors of clinical success. In addition, although some MR appearances may suggest uterine sarcoma, there is no accurate test available. The presence of other pathologies which are likely to have similar clinical profile such as adenomyosis should be ruled out as the role of UAE in such conditions is debatable. There is some evidence that ovarian devascularisation may follow UAE subsequently resulting in iatrogenic menopause though the reported incidence is less than 1% (Amato & Roberts, 2001; Chrisman et al., 2000; Hehenkamp et al., 2007; Rashid et al., 2010). Hence an assessment of follicle-stimulating hormone (FSH) on the third day of the cycle before the procedure is helpful in evaluating ovarian status before the procedure so that declining ovarian function is documented and patient would not attribute this to treatment per say. However there is no general consensus regarding the role of routine hormone assay in patients undergoing UAE.

The use of prophylactic antibiotics to reduce posttreatment infection is debatable. Theoretically there is a possibility of anaerobic and bacterial infection in the avascularised tissue. Likely causal organisms include *Escherichia Coli*, *Streptococci*, *Staphylococci* and *Bacteroides*. Published work suggests that the procedure is associated with a post-treatment infection rate of 2%, even though prophylactic antibiotic therapy has sometimes been used. Evidence from the use of prophylactic antibiotic therapy in association with vaginal hysterectomy suggests that single dose prophylactic antibiotic therapy is reasonable (Volkers et al., 2006). The ideal time for UAE in relation to menstrual cycle is not yet established. The fear is possibility of pregnancy if performed in postovulatory phase of menstrual cycle. However if the patient has taken adequate contraceptive precautions, embolization may be performed at any stage of the menstrual cycle. If adequate contraception has not been used, treatment should only be given in the early to mid-follicular phase of the cycle. Symptomatic or asymptomatic uterine fibroids in women 40 – 45 years old is an ideal case for this procedure. Though recently there are multiple case reports of successful pregnancy after UAE for fibroids, the existing evidence has not fully established its application in younger age as an alternative for medical or surgical therapy (myomectomy) (Michael et al., 2002). Patient education on possible complications and the possibility of amenorrhea occurring after the procedure is a must. UAE should not be contemplated on those who are desirous of childbearing because preservation of fertility can not be assured based on current available evidence. The presence of any conditions mentioned below should deter the interventional physician in performing UAE.

5.3 Main procedure

An interventional radiologist is responsible for all aspects of the procedure; initial evaluation, conducting the embolization, and follow-up care. UAE should only be carried out in a specialist angiographic suite having digital subtraction angiography with measures to minimize X-ray dosage (Nikolic et al., 2000). The procedure is usually done in the hospital with an overnight stay after the procedure. To ensure an optimal therapeutic outcome and

patient satisfaction, it is advisable to inform the patient during the initial consultation for UAE about the concept behind the treatment, potential side effects and the medication given alongside the procedure and offer time for questions. It is recommended to explain briefly the environment of an angio suite to the patient. The patient should then be informed about the level of mental awareness she can expect during the procedure combined with the offer to sedate her, if preferred. The preparation for the procedure including insertion of a Foley catheter, shaving, draping etc. and administration of local anesthesia are explained. The time course, duration, and severity of the postprocedural pain, the components of the postembolization syndrome and the corresponding medications that will be administered to relieve these temporary effects of UAE should be discussed. Certainly postembolization symptoms and potential complications have to be discussed. Most centers use conscious sedation to assure patient comfort during the embolization procedure, although some operators prefer epidural or spinal analgesia. General anesthesia is neither required nor recommended. Prior to the procedure, intravenous cannulation is established, allowing intravenous sedation and analgesia to be given during the procedure and patient-controlled analgesia instituted at the end of the procedure. Thirty to sixty minutes before the procedure each women was given analgesia with diclofenac or ketorolac by intramuscular injection. During the procedure patient controlled analgesia with use of intravenous opioids morphine, meperidine, hydrocodone, or fentanyl. Most radiologists prefer standard percutaneous transfemoral approach, invariably via the right side, whereas some find it easier to catheterise both arteries using a bilateral approach. The choice of an access site should be made by the operator based on his or her personal preference and the vascular anatomy of the patient. An awareness of the uterine artery normal variants is important for the radiologists. The uterine artery arises from the anterior division of the internal iliac artery. When fibroids are present, however, the uterine artery dilates and takes on a readily identifiable configuration. In most cases, the paired uterine arteries are the dominant source of blood flow to uterine fibroids. Variant anatomy has been described, including ovarian artery collaterals (26%), multiple uterine arteries (2%) and partial uterine artery replacement (2%) (Nikolic et al., 2000; Razavi et al., 2002). Collateral flow via an ovarian artery may be a cause of uterine artery embolization treatment failure (Amato & Roberts, 2001). Collaterals may also be present through adhesions. In addition the rectal and vesicle branches of the internal iliac artery may simulate the uterine artery. The optimum occlusion of blood supply to the fibroid is achieved when uterine artery is embolised at the level of perforating branches. Proximal occlusion of larger arteries with coils or similar agents is not expected to provide clinical success and if the procedure needs to be repeated they will prevent re-entry of micro catheter (Spies et al., 2001). At present, distal embolization can best be accomplished with particulate agents suspended in contrast solution. Those in current use include polyvinyl alcohol (350 –500 µL), tris-acryl gelatin microspheres, and gelatin sponge particles and all three agents appear to be equally safe and effective and these particles have been used for embolization in many parts of the human body for more than 20 years without any significant reaction attributed to the agent (Castaneda-Zuniga et al., 1978). The main procedure involves catheter placement in femoral artery via single groin puncture. A 5-F angiographic catheter (3-French = 1mm diameter) is placed via the groin and advanced over the aortic bifurcation to the contralateral internal iliac artery, and digital angiography is done to identify the origin of the uterine artery. There is often a great deal of tortuosity at the origin, and catheter induced spasm is common. This can be avoided to some extent by

coaxial placement of 3-F micro-catheter. After successful catheterization of uterine vessels, solution of polyvinyl alcohol particles mixed with sterile saline and iodinated contrast medium is injected into the vascular lumen. Because fibroids are very vascular, the particles flow to the fibroids first. The particles wedge in the vessels and cannot travel to any other parts of the body. Over several minutes the arteries are slowly blocked. The embolization is continued until there is nearly complete blockage of flow in the vessel. If necessary, after embolization of the artery with particles pledgets of an absorbable gelatin sponge may be placed via catheter to complete the embolization. The 5-French catheter is then formed into a loop, and the catheter is placed into the ipsilateral internal iliac artery; the embolization procedure is then repeated in the right uterine artery. Another postembolization angiogram is taken to confirm complete blockade and all catheters are then removed. The entire procedure takes approximately 60 to 100 minutes.

5.4 Postprocedural care

Of paramount importance is controlled and timely analgesia to treat pain during and after UAE. Periprocedural regimens should include administration of nonsteroidal antiinflammatory drugs (NSAIDs) such as diclofenac (i.m., p.o.), ibuprofene (p.o) or ketorolac (i.v.). Additional pain medication may include paracetamol (acetaminophen) which also has an antipyretic effect. Pain control, particularly in the first twelve hours, is important as some patients develop pelvic pain of severe intensity. Patient controlled analgesia with use of intravenous opioids morphine, meperidine, hydrocodone, or fentanyl has been used effectively in most centers (Ryan et al., 2002). Inadequate pain control is the most common reason for a patient's return or readmission to the emergency department after UAE and pain is the single most remembered side effect of the procedure. Women were given diclofenac, ibuprofene or ketorolac tablets to take home. Postprocedural pain cannot be predicted from baseline uterine or fibroid volume and the severity of pain experienced cannot be used to predict outcome. It varies significantly among patients and consists of an early ischemia-related component followed by pain that is modulated by the inflammatory response to tissue necrosis. Ischemic pain usually occurs by the end of the procedure. However, it may not become apparent until the patient is back in the ward. Pain levels peak within the first 6-8 hours and need to be addressed by a continuous and potent analgesia regimen. Pain may be constant, crampy or in waves, can be quite severe and is unrelated to the size, location or number of fibroids. Pain medication should be started after catheterization of the uterine artery and not after the procedure. Alternatives to intravenous opioids for pain control are spinal or epidural anesthesia. However, these analgesic regimens require the help of anesthesiologists, leading to a technically more complex scenario (Roth et al., 2002; Zhan et al., 2005).

Nausea is a common side effect of the embolization procedure and/or the medications used for pain control and hence there is a significant role for preoperatively administered antiemetic agent. During bedrest the patient should receive standard prophylaxis against deep vein thrombosis. Oral anti-inflammatory agents and narcotics are commonly used for several days after the procedure (usually 7-10 days). In the first postoperative week, approximately 10 to 15 percent of patients experience postembolization syndrome which is characterized by nausea, and/or vomiting, malaise, low grade fever, pain abdomen and elevated white blood count. The pain is due to ischemia induced by vascular occlusion and

fever is probably because of the release of tissue breakdown products from degenerating uterine fibroids (Goodwin et al., 1997). Reported complication rates of UAE are low. Most complications were minor and occurred during the first 3 months after the procedure. A relatively common complication of UAE is vaginal expulsion of an infarcted fibroid, with a reported rate of up to 10% (Spies et al. 2002b; Walker & Pelage, 2002). This complication is more frequently seen in patients with submucosal fibroids or intramural fibroids with a submucosal component. Expulsion most often occurs within 6 months after the procedure, but there are reports of this event after a period of time as long as 4 years (Marret et al., 2004). In most cases, the infarcted fibroid is expelled spontaneously, and no additional treatment is necessary. Hysteroscopic resection or dilation and curettage is reserved for cases in which the fibroid is only partially infarcted and remains firmly attached to the uterine wall due to the increased risk of secondary infection (Marret et al., 2004; Spies et al. 2002b). When uncomplicated, fibroid expulsion can restore the uterine anatomy to nearer normal more rapidly than otherwise. In a minority of cases, however, retention of necrotic fibroid tissue may result in chronic vaginal discharge due to shedding of fibroid material into the endometrial cavity. This condition can be treated effectively by hysteroscopic resection of the necrotic fibroid material (Ogliari et al., 2005; Walker et al., 2004). The most serious, although rare, complication of UAE is the occurrence of intrauterine infection, which has been reported in less than 1% of procedures (Pron et al., 2003b; Walker & Pelage, 2002; Worthington-Kirsch et al., 2005).

If left untreated or refractory to antibiotics, uterine infection can lead to sepsis and the need for emergency hysterectomy. Sepsis is suspected when relatively high grade fever persists beyond the 24 to 48 hours typical of post embolization syndrome. Sepsis is more frequent when UAE is performed on a very large uterus; more than 20 cm in height, when a single fibroid is larger than 9 cm in diameter or when there is a large submucous fibroid (Aungst et al., 2004; Nikolic et al., 2004). Two deaths from uterine infection and overwhelming sepsis have also been reported after UAE (de Block et al., 2003; Vashist et al., 1999). Clinical experience and evidence from a case report (Vashist et al., 1999) suggest that infection may originate from the vagina and/or the urinary tract, which underlines the importance of pre-procedure screening for genitourinary infection. There is also evidence that certain pre-existing conditions, such as a coexistent adnexal pathology (Nikolic et al., 2004), and some minor post-procedure complications, in particular fibroid expulsion (Marret et al., 2004; Spies et al. 2002b), are associated with a higher risk of infection. In addition to two deaths from septic shock (de Block et al., 2003; Vashist et al., 1999), other three deaths following UAE have thus far been reported, one from pulmonary embolism and two from uncertain causes (Worthington-Kirsch et al., 2005), in more than 100 000 procedures performed worldwide. If we assume that all these deaths were related to the procedure, the mortality risk would be 0.05:1000, which compares favourably with the estimated mortality rate of 0.38:1000 following hysterectomy for non-obstetric benign disease (Maresh et al., 2002; Siskin et al., 2002; Vashist et al., 1999). An ischemic injury to the uterus of such severity necessitating hysterectomy is required in less than 1% of patients. Severe infection can occasionally require a hysterectomy (Pelage et al., 2000).

Temporary amenorrhea and post-procedure menopause are not uncommon after UAE. Because the blood supply to the ovaries is partially from the uterine arteries, the procedure of UAE invariably diminishes the blood supply to the ovaries and results in some reduced

ovarian function. Postembolisation amenorrhea is usually limited to a few cycles and is not considered a major complication. Transient or permanent amenorrhea with other symptoms of ovarian failure has been reported in up to 5% of women after UAE. There have been anecdotal reports of ovarian failure in younger women (Pron et al., 2003b; Spies et al. 2002b; Walker & Pelage, 2002). Permanent loss of ovarian function after UAE resulting in menopause has been reported in several studies. This complication seems to occur mainly in women > 45 years of age (Rashid et al., 2010; Tulandi et al., 2002). Transient ovarian failure has also been described (Ahmad et al., 2002; Amato & Roberts, 2001) but other studies did not show any untoward effects on ovarian function from UAE (Ahmad et al., 2002; Tropeano et al., 2004). Ovarian damage is thought to occur after UAE because of passage of embolization particles through anastomotic vessels between uterine and ovarian arteries, causing hypoxic ovarian damage and tissue loss. Indeed, it has been confirmed that embolization particles can be found at histopathologic examination of ovarian tissue after UAE. Furthermore, loss of ovarian perfusion, as demonstrated by sonographic assessment, directly after treatment in a substantial number of patients has been observed (Tulandi et al., 2002).

Permanent ovarian failure can be demonstrated by increased FSH and LH levels, increased menopausal symptoms, decreased estradiol (E2) levels and ultrasound-based ovarian volume and antral follicle count. Ovarian reserve reduction can better be tested by measuring anti-Mullerian-hormone (AMH), a reliable marker of ovarian reserve, especially in relation to the quantity of remaining follicles in the ovaries (Hehenkamp, 2005, 2007; Tropeano et al., 2004). As a result of the abundant collateral arterial circulation, normal uterine tissue usually recovers from the reduction in uterine blood flow induced by bilateral UAE. Ultrasound and MRI follow-up examinations have documented rapid revascularization of the normal myometrium and an essentially normal appearance of the endometrium at 3–6 months after embolization (Pelage et al., 2000; Tropeano et al., 2003). In addition, there are some risks that are associated with any form of angiographic procedure, such as hematoma formation or infection at the catheter insertion site in the groin, contrast media reactions, and damage to blood vessels. There are few case reports of unintended embolization resulting in pelvic organ damage. Radiation exposure occurring during UAE is a significant concern because many women who are candidates for the procedure are of childbearing age. With operator experience and limiting fluoroscopy time, the use of magnified and oblique views, non-pulsed fluoroscopy and road-mapping, the absorbed ovarian dose may be minimized (Andrews & Brown 2000; Binkert et al., 2001).

Patients in the UAE cohort may have experienced severe complications such as death (de Block et al., 2003; Lanocita et al., 1999; Vashist et al., 1999), pulmonary embolus, myocardial infarction, and cerebrovascular accident (stroke) (Hascalik et al., 2004; Spies et al., 2002). These complications are very rare. Furthermore, major complications are thrombosis, septicaemia, and emergency myomectomy/hysterectomy (Spies, 2002, 2002b). In the EMMY Trial, Volkers et al. found that a larger fibroid volume (100 cm³) was associated with an increased risk of complications (Volkers et al., 2006). More often are minor complications like minor infections, haematoma requiring treatment, drug reaction, permanent amenorrhoea, retention of urine requiring catheterisation, and fibroid expulsion (Marret et al., 2004; Spies et al., 2002; Volkers et al., 2006).

5.5 Follow-up

Individual study variations in the definition of UAE failure: symptom persistence, or recurrence, or need for additional therapy. Large case series with less than 2 years of follow-up reported rates of treatment failure, defined as the need for subsequent interventions, ranging from 5.5 to 9.5% (Huang et al., 2006; Spies et al., 2005a; Walker & Pelage, 2002).

There are several possible reasons for UAE failure. First, since the procedure causes fibroid shrinkage but preserves normal uterine tissue, it is possible that new fibroids will develop and symptoms recur. The risk of fibroid recurrence after embolization has not yet been defined. A prospective study using transvaginal ultrasound reported appearance of new fibroids in 8.2% of patients at a median of 30 months after the procedure (Marret et al., 2003). On the other hand, results from MRI follow-up examinations up to 3 years after UAE indicated that many clinical recurrences were not caused by development of new fibroids but related to re-growth of incompletely infarcted fibroids (Pelage et al., 2004). Incomplete fibroid infarction is most often related to technical aspects of the procedure such as the presence of collateral blood supply to the fibroids (usually from the ovarian arteries) or difficulties in cannulating both uterine arteries as a result of anatomical variation or arterial spasm. Successful embolization of only one uterine artery is generally regarded as a technical UAE failure as, in most cases, both uterine arteries contribute to the fibroid blood supply (Spies, 2003).

After left hospital and coming home, an early phone interview allows to verify the expected gradual decrease in pain and physical weakness patients experience after UAE. Patients are reassured, minor problems such as minimally increased temperature, onset of minor vaginal bleeding etc. discussed, and adequate pain medication checked. Some centres with an outpatient interventional radiology clinic may also see the patient at 4 weeks for a regular check-up. Four week follow-up may also be performed by the patient's gynaecologist on condition that he or she is familiar with the typical clinical course after UAE (Pelage et al., 2000; Siskin et al., 2002). It is important to be aware that uterine or individual leiomyoma size reduction is not a good indicator of the clinical success of UAE. Symptom relief remains the single most important measure of clinical success. Improvement in clinical symptoms is generally seen three months after the procedure. At this time, only negligible size reduction of fibroids may be observed. Interventional radiologists should be aware of this discrepancy since patients might be irritated by imaging reports and may need reassurance regarding the course of symptomatic improvement and size reduction of the fibroids treated. While menorrhagia may improve as early as within the first cycle after UAE, bulk-related symptoms may take longer to recede (Hehenkamp et al., 2005; , Spies et al., 2005a). Transient amenorrhea for up to three cycles is common while permanent amenorrhea is uncommon. It is associated with patient age and rarely occurs in patients under the age of 45 years. Follow-up imaging can be done by transvaginal ultrasound in those women who improve. At least one follow-up imaging exam is recommended and should include size measurements to verify fibroid shrinkage. If patients do not report improvement of symptoms 4 months after UAE, the radiologist should investigate the causes of failure. A detailed history of signs and symptoms in the preceding months should be collected to differentiate true persistence of symptoms from symptoms that may be related to ongoing fibroid sloughing, intrauterine residual fibroid tissue or infectious complications. In collaboration with a skilled gynaecologist, the radiologist should initiate adequate measures such as evaluation for infection and hysteroscopy to assess the uterine cavity (including

hysteroscopic removal of residual fibroid) (Pelage et al., 2000; Spies et al., 2005a). Patients with persistent symptoms and no decrease or even an increase in uterine fibroid size should undergo contrast-enhanced imaging to rule out incomplete fibroid infarction after UAE and the possibility of a leiomyosarcoma. MR imaging is particularly helpful in those patients who do not improve after 4 months following embolization. MR imaging depicts morphologic changes such as sloughing of fibroids in contact with the uterine cavity. The latter may be associated with vaginal discharge in patients having undergone UAE but do not require additional treatment in the majority of cases. MRI also identifies side effects and complications associated with UAE such as ongoing fibroid expulsion, endometritis, and uterine necrosis (Marret et al., 2004; Mehta et al., 2002; Walker et al., 2004). Endometritis is seen in 0.5% of cases after embolization, is associated with fibroid expulsion and usually responds well to antibiotics but may spread and result in septicaemia if left untreated (Spies, 2000, 2002b). Patient is asked to return for follow up 2 weeks after procedure for checking healing of the puncture site and screening for unusual symptoms or potential problems (Mehta et al., 2002). It is desirable to have follow-up imaging studies after 3, 6 and 12 months following the embolization. This is useful in determining whether all existing leiomyomata have been infarcted and begun to decrease in volume and will also help determine whether any uterine or adnexal complications have occurred. If a rapid increase in fibroid size is noted, one should try to rule out malignancy (mainly leiomyosarcoma) though this is a rare condition. Patients undergoing UAE should be available for long-term follow-up preferably under the same institution. This is important for monitoring the control of symptoms, but also for detecting complications that may occur (Hehenkamp et al., 2005; Spies et al., 2002a). Late infections, expulsion of portions of leiomyomata, chronic endometritis, chronic vaginal discharge, and cessation or irregularity of menses have all been described after UAE and may develop more than a year after the procedure (Marret et al., 2004; Mehta et al., 2002; Walker et al., 2004). If follow-up study indicates inadequate clinical improvement or volume reduction, a second arteriographic examination and repeat embolization may be necessary especially if there is evidence of continued perfusion of the leiomyomata (McLucas, 2009). However repeat embolization is unlikely to be of use if arteriogram demonstrates fibrotic change and absent perfusion. In indicated cases, it is important to counsel the patient regarding the risks of ovarian injury. This is important because ovarian collateral supply is a common cause for treatment failure, and more aggressive embolization during a second treatment may result in ovarian injury and cause accelerated ovarian failure (Ryu et al., 2001).

Successful embolization of bilateral uterine arteries is achievable in 96% of the cases (Freed & Spies, 2010; Spies & Sacks, 2004). Smaller baseline fibroid size and submucosal location are more likely to result in a positive outcome (Spies et al., 2002c). In the presence of a fibroid larger than 8.7cm the failure rate is higher than 15% and for every additional 1 cm increase in diameter there is an additional increase of 10% in the failure rate. Clinical results show that in approximately 80 to 90%, there is improvement in abnormal bleeding and bulk-related symptoms (Freed & Spies, 2010; Spies et al., 1999; Spies & Sacks, 2004). Of those presenting with menorrhagia 90% return to a normal cycle within three months following the procedure (Pron & Bennett, 2003). The volume shrinkage has been reported between 40 to 50% in most studies (Pron & Bennett, 2003; Spies et al., 2002c). Many fibroids under 5 cm in diameter may become undetectable after UAE. Patient satisfaction is very good in the vast majority, with 85-90% of patients indicating that they would again choose UAE as therapy, and would recommend it to others with symptomatic fibroids (Smith et al., 2004). An

important element in the decision-making process is knowledge about possible outcomes, which can be gained only by appropriate follow-up of patients (Freed & Spies, 2010; Smith et al., 2004; Spies & Sacks, 2004). Initially UAE was a new and experimental procedure carried out under research conditions and information about possible side-effects and outcomes was not readily available to the first patients undergoing the treatment. Now that 16 years have elapsed, more information is readily available and patients are, in general, more carefully counselled prior to their treatment (Freed & Spies, 2010; Smith et al., 2004). Statistics show that 10 percent to 15 percent of women who have UAE will need a follow-up procedure, usually some years later, because of recurrent symptoms from fibroids that either did not fully succumb or from growth of new fibroids. UAE kills the majority of existing fibroids, but these women have already demonstrated that their uterus has a propensity to make fibroids (Hovsepian et al., 2004).

5.6 Effects on fertility

The reports from literature demonstrate that women can conceive and carry a pregnancy successfully to term after embolization (Berkane & Moutafoff-Borie, 2010; Carpenter & Walker, 2005; Ciraru-Vigneron & Ravina, 2001; Cook et al., 2010; D'Angelo et al., 2003; Forman et al., 1999; Homer & Saridogan, 2010; Kovacs et al., 2002; McLucas et al., 2001; Pinto Pabón et al., 2008; Pron et al., 2005; Ravina et al., 2000; Vashisht et al., 2001; Walker & McDowell, 2006). UAE appears to be viable in young women who still want to become pregnant. Potential effects of embolization on ovarian function are an important consideration if fertility preservation is desired. Reduction of ovarian reserve is of special importance when UAE is used in the treatment of women desiring future fertility, which is now still being discouraged (Tulandi et al., 2002; Hascalik et al., 2004). Few studies, however, have reported on gonadotropin levels. Clearly, the evidence is far too limited to make conclusive statements on premature menopause or ovarian failure after embolization (Ahmad et al., 2002; Spies et al., 2001; Tropeano et al., 2004; Tulandi et al., 2002).

Several pregnancy complications have been reported after UAE. In one survey involving 50 published articles on successful pregnancies following UAE, these complications were reported; malpresentations (17%), small for gestational age (7%), cesarean section (56%), preterm delivery (28%), and postpartum hemorrhage (13%) (Goldberg et al., 2002). The rates of abortions, preterm delivery, malpresentations and postpartum haemorrhage are significantly higher in patients treated with UAE compared to myomectomy group (Goldberg et al., 2004; Homer & Saridogan, 2010). Initially it was not known whether an embolized uterus could sustain a pregnancy, and it was thought that fetal losses could be high. Interpreting spontaneous abortion rates after embolization is difficult because of confounding factors such as advanced maternal age and the large leiomyoma burden present in most embolization study cohorts. Spontaneous abortions are known to increase with maternal age, ranging from 18% in the late 30s to 34% in the early 40s in the general population (Coronado et al., 2000). The study of the British embolization cohort reported 20% rate of spontaneous abortions (Walker & Pelage, 2002), but lower than the 35% and 29% reported in the French (Ravina et al., 2000; Ciraru-Vigneron & Ravina, 2001) and American (McLucas et al., 2001) studies. Because embolic techniques with respect to angiographic endpoints were similar in these studies, patient differences and variability due to small samples are likely to account for these discrepancies. The high rate in the French study could be accounted for to some extent by the use of smaller embolic particles (150–300 μm)

and the advanced maternal age of the women (all older than 40 years of age). Based on these initial reports, although the numbers of pregnancies are small, uterine embolization does not seem to confer an obvious increased risk of pregnancy wastage. Uterine embolization causes irreversible ischemia leading to leiomyoma degeneration. Because embolization cannot target exclusively the leiomyoma vascular supply, there is a concern for potential effects on the myometrium. Although the integrity of the myometrium after UAE is not known, results from histopathologic studies of failed embolization have concluded that the adjacent myometrium is generally spared (Colgan et al., 2003). Little is known about the optimal time to achieve pregnancy after embolization. Leiomyomata in most cases gradually shrink, and although most reductions are achieved within 6 months to a year (McLucas et al., 2001), the extent and timing of uterine healing associated with these changes are unknown. In general, patients intending to conceive after embolization were advised to wait several months, in keeping with the advice given women after myomectomy. The next complication is that UAE causes abnormal placentation. Placenta accreta, occurring when there is a focal or diffuse absence of the decidua basalis resulting in a poorly formed decidua that leads to deeper trophoblast invasion is also a rare complication (Miller et al., 1997). The incidence of placenta previa at delivery varies in published studies from 3 to 6 per 1,000 pregnancies (Ananth et al., 2003; Miller et al., 1997).

6. Our experience

6.1 Subjects and methods

The study cohort consisted of 347 premenopausal women with ultrasound documented symptomatic fibroids. All were consecutively selected from women presenting for evaluation for uterine artery embolisation at the Department of Obstetrics and Gynecology of the University Hospital Split, Croatia, between May 1999 and November 2009. According to our existing protocol, patients were considered suitable for UAE if they had single or multiple myomas causing symptoms (namely, heavy menstrual bleeding and bulk related symptoms, which included pelvic pain and pressure effects) sufficiently severe to warrant hysterectomy or myomectomy, and wished to avoid surgery. Eligibility was not restricted by age, fibroid size, location, or previous surgery. Although women desiring children were not excluded from the study, they were further informed of the uncertain effects of UAE on conception or carrying to full term. Exclusion criteria also included patients with pregnancy, active pelvic inflammatory disease, renal insufficiency, undiagnosed pelvic mass, or urogenital infection. A detailed gynecologic history was obtained from each patient, followed by a detailed description on the procedure including a discussion of its potential risks. This study was approved by the Hospital Ethic Committee, with written informed consent obtained from each participant at the time of enrollment.

During preprocedural testing each patient underwent venous blood sampling (complete blood count, blood urea nitrogen, creatinine, prothrombin time) and magnetic resonance imaging of the uterus. Measurements of the uterus and volume of the dominant fibroid were calculated. All the patients were admitted to department of gynecology the day before the procedure. They completed the questionnaire including information on demographics and medical and gynecologic history. All procedures were performed by the same interventional radiologist according to the same procedure protocol. Under local anesthesia vascular access was obtained with 5F catheter via the right femoral artery and aortic

bifurcation to the contralateral internal iliac artery. Digital angiography was performed to identify the origin of the uterine artery, and thereafter, the left uterine artery was catheterized with coaxial 3F microcatheter. The tip of the microcatheter was placed in the distal third of the left uterine artery, and 350-500 μm sized polyvinyl alcohol particles (Ivalon, Nycomed, Paris) were injected until there was complete stasis of flow. After confirming the presence of a stagnant column of contrast in the left uterine artery, the right uterine artery was catheterized in similar fashion and embolized. The procedure is completed when there is no flow in either uterine artery. All catheters were removed and groin pressure was applied for 10 to 15 minutes, thus completing the procedure. The goal of the therapy was to occlude the uterine artery branches that supply only the fibroid tumors and spare normal myometrial vessels. The arteriograms obtained after embolization revealed complete occlusion of the branches supplying the fibroids. After the procedure, patients were kept in hospital for 24-48 hours for further observation hematoma formation at the arterial puncture site, and pain control. The patients had received intravenous medications for nausea, vomiting or pain control. The majority of the patients left the hospital next day after the procedure. They completed outcome questionnaires following their treatment. All patients with successful procedures were evaluated at 3, six and 12 months after embolization with gynecologic examination, magnetic resonance imaging, and questionnaire. They were asked whether their symptoms resolved completely, improved, remained unchanged or deteriorated. Furthermore, they were asked about their satisfaction with the procedure. Measurements of the uterus and volume of the dominant fibroid were calculated. The percent volume reduction was calculated for each patient. Symptom change and patient satisfaction was classified as markedly improved, moderately improved, slightly improved, unchanged and worse.

Descriptive statistics, including means and ranges were calculated for dominant fibroid and uterine volumes, demographic and clinical characteristics. Differences in dominant fibroid and uterine volumes before and after UAE were analyzed with Student's paired *t*-test. Statistical significance was set at a *P* value < 0.05.

6.2 Results

Baseline patient characteristics are summarized in Table 1. There were 347 patients included in the study, but bilateral UAE was successful in 336 (96.8%) cases. Eleven (3.2%) procedures were technically unsuccessful, four because of malformed vessels and one of them had allergic reaction to contrast medium. We excluded from statistical data processing unsuccessful procedures.

	Mean \pm SD	Range
Age (years)	42.9 \pm 4.1	36 - 51
Weight (kg)	67.7 \pm 4.7	55 - 87
Height (cm)	168.5 \pm 3.2	157 - 181
Parity (number)	2.2 \pm 0.4	1 - 4
Procedure time (min.)	37.0 \pm 4.3	25 - 81
Duration of hospitalization (days)	1.4 \pm 0.5	1 - 6

Table 1. Characteristics of patients with successful procedures (N=336)

	N	(%)
Moderate pain	47	(14)
Severe pain	17	(5)
Fever after procedure	30	(9)
Fibroid expulsion	3	(1)
Transient amenorrhea	17	(5)
Persisting amenorrhea	10	(3)

Table 2. Complications after uterine artery embolization (N=336)

Table 2. summarizes complications of the embolization. After the procedure, most patients experienced crampy pelvic pain, of variable intensity, which was well managed with the standard analgesia protocol (narcotics and non-steroidal anti-inflammatory drugs). Some of the participants had nausea, and only few of them had vomiting. The both symptoms were successfully cured with antiemetics. All patients had an uneventful recovery and were able to return to normal activity within two weeks of embolization. Ten (3%) of participants had persisting amenorrhea after procedure. All of them were older than 45 years. None reported any new gynecologic or medical problem during the follow-up period. There were no deaths and no major permanent injuries.

	FOLLOW - UP (months)				<i>P</i> - level*
	0	3	6	12	
Uterine volume (cm ³)	860	534 (-38%)	370 (-57%)	335 (-61%)	< 0.01
Dominant fibroid volume (cm ³)	385	214 (-46%)	155 (-61%)	134 (-66%)	< 0.01

*t-test

Table 3. Rate of regression of uterine and dominant fibroid volume determined by magnetic resonance scanning (N=336)

Rate of regression uterine and dominant fibroid volume determined by magnetic resonance scanning 3, 6 and 12 months after procedure shows Table 3. Median uterine volume decreased by 38%, 57%, and 61% after 3, 6 and 12 months after embolotherapy, respectively. Comparison of the regression of preprocedural and final uterine volume revealed statistical significance ($p < 0.01$). Median dominant fibroid volume decreased by 46%, 61%, and 66% after 3, 6 and 12 months from preprocedure values, respectively. The quantum regression of pretreatment to final dominant fibroid volume also revealed statistical significance ($p < 0.01$).

No patients were lost to follow-up.

	N	(%)
Markedly improved	239	(71)
Moderately improved	71	(21)
Slightly improved	20	(6)
Unchanged	7	(2)
Worse	0	

Table 4. Experience/ satisfaction of the patients (N=336)

Patient satisfaction with UAE treatment paralleled symptomatic outcome, with moderate to great satisfaction expressed by 92 percent patients. All women reported resumption of regular menses except ten (3%) with persisting amenorrhea.

Therefore, during our research we tested 57 women younger than 40 years who were candidates for pregnancy. Our concern was to investigate ovarian function, vitality of the endometrium, existence of menstruation and menstrual cycle, and fertility. Ovarian reserve is best tested by a combination of serum hormones, Follicle Stimulating Hormone (FSH) and Anti-Mullerian hormone (AMH), and pelvic ultrasound (antral follicle count and ovarian volume). The combination of these tests is called the Egg Timer. However, the serum AMH is the most sensitive component of the Egg Timer, and this test alone can be used as an initial screening test for ovarian reserve. AMH levels are constant and the AMH test can be done on any day of a woman's cycle. AMH hormone levels be a fertility test. We serially measured FSH and AMH blood levels before and after UAE. To estimate the ovarian volume, each ovary was measured in three planes (anterior-posterior, longitudinal and transverse), and the volume was calculated with the prolate ellipsoid formula. To estimate the antral follicle number, all follicles up to 5 mm in diameter visible in each ovary were counted. Vitality of the endometrium has been tested on tissue biopsy of the endometrium. Endometrial tissue samples were immunohistochemically evaluated by monoclonal antibodies for protein Ki-67 and matrix metalloproteinases 1 and 2.

All of the patients were evaluated pre- end post-embolization. There was no statistical significance between all parameters studied before and post-embolization. These data are evidence that embolization does not affect the biology of the ovary and endometrium, or the fertility of women. Finally, our greatest successes were 22 pregnancies in 21 women among the tested women younger than 40 years (one woman had two pregnancies). Among them, ten women was duly born to live, full term and normal children. Unfortunately, the other had a miscarriage. However, our results are promising.

7. UAE compared to surgery

There are eight studies published that have compared the outcomes of UAE versus conventional surgical procedures for symptomatic fibroids. So far, three studies have been performed in which clinical outcomes of UAE were compared with those of abdominal myomectomy, two retrospective cohort studies (Broder et al., 2002; Razavi et al., 2003) and one prospective, but non-randomized, trial (Goodwin et al., 2006). Overall, these studies consistently reported that two procedures were equally safe and effective in relieving fibroid-related symptoms. The investigators also reported shorter hospital stays, faster recovery times and a lower overall morbidity rate for UAE than for myomectomy. Finally, they found no differences between the groups in the rate of subsequent interventions.

To date, there have been four studies, one multi-center prospective (Spies, 2004a, 2004b), one multi-center retrospective cohort (Dutton et al., 2007) and two randomized controlled trials (RCTs) (Pinto et al., 2003), and the EMMY trial published in four papers (Hehenkamp, 2005, 2006; Volkers, 2006, 2007) published that compared UAE with hysterectomy. In a third RCT, outcomes of UAE were compared with outcomes of a mixed group of hysterectomies and myomectomies (Edwards et al., 2007).

The investigators from all studies reported significant differences between the groups in the mean hospital stay and recovery time: both were significantly shorter in UAE cohorts. There were no differences between the groups in the degree of improvement in pressure symptoms, overall health assessment, and quality of life scores or the rate of patient satisfaction with outcomes. The investigators found no differences between the groups in the overall complication rate within the first 30 days of treatment, but hysterectomy women were more likely to experience major complications than UAE women. Women in the UAE group also reported significantly less pain during the first 24 h and first week postoperatively and returned to work sooner than hysterectomy patients. The investigators reported lower rates of overall morbidity in UAE group than in the hysterectomy cohort. The overall morbidity was higher in the hysterectomy than in the UAE group.

At the end, from all studies at 1 year of follow-up, 22 women in the UAE groups had required additional interventions (hysterectomy or repeated UAE) to treat persistent or recurrent symptoms. Of these re-interventions, two were due to bilaterally failed UAE procedures. Finally, based on these investigations, uterine artery embolization is equal to surgery in treating uterine fibroids.

8. Conclusion

Expanding non-surgical treatment options for fibroids are advancing care for women, who are now increasingly willing to be treated while keeping the constraints and sequelae of treatment to a minimum. At the same time, the new possibilities afforded by these minimally invasive options do raise challenging questions about changing indications for surgery in the management of uterine fibroids. So far, however, the availability of alternative treatments has failed to substantially change everyday clinical practice, and the majority of women with symptomatic fibroids are still managed surgically. It is more difficult to be sure of the reasons why UAE remains underused in spite of the accumulating good-quality evidence to support its safety and effectiveness. The major issues, however, seem to be about increasing the gynaecologists' awareness and acceptance of UAE as a viable treatment option for fibroids and improving the collaboration between gynaecologists and interventional radiologists to facilitate optimal care for patients.

Nevertheless, it is clear that UAE has good outcomes resulting in a similar complication-rate and similar health related quality of life scores and satisfaction-rates when compared to hysterectomy. In view of these findings, UAE deserves a place in the therapeutic arsenal for symptomatic uterine fibroids. In conclusion, after tens of thousands of successfully performed UAE worldwide, it is proved that this method is an effective alternative to surgery. UAE is a successful, minimal invasive treatment of myomas that preserves the uterus and requires shorter hospitalization and recovery times than surgery. The complication rate is low, and the results are rapid and impressive. In the near future, embolization might replace conventional medical and surgical treatments of uterine fibroids. The results of this study indicate that this procedure might be recommended as a primary treatment for young patients with fibroids who wish to preserve, or enhance, their fertility. In summary, UAE appears to be an excellent treatment option for most women with symptomatic fibroids, especially for those who no longer desire fertility but wish to avoid surgery or are poor surgical risks. Appropriate pre-procedure selection and careful follow-up of patients are necessary to optimize clinical outcomes from this therapy. For this

reason, an interdisciplinary approach involving both gynaecologists and interventional radiologists, with gynaecologists taking a pivotal role in the selection, co-management and follow-up of patients undergoing UAE should be implemented into clinical practice.

9. References

- ACOG Committee Opinion No. 444. (2009). Choosing the route of hysterectomy for benign disease. *Obstet Gynecol*, Vol. 114, No. 5, pp. 1156-1158, ISSN 0029-7844
- Advincula AP, Song A, Burke W, et al.(2004). Preliminary experience with robot-assisted laparoscopic myomectomy. *J Am Assoc Gynecol Laparosc*, Vol. 11, No. 4, pp. 511-518, ISSN 0015-0282
- Ahmad A, Qadan L, Hassan N, et al. (2002). Uterine artery embolization treatment of uterine fibroids: effect on ovarian function in younger women. *J Vasc Interv Radiol*, Vol. 13, No.10, pp. 1017-1020, ISSN 1051-0443
- Altgassen C, Kuss S, Berger U, et al.(2006). Complications in laparoscopic myomectomy. *Surg Endosc*, Vol. 20, No. 4, pp. 614-618, ISSN 0930-2794
- Amato P, Roberts AC.(2001). Transient ovarian failure: a complication of uterine artery embolization. *Fertil Steril*, Vol. 75, No. 2, pp. 438-439, ISSN 0015-0282
- Ananth CV, Demissie K, Smulian JC, et al. (2003). The effect of placenta previa on neonatal mortality: a population based study in the United States, 1989 through 1997. *Am J Obstet Gynecol*, Vol. 188, No. 5, pp. 1299 -1304, ISSN 0002-9378
- Andrews RT, Brown PH. (2000). Uterine arterial embolization: Factors influencing patient radiation exposure. *Radiology* , Vol. 217, No. 3, pp. 713-722, ISSN: 0033-8419 (printed), 1527-1315 (electronic)
- Attilakos G, Fox R. (2005). Regression of tamoxifen-stimulated massive uterine fibroid after conversion to anastrozole. *J Obstet Gynaecol*, Vol. 25, No. 6, pp. 609-610, ISSN 0144-3615
- Aungst M, Wilson M, Vournas K, et al. (2004). Necrotic leiomyoma and gram-negative sepsis eight weeks after uterine artery embolization. *Obstet Gynecol*, Vol. 104, No. 5, pp. 1161-1164, ISSN 0029-7844
- Benassi L, Rossi T, Kaihura CT, et al. (2002). Abdominal or vaginal hysterectomy for enlarged uteri: a randomized clinical trial. *Am J Obstet Gynecol*, Vol. 187, No. 6, pp. 1561-1565, ISSN 0002-9378
- Berkane N, Moutafoff-Borie C. (2010). Impact of previous uterine artery embolization on fertility. *Curr Opin Obstet Gynecol*, Vol. 22, No. 3, p. 242-247, ISSN 1040-872X
- Binkert CA, Andrews RT, Kaufman JA.(2001). Utility of nonselective abdominal aortography in demonstrating ovarian artery collaterals in patients undergoing uterine artery embolization for fibroids. *J Vasc Interv Radiol*, Vol. 12, No. 7, pp. 841-845, ISSN 1051-0443
- Broder MS, Goodwin S, Chen G, et al. (2002). Comparison of long-term outcomes of myomectomy and uterine artery embolization. *Obstet Gynecol*, Vol. 100, No. 5, pp. 864-868, ISSN 0029-7844
- Carpenter TT, Walker WJ. (2005). Pregnancy following uterine artery embolisation for symptomatic fibroids: a series of 26 completed pregnancies. *BJOG*, Vol. 112, No. 3, pp. 321-325, ISSN 1471-0528
- Castaneda-Zuniga WR, Sanchez R, Amplatz K.(1978). Experimental observations on short and long-term effects of arterial occlusion with Ivalon. *Radiology*, Vol. 126, No. 3, pp. 783-785, ISSN: 0033-8419 (printed), 1527- 1315 (electronic)

- Chrisman HB, Saker MB, Ryu RK. (2000). The impact of uterine fibroid embolization on resumption of menses and ovarian function. *J Vasc Interv Radiol*, Vol. 11, No. 6, pp. 699–703, ISSN 1051-0443
- Ciraru-Vigneron N, Ravina JH. (2001) Pregnancy subsequent to uterine artery embolization. *Fertil Steril*, Vol. 75, No. 6, pp. 1247-1248, ISSN 0015-0282
- Colgan TJ, Pron G, Mocarski EJM, et al. (2003). Pathologic features of uteri and leiomyomas following uterine artery embolization for leiomyomas. *Am J Surg Pathol*, Vol. 27, No. 2, pp. 167–177, ISSN 0147-5185
- Committee on Gynecologic Practice, American College of Obstetricians and Gynecologists. (2004). ACOG Committee Opinion: uterine artery embolization. *Obstet Gynecol*, Vol. 103, No. 2, pp. 403–404, ISSN 0029-7844
- Cook H, Ezzati M, Segars JH, et al. (2010). The impact of uterine leiomyomas on reproductive outcomes. *Minerva Ginecol*, Vol. 62, No. 3, pp. 225–236, ISSN 0026-4784
- Coronado GD, Marshall LM, Schwartz SM. (2000). Complications in pregnancy, labor and delivery with uterine leiomyomas: a population-based study. *Obstet Gynecol*, Vol. 95, No. 5, pp. 764–769, ISSN 0029-7844
- D'Angelo AD, Amso NN, Wood A. (2003). Spontaneous multiple pregnancy after uterine artery embolization for uterine fibroid: a case report. *Eur J Obstet Gynecol Reprod Biol*, Vol. 110, No. 2, pp. 245–246, ISSN 0301-2115
- Day Baird D, Dunson DB, Hill MC, et al. (2003). High cumulative incidence of uterine leiomyoma in black and white women: ultrasound evidence. *Am J Obstet Gynecol*, Vol. 188, No. 1, pp. 100–107, ISSN 0002-9378
- de Block S, de Vries C, Prinssen HM, et al. (2003). Fatal sepsis after uterine artery embolization with microspheres. *J Vasc Interv Radiol*, Vol. 14, No. 6, pp. 779–783, ISSN 1051-0443
- Dodero D, Corticelli A, Pedretti L. (2005). Influence of a decisional tree on the route of hysterectomy for benign disease in Italy: personal experience. *Clin Exp Obstet Gynecol*, Vol. 32, No. 3, pp. 185–188, ISSN 0390-6663
- Dutton S, Hirst A, McPherson K, et al. (2007). UK multicentre retrospective cohort study comparing hysterectomy and uterine artery embolisation for the treatment of symptomatic uterine fibroids (HOPEFUL study): main results on medium-term safety and efficacy. *BJOG*, Vol. 114, No. 11, pp. 1340–1351, ISSN 1471-0528
- Edwards RD, Moss JG, Lumsden MA, et al. (2007). Uterine artery embolization versus surgery for symptomatic uterine fibroids. *N Engl J Med*, Vol. 356, No. 4, pp. 360–370, ISSN 0028-4793
- Farquhar CM, Steiner CA. (2002). Hysterectomy rates in the United States 1990–1997. *Obstet Gynecol*, Vol. 99, No. 2, pp. 229–234, ISSN 0029-7844
- Fennessy FM, Tempany CM, McDannold NJ, et al. (2007). Uterine leiomyomas: MR imaging-guided focused ultrasound surgery—results of different treatment protocols. *Radiology*, Vol. 243, No. 3, pp. 885–893, ISSN: 0033-8419 (printed), 1527-1315 (electronic)
- Fiscella K, Eisinger SH, Meldrum S, et al. (2006). Effect of mifepristone for symptomatic leiomyomata on quality of life and uterine size: a randomized controlled trial. *Obstet Gynecol*, Vol. 108, No. 6, pp. 1381–1387, ISSN 0029-7844
- Flake GP, Andersen J, Dixon D. (2003). Etiology and pathogenesis of uterine leiomyomas: a review. *Environ Health Perspect*, Vol. 111, No. 8, pp. 1037–1054, ISSN 0091-6765

- Fogt F, Hinds N, Zimmerman RL. (2003). Histologic Features of Uterine Leiomyomata Treated With Microsphere Embolization. *Obstet Gynecol*, Vol. 102, No. 3, pp. 600-602, ISSN 0029-7844
- Forman RG, Reidy J, Nott V, et al. (1999). Fibroids and fertility. *Min Invas Ther Allied Technol*, Vol. 8, No. 6, pp. 415-419, ISSN: 1364-5706 (printed), 1365-2931 (electronic), 1364-5706 (linking)
- Fraser IS, Critchley HO, Munro MG, et al. (2007). A process designed to lead to international agreement on terminologies and definitions used to describe abnormalities of menstrual bleeding. Writing Group for this Menstrual Agreement Process. *Fertil Steril*, Vol. 87, No. 3, pp. 466-476, ISSN 0015-0282
- Freed MM, Spies JB. (2010). Uterine artery embolization for fibroids: a review of current outcomes. *Semin Reprod Med*, Vol. 28, No. 3, pp. 235-241, ISSN 1526-8004
- Friedman AJ, Daly M, Juneau-Norcross M, et al. (1992). Recurrence of myomas after myomectomy in women pretreated with leuprolide acetate depot or placebo. *Fertil Steril*, Vol. 58, No. 1, pp. 205-208, ISSN 0015-0282
- Gimbel H. (2007). Total or subtotal hysterectomy for benign uterine diseases? A metaanalysis. *Acta Obstet Gynecol Scand*, Vol. 86, No. 2, pp. 133-144, ISSN 0001-6349
- Goldberg J, Pereira L, Berghella V. (2002). Pregnancy after uterine artery embolization. *Obstet Gynecol*, Vol. 100, No. 5, pp. 869-872, ISSN 0029-7844
- Goldberg J, Pereira L, Berghella V. (2004). Pregnancy outcomes after treatment of uterine fibromyomata: UAE vs laparoscopic myomectomy. *Am J Obstet Gynecol*, Vol. 191, No. 1, pp. 18-21, ISSN 0002-9378
- Goodwin SC, Vedantham S, McLucas B, et al. (1997). Preliminary experience with uterine artery embolization for uterine fibroids. *J Vasc Interv Radiol*, Vol. 8, No. 4, pp. 517-526, ISSN 1051-0443
- Goodwin SC, Bradley LD, Lipman JC, et al. (2006). Uterine artery embolization versus myomectomy: a multicenter comparative study. *Fertil Steril*, Vol. 85, No. 1, pp. 14-21, ISSN 0015-0282
- Guarnaccia MM, Rein MS. (2001). Traditional surgical approaches to uterine fibroids: abdominal myomectomy and hysterectomy. *Clin Obstet Gynecol*, Vol. 44, No. 2, pp. 385-400, ISSN 0028-4793
- Harrison-Woolrych M, Robinson R. (1995). Fibroid growth in response to high-dose progestogen. *Fertil Steril*, Vol. 64, No. 1, p.p. 191-192, ISSN 0015-0282
- Hascalik S, Celik O, Sarac K, et al. (2004). Transient ovarian failure: a rare complication of uterine fibroid embolization. *Acta Obstet Gynecol Scand*, Vol. 83, No. 7, pp. 682-685, ISSN 0001-6349
- Heaston DK, Mineau DE, Brown BJ, et al. (1979). Transcatheter arterial embolization for the control of persistent massive puerperal hemorrhage after bilateral surgical hypogastric artery ligation. *Am J Roentgenol*, Vol. 133, No. 1, pp. 152-154, ISSN 0361-803X
- Hehenkamp WJ, Volkers NA, Donderwinkel PF, et al. (2005). Uterine artery embolization versus hysterectomy in the treatment of symptomatic uterine fibroids (EMMY trial): peri- and postprocedural results from a randomized controlled trial. *Am J Obstet Gynecol*, Vol. 193, No. 5, pp. 1618-1629, ISSN 0002-9378
- Hehenkamp WJ, Volkers NA, Brokemans FJ, et al. (2007). Loss of ovarian reserve after uterine artery embolization: a randomized comparison with hysterectomy. *Hum Reprod*, Vol. 22, No. 7, pp. 1996-2005, ISSN 0268-1161

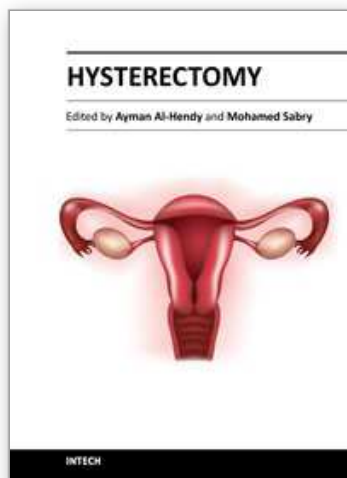
- Hehenkamp WJ, Volkers NA, Birnie E, et al. (2006). Pain and return to daily activities after uterine artery embolization and hysterectomy in the treatment of symptomatic uterine fibroids: results from the randomized EMMY trial. *Cardiovasc Interv Radiol*, Vol. 29, No. 2, pp. 179-187, ISSN 0174-1551
- Holloway RW, Patel SD, Ahmad S. (2009). Robotic surgery in gynecology. *Scand J Surg*, Vol. 98, No. 2, pp. 96-109, ISSN 1457-4969
- Homer H, Saridogan E. (2010). Uterine artery embolization for fibroids is associated with an increased risk of miscarriage. *Fertil Steril*, Vol. 94, No. 1, pp. 324-330, ISSN 0015-0282
- Hovsepian DM, Siskin GP, Bonn J, et al. (2004). Quality improvement guidelines for uterine artery embolization for symptomatic leiomyomata. *J Vasc Interv Radiol*, Vol. 15, No. 6, pp. 535-541, ISSN 1051-0443
- Huang JY, Kafy S, Dugas A, et al. (2006). Failure of uterine fibroid embolization. *Fertil Steril*, Vol. 85, No. 1, pp. 30-35, ISSN 0015-0282
- Jacobson GF, Shaber RE, Armstrong MA, et al. (2006). Hysterectomy rates for benign indications. *Obstet Gynecol* Vol. 107, No. 6, pp. 1278-1283, ISSN 0029-7844
- Johns A. (1997). Supracervical versus total hysterectomy. *Clin Obstet Gynecol*, Vol. 40, No. 4, pp. 903-913, 0009-9201
- Kovacs P, Stangel JJ, Santoro NF, et al. (2002). Successful pregnancy after transient ovarian failure following treatment of symptomatic leiomyomata. *Fertil Steril*, Vol. 77, No. 6, pp. 1292-1295, ISSN 0015-0282
- Kovac SR, Barhan S, Lister M, et al. (2002). Guidelines for the selection the route of hysterectomy: application in a resident clinic population. *Am J Obstet Gynecol*, Vol. 187, No. 6, pp. 1521-1527, ISSN 0002-9378
- Manyonda I, Sinthamoney E, Belli AM. (2004). Controversies and challenges in the modern management of uterine fibroids. *BJOG*, Vol. 111, No. 2, pp. 95-102, ISSN 1471-0528
- Maresh MJ, Metcalfe MA, McPherson K, et al. (2002). The VALUE national hysterectomy study: description of the patients and their surgery. *BJOG*, Vol. 109, No. 3, pp. 302-312, ISSN 1471-0528
- Marret H, Alonso AM, Cottier JP, et al. (2003). Leiomyoma recurrence after uterine artery embolization. *J Vasc Interv Radiol*, Vol. 14, No. 11, pp. 1395-1400, ISSN 1051-0443
- Marret H, Keris Yle B, Acker O, et al. (2004). Late leiomyoma expulsion after uterine artery embolization. *J Vasc Interv Radiol*, Vol. 15, No. 12, pp. 1483-1485, ISSN 1051-0443
- McLucas B, Goodwin S, Adler L, et al. (2001). Pregnancy following uterine fibroid embolization. *Int J Gynaecol Obstet*, Vol. 74, No. 1, pp. 1-7, ISSN 0020-7292
- McLucas B. (2009). Repeat uterine artery embolization following technical failure. *Minim Invasive Ther Allied Technol*, Vol. 18, No. 2, pp. 78-81, ISSN: 1364-5706 (print), 1365-2931 (electronic), 1364-5706 (linking)
- Mehta H, Sandhu C, Matson M, et al. (2002). Review of readmissions due to complications from uterine fibroid embolization. *Clin Radiol*, Vol. 57, No. 12, pp. 1122-1124, ISSN 0009-9260
- Mercorio F, De Simone R, Di Spiezio Sardo A, et al. (2003). The effect of a levonorgestrel-releasing intrauterine device in the treatment of myoma-related menorrhagia. *Contraception*, Vol. 67, No. 4, pp. 277-280, ISSN 0010-7824
- Michael SB, Scott G, Gary C, et al. (2002). Comparison of Long-Term Outcomes of Myomectomy and Uterine Artery Embolization. *Obstet Gynecol*, Vol. 100, No. 5, pp. 864-868, ISSN 0029-7844

- Miller DA, Chollet JA, Goodwin TM. (1997). Clinical risk factors for placenta previa-placenta accreta. *Am J Obstet Gynecol*, Vol. 177, No. 1, pp. 210-214, ISSN 0002-9378
- Morita Y, Ito N, Ohashi H. (2007). Pregnancy following MR-guided focused ultrasound surgery for a uterine fibroid. *Int J Gynaecol Obstet*, Vol. 99, No. 1, pp. 56-57, ISSN 0020-7292
- Myers ER, Barber MD, Gustilo-Ashby T, et al. (2002). Management of uterine leiomyomata: what do we really know? *Obstet Gynecol*, Vol. 100, No. 1, pp. 8-17, ISSN 0029-7844
- Narayan A, Lee AS, Kuo GP, et al. (2010). Uterine artery embolization versus abdominal myomectomy: a long- term clinical outcome comparison. *J Vasc Interv Radiol*, Vol. 21, No. 7, pp. 1011-1017, ISSN 1051-0443
- Nieboer TE, Johnson N, Lethaby E, et al. (2009). Surgical approach to hysterectomy for benign gynecological disease. *Cochrane Database Syst Rev*, (3): CD003677, ISSN 0020-7292
- Nikolic B, Spies JB, Lundsten MJ, et al. (2000). Patient radiation dose association with uterine artery embolization. *Radiology*, Vol. 214, No. 1, pp. 121-125, ISSN: 0033-8419 (printed), 1527-1315 (electronic)
- Nikolic B, Nguyen K, Martin LG, et al. (2004). Pyosalpinx developing from a preexisting hydrosalpinx after uterine artery embolization. *J Vasc Interv Radiol*, Vol. 15, No. 3, pp. 297-301, ISSN 1051-0443
- Ogliari KS, Mohallem SV, Barrozo P, et al. (2005). A uterine cavity-myoma communication after uterine artery embolization: two case reports. *Fertil Steril*, Vol. 83, No. 1, pp. 220-222, ISSN 0015-0282
- Olive DL, Lindheim SR, Pritts EA. (2004). Non-surgical management of leiomyoma: impact on fertility. *Curr Opin Obstet Gynecol*, Vol. 16, No. 3, pp. 239-243, ISSN 1040-872X
- Oliver JA, Lance JS. (1979). Selective embolization to control massive hemorrhage following pelvic surgery. *Am J Obstet Gynecol*, Vol. 135, pp. 431-432, ISSN 0002-9378
- Paxton BE, Lee JM, Kim HS. (2006). Treatment of Intrauterine and Large Pedunculated Subserosal Leiomyomata with Sequential Uterine Artery Embolization and Myomectomy. *JVIR*, Vol. 17, No. 12, pp. 1947-1950, ISSN 1051-0443
- Pelage JP, Le Dref O, Jacob D. (2000). Uterine artery embolization: anatomical and technical considerations, indications results, and complications. *J Radiol*, Vol. 81, No. 12 Suppl., pp. 1863-1872, ISSN 0013-9580
- Pelage JP, Le Dref O, Soyer P, et al. (2000). Fibroid related menorrhagia: treatment with superselective embolization of the uterine arteries and mid-term follow up. *Radiology*, Vol. 215, No. 2, pp. 428-431, ISSN: 0033-8419 (printed), 1527-1315 (electronic)
- Pelage JP, Guaou NG, Jha RC, e al. (2004). Uterine fibroid tumors: long-term MR imaging outcome after embolization. *Radiology*, Vol. 230, No. 3, pp. 803-809, ISSN: 0033-8419 (printed), 1527-1315 (electronic)
- Pinto I, Chimeno P, Romo A, et al. (2003). Uterine fibroids: Uterine artery embolization versus abdominal hysterectomy for treatment-a prospective, randomized, and controlled clinical trial. *Radiology* Vol. 226, No. 3, pp. 425-431, ISSN: 0033-8419 (printed), 1527-1315 (electronic)
- Pinto Pabón I, Magret JP, Unzurrunzaga EA, et al. (2008). Pregnancy after uterine fibroid embolization: follow-up of 100 patients embolized using tris-acryl gelatin microspheres. *Fertil Steril*, Vol. 90, No. 6, pp. 2356-2360, ISSN 0015- 0282

- Pron G, Bennett J. (2003a). The Ontario Uterine Fibroid Embolization Trial. Part 2: uterine fibroid reduction and symptom relief after uterine artery embolization for fibroids. *Fertil Steril*, Vol. 79, No. 1, pp. 120-127, ISSN 0015-0282
- Pron G, Mocarski E, Bennet J, et al. (2003b). Tolerance, hospital stay, and recovery after uterine artery embolization for fibroids: the Ontario Uterine Fibroid Embolization Trial. *J Vasc Interv Radiol*, Vol. 14, No. 10, pp. 1243-1250, ISSN 1051-0443
- Pron G, Mocarski E, Bennett J, et al. (2005). Pregnancy after uterine artery embolization for leiomyomata: the Ontario multicenter trial. *Obstet Gynecol*, Vol. 105, No. 1, pp. 67-76, ISSN 0029-7844
- Rashid S, Khaund A, Murray LS, et al. (2010). The effects of uterine artery embolisation and surgical treatment on ovarian function in women with uterine fibroids. *BJOG*, Vol. 117, No. 8, pp. 985-989, ISSN 1471-0528
- Ravina JH, Herbreteau D, Ciraru-Vigneron, et al. (1995). Arterial embolisation to treat uterine myomata. *Lancet*, Vol. 346, No. 8976, pp. 671-672, ISSN: 0140-6736 (print), 1474-547X (electronic)
- Ravina JH, Ciraru-Vigneron N, Aymard A, et al. (1999). Uterine artery embolisation for fibroid disease: results of a 6 year study. *Minim Invas Ther Allied Technol*, Vol. 8, No. 6, pp. 441-447, ISSN: 1364-5706 (Print), 1365- 2931 (Electronic), 1364-5706 (Linking)
- Ravina JH, Aymard A, Ciraru-Vigneron N. (2000). Arterial embolization of uterine myoma: results apropos of 286 cases. *J Gynecol Obstet Biol Reprod*, Vol. 29, No. 3, pp. 272-275, ISSN 0368-2315
- Ravina JH, Vigneron NC, Aymard A, et al. (2000). Pregnancy after embolization of uterine myoma: report of 12 cases. *Fertil Steril*, Vol. 73, No. 6, pp. 1241-1243, ISSN 0015-0282
- Razavi MK, Wolanske KA, Hwang GL, et al. (2002). Angiographic classification of ovarian artery-to-uterine artery anastomoses: initial observations in uterine fibroid embolization. *Radiology*, Vol. 224, No. 3, pp. 707-712, ISSN: 0033-8419 (printed), 1527-1315 (electronic)
- Razavi MK, Hwang G, Jahed A, et al. (2003). Abdominal myomectomy versus uterine fibroid embolization in the treatment of symptomatic uterine leiomyomas. *Am J Roentgenol*, Vol. 180, No. 6, pp. 1571-1575, ISSN 0361-803X
- Roth RA, Spies JB, Walsh SM, et al. (2000). Pain after uterine artery embolization for leiomyomata: Can its severity be predicted and does severity predict outcome? *J Vasc Interv Radiol*, Vol. 11, No. 8, pp. 1047-1052, ISSN 1051-0443
- Ruuskanen A, Hippeläinen M, Sipola P, et al. (2010). Uterine artery embolisation versus hysterectomy for leiomyomas: primary- and 2-year follow-up results of a randomised prospective clinical trial. *European Radiology*, Vol. 20, No. 10, pp. 2524-2532, ISSN 0938-7994
- Ryan JM, Gainey M, Glasson J, et al. (2002). Simplified pain-control protocol after uterine artery embolization. *Radiology*, Vol. 224, No. 2, pp. 610-611, ISSN (printed) 0033-8419, ISSN (electronic) 1527-1315
- Ryu RK, Chrisman HB, Omary RA, et al. (2001). The vascular impact of uterine artery embolization: prospective sonographic assessment of ovarian arterial circulation. *J Vasc Interv Radiol*, Vol. 12, No. 9, pp. 1071-1074, ISSN 1051-0443
- Shozu M, Murakami K, Segawa T, et al. (2003). Successful treatment of a symptomatic uterine leiomyoma in a perimenopausal woman with a nonsteroidal aromatase inhibitor. *Fertil Steril*, Vol. 79, No. 3, pp. 628-631, ISSN 0015-0282

- Siskin GP, Stainken BF, Dowling K, et al. (2000). Outpatient uterine artery embolization for symptomatic uterine fibroids: experience in 49 patients. *J Vasc Interv Radiol*, Vol. 11, No. 3, pp. 305–311, ISSN 1051-0443
- Sizzi O, Rossetti A, Malzoni M, et al. (2007). Italian multicenter study on complications of laparoscopic myomectomy. *J Minim Invasive Gynecol*, Vol. 14, No. 4, pp. 453–462, ISSN 1553-4650
- Smith WJ, Upton E, Shuster EJ, et al. (2004). Patient satisfaction and disease specific quality of life after uterine artery embolization. *Am J Obstet Gynecol*, Vol. 190, No. 6, pp. 1697–1703, ISSN 0002-9378
- Spies JB, Scialli AR, Jha RC, et al. (1999). Initial results from uterine fibroid embolization for symptomatic leiomyomata. *J Vasc Interv Radiol*, Vol. 10, No. 9, pp. 1149–1157, ISSN 1051-0443
- Spies JB, Roth AR, Gonsalves SM, et al. (2001). Ovarian function after uterine artery embolization of leiomyomata: assessment with use of serum follicle stimulating hormone assay. *J Vasc Interv Radiol*, Vol. 12, No. 4, pp. 437–442, ISSN 1051-0443
- Spies JB, Benenati JF, Worthington-Kirsch RL, et al. (2001). Initial experience with use of tris-acryl gelatin microspheres for uterine artery embolization for leiomyomata. *J Vasc Interv Radiol*, Vol. 12, No. 9, pp. 1059–1063, ISSN 1051-0443
- Spies JB, Spector A, Roth AR, et al. (2002). Complications after uterine artery embolization for leiomyomas. *Obstet Gynecol*, Vol. 100, No. 5, pp. 873–880, ISSN 0029-7844
- Spies JB, Roth AR, Jha RC, et al. (2002). Leiomyomata treated with uterine artery embolization: Factors associated with successful symptom and imaging outcome. *Radiology*, Vol. 222, No. 1, pp. 45–52, ISSN: 0033-8419 (printed), 1527-1315 (electronic)
- Spies JB. (2003). Uterine artery embolization for fibroids: understanding the technical causes of failure. *J Vasc Interv Radiol*, Vol. 14, No. 1, pp. 11–14, ISSN 1051-0443
- Spies JB, Allison S, Flick P, et al. (2004a). Polyvinyl alcohol particles and tris-acryl gelatin microspheres for uterine artery embolization for leiomyomas: results of a randomized comparative study. *J Vasc Interv Radiol*, Vol. 15, No. 8, pp. 793–800, ISSN 1051-0443
- Spies JB, Cooper JM, Worthington-Kirsch R, et al. (2004b). Outcome from uterine embolization and hysterectomy for leiomyomas: results of a multi-center study. *Am J Obstet Gynecol*, Vol. 191, No. 1, pp. 22–31, ISSN 0002-9378
- Spies JB, Sacks D. (2004). Credentials for Uterine Artery Embolization. *J Vasc Interv Radiol*, Vol. 15, No. 2, pp. 111–113, ISSN 1051-0443
- Spies JB, Myers ER, Worthington-Kirsch R, et al. (2005a). The FIBROID Registry: symptom and quality-of-life status 1 year after therapy. *Obstet Gynecol*, Vol. 106, No. 6, pp. 1309–1318, ISSN 0029-7844
- Steinauer J, Pritts EA, Jackson R, et al. (2004). Systematic review of mifepristone for the treatment of uterine leiomyomata. *Obstet Gynecol*, Vol. 103, No. 6, pp. 1331–1336, ISSN 0029-7844
- Stewart EA. (2001). Uterine fibroids. *Lancet*, Vol. 357, No. 9252, pp. 293–298, ISSN: 0140-6736 (print), 1474-547X (electronic)
- Stewart EA, Rabinovici J, Tempany CM, et al. (2006). Clinical outcomes of focused ultrasound surgery for the treatment of uterine fibroids. *Fertil Steril*, Vol. 85, No. 1, pp. 22–29, ISSN 0015-0282

- Tropeano G, Di Stasi C, Litwicka K, et al. (2004). Uterine artery embolization for fibroids does not have adverse effects on ovarian reserve in regularly cycling women younger than 40 years. *Fertil Steril*, Vol. 81, No. 4, pp. 1055–1061, ISSN 0015-0282
- Tulandi T, Sammour A, Valenti D, et al. (2002). Ovarian reserve after uterine artery embolization for leiomyomata. *Fertil Steril*, Vol. 78, No. 1, pp. 197-198, ISSN 0015-0282
- Varelas FK, Papanicolaou AN, Vavatsi-Christaki N, et al. (2007). The effect of anastrozole on symptomatic uterine leiomyomata. *Obstet Gynecol*, Vol. 110, No. 3, pp. 643–649, ISSN 0029-7844
- Vashist A, Studd J, Carey A, et al. (1999). Fatal septicaemia after fibroid embolization. *Lancet*, Vol. 354, No. 9175, pp. 307–308, ISSN: 0140-6736 (print), 1474-547X (electronic)
- Vashisht A, Smith JR, Thorpe-Beeston G, et al. (2001). Pregnancy subsequent to uterine artery embolization. *Fertil Steril*, Vol. 75, No. 6, pp. 1246–1247, ISSN 0015-0282
- Venkatachalam S, Bagratee JS, Moodley J. (2004). Medical management of uterine fibroids with medroxyprogesterone acetate (Depo Provera): a pilot study. *J Obstet Gynaecol*, Vol. 24, No. 7, pp. 798–800, ISSN 0144-3615
- Volkers NA, Hehenkamp WJ, Birnie E, et al. (2006). Uterine artery embolization in the treatment of symptomatic uterine fibroid tumors (EMMY trial): periprocedural results and complications. *J Vasc Interv Radiol*, Vol. 17, No. 3, pp. 471-480, ISSN 1051-0443
- Volkers NA, Hehenkamp WJ, Birnie E, et al. (2007). Uterine artery embolization versus hysterectomy in the treatment of symptomatic uterine fibroids: 2 years' outcome from the randomized EMMY trial. *Am J Obstet Gynecol*, Vol. 196, No. 6, pp. 519.e1–519.e11, ISSN 0002-9378
- Wallach EE, Vlahos NF. (2004). Uterine myomas: an overview of development, clinical features, and management. *Obstet Gynecol*, Vol. 104, No. 2, pp. 393–406, ISSN 0029-7844
- Walker WJ, Pelage JP. (2002). Uterine artery embolisation for symptomatic fibroids: clinical results in 400 women with imaging follow-up. *Br J Obstet Gynecol*, Vol. 109, November, pp. 1263–1272, ISSN 1471-0528
- Walker WJ, Carpenter TT, Kent AS. (2004). Persistent vaginal discharge after uterine artery embolization for fibroid tumors: cause of the condition, magnetic resonance imaging appearance, and surgical treatment. *Am J Obstet Gynecol*, Vol. 190, No. 5, pp. 1230–1233, ISSN 0002-9378
- Walker WJ, McDowell SJ. (2006). Pregnancy after uterine artery embolization for leiomyomata: a series of 56 completed pregnancies. *Am J Obstet Gynecol*, Vol. 195, No. 5, pp. 1266-1271, ISSN 0002-9378
- Weber AM, Lee JC. (1996). Use of alternative techniques of hysterectomy in Ohio, 1988–1994. *N Engl J Med*, Vol. 335, No. 7, pp. 483–489, ISSN 0028-4793
- Worthington-Kirsch RL, Popky GL, Hutchins FL. (1998). Uterine arterial embolization for the management of leiomyomas: quality-of-life assessment and clinical response. *Radiology*, Vol. 208, No. 3, pp. 625-629, ISSN: 0033-8419 (print), 1527-1315 (electronic)
- Worthington-Kirsch R, Spies JB, Myers ER, et al. (2005). The Fibroid Registry for Outcomes Data (FIBROID) for uterine embolization: short term outcomes. *Obstet Gynecol*, Vol. 106, No. 1, pp. 52–59, ISSN 0029-7844
- Zhan S, Li Y, Wang G, Han H, et al. (2005). Effectiveness of intra-arterial anesthesia for uterine fibroid embolization using dilute lidocaine. *Eur Radiol*, Vol. 15, No. 8, pp. 1752-1756, ISSN 0028-4793



Hysterectomy

Edited by Dr. Ayman Al-Hendy

ISBN 978-953-51-0434-6

Hard cover, 426 pages

Publisher InTech

Published online 20, April, 2012

Published in print edition April, 2012

This book is intended for the general and family practitioners, as well as for gynecologists, specialists in gynecological surgery, general surgeons, urologists and all other surgical specialists that perform procedures in or around the female pelvis, in addition to intensives and all other specialties and health care professionals who care for women before, during or after hysterectomy. The aim of this book is to review the recent achievements of the research community regarding the field of gynecologic surgery and hysterectomy as well as highlight future directions and where this field is heading. While no single volume can adequately cover the diversity of issues and facets in relation to such a common and important procedure such as hysterectomy, this book will attempt to address the pivotal topics especially in regards to safety, risk management as well as pre- and post-operative care.

How to reference

In order to correctly reference this scholarly work, feel free to copy and paste the following:

Tomislav Strinic (2012). Is Embolization Equal to Hysterectomy in Treating Uterine Fibroids?, Hysterectomy, Dr. Ayman Al-Hendy (Ed.), ISBN: 978-953-51-0434-6, InTech, Available from:
<http://www.intechopen.com/books/hysterectomy/is-embolization-equal-to-hysterectomy-in-treating-uterine-fibroids->

INTECH
open science | open minds

InTech Europe

University Campus STeP Ri
Slavka Krautzeka 83/A
51000 Rijeka, Croatia
Phone: +385 (51) 770 447
Fax: +385 (51) 686 166
www.intechopen.com

InTech China

Unit 405, Office Block, Hotel Equatorial Shanghai
No.65, Yan An Road (West), Shanghai, 200040, China
中国上海市延安西路65号上海国际贵都大饭店办公楼405单元
Phone: +86-21-62489820
Fax: +86-21-62489821

© 2012 The Author(s). Licensee IntechOpen. This is an open access article distributed under the terms of the [Creative Commons Attribution 3.0 License](https://creativecommons.org/licenses/by/3.0/), which permits unrestricted use, distribution, and reproduction in any medium, provided the original work is properly cited.

IntechOpen

IntechOpen