

# We are IntechOpen, the world's leading publisher of Open Access books Built by scientists, for scientists

6,900

Open access books available

186,000

International authors and editors

200M

Downloads

Our authors are among the

154

Countries delivered to

TOP 1%

most cited scientists

12.2%

Contributors from top 500 universities



WEB OF SCIENCE™

Selection of our books indexed in the Book Citation Index  
in Web of Science™ Core Collection (BKCI)

Interested in publishing with us?  
Contact [book.department@intechopen.com](mailto:book.department@intechopen.com)

Numbers displayed above are based on latest data collected.  
For more information visit [www.intechopen.com](http://www.intechopen.com)



## Joint Salvage Techniques for Stage III/IV Hallux Rigidus

Lawrence M. Oloff, Colin Traynor and Shahan R. Vartivarian  
*Sports Orthopedic and Rehabilitation*  
USA

### 1. Introduction

Hallux rigidus is a disorder of the first metatarsophalangeal joint, characterized by diminished range of motion and progressive degeneration of the joint [Vanore et al, 2003]. It was first described by Davies-Colley who named the disorder “hallux flexus” [Davies-Colley, 1887], then the same condition was reported later by Cotterill and the term “hallux rigidus” was introduced [Cotteril, 2003]. It can occur as a result traumatic injury, congenital or acquired structural deformities, metabolic diseases, biomechanical abnormalities, neuromuscular disorders, or iatrogenic causes.

There is a high prevalence of hallux rigidus in the general population; it is the most common form of osteoarthritis of the foot affecting approximately 2.5% of the adult population, second only to hallux valgus [Keiserman et al, 2005; Padanilam, 2004].

Traumatic causes occur from injuries that result in forced hyperextension or plantar flexion which may create compressive and shear forces that result in chondral or osteochondral injury. The resultant joint damage leads to progressive arthritic changes over time [Shurnas, 2009]. Non-traumatic etiologies alter the normal biomechanics of the first metatarsophalangeal joint. Normal range of motion of the first metatarsophalangeal joint has been defined as being greater than 65 degrees of dorsiflexion and 15 to 20 degrees of plantar flexion [Chang & Camasta, 2001]. Hallux rigidus is a limitation of the normal range of motion. While systemic disease may cause direct degeneration of the articular cartilage, mechanical causes generally result in deterioration through eccentric forces with resultant wear and tear.

Mechanical causes which include metatarsus primus elevatus, congenitally long first metatarsal, hypermobile first ray, pes planus, hallux equinus, hallux valgus and hallux varus [Nilsonne, 1930; Bonney & Macnab, 1952; Bingold & Collins, 1950; Lambrinudi, 1938]. These structural abnormalities alter the axis of motion of the first metatarsophalangeal joint. Elevation of the first metatarsal does not allow the base of the proximal phalanx of the hallux to freely move over the metatarsal head during propulsion. The base of the proximal phalanx instead creates a forced bone on bone interface, jamming the first metatarsophalangeal joint. The dorsal jamming of the joint results in a decrease in dorsiflexion and leads to articular impingement causing abnormal stresses to the dorsal articular surface, promoting osteophytic formation. This further limits joint range of motion,

leading to continued development of periarticular hypertrophic changes and progressive cartilage loss. Continued eccentric wear of the articular surface may progress to ankylosis of the joint. An abnormally long first metatarsal also results in limited dorsiflexion and dorsal eccentric joint overload by preventing plantar flexion of the first metatarsal which improves motion.

## 2. Clinical evaluation

Patients usually present with complaints of pain localized to the first metatarsophalangeal joint or joint stiffness. Onset may be insidious, often times with a history of an arthritic condition, or associated to a specific injury. Patients that describe acute onset need to be evaluated for acute gout, calcium pyrophosphate dehydrate deposition disease, septic arthritis, stress fracture of the sesamoids, soft tissue masses such as ganglion cysts, capsulitis and tendonitis etiologies. Symptoms of hallux rigidus are usually associated with increased activity or by irritation from shoe gear. Casual athletes will note gradual increased pain with trail and hill running in comparison to training on level surfaces. Female patients may state that the height of their heeled shoes has decreased over time due to inability to walk without pain in the great toe joint.

The most common finding on physical exam is the dorsal bunion. Dorsiflexion is generally limited from the jamming of the joint and may or may not be painful [Vanore et al 2003]. Early stage hallux rigidus has pain only at the end range of motion, while in contrast, end stage hallux rigidus may be pain free due to ankylosis of the first metatarsophalangeal joint. Crepitus during range of motion of the joint may also be present. Plantar flexion of the hallux reveals a more pronounced dorsal bump. The patient may experience pain with direct palpation of the dorsal surface of the joint. Gait analysis may reveal compensation leading to lateral metatarsalgia and formation of plantar hyperkeratoses. Gait changes to accommodate the limited motion in the big toe joint. This may manifest as a shortened stride, inverted posture of the foot, or as circumduction of the entire extremity. It is important to note that there may not be a direct correlation between the severity of the disease and the severity of the patient's symptoms.

## 3. Radiographic evaluation

Radiographic evaluation is critical and should include weight bearing Anterior Posterior (AP) and lateral views of the foot. An oblique view can be complementary. The AP view will commonly show eccentric narrowing of the joint, flattening or widening of the joint. Osteophytic changes can be seen and can obscure evaluation of the joint. It is important to evaluate the parabola of the metatarsals and length of the first metatarsal. Lateral view will show a more accurate assessment of the joint without overlying osteophytes. The extent of dorsal osteophytic spurring can be evaluated, however the radiograph tends to underestimate size. The lateral view is also important in evaluating for elevatus of the first metatarsal. Computed tomography or magnetic resonance imaging (MRI) can be helpful for evaluating for osteochondral injuries; however, MRI tends to overestimate severity [Vanore et al 2003].

There are clinical symptoms and radiographic signs that indicate stage and severity of disease. There have been multiple published classification systems for the evaluation of

hallux rigidus. The American College of Foot and Ankle Surgeons have adopted a 4-stage classification, evaluating the disease process by radiographic and clinical findings [Vanore et al, 2003] (Table 1).

Hallux Rigidus Grade	Radiographic Findings	Clinical Findings
I-Functional Limitus	metatarsus primus elevatus, plantar subluxation of the proximal phalanx, no radiographic evidence of degenerative joint disease	Pain at end range of motion
II-Joint adaptation	Dorsal spurring, subchondral eburnation, sclerosis, periarticular lipping, flattening of first metatarsal head, possible development of osteochondral defects	Limited passive range of motion
III-Established joint destruction	Subchondral bone cyst, severe flattening of joint, severe spurring asymmetrical joint space loss, first metatarsal head OCD, articular cartilage loss	Grade II plus joint crepitation, pain with full range of motion
IV-Ankylosis	Obliteration of joint space, intraarticular loose bodies	Grade III plus less than 10 degrees of first metatarsophalangeal joint, possible total ankylosis (asymptomatic)

Table 1. Hallux Rigidus classification.

4. Non-operative treatment

Treatment must be tailored to each patient depending on the extent of arthritis, patient preferences, patient lifestyle and progression of symptoms [Shurnas, 2009]. Initial treatment of hallux rigidus is usually non-operative and is aimed at reduction of inflammation and the painful range of motion of the metatarsophalangeal joint [Keiserman et al, 2005]. Non-surgical management of hallux rigidus focuses on mechanical and systemic intervention. Patients should avoid activities that aggravate their symptoms. Shoe education is a must. Patients need to avoid flexible non-supportive shoes and those with a heel. Rocker bottom shoes allow for a propulsive gait with limited dorsiflexion of the metatarsophalangeal joints. Shoe gear with a wider toe box will help to accommodate an enlarged first metatarsophalangeal joint. A simple over the counter insert with a semi-flexible arch can be

beneficial in transferring weight to the arch and decrease medial column loading, allowing the first ray to plantar flex thereby resulting in greater motion. Custom, more rigid orthoses improve mechanics and allow for forefoot modifications. A patient with pain only at end range of motion can benefit with an extension under the lesser metatarsal joints allowing plantar flexion of the first ray and an increase in dorsiflexion. Patients who have pain throughout range of motion because of more extensive and severe arthritic changes will not be able to tolerate an increase in motion. These patients require either a Morton's extension under the hallux, which will limit the motion, or a completely rigid extension, known as a gait plate, which blocks most motion in the joint. With the progression of the disease and irritation caused by shoe gear, orthoses in later stages of hallux rigidus may not be so readily tolerated due to extent of space occupation [Shurnas, 2009]. Oral, as well as topical nonsteroidal anti-inflammatory drugs (NSAIDs) can be beneficial in decreasing the inflammatory response and reduce associated pain. If unrelieved by NSAIDs, corticosteroids may be considered in the form of intra-articular injections or tapered doses orally [Vanore et al, 2003]. Physical therapy can be helpful in the application of iontophoresis, and mobilization of the joint through distraction techniques.

## 5. Operative treatment

Surgical approach towards hallux rigidus can be grouped into two categories: joint sparing or joint destructive procedures. Traditionally, proposed surgical intervention for Stage I and II hallux rigidus has been geared toward joint salvage procedures. These include cheilectomy, chondroplasty, and/or decompressional osteotomy. Stage III and IV rigidus have been directed toward a joint destructive approach, such as resectional arthroplasty, total joint replacement, and arthrodesis.

### 5.1 Joint salvage procedures

Joint salvage procedures usually use cheilectomy alone or in combination with additional procedures such as a metatarsal or phalangeal osteotomy, and chondroplasty.

#### 5.1.1 Cheilectomy

Cheilectomy is essentially the resection of the dorsal osteophytic formation and the degenerative portion of the articular surface of the metatarsal. It has become a popular procedure for treatment of hallux rigidus, offering the advantage of relieving pain while preserving some motion, propulsive power, and stability [Keiserman et al, 2005]. It also avoids lengthy healing times, allows immediate weight-bearing, doesn't require internal fixation, and doesn't "burn bridges" affording secondary or definitive procedures at a future date if necessary. Typically 25-33% of the metatarsal head are removed [Coughlin & Shurnas, 2004; Mann & Clanton, 1988] with the goal to achieve increased dorsiflexion of the joint, however, the amount of bone to be removed depends on the size of the bony proliferation, damage to the articular cartilage, and intraoperative degree of dorsiflexion achieved during the procedure [Keiserman et al, 2005].

A study on the outcome of cheilectomy on high level athletes demonstrated 95% good or excellent results, and found the procedure to be reliable in this population because it increases joint motion, maintains stability, avoids loss of purchase power, and permits an

early return to sport activity [Mulier et al, 1999]. Mann and Clanton reported 90% patient satisfaction with the procedure and an average 20° of dorsiflexion improvement [Mann & Clanton, 1988]. Feltham et al reported good results in 53 feet, most of which had grade II or III radiographic changes, suggesting radiographic classification does not correlate with surgical outcome [Feltham et al, 2001]. A long term follow-up study, average of 9.6 years, showed significant improvement in dorsiflexion, total motion, and post-operative pain following cheilectomies, with a 92% success rate in terms of function and pain relief [Coughlin & Shurnas, 2003]. The authors showed predictable success in Grade I and II, as well as selected Grade III cases, but recommended arthrodesis in patients with <50% articular cartilage remaining on the metatarsal head. The authors also reported good to excellent outcomes that did not correlate with radiographic appearance of the joint at final follow-up.

Many studies have shown satisfactory results clinically and subjectively in mild to moderate cases of hallux rigidus with cheilectomy. Care must be taken to identify those patients whose complaints are localized to the dorsal exostosis and no pain throughout the midrange of first metatarsophalangeal motion [Seibert et al, 2009].

### 5.1.2 Metatarsal osteotomy

There are several described metatarsal osteotomies that are designed to correct the structural abnormality of either the first ray, or the metatarsophalangeal joint itself. Metatarsal osteotomies shorten and/or plantar flex the first metatarsal and may be performed at the distal or proximal segments of the metatarsal. The degree of dorsiflexion or elevatus determines the required location of the osteotomy [Vanore et al 2003]. If hypermobility is identified, a first metatarsal cuneiform arthrodesis with the first metatarsal fused in a plantar flexed position may be considered. Plantar flexion allows for improved range of motion through an increase in dorsal clearance of the joint. Shortening, or decompressional, osteotomies result in a relative increase in the joint space, hence, increasing dorsiflexion. All of the described osteotomies are commonly done in conjunction with a cheilectomy. The combination of these two treatments allow for a greater effect on the dorsiflexion of the joint. A recent study looked at 57 references in a review of metatarsal osteotomies for hallux rigidus and found a mean increase of 10.4 degrees in dorsiflexion of the first metatarsophalangeal joint [Roukis, 2010]. Healing time is prolonged with all of the osteotomy procedures when compared to an isolated cheilectomy, however immediate weight bearing is tolerated when distal osteotomies are performed. Decompressional osteotomies also allow for future revisional surgery if deemed necessary.

#### 5.1.2.1 Metatarsal osteotomy surgical technique

The first metatarsal osteotomy is performed with a dorsal linear incision centered over the first metatarsophalangeal joint. The extensor hallucis longus tendon is identified and moved laterally to allow visualization of the first metatarsophalangeal joint. A dorsal linear incision is then made through the joint capsule to expose the first metatarsophalangeal joint. The dorsal and medial bony prominences are then resected along with any additional periarticular spurring. The articular cartilage of the first metatarsal head is then evaluated and any isolated and well-defined areas of cartilage loss are debrided to a stable perimeter of cartilage, followed by microfracture with a 0.035 inch K-wire. The osteotomy is the final step in the surgical



approach. A chevron-type osteotomy is created from medial to lateral with the apex of the osteotomy within the head of the first metatarsal. A wedge typically 2-3 mm is then resected from the dorsal arm of the osteotomy. The capital fragment is then impacted onto the shaft of the first metatarsal. A guide wire for a 3.0mm cannulated screw is placed under fluoroscopic guidance. Passive range of motion is then evaluated. If satisfactory, the osteotomy is then fixated with a 3.0mm cannulated short-thread cortical screw (Fig. 1-4).

#### 5.1.2.2 Postoperative management

An isolated decompressional osteotomy of the first metatarsal is allowed to be weight bearing in a postoperative shoe. The DARCO® wedge shoe is preferred for the first three weeks, limiting forefoot loading and possible ground reactive forces that could displace the osteotomy. After week three the patient is then transitioned to a flat stiff soled postoperative shoe for an additional three weeks. Eliminating the propulsive phase of gait with a postoperative shoe is advantageous to the healing of the osteotomy; it does however tend to lead to stiffening of the first metatarsophalangeal joint. To counter the negative affects of a prolonged apropulsive gate, it is critical to start early passive range of motion of the first metatarsophalangeal joint as early as postoperative day three. If chondroplasty of the joint was performed it is absolutely imperative that gentle passive range of motion of the first metatarsophalangeal joint is started early to prevent hemarthrosis, which could also lead to stiffening of the joint (Fig 5).

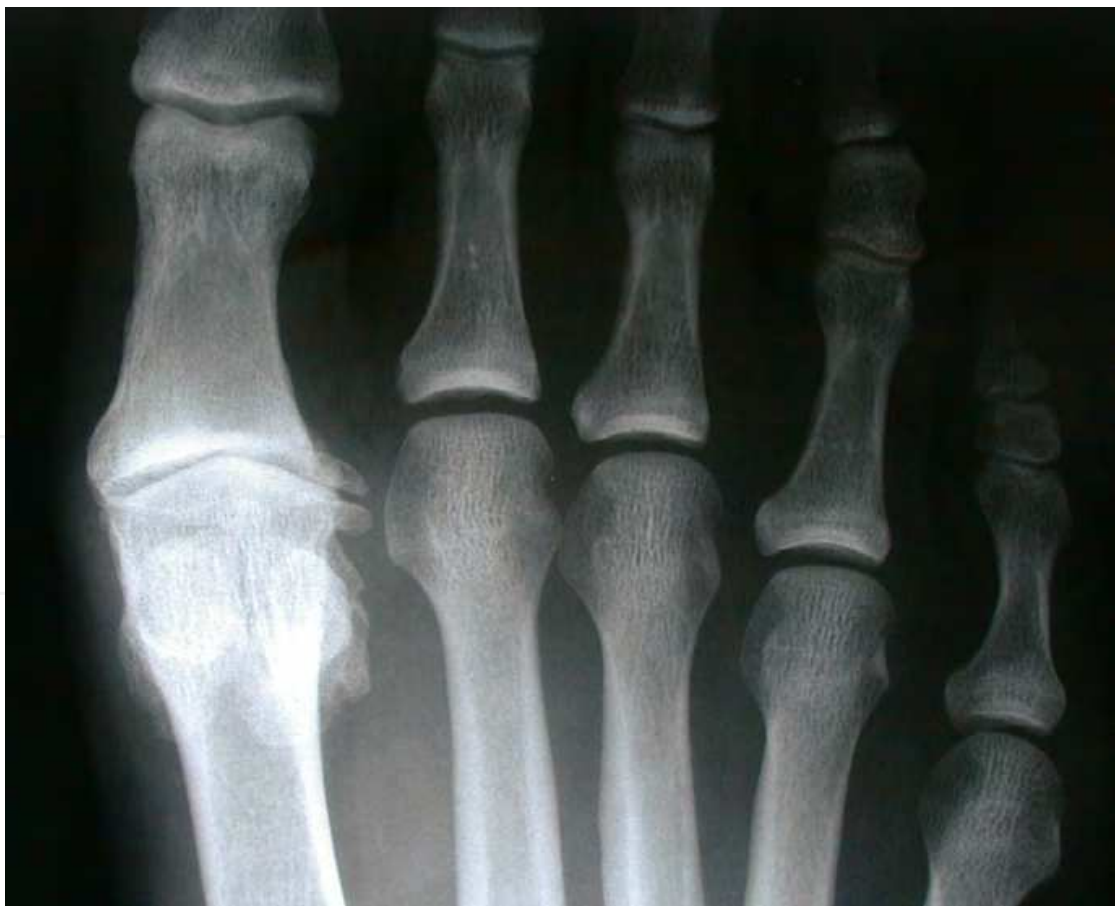

Fig. 1. Late Stage III Hallux Rigidus. Pre-operative AP radiograph with clear evidence of joint narrowing and osteophytic formation.

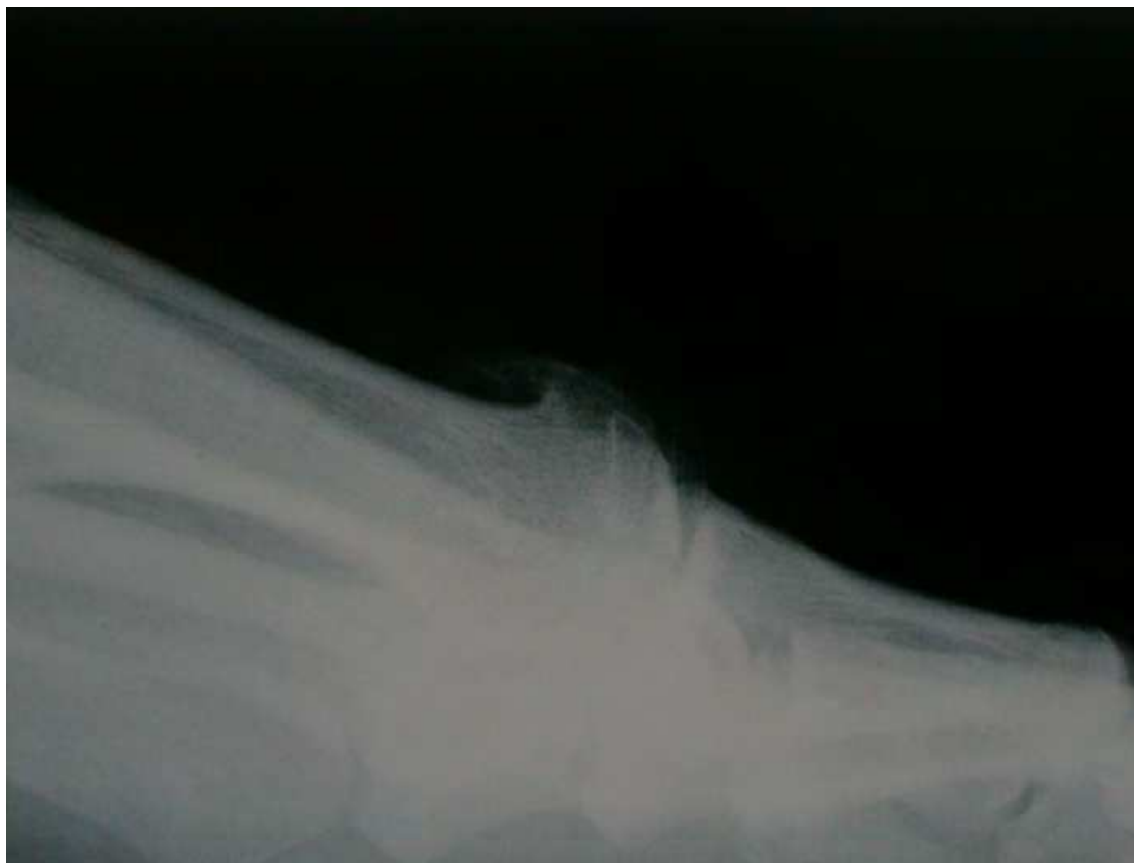

Fig. 2. Pre-operative lateral image of the same patient in Fig 3 with late Stage III Hallux Rigidus. Note the dorsiflexion of the first metatarsal, as well as the large dorsal osteophytic formation to the head of the metatarsal.

## 5.2 Joint destructive procedures

Joint destructive procedures include, arthrodesis, arthroplasty and implant arthroplasty of the first metatarsophalangeal joint. Traditionally joint destructive are reserved for stage III and IV hallux rigidus.

### 5.2.1 Arthrodesis

Arthrodesis of the first metatarsophalangeal joint is a satisfactory procedure for many pathological processes, including hallux rigidus. The optimal position of the hallux after fusion should be  $10^{\circ}$  to  $15^{\circ}$  of dorsiflexion in relation to the floor,  $10^{\circ}$  to  $20^{\circ}$  of valgus, and neutral rotation [Keiserman, 2005]. These recommended numbers should strictly be used as a relative guideline, and each individual patient should be taken into consideration during the preoperative planning [Brage & Ball, 2002].

It is critical to avoid malalignment after the arthrodesis. Overcorrecting or under-correcting is not without consequence. Too little valgus can place the interphalangeal joint at risk of degenerative arthritis [Fitzgerald, 1969], while excessive valgus may cause shoeing difficulties. Overzealous dorsiflexion can cause irritation to the hallux, whereas inadequate dorsiflexion may create pressure and source of pain to the distal aspect of the toe [Coughlin & Shurnas, 2004]. Meticulous joint preparation is essential as well to avoid nonunion and



enable a successful fusion. Disadvantages of arthrodesis include possibility of nonunion or malunion, interphalangeal arthritis, prolonged postoperative time, transfer metatarsalgia, and the possible need for a second procedure to remove hardware. The loss of joint motion is not without potential problems, particularly in the more active patient.

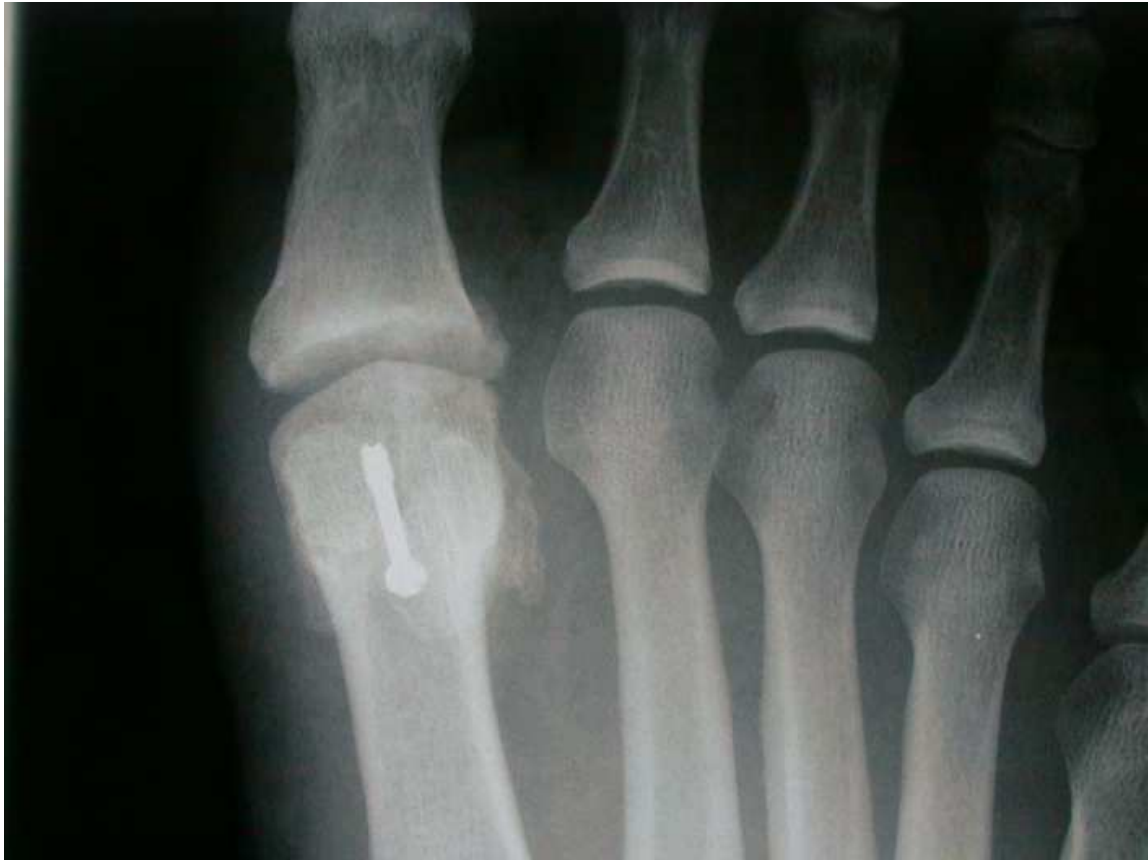

Fig. 3. Post-operative images of the same patient following decompressional osteotomy of the first metatarsal with cheilectomy. Note the significant increase to the first metatarsophalangeal joint space status post decompression. This patient exhibited improved range of motion post-operatively.

### 5.2.2 Arthroplasty and hemi/total implant arthroplasty

Resectional arthroplasty creates increased space between the first metatarsal and proximal phalanx allowing for motion of the hallux without pain, but without function. The hallux, as a result, is shortened. Hemi and total implants also allow for the increased motion; however, they have not proven stable over extended periods of time as have knee and hip arthroplasty. Due to the lack of function as a result of these procedures, patient selection is crucial. It is important to remember that reaction synovitis is still a concern for implants, as well as increase in lateral column pressure, implant loosening, and cost [Gibson & Thomson, 2005]. The ideal candidate is mostly sedentary with the treatment goal of improving symptoms enabling patients to perform activities of daily living [Vanore et al 2003]. The degree of permitted unrestrictive lifestyle following implants remains questionable. However, the biggest problem following joint replacement remains the ability to convert failed implants to arthrodesis. When these implants fail, primary fusion becomes difficult and the resultant tissue loss often requires importing bone to facilitate fusion.

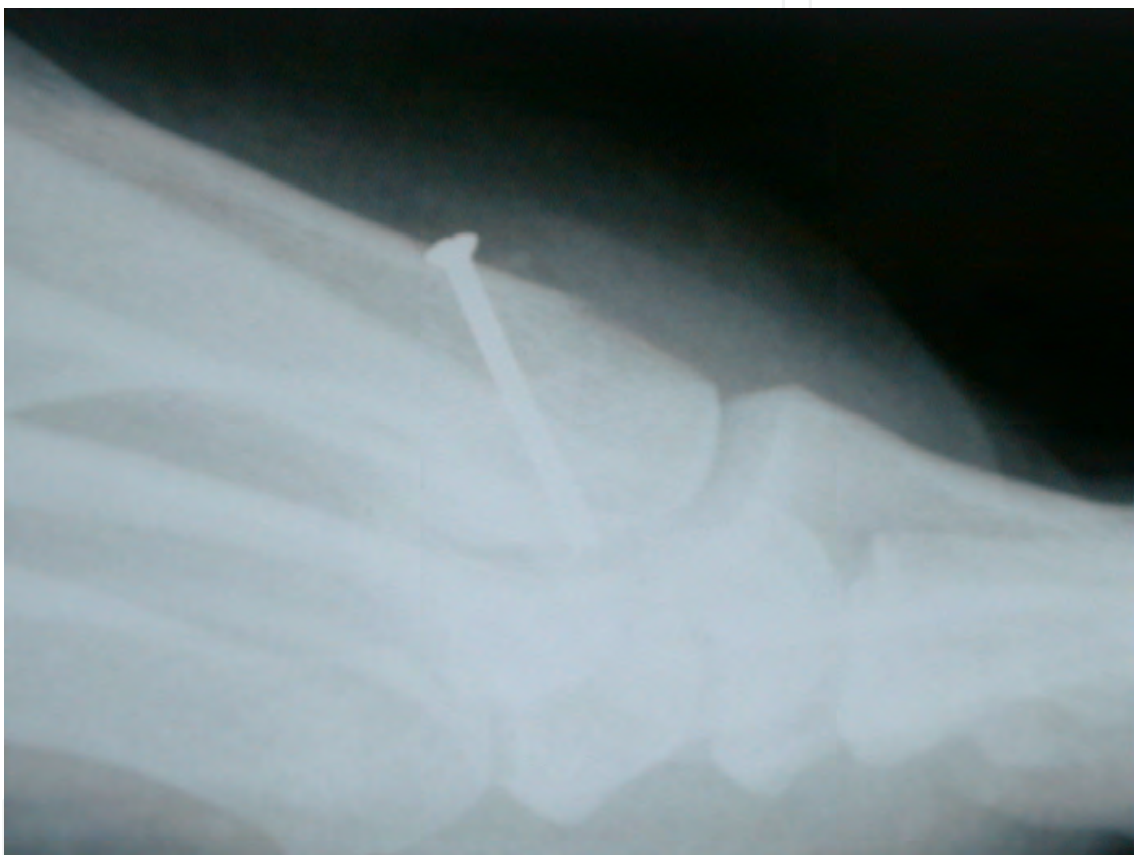

Fig. 4. Lateral radiographic image of the same patient revealing resection of the osteophyte from the dorsal first metatarsal. The increase in joint space can be appreciated in this image as well. Fixation of the osteotomy was provided with a single 3.0 mm short thread cortical screw.

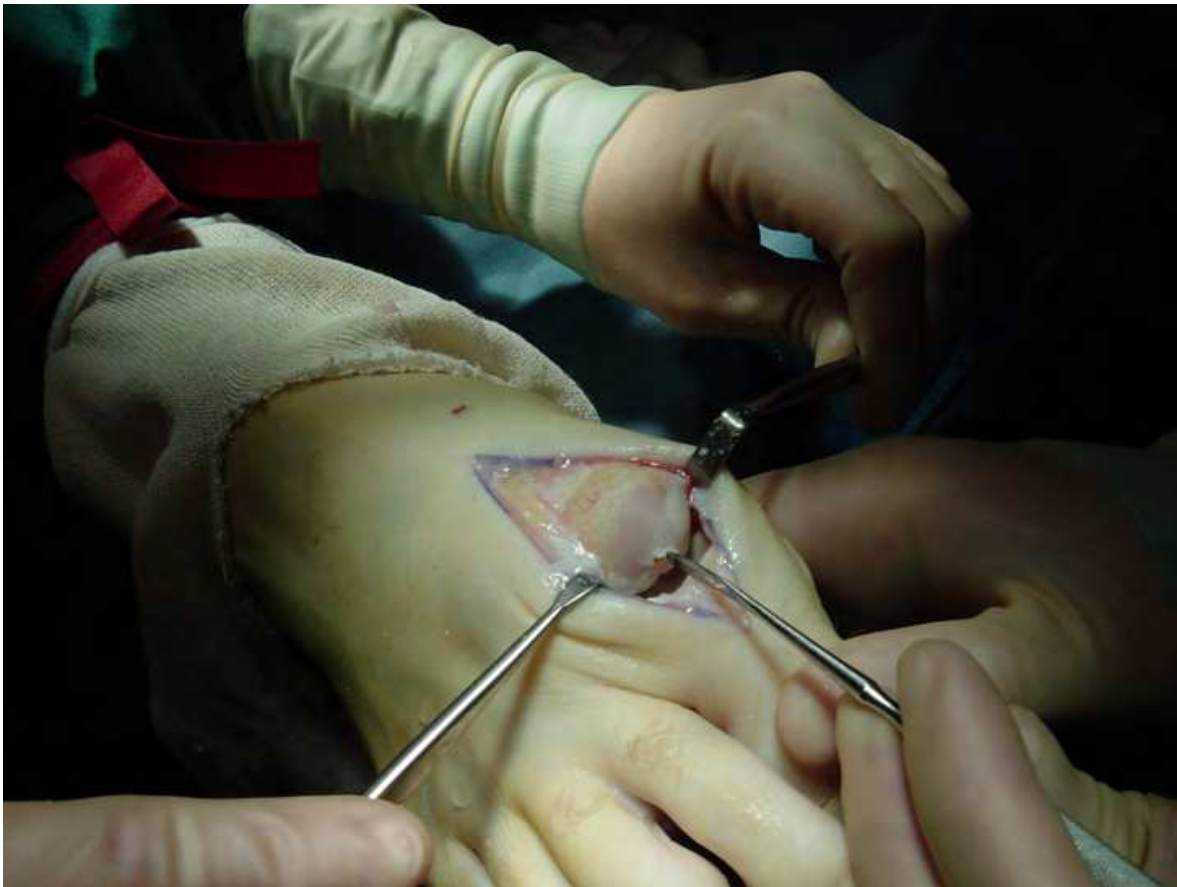

Fig. 5. Intra-operative image revealing degeneration of the dorsal articular surface cartilage. Also note the loosely adhered, friable cartilage toward the center of the joint. This is typical wear pattern found in patients with Hallux Rigidus. At this point chondroplasty of the articular defect should be considered. When performing chondroplasty, early mobilization is important to lessen the chance for ankylosis.

## 6. Discussion

Joint destructive procedures have traditionally been the mainstay of treatment for hallux rigidus stage III and IV patients. The treatment options for joint destruction are not equivalent and require the surgeon to thoroughly evaluate the patient. Traditionally the patient's age dictated the treatment option; however, this has become less important. The patient's function and activity level must be assessed. Patients are living longer and thus staying more active in later stages of life. Arthroplasty of the first metatarsophalangeal joint along with hemi and total implants were traditionally reserved for elderly patients with sedentary lifestyles. It is important to note that implants of the first metatarsophalangeal joint are non-functional and provide nothing more than a spacer preventing shortening of the hallux. This creates a foot that is easier to shoe and provides a more cosmetic appearance. Highly active individuals regardless of age are poor candidates for implant or resectional arthroplasty.

Systemic disease must also be considered. Patients with inflammatory arthritic conditions are poor candidates for implants secondary to an increased risk of failure and may be

inappropriate for joint preservation. Traditionally the accepted treatment for such patients was resectional arthroplasty or arthrodesis. The approach to systemic inflammatory diseases continues to change with the fairly recent introduction of disease modifying anti-rheumatic drugs (DMARDs). These classes of drugs can limit the joint destruction and allow the consideration of joint preservation (Fig. 6-7) [Drago et al, 1984; Niki et al, 2010].

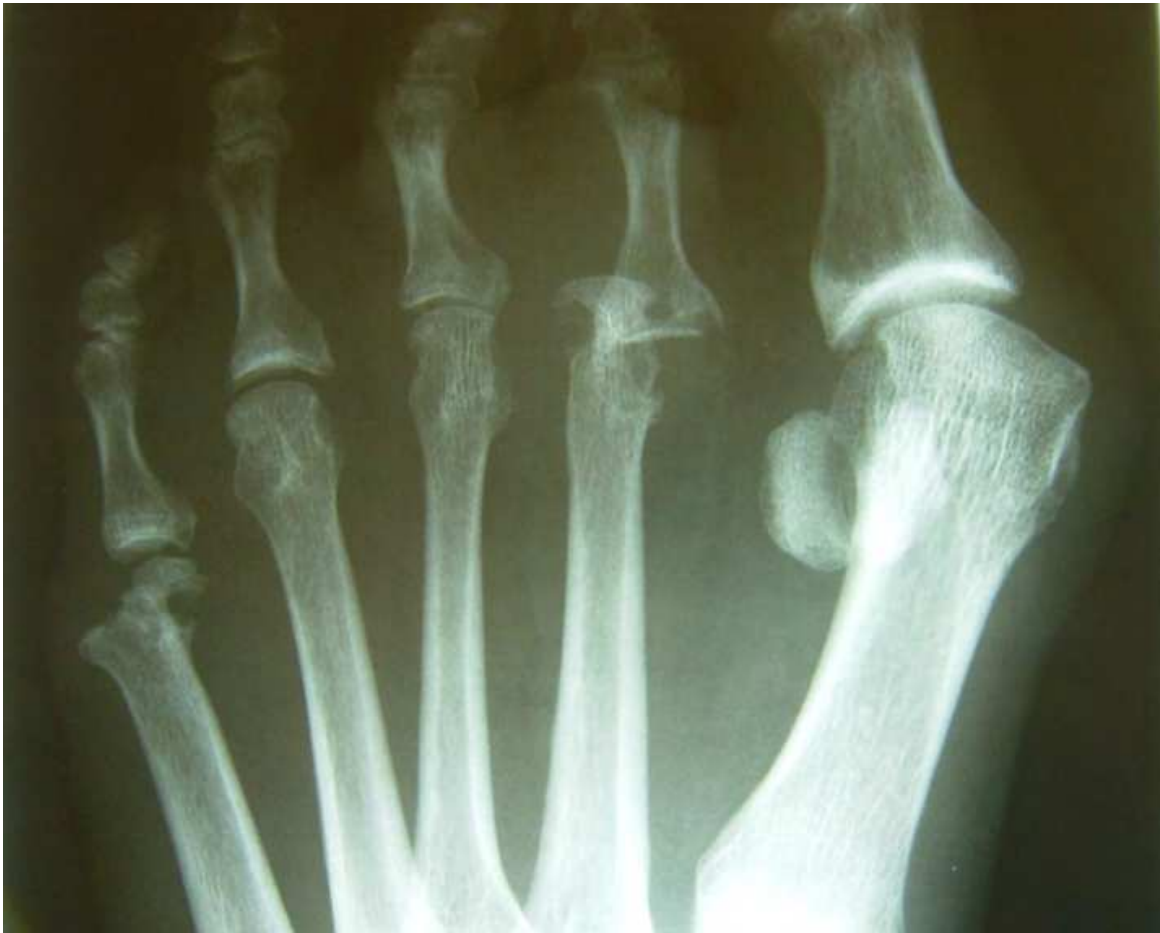

Fig. 6. Pre-operative AP image of a rheumatoid arthritic patient with Hallux Rigidus.

Inability to be non-weight bearing due to lack of care at home, atrophy or deconditioning of upper body muscles, obesity and of course poor compliance are deleterious to arthrodesis of the first metatarsophalangeal joint. While some literature suggests earlier weight bearing is allowable for arthrodesis [Hunt et al, 2011], typically patients are kept non-weight bearing for 4 weeks postoperatively with a transition to protected weight bearing for an additional 2 weeks.

The lead author performed a retrospective analysis of all patients that underwent decompressional osteotomies for stage III and IV hallux rigidus from 1994 to 2004. The inclusion criteria required the patient diagnosis of stage III or IV hallux Rigidus by the senior author, at least 1 year of postoperative follow-up, surgical treatment consisting of first metatarsal decompressional head osteotomy with or without cheilectomy and/or chondroplasty, and the ability to return for the long term follow-up evaluation. The retrospective analysis of all medical records and foot radiographs revealed that 23 patients



(28 feet) met the inclusion criteria. All of the returning patients were asked to complete a subjective 9-item questionnaire. No patients were reported as being worse or without any improvement. The mean AOFAS score was 25.9 preoperatively to 52 postoperatively out of a maximum 70. Of the patients 21 of 28 feet stated a 90% improvement with only 1 patient stating less than 50% improvement [Oloff & Jhala-Patel, 2008].

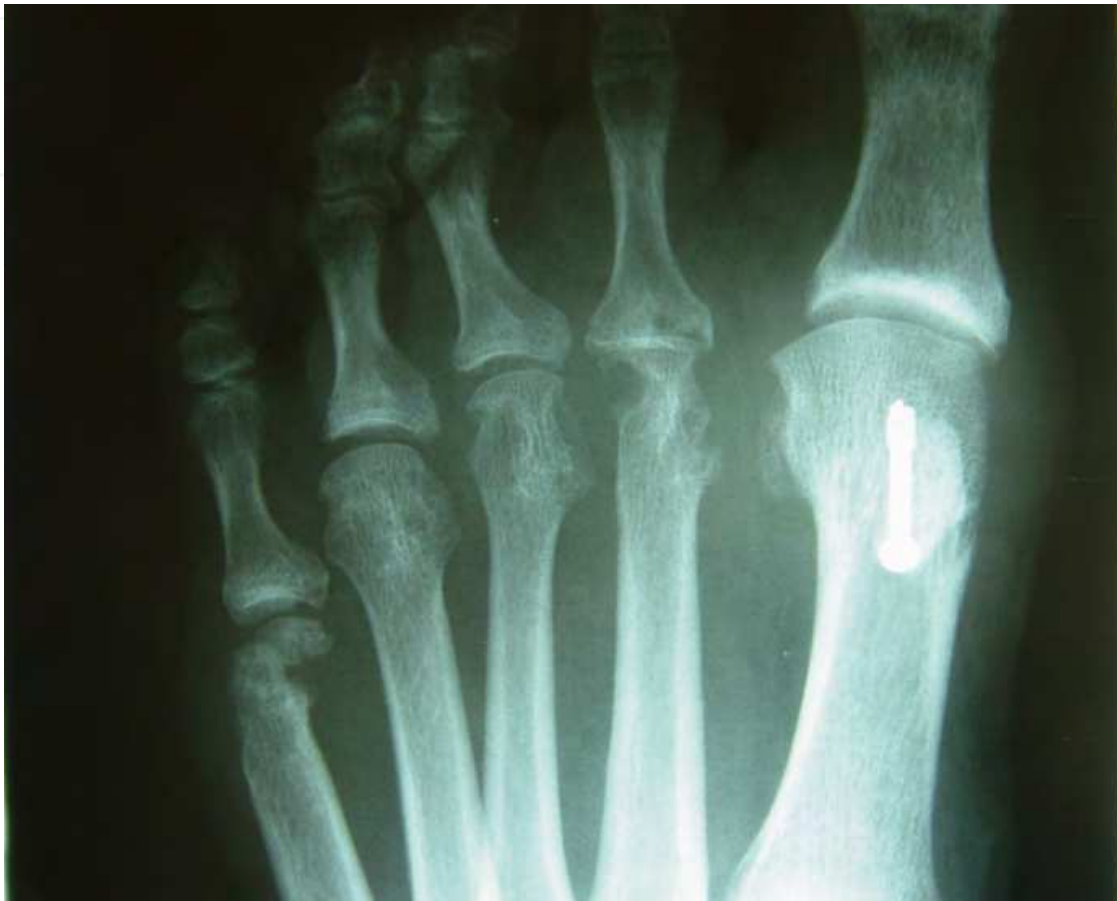

Fig. 7. Post-operative images following decompressional osteotomy of the first metatarsal in the same rheumatoid arthritis patient. In this case a joint preservation procedure was chosen because the patient's long standing rheumatoid arthritis came under control and there was reasonable cartilage remaining in her first metatarsophalangeal joint.

## 7. Summary

Hallux rigidus is a progressive, degenerative osteoarthritis of the first metatarsophalangeal joint with numerous etiologic factors [Vanore et al 2003]. Historically, surgical procedures have been discussed with the nature of the progression of the arthritis in the joint, based on radiographic classification.

Treatment for this condition should be approached with the goal to reduce pain and improve function of the foot as a whole [Vanore et al 2003]. The choice of procedure for a particular patient often is difficult and depends on clinical findings, radiographic staging, and patient lifestyle. It is necessary to approach treatment with the mind set on joint salvage when rationally appropriate.



If decompression alone does not relieve a patient's symptoms, autologous osteochondral transplantation may be considered prior to a joint destructive procedure. The lead author believes that joint salvage can be approached as a two staged procedure. The first stage would be to perform the decompressional osteotomy with possible cheilectomy and chondroplasty followed by autologous osteochondral transplantation as the second stage, which should only be considered after the osteotomy has completely healed radiographically. It is also important to note that current research suggests that we may have additional alternatives to arthrodesis and implants with the advancement of cartilage regeneration. Mesenchymal stem cells could possibly allow for viable cartilage regeneration and repair with positive results in animal models [Dashtdar et al, 2011].

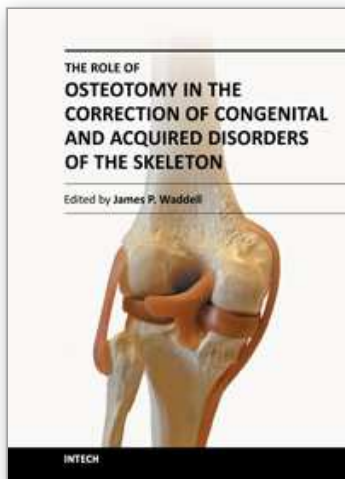
The proposed decompressional osteotomy procedure, with or without cheilectomy and/or chondroplasty has been shown to be an effective procedure even in cases of severe, late stage hallux rigidus. It keeps the door open for new and potentially regenerative techniques on the horizon. Such later stage reconstruction is not feasible after arthrodesis or joint replacement.

## 8. References

- Bingold AC, Collins DH. Hallux rigidus. *J Bone Joint Surg* Vol. 32-B (1950), pp 214-22.
- Bonney G, Macnab I. Hallux valgus and hallux rigidus: a critical survey of operative results. *J Bone Joint Surg Br* Vol. 34(3) 1952, pp 366-85.
- Brage M, Ball S. Surgical options for salvage of end-stage hallux rigidus. *Foot Ankle Clin N Am*, Vol. 7 (2002), pp 49-73.
- Chang TJ, Camasta, CA. (2001) Hallux Limitus and Hallux Rigidus. In: Downey MS, Martin DE, Miller SJ, eds. *McGlamry's Comprehensive Textbook of Foot and Ankle Surgery*, 3<sup>rd</sup> ed., Banks AS, pp 679-711, Lippincott Williams & Wilkins, Philadelphia.
- Cotteril JM. Stiffness of the great toe in adolescents. *British Med J*, 1888;1:158.
- Coughlin MJ, Shurnas PS. Hallux rigidus: grading and long-term results of operative treatment. *J Bone Joint Surg* Vol. 85-A(11), (2003), pp 2072-2088.
- Coughlin M, Shurnas P. Hallux Rigidus: Surgical Techniques (Cheilectomy and Arthrodesis). *J Bone Joint Surg* Vol. 86-A (2004), pp 119-130.
- Dashtdar H. et al. A preliminary study comparing the use of allogenic chondrogenic pre-differentiated and undifferentiated mesenchymal stem cells for the repair of full thickness articular cartilage defects in rabbits. *J Orthop Res* Vol. 29-9, (2011), pp 1336-1342.
- Davies-Colley M. Contraction of the metatarso-phalangeal joint of the great toe. *British Med J*, 1887, pp 1-728.
- Drago JJ, Oloff L, Jacobs AM. A comprehensive review of hallux limitus. *J Foot Ankle Surg* Vol. 23 (1984), pp. 213-220.
- Feltham G, Hanks SE, Marcus RE. Age-based outcomes of cheilectomy for the treatment of hallux rigidus. *Foot Ankle Int* Vol. 22-3 (2001), 192-197.
- Fitzgerald JAW. A review of long-term results of arthrodesis of the first metatarso-phalangeal joint. *J Bone Joint Surg*, Vol. 51-B (1969), pp 488-493.
- Gibson JN, Thomson C. Arthrodesis or Total Replacement Arthroplasty for Hallux Rigidus: A randomized controlled trial. *Foot Ankle Int*, Vol. 26, No. 9 (2005), pp 680-690.

- Hunt KJ, Ellington JK, Anderson RB, Cohen BE, Davis WH, Jones CP. Locked Versus Nonlocked Plate Fixation For Hallux MTP Arthrodesis. *Foot Ankle Int* Vol. 32-7 (2011), pp 704-709.
- Keiserman L, Sammarco J, Sammarco GJ. Surgical Treatment of the Hallux Rigidus. *Foot Ankle Clin N Am*, Vol. 10 (2005), pp 75-96.
- Lambrinudi C. Metatarsus primus elevatus. *Proc R Soc Med* Vol. 31 (1938), pp 1273.
- Mann RA, Clanton TO. Hallux rigidus: treatment by cheilectomy. *J Bone Joint Surg* Vol. 70-A(3), (1988), pp. 400-406.
- Mulier T, Steenwerckx A, Thienpont E, et al. Results after cheilectomy in athletes with hallux rigidus. *Foot Ankle Int* Vol. 20-4, (1999), pp 232-237.
- Niki H et al. Combination joint-preserving surgery for forefoot deformity in patients with rheumatoid arthritis. *J Bone Joint Surg (Br)* Vol. 92-B (2010), pp 380-386.
- Nilsson H. Hallux rigidus and its treatment. *Acta Orthop Scand*, Vol. 1 (1930), pp 295- 302.
- Oloff LM, Jhala-Patel G. A retrospective analysis of joint salvage procedures for grades III and IV hallux rigidus. *J Foot Ankle Surg* Vol. 47-3 (2008), pp 230-236.
- Padanilam, T. (2004). Disorders of the First Ray. In: *Orthopaedic Knowledge Update: Foot and Ankle*, 3<sup>rd</sup> ed, Richardson EG, pp 17-20, Rosemont, American Academy of Orthopaedic Surgeons.
- Roukis T. Clinical outcomes after isolated periarticular osteotomies of the first metatarsal for hallux rigidus. *J Foot Ankle Surg*, Vol. 49, (2010), pp 553-560.
- Seibert, Nicholas R. Kadakia, Anish R. Surgical Management of Hallux Rigidus: Cheilectomy and Osteotomy (Phalanx and Metatarsal). *Foot Ankle Clin N Am* Vol. 14, (2009), pp 9-22.
- Shurnas, P. Hallux Rigidus: Etiology, biomechanics, and nonoperative treatment. *Foot Ankle Clin N Am*, Vol. 14 (2009), pp 1-8.
- Vanore J, Christensen J, Kravitz S, Schuberth J, Thomas J, Weil L, Zlotoff H, Couture S. Diagnosis and Treatment of First Metatarsophalangeal Joint Disorders. Section 2: Hallux Rigidus. *Journal Foot Ankle Surg*, Vol 42, No. 3 (2003).

IntechOpen



## **The Role of Osteotomy in the Correction of Congenital and Acquired Disorders of the Skeleton**

Edited by Prof. James Waddell

ISBN 978-953-51-0495-7

Hard cover, 294 pages

**Publisher** InTech

**Published online** 11, April, 2012

**Published in print edition** April, 2012

This book demonstrates specific osteotomy techniques from the skull to the hallux. The role of osteotomy in the correction of deformity is under appreciated in part because of the ubiquitous nature of joint replacement surgery. It should be remembered, however, that osteotomy has a role to play in the correction of deformity in the growing child, the active young adult, and patients of any age with post-traumatic deformity limiting function and enjoyment of life. In this text we bring you a number of papers defining specific problems for which osteotomy is found to be an effective and lasting solution. I hope you find it useful.

### **How to reference**

In order to correctly reference this scholarly work, feel free to copy and paste the following:

Lawrence M. Oloff, Colin Traynor and Shahan R. Vartivarian (2012). Joint Salvage Techniques for Stage III/IV Hallux Rigidus, The Role of Osteotomy in the Correction of Congenital and Acquired Disorders of the Skeleton, Prof. James Waddell (Ed.), ISBN: 978-953-51-0495-7, InTech, Available from:  
<http://www.intechopen.com/books/the-role-of-osteotomy-in-the-correction-of-congenital-and-acquired-disorders-of-the-skeleton/joint-salvage-techniques-for-stage-iii-iv-hallux-rigidu>

**INTECH**  
open science | open minds

### **InTech Europe**

University Campus STeP Ri  
Slavka Krautzeka 83/A  
51000 Rijeka, Croatia  
Phone: +385 (51) 770 447  
Fax: +385 (51) 686 166  
[www.intechopen.com](http://www.intechopen.com)

### **InTech China**

Unit 405, Office Block, Hotel Equatorial Shanghai  
No.65, Yan An Road (West), Shanghai, 200040, China  
中国上海市延安西路65号上海国际贵都大饭店办公楼405单元  
Phone: +86-21-62489820  
Fax: +86-21-62489821

© 2012 The Author(s). Licensee IntechOpen. This is an open access article distributed under the terms of the [Creative Commons Attribution 3.0 License](https://creativecommons.org/licenses/by/3.0/), which permits unrestricted use, distribution, and reproduction in any medium, provided the original work is properly cited.

IntechOpen

IntechOpen