

We are IntechOpen, the world's leading publisher of Open Access books Built by scientists, for scientists

6,900

Open access books available

186,000

International authors and editors

200M

Downloads

Our authors are among the

154

Countries delivered to

TOP 1%

most cited scientists

12.2%

Contributors from top 500 universities



WEB OF SCIENCE™

Selection of our books indexed in the Book Citation Index
in Web of Science™ Core Collection (BKCI)

Interested in publishing with us?
Contact book.department@intechopen.com

Numbers displayed above are based on latest data collected.
For more information visit www.intechopen.com



Three-Dimensional Computer-Assisted Corrective Osteotomy Techniques for the Malunited Distal Radius

Joy C. Vroemen and Simon D. Strackee

*Department of Plastic, Reconstructive and Hand Surgery,
Academic Medical Center,
University of Amsterdam,
The Netherlands*

1. Introduction

A corrective osteotomy is a frequently required procedure for symptomatic malunions of the distal radius. A multitude of different methods have been proposed for correction of distal radius malunions. However, precise correction of a severe malunion that requires simultaneous adjustment of displacement and rotation in multiple planes remains a challenge. Technological advancements have resulted in improved techniques to perform radial corrective osteotomy. In the last few decades a number of computer-assisted techniques have been proposed. Computer-assisted surgery with the use of three-dimensional (3D) pre-operative planning offers multiple advantages. 3D imaging and reconstructions are more intuitive and show details that cannot be observed from two-dimensional (2D) radiographs. This chapter describes and discusses current techniques in computer-assisted corrective osteotomy techniques of the malunited distal radius.

1.1 Malunion of the distal radius

A small number of distal radius fractures results in a symptomatic malunion of the bone. However, because the fracture of the distal radius is the most common fracture in the upper limb, the absolute number of symptomatic malunited distal radii is considerably large. (Cooney et al, 1980; Menon et al, 2008; Solgaard & Petersen, 1985) Symptoms of a malunited radius may include pain, reduced range of motion, reduced grip strength, carpal instability and eventually osteoarthritis. (Cheng et al, 2008; Crisco et al, 2007) Pain and other symptoms have various causes.

Malalignment of the distal radius segment after trauma contributes in most of the cases to a loss of the normal palmar tilt and radial inclination. This leads to a wrong position of the sigmoid notch, which can result in pain and limited forearm rotation, whereby the patient is less able to perform pronation or supination. The mismatch between sigmoid notch and the ulna also causes an adaptive position of the carpus. Carpal malalignment following the malunited distal radial fracture is described to develop as an adaptation to realign the

position of the hand to the malunion (Gupta et al., 2002) and may contribute to carpal instability. Changes in the sigmoid notch and thus the DRU joint mechanics are involved in the dysfunction associated with malunion of the distal radius. (Crisco et al., 2007) Clinical studies have shown that poor clinical outcomes are associated with malunited distal radius fractures that heal with more than 20° of dorsal tilt or loss of more than 10° of radial inclination (Kihara et al, 1996), especially in young, manually active patients.

Another problem in malunions of the radius is the shortening of the radial bone, which leads to a positive ulnar variance. This may cause ulnar abutment. In the treatment of the malunited distal radius, it is important to take the relationship between the lengths of the radius and ulna into account.

If the patient has severe complaints that seem to belong to the malunion of the distal radius, a corrective osteotomy can be performed to reduce the pain and improve the function. The goal of a corrective osteotomy is to restore the original position of the distal radius segment and thus the original anatomical relationships in the wrist.

It is shown that there is a correlation between the accuracy of the anatomical reconstruction of the wrist and its function. (Brogren et al., 2011; Pogue et al., 1990) To increase accuracy in the corrective osteotomy of the radius, accurate pre-operative planning is important.

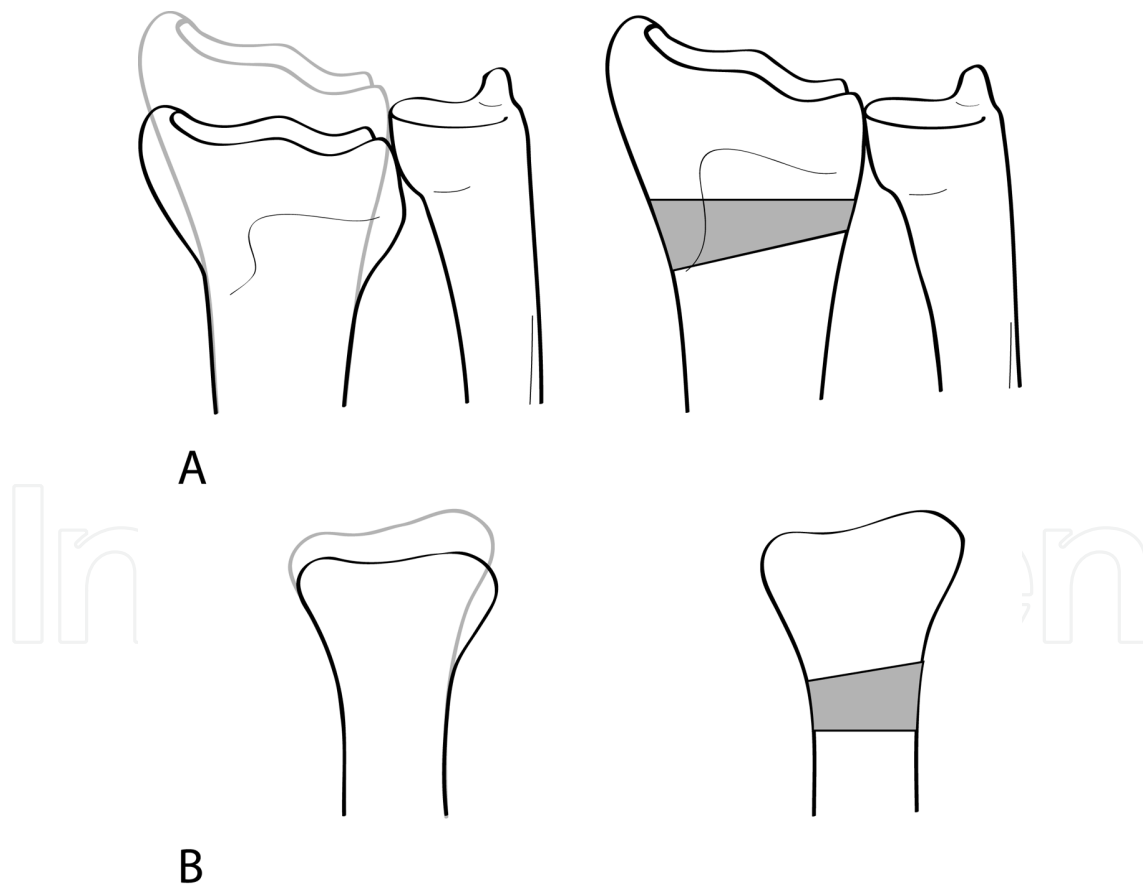


Fig. 1. Schematic representation of the corrective osteotomy procedure of the malunited distal radius. Fig. 1A shows the posterior-anterior view and Fig. 1B the lateral view of the wrist. The left side represents the malunited situation and on the right side the corrected situation is displayed.

1.2 Conventional techniques for radial corrective osteotomy

In the conventional technique, the pre-operative planning of a corrective osteotomy of the radius is done on plain 2D radiographs of the malunited radius. The planning is based on three radiographically obtained parameters: the radial inclination, palmar tilt and ulnar variance. These parameters are used to assess the shape of the supporting bone graft pre-operatively. In early surgery, average values of population data of these parameters were used for surgical planning, and subsequent techniques use the radiograph of the contralateral arm as a reference for planning and restoring the malunited distal radius.

The procedure involves cutting the malunited distal radius near its original fracture site and restoring the original position of the distal radius segment (Fig. 1). The new situation is often supported by a wedge-shaped bone graft or bone substitute, followed by fixation of the osseous structures with a fracture-fixation plate. Sometimes no supporting structures are used, and the fixation is by a fixed-angle fracture-fixation plate alone.

1.3 Computer-assisted radial corrective osteotomy

Since there is a correlation between the accuracy of the reconstruction of the radius and the eventual wrist function, it is important to restore the original position of the distal radius segment as accurate as possible. Lately, the reliability of measurements on 2D radiographs is frequently questioned in the literature. The radiographic parameters are hampered by inter-observer variations and overprojection, which hides rotations around the longitudinal axis of the bone. (Capo et al., 2009; Pennock et al., 2005) When planning a corrective osteotomy, these limitations of 2D imaging may cause a misinterpretation of the correction parameters. Six parameters are required for optimal planning of repositioning the radial distal segment: three displacements and three rotations around three axes. Therefore 3D planning should be used in performing a corrective osteotomy. This allows correction of all six repositioning parameters, not only the shortening and the angulations seen on 2D radiographs.

In the last few decades a number of 3D computer-assisted techniques have been proposed for corrective surgery. In these new techniques the malunited radius is restored with the help of the unaffected mirrored contralateral radius, which serves as a reference. Because the surgeon has no information about the former position of the radius and does not want to differ too much from the original anatomy, the only reference is currently the contralateral healthy radius. In that way there is an objective goal for the computer-assisted pre-operative planning.

The procedure of a corrective osteotomy for the malunited distal radius experienced major technological advancements in the last decade. This chapter gives a chronological overview of the different computer-assisted techniques for the planning and treatment of radial corrective osteotomy that are described in the literature so far.

2. Current computer-assisted techniques

Most computer-assisted corrective osteotomy techniques use the mirrored image of the unaffected contralateral radius as a template for the affected side. A computer-assisted planning procedure is divided into different phases. The first phase is data collection through imaging, the second phase is creation of virtual 3D models and performing a virtual

osteotomy on the affected radius. By matching a proximal and distal segment of the virtual affected radius with the virtual healthy radius, the required position of the distal segment of the affected radius after the osteotomy is calculated. This is the preoperative plan. The third and last phase is the translation of the preoperative plan to the operating room. Computer-assisted techniques have different ways to perform each phase but every technique will have to go through these three phases.

2.1 The BIZCAD method

In 1988 Bilic and Zdravkovic presented a computer-aided planning method for preoperative planning of corrective osteotomy of malunited fractures of the radius. (Bilic & Zdravkovic, 1988a, 1988b) Conventional orthogonal radiographs are used and the goal of the whole procedure is to make the entire procedure as simple as possible, and to make preoperative planning decisions easy and objective. Bizcad is a computer-aided preoperative planning method which provides 3D wire models of bones. From these models the dimensions of the required bone graft and the amount and direction of angulation and translation at the osteotomy can be calculated.

Two plain radiographs are taken from both the affected and the unaffected wrist. From these radiographs, wire models of the distal end of the radius of both hands are constructed and presented in a Cartesian coordinate system with a one-millimeter raster. A null coordinate system point is defined on both projection radiographs of both hands. In this way the lateral and the posterior-anterior view can be linked. Fourteen points are recognized on both views and used as vertex points for a model reconstruction. These points were typical landmarks such as the top of the styloid process, the volar edge of the ulnar notch, and points along the osteotomy line. (Fig. 2A) These reference points of the distal end of the radius were used to generate a computer wire model. (Fig. 2B) After determination of axis lines, vertex points and an osteotomy line, the coordinates were measured and data was processed with a computer. Models of both wrists are constructed and the model of the unaffected radius is mirrored to serve as a reference for the affected side. The model of the part of the radius where the osteotomy is to be made can now be interactively translated and rotated by the surgeon until the point of best fit to the healthy radius model is reached. After this, the shape and measurements of the bone graft needed are calculated and displayed.

This method seems more precise than the conventional planning method of two radiographs and three radiographic parameters. In the conventional corrective osteotomy, when planning a surgical procedure, the surgeon passes from one radiographic view to the other and no allowance is made for the fact that changes in the lateral view imply changes in the anterior-posterior view. The Bizcad method solves this problem. Disadvantages are a complicated planning procedure and an incomplete solution for problems concerning rotational deviations of the distal radius fragment. The system is unable to provide intraoperative guidance and represents details poorly. An advantage of this method is that plain radiographs keep the procedure cheap and simple.

2.2 Computer generated solid plastic bone models

In 1992 Jupiter et al. reported on computer-assisted design and a manufacturing technology to create solid plastic models of complex, multidirectional malunions of the distal radius.

(Jupiter et al., 1992) By the ability to perform the surgical procedure on these models preoperatively, the intention is to enhance the preoperative planning. In this method patients underwent CT scans of both wrists. CT image data are reformatted and transferred to a computer numerically controlled milling machine, which creates a master model that is used to produce plastic models of the malunion and also of the opposite uninjured side. The distal ulna and carpal bones are included in these models. (Fig. 3) The surgical procedure can be readily performed on these solid models. In addition to provide a hands-on exercise for the surgical team, the dimensions of the required bone graft, the size and shape of the internal fixation, and the potential for articular realignment can be visually appreciated. The preoperative solid models make it possible to have a better understanding of the 3D nature of the malunion, especially if there is a malrotation present. Rotational correction can be judged by comparison with the model of the unaffected radius.

An advantage is the availability of a true-to-life 3D appreciation of the deformity. A disadvantage is the extra cost due to the CT scan and producing the solid models. The authors recommend that this method should only be used in cases of unusually complex, multidirectional deformities in which it proves difficult to gain a 3D understanding from plain radiographs.

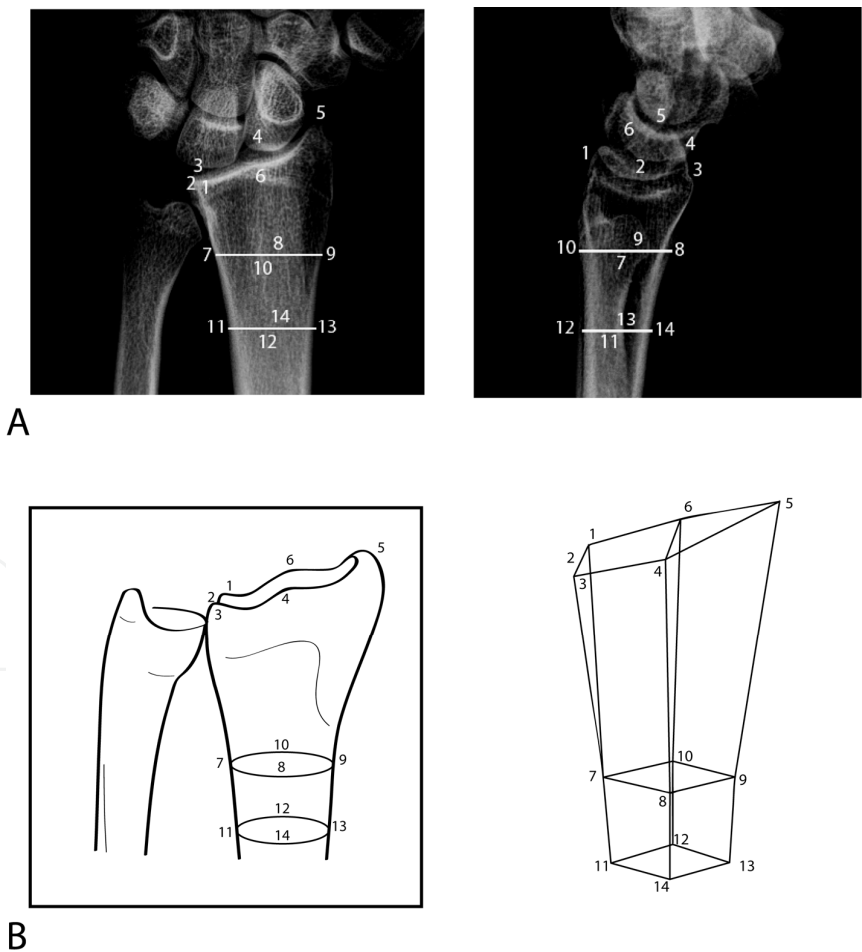


Fig. 2. Reference points of the distal radius segment on two projections for the computer wire model generation are shown on Fig. 2A. Fig. 2B represents the creation of the wire model. This image represents a healthy left wrist. (Method described by Bilic & Zdravkovic et al.)

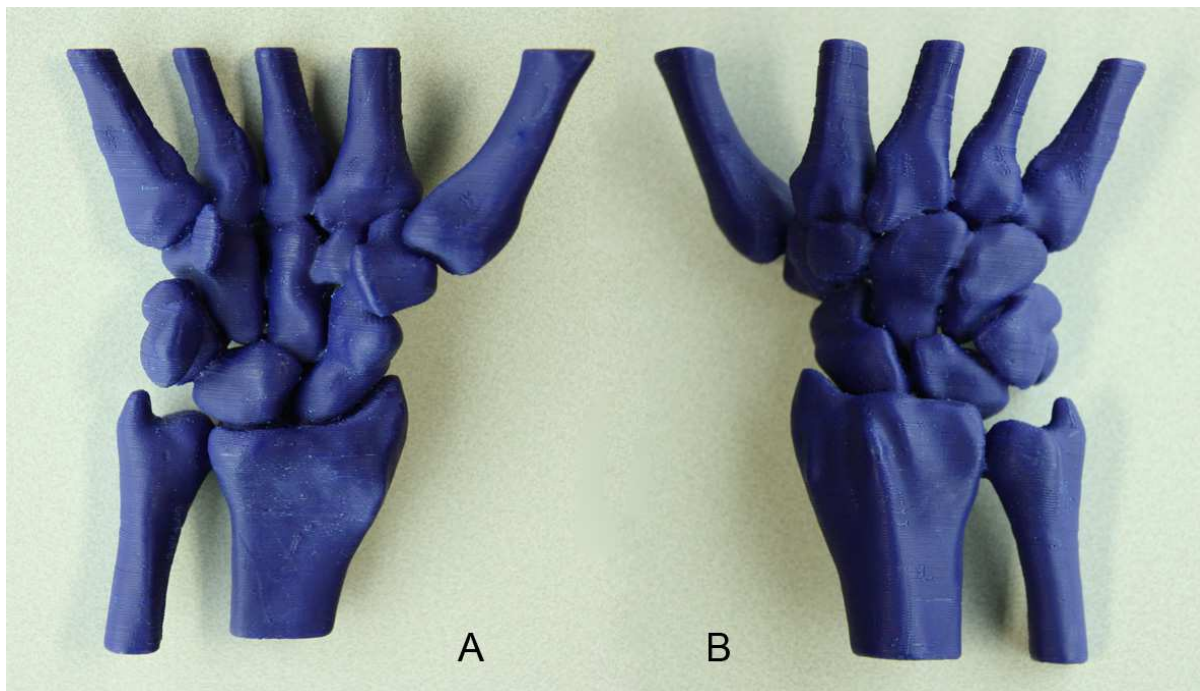


Fig. 3. An example of a computer generated solid plastic bone model of a healthy wrist joint. Fig. 3A is the view of the volar side and Fig. 3B of the dorsal side.

2.3 Computer-assisted fixation-based surgery

In 2001 and 2003 a fixation-based 3D preoperative planner and an intraoperative guidance system for distal radius osteotomy was introduced. (Croitoru et al., 2001; Athwal et al., 2003) Fixation-based surgery is a technique using a fixation device, such as a fracture-fixation plate, during the alignment and distraction phases of an osteotomy. In this technique patient-specific measurements are used, in which the malunited wrist is realigned to match the unaffected wrist.

The computer-assisted system described by Croitoru et al. and Athwal et al. is a two-step process. The first step is the preoperative plan, which contains a 3D reconstructed virtual model of both forearms from CT images and a digitized model of a fracture-fixation plate. A virtual osteotomy is conducted with the preoperative planner and the malunited distal radius segment is realigned to best fit the virtual model of the unaffected radius. Then the digitized fracture-fixation plate is virtually fit to the corrected radius. In this way the positions of the proximal and distal screw holes are known onto the original malunion model. These coordinates, along with the coordinates for the osteotomy plane, are saved and imported into the guidance software.

The second step is the intraoperative guidance system, which is used to translate the preoperative plan towards the operation room. Registration is obtained by matching the patient-specific preoperative plan with landmarks on the patient's in vivo distal radius. This is done by attachment of infrared emitting diodes (IRED) to the radius, which are monitored by an optical tracking device. An IRED target is also attached to the drill. That way the location and orientation of the drill in space is known and can be referenced to the preoperative plan and to precise locations on the patient's exposed distal radius. During the

operation, the surgeon sees virtual images of the radius with the planned locations of the screw holes and in this same image the real-time position of the surgical drill. The user-computer interface guides the surgical tools to the location of the planned osteotomy and to the locations of the screw holes in the fracture-fixation plate. Pilot holes are drilled into the bone as indicated by the plan. (Fig. 4B) The osteotomy cut is made, and the distal fragment is shaved to fit the plate. (Fig. 4C) The plate is then fixed to the distal fragment. When the holes through the plate align with the pilot holes in the bone, the surgeon knows that the correct alignment has been achieved and the plate is in the correct position for fixation. (Fig. 4D) The osteotomy gap is filled with a bone graft or bone substitute, and the plate then acts as fixation for the reconstructed radius.

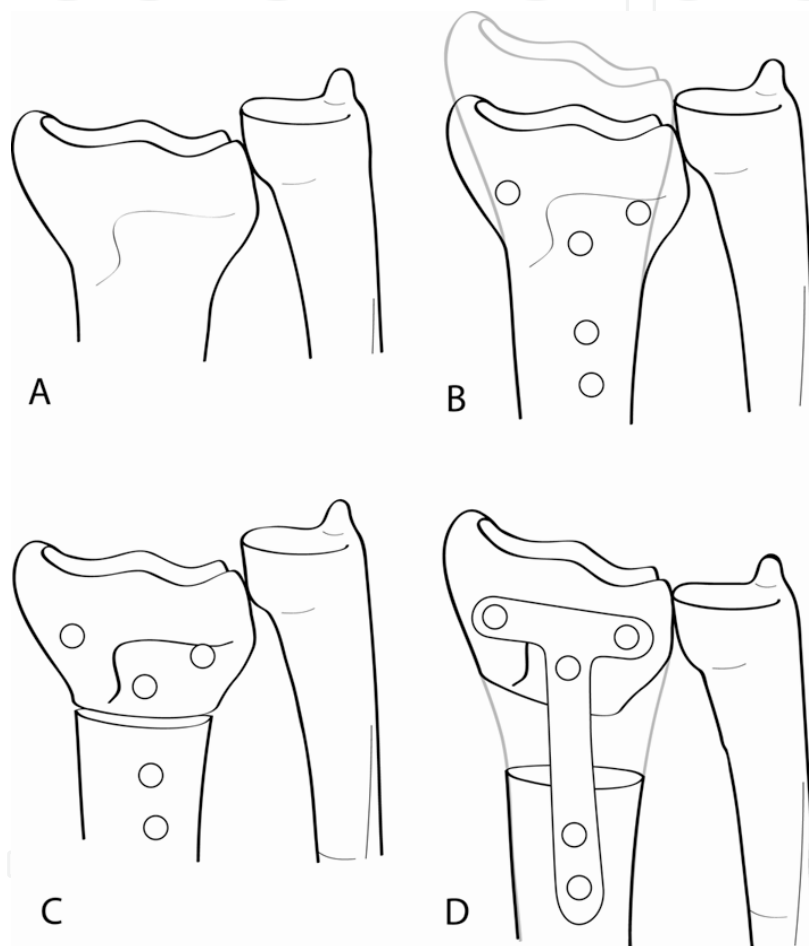


Fig. 4. Schematic view of the computer-assisted fixation-based surgery technique for corrective osteotomy of the distal radius. (Method described by Croitoru et al. and Athwal et al.) Fig. 4A is the malunited radius, Fig. 4B is the malunited radius with pilot holes drilled into the bone as indicated by the preoperative plan. On Fig. 4C the osteotomy is made and in Fig. 4D the plate is fixed to the bone and correct alignment is achieved.

Advantages of computer-assisted fixation-based surgery include that the computer system is simple to use and that the technique takes the required six degrees of freedom of correction into account. The procedure reduces X-ray radiation by eliminating the use of fluoroscopy for achieving the alignment. Furthermore, it is possible to perform multiple simulations of the surgical procedure preoperatively, which can optimize the plan and

makes it easy to identify potential problems during realignment. Also exceptionally large defects can be corrected. A disadvantage is the additional preoperative time needed for the planning process. Also, registration of the patient to the surgical planner and guidance system is critical; poor registration may lead to poor outcomes.

2.4 Computer-assisted creation of a repositioning device

In 2004 Rieger et al described a computer-assisted technique with the use of a patient-specific repositioning device. (Rieger et al., 2004) In this method, 3D virtual models of both radii are again created from CT images. The ulna, and a proximal and distal part of the malunited radius, are digitally matched with the ulna and radius of the contralateral healthy forearm, which is mirrored and used as a reference. The planning software of this technique allows the exact calculation of the geometry of the gap in the radius after the virtual osteotomy and positioning. A 3D model that resembles the gap is then created. This model is used to manufacture a synthetic template (i.e. the repositioning device) of stereolithographic material. This repositioning device is placed at the surgical osteotomy site to reposition objectively the distal radius segment before fixation of the osseous structures. The level of osteotomy is determined preoperatively in the virtual planning procedure. After the fixation with the fracture-fixation plate, the repositioning device is replaced with a bone graft or bone substitute. (Fig. 5)

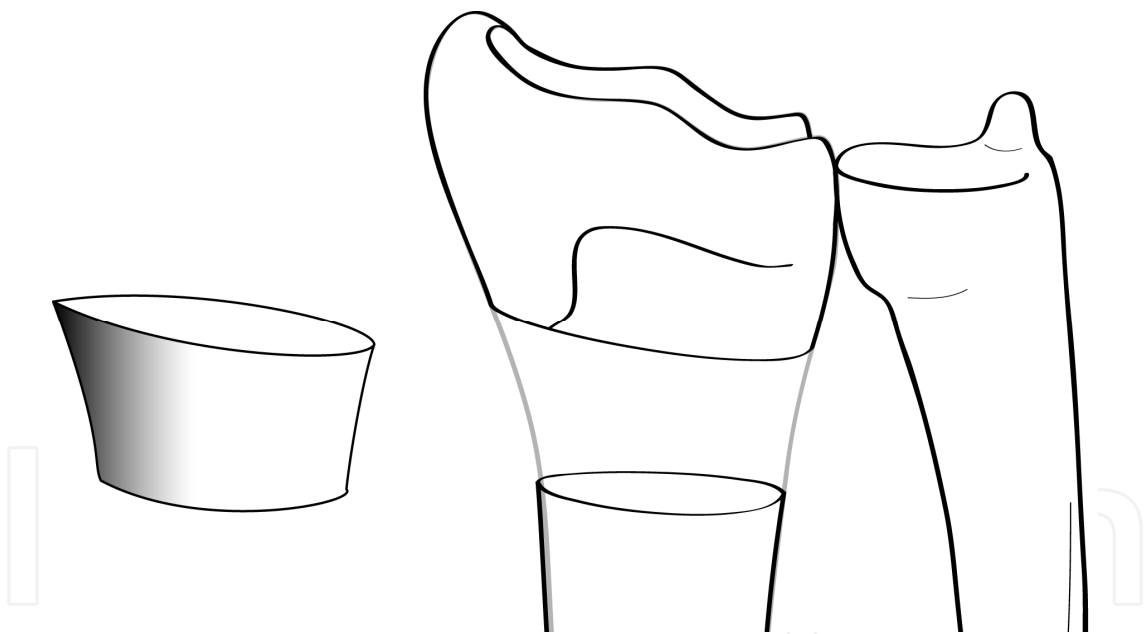


Fig. 5. Schematic view of the computer-assisted technique for corrective osteotomy of the malunited radius using a patient-specific repositioning device. (Method described by Rieger et al.)

This method provides a preoperative insight of the individual operative field and shows, virtually, possible limitations in advance. Also, objective details of the appropriate position of the distal radius segment and the measurements of the required bone graft are known. An advantage of this computer-assisted technique is the fast operative procedure. Disadvantages are the costs and the difficulty to correct rotational misalignment, which is difficult to assess despite the repositioning device.

2.5 Computer-assisted stereolithographic surgical guide

Several studies have been published on computer-assisted corrective osteotomy techniques using patient-specific surgical guides. (Miyake et al., 2010; Oka et al., 2010) These described methods have the same principle.

The corrective osteotomy is simulated and planned with the help of 3D virtual radii models created using CT images of both forearms. Then appropriate screw holes are simulated in the affected radius using computer-assisted design data of a fracture-fixation plate. The location and direction of the screw holes are calculated by the computer to automatically correct the malunion after osteotomy and fixation with a volar fracture-fixation plate.

To translate the preoperative plan to the actual surgery, a patient-specific custom-made osteotomy template with drilling guide holes and an osteotomy slit were designed to exactly fit the surface of the distal radius. The surgical guide is a plastic model made by rapid prototyping technology. With this guide the simulated screw holes can be drilled in the right place. Only then the osteotomy is made through the osteotomy slit. (Fig. 6) The predrilled holes are used to fixate the plate, resulting in automatic reduction of the distal radius segment into the planned position.

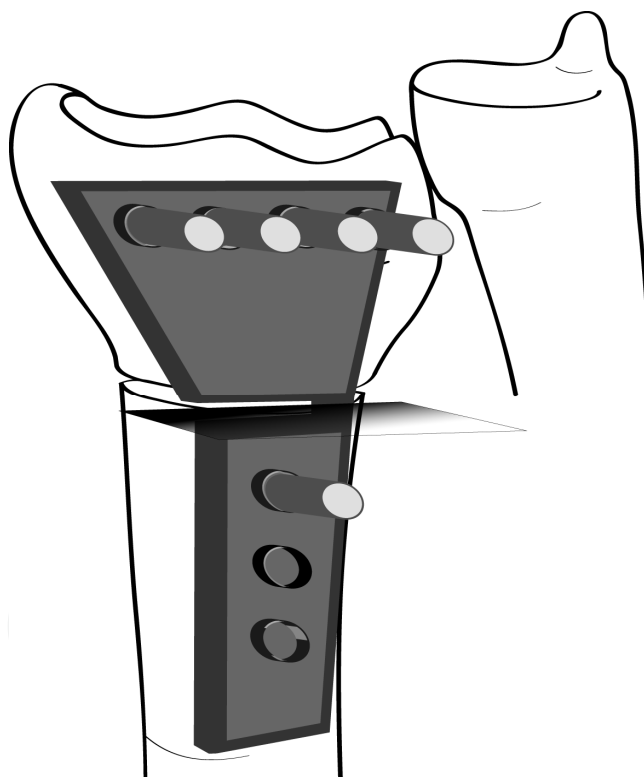


Fig. 6. Schematic view of the computer-assisted corrective osteotomy technique using a patient-specific stereolithographic surgical guide with drilling guide holes and an osteotomy slit. (Method described by Miyake et al. and Oka et al.)

The final step is filling the osteotomy gap with a bone graft or bone substitute. Another option is to combine this method with the creation of a patient-specific repositioning device (see paragraph 2.4) made of biocompatible material. In the latter case no additional surgery is needed at the bone graft site.

One of the advantages of this technique using a custom-made surgical guide is that the intraoperative procedure is simple and undemanding to accomplish. A disadvantage is the rather invasive operation technique. To fit the surgical guide to the bony surface of the radius, the incision must be rather large.

2.6 Computer-assisted correction with manipulator-fixator system

The paper of Dobbe et al. in 2011 introduces a new technique that uses preoperative planning based on 3D CT images in combination with intraoperative 3D imaging. (Dobbe et al., 2011) In this method the first step is again the preoperative planning based on 3D virtual models created from CT images of both the affected and the contralateral healthy radius. Intraoperatively, the distal bone segment needs to be aligned and fixated in the correct position that is determined in the preoperative plan. This is accomplished using Kirschner wires (K-wires) and a positioning tool, called a manipulator-fixator system. The positioning tool is very similar to existing external fixators, the difference is that it is already in the right configuration.

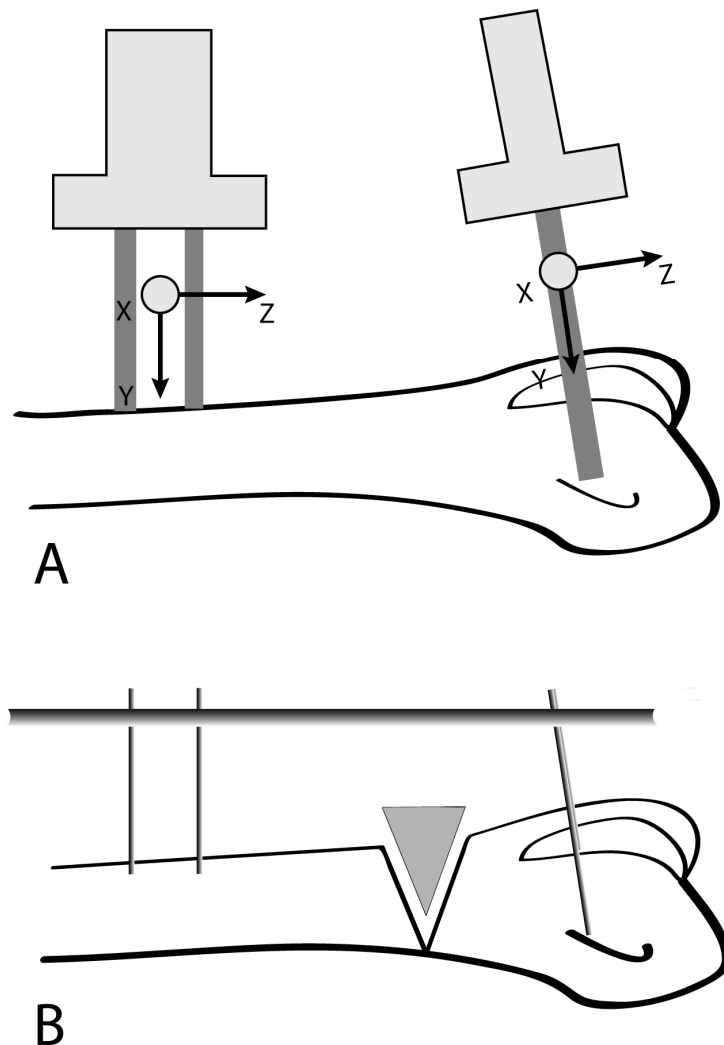


Fig. 7. The manipulator-fixator system that is used in the computer-assisted radial corrective osteotomy technique. (Method by Dobbe et al.)

During the operation, two parallel K-wires are drilled into the proximal part of the radius and a second pair of K-wires into the distal radius segment. Then marker tools are slid over the K-wire pairs and an intraoperative 3D scan is made with a 3DRX scanner. (Fig. 7A) The marker tools allow detection of the K-wires. The preoperative plan and the intraoperative imaging are matched and in this way the positions of the k-wires are known in the preoperative plan. With this information the positioning tool (i.e. the fixator) is adjusted into the right configuration. This is done according to the results of the image analysis software by using a computer-controlled manipulator. The fixator, in the adjusted configuration is attached to the K-wires and in this way the distal radius segment is navigated to the correct position. (Fig. 7B) The osseous structures can now be fixated in this position.

The major advantages of this method are the ease of applicability in the operating room and a high accuracy of repositioning and evaluation using all six degrees of freedom. This method is the first that aims at a minimally invasive technique by making it possible to perform the osteotomy and the bone segment positioning through only small incisions. This could result in less wound problems and less muscle, tendon and nerve complications. Unfortunately, a limitation is that there is currently no minimally invasive fixation method available instead of the fracture-fixation plate and screws.

3. Conclusion

In this chapter the focus is on computer-assisted techniques for corrective osteotomy of the distal radius. However, conclusions in this paragraph also cover other corrective osteotomy procedures, such as osteotomies of the ulna, humerus, clavicle or bones of the lower extremity.

3.1 Advantages of computer-assisted techniques for corrective osteotomies

The greatest advantage of computer-assisted corrective osteotomy that is already described in the introduction is the fact that the preoperative planning is done in 3D instead of the conventional 2D methods. 3D imaging has several potential advantages over 2D radiographs and CT scans. (Guitton & Ring, 2010) Three-dimensional imaging is more intuitive and shows details that cannot be observed on 2D imaging. This allows better preoperative planning and makes the surgeon's mental and psycho-motor preparation easier. Also, 3D physical models can add the sense of touch and immediate 3D manipulations. There is also the possibility for practicing procedures on models preoperatively. Models can be used in the communication with the patient, educational settings, research and development.

3.2 Disadvantages of computer-assisted techniques for corrective osteotomies

Disadvantages of current computer-assisted techniques are radiation exposure for the CT images and the time and effort required for the preoperative planning procedures. The major disadvantage of computer-assisted techniques is the often high manufacturing costs. Of course the new techniques described above are only applied small-scale so far, and cheaper options will be presented. Besides, research has shown that 3D reconstructions may outweigh this latter disadvantage, as both the surgeon and the patient will benefit significantly.

Regarding the disadvantages of the individual current techniques described in this chapter: the use of an intraoperative guidance system like IRED and optical tracking devices requires many touching landmarks at the surface of the bone. This is only possible if the incision for the operative procedure is large and thus invasive. This also applies for the current techniques using a patient-specific stereolithographic surgical guide. To fit the often bulky guide to the bony surface of the radius, the bone must be completely dissected.

Also, another important disadvantage of computer-assisted corrective osteotomy is the requirement of a healthy unaffected contralateral radius, which serves as a reference for the affected radius. There are often cases where a patient has a radius fracture or malunion in both forearms, and this would limit the preoperative planning considerably.

3.3 Perspectives

The perspectives of the newly introduced computer-assisted techniques are promising and it seems that these techniques will have many further applications. The pre-operative 3D planning described in this chapter could also be applied in corrective osteotomies of other long bones, such as the ulna, humerus, clavicle and bones of the lower extremity.

What can be concluded from the advantages and disadvantages of the current computer-assisted techniques is that there are still a few important points that need to be improved. For example, to make computer-assisted corrective osteotomies also minimal invasive, new fixation methods have to be developed, since the bone fixation with a fracture-fixation plate and screws always requires a relatively large incision. Furthermore, the issue of a possible absence of a healthy contralateral radius needs to be addressed. It would be an important development if there would be a statistical model of the wrist joint. In this way relationships between the different bones in the wrist could be calculated and analyzed without the need of an extra CT scan of the contralateral wrist. Of course, this applies to multiple joints which also undergo corrective surgery. Finally, a perspective is that not only the preoperative planning, but also the intraoperative and postoperative evaluation will be in 3D instead of the current postoperative evaluation on 2D radiographs.

Our recommendation for future computer-assisted techniques is a mechanism that resembles the method described by Dobbe et al. (see paragraph 2.6). This technique aims at a system that is minimal invasive and also reusable. By avoiding the need for the manufacturing of patient-specific surgical guides for each individual patient, there will be a significant reduction in cost, and it will be time-saving. More importantly, it will be a technique that is universally applicable and it allows a 3D assessment during the operative procedure.

4. Acknowledgment

The authors would like to thank R.T. Bosscha for the illustrations in this chapter.

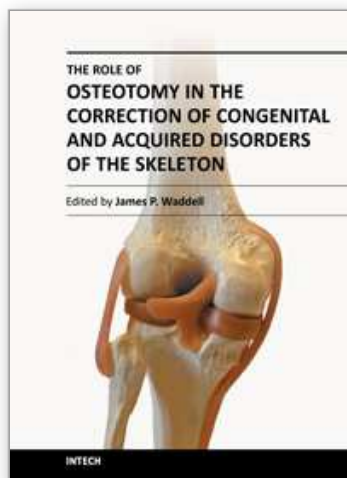
5. References

Athwal, GS; Ellis, RE; Small, CF & Pichora, DR. (2003). Computer-assisted distal radius osteotomy. *American Journal of Hand Surgery*, Vol.28A, No.6, (November 2003), pp. 951-958

- Bilic, R & Zdravkovic, V. (1988a). Planning corrective osteotomy of the distal end of the radius. 1. Improved method. *Unfallchirurg*, Vol.91, No.12, (December 1988), pp. 571-574
- Bilic, R & Zdravkovic, V. (1988b). Planning corrective osteotomy of the distal end of the radius. 2. Computer-aided planning and postoperative follow-up. *Unfallchirurg*, Vol.91, No.12, (December 1988), pp. 575-580
- Brogren, E; Hofer, M; Petranek, M; Wagner, P; Dahlin, LB & Atroshi, I. (2011) Relationships between distal radius fracture malunion and arm-related disability: a prospective population-based cohort study with 1-year follow-up. *BMC Musculoskeletal Disorders*, Vol.12, No.9, (January 2011), pp. 1-9, ISSN 1471-2474
- Capo, JT; Accousti, K; Jacob, G & Tan, V. (2009). The effect of rotational malalignment on X-rays of the wrist. *Journal of Hand Surgery European Volume*, Vol.34, No.2, (April 2009), pp. 166-172
- Cheng, HS; Hung, LK; Ho, PC & Wong, J. (2008). An analysis of causes and treatment outcome of chronic wrist pain after distal radial fractures. *Hand Surgery*, Vol.13, No.1, (February 2008), pp. 1-10
- Cooney, WP; Dobyns, JH; & Linscheid, RL. (1980). Complications of Colles fractures. *American Journal of Bone and Joint Surgery*, Vol.62, No.4, (June 1980), pp. 613-619
- Crisco, JJ; Moore, DC; Maral, GE; Laidlaw, DH; Akelman, E; Weiss, AP & Wolfe, SW. (2007). Effects of distal radius malunion on distal radioulnar joint mechanics, an in vivo study. *Journal of Orthopaedic Research*, Vol.25, No.4, (April 2007), pp. 547-555
- Croitoru, H; Ellis, RE; Prihar, R; Small, CF & Pichora, DR. (2001). Fixation-based surgery: a new technique for distal radius osteotomy. *Computer Aided Surgery*, Vol.6, No.3, (March 2001), pp. 160-169
- Dobbe, JGG; Strackee, SD; Schreurs, AW; Jonges, R; Carelsen, B; Vroemen, JC; Grimbergen, CA & Streekstra, GJ. (2011). *IEEE Transactions on Biomedical Engineering*, Vol.58, No.1, (January 2011), pp. 182-190
- Guittou, TG & Ring, D. (2010). Three-dimensional computer tomographic imaging and modeling in the upper extremity. *Hand Clinics*, Vol.26, No.3, (August 2010), pp. 447-453
- Gupta, A; Batra, S; Jain, P & Sharma, SK. (2002). Carpal alignment in distal radial fractures. *BMC Musculoskeletal Disorders*, Vol.24, No.3, (May 2002), pp. 14-20
- Jupiter, JB; Ruder, J & Roth, DA. (1992). Computer-generated bone models in the planning of osteotomy of multidirectional distal radius malunions. *American Journal of Hand Surgery*, Vol.17, No.3, (May 1992), pp. 406-415
- Kihara, H; Palmer, AK; Werner, FW; Short, WH & Fortino, MD. (1996). The effect of dorsally angulated distal radius fractures on distal radioulnar joint congruency and forearm rotation. *American Journal of Hand Surgery*, Vol.21, No.1, (January 1996), pp. 40-47
- Menon, MRG; Walker, JL & Court-Brown, CM. (2008). The epidemiology of fractures in adolescents with reference to social deprivation. *British Journal of Bone and Joint Surgery*, Vol.90, No.11, (November 2008), pp. 1482-1486
- Miyake, J; Murase, T; Moritomo, H; Sugamoto, K & Yoshikawa, H. (2011). Distal radius osteotomy with volar locking plates based on computer simulation. *Clinical Orthopaedics and Related Research*, Vol.469, No.6, (June 2011), pp. 1766-1773
- Oka, K; Murase, T; Moritomo, H; Goto, A; Sugamoto, K & Yoshikawa, H. (2010). Corrective osteotomy using customized hydroxyapatite implants prepared by preoperative

- computer simulation. *International Journal of Medical Robotics and Computer Assisted Surgery*, Vol.6, No.2, (June 2010), pp. 186-193
- Pennock, AT; Phillips, CS; Matzon, JL & Daley, E. (2005). The effects of forearm rotation on three wrist measurements: radial inclination, radial height and palmar tilt. *Hand Surgery*, Vol.10, No.1, (July 2005), pp. 17-22
- Pogue, DJ; Viegas, SF; Patterson, RM; Peterson, PD; Jenkins, DK; Sweo, TD & Hokanson, JA. (1990). Effects of distal radius fracture malunion on wrist joint mechanics. *American Journal of Hand Surgery*, Vol.15, No.5, (September 1990), pp. 721-727
- Rieger, M; Gabl, M; Gruber, H; Jaschke, WR & Mallouhi, A. (2005). CT virtual reality in the preoperative workup of malunited distal radius fractures: preliminary results. *European Radiology*, Vol.15, No.4, (April 2005), pp. 792-797
- Solgaard, S & Petersen, VS. (1985). Epidemiology of distal radius fractures. *Acta Orthopædica*, Vol.56, No.5, (October 1985) pp. 391-393

IntechOpen



The Role of Osteotomy in the Correction of Congenital and Acquired Disorders of the Skeleton

Edited by Prof. James Waddell

ISBN 978-953-51-0495-7

Hard cover, 294 pages

Publisher InTech

Published online 11, April, 2012

Published in print edition April, 2012

This book demonstrates specific osteotomy techniques from the skull to the hallux. The role of osteotomy in the correction of deformity is under appreciated in part because of the ubiquitous nature of joint replacement surgery. It should be remembered, however, that osteotomy has a role to play in the correction of deformity in the growing child, the active young adult, and patients of any age with post-traumatic deformity limiting function and enjoyment of life. In this text we bring you a number of papers defining specific problems for which osteotomy is found to be an effective and lasting solution. I hope you find it useful.

How to reference

In order to correctly reference this scholarly work, feel free to copy and paste the following:

Joy C. Vroemen and Simon D. Strackee (2012). Three-Dimensional Computer-Assisted Corrective Osteotomy Techniques for the Malunited Distal Radius, The Role of Osteotomy in the Correction of Congenital and Acquired Disorders of the Skeleton, Prof. James Waddell (Ed.), ISBN: 978-953-51-0495-7, InTech, Available from: <http://www.intechopen.com/books/the-role-of-osteotomy-in-the-correction-of-congenital-and-acquired-disorders-of-the-skeleton/three-dimensional-computer-assisted-corrective-osteotomy-techniques-of-the-malunited-distal-radius>

INTech
open science | open minds

InTech Europe

University Campus STeP Ri
Slavka Krautzeka 83/A
51000 Rijeka, Croatia
Phone: +385 (51) 770 447
Fax: +385 (51) 686 166
www.intechopen.com

InTech China

Unit 405, Office Block, Hotel Equatorial Shanghai
No.65, Yan An Road (West), Shanghai, 200040, China
中国上海市延安西路65号上海国际贵都大饭店办公楼405单元
Phone: +86-21-62489820
Fax: +86-21-62489821

© 2012 The Author(s). Licensee IntechOpen. This is an open access article distributed under the terms of the [Creative Commons Attribution 3.0 License](#), which permits unrestricted use, distribution, and reproduction in any medium, provided the original work is properly cited.

IntechOpen

IntechOpen