

We are IntechOpen, the world's leading publisher of Open Access books Built by scientists, for scientists

6,900

Open access books available

185,000

International authors and editors

200M

Downloads

Our authors are among the

154

Countries delivered to

TOP 1%

most cited scientists

12.2%

Contributors from top 500 universities



WEB OF SCIENCE™

Selection of our books indexed in the Book Citation Index
in Web of Science™ Core Collection (BKCI)

Interested in publishing with us?
Contact book.department@intechopen.com

Numbers displayed above are based on latest data collected.
For more information visit www.intechopen.com



Quality Control of Reconstructed Sagittal Balance for Sagittal Imbalance

Kao-Wha Chang

*Taiwan Spine Center, Taichung Jen-Ai Hospital, Taiwan,
Republic of China*

1. Introduction

Sagittal balance is important for biomechanical optimization of forces at segmental interspaces. Sagittal plane malalignment is most often clinically significant when there is loss of normal lordosis of the lumbar spine. Excessive kyphosis across these mobile, unsupported segments increases intradiscal pressures and compromises the mechanical advantage of the erector spinae musculature (White AA, Panjabi MM, 1990). Clinically, the patient with sagittal imbalance presents with intractable pain, early fatigue, and a subjective sense of imbalance and leaning forward, and difficulty with horizontal gaze. Compensation can be gained by extension of the hips and flexion of the knees, although this causes increased fatigue. As patients age, muscular weakness, adjacent disc degeneration, and hip and pelvic disease may decrease compensation and increase disability. Restoration of normal and economical sagittal balance reduces the work of the erector spinae and hamstring muscles to achieve balance during normal activity. During reconstructive surgery, restoration of optimal sagittal balance is crucial for obtaining satisfactory clinical results (Mac-Thiong JM et al., 2009; Glassman SD et al., 2005). However, there is no way to control the quality of the reconstructed sagittal balance before or during surgery.

Many clinicians have investigated regional and global spinal alignment in the normal (asymptomatic) adult population (Schwab F, 2006, 2009; Bernhardt M & Bridwell KH, 1989; Berthounaud E et al., 2005; During J et al., 1985; Gelb DE et al., 1995; Jackson RP et al., 2000; Vaz G et al., 2002). These data have provided a basic understanding of the normative values of spinal parameters. However, since the work by Vidal and Marnay (Vidal J & Marnay T, 1983, 1984), several authors have enhanced the understanding of global alignment by including the pelvis, which has been described as a regulator of sagittal plane alignment. Numerous studies have been conducted to understand the relationship between pelvic parameters and spinal alignment. This has led to the recognition that pelvic morphology and position are essential components of standing alignment (Schwab F et al., 2006; Duval-Beaupere G et al., 2002; Legaye et al., 1998; Roussouly P et al., 2005; Vialle R et al., 2005). In clinical practice, radiographic reference values help identify regional angulations and linear displacements that can be considered as within the normal alignment range for a given patient. However, because of the large range considered "normal," regional values alone are insufficient in assessing patient-specific harmonious alignment and the optimal values to strive for in realigning a deformity. It is thus important to consider the idea of spinopelvic

harmony, which relates to the proportionality of one given regional parameter to another and in practical terms the global spinopelvic alignment of the individual. In a simplified manner, for a given subject, a ground rule of harmonious alignment consist of a lumbar lordosis proportional to pelvic incidence while the thoracic kyphosis is proportional to the lumbar lordosis (to a lesser extent) (Schwab F et al., 2010).

When pathology, such as kyphotic deformity perturbs regional alignment, it leads to a chain of modifications along the standing axis. In severe cases, the consequence is a large sagittal vertical axis and pelvic tilt, lost lumbar lordosis resulting in “spinopelvic mismatch” and sagittal imbalance. Based on the idea of spinopelvic harmony and believing that by a chain of interconnected parameters (Berthonnaud E et al.,2005; Schwab F et al.,2006; Vialle R et al.,2005), spinopelvic harmony can be reconstructed according to and in proportion to pelvic morphology, we developed a method to determine the lumbosacral curve which theoretically would bring sagittal balance to an ideal state by calculation and simulation for each patient preoperatively and made template rods of the curve and a blueprint accordingly for operative procedures to follow. It is a pragmatic approach for optional spinopelvic realignment to a given individual on the basis of their respective pelvic morphology. As a pragmatic tool for clinical application, spinopelvic realignment objectives involve utilizing the key pelvic parameters that are constant for each given patient. (The codes of each patient for optimizing reconstructed sagittal balance).

2. Materials and methods

The medical records of 103 consecutive patients who underwent surgery according to the blueprints and with utilization of the template rods for correction of sagittal imbalance by the same surgeon from 2003-2007 were reviewed. Three patients died of unrelated causes and six were lost to follow-up. The remaining 94 patients (73 women, 21 men; mean age 64.7 years, range 51-81 years) were followed up for 2-6 years.

Diagnoses included degenerative lumbar kyphosis (n=41), degenerative lumbar kyphoscoliosis (n=16), posttraumatic lumbar kyphosis (including osteoporotic compression fracture) (n=27), and iatrogenic lumbar kyphosis resulted from extensive neurological decompression without instrumentation and fusion (n=10). We excluded patients with neuromuscular disease, ankylosing spondylitis, or flatback syndrome with instrumented lumbar fusion, patients with lumbar kyphosis combined with weakness of lumbar extensors proved by inability to lift their trunk from the floor by contraction of the extensor muscles in the prone position with their legs being fixed and patients with major hip pathology (hip osteoarthritis, hip flexion contracture ...) as this affects pelvic position and the ability of compensation for sagittal imbalance through their hip.

The efficacy of a method to correct sagittal imbalance can be assessed by radiographic parameters and absolute correction. Preoperative, 2-month postoperative, and final follow-up radiographs were analyzed. One of the authors, who was independent of the surgical team, made all the radiographic measurements. Sagittal measurements were made on 36-in. standing lateral views of the entire spine and upper femur obtained with the hips and knees fully extended. Thoracic kyphosis was measured from the upper endplate of T1 to the lower endplate of T12, and lumbar lordosis was measured from the upper endplate of L1 to the upper endplate of S1. Positive values were used to denote kyphosis and negative values

were used to indicate lordosis. Sagittal global balance was measured as the horizontal distance between vertical lines through the hip axis and sacral promontory and represented as sacrofemoral distance (SFD, positive values for femoral anterior to the promontory). The acceptable range of the reconstructed sagittal global balance was -2 to 2 cm (HA nearly under the promontory). Sagittal spinal balance was measured as the horizontal distance between the C7 sagittal plumb line and the posterior superior corner of S1. Because the posterosuperior aspect of the S1 body was the reference, the normal neutral range for sagittal spinal balance was ≤ 3 cm from this point (plumb line through or behind the L5-S1 disc). Sacral inclination angle (SIA) was defined as the angle subtended by the sacral endplate and horizontal reference line (positive for anterior inclination). The proximal junctional angle was defined as the angle of the inferior endplate of the upper instrumented vertebrae (UIV) to the superior endplate of one suprajacent vertebra above the UIV. Abnormal proximal junctional kyphosis was defined by the proximal junction sagittal Cobb angle $+10^\circ$ or more and proximal junction sagittal Cobb angle being at least 10° higher than the preoperative measurement. Fracture of the UIV or one suprajacent vertebra above the UIV was noted as a junctional fracture. Segmental lordosis from L1 to S1 was measured by the Cobb method from the superior endplates of adjacent vertebrae and was utilized to distribute segmental lordosis of the determined lumbosacral curve. Closing-opening wedge osteotomy (COWO) angle was the segmental lordosis of the segment with COWO. L4-S1 lordosis was the Cobb angle between the superior endplates between L4 and S1.

Magnetic resonance imaging was used to confirm spinal stenosis and identify neural compression (retropulsed bone or disc). All patients received the standard method of measuring bone density via dual-energy radiographic absorptiometry. Thirty-four patients were osteopenic (T scores between -1.0 and -2.5) and 43 patients were osteoporotic (T scores < -2.5). Seventeen patients had normal bone stock (T scores between 1 and -1).

Paired t tests were used for continuous variables between time points and between estimated and reconstructed values. Statistical significance was set at $p < 0.05$.

2.1 Making template rods and blueprint for surgery

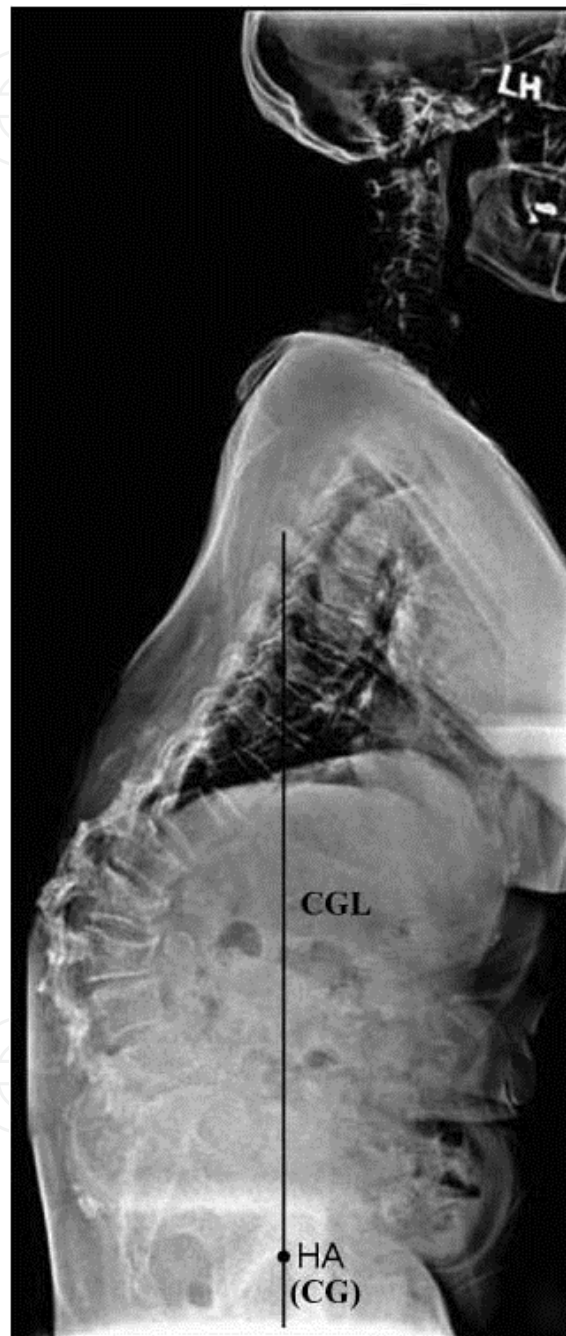
2.1.1 Identify the center of gravity line

The center of gravity (CG) is over the HA and normally directly under the promontory of the sacrum (Takemitsu Y et al., 1988). The CG line is a vertical line through the CG, and it was used as a guideline for the reconstruction of optimal sagittal balance in this study. The ideal sagittal balance to be reconstructed was to have a sagittal global balance with the CG directly under the promontory with SFD = 0 (Figure 1A).

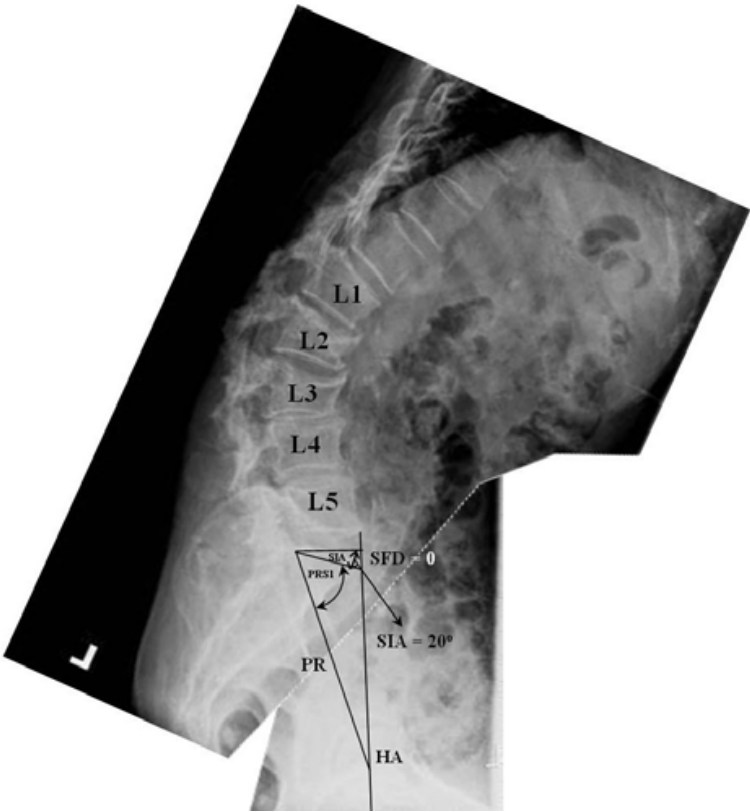
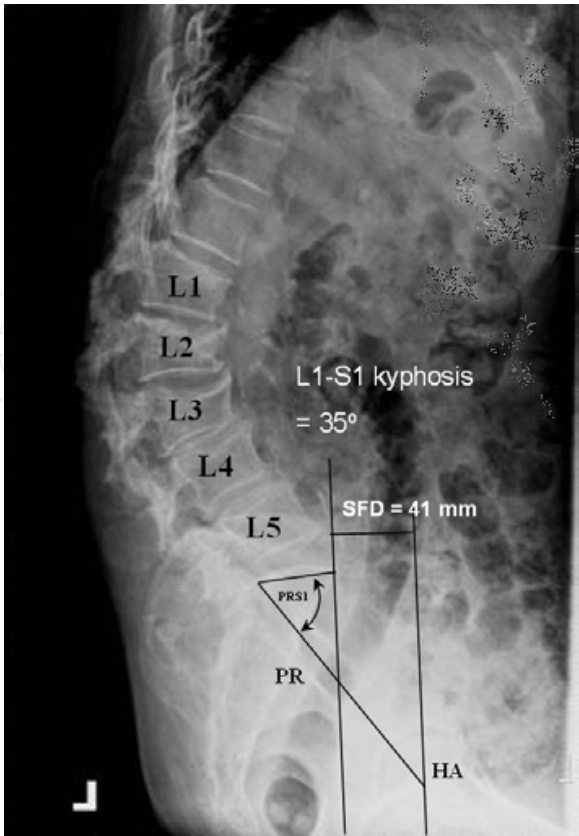
2.1.2 Determine pelvic orientation

Each person has a unique posture and spinopelvic balance with a particular set of sagittal alignment. Pelvic morphology has been shown to affect standing lumbosacral lordosis and pelvic balance significantly around the hips in studies involving both adult volunteers and patients with spinal disorders. (Jackson PR, 1997, 1998, 2000; During J et al., 1985; Kobayashi T, 2004). Measurements of pelvic morphology have been made by determining the approximate centers of the hip joints on lateral radiographs (Jackson RP & Hales C, 2000). Jackson and Hales (Jackson RP & Hales C, 2000) described a specific "pelvic radius

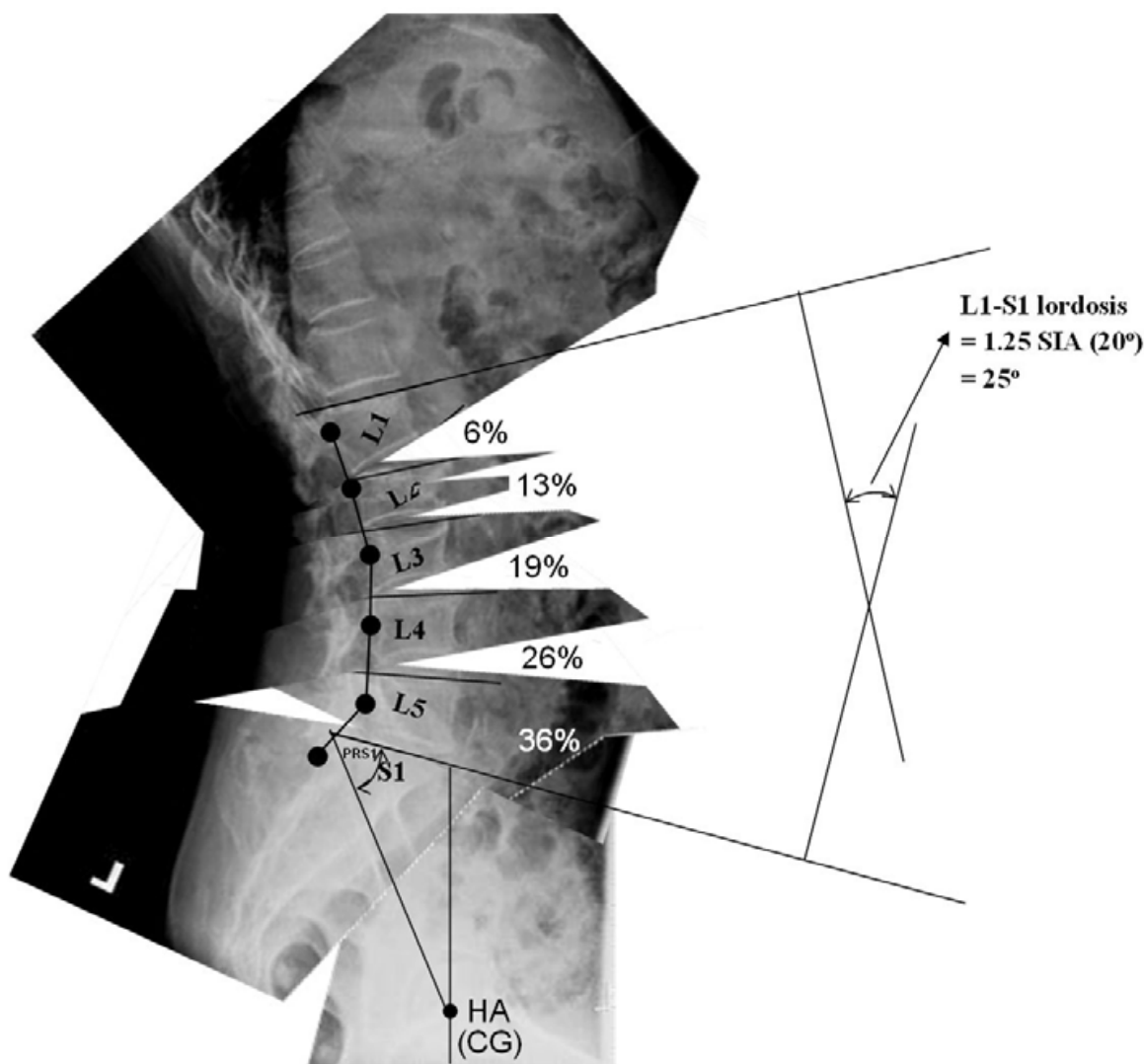
technique, which involved locating a midpoint between the hip centers called the pelvic “hip axis” and drew a line from this axis to the posterior superior corner of S1.



(A) subfigure 1

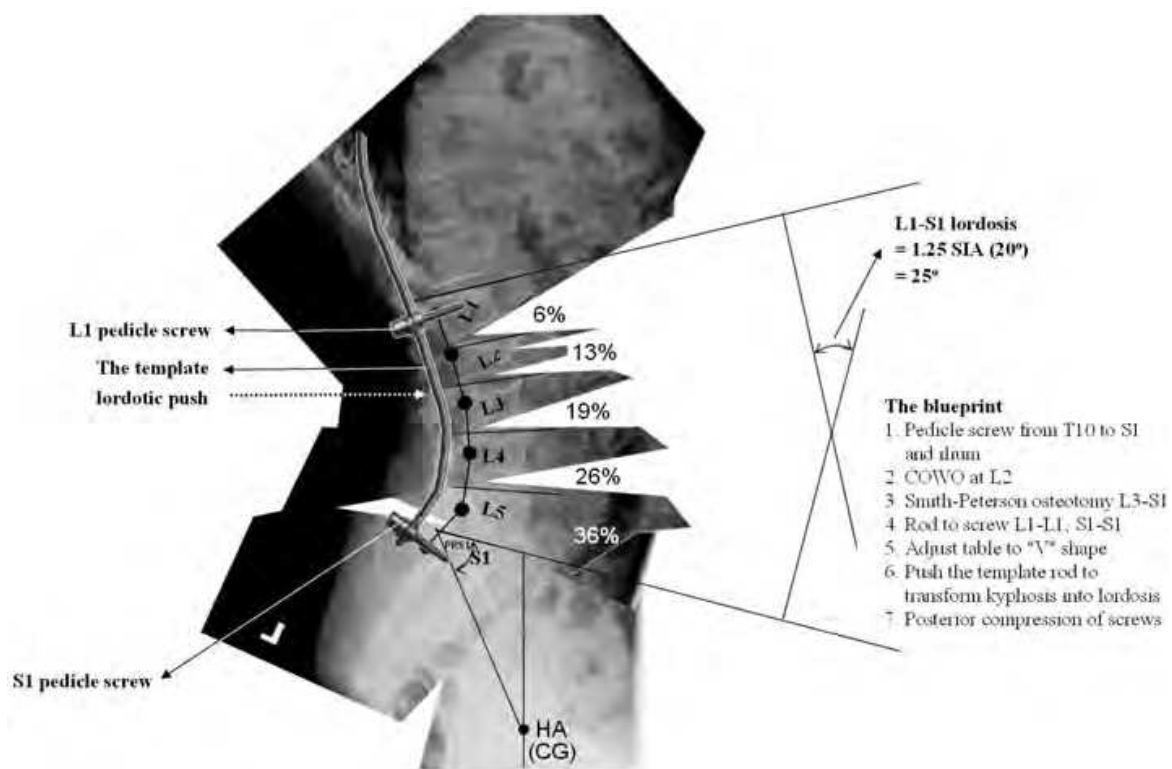


(B) subfigure 1

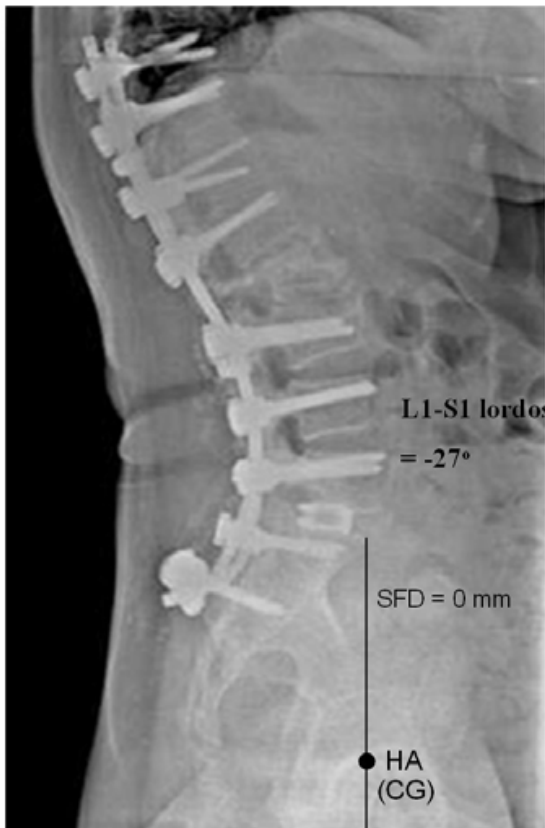

(C) subfigure 1

Fig. 1. A representative example of quality control of reconstructed sagittal balance for sagittal imbalance. A 67-year-old woman with iatrogenic lumbar kyphosis. The preoperative value of L1-S1 lordosis, sacral inclination angle (SIA), sacrofemoral distance (SFD), and sagittal spinal balance were 35°, -9°, 41 mm, and 150 mm, respectively. A, Identify the center of gravity line (CGL). Hip axis (HA) is the midpoint between the hip centers. The center of gravity (CG) is over the HA. The CGL is a vertical line through the CG and is a guideline for reconstruction of optimal sagittal balance. B, Determine pelvic orientation. The lumbopelvic portion of the standing radiograph was magnified to life size and the values of pelvic-radius length and pelvic radius-S1 angle were measured, which are constants for each patient. The lumbopelvic portion was divided into the hips and spinopelvic portion. Given the two anatomic constants and 0-mm SFD, pelvic orientation can be determined by translating and rotating the paper with the spinopelvic portion to a position with the values. C, Determine the lumbosacral curve. The Cobb angle between L1 and S1 is equal to the estimated L1-S1 lordosis. The lumbosacral curve was made approximately according to the reported distribution by simulation of operative procedures and motion behavior of vertebral segments.



(D) subfigure 1



(E) subfigure 1

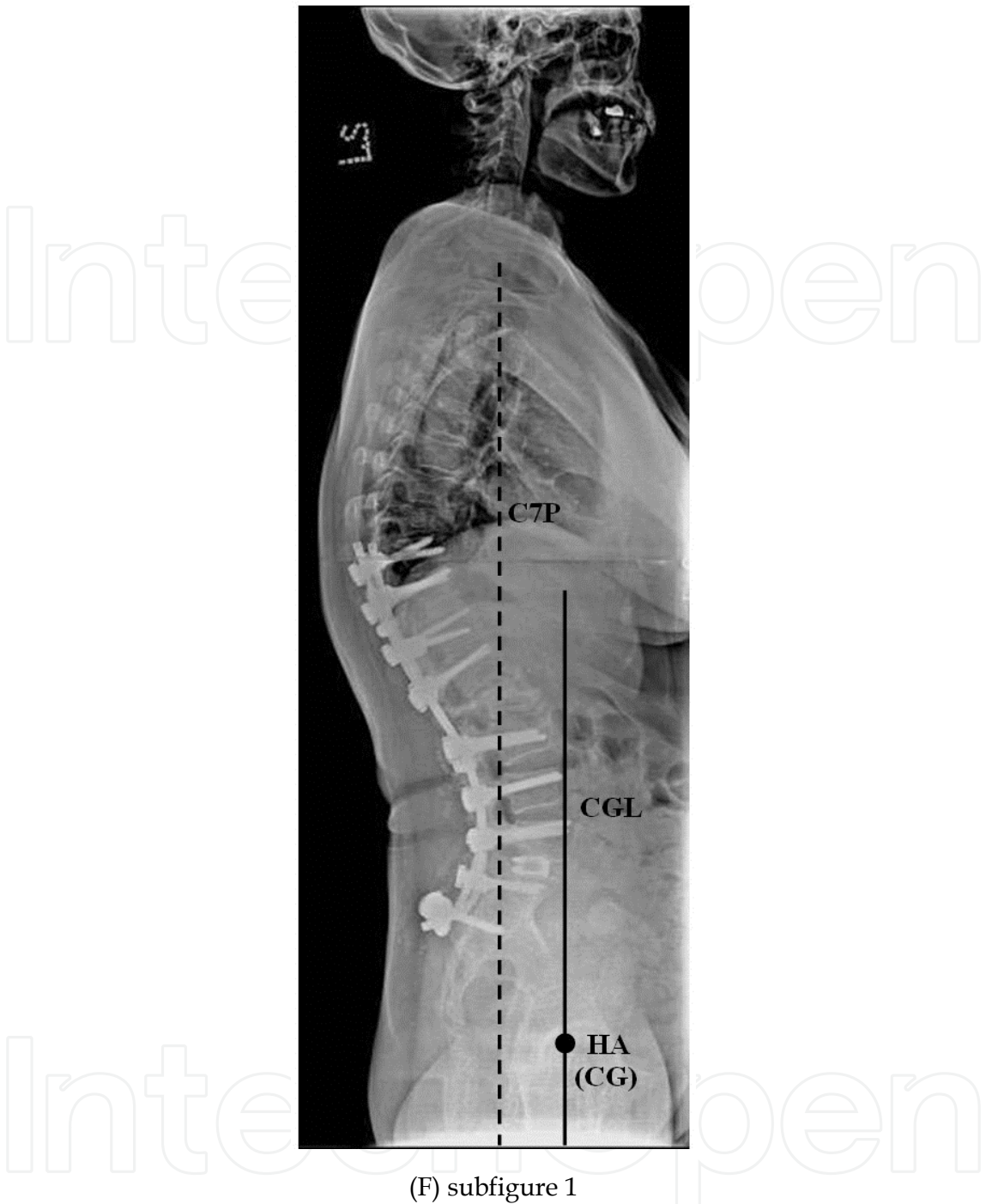


Fig. 1. D, The template, a rod positioned 15 mm (the average length of the patient's lumbar pedicles) posterior to the curve and contoured to match the lumbosacral curve. The two marks on the rod would be connected to the pedicle screw of L1 and S1. The blueprint is for operative procedures to follow. E, After instrumentation-assisted correction with the template rod. The estimated values of L1–S1 lordosis, SIA, SFD, closing-opening wedge osteotomy angle, and L4–S1 lordosis were -25° , 20° , 0 mm, -3.3° , and -15.5° , respectively, as compared with the reconstructed values -27° , 19° , 0 mm, -11° , and -14° . F, Sagittal spinal and global balance improved from 150 mm and 41 mm before surgery to 0 mm and 0 mm 2 months after surgery.

This line segment was named the “pelvic radius” (PR) because the sacrum rotated around the HA along an arc that can be defined by this radial line. Intraobserver and interobserver assessments for lumbopelvic lordosis and sacropelvic alignment, as well as for pelvic morphology, have been reported as very reliable and reproducible by the PR technique (Jackson RP, 2000a, 2000b).

Individual pelvic anatomy should be constant in the adult and therefore not changing much over time. PR lengths and PRS1 angles are constants for each person (Jackson RP et al., 2000) and should not change with pelvic rotation or sagittal translation. In adult volunteers and in patients with spinal disorders, pelvic morphology and lumbosacral lordosis are strongly correlated and complementary in determining lumbopelvic lordosis (Jackson RP et al., 2000), which are strongly correlated with pelvic balance around the HA. The SFD determines pelvic balance. Therefore, given the two anatomic constants and 0-mm SFD, pelvic orientation can be determined. The lumbopelvic portion of the standing lateral radiograph was magnified to life size and printed on transparent paper, which was divided into the hips and spinopelvic portions. We located the HA and rotated and translated the paper, with the spinopelvic portion to a position with the original PR length and PRS1 angle (constants for each individual) (Jackson RP et al., 2000) and with an SFD value of 0 mm. (The CG line normally is directly under the promontory (Takemitsu Y et al., 1988). Pelvic orientation and the SIA could thus be identified (Figure 1B).

2.1.3 Determine lumbosacral lordosis

Spinal balance is conceived as the result of an optimal lordotic positioning of the vertebrae above a correctly oriented pelvis (Legaye J et al, 1998). Kobayashi et al (Kobayashi T et al., 2004) substantiated their previous results showing that the strongest determinant of lumbar lordosis is sacral alignment. Appropriate lumbar lordosis was estimated to be 80% of sacral inclination by using standing radiographs. The study provides practical data for the assessment of sagittal spinal alignment. For L1–L5 lordosis, 40% are at L4–L5 in the aging spine. (Hammerberg EM & Wood KB, 2003) L5–S1 lordosis/L4 L5 lordosis ave aged 1.4 (Jackson RP & McManus AC, 1994). Total L1–S1 lordosis was estimated accordingly: L1–S1 lordosis = $([SIA \times 0.8] \times 0.4) \times 1.4 + SIA \times 0.8 = 1.25 SIA$.

2.1.4 Determine the lumbosacral curve that can bring the promontory directly above the center of gravity

COWO (Chang KW et al., 2008) (Figure 2) and Smith-Peterson osteotomy (SPO) (Smith-Peterson MN et al., 1969) were performed in this study to provide adequate release and flexibility for optimal correction. The apex of the lumbar kyphosis was usually between L2 and L4. The site of COWO for three-column release was as close to the apex as possible (usually L2 or L3) and also allowed enough segments below for rigid fixation. The site of COWO was located and marked on the paper of the spinopelvic portion. The spinopelvic portion was divided at the site of COWO and at each disc to simulate release provided by COWO and SPO. Each divided portion of the paper was rotated and translated with correction hinges, either at the pedicular base of the COWO vertebra to simulate closing and opening wedge of COWO or at the posterior border of each divided disc to simulate lordotic correction until the angle between superior end plate of L1 and S1 was equal to the estimated L1–S1 lordosis. For L1–L5 lordosis, the distribution of lordosis had been reported

to be approximately 10% at L1-L2, 20% at L2-L3, 30% at L3-L4, and 40% at L4-L5 and L5-S1 lordosis/L4-L5 lordosis averaged 1.4 (Jackson RP & McManus AC, 1994) Therefore, the distribution of L1-S1 lordosis was approximately 6% at L1-L2, 13% at L2-L3, 19% at L3-L4, 26% at L4-L5, and 36% at L5-S1. The estimated distribution of lordosis at the COWO segment of the determined lumbosacral curve would be either 13% if COWO was at L2 or 19% if COWO was at L3. The estimated distribution of lordosis at L4-S1 segments would be 62%. The lumbosacral curve connecting each pedicle base of L1-S1 was approximately made (Figure 1C).

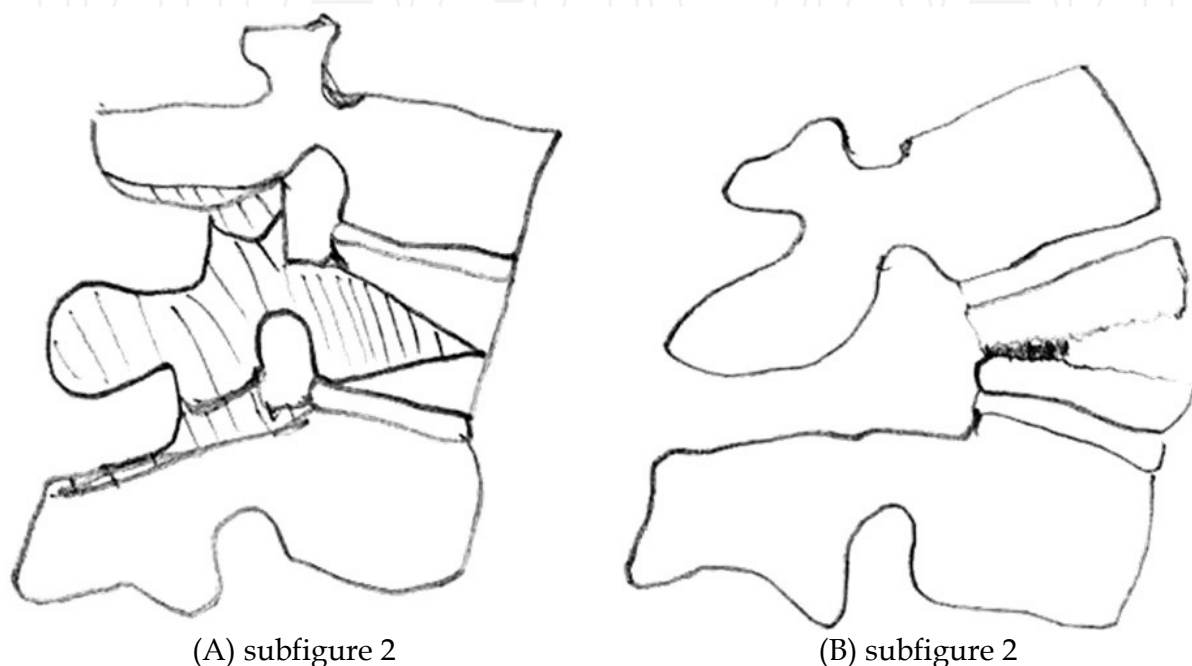


Fig. 2. Diagram of closing-opening wedge osteotomy. A, Lateral view outlines the bone block to be resected. B, Postoperative view shows that the correction is achieved by hinging on the closed middle column, closing the intravertebral osteotomy and creating an open wedge of the anterior column.

2.1.5 Make template rod and blueprint for reconstruction of optimal sagittal balance

The template, a rod, positioned at the distance of the average length of the patient's lumbar pedicles posterior to the curve and contoured to match the lumbosacral curve, was marked on points L1 and S1, which would be connected with pedicle screws of L1 and S1 (Figure 1D). In theory, the promontory of the sacrum could be brought near to the CG line if the lumbosacral curve could be reconstructed accordingly. Through simulation, the site of osteotomy was noted, and what corrective forces, such as translation, compression, distraction, or rotation, were required during correction was noted on the paper as a blueprint for operative procedures to follow (Figure 1D). The previously mentioned method of template generation can also be done on a computerized model instead of paper cutouts. (Figure 1)

2.2 Surgery

Patients were placed in the prone position with padding at the iliac crests, knees, shoulders, and chest. The abdomen was left free to reduce intraoperative bleeding. The osteotomy site

(L2 or L3) was kept over the hinge in the table so that as the osteotomy was closed and the table could be moved from the neutral to “V” position. A standard posterior midline incision was made (usually from T10 to the sacrum). The spine was bilaterally exposed to the tip of the transverse processes with a strictly subperiosteal approach to reduce bleeding. Pedicle screws were inserted (usually from T10 to the sacrum and ilium except at the COWO level). Intraoperative lateral radiographs were used to adjust the length between the bases of the pedicle and screw head to be the average length of the patient's lumbar pedicles.

Wide posterior decompression and formal lateral-recess decompression and foraminotomy of the involved stenotic levels were usually necessary to treat neurogenic claudication and pain. According to the blueprint, COWO (Chang KW et al., 2008) for three-column release was performed as close to the apical vertebra of the deformity as possible (either L2 or L3). Laminectomy and facetectomy at the level of osteotomy were performed. After both pedicles to be resected were identified, holes were made through them to the vertebral body and curettes were used to enlarge the holes. The transverse processes were excised at their bases. With angled curettes, the cancellous bone was pushed anteriorly into the body to create a cavity. The anterior, posterior, and lateral cortexes of the body were thinned with angled curettes, and both pedicles were enucleated with a small osteotome. The posterior cortex was then pushed down into the body. A rongeur was used to resect the appropriate lateral cortex bilaterally. The anterior cortex was weakened by bilateral penetration with a blunt-end cage trial to facilitate its fracture and opening during corrective procedures for patients with sagittal imbalance requiring large magnitude of correction. Correction was achieved by hinging on the closed middle column, closing the intravertebral osteotomy, and creating an open wedge of the anterior column of the osteotomized vertebra. Before correction, abundant autogenous bones from laminectomy and facetectomy were pushed into the anterior portion of intravertebral osteotomy as bone grafts for the open wedge of the anterior column created by correction. SPO was performed at the other levels for posterior release. These osteotomies provide enough flexibility for optimal correction. A template rod was connected to the pedicle screws with mark S1 connected to the S1 pedicle screw and mark L1 connected to the L1 pedicle screw. The pedicle screws were long-arm pedicle screws. The ample space within the screw head and the flexibility of the rod allow the rod to connect to the screw heads. The operating table was slowly moved to a “V” position to facilitate correction and provide space for sagittal translation and rotation around the site of COWO and the HA. The rod was rotated to correct any scoliosis. The surgeon and assistant pushed the rod against the lumbosacral spine to transform kyphosis into lordosis and compressed the pedicle screws to each other to create lordosis between segments and thus create the lordotic lumbosacral curve (Figure 1E, F). The sacrum of the properly oriented pelvis, which had been brought above the HA, needed to be confirmed by intraoperative lateral radiographs. Wake-up tests were performed. Iliac screws were used for all arthrodeses. Anterior bone grafts were not routinely used for segments added to the arthrodesis. However, interbody fusion with wedge-shaped cages placed posteriorly for anterior-column support and fusion at L5-S1 were performed along with neurologic decompression procedures for 32 patients combined with spinal stenosis at L5-S1 because of the known difficulty of obtaining a long fusion to the sacrum. For patients with T scores less than -1.0, we augmented the UIV and its one suprajacent level with polymethylmethacrylate (PMMA) bone cement to prevent the junctional fracture (Figure 3).

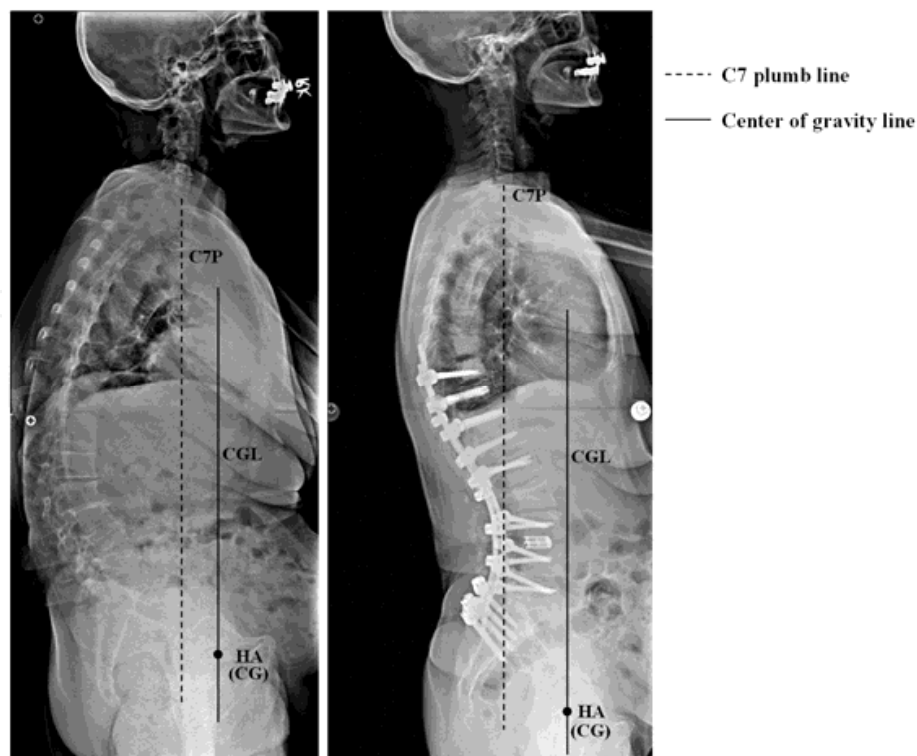


Fig. 3. A 69-year-old woman with degenerative lumbar kyphosis. The preoperative values of L1–S1 lordosis, sacral inclination angle, sacrofemoral distance, and sagittal spinal balance were 17° , -10° , 74 mm, and 75 mm, respectively, compared with postoperative values -48° , 30° , 10 mm, and 0 mm. The upper instrumented vertebrae and its one suprajacent vertebra were augmented with PMMA bone cement to prevent junctional fracture.

Patients ambulated 48 hours later and used custom-made thoracolumbar orthoses for 6 months. Rehabilitation of lumbar extensor musculature by standing straight as much as possible for 15 to 30 minutes every 2 hours during day time began 1 week after the operation.

3. Results

The average preoperative T1–T12 kyphosis was 13° . This increased to 25.2° 2 months after surgery and to 34.5° at the most recent follow-up. The average preoperative L1–S1 lordosis was 19.1° . The curve was corrected to -41.1° 2 months after surgery and to -40.4° at the most recent follow-up. Mean sagittal spinal balance improved from 97.4 mm before surgery to 11 mm 2 months after surgery. Normal sagittal spinal balances (≤ 3 mm) were reconstructed in 85 of the 94 patients. At the final postoperative visit, the mean sagittal balance increased to 25.4 mm, and there was a significant loss of the reconstructed sagittal spinal balance ($P < 0.01$); however, the normal sagittal spinal balance appeared to be maintained. Mean SFD improved from 61.4 mm before surgery to 3.9 mm 2 months after surgery and to 1.3 mm at the final visit. Acceptable sagittal global balances ($\text{SFD} = -2$ to 2 cm) were reconstructed in all patients. There were no significant differences in the mean value between the 2-month and most recent postoperative visits ($P = 0.3$). Mean SIA improved from -5.4° before surgery to 23.3° 2 months after surgery and to 25.7° at final follow-up. There was no significant change of SIA at the final postoperative visit ($P = 0.4$). (Table 1)

Measurement	Preoperative	Postoperative 2 months	Last Follow- up	Correction	Loss of Correction
T1-T12 kyphosis (°)	13 ± 5.2 (-13 to 22)	25.2 ± 11.1 (11 to 34)	34.5 ± 11.3 (18 to 41)	12.2 ± 3.1 (3 to 14)*	9.3 ± 2.1 (5.1 to 11.1)*
L1-S1 lordosis (°)	19.1 ± 8.3 (-7 to 42)	-41.1 ± 15 (-21 to -51)	-40.4 ± 13 (-20 to -51)	60.2 ± 18.1 (31 to 78)*	0.7 ± 0.4 (0.3 to 2.5)
Sagittal balance (mm)	97.4 ± 24.3 (23 to 193)	11 ± 5.3 (-34 to 43)	25.4 ± 7.3 (-31 to 51.3)	86.4 ± 21.1 (23 to 161)*	14.4 ± 5.3 (7.4 to 37.2) *
SIA (°)	-5.4 ± 3.9 (-12 to 13)	23.3 ± 8.8 (14 to 34)	25.7 ± 7.4 (13 to 34)	28.7 ± 11.3 (19 to 37)*	2.4 ± 0.8 (0.1 to 3.5)
SFD (mm)	61.4 ± 17 (25 to 83)	3.9 ± 2.1 (-13 to 19)	1.3 ± 2.1 (-11 to 24)	57.5 ± 15.8 (25 to 83)*	0.4 ± 0.3 (0 to 5.1)

Table 1. Summary of Radiographic Data. Data are presented as the mean ± standard deviation (range). * means P < 0.05. SFD indicates sacrofemoral distance or the distance between the plumb line through the hip axis and the sacral promontory; SIA, sacral inclination angle or the angle between the upper surface of the sacrum and the horizontal line.

COWO was performed at L2 in 46 patients and at L3 in 48 patients. The mean lordosis at the COWO site was -17° and 41% of the reconstructed L1-S1 lordosis 2 months after surgery. The mean estimated lordosis at the COWO site was -5° and 16.1% of the reconstructed L1-S1 lordosis, which was significantly different from the reconstructed value. The mean postoperative L4-S1 lordosis was -19° and 46% of the reconstructed L1-S1 lordosis. The mean estimated lordosis at the L4-S1 segment was -19° and 62% of the reconstructed L1-S1 lordosis. The magnitude was not significantly different from the reconstructed value; however, the percentage of distribution was significantly different from the reconstructed value (P < 0.01). The estimated L1-S1 lordosis was -30.8°, which was significantly less than the reconstructed L1-S1 lordosis. The estimated values of SIA and SFD were 24.6° and 0 mm, respectively, which were not significantly different from the reconstructed values (23.3° and 3.9 mm). (Table 2) Only three patients developed junctional kyphosis. No junctional fracture occurred.

Measurements	Estimated value	Postoperative 2 months	Difference
L1-S1 lordosis (°)	-30.8 ± 6.8 (-19 to -43)	-41.1 ± 15 (-21 to -49)	10.5 ± 3.1 (1 to 18.3)*
Dsitribution			
COWO angle (°)	-5 ± 2.6 (-3 to -7)	-17 ± 5.7 (-9 to -20)	12 ± 4.7 (8 to 18)*
% of L1-S1 lordosis	16.1	41 ± 13.1 (33 to 57)	24.9 ± 8 (16.9 to 40.9)*
L4-S1 lordosis (°)	-19 ± 5.8 (-12 to -27)	-19 ± 4.9 (-10 to -23)	0 ± 1.1 (-3 to 5)
% of L1-S1 lordosis	62	46 ± 12.3 (39 to 52)	16 ± 4.3 (10 to 23)*
SIA (°)	24.6 ± 7.4 (15 to 34)	23.3 ± 8.8 (14 to 34)	1.3 ± 0.3 (-2 to 2.5)
SFD (mm)	0	3.9 ± 2.1 (-13 to 19)	3.9 ± 2.1 (-13 to 19)

Table 2. Summary of Estimated and Reconstructed Data. Data are presented as the mean ± standard deviation (range). * means P < 0.05. COWO indicates closing-opening wedge osteotomy; SFD, sacrofemoral distance or the distance between the plumb line through the hip axis and the sacral promontory; SIA, sacral inclination angle or the angle between the upper surface of the sacrum and the horizontal line.

4. Discussion

Patients with sagittal imbalance cannot stand erect without compensatory hip extension, knee flexion, and overwork of the erector spinae musculature because reduced moment arm compromises the mechanical advantage. The result is muscle fatigue and activity-related pain. As patients age, muscular weakness, adjacent disc degeneration, and hip and pelvic disease may decrease compensation and increase disability. During reconstructive surgery, restoration of optimal sagittal balance is crucial for obtaining satisfactory clinical results. The spine should be fused in a balanced position that is as close to the normal configuration as possible because insufficient deformity correction involving posterior instrumentation alone may lead to lost correction, pseudarthrosis, increased reoperation rates, or poor clinical results (Grubb SA & Lipscomb HJ, 1992; Bradford DS et al., 1999).

Global sagittal spinal alignment has been historically quantified by measuring a vertical line from the center of the C7 vertebral body with respect to the posterior superior corner of S1 (Gelb DE et al., 1995; Van Royen BJ et al., 1998; Vedantam R et al., 2000). This sagittal vertical axis describes the cumulative balance of the sagittal spinal curves of the trunk but not the entire body, which occurs at the CG. Assessment of the gravity line is gaining interest among spine surgeons in the evaluation of sagittal global balance in normal subjects (Roussouly P et al., 2006; Gangnet N et al., 2003; Legaye J & Duval-Beaupere G, 2008; Schwab F et al., 2006) and in patients with spinal deformity (Allard P et al., 2004; El Fegoun AB et al., 2005; Geiger EV et al., 2007; Nash ML et al., 2002). The CG is near the axis through the hip for pelvic rotation and normally is directly under the promontory (Takemitsu Y et al., 1988). Some patients in this study presented with a lumbar kyphosis and a compensatory thoracic lordosis had a normal sagittal spinal balance and a severely abnormal sagittal global balance (Figure 4). Improved association of the spine, pelvis, and CG or economical sagittal balance reduces the work of the erector spinae and hamstring muscles to achieve balance during normal activity.

According to normal standards (Jackson RP & Hales C, 2000; Takemitsu Y et al., 1988; Kobayashi T et al., 2004), all patients in this study had decreased inclination in the upper sacral surface, or backward rotation, which can be explained by compensated lumbar kyphosis. The line connecting both hip joints was far in front of the promontory, increasing the SFD. Even in natural standing, the lumbar extensors overworked to secure balance against a center of gravity located far in front of the lumbosacral junction. Muscle fatigue, spasm, and pain are clinical symptoms of attempted correction of truncal and whole-body imbalance. Correction of lumbar kyphosis and improvement of sagittal spinal balance without relocating the promontory close to the CG line does not relieve myogenic pain in lumbar kyphosis.

Adult pelvic anatomy is stable, and the pelvic-radius length and pelvic-radius-S1 angle are considered to be constant (Jackson RP et al., 2000) and should not change with pelvic rotation or sagittal translation. In adult volunteers and in patients with spinal disorders, pelvic morphology and lumbosacral lordosis are strongly correlated and complementary in determining lumbopelvic lordosis (Jackson RP et al., 2000), which is strongly correlated with pelvic balance around the hip axis. The SFD determines pelvic balance and sacral inclination, which determines L1-S1 lordosis. Therefore, given the 2 anatomic constants and 0-mm SFD, and simulated motion behavior of the kyphotic lumbar spine which is adequately released by osteotomies during correction, a lumbosacral curve with reported distributions to bring the promontory close to the CG line theoretically could be approximately simulated.

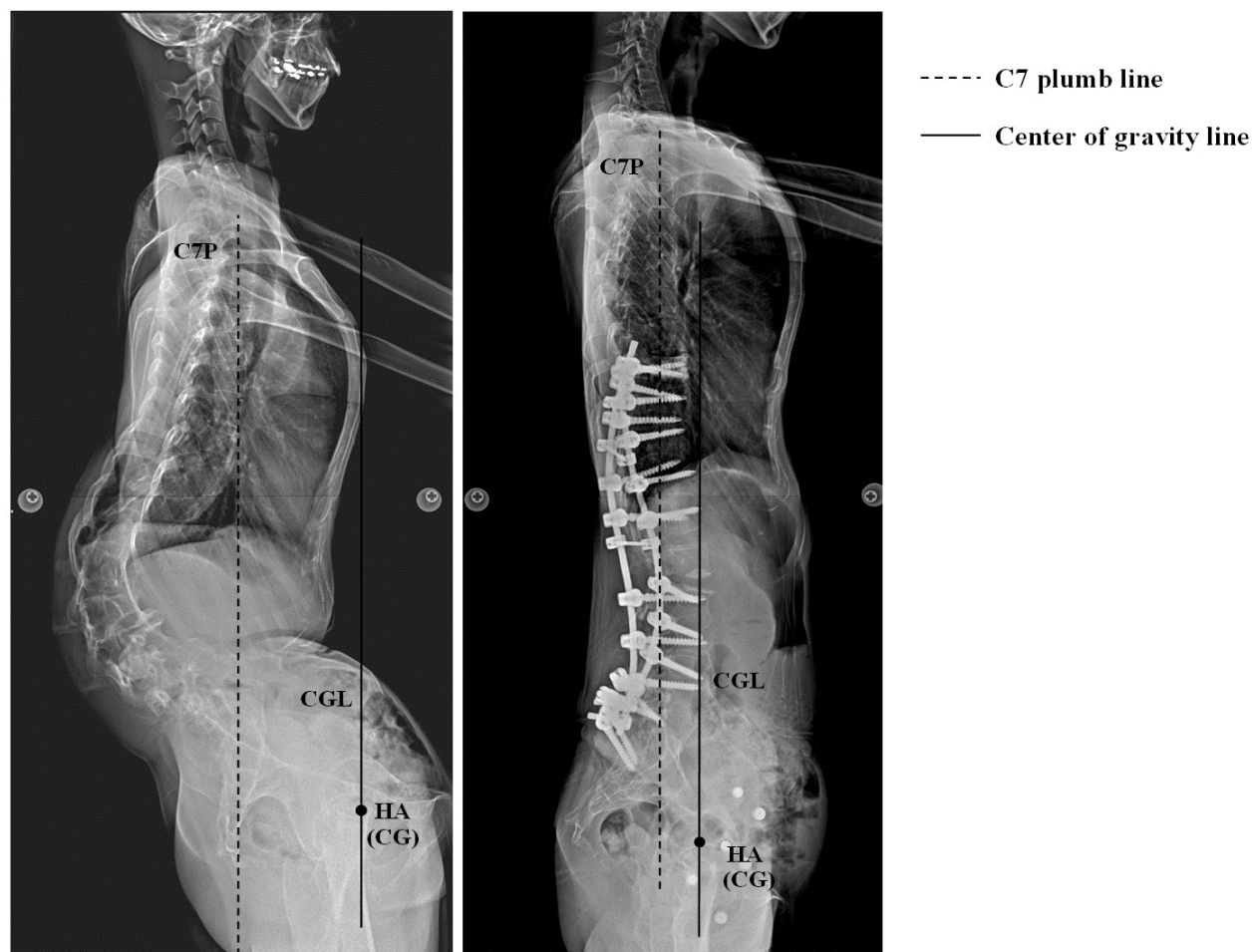


Fig. 4. A 57-year-old woman presented with a lumbar kyphosis and a compensatory thoracic lordosis had a normal sagittal spinal balance and a severely abnormal sagittal global balance. Sagittal global balance was satisfactory reconstructed by the pragmatic approach presented in this study.

Because the caudal end of the construct was sacral and ilial, and because correction of lumbar kyphosis and restoration of lumbosacral lordosis was accomplished by pushing the template rods toward the "V" position of the operating table, the lumbar spine around the apex, which had been three-column released by COWO, translated anteriorly and the lumbopelvic segment caudal to the apex rotated around the hip axis. When the pelvis rotated anteriorly, the distance from the promontory to the CG line decreased and inclination of the upper sacral surface increased. Therefore, the SFD decreased and the SIA increased. All patients obtained significant decrease in SFDs and increase in the SIA.

Because of the rigidity of the deformities, proper release is needed to provide adequate flexibility before posterior instrumentation-augmented correction can be successful. COWO is a three-column release procedure and is responsible for transforming kyphosis into lordosis by lengthening of the anterior column and shortening of the middle and posterior columns. Smith-Peterson osteotomy is a posterior column-only release procedure. The

flexibility of a segment with COWO is more than the flexibility of the other segments provided by SPO. It is reasonable that the magnitude of correction obtained at the segment with COWO is the largest (41%) among all segmental lordoses of the reconstructed L1-S1 lordosis. Spinal balance is conceived as the result of an optimal lordotic positioning of the vertebral column above a correctly oriented pelvis (Legaye J et al., 1998). Anatomically, the L4-S1 angle is an important source of lordosis in the lumbosacral spine and about two thirds of an L1-S1 lordosis is distributed below L4 to maintain a "correctly oriented pelvis." Correction by pushing the template rod, with 62% of the estimated L1-S1 lordosis being contoured into the portion of template rod connected to L4-S1 segments, obtained only 46% lordosis of the reconstructed L1-S1 lordosis at L4-S1 segments. This is 16% less than the preoperatively estimated distribution at L4-S1 segments. However, the reconstructed L1-S1 lordosis was 33% larger than the estimated L1-S1 lordosis. We believe this was due to pushing the flexible and deformable template rod during correction. The magnitude of reconstructed L4-S1 lordosis was not significantly different from the estimated value of L4-S1 lordosis (-19° vs -19°). Therefore, a properly oriented pelvis can be reconstructed according to the preoperatively made template and blueprint. We reconstructed a lumbosacral curve with L1-S1 lordosis of -41.1° and proper oriented pelvis with an SIA of 23.3° , which improved sagittal spinal balance from 97.4 mm to 11 mm and improved sagittal global balance by decreasing the SFD from 61.4 to 3.9 mm. We approximated lumbopelvic and sagittal balance to the physiologic state. Although the method were approximate, the results demonstrated it was efficient.

We compared the estimated and reconstructed values of L1-S1 lordosis, L4-S1 lordosis, and the SIA. The reconstructed L1-S1 lordosis was 33% larger than the estimated L1-S1 lordosis, and the reconstructed L4-S1 lordosis was 16% less than the estimated L4-S1 lordosis, so the reconstructed L4-S1 lordosis and SIA were not significantly different from the estimated value. Evidently, the lumbar spine was comparatively overlordosed; however, optimal sagittal spinal and global balance were obtained. Sagittal balance is conceived as the result of an optimal lordotic positioning of the vertebrae above a correctly oriented pelvis (Nash ML et al., 2002). On the basis of this study, a "correctly oriented pelvis" is probably more crucial than "optimal lordotic positioning" for quality control of optimal sagittal balance reconstruction. It is necessary to create enough L1-S1 lordosis with adequate distribution at L4-S1 segments to obtain a "correctly oriented pelvis" and optimal sagittal balance, sometimes at the expense of overcorrection of the lumbar spine. In this study, we excluded patients with ankylosing spondylitis or fl at-back syndrome with instrumented lumbar fusion, because the fused L4-S1 segments, unlike motion behavior at L4-S1 segments in this series, would not accept enough distribution from reconstructed L1-S1 lordosis to obtain a "correctly oriented pelvis" during reconstructive surgery. However, the exclusion does not mean that this study is not helpful for these patients who represent a challenging group of patients that constitute a significant proportion of adult spinal deformity surgeons' practices. Additional release procedures at L4-S1 levels to provide adequate flexibility allow L4-S1 segments to accept enough lordosis for obtaining a correctly oriented pelvis and optimal sagittal balance. Of course, all these additional procedures would increase operation time, blood loss, and complications. Overlordosating the lumbar spine to distribute enough lordosis at L4-S1

segments is another option for these patients. (Chang KW 2005a, 2005b, 2006, 2009). However, more-severe proximal junctional problems and compensatory changes of the thoracic spine above might compromise the reconstructed sagittal balance.

The pelvic incidence (Legaye J et al., 1998) (PI) is defined as the angle between the line perpendicular to the sacral plate at its midpoint and the line connecting this point to the axis of the femoral heads. It is an anatomic parameter, unique to each individual, independent of the spatial orientation of the pelvis. This parameter can be considered as a constant because it is an anatomic one, independent of the position of the pelvis, and independent of the age, once growth is completed. PI is an important component of assessing and reconstructing the sagittal alignment. In fact, it determines it. In this study, we used PRS1 angle (the angle between PR and sacral plate) instead of PI, because PRS1 angle is much easier to be identified and measured than PI. Jackson and Hales (Jackson RP & Hales C, 2000) demonstrated that PRS1 angle was one of the most reliable radiographic measurements of pelvic morphology. PRS1 angle can be utilized in place of PI and is based on the following mathematical calculation (A) and mechanic analysis (B).

A. Mathematical calculation (Figure 5)

1. According to the law of sine: Principle of trigonometry, stating that the lengths of the sides of any triangle are proportional to the sines of the opposite angles. When a, b, and c are the sides and A, B, and C are the opposite angles.

$$\frac{a}{\sin(A)} = \frac{b}{\sin(B)} = \frac{c}{\sin(C)} = \text{constant}$$

2. Refer to Figure 5 and the triangle OAB, $\angle OBA + \angle BOA + \angle OAB = 180^\circ$, the angle α (ie; pelvic incidence) is a constant, Because (∴) AD is perpendicular to BC so (∴) the angle $OAB = \alpha + 90^\circ$ is a constant.

$$\frac{\overline{OB}}{\sin(\angle OAB)} = \frac{\overline{OA}}{\sin(\angle OBA)} = \frac{\overline{AB}}{\sin(\angle BOA)} = \text{constant}$$

$$\Rightarrow \frac{\overline{OB}}{\sin(\alpha + 90^\circ)} = \frac{\overline{OA}}{\sin(\beta)} = \frac{\overline{AB}}{\sin(180^\circ - \alpha - 90^\circ - \beta)} = \text{constant}$$

∴ the length of $AB = 1/2BC$ is a constant

∴ angle BOA is a constant.

∴ the angle $BOA = 180^\circ - \angle OBA - \angle OAB$, and the angle OAB is constant.

∴ the angle $OBA = \beta$ (ie; PRS1 angle) is a constant.

B. Mechanic analysis (Figure 6)

The PI (angle α) is an anatomic parameter. The anatomic components involved in the make-up of this parameter were the first three sacral vertebrae, the sacroiliac joints, and the posterior segment of the iliac bone. HA was considered to be a fixed or stationary reference point as the hinge of motion. The mobility of sacroiliac joint is considered negligible. According to this characteristic property, we can assume that it is a rigid-body; any rigid-

body displacement can be considered to be a combination of a rigid-body translation and a rigid-body rotation. The resulting displacements are such that there is no change in the distance between any two points in the body and in any way of moving in rigid-body motion in a fixed axis or plane; all the points maintain the relative distance, and the relative position between points stays the same (Jansson PA & Grahn R, 1995). In this case, the angle α (i.e., PI) and angle β (i.e., PRS1 angle) are constants and the distance between any two arbitrary points of the body is constant and should not change with pelvic rotation or sagittal translation (Figure 6).

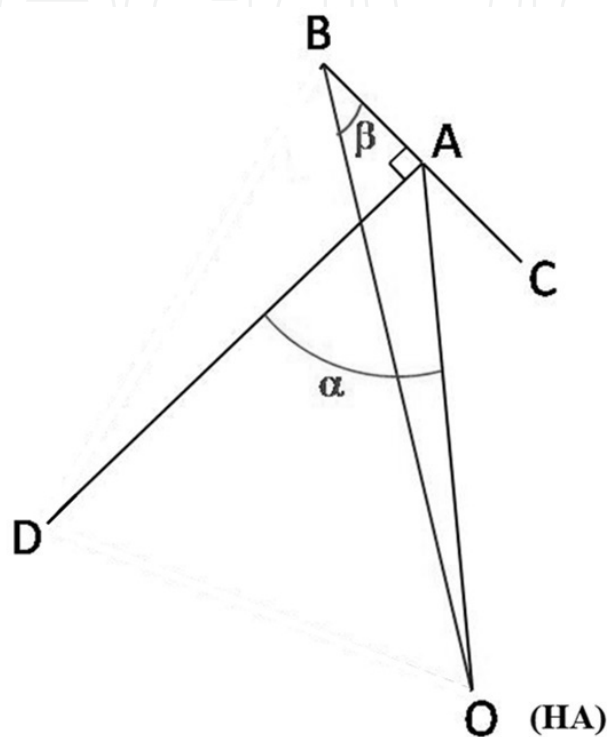


Fig. 5. Mathematical calculation of PI and PRS1 angle. Point O is the hip axis. Point B is the posterosuperior corner of sacrum. Point A is the midpoint of sacral plate. Point C is promontory of sacrum. BC is sacral plate. AD is perpendicular to BC. OB is pelvic radius. Angle α is pelvic incidence. Angle β is PRS1 angle.

On the basis of the above calculation and analysis, both PI and PRS1 are constants and should not change with pelvis rotation or sagittal translation.

The ideal sagittal balance to be reconstructed was to have a sagittal global balance with the CG directly under the promontory, with SFD = 0 (Figure 1A). Given the two anatomic constants (PR and PRS1 angle instead of PI) and 0-mm SFD, pelvic orientation to be reconstructed could be determined before surgery. The results of this study demonstrated that optimal sagittal balance could be reconstructed for sagittal imbalance if the pelvic orientation could be reconstructed accordingly.

There was no significant loss of correction of the reconstructed lumbosacral curve. With the aid of abundant bone grafting the anterior portion of intravertebral osteotomy before correction as bone grafts for the open wedge of the anterior column of the osteomized vertebra created by correction, the union of the anterior open wedge of the anterior column

is like the union of a close fracture with rigid fixation, which is fast and definite. During union period, there might be some loss of correction; we believe that it should be minimal.

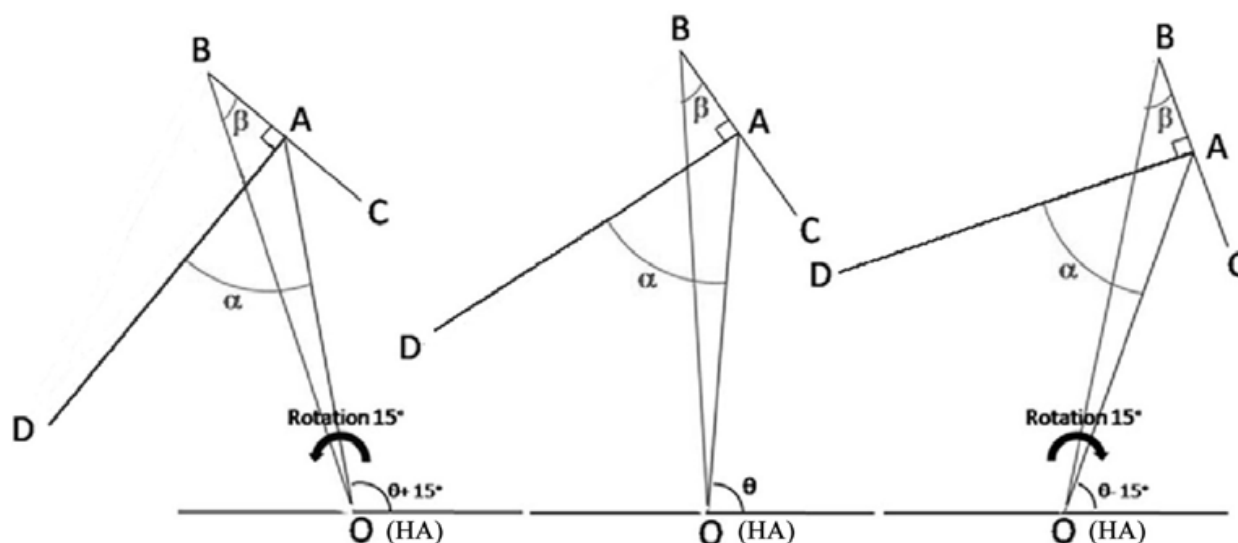


Fig. 6. Mechanical analysis of PI and PRS1 angle. The anatomic construct of pelvic incidence can be considered as a rigid body. Pelvic incidence (angle α) and PRS1 angle (angle β) stay the same, no matter pelvis moves around the hinge (Point O, the hip axis). The illustrations show that angle α and angle β stay the same while the pelvis is rotating 15° and translating posteriorly, staying in neutral position, or rotating 15° and translating anteriorly.

At the level of L5-S1, anterior-column support and anterior bone grafting reduced but did not eliminate the complications such as pseudarthrosis and rods breakage. So, it was not our routine practice to perform structural grafting at L5-S1 through anterior approach. Interbody fusion, with wedge-shaped cages placed posteriorly for anterior-column support, and grafting with high concentrations of autogenous bone and bone morphogenetic protein anteriorly and posteriorly at L5-S1 were performed along with neurologic decompression procedures for patients combined with spinal stenosis at L5-S1 because of the known difficulty of obtaining a long fusion to the sacrum.

For patients with fusion of long segments, and especially for osteoporotic patients, increased motion and stress concentration at a junctional area can induce junctional failure at or above the UIV and adjacent-disc degeneration, leading to junctional kyphosis. Junctional fracture and kyphosis may result in catastrophic neurologic injury, significant loss of sagittal balance, and require reoperation for progressive junctional kyphosis or neurologic deficit. In this study, the lumbar spine was overlordosed; hence, more-severe proximal segmental junctional problems might occur. Preventing the occurrence of junctional problems is crucial for maintaining the reconstructed sagittal balance. DeWald and Stanley (DeWald CJ & Stanley T, 2006) believe that the occurrence of junctional kyphosis is an inevitable consequence of multilevel instrumentation in patients with poor bone stock. They suggested that a potential approach to this problem was to perform limited fusion with the intention of staging proximal extension as the junctional kyphosis progresses. On the basis of our observation of 33 osteoporotic patients who were older than 65 years, had a T score less than -2.5 , had a fusion of long segments, and were followed up for an average of 3.7 years, 26%

developed junctional fracture and 29% developed junctional kyphosis, whereas among 46 patients who were older than 65 years, had a T score less than -2.5 , had long-segment fusion with PMMA augmentation of UIV and its one suprajacent vertebra to prevent junctional fracture, and were followed up for 4.7 years, none had junctional fracture and nine (20%) developed junctional kyphosis. The cause of junctional kyphosis was suprajacent disc degeneration rather than junctional fracture, so the severity of junctional kyphosis was diminished. We also observed 43 patients older than 65 year who had osteopenia (T score < -0.1) with fusion of long segments and found that 8% developed junctional fracture and 11% developed junctional kyphosis.

In this study, PMMA augmentation of UIV (usually T10) and its one suprajacent vertebra was performed to prevent junctional fracture for osteopenia or osteoporotic patients with a T score less than -1 . No junctional failure occurred, and 13 (14%) patients developed junctional kyphosis because of suprajacent disc degeneration. This technique could effectively prevent junctional failure and minimize the severity of junctional kyphosis and the risk of jeopardizing the reconstructed sagittal balance.

The primary cause of lumbar kyphosis might be the following: (1) decline of the anterior elements, multiple disc narrowing, and vertebral wedging or collapse; (2) weakness and loosening of the posterior elements and atrophy of the extensor muscles; (3) combined factors (Takemitsu Y et al., 1988). Spinal alignment can be reconstructed surgically; however, sagittal balance cannot be restored in the presence of weak and atrophic extensor spinal musculature. Therefore, in this study, we excluded patients with neuromuscular disease and those with lumbar kyphosis who could not lift their trunks from the floor by contraction of the extensor muscles in the prone position with legs being fixed. Undoubtedly, the severe reconditioning of the lumbar extensor musculature that occurs as the result of the posterior exposure influences the patient's ability to stand erect. Postoperative rehabilitation of the lumbar extensor muscles is crucial for maintaining the reconstructed sagittal balance and should be started as early as possible and continued.

The average increase of the thoracic sagittal Cobb angle between T1 and T12 at 2 months after surgery was 25.2° and at final follow-up was 34.5° . Although how the thoracic spine would change above was unpredictable and there were significant compensatory changes of the thoracic spine above and significant loss of sagittal spinal balance, the optimal reconstructed sagittal global and spinal balance appeared to be maintained by effective prevention of occurrence of junctional failure and persistent rehabilitation of extensor spinal musculature.

5. Conclusion

Sagittal imbalance can present with a wide range of clinical symptoms and radiographic findings. Recent work has identified key structural parameters to consider in the evaluation and treatment of sagittal imbalance. In addition to the clinical affect of spinal and pelvic parameters, recognition of the interrelationship and necessary harmony between values is critical to optimize individualized treatment. In a simplified manner, for a given subject, a ground rule of harmonious alignment consist of a lumbar lordosis proportional to pelvic incidence while the thoracic kyphosis is proportional to the lumbar lordosis.

When pathology, such as kyphotic deformity perturbs regional alignment, it leads to a chain of modifications along the standing axis. In severe cases, the consequence is a large sagittal vertical axis and pelvic tilt, lost lumbar lordosis resulting in “spinopelvic mismatch” and sagittal imbalance. Based on the idea of spinopelvic harmony and believing that by a chain of interconnected parameters, spinopelvic harmony can be reconstructed according to and in proportion to pelvic morphology. A pragmatic approach for reconstruction of optimal sagittal balance has been presented in this study. Sagittal vertical axis (including C7 plumb line and center of gravity line), and fixed pelvic constants (PR and PRS1 angle) are key parameters and permit a framework to a pragmatic approach for reconstruction of sagittal balance. A correctly oriented pelvis, which can be determined before surgery, reconstructed by restoration of enough L1-S1 lordosis with adequate distribution at L4-S1 segments is a matter of critical importance for optimizing reconstructed sagittal balance. Prevention of junctional fracture and persistent rehabilitation of surgically injured lumbar extensor musculature are crucial for maintaining reconstructed sagittal balance.

The significance of this approach is that quality control of the reconstructed sagittal balance for surgical treatment of sagittal imbalance is possible. It should be noted that the complexity of standing alignment and deformity leaves much work to be done. Surgical planning should strive for ideal alignment while being tempered by risk factors and limitations in the patient’s healthcare environment. Ongoing clinical outcome studies are certain to offer useful algorithms in the near future.

6. References

- Allard P, Chavet P & Barbier F. (2004). Effect of body morphology on standing balance in adolescent idiopathic scoliosis. *Am J Phys Med Rehabil*, 83:689-97.
- Bernhardt M & Bridwell KH. (1989). Segmental analysis of the sagittal plane alignment of the normal thoracic and lumbar spines and thoracolumbar junction. *Spine*, 14:717-21.
- Berthonnaud E, Dimner J & Roussouly P. (2005). Analysis of the sagittal balance of the spine and pelvis using shape and orientation parameters. *J Spinal Disord Tech*, 18:40-7.
- Bradford DS, Tay BK & Hu SS. (1999). Adult scoliosis: surgical indications, operative management, complications, and outcomes. *Spine*, 24:2617-29.
- Chang KW, Chen YY & Lin CC. (2005). Closing wedge osteotomy versus opening wedge osteotomy in ankylosing spondylitis with thoracolumbar kyphotic deformity. *Spine*, 30:1584-93.
- Chang KW, Chen YY & Lin CC. (2005). Apical lordosating osteotomy and minimal segment fixation for the treatment of thoracic or thoracolumbar osteoporotic kyphosis. *Spine*, 30:1674-81.
- Chang KW, Chen HC & Chen YY. (2006). Sagittal translation in opening wedge osteotomy for the correction of thoracolumbar kyphotic deformity in ankylosing spondylitis. *Spine*, 31:1137-42.
- Chang KW, Cheng CW & Chen HC. (2008). Closing-opening wedge osteotomy for the treatment of sagittal imbalance. *Spine*, 33:1470-7.

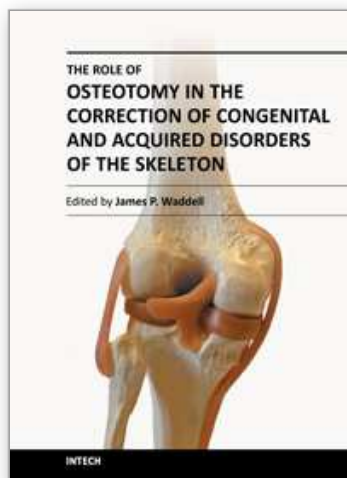
- Chang KW, Cheng CW & Chen HC. (2009). Correction hinge in the compromised cord for severe and rigid angular kyphosis with neurologic deficits. *Spine*, 34:1040-45.
- DeWald CJ & Stanley T. (2006). Instrumentation-related complications of multilevel fusions for adult spinal deformity patients over age 65. *Spine*, 31:S144-51.
- During J, Goudfrooij H & Keessen W. (1985). Toward standards for posture. Postural characteristics of the lower back system in normal and pathologic conditions. *Spine*, 10:83-7.
- Duval-Beaupere G, Marty C & Barthel F. (2002). Sagittal profile of the spine prominent part of the pelvis. *Stud Health Technol Inform*, 88:47-64.
- El Fegoun AB, Schwab F & Gamez L. (2005). Center of gravity and radiographic posture analysis: a preliminary review of adult volunteers and adult patients affected by scoliosis. *Spine*, 30:1535-40.
- Gangnet N, Pornero V & Dumas R. (2003). Variability of the spine and pelvis location with respect to the gravity line: a three-dimensional stereoradiographic study using force platform. *Surg Radiol Anat*, 25:424-33.
- Geiger EV, Müller O & Niemeyer T. (2007). Adjustment of pelvispinal parameters preserves the constant gravity line position. *Int Orthop*, 31:253-8.
- Gelb DE, Lenke LG & Bridwell KH. (1995). An analysis of sagittal spinal alignment in 100 asymptomatic middle and older aged volunteers. *Spine*, 20:1351-8.
- Glassman SD, Berven S & Bridwell K. (2005). Correlation of radiographic parameters and clinical symptoms in adult scoliosis. *Spine*, 30:682-8.
- Glassman SD, Bridwell K & Dimar JR. (2005). The impact of positive sagittal balance in adult spinal deformity. *Spine*, 30:2024-9.
- Grubb SA & Lipscomb HJ. (1992). Diagnostic findings in painful adult scoliosis. *Spine*, 17:518-27.
- Hammerberg EM & Wood KB. (2003). Sagittal profile of the elderly. *J Spinal Disord Tech*, 16:44-50.
- Jackson RP & McManus AC. (1994). Radiographic analysis of sagittal plane alignment and balance in standing volunteers and patients with low back pain matched for age, sex, and size: a prospective controlled clinical study. *Spine*, 19:1611-8.
- Jackson PR. (1997). Spinal balance, lumbopelvic alignments around the "hip axis" and positioning for surgery. *Spine State Art Rev*, 11:33-58.
- Jackson PR, Peterson MD & McManus AC. (1998). Compensatory spinopelvic balance over the hip axis and better reliability in measuring lordotic to the pelvic radius on standing lateral radiographs of adult volunteers and patients. *Spine*, 16:1750-67.
- Jackson RP & Hales C. (2000). Congruent spinopelvic alignment on standing lateral radiographs of adult volunteers. *Spine*, 25:2808-15.
- Jackson RP, Kanemura T & Kawakami N. (2000). Lumbopelvic lordosis and pelvic balance on repeated standing lateral radiographs of adult volunteers and untreated patients with constant low back pain. *Spine*, 25:575-86.

- Jansson PA & Grahn R. (1995). Engineering Mechanics: Vol. 2, Dynamics. *Prentice Hall International*, 253–370. Hemel Hempstead, Hertfordshire, United Kingdom
- Kobayashi T, Atsuta Y & Matsuno T. (2004). A longitudinal study of congruent sagittal spinal alignment in an adult cohort. *Spine*, 29:671–6.
- Legaye J, Duval-Beaupere G & Hecquer J. (1998). Pelvic incidence: a fundamental pelvic parameter for three-dimensional regulation of spinal sagittal curves. *Eur Spine J*, 7:99–103.
- Legaye J & Duval-Beaupere G. (2008). Gravitational forces and sagittal shape of the spine. Clinical estimation of their relations. *Int Orthop*, 32:809–16
- Mac-Thiong JM, Transfeldt EE & Mehbood AA. (2009). Can C7 plumbline and gravity line predict health related quality of life in adult scoliosis? *Spine*, 34:E519–27.
- Nash ML, Allard P & Hinse S. (2002). Relations between standing stability and body posture parameters in adolescent idiopathic scoliosis. *Spine*, 27:1911–7.
- Roussouly P, Gollogly S & Berthonnaud E. (2005). Classification of the normal variation in the sagittal alignment of the human lumbar spine and pelvis in the standing position. *Spine*, 30:346–53.
- Roussouly P, Gollogly S & Nosedá O. (2006). The vertical projection of the sum of the ground reactive forces of a standing patient is not the same as the C7 plumb line: a radiographic study of the sagittal alignment of 153 asymptomatic volunteers. *Spine*, 31:E320–5.
- Schwab F, Lafage V & Boyce R. (2006). Gravity line analysis in adult volunteers: age-related correlation with spinal parameters, pelvic parameters, and foot position. *Spine*, 31:E959–67.
- Schwab F, Lafage V & Patel A. (2009). Sagittal plane considerations and the pelvis in the adult patient. *Spine*, 34:1828–33.
- Schwab F, Patel A & Ungar B. (2010). Adult spinal deformity-postoperative standing imbalance. *Spine*, 35:2224–2231.
- Smith-Peterson MN, Larson CB & Aufranc OE. (1969). Osteotomy of the spine for correction of flexion deformity in rheumatoid arthritis. *Clin Orthop Relat Res*, 66:6–9.
- Van Royen BJ, Toussaint HM & Kingma I. (1998). Accuracy of the sagittal vertical axis in a standing lateral radiograph as a measurement of balance in spinal deformities. *Eur Spine J*, 7:408–12.
- Vaz G, Roussouly P & Berthonnaud E. (2002). Sagittal morphology and equilibrium of pelvis and spine. *Eur Spine J*, 11:80–7.
- Vedantam R, Lenke LG & Bridwell KH. (2000). The effect of variation in arm position on sagittal spinal alignment. *Spine*, 25:2204–9.
- Vialle R, Levassor N & Rillardon L. (2005). Radiographic analysis of the sagittal alignment and balance of the spine in asymptomatic subjects. *J Bone Joint Surg Am*, 87:260–7.
- Vidal J & Marnay T. (1983). Morphology and anteroposterior body equilibrium in spondylolisthesis L5-S1. *Rev Chir Orthop Reparatrice Appar Mot*, 69:17–28.
- Vidal J & Marnay T. (1984). Sagittal deviations of the spine, and trial of classification as a function of the pelvic balance. *Rev Chir Orthop Reparatrice Appar Mot*, 70(suppl 2):124–6.

White AA & Panjabi MM. (1990). Practical biomechanics of scoliosis and kyphosis. In: *Clinical biomechanics of the spine*. White AA, Panjabi MM, eds, 127-68. Philadelphia: Lippincott-Raven.

IntechOpen

IntechOpen



The Role of Osteotomy in the Correction of Congenital and Acquired Disorders of the Skeleton

Edited by Prof. James Waddell

ISBN 978-953-51-0495-7

Hard cover, 294 pages

Publisher InTech

Published online 11, April, 2012

Published in print edition April, 2012

This book demonstrates specific osteotomy techniques from the skull to the hallux. The role of osteotomy in the correction of deformity is under appreciated in part because of the ubiquitous nature of joint replacement surgery. It should be remembered, however, that osteotomy has a role to play in the correction of deformity in the growing child, the active young adult, and patients of any age with post-traumatic deformity limiting function and enjoyment of life. In this text we bring you a number of papers defining specific problems for which osteotomy is found to be an effective and lasting solution. I hope you find it useful.

How to reference

In order to correctly reference this scholarly work, feel free to copy and paste the following:

Kao-Wha Chang (2012). Quality Control of Reconstructed Sagittal Balance for Sagittal Imbalance, The Role of Osteotomy in the Correction of Congenital and Acquired Disorders of the Skeleton, Prof. James Waddell (Ed.), ISBN: 978-953-51-0495-7, InTech, Available from: <http://www.intechopen.com/books/the-role-of-osteotomy-in-the-correction-of-congenital-and-acquired-disorders-of-the-skeleton/quality-control-of-reconstructed-sagittal-balance-for-sagittal-imbalance>

INTECH
open science | open minds

InTech Europe

University Campus STeP Ri
Slavka Krautzeka 83/A
51000 Rijeka, Croatia
Phone: +385 (51) 770 447
Fax: +385 (51) 686 166
www.intechopen.com

InTech China

Unit 405, Office Block, Hotel Equatorial Shanghai
No.65, Yan An Road (West), Shanghai, 200040, China
中国上海市延安西路65号上海国际贵都大饭店办公楼405单元
Phone: +86-21-62489820
Fax: +86-21-62489821

© 2012 The Author(s). Licensee IntechOpen. This is an open access article distributed under the terms of the [Creative Commons Attribution 3.0 License](https://creativecommons.org/licenses/by/3.0/), which permits unrestricted use, distribution, and reproduction in any medium, provided the original work is properly cited.

IntechOpen

IntechOpen