

We are IntechOpen, the world's leading publisher of Open Access books Built by scientists, for scientists

6,900

Open access books available

186,000

International authors and editors

200M

Downloads

Our authors are among the

154

Countries delivered to

TOP 1%

most cited scientists

12.2%

Contributors from top 500 universities



WEB OF SCIENCE™

Selection of our books indexed in the Book Citation Index
in Web of Science™ Core Collection (BKCI)

Interested in publishing with us?
Contact book.department@intechopen.com

Numbers displayed above are based on latest data collected.
For more information visit www.intechopen.com



Surgery of the Bony and Cartilaginous Vault in Rhinoplasty

Pavel Dolezal

*Slovak Medical University, Department of Otorhinolaryngology,
University Hospital Bratislava, Bratislava,
Slovakia*

1. Introduction

An osteotomy must be performed in almost all types of external nose correction. By mobilising the bony skeleton, the nose may be sculpted into the desired shape and position. The osteotomy is carried out as gently as possible in an effort to minimize postoperative swelling and soft tissue bleeding. Finger and sharp chisels are used. Nasal bones are accessed through a short intercartilaginous incision above the lateral nasal cartilage. The outer periosteum is pushed to the side, then an osteotome is placed about 2mm paramedially and, using rhythmic taps of a metal mallet, a medial osteotomy is performed. The position of the osteotome is checked by finger palpation on the nasal dorsum. The osteotome is worked through the bone up to the level of the frontal bone. Before removal, the resilience of the nasal bone is checked by turning the instrument laterally.

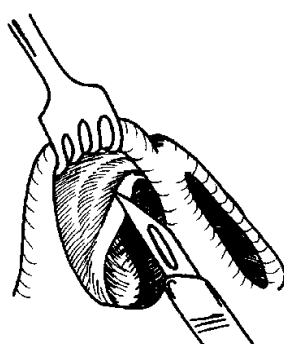


Fig. 1. Short intercartilaginous incision for a medial osteotomy

A lateral osteotomy is carried out through an ancillary vestibular incision in front of the head of the inferior turbinate. The incision is extended to the piriform aperture very close to the maxillary edge in order to obviate needless bleeding. A raspatory is used on the bony edge through a 1 cm long incision, and the anterior periosteum of maxilla and part of the nasal bone are prepared up to the middle canthus. In fact, a subperiosteal tunnel is formed. An identical tunnel is created on the inner side, in the nasal cavity. An osteotome is applied to the bony edge and a lateral osteotomy is performed in the direction outlined in the picture. Cranially, the osteotome is turned towards the cranial end of the previous medial osteotomy. The nasal bone is broken on one side by lateral rotation of the osteotome and is checked by palpation.

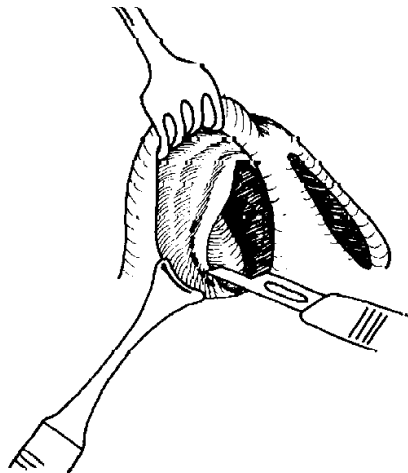


Fig. 2. Short lateral incision for lateral osteotomy

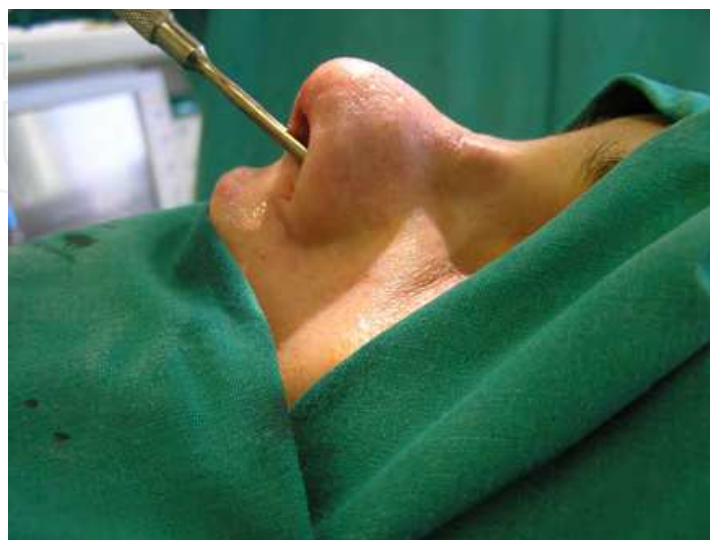

Fig. 3. Creation of a medial tunnel for a lateral osteotomy using a raspatory

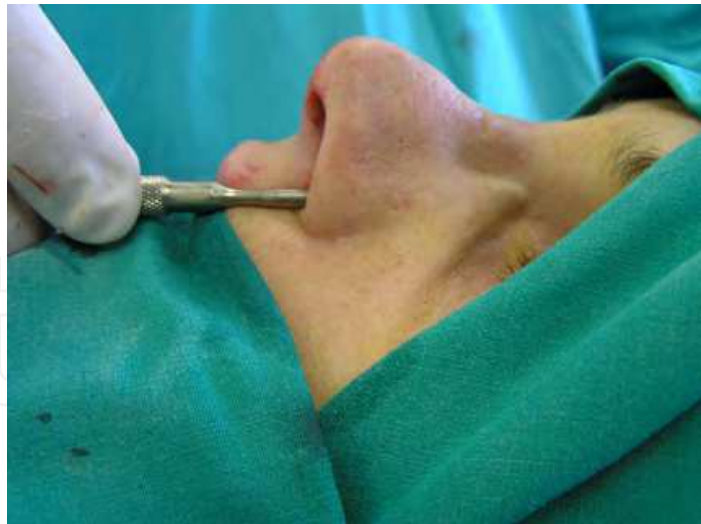


Fig. 4. Creation of a lateral tunnel for a lateral osteotomy

Thorough mobilisation of the nasal skeleton is the most important element in achieving the appropriate cosmetic effect. Sometimes this mobilisation is not sufficient even after a quadruple osteotomy. The transversal part of the osteotomy is sometimes questionable when a straight chisel is used. It can be done using a curved osteotome, following the line of lateral osteotomy slantwise upwards, aiming from the middle canthus to the frontal bone. However, an osteotomy performed using an osteotome, which is a rather thick instrument, is less precise and destroys more surrounding soft tissue than an osteotomy done using a sharp chisel.

If sufficient mobilisation was not obtained, a transversal osteotomy through the skin of the nasal root must be performed. In a skin fold on the nasal root a small incision to the bone surface is made with blade No.15. A 2-3mm wide chisel is put into the incision and, using rhythmic taps, a fixed section of the nasal bone is cut off. Care is taken with all bone fragments. A splinter can easily be pressed inward towards the nasal cavity. If a large fragment is broken, it must be elevated and redressed in the nasal vault line. Irregularities in the nasal skeleton are hidden by edema and hematoma after an osteotomy, but after absorption of edema and decomposition of hematoma all irregularities of the nasal vault

become evident. Therefore, maximum care must be taken when performing an osteotomy. In using the closed technique, the progress of the operation must be confirmed by repeated palpation.

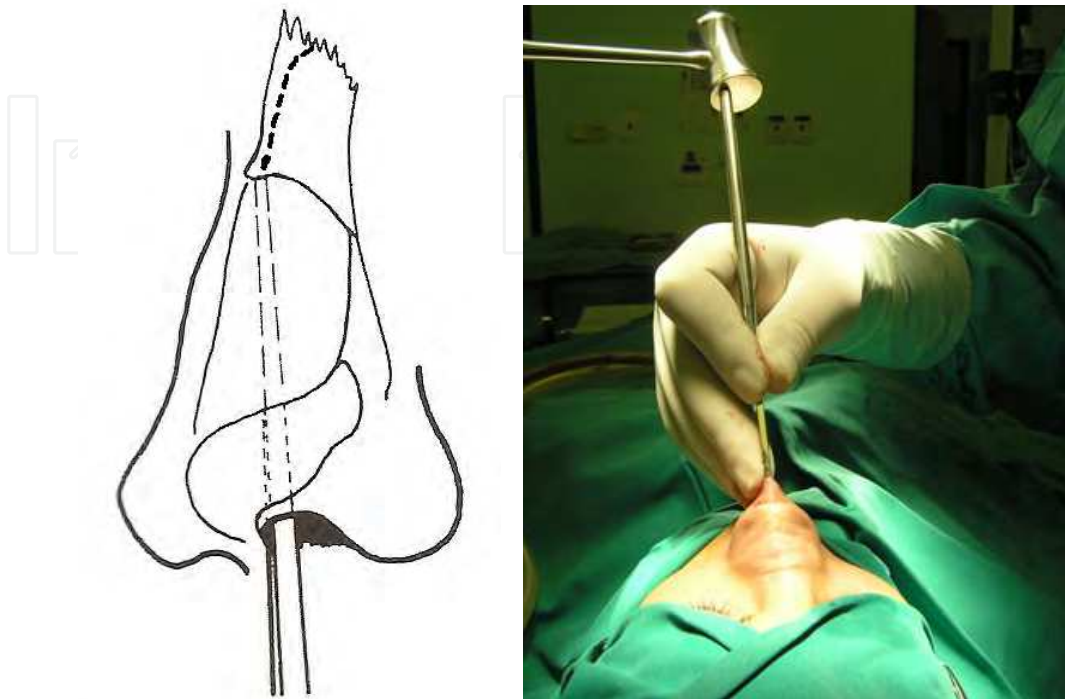


Fig. 5. Medial osteotomy. Osteotome or sharp straight chisel is worked paramedially along the upper edge of the nasal septum to the level of the frontal bone

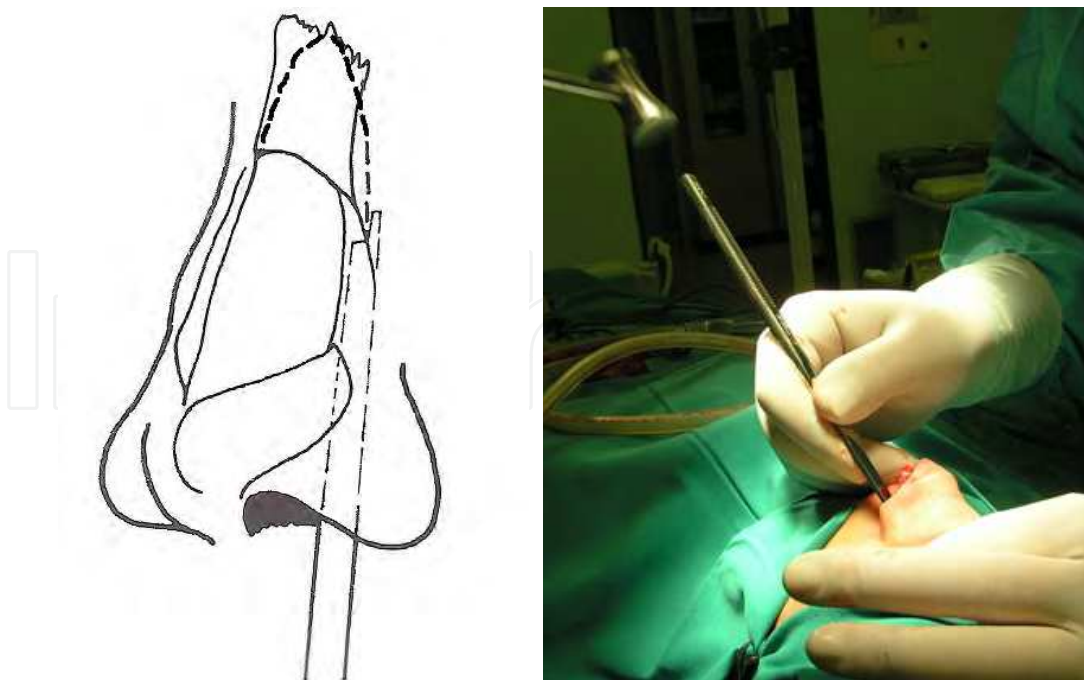


Fig. 6. Lateral osteotomy. Osteotome or chisel is directed across the frontal process of maxilla towards the nasal root and then turned upwards to the line of medial osteotomy. This procedure is also called transversal osteotomy.

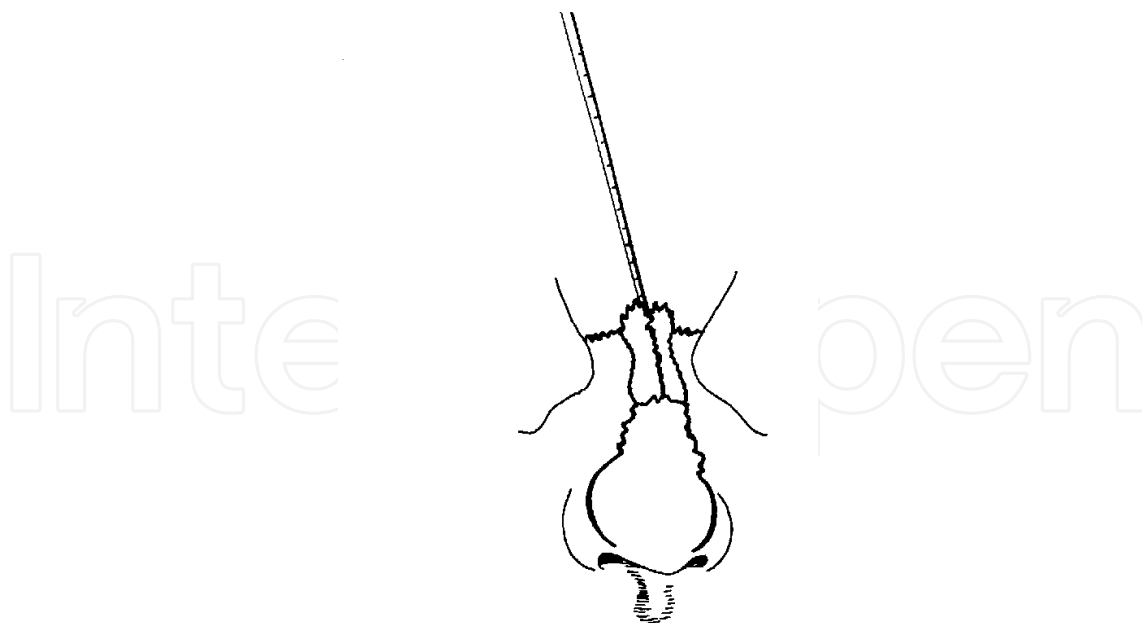


Fig. 7. Transversal transcutaneous osteotomy of nasal bones

In certain cases, the nasofrontal angle can be corrected using this approach. The so-called mini-osteotomy is another method of skeletal mobilisation. It consists of a multiple splitting of the the nasal bones in the line of medial and lateral osteotomy, gaining access through the skin. A narrow chisel can reach under the skin to the region of the frontal process of maxilla. The osteotomy is finished using an endonasal approach. Nasal bones are broken in the proposed line. As well, a mini-osteotomy can be performed through the skin using more incisions. This procedure is more precise, but small scars remain on the lateral nasal wall and mainly on the nasal slope.

2. Resection of a nasal hump

Resection of a nasal hump in the cartilaginous and bony part of the skeleton is a frequent procedure in rhinoplasty. Sometimes there is no real gibbus to correct, it is only necessary to lessen the projection of the nasal dorsum slightly overlapping the line from nasion to nasal tip. A nasal hump may be more developed in the cartilaginous area, where it is formed by septal and lateral cartilage. In the bony part, it is formed by prominent nasal bones. In almost all cases a hump is formed by both parts, therefore they should be reduced together. Several procedures are described in the literature (1-4). In a resection, scissors are used in the beginning to cut the cartilage to the level of resection. Septal cartilage and both prominent lateral cartilages are resected up to the level of the nasal bones. A sharp chisel is inserted under the resected cartilage and the resection of the bony hump is completed. In a successful case, a cartilaginous and bony hump is extracted in one piece using forceps. This piece is oval in shape and symmetric. After a resection, sharp edges are trimmed using a rasp. After each hump removal, a flat nose remains which must be narrowed and the defect in the nasal roof should be closed. A medial osteotomy must be performed and then a lateral osteotomy using the method described in the previous chapter. When the nasal skeleton is mobilised, the bones are narrowed and the external nose is formed in the medial line.

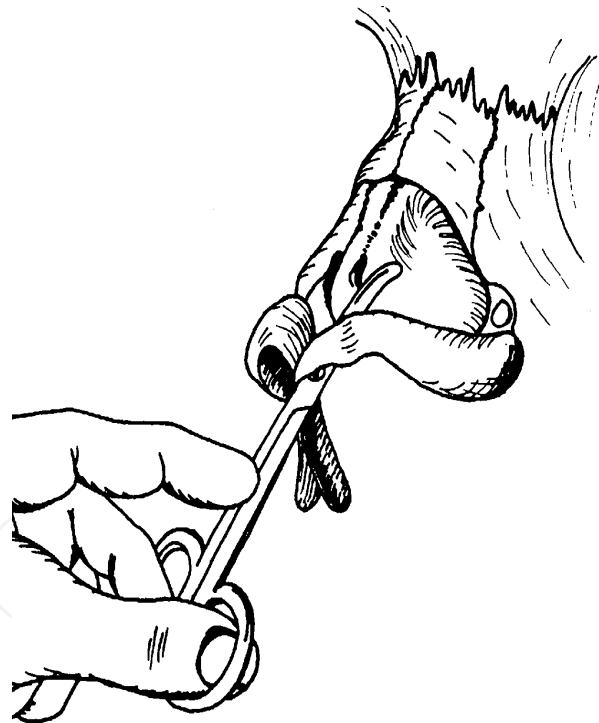
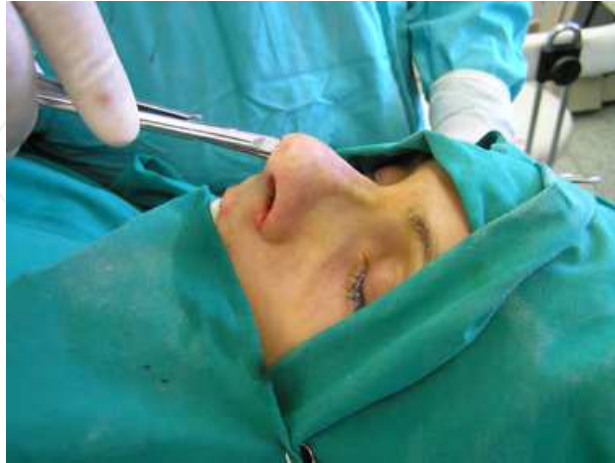

Fig. 8. Preparation of the upper part of the nasal pyramid. Using an intercartilaginous approach, scissors are inserted under the skin. Following the surface of the nasal hump, soft tissues are mobilised.

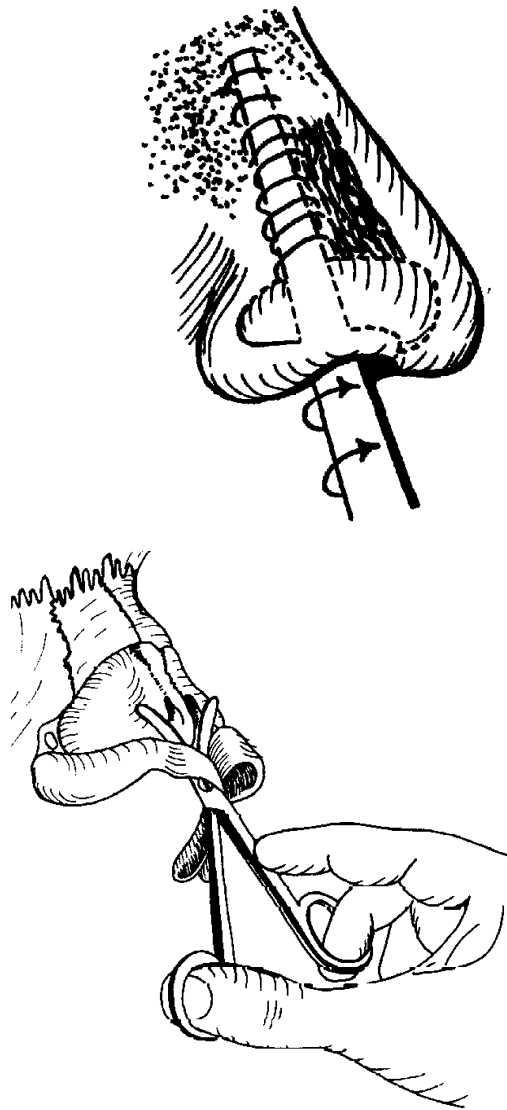


Fig. 9. Soft tissue mobilisation of the nasal pyramid using a raspatory

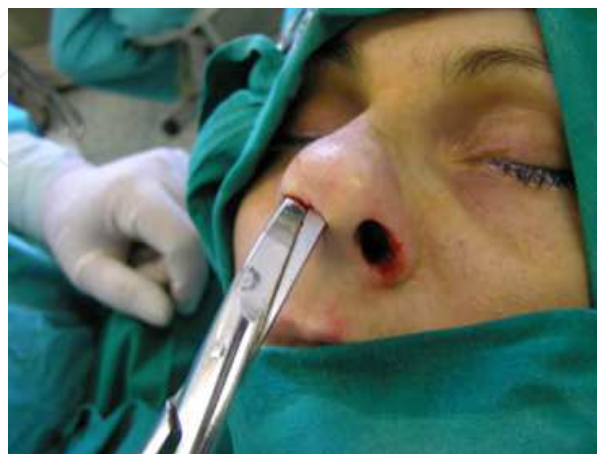

Fig. 10. Cutting the nasal septal cartilage that creates the caudal margin of a cartilaginous and bony hump. After accessing the margin of the nasal bones using scissors, the resection is completed using a straight chisel.

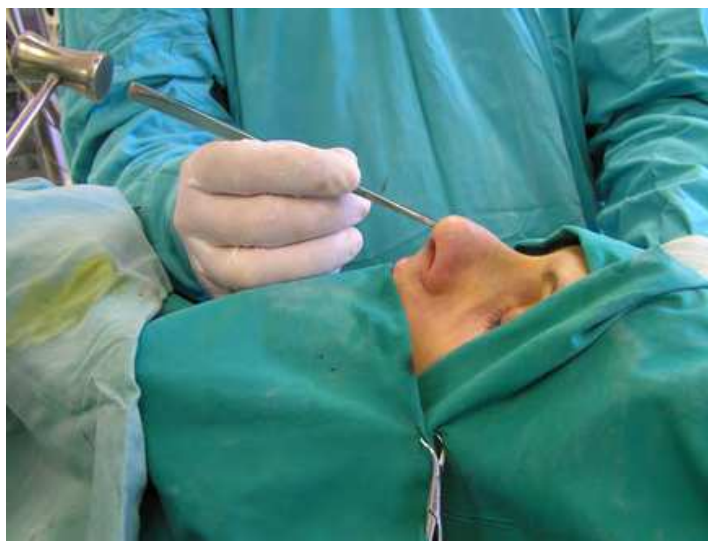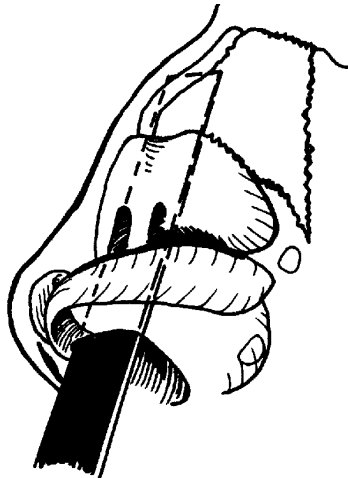


Fig. 11. Resection of cartilaginous and bony hump using a wide chisel

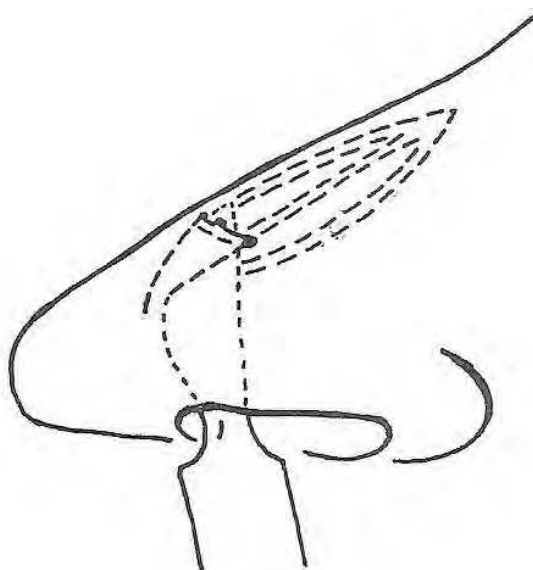

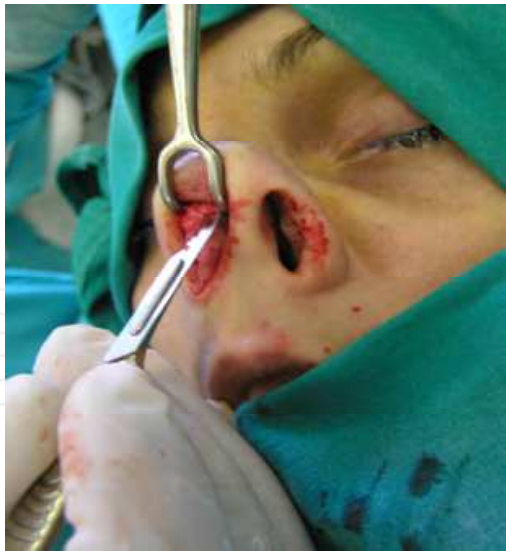


Fig. 12. Alignment of prominent cartilage using a scalpel

The lower, cartilaginous part of the hump may be cut off using a scalpel or sharp scissors. It is better to do so after retracting the skin and cutting under direct vision (figure 12).

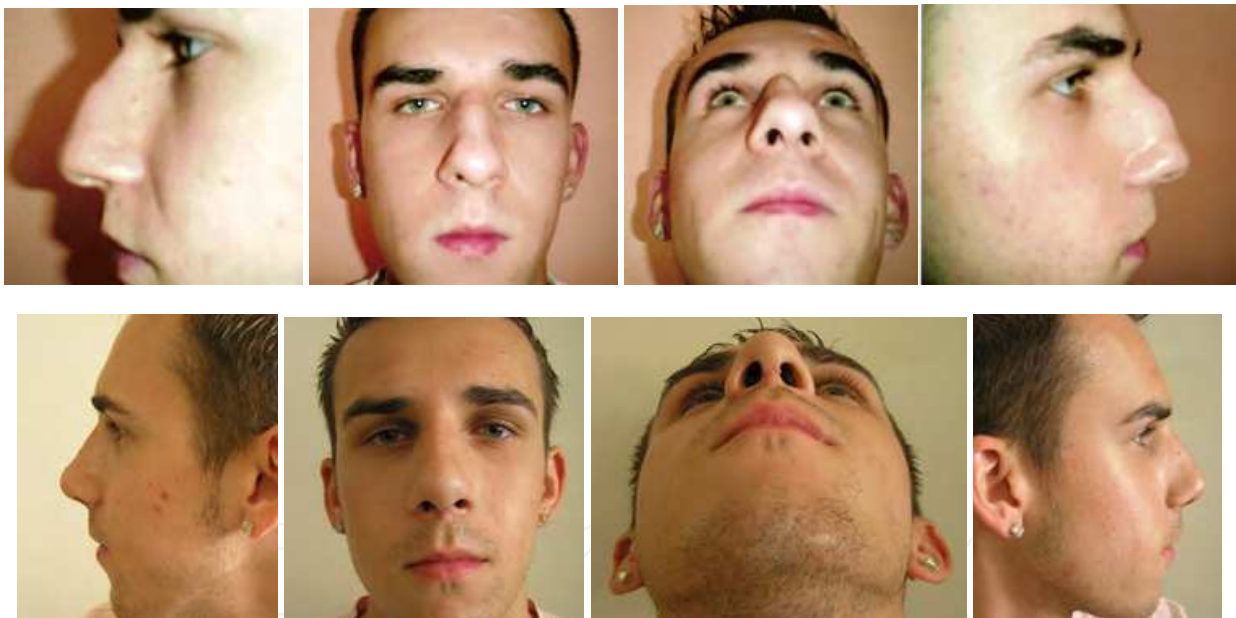

Fig. 13. Patient with a nasal hump, slight deviation to the right side and wide tip (upper pictures). After resection of the hump, osteotomies and interdomal tip suture (lower pictures)

3. Osteotomy in external nose deviation

Fixed elderly external nose deviation causes asymmetry not only of nasal shape but also in the length of the lateral nasal wall. Osteotomy alone is usually not sufficient to align the nasal skeleton into the medial plane because on the opposite side of the deviation, the lateral nasal wall is larger. In this case a "wedge resection" is planned. On the larger side, part of the nasal bone is shaped into a wedge or triangle with its base inverted and the caudal bone

is resected (figure 14). The surgeon has to be experienced and must make an adequate approach to the margin of maxilla and the nasal bone on the side of the resection. Subperiosteal tunnels are made as in a lateral osteotomy. The tunnels must be a little bit wider in order to insert long nasal forceps into them. After extending the branches margin of the piriform aperture, the frontal process of maxilla and nasal bone are more visible. An assessment must be made of the width of the piece of bone to be removed. The first osteotomy is performed close to the nasal bone. A subsequent osteotomy is localized behind this line so that the two lines converge at the level of the inner canthus. The resected bone should therefore be in the shape of a triangle. If the bone is not removed in one piece, all remnants and fragments must be definitely eliminated, best done under direct vision. The lines of fracture should be straight and smooth in order not to hinder the reformation of the nasal skeleton in the new position. Usually a strip of cartilage and bone from the nasal septum must be removed at its base (figure 15).

Deviation may be corrected by outfracture of the nasal bone on the side of the deviation and by infracture on the opposite side. This procedure compensates for curvature optically because it redresses the length of both slopes of the nasal pyramid. Septal mobilisation and thoroughgoing osteotomy is necessary (figure 15)

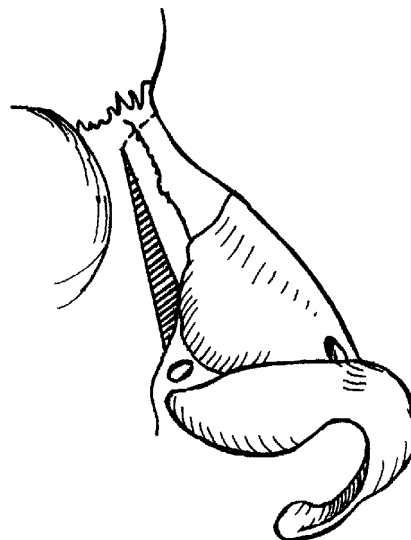


Fig. 14. Wedge resection of maxilla on the side opposite to the deviation

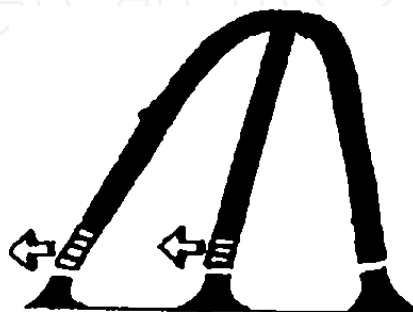


Fig. 15. Bony wedge resected from the frontal process of maxilla on the contralateral side of the deviation and resection of a basal strip of the nasal septum. Schematic picture of nasal pyramid in axial plane

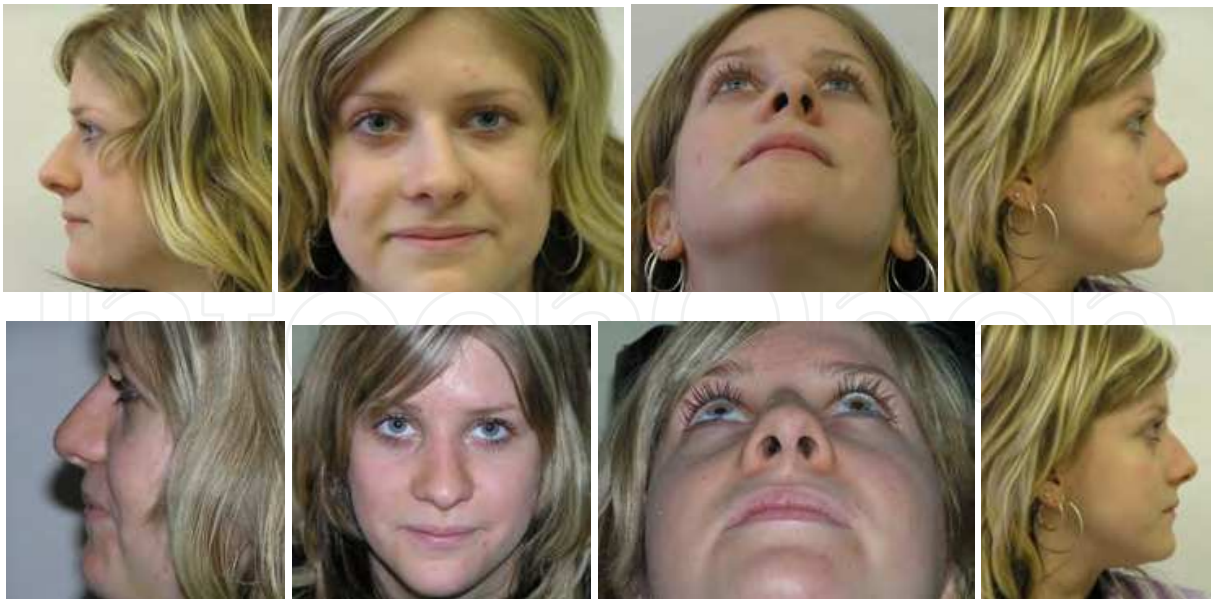

Fig. 16. Patient with external nasal deviation to the left side (upper pictures). After wedge resection on her right side, osteotomies and remodeling of nose to the medial plane (lower pictures)

4. Osteotomy in wide nasal vault

Medial and lateral osteotomy is insufficient in the case of wide and flat nasal dorsum. Nasal bones create a wide arc even after their separation from septum and maxilla (figure 17) Thorough mobilisation would therefore not allow to narrow nasal vault in desired extend. It is necessary to think of it before and to perform multiple osteotomy. First is medial, then intermedial a finally lateral osteotomy. Originally wide nasal vault will divide to several bony fragments. They are elevated and narrowed in desirable shape.

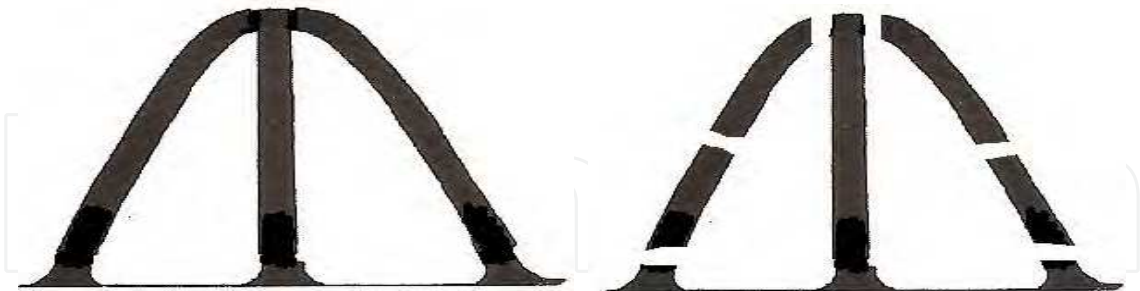


Fig. 17. Wide bony pyramid in axial plane. Medial, intermedial and lateral osteotomies are performed.

5. Correction of external saddle nose deformity

Severe saddle nose deformity of the external nose results after strong blow directly to the nasal dorsum. The nasal bones are smashed and moved in a lateral and dorsal direction. Viewed from the front, the nose is short, wide and unsightly because the nasal tip is retracted upwards. From a lateral view, the loss of the dorsal nasal vault becomes evident. The outcome of an injury to the nasal septum may be luxation or cartilage aposition with

manifold spines and crests. In a mild saddle nose deformity, a cartilaginous or osseous graft is inserted into a prepared subcutaneous tunnel and this is sufficient to straighten the line from nasion to nasal tip. There is no need to use the open approach. On the contrary, if it is necessary to replace the nasal dorsum and columella and at the same time to correct the alar cartilages and the nasal tip, or alternatively the nasal septum with lateral cartilages, then the open approach and reconstruction of the whole nasal skeleton under direct vision is more convenient.

After external nasal skin withdrawal, the nasal septum is reconstructed using some of the techniques described previously. Then a quadruple osteotomy is done. Care is taken to keep the osteotome lateral enough because the nasal bones are usually wider and flatter in this type of deformity. Mobile bones should be elevated. Usually a sufficient nasal dorsal shape is not achieved using this procedure and it is therefore necessary to apply an autograft. It is more advantageous to use bone rather than cartilage.

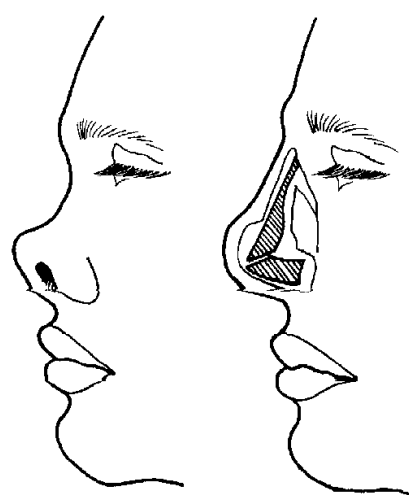


Fig. 18. Basic principle of saddle nose deformity correction using an “L”-shaped osseal or cartilaginous graft

5.1 Technique of harvesting an osseal graft

A bony graft is harvested from the pelvic bone shovel, from the area of the anterior superior iliac spine. Its anterior margin is accessed through an approximately 5cm long cut above the pelvic bone crest (figure 19). It is the case in which a rotary saw is used. Shorter incision is performed if the bony graft is removed by a chisel.

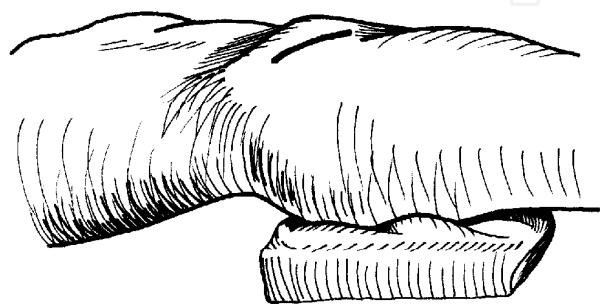


Fig. 19. Bony graft harvesting

The periosteum is torn and the bone surface is exposed. Medially, there are muscular tendons, therefore only the necessary bone area is disclosed. Resection lines are denoted by coloured pencil and from both sides the margins are partially cut using a sharp chisel, then the graft is cut off from top to bottom using a wide chisel. After harvesting the graft, bleeding from the donor site is controlled by bony wax or gel foam. Preserved periosteum is sutured in midplane. In greater part of patients the postoperative pain is severe. Postoperative scar may cause an esthetic problem mainly in young women, therefore in such patient we predominantly use a cartilaginous graft from auricle

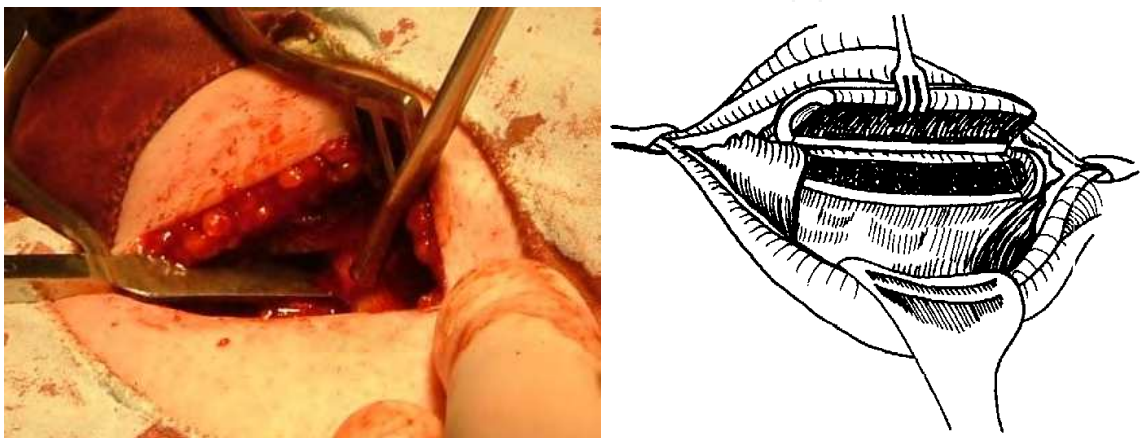


Fig. 20. Resection of bone of necessary size

The "L"-shaped graft is prepared from harvested bone material. After insertion into the prepared setting, both pieces of bone graft are sutured together in the correct angle, thereby ensuring a stable position. (figures 21 - 22)

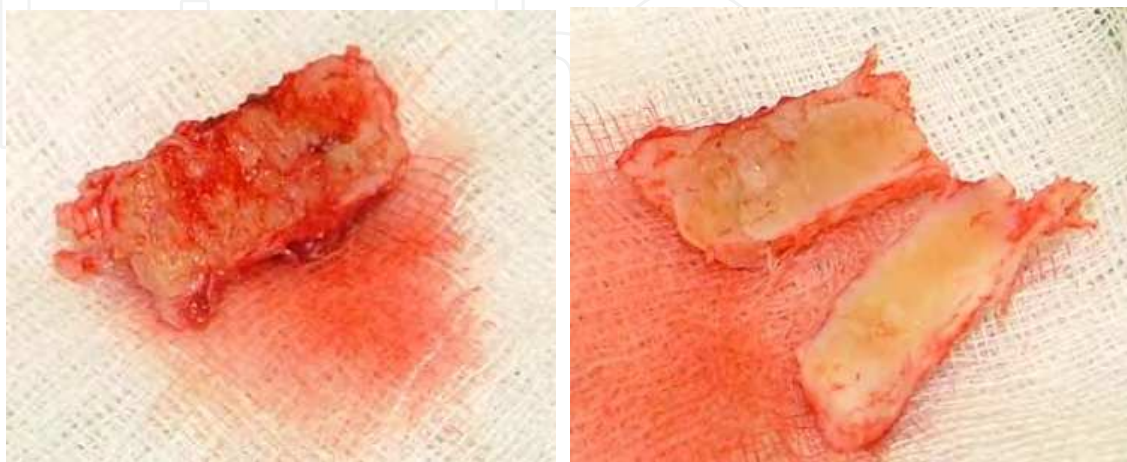

Fig. 21. Bony graft divided in two pieces



Fig. 22. Cantilever „L” shaped bony graft prepared for insertion

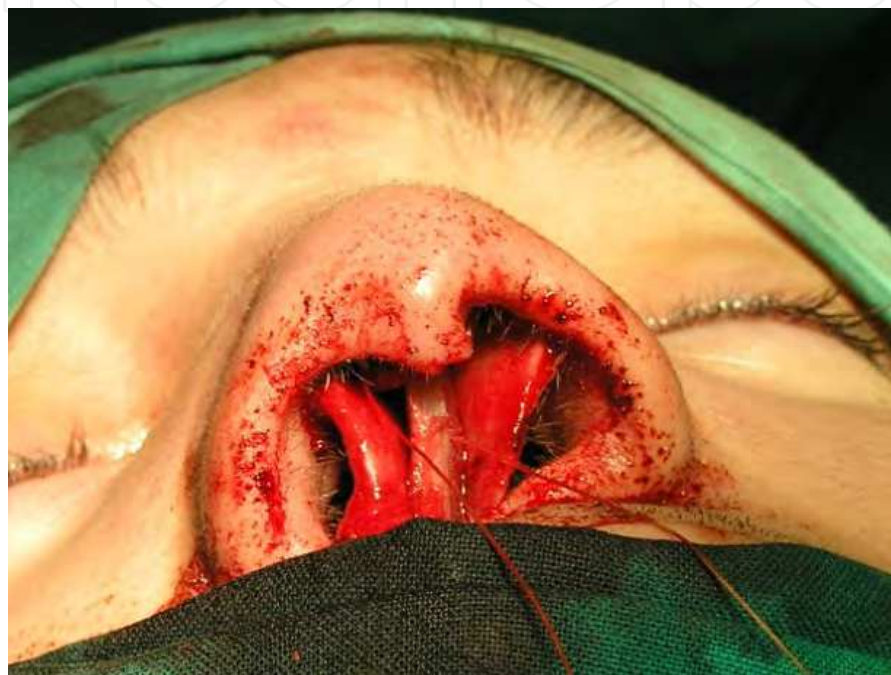

Fig. 23. Graft inserted in the nose

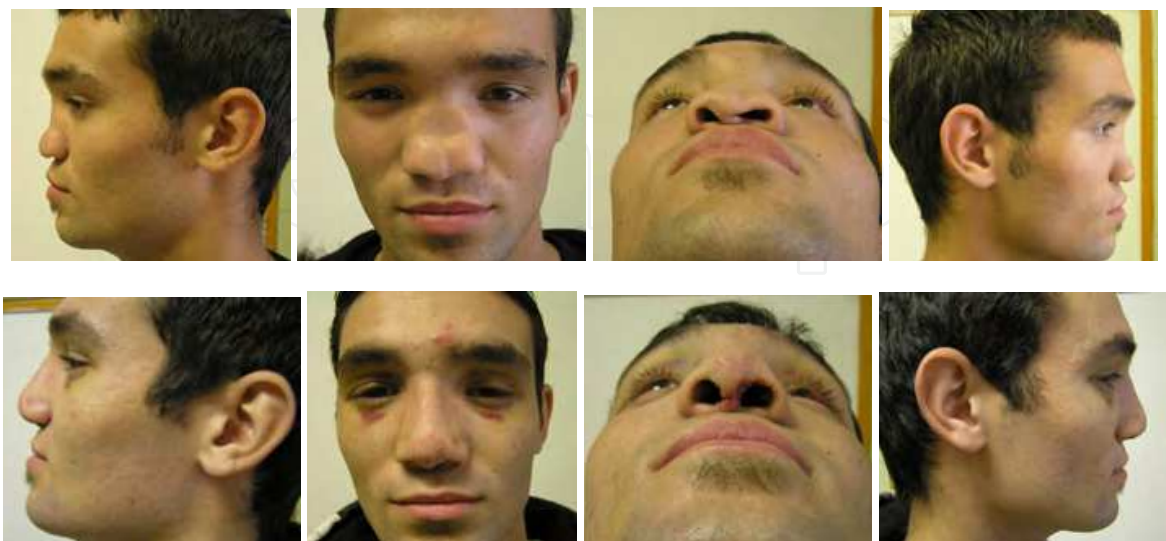

Fig. 24. Patient with saddle nose deformity (upper pictures). One week after the operation (lower pictures)

5.2 Technique of harvesting a chondral graft

A chondral graft is harvested from the cartilage by which ribs are joined to the sternum. In men, the skin incision and cartilage excision is usually localized between the sternal and parasternal line. In women, it is more convenient to plan the incision between the parasternal and mamillar lines at the lower border of the breast because the scar is then less visible.

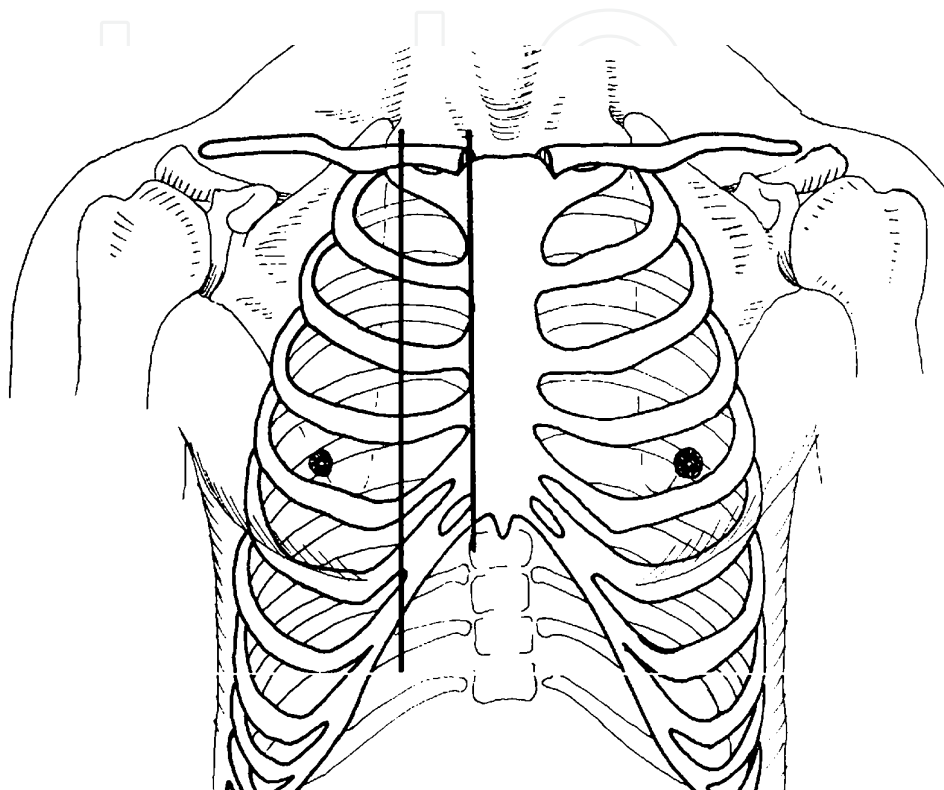


Fig. 25. Site of chondral graft harvesting

The graft can be taken from the fifth rib in cases where a combined chondro-osseous block is needed. A larger amount of cartilage occurs near the seventh and eighth ribs where the ribs are connected to one another and the cartilage is wider. An oblique skin incision about 4cm long is led downwards along the lower border of the sternal junction of the rib. The incision is started slightly laterally from the sternal border. The blunt preparation of muscles is recommended. Intercostal nerves and vessels are preserved. Preparation has to be very careful in order not to damage chest wall with pleura. In dicky situation the wound is filled with sterile saline and observed if there occur gas bubbles. Surgeon must be prepared to solve such complication as pleural tear and pneumotorax.

After uncovering the surface, the rib is prepared in its entire thickness. Rib cartilage in its entire thickness or its inferior part in accordance to actual need is resected. Sometimes in young people with enough soft cartilage just the superficial part of the rib can be harvested. It is cut by a knife parallel with its longitudinal axis.

If a straight graft is needed, only the central part of the cartilage is required. Shortly after dissection, the peripheral layer usually rolls to the outside. In young people the cartilage is soft and can be easily trimmed, creating a graft of the desired shape and size.

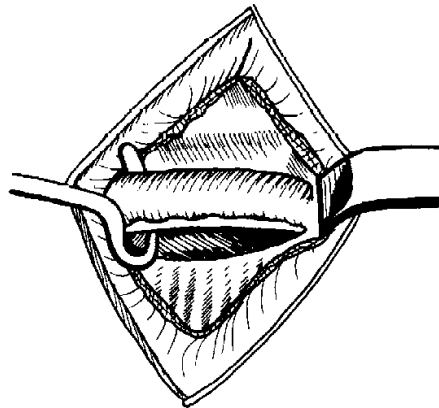


Fig. 26. Rib cartilage prepared for resection

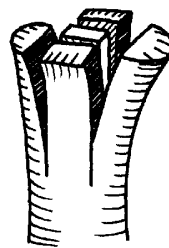


Fig. 27. After dissection the cartilage margins usually roll. The central column is more stable in shape.




Fig. 28. Middle cartilaginous plate is resected from the rib

If a wider graft is needed, for example for septal cartilage replacement, it can be taken from the central part of a rib. In elderly people this cartilage is usually ossified and modelling is therefore more difficult.

More often in the correction of saddle nose deformity, bony material taken from the periosteum is used. The long edge of the "L"-shaped graft is inserted into the nasal dorsum in order to be in contact with the nasal bones. Thereby its nutrition and proper healing is ensured. The short edge is inserted between the medial crura of the alar cartilages to strut the nasal tip. Both edges are fixed by suture. Other parts of the nasal skeleton are corrected by means of the above-mentioned methods. A cartilaginous graft is rarely used if the patient does not agree to extirpation of an osseous autograft from the pelvic bone.

Reparation of saddle nose deformity is among the most troublesome procedures in esthetic rhinosurgery. The choice of an optimal reparative method is based mostly on the surgeon's own experience. Authors dealing with saddle nose deformity correction (4 - 7) consent to use predominantly autogenous materials. Autotransplant is physiologic, it heals easily and is therefore safe. It can be stored for long enough periods using appropriate methods . Homogenous material can be rapidly absorbed or rejected, which was also observed in our

patients. Hellmich (8) prefers using homogenous rib cartilage stored in merthiolate. The availability and unlimited amount of well-formed material are the advantages of this method. Using any foreign material (plastic, metal and others) in the nose is risky, because rejection of such a graft may happen even after many years (9). In spite of that, some authors try to find suitable synthetic material shapable and ready for use at any moment (10,11).

Effaced cartilaginous autograft can be used to fill in any drop in the nasal dorsum. One must be gentle when working with this cartilage in order not to crush the whole piece or to destroy its structure. Bujia (12) found that after crushing the cartilage, only 10 to 30% of the chondrocytes survived. Such material can be implanted but tends to be reabsorbed. In cutting the cartilage using a sharp scalpel, the majority of the chondrocytes survive and tend to proliferate. Such cartilage is more suitable as soft tissue support against pressure or traction forces. Haas (13) warns of the possibility of rib cartilage torsion as a cause of secondary nasal deformity even after long periods. It is important to harvest the graft properly and then to trim it until a smooth surface is achieved. In implanting homogenous cartilage, more extensive reabsorption is assumed than in implanting autogenous. The advantages and disadvantages of "L"-shaped cartilage grafts were described by Fomon et al. (14) and Musebeck (15).

Daniel (16) uses an osteocartilaginous segment of a rib as a support in rhinoplasty. The bony part of the rib serves to create a new dorsal nasal contour, whereas the cartilaginous part struts the columella and elevates nasal tip projection. These segments are joined together using microscrews.

An autogenous bony graft is suitable for elevating nasal dorsal projection. It is most frequently harvested from the pelvic bone, rarely from the calva (17, 18). Takato et al. (19) prefer the qualities of an "L"-shaped bony graft. After healing, a narrow nose with elevated tip and columella projection results.

In their work from 1995, Takato and associates explored the survival rate of a bony implant inserted into the nose. The implant was placed subperiostally in order to be in direct contact with the nasal bones. In a group of 14 patients, they found that the graft diminished slightly and its margins became curved during the first 2-3 months in the new environment. After six months there were no significant macroscopic changes in the graft. Burian (9) stated that, with the exception of nasal bones and nasal septal bones, every implanted autogenous bone undergoes remodeling of its structure. After some time it is remodeled and replaced by new bony tissue. In correcting saddle nose deformity, the author emphasises direct contact of implanted bone with original nasal bones. If the implanted bone is not in this close contact, it can be completely absorbed later on. The time interval depends on the graft's structure. Compact bone may be absorbed after several years, spongy usually sooner.

In our first group of 10 patients, with the exception of one case, an autogenous bone or cartilage graft was used in saddle nose deformity correction. The patients were followed up for one to six years post-operation. In all cases, the autogenous material healed and no complications of graft rejection were observed. In one patient, after the implantation of fresh rib cartilage, elevation of the upper margin in the nasal root region became evident. Some patients had marked combined nasal deformity after an injury and therefore the esthetic result following septorhinoplasty was not as perfect as they had anticipated. We are aware that repeated surgical procedure on a previously repaired nose involves some risk because it may endanger the original graft and cause new scar formation. This is why no further correction was performed in these cases.

5.3 Postoperative care

Comprehensive and adequate postoperative care is as important as proper operative technique. This includes external nasal fixation, dressing and internal nasal fixation, and general and local drug therapy during the postoperative period.

6. External nasal fixation

At the end of surgery, after shaping and repositioning the nose into the medial plane, it should be properly fixed. External fixation is achieved with taping, plaster of Paris, metal or plastic splints, stomatologic thermoplastic material, etc. We usually apply modified plaster splints attached to the forehead, which better fix the nose in the middle plane. Nasal skin is first covered using Leukopor (paper tape) by which gives a proportional pressure of skin to subcutis (figure 29). Then a plaster splint accomodated to nasal proportions is applied and held in place by finger pressure until it dries (figure 30,). This part of fixation is very important. If back pressure is not created, the plaster splint will extend and the nasal root will remain wide. Finally, the plaster splint is affixed using Leukoplast (plastic tape) to the cheek and forehead. The splint is changed when postoperative swelling subsides, usually three to five days after surgery. The overall period of external fixation is about ten days. In cases in which an osteotomy was not performed, a smaller plaster splint covering only the external nose is applied. It creates back pressure on the internal dressing and helps to maintain the desired nasal shape in the early postoperative period. Such a splint is left in place for a few days. In patients who for any reason tolerate external splinting badly, a minimum period of 7 days of fixation is recommended.

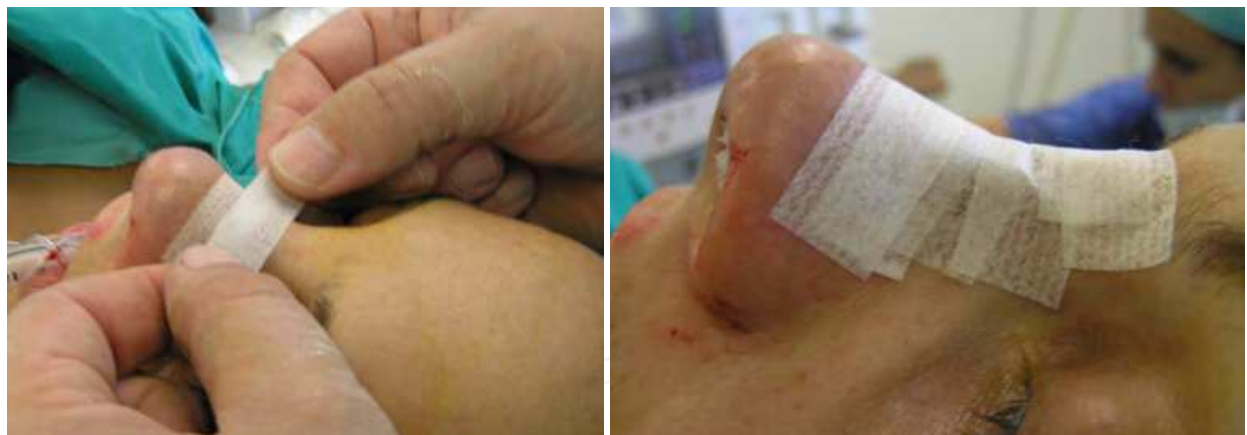

Fig. 29. Nasal dorsum is covered with paper tape

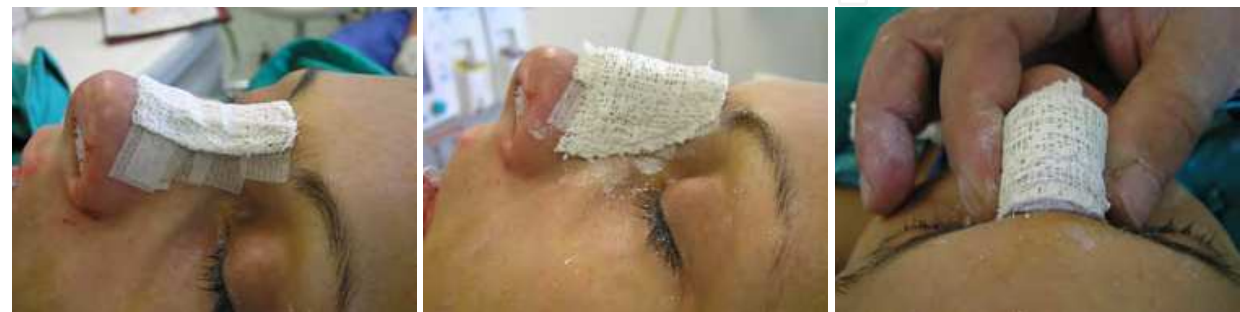

Fig. 30. Modelation of plaster splint

7. Tamponade, internal nasal splints

Nasal cavity packing with vaseline dressing gauze is used after each septorhinoplasty for a postoperative period of 24 hours. Tamponade lessens postoperative bleeding, development of a synechia or hematoma, and fixes and holds together intranasal incision margins. The patient tolerates tamponade quite well after surgery using general anesthesia until the next day. After removing the tamponade, the nose is left free.

Internal splints are used after any operation for septal perforation. Original splints from the firm XOMED or thick polyethylene foil is arranged according to the size of the nasal cavity and is placed on both sides of the nasal septum. The splints are fixed by transseptal suture. Until the first postoperative day, a light nasal packing is added. Internal splints are removed after 7 days at the earliest. In cases in which bilateral subperichondrial septal tunnels were created, it is not recommended to apply only internal splints without tamponade. An intranasal splint alone does not avoid the formation of a hematoma nor does it improve nasal ventilation in the early postoperative period. Certain improvement of nasal ventilation, and thereby the patient's comfort, can be achieved by inserting an intranasal plastic splint with a tube for breathing. These splints are expensive but they can be replaced for example by a thin intubation tube.

In our opinion, for proper septal fixation and hemostasis in the early postoperative period, it is necessary to put a vaseline or other type of nasal packing into the nasal cavity. Tamponade must be compact enough in order not to shift into the nasopharynx or to be aspirated. Of course, any foreign body in the nasal cavity causes discomfort. The patient feels pressure in his nose, unpleasant mucosal flow, must breathe through his mouth and has a sense of dry mouth, etc.. Serpell and associates (20) examined the influence of nasal packing on blood oxygen saturation during sleep. They discovered that nasal packing does not have a fundamental influence on oxygen saturation in otherwise healthy individuals. Nevertheless, in patients with ventilation nasal tubes better objective and subjective results were observed.

After septoplasty in which a synechia between the nasal septum and the lateral nasal wall is split, a soft polyethylene foil covering the wound surface is inserted. The foil is fixed by septal suture and left in place for 14 days.

8. Local and general therapy in the postoperative period

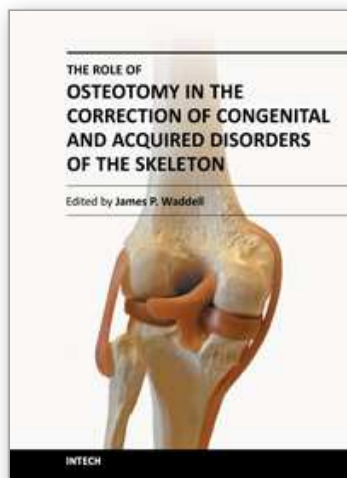
Standard local therapy after septorhinoplasty includes intranasal antibiotic ointment and paraffin oil. Long lasting swelling mainly at the nasal tip is managed by skin massage with nutritive cream. Local administration of corticosteroids by injection in the case of subcutaneous scarring after surgery is evaluated very carefully. After initial improvement, repeated application may cause subsequent weakening or even atrophy of subcutaneous tissues, with unfavourable consequences.

General antibiotic therapy is indicated in patients after complicated nasal surgery with the open approach and with autotransplant insertion.

9. References

- [1] Huizing, E.H., De Groot, J.A.M.: Techniques in functional corrective nasal surgery. Utrecht, Printing Office University Hospital 1995, 33 s.

- [2] Orak, F. a spol.: Reversed roof graft for the severely deviated nose. *Aesthetic Plast. Surg.*, 19, 1995, č. 1, s. 31–36.
- [3] Mommaerts, M.Y. et al.: Rhinoplasty with nasal bone disarticulation to deepen the nasofrontal groove. Experimental and clinical results. *J. Craniomaxillofac. Surg.*, 23, 1995, č. 2, s. 109–114.
- [4] Ortiz-Monasterio, F.: *Rhinoplasty*. Philadelphia, W.B. Saunders 1994, 291 s.
- [5] Candiani, P. a spol.: Anatomical reconstruction versus camouflage of the inferior two thirds of the nasal septum. *Ann. Plast. Surg.*, 34, 1995, č. 6, s. 625–630.
- [6] Johnson, C.M., Toriumi, D.M.: *Open structure rhinoplasty*, W.B. Saunders Company, Philadelphia, 1990, 516 s.
- [7] Nicolle, F.V.: *Aesthetic rhinoplasty*. London, W.B. Saunders 1996, 126 s.
- [8] Hellmich, S.: Der Einfluss unterschiedlicher Konservierungsmethoden auf die biologische Qualität von Knorpelimplantaten. *Laryng Rhinol Otol*, 53, 1974, 10, p.711-717
- [9] Burian, F.: *Plastická chirurgie*. Praha, Nakladatelství Československé akademie věd 1959, 101 s.
- [10] Owsley, T.G., Taylor, C.O.: The use of Gore-Tex for nasal augmentation, a retrospective analysis of 105 patients. *Plast. Reconstr. Surg.*, 94, 1994, č. 2, p. 241–248.
- [11] Lindsey, WH., Ogle, RS., Morgan, RF., Cantrell, RW., Sweeney, TM.: Nasal reconstruction using an osteoconductive collagen matrix. *Arch Otolaryngol Head Neck Surg*, 122, 1996, 1, p.37-40
- [12] Bujia, J.: Determination of the viability of crushed cartilage grafts: clinical implications for wound healing in nasal surgery. *Ann. Plast. Surg.*, 32, 1994, č. 3, s. 261–265.
- [13] Haas, E.: Materialbedingte Gefahren bei der Sattelnasenkorektur. *Laryngol. Rhinol. Otol.*, 48, 1969, č. 1, s. 28–34.
- [14] Fomon, S. a spol.: Saddle nose and the "L" shaped graft. *Arch. Otolaryng.*, 71, 1960, s. 932–940.
- [15] Musebeck, K.: Nachteile der Winkelspäne bei der Sattelnasenkorrektur. *Laryngol. Rhinol. Otol.*, 48, 1969, č. 1, s. 34–37.
- [16] Daniel, RK.: Rhinoplasty and rib grafts: evolving a flexible operative technique. *Plast Reconstr Surg*, 94, 1994, 5, p. 597-609
- [17] Citardi, MJ., Friedman, CD.: Nonvascularized autogenous bone grafts for craniofacial skeletal augmentation and replacement. *Otolaryngol Clin North Am*, 27, 1994, p 894–910
- [18] Frodel, JL.: Management of the nasal dorsum in central facial injuries. Indications for calvarial bone grafting. *Arch Otolaryngol Head Neck Surg.*, 121, 1995, 3, p 307 – 12
- [19] Takato, T., Yonehara, Y, Mori, Y, Susami, T.: Use of cantilever iliac bone grafts for reconstruction of cleft lip-associated nasal deformities. *J Oral Maxillofac Surg*, 53, 1995, 7, p.757-62
- [20] Serpell, MG., Padgham, N., McQueen, F.M., Block, R., Thomson, M.: The influence of nasal obstruction and its relief on oxygen saturation during sleep at the early postoperative period. *Anesthesia*, 49, 1994, 6, p.538-540



The Role of Osteotomy in the Correction of Congenital and Acquired Disorders of the Skeleton

Edited by Prof. James Waddell

ISBN 978-953-51-0495-7

Hard cover, 294 pages

Publisher InTech

Published online 11, April, 2012

Published in print edition April, 2012

This book demonstrates specific osteotomy techniques from the skull to the hallux. The role of osteotomy in the correction of deformity is under appreciated in part because of the ubiquitous nature of joint replacement surgery. It should be remembered, however, that osteotomy has a role to play in the correction of deformity in the growing child, the active young adult, and patients of any age with post-traumatic deformity limiting function and enjoyment of life. In this text we bring you a number of papers defining specific problems for which osteotomy is found to be an effective and lasting solution. I hope you find it useful.

How to reference

In order to correctly reference this scholarly work, feel free to copy and paste the following:

Pavel Dolezal (2012). Surgery of the Bony and Cartilaginous Vault in Rhinoplasty, The Role of Osteotomy in the Correction of Congenital and Acquired Disorders of the Skeleton, Prof. James Waddell (Ed.), ISBN: 978-953-51-0495-7, InTech, Available from: <http://www.intechopen.com/books/the-role-of-osteotomy-in-the-correction-of-congenital-and-acquired-disorders-of-the-skeleton/surgery-of-the-bony-and-cartilaginous-vault>

INTECH
open science | open minds

InTech Europe

University Campus STeP Ri
Slavka Krautzeka 83/A
51000 Rijeka, Croatia
Phone: +385 (51) 770 447
Fax: +385 (51) 686 166
www.intechopen.com

InTech China

Unit 405, Office Block, Hotel Equatorial Shanghai
No.65, Yan An Road (West), Shanghai, 200040, China
中国上海市延安西路65号上海国际贵都大饭店办公楼405单元
Phone: +86-21-62489820
Fax: +86-21-62489821

© 2012 The Author(s). Licensee IntechOpen. This is an open access article distributed under the terms of the [Creative Commons Attribution 3.0 License](https://creativecommons.org/licenses/by/3.0/), which permits unrestricted use, distribution, and reproduction in any medium, provided the original work is properly cited.

IntechOpen

IntechOpen