

# We are IntechOpen, the world's leading publisher of Open Access books Built by scientists, for scientists

6,900

Open access books available

185,000

International authors and editors

200M

Downloads

Our authors are among the

154

Countries delivered to

TOP 1%

most cited scientists

12.2%

Contributors from top 500 universities



WEB OF SCIENCE™

Selection of our books indexed in the Book Citation Index  
in Web of Science™ Core Collection (BKCI)

Interested in publishing with us?  
Contact [book.department@intechopen.com](mailto:book.department@intechopen.com)

Numbers displayed above are based on latest data collected.  
For more information visit [www.intechopen.com](http://www.intechopen.com)



## Echinococcosis

Mesut Akarsu, Funda Ugur Kantar and Aytaç Gülcü  
Dokuz Eylul University, Faculty of Medicine,  
Turkey

### 1. Introduction

Echinococcosis is a parasitic zoonosis caused by adult or larval stages of cestodes belonging to the genus *Echinococcus* (family Taeniidae). There are two major species of echinococcosis which are *Echinococcus granulosus* and *Echinococcus multilocularis*, which cause cystic echinococcosis (CE) and alveolar echinococcosis (AE), respectively. In endemic areas, the diseases are important for both medical and social aspects. CE and AE are both serious diseases, the latter especially so, with a high fatality rate and poor prognosis if careful clinical management is not carried out (Zhang&McManus,2006).

The annual incidence of CE ranges from <1 to 200 per 100,000 inhabitants, whereas the annual incidence of AE ranges from 0.03 to 1.2 per 100,000. It may be significantly higher in certain endemic areas. The global human burden of CE averages 285,000 disability-adjusted life years (DALYs) and causes an annual economic loss of US \$194,000,000. The mortality is also high, especially in untreated cases. The mortality, which is higher in AE than CE, reaches about %90 in untreated or inadequately treated cases of AE (Brunetti, 2010).

In this chapter, we evaluated this complex parasitic disease, which is a challenge for the physicians in both diagnostic and therapeutic aspects. We also mentioned about the social and economic burden of the disease and investigated the control and preventive measures.

### 2. Epidemiology

#### 2.1 Epidemiology of *E. granulosus*

CE has a serious impact on human health and livestock production in endemic areas such as in South and Central America, the Middle East, some sub-Saharan African countries, China, and the former Soviet Union. The overall prevalence of echinococcal infection is not clear because of the lack of systemic population surveys.

In some European countries or regions, the annual incidences of hospital cases of human CE vary between 1 and 8 per 100,000 population. High incidence rates or prevalences have also been recorded from countries in northern and eastern Africa (prevalences of 3%) and South America (for example; an annual incidence of 9.2 per 100,000 population in Uruguay in 1995).(Eckert&Deplazes,2004)

Epidemiological studies in endemic villages of Peru have shown human infection prevalences ranging from 5.5% to 9.1%, with the prevalence of CE in sheep and cattle as high as 77% and 68%, respectively (Moro et al. 2011).

A recent survey in Spain showed human CE annual incidence rates in the range of 1.1 to 3.4 cases per 10<sup>5</sup> person-years, in combination with ovine or bovine CE prevalence proportions of up to 23%. (Bernner et al. 2010)

In China where CE is highly endemic, farmers (76%) were the main group of echinococcosis patients, followed by students (12.4%), workers including those self employed (5.2%), cadres (4.8%) and others (2%). Females outnumbered male patients with a ratio of 1.38. For 2000, the population ratio showed a significantly higher morbidity in females for echinococcosis (Yang et al. 2010).

Cystic echinococcosis (CE) is an endemic zoonosis in Iran particularly in rural regions. Harandi et al prepared a study to determine the prevalence of CE among rural communities in Kerman using ultrasonography (US) and serology in southeastern Iran. Two hydatid cases (0.2%) were detected by ultrasound. Serological results showed 7.3% seropositivity, and females (8.3%) were significantly more positive than males (2.1%). There were significant difference between CE seropositivity and sex, age and occupation. Dog ownership does not appear to be a significant risk factor for CE in the region. The serological study showed that many people, especially women, had been exposed to *Echinococcus* eggs and had seroconverted but were not infected (Harandi et al, 2011).

Greece is another country where national surveillance programmes are running for Cystic echinococcosis. The prevalence of human hydatidosis, declined from an annual incidence of 14.8 per 100,000 inhabitants during 1967-1971 to 0.3 in 2008. Late surveys revealed that in Greece the prevalence of echinococcosis was 23-39.2% for sheep, 7.6-14.7% for goats, 0% in cattle and 0.6% in pigs (Sotirakis & Chaligiannis, 2010).

The prevalence of CE in sheep reported to European Food Safety Authority (EFSA) in 2008 is 4.3% in Bulgaria, 11.3% in Italy, 6.7% in Poland and 5% in Romania. High levels of sheep CE were also reported in Portugal and Greece in 2007 (9.4% and 3.9%, respectively) (<http://www.efsa.europa.eu/en/scdocs/scdoc/1496.htm>)

Mastin et al. evaluated the prevalence of canine echinococcosis by using coproantigen in mid/south Wales. The coproantigen prevalence identified in dogs was 10.6%, with 20.6% of farms containing at least one coproantigen-positive dog (Mastin et al, 2011).

## 2.2 Epidemiology of *E. multilocularis*

Although generally rare, AE deserves public health attention due to the high fatality rate of untreated patients and the high costs of treatment. *Echinococcus multilocularis* occurs across the Northern Hemisphere, in parts of central Europe, Russia, western China, areas of North America, and Northern Africa. In Europe, the endemic area of *Echinococcus multilocularis* covers parts of the western continent (France, Benelux States) and all countries of central Europe, including the Baltic States. Furthermore, foci exist in Denmark and on the Norwegian Svalbard Island. In Eastern Europe, Russia belongs to the endemic area, and the parasite has also been found in Byelorussia, Ukraine, Moldavia, and Armenia (Jenkins et al, 2005).

Ultrasonographic and immunodiagnostic surveys (1991 to 1997) have revealed a very high prevalence within a focus in China, where 135 (4%) of 3,331 people examined had documented AE (Craig et al,2000). A recent study from Western China including the Tibetan Plateau reported total prevalence rate of 8.1% (3.9% for alveolar echinococcosis and 4.2% for cystic echinococcosis) which is the highest level for echinococcosis ever reported in the world (Li et al,2010).

### 3. Pathogenesis

#### 3.1 Pathogenesis of *E. granulosus*

The hydatid cyst has three layers:

1. The outer pericyst is a dense and fibrous zone and composed of modified host cells. It is the protective layer.
2. The middle is the laminated membrane. It is acellular and allows the passage of nutrients.
3. The inner layer is the germinative layer which gives rise to the hydatid fluid and small secondary cysts (brood capsules) which bud internally from this layer. Fragmentation of the germinative layer and brood capsules gives rise to daughter cysts. These may develop within the original cyst or separately.

The middle laminated membrane and the germinal layer form the true wall of the cyst, usually referred to as the endocyst, although the acellular laminated membrane is occasionally referred to as the ectocyst (Pedrosa et al,2000). Daughter vesicles (brood capsules) are small spheres that contain the protoscolices and are formed from rests of the germinal layer. 10-12 months after infection, protoscolices are produced in broad capsules. Cysts containing protoscolices are fertile and can produce daughter cysts, whereas cysts without protoscolices are sterile. Before becoming daughter cysts, these daughter vesicles are attached by a pedicle to the germinal layer of the mother cyst. At gross examination, the vesicles resemble a bunch of grapes. Daughter cysts may grow through the wall of the mother cyst, particularly in bone disease (Pedrosa et al,2000)

The pattern of *E. granulosus* infection varies in different geographic regions and among different populations. Among patients in Turkana, Kenya, for example, many cysts are large, unilocular and fertile. In contrast, cysts among individual in the northern hemisphere tend to be calcified, small, and infertile. The time between infection and diagnosis, intraspecies variation of the parasite and host differences (immunologic, genetic and/or nutritional) can influence these variations (Eckert&Deplazes,2004).

#### 3.2 Pathogenesis of *E. multilocularis*

*E. multilocularis* can cause severe infection in humans. The metacestode tissue invades and destroys tissue, extends beyond organ borders into adjacent structures, and can metastasize to distant sites. In macroscopic sections of the human liver, the metacestodes of *E. multilocularis* exhibit an alveolar spongy structure composed of numerous irregular vesicles with diameters between less than 1 and 20 mm. There is no sharp demarcation from surrounding organ tissue. The vesicles are embedded in a very dense and hard fibrous stroma so, fibrosis and in some cases central necrosis are hallmarks of alveolar

echinococcosis. The lack of limiting membrane allows exogenous budding, proliferation and infiltration into adjacent tissues, resulting in necrosis of surrounding host tissue. (Ammann& Eckert,1996; Kern 2010).

In the human host, there may be adjacent organ metastases (gall bladder, pancreas, diaphragm,etc.) or spread to distant localizations (lungs, bones, muscles, skin, brain, spine, etc.) by haematogenous or lymphatic route. The morphological structure of the *E. multilocularis* metacestode in other organs is essentially similar to that in the liver.

Microscopically, the cysts are composed of a thin laminated layer with minimal or no germinative layer. Brood capsules and protoscolices form in less than 10 percent of these cysts. The metacestode of *E. multilocularis* proliferate either by exogeneous budding and separation of smaller daughter vesicles from larger old ones, or by endogenous formation of small daughter vesicles originating from the germinal layer of older large vesicles (Hemphill et al 2010). Metacestodes can die spontaneously, followed by degeneration (Rausch et al, 1987).

#### 4. Genetic variation and immunity

*E. granulosus* shows genetic variations which are important for the formation of different strains. There are 10 distinct genetic types of *E. Granulosus* ( genotypes G1-10 ) with different biological properties important for life cycle patterns, host specificity, development rate, antigenicity, transmission dynamics, sensitivity to chemotherapeutic agents and pathology with important implications for the design and development of vaccines, diagnostic reagents and drugs (Zhang&McManus,2006).On the other hand, *E. multilocularis* lacks this property and exhibit limited genetic variation.

Echinococcosis is mostly asymptomatic for a long period after infection but hosts' immune response is continuous.

##### 4.1 Immune response against Cystic Echinococcosis (CE)

The immune response against early *E. granulosus* infection begins after the oncosphere locates a target organ and forms hydatid cyst that causes infiltration of macrophages and eosinophil cells, and low-level polarized Th1 responses (Zhang&McManus,2006). This generally does not result in a severe inflammatory response and aged cysts tend to become surrounded by a fibrous layer that separates the laminated layer from host tissue. Antibody responses are also weak and are, normally, undetectable in the early two to three weeks following infection ( Zhang et al, 2003).

As the parasite grows, it produces significant quantities of antigens that modulate the immune responses which include polarized Th2 responses, balanced with Th1 responses. Elevation of IL-4, IL-5, IL-6 and IL-10 also has been recorded in most hydatid patients where cytokine levels have been measured. In addition, IgG, especially IgG1 and IgG4, IgE and IgM are elevated as the cyst grows and becomes established. When a cyst dies naturally, is killed by chemotherapy treatment or is removed by surgery, Th2 responses drop rapidly, and Th1 responses become dominant. This can be interpreted as Th1 lymphocytes contribute significantly to the inactive stage of hydatid disease, with Th2 lymphocytes being more important in the active and transitional stages. IgG levels can be maintained in



humans for several years after the cyst has been removed. In case of relaps, the Th2 responses regenerate very quickly. (Zhang&McManus,2006). These patients have high levels of IgE and IgG4, increased levels of IL-5, IL4, and IL-10, and low levels of IFN- $\gamma$  compared to patients with a primary infection (Rigano et al,1995a; Rigano et al,1996). Patients with a primary infection have higher levels of IL-2, IFN- $\gamma$ , and IL-5. The high level of IL-5 is in agreement with the high levels of IgG4 and IgE observed (Rigano et al,1996). There is a significant correlation between IgE and IgG4 production in sera from patients with hydatid disease and a trend toward increased IL-4 and IL-10 levels in patients who are high producers of IgE and IgG4 ( Rigano,1995b; Zang et al, 2003) Serum IL-4 may be a useful marker for the follow up of patients with CE (Rigano et al, 1999).

Eosinophilis and high levels of IgE are the common consequences of infection by helminths (Bell,1996; Capron,1992). They may be important as a defense against the tissue stages of parasites that are too large to be phagocytosed (Haynes,1990). IgE-dependent mast cell reaction can be involved both in localization of eosinophils near the parasite and enhancing their antiparasitic functions (Bell,1996). Eosinophils are less phagocytic than neutrophils, but, like neutrophils, they can kill larval stages of parasites such as Echinococcus. Their activities are also enhanced by cytokines (Rainbird et al,1998; Meeusen&Balic, 2000).

#### 4.2 Immune response against Alveolar Echinococcosis (AE)

Human AE is a chronic and often fatal disease which is characterized by slowly developing cysts, mainly in the liver. It destroys the liver parenchyma, bile ducts and blood vessels forming necrotic cavities, causes biliary obstruction and portal hypertension. Like CE infection, Th1 responses predominate in the early stages of AE infection, with the immune response switching to a Th2 polarized profile in later progression (Zhang &McManus ,2006; Wei et al, 2004). Pathological examination of AE infection shows large granulomatous infiltrate surrounding the parasitic lesions (Vuitton et al., 1989; Ricard-Blum et al., 1996; Grenard et al., 2001).The cells involved in the formation of the periparasitic granuloma are mainly macrophages, myofibroblasts and T lymphocytes. In patients with abortive or dead lesions, a large number of CD4 T lymphocytes are present, whereas patients with active metacestodes display a significant increase in activation of predominantly CD8 T cells (Manfras et al., 2002), indicating that CD4 T cells play a role in the killing mechanism. In the absence of T cells, the cellular immune response to infection decreases that will disturb the hepatic granuloma formation. Today it is known that CD4 T cells play in limiting *E. multilocularis* proliferation, while CD8 T and B cells appeared to play a minor role in the control of parasite growth. (Dai et al 2004)

Significantly higher levels of IL-10 and IL-5 have been found in AE patients than in controls (Wellingshausen et al,1999; Sturn et al,1995; Riley et al,1985) . In contrast, IL-4 was measurable in only a minority of patients and controls. IL-12 levels were comparable between AE patients and controls and showed a similar distribution pattern to IL-10 with regard to disease progression (Zang et al,2003) AE patients experiencing a relapse of the disease have a tendency to increased production of IL-5 but lower IFN- $\gamma$  production accompanied by significantly higher levels of IgE and IgG4 compared to patients with a primary infection (Godot et al,1997).

One of the most important issue about *E. multilocularis* is the interplay between the immunity of the host and the parasite. The disease spectrum is clearly dependent on the

genetic background of the host as well as on acquired disturbances of Th1-related immunity. The laminated layer of the metacestode, and especially its carbohydrate components, plays a major role in tolerance induction. Th2-type and anti-inflammatory cytokines, IL-10 and TGF-beta, as well as nitric oxide, are involved in the maintenance of tolerance and partial inhibition of cytotoxic mechanisms. The production of nitric oxide by intraperitoneal macrophages of mice during secondary infection with *Echinococcus multilocularis* mediates immunosuppression at early and late stages of infection. Results of these studies in the experimental mouse model and in patients suggest that immune modulation with cytokines, such as interferon-alpha, or with specific antigens could be used in the future to treat patients with alveolar echinococcosis and/or to prevent this very severe parasitic disease (Dai et al,2003; Vuitton&Gottstein,2010)

## 5. Life cycle and transmission

The life cycle of *Echinococcus* includes a definitive host (usually dogs or related species) and an intermediate host (herbivores such as sheep, horses, cattle, pigs, goats and camels,etc ). Humans are incidental hosts; they do not play a role in the transmission cycle. *E. granulosus* adult tapeworms are usually found in dogs or other canids. *E. multilocularis* adult tapeworms are usually found in foxes, other canids, or occasionally cats.

The tapeworm of *E. granulosus* in definitive host is composed of at least three proglottid segments which have both male and female sexual organs, which are about 2-7 mm long. They can produce thousands of parasite eggs 30 to 40 µm in size containing embryos (oncospheres). Gravid proglottids or released eggs are shed in the faeces and, following their ingestion by a human or ungulate host, an oncosphere larva is released that penetrates the intestinal epithelium into the lamina propria. This is then transported passively through blood or lymph to the target organs where it develops into a hydatid cyst. About 5 days after ingestion of eggs of *E. granulosus*, the metacestode forms. It is a small vesicle which is about 60 to 70 mm in diameter consisting of an internal cellular layer (germinal layer) and an outer acellular, laminated layer. Endocyst gradually expands and induces a granulomatous host reaction, followed by a fibrous tissue reaction and the formation of a connective tissue layer (pericyst). *E. granulosus* cysts in the human body is highly variable in size and usually ranges between 1 and 15 cm but much larger cysts (20 cm in diameter) may also occur (Ammann&Eckert,1996; Eckert&Plazes ,2004).

*E. multilocularis* worms are up to 4 mm long with two to six proglottic segments. The metacestode stage of *E. multilocularis* is a tumor-like multivesicular, infiltrating structure consisting of numerous small vesicles embedded in stroma of connective tissue; the larval mass usually contains a semisolid matrix rather than fluid (Eckert & Plazes, 2004). This exogenous tumour-like proliferation, which leads to infiltration of the affected organs and, in progressive cases, to severe disease and even death. The single vesicle has a wall structure similar to that of the metacestode of *E. granulosus* (germinal and laminated layer).

*E. granulosus* eggs can survive under humid conditions for several weeks or months in areas of warm and cold climates, but they are sensitive to desiccation (Eckert et al,2001). Eggs of *E. multilocularis* remain infective for approximately 1 year in a suitable, moist environment at lower temperatures, but they are sensitive to desiccation and high temperatures (Veit et al,1995). These eggs can survive at (-) 50°C for 24 h but are killed at (-) 70°C within 96 h and at (-)80 to (-)83°C within 48 h. Deep-freezing at (-)70°C for at least 4

days or at (-)80°C for at least 2 days is recommended for inactivating *E. multilocularis* eggs in carcasses or intestines of final hosts or in fecal material before examination in the laboratory.

Humans acquire primary CE by oral uptake of *E. granulosus* eggs excreted by infected carnivores. The infection may be acquired by handling infected definitive hosts, egg-containing feces, or egg-contaminated plants or soil followed by direct hand-to-mouth transfer. Transmission frequently occurs in settings where dogs eat the viscera of slaughtered animals. The dogs then excrete infectious eggs in their feces, which are passed on to other animals or humans via fecal-oral transmission. This may occur via environmental contamination of water and cultivated vegetables, or contact between infected domestic dogs and humans (often in children). It has been shown that Echinococcus eggs adhere to the coat of dogs, particularly to the hairs around the anus and on the thighs, muzzles, and paws. It is generally assumed that humans can become exposed to the eggs of *E. multilocularis* by handling infected definitive hosts or by ingesting food or water contaminated with eggs. Direct transmission of echinococcosis from human to human does not occur since two mammalian species are required for completion of the life cycle. Prenatal transfer of *E. granulosus* does not play a role (Conn,1994; Eckert et al, 2001).

The identification of risk factors of transmission is also an important issue. In a case-control study in Argentina, spending the first years of life surrounded by a large number of dogs was found to be an important risk factor (Larrieu et al,2002). In Tibetan areas of China (Sichuan), increased risks for CE were associated with nomadic life, age, playing with dogs, not protecting food from flies, and raising yaks or sheep (Wang et al,2001). In another study, risk factors for human cystic echinococcosis were found to be pastoral occupation, history of dog ownership, poor education, age, sex, and drinking water source (McManus,2003).

Domestic dogs and cats can also be infected with *E. multilocularis*. In a previous study in France, 5.6% of 36 dogs were identified as carriers of *E. multilocularis*, and in a further five studies in Germany and France, 0.5 to 3.7% of cats (58 of 498) were identified (by necropsy) as carriers (Eckert et al,2000). In an area of endemic infection in eastern Switzerland with an average prevalence of *E. multilocularis* in foxes of approximately 33%, only 0.30% of 660 dogs and 0.38% of 265 cats from "normal" populations were parasite carriers (Deplazes,1999). Dogs are highly susceptible to *E. multilocularis*, but cats appear to have a lower and a more variable degree of susceptibility, as observed both in several older and in more recent experimental studies (Jenkins&roming,2000). However, naturally infected cats can harbor small numbers of *E. multilocularis* worms containing fully developed eggs and are therefore potential sources of infection.

## 6. Clinical aspects of Echinococcus disease

### 6.1 Clinics in *Echinococcus granulosus*

CE can be seen in all age groups. In endemic areas, most hospital cases are recorded in the age groups between 21 and 40 years. Many infections are acquired in childhood but do not cause clinical manifestations until adulthood. The initial phase of primary infection is always asymptomatic. Latent periods may be very long such as 50 years. An analysis of 8,596 individuals in areas of endemic infection in Uruguay has revealed a significant age dependent increase of hepatic cysts detectable by ultrasonography from 0.33% in the age group from 0 to 9 years to 3.80% in the age group from 70 to 79 years. Similar observations



were made in other areas of endemic infection. Morbidity is higher in younger individuals aged between 6 and 20 years (Eckert&Deplazes,2003)

The cysts of *E. granulosus* may grow at a rate of 1-5 cm yearly or may persist without changes for years (Brunetti et al,2010). Hydatid cysts can be found in any part of the body, but liver is the most affected organ (Figure 1). Lung, brain, muscle, kidney, bone, heart and pancreas can be involved also. Up to 80% of patients infected with *E. granulosus* have single organ involvement and a solitary cyst located in the liver (Yang et al,2006;) or lung (Brunetti&Junghanss,2009). The clinical presentation of *E. granulosus* infection depends upon the site of the cysts and their size. Small and/or calcified cysts may remain asymptomatic indefinitely. In larger cysts, there may be symptoms due to compression or rupture into neighbouring structures. (Brunetti et al,2010).

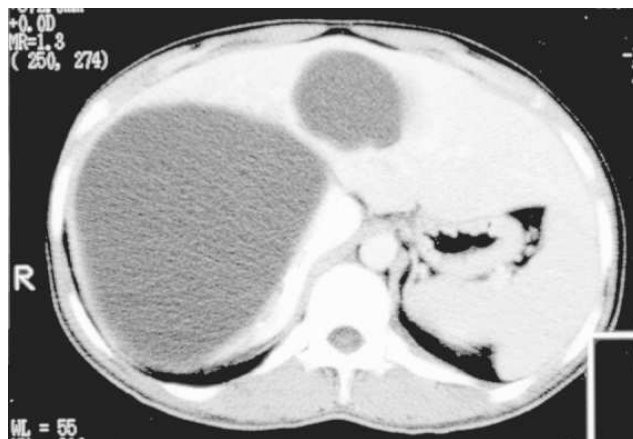


Fig. 1. CT examination shows two hypodense cystic liver lesions. Well defined fluid collections, consistent with cyst hydatid.

### 6.1.1 Liver involvement

*E. granulosus* infection of the liver frequently produces no symptoms. The right lobe is affected in 60 to 85 percent of cases. Significant symptoms are unusual before the cyst has reached at least 10 cm in diameter. The rate of growth of cysts is variable depending on the strain differences and the organ involved. Typical measurements state that the average cyst growth is 1 cm to 1.5 cm/year. Moreover, small, well-encapsulated, or calcified cysts typically do not elicit major pathology. Hydatid hepatic cyst symptoms include pain in the upper abdominal region, hepatomegaly, cholestasis, biliary cirrhosis, portal hypertension, and ascites. Serious complications include cyst rupture either into the peritoneal cavity resulting in anaphylaxis or secondary cystic Echinococcosis, cyst rupture into the biliary tree resulting in cholangitis and cholestasis. Secondary bacterial infection of the cysts can result in liver abscesses.(Scherer et al,2009)

In a study of Avgerinos et al. where they shared their 20 year experience with liver hydatidosis, the presenting symptoms or findings leading to the diagnosis of liver echinococcosis were jaundice (six cases, 17%), abdominal pain (five cases, 14%), gastrointestinal discomfort of the upper abdomen (e.g. nausea, vomiting, distention, anorexia) (two cases, 6%), acute pancreatitis (one case, 3%) and portal hypertension (one case, 3%). The rest of the cases were diagnosed incidentally (20 cases, 57%). (Avgerinos et al,2006)

### 6.1.2 Lung involvement

The ratio of lung:liver involvement is higher in children than in adults. Most pulmonary cases are discovered incidentally on routine radiograph evaluation; also most infected individuals remain asymptomatic until the cyst enlarges sufficiently to cause symptoms (Santivanez & Garcia, 2010). Approximately 60 percent of pulmonary hydatid disease affects the right lung and 50 to 60 percent involve the lower lobes. Multiple cysts are common. Approximately 20 percent of patients with lung cysts also have liver cysts. Symptoms are usually caused by mass effect from the cyst. Complications such as cyst rupture and aggregated infection change the clinical presentation, producing cough, chest pain, hemoptysis, or vomiting. If cysts rupture into the pleural space, a pleural effusion or empyema may develop. Diagnosis is obtained by chest radiographs or computed tomography, and supported by serology. (Baden & Elliot, 2003; Santivanez & Garcia, 2010)

### 6.1.3 Other organs

Involvement of heart, central nervous system, kidneys, bone and eye have been reported in the literature. Echinococcal infections of these organs are rare but can lead to significant morbidity and mortality. Cardiac involvement is a rare, but potentially a very serious complication of the hydatid disease. The diagnosis of cardiac cyst hydatid may be difficult due to the nonspecific symptoms and varying clinical presentations. The most common localizations within the heart are left ventricle, interventricular septum, right ventricle, pericardium and right or left atrium. Infection of the heart can result in mechanical rupture with widespread dissemination or pericardial tamponade (Demircan et al, 2010)

Cerebral hydatid cysts are usually supratentorial, whereas infratentorial lesions are quite rare. Clinically the disease presents as intracranial space occupying lesion and is more common in children. It can produce symptoms such as seizures and stroke (Ali et al, 2009).

Cysts in the kidney can cause hematuria or flank pain, immune complex-mediated disease, glomerulonephritis leading to the nephrotic syndrome, and secondary amyloidosis (Gogus et al, 2003; Gelman et al, 2000) (Figure 2).

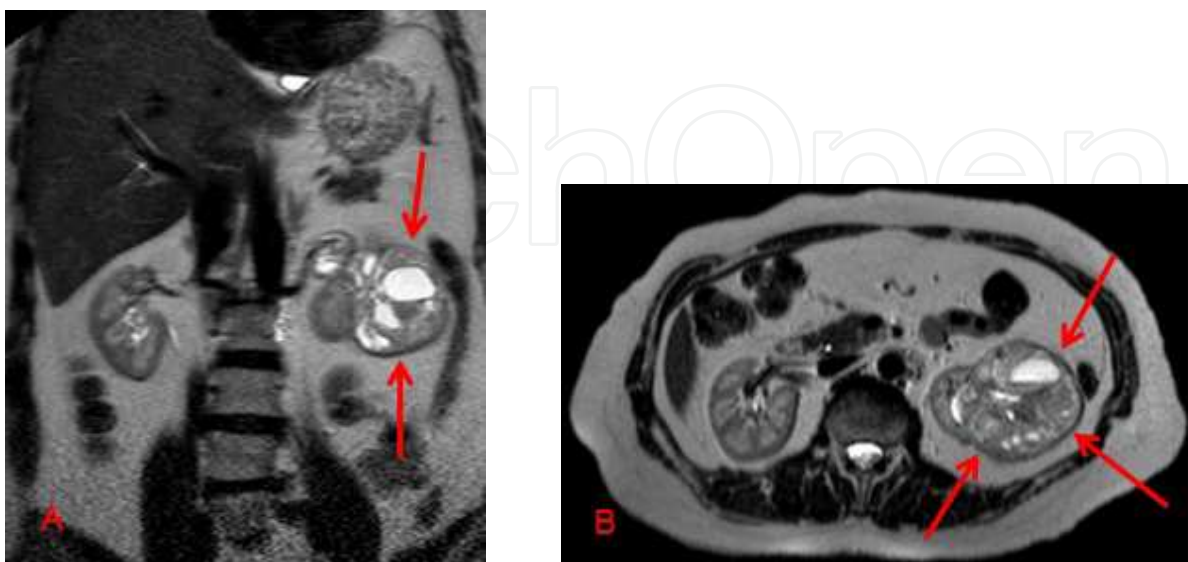


Fig. 2. A,B: MRI T2W coronal and axial images show a heterogeneous semisolid cyst hydatid lesion (Gharbi type 4, WHO CE4) with hyperintense cystic areas located at the left kidney.

Bone involvement is rare (0.2-4%), affecting the spine in almost half of the cases. The other localizations are pelvis and long bones. The disease is usually silent until a complication such as paraplegia or pathologic fracture occurs. Many cases are diagnosed intraoperatively. Pre-operative diagnosis is based on radiological findings and serological assays (Papanikolaou,2008).

Ocular cysts also occur (Schallenberg et al,2007).

Cyst rupture is another severe complication of cystic echinococcosis. Acute hypersensitivity reactions including anaphylaxis, may be the principal manifestations of cyst rupture. Fever can be seen. Hypersensitivity reactions are related to the release of antigenic material and secondary immunologic reactions

Calcification occurs mostly with hepatic cyst but can also be seen in pulmonary or bone cysts. It usually requires five to 10 years to develop. Total calcification of the cyst wall suggests that the cyst may be nonviable.

## 6.2 Clinics in *Echinococcus multilocularis*

Alveolar echinococcosis is characterized by an initial asymptomatic incubation period of 5–15 years and a subsequent chronic course. The infection may persist for years within an initial phase and might be detected by chance or during screening programmes. The most common presenting complaints include malaise, weight loss and right upper quadrant discomfort due to hepatomegaly. Later, severe hepatic dysfunction occurs and is often associated with portal hypertension. Cholestatic jaundice, cholangitis and the Budd-Chiari syndrome can also occur (Kern,2010).

Alveolar echinococcosis is a rare chronic and progressive disease, which can involve mostly liver and in rare cases lung and brain. It develops predominantly in the right lobe, from foci of a few millimetres to areas of 15–20 cm in diameter, sometimes with central necrosis. Giant lesions are reported occasionally (Yapici et al,2011).

Rarely, parasitic cysts may cause compression and thrombosis of the hepatic venous outflow tract. It may present as portal hypertension and variceal upper gastrointestinal bleeding (Dulger et al,2010).

Extrahepatic primary disease is very rare (1 percent of cases). Thirteen percent of cases present as multiorgan disease where metacestodes involve the lungs, spleen, bone or brain in addition to the liver. In patients with cerebral alveolar echinococcosis, neurological symptoms prevailed, such as headache, seizures, vomiting, blindness, left face numbness, aphasia, or ataxia (Kern,2010).

Immunodeficiency, such as HIV or transplantation, may accelerate the manifestations of alveolar echinococcosis. If left untreated, mortality is high (more than 90 percent of patients will die within 10 years of the onset of clinical symptoms, and virtually 100 percent by 15 years). Since treatment with albendazole has been introduced, the prognosis has improved considerably

In a recent study from France, where 362 patients with AE were evaluated. 83% of the patients were presented with clinical patterns evocative either of a digestive or a hepatic

disorder. Other symptomatic patients presented with clinical pictures, generally due to metastasis or extra-hepatic location of the parasite. Except for a few patients with particularly severe AE who died shortly after the diagnosis, most patients were treated using benzimidazoles and their mortality tends to merge with that of the general French population, matched by sex, age, and calendar year (Piarroux et al,2011).

## 7. Diagnosis

### 7.1 Diagnosis of *Echinococcus granulosus*

#### 7.1.1 Routine laboratory tests

Nonspecific leukopenia or thrombocytopenia, mild eosinophilia, and nonspecific liver function abnormalities may be detected, but are not diagnostic. Eosinophilia is seen in 15% of cases and generally occurs only if there is leakage of antigenic material.

#### 7.1.2 Imaging

Computed tomography (CT) scanning, magnetic resonance imaging (MRI), and ultrasound are used to detect hydatid cysts and to evaluate their characteristics. Ultrasound is employed most widely because it is easy to perform and less expensive.

Plain radiography may reveal calcification within a cyst, but cannot detect uncalcified cysts and is not the imaging technique of choice.

##### 7.1.2.1 Ultrasound

US examination is the basis of CE diagnosis in abdominal locations, at both the individual and population levels (Macpherson and Milner, 2003). It has a sensitivity of approximately 90 to 95 percent. US may visualize cysts in liver or in other organs, including lung when cysts are peripherally located (El Fortia et al.2006). The most common appearance on ultrasound is an anechoic smooth, round cyst, which can be difficult to distinguish from a benign cyst. When the liver cyst contains membranes, mixed echoes will appear that can be confused with an abscess or neoplasm. Internal septations are due to daughter cysts. Pulmonary lesions may be single or multiple, usually do not calcify, rarely lead to daughter cyst formation, and may contain air if the cyst has ruptured.

The ultrasonographic (US) appearance of hydatid cysts may vary. The cyst wall usually manifests as double echogenic lines separated by a hypoechogenic layer. Simple cysts do not demonstrate internal structures, although multiple echogenic foci due to hydatid sand may be seen within the lesion by repositioning the patient. The term "hydatid sand," reflects a complex image which consists predominantly of hooklets and scolexes from the protoscolices. This finding may be visible when shifting the patient's position during imaging. The echogenic foci quickly fall to the most dependent portion of the cavity without forming visible strata. This finding has been referred to as the snowstorm sign (Pedrosa et al,2000).

US is the most sensitive modality for the detection of membranes, septa, and hydatid sand within the cyst. US also allows for the classification of the cyst(s) by biologic activity. Cyst may be active, transitional, or inactive. An inactive lesion include a collapsing, flattened elliptical cyst which means low pressure within the cyst, detachment of the germinal layer

from the cyst wall, coarse echoes within the cyst, and calcification of the cyst wall (Salama et al,1995; Suwan,1995). Detachment of the endocyst from the pericyst is probably related to decreasing intracystic pressure, degeneration, host response, trauma, or response to therapy. Complete detachment of the membranes inside the cyst has been referred to as the US water lily sign because of its resemblance to the radiographic water lily sign in pulmonary cysts. Cysts with a calcified rim may have an "eggshell" appearance.

Multivesicular cysts manifest as well-defined fluid collections in a honeycomb pattern with multiple septa representing the walls of the daughter cysts. Daughter cysts appear as cysts within a cyst. The matrix represents hydatid fluid containing membranes of broken daughter vesicles, scolices, and hydatid sand. Membranes within the matrix can be seen as serpentine linear structures and this finding is highly specific for hydatid disease.

When the matrix fills the cyst completely, a mixed echogenic pattern is created that mimics a solid mass. Daughter vesicles or membranes are very important images for differential diagnosis of the lesion. Cyst calcification usually occurs in the cyst wall, although internal calcification in the matrix may also be seen. When the cyst wall is heavily calcified, only the anterior portion of the wall is visualized and appears as a thick arch with a posterior concavity. Partial calcification of the cyst can not be assumed as the death of the parasite but densely calcified cysts are mostly inactive.

There are some classification systems based upon ultrasound appearance: One is the Gharbi classification, which divides cysts into five types (Gharbi,1981). Type I cysts consist of pure fluid (Figure 3); type II have a fluid collection with a split wall; type III cysts contain daughter cysts (with or without degenerated solid material); type IV have a heterogeneous echo pattern (Figure 4); and type V have a calcified wall.

In 1995, the WHO-IWGE developed a standardised classification that could be applied in all settings allowing grouping of the cysts into three relevant groups: active (CE1 and 2), transitional (CE3) and inactive (CE4 and 5) (WHO and Echinococcosis, 2003).

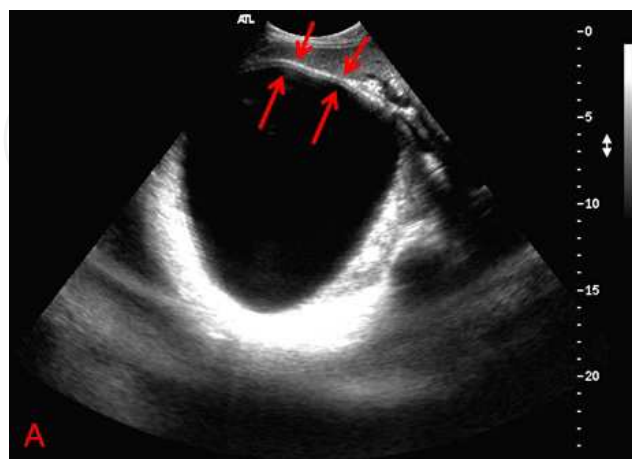


Fig. 3. A: B-mode ultrasonography demonstrating an anechoic, smooth cyst located at the right lobe of the liver: Cyst Hydatid (Gharbi type 1, WHO; CE 1). The cyst wall manifests as double echogenic lines separated by a hypoechogenic layer (arrows).



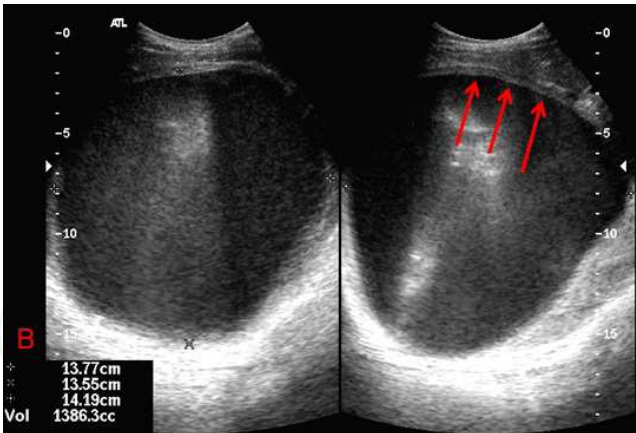


Fig. 3. B: Cyst volume: 1386 cc. Arrows indicating cyst wall.

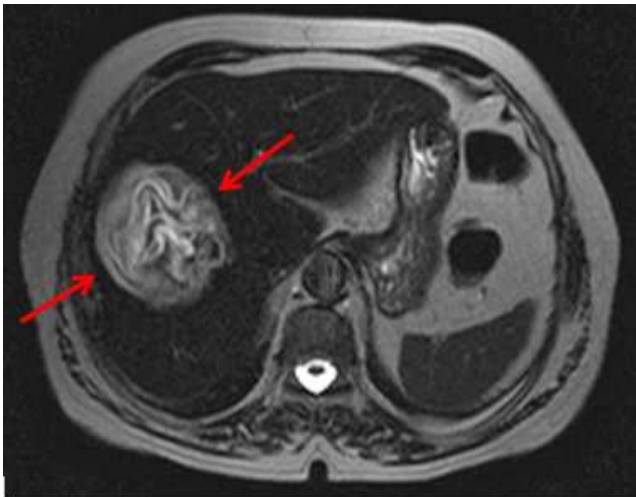


Fig. 4. MRI T2W image shows a hyperintense heterogenous cyst hydatid (Gharbi Type 4, WHO CE 4) (arrows) located at right liver lobe.

Gharbi	I	II	III	IV	V
WHO	CE1	CE3a	CE2	CE4	CE5
CL			CE3b		

Table 1. Comparison of Gharbi’s and WHO-IWGE ultrasound classification. (Brunetti,2010)

WHOIWGE classification differs from Gharbi's classification introduced in 1981 by adding a "cystic lesion" (CL) stage (undifferentiated), and by reversing the order of CE Types 2 and 3. CE3 transitional cysts may be differentiated into CE3a (with detached endocyst) and CE3b (predominantly solid with daughter vesicles) (Junghanss et al et al. 2008). CE1 and CE3a are early stages and CE4 and CE5 late stages.

#### 7.1.2.2 Computed tomography

CT is indicated in cases in where US could not be used due to patient-related difficulties such as obesity, excessive intestinal gas, abdominal wall deformities, previous surgery or disease complications. It has a high sensitivity and specificity for hepatic hydatid disease (Figure 5). Intravenous administration of contrast material is not necessary unless complications are suspected, especially infection and communication with the biliary tree. CT is best in showing cyst wall calcification, cyst infection and peritoneal seeding (Ilica et al,2007).

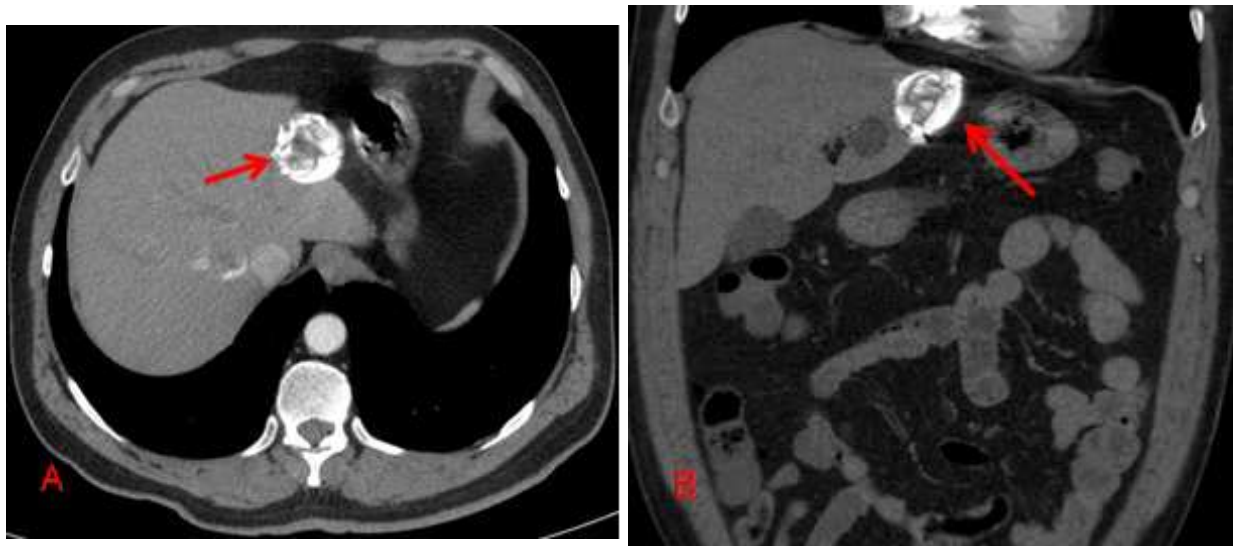


Fig. 5. A, B: CT axial (A) and coronal (B) images show hyperdense calcified cyst hydatid (arrows) (Gharbi type 5, WHO CE 5) located at the left liver lobe. Another smaller hypodense cyst hydatid lesion (arrowhead) can be seen on the coronal plane.

CT may show hepatic cystic lesion which includes many small round shaped cystic lesions that have a lower density of inner substance than the density of the inner substance of the mother cystic lesion. The presence of daughter cysts is a pathognomonic sign of the cystic hydatid nature, and these CT findings are thought to be specific for cystic echinococcosis in spite of the low appearance rate of 30%. (Ohnishi et al,2008)

In one study, ultrasound performed better than CT in the investigation of the cyst wall, hydatid sand, daughter cysts, and splitting of the cyst wall, while CT was superior in detecting gas and minute calcifications within the cysts, in attenuation measurement, and in anatomic mapping. Detachment of the laminated membrane from the pericyst can be visualized as linear areas of increased attenuation within the cyst. Daughter vesicles manifest as round structures located peripherally within the mother cyst.

Extrahepatic abdominal hydatid lesions have nearly identical imaging features, including the presence of cyst wall calcification, daughter cysts, and membrane detachment. The

combinations of radiologic and serologic tests especially in patients living in the endemic areas contribute to the diagnosis( Ohnishi et al,2008; Ilica et al,2007).

### 7.1.2.3 Magnetic Resonance Imaging (MRI)

MRI shows the characteristic low-signal-intensity rim of the hydatid cyst on T2-weighted images(Reiterova,2005). It probably represents the outer layer of the hydatid cyst (pericyst), which is rich in collagen and is generated by the host. Although cyst wall calcification is more clearly depicted at CT, MR imaging is superior in demonstrating irregularities of the rim. These irregularities probably represent incipient detachment of the membranes (Davilo et al,1990) (Figure 6).

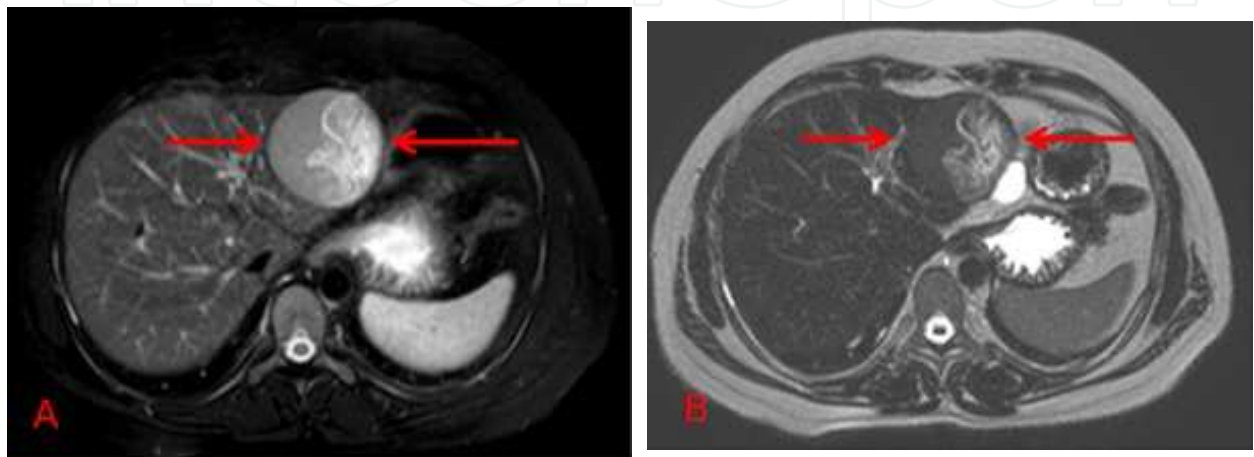


Fig. 6. A,B: MRI T2W (A) and Heavy T2W (B) images show hypointense cyst hydatid lesion with a hyperintense split wall located at the left liver lobe (Gharbi Type 2, WHO C3a).

According to WHO, computed tomography and magnetic resonance imaging, and if possible cholangiopancreatography (MRCP) are indicated in

1. Subdiaphragmatic location,
2. Disseminated disease,
3. Extraabdominal location,
4. In complicated cysts (abscess, cysto-biliary fistulae) and
5. Pre-surgical evaluation.

Whenever possible, MR imaging should be preferred to CT due to better visualization of liquid areas within the matrix (Hosch et al, 2008).

Other imaging techniques such as cholangiography may be indicated to diagnose biliary involvement, particularly in patients with cholestatic jaundice. ERCP can be performed in patients with liver cysts prior to intervention.

### 7.1.3 Serology

Sensitivity of serum antibody detection using indirect hemagglutination, enzyme-linked immunosorbent assay (ELISA), or latex agglutination, with hydatid cyst fluid antigens, ranges between 85 and 98% for liver cysts, 50–60% for lung cysts and 90–100% for multiple organ cysts (Siracusano and Bruschi, 2006; Ito and Craig, 2003; Siles-Lucas and Gottstein, 2001). Detection of circulating *E. granulosus* antigens in serum is less sensitive than antibody

detection, which remains the method of choice. Nevertheless, due to the cross-reactions with other cestode infections (*E. multilocularis* and *Taenia solium*), some other helminth diseases, malignancies, liver cirrhosis and presence of anti-P1 antibodies, the specificity of all tests are limited and confirmatory tests must be used (arc-5 test; Antigen B (AgB) 8 kDa/12 kDa subunits or EgAgB8/1 immunoblotting) in dubious cases (Siracusano and Bruschi, 2006; Ito and Craig, 2003).

Detection of parasite-specific IgE or IgG4 has no significant diagnostic advantage since these antibodies remain in serum for long periods following surgical removal or effective drug treatment of cysts, or even if the infection self-cures. Bulut et al showed that after surgical treatment of the disease, total IgE levels in the sera of the patients decreased to normal six months after surgery. Specific IgE against echinococcal antigens decreased one year after operation, but serum levels were still significantly high. There were no changes in the levels of anti-*Echinococcus* IgG and total IgG in follow-up period. Additionally, other parameters, such as IgA, IgM, C3 and C4, were not affected (Bulut et al, 2001). There may be also false negative results with varying frequency depending upon the site of the lesion and the cyst's integrity and viability. Antigen-antibody complexes that remove all antibodies may lead to false negative reactions. Thus, a negative serologic test generally does not rule out echinococcosis.

In fact ELISA using crude hydatid cyst fluid has a high sensitivity (over 95%) but its specificity is often unsatisfactory. If purified antigens like antigen B or other techniques such as immunoblot analysis, detection of immunoglobulin G4 (IgG4) antibodies and immunoelectrophoresis are used, specificity is improved but average sensitivity is much lower. Furthermore, it should be remembered that approximately 10 to 20% of patients with hepatic cysts and about 40% with pulmonary cysts do not produce detectable specific serum antibodies (IgG) and therefore give false-negative results. Cysts in the brain, bone, or eye and calcified cysts often induce no or low antibody responses. Children and pregnant women more frequently have negative serology than other patient populations. Nevertheless, immunoblotting may be used as a first-line test and is best for differential diagnosis (Akisu et al, 2006; Eckert & dePlazes, 2004)

#### 7.1.4 Cyst aspiration or biopsy

Microscope examination of protoscoleces after cyst fluid aspiration using vital staining gives evidence for the parasitic nature and viability of a cyst (WHO/OIE, 2001). Detection of parasitic antigens gives no indication of viability. Presence of calcification is not reliable as an indicator of non-viability: more frequent in CE4 and CE5, it may be observed at all stages (Hosch et al, 2007).

MRS may be used to examine cyst fluid ex vivo and prepare detailed quantitative metabolite profiles, enabling a multivariate metabolomics approach to cyst staging. (Hosch et al., 2008). In vivo evaluation of cyst viability has already been performed using MR spectroscopy in cysts that do not move with respiration such as brain cysts. In a patient with hydatid disease of the brain and on albendazole treatment, Seckin et al. performed MRS before the medical therapy was begun, which revealed the typical findings of a hydatid cyst with resonance of alanine, acetate, and succinate that were specific for hydatid disease, and additional nonspecific lactate peaks with an additional small peak of choline. Two sequential MRS imaging revealed a prominent decrease of the succinate and acetate resonance, accompanied by a smaller decline of the alanine resonance progressively, correlated with the conventional MRI findings of the cyst, which had a smaller size with blurred margins in the meantime.



After 5 months of medical treatment, the cyst had completely disappeared. The patient has been monitored for 5 years and remains well without recurrence. The author concluded that changes in the metabolic profile of the cyst, especially those regarding succinate and acetate may represent the efficacy of the medical treatment.(Seckin et al, 2008) and might become possible for other locations in the future (Hosch et al, 2008).

Percutaneous aspiration of an active cysts reveal clear watery fluid containing scolices and have elevated pressure, whereas inactive cysts exhibit cloudy fluid without detectable scolices and do not have elevated pressure (Salama et al,1995). Percutaneous aspiration of liver cyst contents is associated with very low rates of complications, but this method of diagnosis is generally reserved for situations when other diagnostic methods are inconclusive because of the potential for anaphylaxis and secondary spread of the infection (Gargouri et al,1990; Khuroo et al,1993; Filice et al,1990; Giorgio et al,1992).To prevent secondary echinococcosis if a hydatid cyst is punctured, chemotherapy with albendazole is recommended for 4 days before the procedure. Chemotherapy should be continued for at least 1 month after puncturing a lesion that was diagnosed as an *E. granulosus* cyst even after its immediate surgical removal Increasingly, cyst puncture also is performed as a therapeutic measure.

According to WHO, the diagnostic criterias for cystic echinococcus are:

1. Typical organ lesion(s) detected by imaging techniques (e.g. US, CT-scan, plain film radiography, MR imaging
2. Specific serum antibodies assessed by high-sensitivity serological tests, confirmed by a separate high specificity serological test.
3. Histopathology or parasitology compatible with cystic echinococcosis (e.g. direct visualization of the protoscolex hooklets in cyst fluid).
4. Detection of pathognomonic macroscopic morphology of cyst(s) in surgical specimens.

WHO defines the possible versus probable versus confirmed cases as follows:

Possible case: Any patient with a clinical or epidemiological history, and imaging findings or serology positive for CE.

Probable case: Any patient with the combination of clinical history, epidemiological history, imaging findings and serology positive for CE on two tests

Confirmed case: The above, plus either

1. Demonstration of proto scoleces or their components, using direct microscopy or molecular biology, in the cyst contents aspirated by percutaneous puncture or at surgery, or
2. Changes in US appearance, e. g. Detachment of the endocyst in a CE1 cyst, thus moving to a CE3a stage, or solidification of a CE2 or CE3b, thus changing to a CE4 stage, after administration of ABZ (at least 3 months) or spontaneous

## 7.2 Diagnosis of *Echinococcus multilocularis*

### 7.2.1 Routine laboratory tests

Nonspecific leukopenia or thrombocytopenia, mild eosinophilia, and nonspecific liver function abnormalities may be detected, but are not diagnostic. Hypergammaglobulinemia



and elevated serum IgE levels are present in more than 50 percent of cases. In a recent study, absence of eosinophils in the peritoneal cavity and a low number of such cells in the blood of infected animals was observed and this was related to metacestode antigens (in vitro generated vesicle fluid and E/S products) that were able to proteolytically digest eotaxin. Proteolysis of eotaxin was, thus, dose-dependent and proportional to the time of incubation with the metacestode antigens. Absent eosinophils, thus, may be a part of a series of events that maintain a low level of inflammation displayed within the peritoneal cavity of experimentally infected mice (Mejri&Gottstein, 2009).

## 7.2.2 Imaging

### 7.2.2.1 Ultrasound

US examination is the basis of AE diagnosis in abdominal locations, at the individual and population levels, but needs an experienced examiner (Bartholomot et al., 2002; Romig et al., 1999). The lesion resembles a tumor, but the patient's overall condition is usually better than would be expected for a malignancy.

Typical findings (70% of cases) include

1. Juxtaposition of hyper- and hypoechogenic areas in a pseudo-tumour with irregular limits and scattered calcification and
2. Pseudo-cystic appearances due to a large area of central necrosis surrounded by an irregular hyperechogenic ring.

Less typical features (30% of cases) include

1. 1- Hamangioma-like hyperechogenic nodules as the initial lesion and
2. 2- A small calcified lesion due either to a dead or a small sized developing parasite (Bresson-Hadni et al., 2000, 2006).

US with colour Doppler provides information on biliary and vascular involvement.

### 7.2.2.2 CT and MRI

CT gives an anatomical and morphological characterization of lesions and best depicts the characteristic pattern of calcification (WHO/OIE, 2001). In cases of diagnostic uncertainty, MR imaging may show the multivesicular morphology of the lesions, thereby supporting the diagnosis (Bresson-Hadni et al., 2006). It is the best technique to show invasions to adjacent structures. For pre-operative evaluation, MRCP has replaced percutaneous cholangiography to study the relationship between the AE lesion and the biliary tree (Bresson-Hadni et al., 2006). Initial radiological examination to exclude pulmonary and cerebral AE is recommended.

Common CT and MR imaging findings of cerebral lesion seen with *E. multilocularis* is a well-defined multiseptated mass consisting of solid and cystic components with calcification in the solid portion (Bukte et al., 2004).

The characteristic radiological findings of pulmonary alveolar hydatid disease include intersegmental distribution involving the segmental veins. Alveolar hydatid disease probably spreads via emboli, in a manner similar to that of metastatic neoplasms. The

absence of marked retraction of adjacent organs such as pleura, bronchus and pulmonary vessels seems to be characteristic of pulmonary alveolar hydatid disease caused by *E. multilocularis* (Ohsaki et al,2007).

### 7.2.3 Serology

Serology can also be helpful in the diagnosis of *E. multilocularis* infection. Immunodiagnostic tests for primary diagnosis or confirmation of imaging results are more reliable in the diagnosis of AE than of CE since more specific antigens are available. For example, the Em2plus-ELISA, using a mixture of affinity-purified *E. multilocularis* metacestode antigens (Em2-antigen) and a recombinant antigen (EmII/3-10), exhibited a diagnostic sensitivity of 97% in patients with confirmed AE and an overall specificity of 99% for infections due to other helminths. The use of purified and/or recombinant, or in vitro-produced *E. multilocularis* antigens (Em2, Em2+, Em18, etc) has a high diagnostic sensitivity of 90–100%, with a specificity of 95–100%. Most of the purified antigens allow discrimination between AE and CE in 80–95% of cases. Immunoblotting tests may be used for confirmation or as a firstline investigation if easily available. Serology usually remains positive indefinitely in patients receiving chemotherapy, yet may become negative within a few years following complete surgical resection. Clinical recurrence is often associated with rising serologic titers. IgG1 and IgG4 antibodies are the most sensitive isotypes for monitoring the success of therapy (Schantz et al,1983; Ito et al,1995; Brunetti et al,2010)

For AE screening, a combined approach using US and serology discriminates different infection status among seropositive individuals:

1. Patients with active hepatic lesions,
2. Individuals presenting with fully calcified lesions and
3. Individuals presenting with no detectable lesion at all.

The latter two variants refer to persons exposed to infection but in whom the parasite has not become established or does not progress (Vuitton et al., 2006).

According to WHO, the diagnostic criteria for alveolar echinococcus are:

1. Typical organ lesions detected by imaging techniques (e.g.abdominal US, CT, MR).
2. Detection of Echinococcus spp. specific serum antibodies by highsensitivity serological tests and confirmed by a high specificity serological test.
3. Histopathology compatible with AE.
4. Detection of *E. multilocularis* nucleic acid sequence(s) in a clinical specimen.

WHO defines the possible versus probable versus confirmed cases as follows:

Possible case: Any patient with clinical and epidemiological history and imaging findings or serology positive for AE.

Probable case: Any patient with clinical and epidemiological history, and imaging findings and serology positive for AE with two tests.

Confirmed test: The above, plus (1) histopathology compatible with AE and/or (2) detection of *E. multilocularis* nucleic acid sequence(s) in a clinical specimen

## 8. Treatment

### 8.1 Treatment of *Echinococcus granulosus*

A number of surgical and non-surgical options exist to treat cystic echinococcosis of the liver. Pre- and post-intervention chemotherapy with albendazole or mebendazole reduces the risk of disease recurrence and intraperitoneal seeding of infection that may develop by cyst rupture and spillage occurring spontaneously or during surgery or needle drainage. PAIR appears to be more effective treatment method with lower rates of major and minor complications, mortality, and disease recurrence. Hospitalization period is also shorter compared to patients treated surgically. PAIR is a safe and effective procedure of choice for patients with hepatic echinococcosis, and perhaps other anatomic sites of infection such as lung, peritoneum, kidney, and other viscera when the medication are ineffective. Surgery should be reserved for patients with hydatid cysts refractory to PAIR because of secondary bacterial infection or for those with difficult-to-manage cyst-biliary communication or obstruction (Smego et al, 2005).

#### 8.1.1 Open surgery

Indications for surgery should be evaluated carefully before making decision. Open surgery is the first treatment choice for complicated cysts, and it is also an option for complete removal of the parasite in patients who can tolerate surgery and who have cysts in amenable locations. According to WHO-IWGE experts, the indications for surgery are:

1. Removal of large CE2-CE3b cysts with multiple daughter vesicles,
2. Single liver cysts, situated superficially, that may rupture spontaneously or as a result of trauma when PTs are not available,
3. Infected cysts, again, when PTs are not available,
4. Cysts communicating with the biliary tree (as alternative to PT) and
5. Cysts exerting pressure on adjacent vital organs (Brunetti et al, 2010).

Surgery is also preferred for large liver cysts (diameter >10 cm, especially if associated with multiple daughter cysts); superficially located single liver cysts; complicated cysts such as those accompanied by infection, compression, or obstruction; or cysts in the lung, kidney, bone, brain, or other organs (Dervenis et al, 2005; Safioleas et al, 2006; Junghanss et al, 2008).

Contraindications of surgery are (Brunetti et al, 2010):

1. Patients to whom general contraindication for surgery apply,
2. Inactive asymptomatic cyst
3. Difficult to Access cyst
4. Very small cyst

##### 8.1.1.1 Surgical techniques

Total removal of the cyst is usually described as “pericystectomy.” “Closed total pericystectomy” removes the cyst without opening it, and “open total pericystectomy” sterilizes the metacestode with protoscolicidal agents, evacuates the contents of the cyst, then removes the pericystic tissue. There is a cleavage plane between the inner layer of the host’s reaction facing towards the parasite and the outer layer, or adventitia which limits the damage

to liver parenchyma when dissecting around the cyst and allows safer removal of the cyst (Peng et al. 2002). All these operations can be named as total cystectomy. Partial cystectomy, in which the cyst content is sterilized and removed after opening, with the pericyst partially resected, is especially suited for endemic areas where the operations are performed by general surgeons. But the risk of secondary echinococcosis from protoscolex dissemination is higher than with total pericystectomy or total cystectomy (Brunetti et al, 2010).

The main goals of surgical therapy include:

1. Evacuation of the cyst while avoiding spillage of its contents,
2. Neutralization of the cyst, and
3. Obliteration of the residual cavity (Safioleas et al, 2006).

Adequate drainage and obliteration of the remaining cavity is a necessary procedure to minimize the possibility of serum or blood accumulation or liver abscess formation. Although conservative surgical procedures are considered simpler and safer to perform, the rate of postoperative complications such as biliary fistula, residual cavity and recurrence, and cavity suppuration has been reported to be about 35%. On the other hand, radical surgery can be performed with low risk of recurrence (3.2%). (Aydin et al. 2008).

The treatment modalities for liver cysts include total pericystectomy, partial hepatic resection and more conservative procedures including simple-closure tube drainage and cavity management via capitonnage (obliteration of residual cavity after cyst extrusion using deep purse-string suturing). Marsupialization (now rarely done), omentoplasty, introflexion or internal drainage are not commonly performed.

The surgical options for lung cysts include lobectomy, wedge resection, pericystectomy, intact endocystectomy, and capitonnage. In a large study of 842 patients followed for 3 to 20 years, a recurrence rate of 1.9 percent was noted after intact endocystectomies (Qian, 1998).

Any effort made to avoid fluid spillage is recommended, including protection of peritoneal tissues and organs with protoscolicide-soaked surgical drapes and injection of protoscolicide into the cyst before opening (Brunetti et al, 2010). Twenty percent hypertonic saline is recommended, and should be in contact with the germinal layer for at least 15 minutes. (WHO/OIE, 2001). In order to reduce the risk of chemically-induced sclerosing cholangitis, its use should be avoided when communication between the cyst and the bile ducts is found. Formalin, which frequently was used for this purpose in the past, is no longer recommended because of an increased risk of sclerosing cholangitis.

Ivermectin, praziquantel (PZQ) and BMZ solutions have been used as protoscolicidal agents however, they should be further studied in humans for efficacy and safety (Bygott and Chiodini, 2009; Dziri et al., 2009). Peri-operative BMZ may reduce cyst pressure and decrease the risk of secondary CE. The length of administration usually ranges between 1 day before and 1 month after surgery but has never been formally evaluated.

#### 8.1.1.2 Cysto-Biliary fistulas

In clinically asymptomatic patients, cyst diameter can be a clue for the presence of cysto-biliary fistulas. With a cyst diameter of 7.5cm as a cut-off point, a 79% likelihood to find a cysto-biliary fistula was calculated (Aydin et al. 2008). When this complication is detected,

sphincterotomy alone is not an adequate treatment. Most communications can be managed with suture during surgery. However, biliary-intestinal anastomosis or liver resection are sometimes necessary. It is also advisable to do an ERCP pre-PAIR and to perform postaspiration imaging of the cyst using contrast to rule out possible communication with the biliary tree.

#### 8.1.1.3 Outcome

Complications of surgery include infection of the residual cavity, intraabdominal abscesses, anaphylactic reactions, spillage of parasite material leading to secondary echinococcosis, biliary fistulation, and sclerosing cholangitis. Surgical mortality is usually 0.5 to 4 percent for the first intervention, but increases with repeated interventions and with inadequate experience or operative facilities. Surgery is not the optimal treatment for complicated liver CE and disseminated CE (Dziri et al., 2004).

#### 8.1.2 Laparoscopy

Laparoscopic treatment of liver echinococcosis has become increasingly popular, most suitable treatment option for the cases with anteriorly located hepatic cysts; have high success, low complication and low recurrence rates(Bickel et al,1998). Laparoscopic treatment includes partial or total pericystectomy and cyst drainage with omentoplasty. Disadvantage of laparoscopy is the lack of precautionary measures to prevent spillage under the high intraabdominal pressures caused by pneumoperitoneum(Dervenis et al,2005). Allergic reactions are more common in laparoscopic interventions due to peritoneal spillage, although length of stay is generally shorter and morbidity rates lower than for open procedures. Laparoscopic treatment is not suitable for deep intraparenchymal cysts or posterior cysts situated close to the vena cava, more than three cysts with thick and calcified walls (Chowbey et al,2003; Ertem et al,2002; Seven et al,2000).

#### 8.1.3 Percutaneous treatments

Percutaneous treatments can broadly be divided into:

1. Those aiming at the destruction of the germinal layer (puncture, aspiration, injection and reaspiration, or PAIR) and
2. Those aiming at the evacuation of the entire endocyst (also known as Modified Catheterization Techniques). (Brunetti et al,2010)

##### 8.1.3.1 PAIR procedure

Puncture, aspiration, injection and reaspiration (PAIR) is a percutaneous cyst puncture procedure performed under ultrasound or CT guidance followed by aspiration of substantial amounts of cyst fluid and injection of a protoscolicidal agent into the cyst cavity. PAIR confirms the diagnosis and removes parasitic material. It is minimally invasive, less risky and usually less expensive than surgery (Smego et al., 2003).

Protoscolicides used in PAIR are mainly 20% NaCl and 95% ethanol. Transhepatic cyst puncture prevents peritoneal protoscolex spillage. The cyst is then reaspirated after a period of at least 15 minutes. Prophylaxis with ABZ 4 h before and 1 month after PAIR is mandatory (WHO-IWGE, 2003a,b).



PAIR is a minimally invasive technique used in the treatment of cysts in the liver and other abdominal locations (WHO-IWGE, 2003a,b). It is indicated for inoperable patients and those who refuse surgery, in cases of relapse after surgery or failure to respond to BMZ alone. Best results with PAIR + BMZ are achieved in >5cm CE1 and CE3a cysts and suggested as first-line treatment (Khuroo et al., 1993). PAIR is contraindicated for CE2 and CE3b, for CE4 and CE5, and for lung cysts. The presence of biliary fistulae is also a contraindication for PAIR because of protoscolicide use. It should not be used in patients with inaccessible cysts, superficially located liver cysts where there is a risk of spillage into the abdominal cavity, cysts with nondrainable solid material or echogenic foci and inactive or calcified cysts.

The potential risks of this procedure include anaphylaxis, secondary echinococcosis, hemorrhage, infection, chemical sclerosing cholangitis, and biliary fistulas. PAIR should only be performed by experienced physicians with drugs and resuscitation equipment to manage anaphylactic shock at hand and a surgical back-up team. The WHO panel concluded that the use of PAIR is widespread and increasing in all areas where cystic hydatid disease is a problem and PAIR appears to be a safe and effective therapeutic tool.

In a study from Bulgaria, PAIR was performed in 230 patients with 348 echinococcal cysts. At 12-month follow-up, 77.6% of the cysts, all cystic echinococcosis (CE) 1 and CE3a cysts according to the World Health Organization Informal Working Group classification, showed various degrees of obliteration. In 11.5% of cysts, all of which were > 10 cm-type CE1, a significant amount of fluid persisted, and they were punctured again. Of those, 16 (4.6%) contained protoscolices and were treated by a second PAIR. The remaining 24 (6.9%) cysts were treated by simple aspiration or drainage. No significant reduction in size and no changes in the structure were observed in 10.9% of cysts, all of which were classified as CE2 or CE3b. Complications developed in 25.2% of patients, including severe anaphylactic reaction in two (0.9%) patients (Golemanov et al, 2011).

Percutaneous treatment of hydatid cysts in pregnancy is also an efficient and safe procedure in cases where percutaneous treatment is indicated (Ustunsoz et al, 2008).

Ustunsoz has reported six pregnant patients (age range 19-28 years; mean age 23 years) with six hepatic hydatid cysts who underwent percutaneous treatment without albendazole prophylaxis. PAIR technique was used to treat the cysts. They used hypertonic saline solution as cytotoxic agent and followed-up patients mainly by sonography every 2 weeks during pregnancy, every third month post-partum for the first year, every 6 months for the second year, and once a year thereafter. Average hydatid cyst volume which was 2,145 ml before treatment was reduced to 145 ml post-treatment at the time of delivery. A cystobiliary fistula was found in one patient and a percutaneous catheter was placed into the postresidual cavity and a nasobiliary catheter was placed into the common bile duct after sphincterotomy. The fistula was closed in 2 weeks. This patient has a follow-up time of 1 year so far without any problem. No mortality, morbidity, fetal loss, abdominal dissemination, or tract seeding was observed among these cases.

Another paper from Turkey reported a single-center experience comparing surgery, laparoscopic surgery, and percutaneous treatments in 355 patients with 510 hydatid cysts of the liver over a period of 10 years. There were two postoperative deaths (1.08%) in the open surgery group. Biliary leakage was observed in 28 patients treated with open surgery, in 10 patients after PT, and in 2 after laparoscopic treatment. Recurrence rates were 16.2%, 3.3%,

and 3.5% after open surgery, laparoscopic surgery, and percutaneous treatment, respectively. They stated that characteristics of the cyst, presence of cystobiliary communications, and the availability of a multidisciplinary team are the factors affecting the results and concluded that PAIR is effective and safe (Yagci et al,2005).

Gabal et al. performed a modified PAIR technique for percutaneous high risk hydatid cysts. In this method, they used a coaxial catheter system to achieve concomitant evacuation of cyst contents while infusing scolicidal agent. Hypertonic saline was used to wash out cyst contents and to kill protoscolices which was followed by injection of a sclerosant (ethyl alcohol 95%) into the residual cyst cavity to prevent formation of a cyst collection after the procedure. 17 cysts in 14 patients were successfully aspirated. They found gradual decrease in cyst size (17 cysts, 100%), thickening and irregularity of the cyst wall due to separation of endocyst from pericyst (7 cysts, 41%), development of a heterogeneous appearance of the cyst components (8 cysts, 47%) and development of pseudotumor (2 cysts, 12%). They concluded that modified PAIR technique is a reliable method for percutaneous treatment of risky and symptomatic hydatid cysts (Gabal et al, 2005).

#### 8.1.3.2 Other percutaneous treatments

Modified Catheterization Techniques are reserved for cysts that are difficult to drain or for cysts that tend to relapse after PAIR. These procedures aim to remove the entire endocyst and daughter cysts from the cyst cavity using large-bore catheters and cutting devices together with an aspiration apparatus. Among more than 1000 patients, rates of short- and medium-term success are satisfactory with minimal complications. These techniques have also been successfully employed for CE2 cysts located outside the abdomen (Akhan et al., 2007). However, long-term follow-up of patients is unavailable, and the procedure should be done with caution. ( Brunetti et al,2010)

#### 8.1.4 Antiparasitic drug treatment

Benzimidazoles (BMZ) inhibit the assembly of tubulin into microtubules, thus impairing glucose absorption through the wall of the hydatid parasite. This causes glycogen depletion and degeneration of the endoplasmic reticulum and mitochondria of the germinal layer of the metacestode, and results in an increase in lysosomes and subsequent cellular death.

WHO recommendations state that medical therapy should be used for (Brunetti et al,2010):

1. 1-Inoperable patients with liver or lung CE,
2. 2-Patients with multiple cysts in two or more organs,
3. 3-Peritoneal cysts,
4. 4-Small (<5 cm) CE1 and CE3a cysts in the liver and lung
5. 5-Prevention of recurrence following surgery or PAIR

According to WHO-IWGE experts, the contraindications for benzimidazoles are:

1. 1-Cysts at risk of rupture
2. 2-In early pregnancy

Adverse effects of benzimidazoles include hepatotoxicity, leucopenia, thrombocytopenia and alopecia, so benzimidazoles must be used with caution in patients with chronic hepatic disease and should be avoided in those with bone-marrow depression. Inactive or calcified

asymptomatic cysts should not be treated unless they are complicated. BMZ alone are not effective in large cysts (over 10 cm), as their effect is extremely slow in cysts with large volumes of fluid.

BMZ can be used in patients of any age. However, there is little experience with children under-6 years old; it is less limited by the patient's status than surgery. The cure rate after a treatment period of 3-6 months with standard doses is 30%. Stojkovic et al. collected and analysed data from 711 treated patients with 1,308 cysts from six centres (five countries). Analysis was restricted to 1,159 liver and peritoneal cysts. They evaluated the importance of cyst stage and size in determining response to treatment. They found that 1-2 y after initiation of benzimidazole treatment 50%-75% of active C1 cysts were classified as inactive/disappeared compared to 30%-55% of CE2 and CE3 cysts. They showed that 50%-60% of cysts <6 cm responded to treatment after 1-2 y compared to 25%-50% of cysts >6 cm. However, 25% of cysts reverted to active status within 1.5 to 2 y after having initially responded and multiple relapses were observed; after the second and third treatment 60% of cysts relapsed within 2 years. (Stojkovic et al., 2009).

#### 8.1.4.1 Mebendazole

It is the first benzimidazole agent tested against *Echinococcus*. The usual dosage is 40 to 50 mg/kg per day, given in three divided doses with fat-rich meals. Maximal daily dose that can be given is 6 g. Therapy is usually indicated for at least three to six months. It is used if albendazole is not available or not tolerated.

#### 8.1.4.2 Albendazole

Albendazole is currently the drug of choice to treat CE, either alone or together with PT. Given orally, at a dosage of 10-15 mg/kg/day, in two divided doses, with a fat-rich meal to increase its bioavailability. The hepatic metabolite of albendazole, albendazole sulfoxide, is also active against the parasite. Because of safety concern, albendazole was administered intermittently in four week courses, followed by an interval of two drug-free weeks but today it is recognised that continuous therapy does not increase the risk of side effects, and efficacy may be improved.

In cases of preoperative treatment with albendazole, the results were in favor of the 3-month treatment while even the 1-month treatment was associated with improved effectiveness compared to no treatment. (Gil-Grande et al, 1993) Wen H et al and Aktan et al also performed prospective controlled trials that showed that 4-month cyclic (30 days on-therapy and 10 days off-therapy) and 3-week continuous preoperative treatment with albendazole, respectively, resulted to fewer viable cysts at the time of operation compared to no treatment. In a recent study, Stankovic et al reported statistically fewer viable protoscolices at the time of surgery for patients that received 3 weeks preoperative treatment with albendazole compared to those that received no preoperative treatment. (Wen et al, 1994; Aktan et al, 1996; Stankovic et al, 2005)

#### 8.1.4.3 Flubendazole

Flubendazole is another benzimidazole drug, which has been evaluated for CE treatment in both mice and men. Flubendazole has shown poor in vivo efficacy against CE in humans and mice. However, flubendazole causes marked in vitro damage on *E. granulosus* protoscoleces (Ceballos et al, 2010). In a study by Ceballos et al, pharmacological

performance of the benzimidazole compounds flubendazole (FLBZ) and albendazole (ABZ) were evaluated. And they stated that flubendazole offers a great potential to become a drug of choice in the treatment of cystic echinococcosis (Ceballos et al, 2011)

#### 8.1.4.4 Praziquantel

This isoquinoline has been shown to have effective protoscolicidal activity, and may be more effective than albendazole *in vitro*. It can be used alone or in combination with albendazole. The dose of praziquantel is 40 mg/kg once a week or 25 mg/kg orally each day. Praziquantel increases serum concentrations of albendazole sulfoxide fourfold so combination of the two drugs seems more effective in killing protoscoleces than any alone (McManus et al, 2003). It usually is well tolerated but occasionally causes headache, nausea or abdominal discomfort. However, the efficacy of praziquantel has varied in clinical studies, and its role in primary chemotherapy has not been clearly defined (Wen et al, 1993). In a study of Mohamed et al. 41 patients with hepatic hydatid cysts were treated with either albendazole alone or in combination with praziquantel. Albendazole alone resulted in the complete disappearance of the cyst in 36 percent of subjects with treatment periods ranging from six months to two years, while the combination led to the complete disappearance of cysts in 47 percent after only two to six months of drug therapy (Mohamed et al, 1998). In another study Cobo showed that in a patient cohort with intraabdominal hydatidosis, significantly greater number of patients treated preoperatively with albendazole and praziquantel had nonviable protoscolices at the time of surgery compared to patients receiving albendazole alone, at doses of both 10 mg/kg/day and 20 mg/kg/day. (Cobo et al, 1998; Smego et al, 2005)

#### 8.1.4.5 Problems with chemotherapy

Low penetrate of the drugs through the tissue barriers to reach inner compartments of the metacestode is an important problem in clinical practice. Manterola et al. studied the plasmatic and intracystal concentrations of albendazole sulfoxide (AS) and correlated them with the viability of the scolices in patients surgically treated for hepatic hydatid cysts that received albendazole preoperatively, as an indirect way of evaluating the scolicide efficacy of the drug. The patients were given 10 mg/kg/day of albendazole for 4 days prior to the surgery. Intraoperative samples of venous blood and hydatid fluid were taken, in which the plasmatic concentration and intracystal concentration of AS were measured by means of high-performance liquid chromatography. They found that there was no association between intracystal levels of AS and the viability of the scolices and concluded that albendazole is ineffective as a scolicide agent administered preoperatively for 4 days (Manterola et al, 2005).

Since the intracystic concentration of albendazole is not correlated with the efficacy of the drug, duration of therapy may be an important issue.

#### 8.1.4.6 Outcome

Albendazole is the drug of choice for the treatment of CE. Studies that have directly compared mebendazole and albendazole have shown that mebendazole leads to an improvement in radiologic appearance in approximately 50 to 60 percent of patients, while 75 to 85 percent of patients show a response to albendazole (Horton, 1997; Teggi et al, 1993; Todorov et al, 1992). The duration of treatment is shorter than mebendazole with a better

response rate. The results of chemotherapy are affected by cyst characteristics such as size, age and location, as well as by host characteristics (El-On,2003).

### **8.1.5 Management of cysts in extra-hepatic sites**

The frequency of CE in extra-hepatic site is very low, and WHO recommendations for treatment is as follows:

#### **8.1.5.1 Lung**

The presentation of pulmonary CE varies widely, making a uniform treatment recommendation impossible. BMZ used alone showed good efficacy on small, uncomplicated lung cysts but should be avoided pre-operatively in larger lung cysts. Surgery aims at removing the parasite and treating associated pathology. It should be as conservative as possible. Radical procedures are required for extended parenchymal involvement, severe pulmonary suppuration, and complications (Isitmangil et al. 2002).

#### **8.1.5.2 Bone**

Bone involvement accounts for 0.5–2% of the total number of cases and is potentially the most debilitating form of CE. The most effective treatment is radical resection of the affected bone (Zlitni et al., 2001). Surgical procedures can be repeated because of the recurrences, and some serious complications such as spinal involvement, fistulae, acute and chronic osteomyelitis, have an extremely poor prognosis. When the hip is involved, broad resections should be carried out, with the implantation of a prosthetic hip absolutely contraindicated. CE in bone is less sensitive to ABZ than cysts at other sites and high dosage and long-term administration (years) are indicated (Brunetti et al,2010).

#### **8.1.5.3 Heart**

Cardiac involvement accounts for 0.5–2% of total cases with 10% of cases showing various symptoms. Surgery is the treatment of choice (Thameur et al., 2001). Venous filters are used to prevent dissemination. If complete removal of the cysts is possible, the prognosis is good, with a low rate of recurrence.

#### **8.1.5.4 Disseminated disease**

When cysts are widespread, usually after cyst rupture, spontaneously or during surgery, a surgical approach is often impractical. If the cysts are very large or located in or near vital organs the treatment should be combined surgery and ABZ, despite its palliative nature. However, medical treatment alone with ABZ, maintained for an indefinite length of time, is the only option available in most cases, with an acceptable response (reduction in the number and/or size of lesions) (Chawla et al., 2003). Discontinuation is often associated with recurrence.

### **8.1.6 Watch and wait**

The idea of leaving certain cyst types untreated and just monitoring them over time is a logical consequence because of two main findings:

1. A good proportion of cysts are consolidating and calcifying and becoming completely inactive without any treatment and



2. Cysts that have arrived at this stage, not compromising organ functions or causing discomfort seem to remain like this or stabilize even further( Junghanss et al,2008).

CE4 and CE5 cysts do not require any treatment if uncomplicated, CL cysts should not be treated, until their parasitic nature has been proven. Long-term follow-up of with US imaging has increased clinicians' confidence that in selected cases, i.e. when inactive cysts are not complicated, treatment can be put on hold. This decision must, however, be accompanied and verified by long-term ultrasonographic follow- up. Ten years seem to be an adequate time frame ( Junghanss et al. 2008).

#### **8.1.7 Comparisons of therapy for *E. granulosus***

There have been few studies that have directly compared the various forms of therapy for cystic echinococcosis.

A number of surgical and non-surgical options exist to treat cystic echinococcosis of the liver. Pre- and post-intervention chemotherapy with albendazole or mebendazole reduces the risk of disease recurrence and intraperitoneal seeding of infection that may develop by cyst rupture and spillage occurring spontaneously or during surgery or needle drainage. PAIR appears to be more effective treatment method with lower rates of major and minor complications, mortality, and disease recurrence. Hospitalization period is also shorter compared to patients treated surgically. PAIR is a safe and effective procedure of choice for patients with hepatic echinococcosis, and perhaps other anatomic sites of infection such as lung, peritoneum, kidney, and other viscera when the medication are ineffective. Surgery should be reserved for patients with hydatid cysts refractory to PAIR because of secondary bacterial infection or for those with difficult-to-manage cyst-biliary communication or obstruction(Smego,2005)

#### **8.1.8 Monitoring the response to therapy**

Follow-up visits, including US examination should be done every 3–6 months initially and every year once the situation is stable. Leukocyte counts and aminotransferase measurements are necessary at monthly intervals to detect adverse reactions. Serum levels of the drugs can be measured but only few laboratories have the capacity to determine plasma drug levels (Brunetti et al,2010).

##### **8.1.8.1 Ultrasound**

Radiologic changes are not entirely reliable in assessing response to therapy. However, changes seen on ultrasound that seem to correlate with effective therapy include (Khuroo et al,1993; Sciarrino et al, 1991):

1. Reduction in cyst size and volume
2. Separation of the endocyst from the pericyst and detachment or collapse of membranes leading to a split wall (water lily sign)
3. Decrease in size or number of daughter cysts and/or rupture of vesicles in multivesicular cysts
4. Decrease in fluid within the cyst and increase of the solid component, leading first to development of internal echoes within the cyst (heterogeneous echo pattern) and then to obliteration of the cyst cavity by echogenic material (pseudotumor echo pattern)

5. Thickening and irregularity of the cyst wall
6. Complete disappearance of the cyst (Figure 7, 8).

Development of new cysts, increase in its volume or its liquid component and disappearance of visibly detaching membrane can be interpreted as relaps. (Echinonet, 2005)

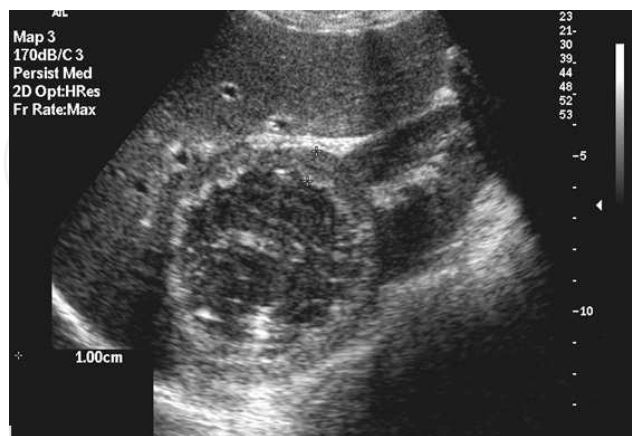


Fig. 7. Post percutaneous treatment. B-mod US shows inactive cyst containing membranes and coarse echoes. Cyst wall is markedly thickened.

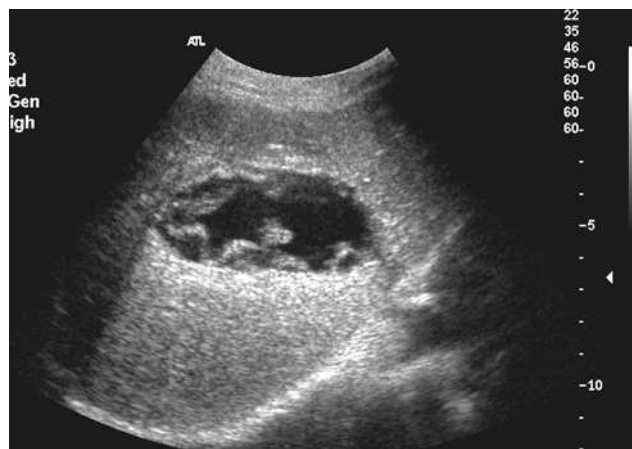


Fig. 8. Post percutaneous treatment. B-mode US shows collapsed flattened elliptical cyst (low pressure within the cyst), germinal layer detached from the cyst wall.

#### 8.1.8.2 Serology

Serologic titers usually fall 1-2 years after successful surgery but it is not a rule. Antibodies may remain elevated even many years after cyst removal (Rigano et al, 2002; Galitza et al, 2006). Specific IgE antibody titers, IgG4 antibody and arc 5-based tests have been shown to be more sensitive than other tests (Baldelli et al, 1992; Guisantes et al, 1994; Shambesh et al, 1997; Rigano et al, 2002; Galitza et al, 2006). There are also some new antigens which can be important in post-treatment monitoring. Nour et al. synthesized recombinant *Echinococcus granulosus* protoscolex recP29 antigen to be preliminarily assessed by ELISA and immunoblotting and carried out on 54 young patients with cystic echinococcosis (CE). RecP29 ELISA showed a gradual decrease of antibody concentrations in all cured-CE cases that were initially (before treatment) seropositive to this antigen or that seroconverted following treatment. A complete seronegativity was reached within 3 years post-surgery in

all of these cases. They showed that recombinant P29 protein appears prognostically useful for monitoring those post-surgical CE cases with an initial seropositivity to this marker ( Ben Nouir ,2009). In a recent study of the same author, *Echinococcus granulosus* protoscolex soluble somatic antigens (PSSAs) were assessed for their prognostic value in the serological follow-up of young patients treated for cystic echinococcosis (CE), compared to conventional hydatid fluid (HF) antigen. They stated that PSSA represents a useful candidate to carry out a serologic follow-up of CE ( Ben Nouir et al,2008).

One of the major problems of CE is the assesment of serological markers to diagnose relapses. Galitza et al. followed six cystic echinococcosis patients who underwent surgery for the removal of echinococcal cysts. All were treated with albendazole prior to and following treatment. After surgery, no cysts were detected in five of the six patients examined. Both ELISA and immunoblot analysis have been used to determine specific IgG, IgG4 and IgE activities. Total elimination of IgG and IgG4 was not achieved in any of the patients studied. Prior to the first surgery/treatment, specific IgG, IgG4 and IgE antibodies were demonstrated in all patients, except one who did not show any IgE activity. The first treatment was followed by highly elevated IgE in two patients; in one of them it was further combined with an apparent decrease in IgG activity. Repeated treatment with albendazole given 0.8-8.5 years after the first treatment/surgery was followed by either moderate or highly reduced IgE activity in two patients, respectively, and a slight increase in IgG4 in another patient. A third course of treatment, given 2-2.5 years after the second treatment, barely affected the antibody activities. The study suggests that anti-echinococcal antibody activity may remain high many years after successful cyst removal. The presence of anti-echinococcal antibodies after surgery with no cyst detection does not necessarily indicate an active echinococcal infection (Galitza et al., 2006).

## 8.2 Treatment for *Echinococcus multilocularis*

The following principles should be followed for treatment for alveolar echinococcus:

1. BMZ are mandatory in all patients, temporarily after complete resection of the lesions, and for life in all other cases,
2. Interventional procedures should be preferred to palliative surgery whenever possible,
3. Radical surgery is the first choice in all cases suitable for total resection of the lesion(s) (Brunetti et al,2010).

### 8.2.1 Antiparasitic drug treatment

Long-term BMZ treatment for several years is mandatory in all inoperable AE patients and following surgical resection of the parasite lesions. Since residual parasite tissue may remain undetected at radical surgery, including liver transplantation(LT), BMZ should be given for at least 2 years and these patients monitored for a minimum of 10 years for possible recurrence. Pre-surgical BMZ administration is not recommended except in the case of LT. The contraindications for medical treatment consist of only the life-threatening side effects of the drugs. In cases of pregnancy, the drug should be used with cautions (Brunetti et al,2010).

The dose of albendazole is 10-15mg/kg/day given in 2 divided doses with a fat-rich meal. Continuous treatment with albendazole is preferred instead of intermittent treatment and it is well tolerated for more than 20 years. If ABZ is not available or not well tolerated,

mabendazole may be given at daily doses of 40–50 mg/kg/day divided into three doses with fat-rich meals. Based on experimental data, PZQ has no place in the treatment of human AE (Marchiondo et al., 1994). Nitazoxanide has no efficacy for treatment of AE. (Kern et al., 2008). Conventional and liposomal amphotericin B have been used as a salvage treatment in a few patients who did not tolerate BMZ (Reuter et al., 2003).

During treatment, the clinician must control liver function tests initially every 2 weeks (first 3 months), then monthly (first year), then every 3 months. BMZ administration is crucial in all cases of AE, but if an increase above 5 times the upper limit of normal (ULN) of aminotransferases is observed, the following steps are recommended:

1. Check for other causes of the increase (other medication, viral hepatitis, AE-related biliary obstruction or liver abscess),
2. Monitor drug levels,
3. If ABZ sulfoxide plasma levels are higher than the recommended range of concentrations (1–3 mol/L, 4 h after morning drug intake), decrease ABZ dosage and shift to the alternative BMZ (MBZ if ABZ and vice versa) and
4. If an increase over 5×ULN persists, consult a reference centre.

Decrease of leukocyte count under  $1.0 \times 10^9/L$  indicates BMZ toxicity and warrants treatment withdrawal (Brunetti et al, 2010).

Medical therapy can improve the quality and length of survival, even though benzimidazoles are only parasitostatic and not curative. Approximately one-half the patients respond with regression or at least stabilization of their lesion. Survival rates of 53 to 80 percent at 15 years have been observed with chemotherapy alone compared to 100 percent mortality at 15 years without treatment (Ammann et al, 1990; Wilson et al, 1992; Wilson et al, 1995).

### 8.2.2 Surgery

Radical resection is the primary goal. Whenever possible complete resection of AE lesions should be performed. In principle, radical surgery should be avoided when R0- resection is not achievable. Excision of the entire parasitic lesion should follow the rules of tumour surgery, with a 2cm safety margin classified according to the quality of resection: (R0: no residue; R1: microscopic residue; R2: macroscopic residue). Lesions not confined to the liver are not a contraindication to surgery per se, but curative procedures have to meet the criteria for R0- resections as well. Lesions in other organs (e.g. brain) should be managed either by surgery or by alternative measures. Irrespective of the type of procedure, concomitant BMZ treatment is mandatory for at least 2 years. LT is contraindicated in the presence of extra-hepatic locations and if immunosuppressive drugs and/or BMZ are contraindicated.

Li et al published their experiences in treatment of human multiorgan alveolar echinococcosis by surgery and drugs. Among 17 cases, 8 cases achieved an excellent effect after taking liposomal albendazole, 3 cases received radical hepatectomy and 1 case pneumonectomy with a better effect, 1 case of palliative liver transplantation had lung metastasis and stayed on a long-term therapy of liposomal albendazole. Another case of liver transplantation received a long-term postoperative chemotherapy. And the metastases of lung and brain

were found. Three operative cases suffered serious complications in liver and brain and received a long-term chemotherapy. One of them died of serious brain complications after a 6-month follow-up. And one advanced AE patient died at home due to a refusal of any further treatment. They concluded that multi-organ AE patients may have a prolonged survival and an improved clinical outcome (Li et al,2010)

### 8.2.3 Liver transplantation

The indications for liver transplantation are:

1. Severe liver insufficiency (secondary biliary cirrhosis or Budd-Chiari syndrome) or recurrent life-threatening cholangitis,
2. Inability to perform radical liver resection
3. Absence of extra-hepatic AE locations: cases with residual AE in lung or abdominal cavity should be regarded as exceptional indications, (Scheuring et al., 2003).

Liver transplantation can be performed in cases with nonresectable lesions and severe liver compromise, but residual parasite tissue may be prone to more rapid growth because of the immunosuppression that is required following transplantation. In order to minimize the risk, post-transplant adjuvant chemotherapy with a benzimidazole is advised (Bresson-Hadni,1999). Moray et al. reported 2 patients with advanced alveolar echinococcal disease that invaded both lobes of the liver and neighboring vital structures including the inferior vena cava. Despite the technical difficulty of the surgery, both patients were successfully treated with living donor liver transplantation. The author concludes that liver transplantation should be accepted as a life-saving treatment of choice in patients with alveolar echinococcosis for whom there is no other medical or surgical treatment options (Moray et al,2009).

Liver transplantation is currently contraindicated in patients with residual or metastatic alveolar echinococcosis lesions. Hadni et al. evaluated the long-term course of such patients who underwent LT and were subsequently treated with benzimidazoles. They found that high doses of immunosuppressive drugs, the late introduction of therapy with benzimidazoles, its withdrawal due to side effects, and nonadherence to this therapy adversely affected the prognosis. They stated that potential recurrence of disease, especially in patients with residual or metastatic AE lesions, should not be regarded as a contraindication to LT when AE is considered to be lethal in the short term (Bresson-Hadni et al,2011).

### 8.2.4 Endoscopic and Percutaneous Interventions (EPI)

EPIs are indicated for complications if surgery is felt to be too high a risk and total resection of the lesions cannot be safely performed. Main indications include liver abscess due to bacterial infection of necrotic lesions, jaundice due to bile duct obstruction with or without acute cholangitis, hepatic or portal vein thrombosis and bleeding of oesophageal varices secondary to portal hypertension. But EPI spread parasite material and should be avoided if postinterventional BMZ is not possible. EPIs together with BMZ avoid palliative surgery and can improve life expectancy and quality of life of AE patients. In addition, radical resection which was not possible initially may become feasible following the shrinkage of a



necrotic cavity after percutaneous drainage. Risks of EPIs include haemorrhage (for all procedures) and internal bile leakage or prolonged bile leakage through an external drain for bile duct drainage.

### 8.2.5 Monitoring treatment

After initiation of any type of treatment, long-term follow-up by US at shorter intervals and CT and/or MRI at intervals of 2–3 years, should be planned. Progression is documented by enlargement of lesions over time. Determination of ABZ sulfoxide blood levels, 4 h after the morning dose, is recommended 1, 4 and 12 weeks after starting treatment, and 2–4 weeks after each dose adjustment with an estimated therapeutic range of 0.65–3 mol/L. ABZ dosage should be reduced if 2 sequential measurements are above 10 mol/L. Monitoring of MBZ plasma level is possible; plasma levels should be over 250 nmol/L (WHO-IWGE, 1996).

Scheuring et al. reported a case of advanced alveolar echinococcosis which was diagnosed histologically from a subcutaneous nodule with skin inflammation on the right leg. The patient showed bone metastases in the lower thoracic spine and the left third toe by hematogenic spread. The patient was treated with albendazole and remained stable for 6 years. When progression of AE occurred the therapy was changed to mebendazole, resulting in a stable condition for further 4 years. The author showed that serum levels of Anti-Em2 and anti-Em18 antibodies decreases rapidly after complete surgical removal of the lesions. (Scheuring et al., 2003). Interpretation of serological results in patients treated with BMZ without radical resection is more complex (Tappe et al., 2009).

Ammann et al showed that in patients with curative surgery, the profiles of specific antibodies against EmII/3-10 antigen normalized within 3 years but remained above the cut-off value in 40% of non-resectable group. This lack of normalization was associated with lower bioavailability of mebendazole. AE-recurrence after 'radical' surgery was associated with high anti-EmII/3-10 concentrations. Presence of anti-II/3-10/Em18-antibodies is more likely to reflect the presence of a viable metacestode with disappearance of such antibodies indicating lesions dying-out (Ammann et al., 2004).

BMZ are only parasitostatic and many studies have demonstrated that they do not kill *E. multilocularis* metacestodes (WHO-IWGE, 1996). Methods to assess early therapeutic efficacy are lacking. Recently, AE liver lesions were reported to exhibit increased F-18-fluorodeoxyglucose (FDG) uptake in positron emission tomography. This may be an important tool when there is a tendency to stop treatment. Although it does not provide direct evidence of *E. multilocularis* viability and recurrence may occur, this technique, together with the follow-up of specific serum antibodies, may support decision making and follow-up after BMZ withdrawal in highly selected patients. (Reuter et al., 2004; Stumpe et al., 2007).

## 9. Economic burden of Echinococcosis

Echinococcus is an important public health and economic problem in endemic regions of the world. In humans, CE may have various consequences, including direct costs such as diagnosis, hospitalisation, surgical or percutaneous treatments, medical therapy, post-treatment care, travel for both patient and family members as well as indirect costs such as

mortality, suffering and social consequences of disability, loss of working days or “production”, abandonment of farming or agricultural activities by affected or at-risk persons (Battelli, 2009). In the literature, there are some studies evaluating the overall economic losses due to human and animal disease. The total estimated cost of human CE in Peru is U.S.\$2,420,348 per year. Total estimated livestock-associated costs due to CE ranges from U.S.\$196,681 if only direct losses (i.e., cattle and sheep liver destruction) are taken into consideration to U.S.\$3,846,754 if additional production losses (liver condemnation, decreased carcass weight, wool losses, decreased milk production) are accounted for. An estimated 1,139 (95% CI: 861–1,489) disability adjusted life years (DALYs) are also lost due to surgical cases of CE (Moro et al,2011).

A study from Spain showed that the overall economic loss attributable to CE in humans and animals in 2005 was estimated at 148 964 534 euros. Human-associated losses were estimated at €133 416 601 and animal-associated losses at €15 532 242 (Benner et al,2010). Another study from Turkey where the mean prevalence rates of the cystic echinococcosis disease were calculated to be 7.4% in cattle, 46.3% in sheep and 10.9% in goats, the production losses in an infected ruminant were estimated as US\$ 139.2 for cattle, US\$ 13.7 for sheep, and US\$ 13.9 for goats. The nation-wide annual losses due to CE were estimated as US\$ 32.4 million (26.2–39.1) for cattle, US\$ 54.1 million (43.8–65.5) for sheep and US\$ 2.7 million (2.2–3.3) for goats. The nation-wide production losses due to CE in Turkey in 2008 were calculated as US\$ 89.2 million (72.2–107.9) (Sariozkana&Yalcin, 2009).

In a report from China quantifying the economic losses due to *Echinococcus multilocularis* and *E. granulosus* in Shiqu County, Sichuan; showed that human losses associated with treatment costs and loss of income due to morbidity and mortality, in addition to production losses in livestock due to *E. granulosus* infection was estimated to reach 218,676 U.S. dollars if only liver-related losses in sheep, goats, and yaks are taken into account. This was equal to approximately 3.47 U.S. dollars per person annually or 1.4% of per capita gross domestic product. They stated that total annual losses could be nearly 1,000,000 U.S. dollars if additional livestock production losses were assumed (Budke et al,2005).

A report from Tunisia states that Echinococcosis causes significant direct and indirect losses in both humans and animals of approximately US dollars 10-19 million annually (Majorowski et al,2005).

The awareness of the social and economic burden of the disease accelerated the use of control and prevention programmes.

## 10. Control of the disease

### 10.1 Control of *E. granulosus* infection

Prevention of cystic echinococcosis often can be achieved mostly by avoiding close contact with dogs. Careful washing of vegetables and contaminated fresh produce can also reduce infection. Prohibition of home-slaughter of sheep will prevent dogs from consuming infected viscera, thus disrupting the life cycle of the parasite(23).

In some countries where an eradication program has been attempted (eg, Iceland, Australia and New Zealand), a marked decrease in human cases has occurred (Craig et al,2006).

Vaccination of livestock and dogs, special educational programmes, development of better diagnostics for definitive hosts and human beings (including dog coproantigen detection), more effective antiparasitic treatments and the use of mathematical models to simulate best possible cost-effective interventions, will improve the hydatid control programmes (Craig et al, 2007).

Albendazole (ABZ), along with levamisole and ivermectin, is one of the most used antiparasitic drug in sheep, goats, cattle, horses and pigs. It has been shown that ABZ is not detected in the plasma of treated sheep at any time after administration, but its active metabolites, albendazole sulphoxide and albendazole sulphone are detectable for about 48 hr after administration. Oxfendazole (OXF), another benzimidazole like ABZ, has broad-spectrum activity against larval stages of gastrointestinal roundworms, tapeworms, and lungworms in many animal species (Lanusse et al, 1995).

In a study of Gavida et al, effects of Oxfendazole alone (an antiparasitic drug used in animals), Oxfendazole plus Praziquantel, and Albendazole plus Praziquantel against hydatid cysts in sheep were evaluated. They demonstrated that over 4 to 6 weeks of treatment, Oxfendazole at 60 mg, combination Oxfendazole/Praziquantel and combination Albendazole/Praziquantel were successful schemas that could be added to control measures in animals. OXF has not yet been approved for human (Gavida et al, 2010).

## 10.2 Control of *E. multilocularis* infection

Currently, there is no reliable and cost-effective method for sustainable control or eradication of *E. multilocularis* in the sylvatic cycle. Large field trials have been conducted since 1995 in Germany for mass treatment of red foxes with baits containing 50 mg of praziquantel. The baits are repeatedly distributed by light aircraft. Although first reports stated that reducing the prevalence of *E. multilocularis* in the fox population was possible, other trials suggest that long-term control of *E. multilocularis*, in the sylvatic cycle in large areas, is extremely difficult and costly (Eckert & De-Plazes, 2004). In another study in Zurich, praziquantel-containing baits were distributed every month for 2 years in six areas of 1 km<sup>2</sup> inhabited by foxes. Preliminary results indicate a significant decrease of the environmental contamination with *E. multilocularis* eggs and of parasite prevalences in voles in baited areas compared to those in control areas (Heglin et al, 2003). Monthly praziquantel given to dogs in a 10-year field trial in Alaska was effective in reducing egg contamination (Rausch et al, 1990).

In areas of endemic infection with low prevalences of *E. multilocularis* infection in dog and cat populations, mass treatment of these animals may currently be neither indicated nor feasible. In these circumstances it may be appropriate to give regular praziquantel treatment every 4 weeks only to dogs and cats having access to infected rodents (Eckert & De-Plazes, 2004).

For persons at especial risk (for example, laboratory personnel working with *E. multilocularis* eggs or handling infected definitive hosts, children after exposure to feces of infected foxes, etc.), repeated serological screening for anti-*E. multilocularis* antibodies by using highly sensitive and specific tests is recommended, with the aim of detecting an infection in an early stage or excluding it with a reasonable degree of probability. Special safety precautions

are recommended for laboratory and field workers possibly exposed to infective *E. multilocularis* eggs (Eckert et al,2001).

## 11. Vaccination

The life-cycles of *E. granulosus* and *E. multilocularis* include two hosts: an intermediate and a definitive host. Prevention of transmission to either host can reduce or even eliminate the infection in human and livestock populations. Vaccination is the most important issue for the control of the disease. Vaccination of humans would provide the most direct means to prevent echinococcosis but the economic burden might be very high. Instead, vaccination of the normal animal hosts of the parasites, indirectly achieves a reduction in human incidence by decreasing or removing the source of infective material for humans. The latter strategy would be considerably less expensive to develop and implement.(Craig et al, 2007)

The sylvatic nature of the lifecycle of *E. multilocularis* makes a vaccination approach impossible.(Zhang &McManus 2006) But a defined recombinant vaccine for ovine cystic echinococcosis (called EG95) was developed in 1996 by the groups of Marshall Lightowers and David Heath in Australia and New Zealand. The native molecule is 24.5 kDa and cloned as a 16.5 cDNA fusion peptide of 155 aminoacids with a fibronectin-like motif under the control of seven closely related genes. EG95 vaccine, contains a purified recombinant protein of the parasite oncosphere as well as an adjuvant. Echinococcus vaccines would ideally prevent oncosphere development to hydatid cysts in sheep, and thus stop the development of adult gravid tapeworms in dogs. Two doses of the vaccine are administered initially one month apart, followed by a required annual booster. This vaccine has been studied in animals and appears to afford 95 percent protection to sheep, cattle and goats in preliminary trials(Heath et al,2003; Lightowers et al,1996,2000; Zhang,2003).

The EG95 hydatid vaccine was licensed for application in China in June 2007 and is currently being assessed for registration in Argentina. Field trials are underway in Argentina in the Tehuelche communities of Chubut province and the Mapuche communities of Rio Negro province. Clinical trials are underway in Turkey with a clostridial / EG95 combination vaccine for sheep. It would be better to incorporate EG95 with an existing commercial livestock vaccine such as tetanus, leptospirosis, or sheep orf.( Bethony et al,2011)

Compared with the major advances in vaccinating sheep against *E. granulosus*, there is currently no practical vaccine available for use in canid hosts of *E. granulosus*. However, a vaccine that reduces egg production would potentially be sufficient to limit transmission in areas where the parasite is endemic. In fact, dogs are the major definitive host for *E. granulosus* and plays a very important role in transmission. Interruption of the parasite life cycle in the dog host can provides a very acceptable and cost-effective complementary method for control by vaccination.(Zhang & McManus ,2006) Nevertheless, a series of experiments to induce immunity in dogs through vaccination have been carried out, with some encouraging results.

Zhang et al. used differential-display PCR to isolate three differentially expressed sequences (egM4, egM9 and egM123) belonging to a novel egM family of proteins expressed



exclusively by mature adult worms (MAWs) of *E. granulosus* and associated with adult worm maturation and/or egg development (Zhang et al, 2003b). Subsequently, the three genes were subcloned into an expression vector that expressed the molecules as soluble glutathione S-transferase (GST) fusion proteins in *Escherichia coli*. The three fusion proteins were purified for vaccine trials in which the dogs were vaccinated and necropsied 45 days after challenge infection (Zhang et al, 2006). Compared with worms in the control dogs that received GST, the three recombinant proteins induced a high level of protection (97–100%) in terms of suppression of worm growth and, especially, of egg development and embryogenesis. This study was the first to demonstrate protection against *E. granulosus* in dogs vaccinated with recombinant proteins derived from MAWs.

Another group isolated a single copy gene (EgA31) from *E. granulosus* encoding a paramyosin-like 66-kDa fibrillar protein present in the muscles and tegument of adult worms (Fu et al, 1999). A recombinant form of EgA31 induced significant cellular immune responses in lymph nodes from dogs after intradermal injection (Fu et al, 2000; Saboulard et al, 2003). Subsequently, a polypeptide encoded by the Pst I–Hind III fragment of the complete EgA31 cDNA was shown to be the most potent antigenically during infection in the dog (Saboulard et al, 2003). Surprisingly, neither recombinant forms of EgA31 nor the Pst I–Hind III fragment were tested for protective efficacy in dogs challenged with *E. granulosus*.

## 12. Conclusion

Echinococcosis is a zoonotic parasitic disease distributed widely around the world and is an important cause of human morbidity and mortality, particularly in developing countries. Although imaging and immunological techniques for diagnosing CE and AE are improved, elimination of the disease is still difficult with current treatment modalities. Surveillance programmes and monitoring systems are very important tools in disease control as well as vaccination, although there is still no reliable and cost effective method for sustainable control or eradication of AE. Vaccination is the most reliable method in control of CE. The EG95 vaccine of livestock animals has considerable impact on management of hydatid disease in endemic areas and achieves a reduction in human incidence. Nevertheless, development of EG95 as a human vaccine would provide the most direct way of preventing the disease and be important in reduction of human morbidity and mortality caused by hydatid disease in endemic areas.

## 13. References

- Akhan. O, Gumus, B., Akinci, D., Karcaaltincaba, M., Ozmen, M.. (2007). Diagnosis and percutaneous treatment of soft-tissue hydatid cysts. *Cardiovasc. Intervent. Radiol.* 30, 419–425
- Akisu, C., Delibas, S.B., Bicmen, C., Ozkoc, S., Aksoy, U., Turgay, N., (2006). Comparative evaluation of western blotting in hepatic and pulmonary cystic echinococcosis. *Parasite* 13, 321–326.
- Aktan AO, Yalin R. (1996) Preoperative albendazole treatment for liver hydatid disease decreases the viability of the cyst. *Eur J Gastroenterol Hepatol*; 8:877–9.
- Ali M, Mahmood K, Khan P. (2009). Hydatid cysts of the brain. *J Ayub Med Coll Abbottabad*. 21(3):152–4.



- Ammann RW, Hirsbrunner R, Cotting J, et al.(1990). Recurrence rate after discontinuation of long-term mebendazole therapy in alveolar echinococcosis (preliminary results). *Am J Trop Med Hyg*; 43:506.
- Ammann RW, Eckert J. (1996). Parasitic diseases of the liver and intestine: cestodes, *Echinococcus*. *Gastroenterol Clin North Am*; 25:655-689
- Ammann, R.W., Renner, E.C., Gottstein, B., Grimm, F., Eckert, J., Renner, E.L., (2004). Immunosurveillance of alveolar echinococcosis by specific humoral and cellular immune tests: long-term analysis of the Swiss chemotherapy trial (1976-2001). *J. Hepatol.* 41, 551-559
- Avgerinos ED, Pavlakis E, Stathouloupoulos A, Manoukas E, Skarpas G, Tsatsoulis P.(2006). Clinical presentations and surgical management of liver hydatidosis: our 20 year experience. *HPB*, 8: 189-193
- Aydin, U., Yazici, P., Onen, Z., Ozsoy, M., Zeytunlu, M., Kilic, M., Coker, A., (2008). The optimal treatment of hydatid cyst of the liver: radical surgery with a significant reduced risk of recurrence. *Turk. J. Gastroenterol.* 19, 33-39.
- Baden LR, Elliott DD.(2003). Case records of the Massachusetts General Hospital. Weekly Clinicopathological exercises. Case 4-2003. A 42-year-old woman with cough, fever, and abnormalities on thoracoabdominal computed tomography. *N Engl J Med*, 348:447.
- Baldelli F, Papili R, Francisci D, et al. (1992).Post operative surveillance of human hydatidosis: evaluation of immunodiagnostic tests. *Pathology*; 24:75.
- Bartholomot, G., Vuitton, D.A., Harraga, S., Shida, Z., Giraudoux, P., Barnish, G., Wang, Y.H., MacPherson, C.N., Craig, P.S., (2002). Combined ultrasound and serologic screening for hepatic alveolar echinococcosis in central China. *Am. J. Trop. Med. Hyg.* 66, 23-29.
- Ben Nouir N, Nuñez S, Gianinazzi C, et al.(2008). Assessment of *Echinococcus granulosus* somatic protoscolex antigens for serological follow-up of young patients surgically treated for cystic echinococcosis. *J Clin Microbiol*; 46:1631.
- Ben Nouir N, Gianinazzi C, Gorcii M, et al.(2009).Isolation and molecular characterization of recombinant *Echinococcus granulosus* P29 protein (recP29) and its assessment for the post-surgical serological follow-up of human cystic echinococcosis in young patients. *Trans R Soc Trop Med Hyg*; 103:355.
- Battelli G. (2009). Echinococcosis: costs, losses and social consequences of a neglected zoonosis. *Vet Res Commun*, 33 (Suppl 1):S47-S52
- Bell, R. G. (1996). IgE, allergies and helminth parasites: a new perspective on an old conundrum. *Immunol. Cell Biol.* 74:337-345
- Benner C, Carabin H, Sánchez-Serrano LP, Budke CM & Carmena D.(2010). Analysis of the economic impact of cystic echinococcosis in Spain. *Bull World Health Organ*; 88:49-57
- Bethony JM, Cole RN, Guo X, Kamhawi S, Lightowlers M, Loukas A, Petri W, Reed S, Valenzuela JG, Hotez PJ. (2011).Vaccines to combat the neglected tropical diseases. *Immunological Reviews*, Vol. 239: 237-270
- Bickel A, Daud G, Urbach D, et al.(1998). Laparoscopic approach to hydatid liver cysts. Is it logical? Physical, experimental, and practical aspects. *Surg Endosc*; 12:1073.

- Bresson-Hadni S, Koch S, Beurton I, et al.(1999) Primary disease recurrence after liver transplantation for alveolar echinococcosis: long-term evaluation in 15 patients. *Hepatology*; 30:857.
- Bresson-Hadni, S., Vuitton, D.A., Bartholomot, B., Heyd, B., Godart, D., Meyer, J.P., Hrusovsky, S., Becker, M.C., Manton, G., Lenys, D., Miguet, J.P. (2000). A twentyyear history of alveolar echinococcosis: analysis of a series of 117 patients from eastern France. *Eur. J. Gastroenterol. Hepatol.* 12, 327–336.
- Bresson-Hadni, S., Delabrousse, E., Blagosklonov, O., Bartholomot, B., Koch, S., Miguet, J.P., Manton, G., Vuitton, D.A., (2006). Imaging aspects and non-surgical interventional treatment in human alveolar echinococcosis. *Parasitol. Int.* 55 (Suppl.), S267–S272.
- Bresson-Hadni S, Blagosklonov O, Knapp J, Grenouillet F, Sako Y, Delabrousse E, Brientini MP, Richou C, Minello A, Antonino AT, Gillet M, Ito A, Manton GA, Vuitton DA.(2011). Should possible recurrence of disease contraindicate liver transplantation in patients with end-stage alveolar echinococcosis? A 20-year follow-up study. *Liver Transpl.* Jul;17(7):855-65
- Brunetti E&Junghanss T(2009). Update on cystic hydatid disease. *Current Opinion in Infectious Diseases*, 22:497–502
- Brunetti E, Kern P. Vuitton D.A, Writing Panel for the WHO-IWGE (2010) Expert consensus for the diagnosis and treatment of cystic and alveolar echinococcosis in humans.*J.Acta Tropica*.114,1-16
- Budke CM, Jiamin Q, Qian W, Torgerson PR (2005). Economic effects of echinococcosis in a disease-endemic region of the Tibetan Plateau. *Am J Trop Med Hyg.* Jul;73(1):2-10.
- Bulut V, Ilhan F, Yucel AY, Onal S, Ilhan Y & Godekmerdan A (2001) Immunological follow-up of hydatid cyst cases. *Mem Inst Oswaldo Cruz* 96: 669–671.
- Bükte Y, Kemaloglu S, Nazaroglu H, Ozkan U, Ceviz A, Simsek M. (2004).Cerebral hydatid disease: CT and MR imaging findings. *Swiss Med Wkly.* 7;134(31-32):459-67.
- Bygott, J.M., Chiodini, P.L., (2009). Praziquantel: neglected drug? Ineffective treatment? Or therapeutic choice in cystic hydatid disease? *Acta Trop.* 111, 95–101.
- Capron, A., and J. P. Dessaint. (1992). Immunologic aspects of schistosomiasis. *Annu. Rev. Med.* 43:209–218.
- Ceballos L, Elisondo C, Bruni SS, Confalonieri A , Denegri G, Alvarez L, Lanusse C.(2010). Chemoprophylactic Activity of Flubendazole in Cystic Echinococcosis *Chemotherapy*;56:386–392
- Ceballos L, Elisondo C, Sánchez Bruni S, Denegri G, Lanusse C, Alvarez L (2011). Comparative performance of flubendazole and albedazole in cycstic echinococcus:ex vivo activity, plasma/cysts disposition and efficacy in infected mice.*Antimicrob Agents Chemother.* Sep 19
- Chawla, A., Maheshwari, M., Parmar, H., Hira, P., Hanchate, V., (2003). Imaging features of disseminated peritoneal hydatidosis before and after medical treatment. *Clin. Radiol.* 58, 818–820.
- Chowbey PK, Shah S, Khullar R, et al.(2003). Minimal access surgery for hydatid cyst disease: laparoscopic, thoracoscopic, and retroperitoneoscopic approach. *J Laparoendosc Adv Surg Tech A*; 13:159.
- Cobo F, Yarnoz C, Sesma B, et al.(1998) Albendazole plus praziquantel versus albendazole alone as a pre-operative treatment in intra-abdominal hydatidosis caused by *Echinococcus granulosus*. *Trop Med Int Health*; 3:462.

- Conn, D. B. (1994). Cestode infections of mammary glands and female reproductive organs: potential for vertical transmission? *J. Helminthol. Soc. Wash.* 61:162-168.
- Craig, P. S.P. Giraudoux, D. Shi, B. Batholomot, G. Barnish, P. Delattre, J. P. Quere, S. Harraga, G. Bao, Y. Wang, F. Lu, A. Ito, and D. A. Vuitton. (2000). An epidemiological and ecological study of human alveolar echinococcosis transmission in south Gansu, China. *Acta Trop.* 77:167-177.
- Craig PS, Larrieu E.(2006).Control of cystic echinococcosis/hydatidosis: 1863-2002. *Adv Parasitol*; 61:443
- Craig PS, McManus DP, Lightowlers MW, Chabalgoity JA, Garcia HH, Gavidia CM, Gilman RH, Armando E Gonzalez, Myriam Lorca, Cesar Naquira, Alberto Nieto, Peter M Schantz.(2007). Prevention and control of cystic echinococcosis *Lancet Infect Dis*; 7: 385-394
- Dai WJ, Waldvogel A, Jungi T, Stettler M, Gottstein B.Immunology. (2003) Inducible nitric oxide synthase deficiency in mice increases resistance to chronic infection with *Echinococcus multilocularis*. *Immunology Feb*;108(2):238-44.
- Dai WJ, Waldvogel A, Siles-Lucas M & Gottstein B (2004) *Echinococcus multilocularis* proliferation in mice and respective parasite 14-3-3 gene expression is mainly controlled by an alphabeta CD4 T-cell-mediated immune response. *Immunology* 112: 481-488.
- Davolio SA, Canossi GC, Nicoli FA, et al. (1990).Hydatid disease: MR imaging study. *Radiology*, 175:701-706.
- Demircan A, Keles A, Kahveci FO, Tulmac M, Ozsarac M.(2010). Cardiac tamponade via a fistula to the pericardium from a hydatid cyst: case report and review of the literature *J Emerg Med.*38(5):582-6.
- Deplazes, P., P. Alther, I. Tanner, R. C. A. Thompson, and J. Eckert. (1999). *Echinococcus multilocularis* coproantigen detection by enzyme-linked immunosorbent assay in fox, dog, and cat populations. *J. Parasitol.* 85:115-121.
- Derveniz C, Delis S, Avgerinos C, et al.(2005). Changing concepts in the management of liver hydatid disease. *J Gastrointest Surg*; 9:869.
- Dziri, C., Haouet, K., Fingerhut, A., (2004). Treatment of hydatid cyst of the liver: where is the evidence? *World J. Surg.* 28, 731-736.
- Dziri, C., Haouet, K., Fingerhut, A., Zaouche, A., (2009). Management of cystic echinococcosis complications and dissemination: where is the evidence? *World J. Surg.* 33, 1266-1273
- Dülger AC, Küçükoğlu ME, Akdeniz H, Avcu S, Kemik O.(2010). Case report: Budd-Chiari syndrome and esophageal variceal bleeding due to alveolar echinococcosis].*Turkiye Parazitol Derg.* 34(3):187-90
- Echinonet. Online version of Echinonews: [www.medicalweb.it/aumi/echinonet/](http://www.medicalweb.it/aumi/echinonet/) ( Accessed March 8, 2005). WHO; 2000.
- Eckert, J., F. J. Conraths, and K. Tackmann.( 2000). Echinococcosis: an emerging or reemerging zoonosis? *Int. J. Parasitol.* 30:1283-1294.
- Eckert, J.B. Gottstein, D. Heath, and F.-J. Liu. (2001). Prevention of echinococcosis in humans and safety precautions, p. 238-247. *In* J. Eckert, M. A. Gemmell, F.-X. Meslin, and Z. S. Pawlowski (ed.), WHO/OIE manual on echinococcosis in humans and animals: a public health problem of global concern. World Organisation for Animal Health, Paris, France.

- Eckert J, De-Plazes P.(2004) Biological, Epidemiological, and Clinical Aspects of Echinococcosis,a Zoonosis of Increasing Concern.*Clin Microbiology Reviews*.17(1),107-135.
- El Fortia, M., El Gatit, A., Bendaoud, M.(2006). Ultrasound wall-sign in pulmonary echinococcosis (new application). *Ultraschall Med*. 27, 553–557.
- El-On J.(2003). Benzimidazole treatment of cystic echinococcosis. *Acta Trop*; 85:243
- Ertem M, Karahasanoglu T, Yavuz N, Erguney S.(2002). Laparoscopically treated liver hydatid cysts. *Arch Surg*; 137:1170
- Filice C, Di Perri G, Strosselli M, et al. (1990). Parasitologic findings in percutaneous drainage of human hydatid liver cysts. *J Infect Dis*; 161:1290.
- Fu, Y. et al. (1999) A new potent antigen from *Echinococcus granulosus* associated with muscles and tegument. *Mol. Biochem. Parasitol*. 102, 43–52
- Fu, Y. et al. (2000) Cellular immune response of lymph nodes from dogs following the intradermal injection of a recombinant antigen corresponding to a 66 kDa protein of *Echinococcus granulosus*. *Vet. Immunol. Immunopathol*. 74, 195–208
- Gabal AM, Khawaja FI, Mohammad GA(2005). Modified PAIR technique for percutaneous treatment of high-risk hydatid cysts. *Cardiovasc Intervent Radiol*.;28(2):200-8.
- Galitza Z, Bazarsky E, Sneier R, et al.(2006). Repeated treatment of cystic echinococcosis in patients with a long-term immunological response after successful surgical cyst removal. *Trans R Soc Trop Med Hyg*; 100:126.
- Gargouri M, Ben Amor N, Ben Chehida F, et al. (1990).Percutaneous treatment of hydatid cysts (*Echinococcus granulosus*). *Cardiovasc Intervent Radiol*, 13:169.
- Gavidia CM, Gonzalez AE, Barron EA, Ninaquispe B, Llamosas M., Verastegui MR, Robinson C, Gilman RH. (2010). Evaluation of Oxfendazole, Praziquantel and Albendazole against Cystic Echinococcosis: A Randomized Clinical Trial in Naturally Infected Sheep. *Neglected tropical disease*.4(2), e616
- Gelman R, Brook G, Green J, et al.(2000). Minimal change glomerulonephritis associated with hydatid disease. *Clin Nephrol*; 53:152
- Gharbi HA, Hassine W, Brauner MW, Dupuch K.(1981). Ultrasound examination of the hydatid liver. *Radiology*, 139:459.
- Gil-Grande LA, Rodriguez-Caabeiro F, Prieto JG, et al. (1993). Randomised controlled trial of efficacy of albendazole in intraabdominalhydatid disease. *Lancet*;342:1269–72.
- Giorgio A, Tarantino L, Francica G, et al.(1992). Unilocular hydatid liver cysts: treatment with US-guided, double percutaneous aspiration and alcohol injection. *Radiology*; 184:705
- Grenard P, Bresson-Hadni S, El Alaoui S, Chevallier M, Vuitton DA & Ricard-Blum S (2001) Transglutaminase-mediated cross-linking is involved in the stabilization of extracellular matrix in human liver fibrosis. *J Hepatol* 35: 367–375.
- Godot, V., S. Harraga, M. Deschaseaux, S. Bresson-Hadni, B. Gottstein, D. Emilie, and D. A. Vuitton (1997). Increased basal production of interleukin- 10 by peripheral blood mononuclear cells in human alveolar echinococcosis. *Eur. Cytokine Netw*. 8:401–408.
- Golemanov B, Grigorov N, Mitova R, Genov J, Vuchev D, Tamarozzi F, Brunetti E(2011). Efficacy and safety of PAIR for cystic echinococcosis: experience on a large series of patients from Bulgaria. *Am J Trop Med Hyg*. 2011 Jan;84(1):48-51
- Göğüş C, Safak M, Baltaci S, Türkölmez K.( 2003).Isolated renal hydatidosis: experience with 20 cases. *J Uro*, 169:186.



- Guisantes JA, Vincente-García F, Abril MJ, et al.(1994). Total and specific IgE levels in human hydatid disease determined by enzyme immunoassay: serological follow-up after surgery. *J Investig Allergol Clin Immunol*; 4:301.
- Haynes, A. P., and J. Fletcher. 1990. Neutrophil function tests. *Baillieres Clin. Haematol.* 3:871–887.
- Harandi MF, Moazezi SS, Saba M, Grimm F, Kamyabi H, Sheikhzadeh F, Sharifi I, Deplazes P.(2011) Sonographical and Serological Survey of Human Cystic Echinococcosis and Analysis of Risk Factors Associated with Seroconversion in Rural Communities of Kerman, Iran. *Zoonoses Public Health.* May 6.1863-2378
- Heath DD, Jensen O, Lightowlers MW. (2003).Progress in control of hydatidosis using vaccination--a review of formulation and delivery of the vaccine and recommendations for practical use in control programmes. *Acta Trop*; 85:133
- Hegglin, D., P. Ward, and P. Deplazes. (2003). Anthelmintic baiting of foxes against urban contamination with *Echinococcus multilocularis*. *Emerg. Infect. Dis.* 9:1266–1272
- Hemphill A, Stadelmann B, Scholl S, et al.(2010) *Echinococcus* metacestodes as laboratory models for the screening of drugs against cestodes and trematodes. *Parasitology*; 137:569–587.
- Horton RJ.(1997). Albendazole in treatment of human cystic echinococcosis: 12 years of experience. *Acta Trop*; 64:79.
- Hosch, W., Stojkovic, M., Janisch, T., Kauffmann, G.W., Junghanss, T.(2007). The role of calcification for staging cystic echinococcosis (CE). *Eur. Radiol.* 17, 2538–2545
- Hosch, W., Junghanss, T., Stojkovic, M., Brunetti, E., Heye, T., Kauffmann, G.W., Hull, W.E., (2008). Metabolic viability assessment of cystic echinococcosis using highfield <sup>1</sup>H MRS of cyst contents. *NMR Biomed.* 21, 734–754.
- Ilica AT, kocaoglu M, zeybek N, Guven S, Adaletli I, Basgul A, coban H, Bilici A, Bukte Y.(2007). Extrahepatic Abdominal Hydatid Disease Caused by *Echinococcus granulosus*: Imaging Findings. *AJR*; 189:337–343
- Isitmangil, T., Sebit, S., Tunc, H., Gorur, R., Erdik, O., Kunter, E., Toker, A., Balkanli, K., Ozturk, O.Y. (2002). Clinical experience of surgical therapy in 207 patients with thoracic hydatidosis over a 12-year-period. *Swiss Med. Wkly.* 132, 548–552.
- Ito A, Schantz PM, Wilson JF.(1995).Em18, a new serodiagnostic marker for differentiation of active and inactive cases of alveolar hydatid disease. *Am J Trop Med Hyg*; 52:41.
- Ito, A., Craig, P.S.( 2003). Immunodiagnostic and molecular approaches for the detection of taeniid cestode infections. *Trends Parasitol.* 19, 377–381.
- Jenkins, D. J., and T. Romig. (2000). Efficacy of Droncit Spot-on (praziquantel) 4 % w/v against immature and mature *Echinococcus multilocularis* in cats. *Int. J. Parasitol.* 30:959–962.
- Jenkins DJ, Roming T, Thompson RCA.(2005). Emergence/re-emergence of *Echinococcus* spp. – a global update. *International Journal for Parasitology* 35, 1205–1219.
- Junghanss, T., Menezes da Silva, A., Horton, J., Chiodini, P.L., Brunetti, E., (2008). Clinical management of cystic echinococcosis: state of the art, problems, and perspectives. *Am. J. Trop. Med. Hyg.* 79, 301–311.
- Kern, P., Abboud, P., Kern, W., Stich, A., Bresson-Hadni, S., Guerin, B., Buttenschoen, K., Gruener, B., Reuter, S., Hemphill, A., (2008). Critical appraisal of nitazoxanide for the treatment of alveolar echinococcosis. *Am. J. Trop. Med. Hyg.* 79, 119



- Kern (2010). Clinical features and treatment of alveolar echinococcosis. *Current Opinion in Infectious Diseases*, 23:505–512
- Khuroo MS, Dar MY, Yattoo GN, et al. (1993). Percutaneous drainage versus albendazole therapy in hepatic hydatidosis: a prospective, randomized study. *Gastroenterology*; 104:1452.
- Lanusse CE, Gascon LH, Prichard RK (1995) Comparative plasma disposition kinetics of albendazole, fenbendazole, oxfendazole and their metabolites in adult sheep. *J Vet Pharmacol Ther* 18: 196–203.
- Larrieu, E. J., M. T. Costa, M. Del Carpio, S. Moguillansky, G. Bianchi, and Z. E. Yadon. (2002). A case-control study of the risk factors for cystic echinococcosis among children of Rio Negro province, Argentina. *Ann. Trop. Med. Parasitol.* 96:43–52.
- Li HT, Tuerganaili, Ayifuhanahan, Shao YM, Zhao JM, Ran B, Wen H. (2010). Clinical experiences in the treatment of human multi-organ alveolar echinococcosis by surgery and drugs. *Zhonghua Yi Xue Za Zhi.* 2;90(40):2839-42
- Lightowlers MW, Lawrence SB, Gauci CG, et al. (1996). Vaccination against hydatidosis using a defined recombinant antigen. *Parasite Immunol*; 18:457
- Lightowlers MW, Flisser CG, Gauci CG, Heath DD, Jensen O, Rolfe R. (2000) Vaccination against cysticercosis and hydatid disease. *Parasitol Today*; 16: 191–96.
- Li T, Chen X, Zhen R, et al (2010). Widespread co-endemicity of human cystic and alveolar echinococcosis on the eastern Tibetan Plateau, northwest Sichuan/ southeast Qinghai, China. *Acta Trop*; 113:248–256.
- Majorowski MM, Carabin H, Kilani M, Bensalah A. (2005). Echinococcosis in Tunisia: a cost analysis. *Trans R Soc Trop Med Hyg.* 2005 Apr;99(4):268-78.
- Manfras BJ, Reuter S, Wendland T & Kern P (2002) Increased activation and oligoclonality of peripheral CD8(1) T cells in the chronic human helminth infection alveolar echinococcosis. *Infect Immun* 70: 1168–1174
- Manterola C, Mansilla JA, Fonseca F. (2005). Preoperative albendazole and scolices viability in patients with hepatic echinococcosis. *World J Surg*; 29(6):750-3.
- Mastin A, Brouwer A, Fox M, Craig P, Guitián J, Li W, Stevens K (2011) Spatial and temporal investigation of *Echinococcus granulosus* coproantigen prevalence in farm dogs in South Powys, Wales. *Vet Parasitol.* 178(1-2):100-7.
- Mejri N, Gottstein B. (2009). *Echinococcus multilocularis* metacestode metabolites contain a cysteine protease that digests eotaxin, a CC pro-inflammatory chemokine. *Parasitol Res.* 105(5):1253-60.
- McManus DP, Zhang W, Li J, Bartley PB. (2003) Echinococcosis. *Lancet* ; 362: 1295–304.
- Macpherson, C.N., Milner, R. (2003). Performance characteristics and quality control of community based ultrasound surveys for cystic and alveolar echinococcosis. *Acta Trop.* 85, 203–209
- Marchiondo, A.A., Ming, R., Andersen, F.L., Slusser, J.H., Conder, G.A. (1994). Enhanced larval cyst growth of *Echinococcus multilocularis* in praziquantel-treated jirds (*Meriones unguiculatus*). *Am. J. Trop. Med. Hyg.* 50, 120–127.
- Meeusen, E. N., and A. Balic. (2000). Do eosinophils have a role in the killing of helminth parasites? *Parasitol. Today* 16:95–101.
- Mohamed AE, Yasawy MI, Al Karawi MA. (1998). Combined albendazole and praziquantel versus albendazole alone in the treatment of hydatid disease. *Hepatogastroenterology*; 45:1690.

- Moro PL, Budke CM, Schantz PM, Vasquez J, Santivan SJ, Villavicencio J.(2011) Economic Impact of Cystic Echinococcosis in Peru. *Neglected Tropical Disease*.5(5),e1179.
- Moray G, Shahbazov R, Sevmis S, Karakayali H, Torgay A, Arslan G, Savas N, Yilmaz U, Haberal M.(2009). Liver transplantation in management of alveolar echinococcosis: two case reports. *Transplant Proc.*;41(7):2936-8.
- Ohnishi K 1, Nakamura-Uchiyama F1, Komiya N1,Satoh S2, Ohkubo T, Umekita N.(2008). Hepatic Cystic Echinococcosis with Specific CT Findings. *Inter Med* 47: 803-805.
- Ohsaki Y, Sasaki T, Shibukawa K, Takahashi T, Osanaı S.(2007). Radiological findings of alveolar hydatid disease of the lung caused by *Echinococcus multilocularis* *Respirology* 12, 458-461
- Papanikolaou A.2008. Osseous hydatid disease. *Trans R Soc Trop Med Hyg.* 2008 Mar;102(3):233-8.
- Pedrosa I, Saiz A, Arrazola J, Ferreiros J, Pedrosa CS.(2000) Hydatid Disease: Radiologic and Pathologic Features and Complications. *RadioGraphics*, 20, 795-817.
- Peng, X., Zhang, S., Niu, J.H.(2002). Total subadventitial cystectomy for the treatment of 30 patients with hepatic hydatid cysts. *Chin. J. Gen. Surg.* 17, 529-530.
- Piarroux M, Piarroux R, Giorgi R, Knapp J, Bardonnnet K, Sudre B, Watelet J, Dumortier J, Gérard A, Beytout J, Abergel A, Mantion G, Vuitton DA, Bresson-Hadni S.(2011). Clinical features and evolution of alveolar echinococcosis in France from 1982 to 2007: Results of a survey in 387 patients. *J Hepatol*.55(5):1025-33
- Qian ZX. (1988).Thoracic hydatid cysts: a report of 842 cases treated over a thirty-year period. *Ann Thorac Surg*; 46:342.
- Rainbird, M. A., D. Macmillan, and E. N. Meeusen. (1998). Eosinophilmediated killing of *Haemonchus contortus* larvae: effect of eosinophil activation and role of antibody, complement and interleukin-5. *Parasite Immunol.* 20:93-103.
- Rausch RL, Wilson JF, Schantz PM, McMahon BJ.(1987) Spontaneous death of *Echinococcus multilocularis*: cases diagnosed serologically (by Em2 ELISA) and clinical significance. *Am J Trop Med Hyg*; 36:576.
- Rausch RL, Wilson JF, Schantz PM.(1990). A programme to reduce the risk of infection by *Echinococcus multilocularis*: the use of praziquantel to control the cestode in a village in the hyperendemic region of Alaska. *Ann Trop Med Parasitol*; 84:239
- Reiterova K, Miterpakova M, Turcekova L, Antolova D, Dubinsky P.(2005). Field evaluation of an intravital diagnostic test of *Echinococcus multilocularis* infection in red foxes. *Vet Parasitol* ,128: 65-71.
- Reuter, S., Buck, A., Grebe, O., Nussle-Kugele, K., Kern, P., Manfras, B.J., (2003). Salvage treatment with amphotericin B in progressive human alveolar echinococcosis. *Antimicrob. Agents Chemother.* 47, 3586-3591
- Reuter, S., Buck, A., Manfras, B., Kratzer, W., Seitz, H.M., Darge, K., Reske, S.N., Kern, P., (2004). Structured treatment interruption in patients with alveolar echinococcosis. *Hepatology* 39, 509-517.
- Ricard-Blum S, Bresson-Hadni S, Guerret S, Grenard P, Volle PJ, Risteli L, Grimaud JA &Vuitton DA (1996) Mechanism of collagen network stabilization in human irreversible granulomatous liver fibrosis. *Gastroenterology* 111: 172-182.
- Riley, E. M., J. B. Dixon, D. F. Kelly, and D. A. Cox. (1985). The immune response to *Echinococcus granulosus*: sequential histological observations of lymphoreticular and connective tissues during early murine infection. *J. Comp. Pathol.* 95:93-104.

- Rigano, R., E. Profumo, S. Ioppolo, S. Notargiacomo, E. Ortona, A. Teggi, and A. Siracusano. (1995). Immunological markers indicating the effectiveness of pharmacological treatment in human hydatid disease. *Clin. Exp. Immunol.* 102:281–285.
- Rigano, R., E. Profumo, G. Di Felice, E. Ortona, A. Teggi, and A. Siracusano. (1995). In vitro production of cytokines by peripheral blood mononuclear cells from hydatid patients. *Clin. Exp. Immunol.* 99:433–439.
- Rigano, R., E. Profumo, A. Teggi, and A. Siracusano. (1996). Production of IL-5 and IL-6 by peripheral blood mononuclear cells (PBMC) from patients with *Echinococcus granulosus* infection. *Clin. Exp. Immunol.* 105:456–459.
- Rigano R, Profumo E, Ioppolo S, Notargiacomo S, Teggi A & Siracusano A (1999) Serum cytokine detection in the clinical follow up of patients with cystic echinococcosis. *Clin Exp Immunol* 115: 503–507.
- Riganò R, Ioppolo S, Ortona E, et al. (2002). Long-term serological evaluation of patients with cystic echinococcosis treated with benzimidazole carbamates. *Clin Exp Immunol*; 129:485.
- Romig, T., Kratzer, W., Kimmig, P., Frosch, M., Gaus, W., Flegel, W.A., Gottstein, B., Lucius, R., Beckh, K., Kern, P. (1999). An epidemiologic survey of human alveolar echinococcosis in southwestern Germany. Romerstein Study Group. *Am. J. Trop. Med. Hyg.* 61, 566–573.
- Saboulard, D. et al. (2003) The *Echinococcus granulosus* antigen EgA31: localization during development and immunogenic properties. *Parasite Immunol.* 25, 489–501
- Safioleas MC, Misiakos EP, Kouvaraki M, et al. (2006). Hydatid disease of the liver: a continuing surgical problem. *Arch Surg*; 141:1101.
- Salama H, Farid Abdel-Wahab M, Strickland GT. (1995). Diagnosis and treatment of hepatic hydatid cysts with the aid of echo-guided percutaneous cyst puncture. *Clin Infect Dis*, 21:1372
- Santivanez S, Garcia HH. (2010). Pulmonary cystic echinococcosis. *Curr Opin Pulm Med.* 16(3):257–61.
- Sariozkana S, Yalcin C. (2009). Estimating the production losses due to cystic echinococcosis in ruminants in Turkey. *Veterinary Parasitology*, 163, 4, (26) :330–334
- Schallenberg M, Gök M, Katsounas A, Mellin KB, Steuhl KP. (2007). Keratitis caused by infection with *Echinococcus granulosus*. *Klin Monbl Augenheilkd.*; 224(3):213–5
- Schantz PM, Wilson JF, Wahlquist SP, et al. (1983). Serologic tests for diagnosis and post-treatment evaluation of patients with alveolar hydatid disease (*Echinococcus multilocularis*). *Am J Trop Med Hyg* 1983; 32:1381
- Scherer K, Gupta N, Caine WP, Panda M. (2009). Differential Diagnosis and Management of a Recurrent Hepatic Cyst: A Case Report and Review of Literature. *J Gen Intern Med* 24(10):1161–5
- Scheuring, U.J., Seitz, H.M., Wellmann, A., Hartlapp, J.H., Tappe, D., Brehm, K., Spengler, U., Sauerbruch, T., Rockstroh, J.K. (2003). Long-term benzimidazole treatment of alveolar echinococcosis with hematogenic subcutaneous and bone dissemination. *Med. Microbiol. Immunol. (Berl.)* 192, 193–195.
- Sciarrino E, Virdone R, Lo Iacono O, et al. (1991) Ultrasound changes in abdominal echinococcosis treated with albendazole. *J Clin Ultrasound*; 19:143.
- Seven R, Berber E, Mercan S, et al. (2000). Laparoscopic treatment of hepatic hydatid cysts. *Surgery*; 128:36

- Seckin, H., Yagmurlu, B., Yigitkanli, K., Kars, H.Z., (2008). Metabolic changes during successful medical therapy for brain hydatid cyst: case report. *Surg. Neurol.* 70, 186–189.
- Shambesh MK, Craig PS, Wen H, et al.(1997). IgG1 and IgG4 serum antibody responses in asymptomatic and clinically expressed cystic echinococcosis patients. *Acta Trop*; 64:53.
- Siles-Lucas, M.M., Gottstein, B.B.(2001). Molecular tools for the diagnosis of cystic and alveolar echinococcosis. *Trop. Med. Int. Health* 6, 463–475.
- Siracusano, A., Bruschi, F.(2006). Cystic echinococcosis: progress and limits in epidemiology and immunodiagnosis. *Parassitologia* 48, 65–66.
- Smego Jr., R.A., Bhatti, S., Khaliq, A.A., Beg, M.A.(2003). Percutaneous aspirationinjection-reaspiration drainage plus albendazole or mebendazole for hepatic cystic echinococcosis: a meta-analysis. *Clin. Infect. Dis.* 37, 1073–1083.
- Smego RA Jr, Sebanego P.(2005). Treatment options for hepatic cystic echinococcosis. *Int J Infect Dis*; 9:69
- Sotiraki S, Chaligiannis I.(2010) Cystic echinococcosis in Greece. Past and present. *Parasite.* 17(3):205-10
- Stankovic N, Ignjatovic M, Nozic D, et al. (2005). Liver hydatid disease: morphological changes of protoscoleces after albendazole therapy. *Vojnosanit Pregl* 62:175–9.
- Stojkovic, M., Zwahlen, M., Teggi, A., Vutova, K., Cretu, C.M., Virdone, R., Nicolaidou, P., Cobanoglu, N., Junghanss, T., (2009). Treatment response of cystic echinococcosis to benzimidazoles: a systematic review. *PLoS Negl. Trop. Dis.* 3, e524.
- Stumpe, K.D., Renner-Schneider, E.C., Kuenzle, A.K., Grimm, F., Kadry, Z., Clavien, P.A., Deplazes, P., von Schulthess, G.K., Muellhaupt, B., Ammann, R.W., Renner, E.L.(2007). F-18-fluorodeoxyglucose (FDG) positron-emission tomography of *Echinococcus multilocularis* liver lesions: prospective evaluation of its value for diagnosis and follow-up during benzimidazole therapy. *Infection* 35, 11–18.
- Sturm, D., J. Menzel, B. Gottstein, and P. Kern.(1995). Interleukin-5 is the predominant cytokine produced by peripheral blood mononuclear cells in alveolar echinococcosis. *Infect. Immun.* 63:1688–1697.
- Suwan Z. (1995). Sonographic findings in hydatid disease of the liver: comparison with other imaging methods. *Ann Trop Med Parasitol*, 89:261.
- Tappe, D., Frosch, M., Sako, Y., Itoh, S., Gruener, B., Reuter, S., Nakao, M., Ito, A., Kern, P.(2009). Close relationship between clinical regression and specific serology in the follow-up of patients with alveolar echinococcosis in different clinical stages. *Am. J. Trop. Med. Hyg.* 80, 792–797.
- Teggi A, Lastilla MG, De Rosa F. (1993).Therapy of human hydatid disease with mebendazole and albendazole. *Antimicrob Agents Chemother*; 37:1679.
- Thameur, H., Abdelmoula, S., Chenik, S., Bey, M., Ziadi, M., Mestiri, T., Mechmeche, R., Chaouch, H.(2001). Cardiopericardial hydatid cysts. *World J. Surg.* 25, 58–67.
- Todorov T, Vutova K, Mechkov G, et al.(1992). Chemotherapy of human cystic echinococcosis: comparative efficacy of mebendazole and albendazole. *Ann Trop Med Parasitol*; 86:59
- Ustunsoz B, Ugurel MS, Uzar AI, Duru NK.(2008). Percutaneous treatment of hepatic hydatid cyst in pregnancy: long-term results. *Arch Gynecol Obstet.* 277(6):547-50.




- Veit, P., B. Bilger, V. Schad, J. Schäfer, W. Frank, and R. Lucius. (1995). Influence of environmental factors on the infectivity of *Echinococcus multilocularis* eggs. *Parasitology* 110:79–86.
- Vuitton DA, Bresson-Hadni S, Laroche L, Kaiserlian D, Guerret- Stocker S, Bresson JL & Gillet M (1989) Cellular immune response in *Echinococcus multilocularis* infection in humans. II. Natural killer cell activity and cell subpopulations in the blood and in the periparasitic granuloma of patients with alveolar echinococcosis. *Clin Exp Immunol* 78: 67–74
- Vuitton, D., Zhang, S.L., Yang, Y., Godot, V., Beurton, I., Manton, G., Bresson-Hadni, S.(2006). Survival strategy of *Echinococcus multilocularis* in the human host. *Parasitol. Int.* 55(Suppl.), S51–S55
- Vuitton DA, Gottstein B (2010) *Echinococcus multilocularis* and its intermediate host: a model of parasite-host interplay. *J Biomed Biotechnol.* Mar 21.
- Wang, Q., J. Qiu, P. Schantz, J. He, A. Ito, and F. Liu. (2001). Investigation of risk factors for development of human hydatidosis among households raising livestock in Tibetan areas of western Sichuan province. *Chin. J. Parasitol. Parasit. Dis.* 19:93–96.
- Wei XL, Ding JB, Xu Y, Wen H & Lin RY (2004) Change of cytokines in mice with *Echinococcus multilocularis* infection. *Zhongguo Ji Sheng Chong Xue Yu Ji Sheng Chong Bing Za Zhi* 22: 361–364.
- Wen H, New RR, Craig PS.(1993). Diagnosis and treatment of human hydatidosis. *Br J Clin Pharmacol*; 35:565.
- Wen H, Zou PF, Yang WG, et al. (1994).Albendazole chemotherapy for human cystic and alveolar echinococcosis in north-western China. *Trans R Soc Trop Med Hyg*;88:340–3.
- Wellingshausen, N., P. Gebert, and P. Kern. (1999). Interleukin (IL)-4, IL-10 and IL-12 profile in serum of patients with alveolar echinococcosis. *Acta Trop.* 73:165–174
- WHO-Informal Working Group on Echinococcosis,( 1996). Guidelines for treatment of cystic and alveolar echinococcosis in humans. *Bull. WHO* 74, 231–242.
- WHO/OIE Manual on Echinococcosis (2001). *Echinococcosis in Humans and Animals: A Public Health Problem of Global Concern.* World Organisation for Animal Health (Office International des Epizooties) and World Health Organisation
- WHO-Informal Working Group on Echinococcosis, (2003a). PAIR: Puncture, Aspiration, Injection, Re-Aspiration. An Option for the Treatment of Cystic Echinococcosis. WHO, Geneva
- WHO-Informal Working Group on Echinococcosis, (2003b). International classification of ultrasound images in cystic echinococcosis for application in clinical and field epidemiological settings. *Acta Trop.* 85, 253–261.
- Wilson JF, Rausch RL, McMahon BJ, Schantz PM.(1992). Parasitocidal effect of chemotherapy in alveolar hydatid disease: review of experience with mebendazole and albendazole in Alaskan Eskimos. *Clin Infect Dis*; 15:234.
- Wilson JF, Rausch RL, Wilson FR. Alveolar hydatid disease. (1995).Review of the surgical experience in 42 cases of active disease among Alaskan Eskimos. *Ann Surg*; 221:315
- Yagci G, Ustunsoz B, Kaymakcioglu N, et al.(2005) Results of surgical, laparoscopic, and percutaneous treatment for hydatid disease of the liver: 10 years experience with 355 patients. *World J Surg*; 29:1670.
- Yang YR, Liu XZ, Vuitton DA, et al.(2006). Simultaneous alveolar and cystic echinococcosis of the liver. *Trans R Soc Trop Med Hyg*, 100:597–600.



- Yapici O, Erturk SM, Ulusay M, Ozel A, Halefoglu A, Karpaz Z, Basak M.(2011). Hepatic alveolar echinococcosis: a diagnostic challenge. *JBR-BTR*. 94(1):21-3.
- Yu Rong Yang YR, William GM, Craig PS & McManus DP.(2010) Impact of Increased Economic Burden Due to Human Echinococcosis in an Underdeveloped Rural Community of the People's Republic of China. *Neglected Tropical Disease*,4(9),e801.
- Zhang W, Li J & McManus DP (2003) Concepts in immunology and diagnosis of hydatid disease. *Clin Microbiol Rev* 16: 18-36
- Zhang, W. et al. (2003b) A gene family from *Echinococcus granulosus* differentially expressed in mature adult worms. *Mol. Biochem.Parasitol.* 126, 25-33
- Zhang W, McManus D.P.(2006) Recent advances in the immunology and diagnosis of echinococcosis. *FEMS Immunol Med Microbiol* 47 ,24-41
- Zhang, W. et al. (2006) Vaccination of dogs against *Echinococcus granulosus*, the cause of cystic hydatid disease in humans. *J. Infect. Dis.* 194, 966-974
- Zlitni, M., Ezzaouia, K., Lebib, H., Karray, M., Kooli, M.,Mestiri, M.(2001). Hydatid cyst of bone: diagnosis and treatment. *World J. Surg.* 25, 75-82.

IntechOpen



## **Zoonosis**

Edited by Dr. Jacob Lorenzo-Morales

ISBN 978-953-51-0479-7

Hard cover, 436 pages

**Publisher** InTech

**Published online** 04, April, 2012

**Published in print edition** April, 2012

Zoonotic diseases are mainly caused by bacterial, viral or parasitic agents although "unconventional agents" such as prions could also be involved in causing zoonotic diseases. Many of the zoonotic diseases are a public health concern but also affect the production of food of animal origin thus they could cause problems in international trade of animal-origin goods. A major factor contributing to the emergence of new zoonotic pathogens in human populations is increased contact between humans and animals. This book provides an insight on zoonosis and both authors and the editor hope that the work compiled in it would help to raise awareness and interest in this field. It should also help researchers, clinicians and other readers in their research and clinical usage.

### **How to reference**

In order to correctly reference this scholarly work, feel free to copy and paste the following:

Mesut Akarsu, Funda Ugur Kantar and Aytaç Gülcü (2012). Echinococcosis, Zoonosis, Dr. Jacob Lorenzo-Morales (Ed.), ISBN: 978-953-51-0479-7, InTech, Available from:  
<http://www.intechopen.com/books/zoonosis/echinococcosis>

**INTECH**  
open science | open minds

### **InTech Europe**

University Campus STeP Ri  
Slavka Krautzeka 83/A  
51000 Rijeka, Croatia  
Phone: +385 (51) 770 447  
Fax: +385 (51) 686 166  
[www.intechopen.com](http://www.intechopen.com)

### **InTech China**

Unit 405, Office Block, Hotel Equatorial Shanghai  
No.65, Yan An Road (West), Shanghai, 200040, China  
中国上海市延安西路65号上海国际贵都大饭店办公楼405单元  
Phone: +86-21-62489820  
Fax: +86-21-62489821

© 2012 The Author(s). Licensee IntechOpen. This is an open access article distributed under the terms of the [Creative Commons Attribution 3.0 License](https://creativecommons.org/licenses/by/3.0/), which permits unrestricted use, distribution, and reproduction in any medium, provided the original work is properly cited.

IntechOpen

IntechOpen