

# We are IntechOpen, the world's leading publisher of Open Access books Built by scientists, for scientists

6,900

Open access books available

186,000

International authors and editors

200M

Downloads

Our authors are among the

154

Countries delivered to

TOP 1%

most cited scientists

12.2%

Contributors from top 500 universities



WEB OF SCIENCE™

Selection of our books indexed in the Book Citation Index  
in Web of Science™ Core Collection (BKCI)

Interested in publishing with us?  
Contact [book.department@intechopen.com](mailto:book.department@intechopen.com)

Numbers displayed above are based on latest data collected.  
For more information visit [www.intechopen.com](http://www.intechopen.com)



## Angiostrongyliasis in the Americas

Arnaldo Maldonado Jr.<sup>1</sup>, Raquel Simões<sup>1,2</sup> and Silvana Thiengo<sup>1</sup>

<sup>1</sup>Oswaldo Cruz Foundation,

<sup>2</sup>Federal Rural University of Rio de Janeiro,  
Brazil

### 1. Introduction

Abdominal angiostrongyliasis, a parasitic disease originally from the Americas, and eosinophilic meningoencephalitis, from Asia, are caused by two species of angiostrongilids nematodes, belonging to the family Metastrongylidae Leiper, 1908. In both cases, rats are the main definitive hosts and snails are the intermediate hosts (Acha & Szyfres, 2003).

The helminth *Angiostrongylus costaricensis* Morera & Céspedes, 1971 is endemic to the Americas and is responsible for a pathological abdominal syndrome, caused by the presence of the adult helminth in the mesenteric arteries. This is microscopically characterized by eosinophilic infiltration, vascular abnormality and a granulomatous reaction (Graeff-Teixeira et al., 1987). The disease was first reported in humans by Céspedes et al. (1967) and Morera (1967) in Costa Rica. The adult worm was subsequently described from specimens recovered during surgical procedures by Morera & Céspedes (1971). The parasite's current distribution ranges from the southern United States to northern Argentina (Morera, 1988), with human cases having been reported in Costa Rica, Honduras, Colombia, Martinique, Dominican Republic, Puerto Rico, Nicaragua, Mexico, Venezuela, Guadalupe, El Salvador, Panama and Brazil (Kaminsky, 1995).

In turn, *Angiostrongylus cantonensis*, the agent that causes eosinophilic meningoencephalitis, was first described in Canton, China, by Chen (1935), and is now dispersed to various Pacific islands, Australia, Africa, and more recently, the Americas (Foronda et al., 2010). It is believed that the initial dissemination to islands in the Pacific resulted from the introduction of naturally infected rats in containers coming from Asia (Diaz, 2008). The growing flows of global trade and tourism, as well as the spread of habits and customs among countries, have enabled the dispersion of the definitive and intermediate hosts of *A. cantonensis* (Cross, 1987). Currently there are reports of human infection in the United States (New et al., 1995), Cuba (Aguiar et al., 1981), Jamaica (Slom & Johnson, 2003), Ecuador (Dorta-Contreras et al., 2010) and Brazil (Lima et al., 2009.) In particular the introduction of the *Achatina fulica* in Brazil (Thiengo et al., 2007) and *Pomacea canaliculata* (Lamarck, 1822) in China are examples of the importance of exotic snails in the spread of this helminthiasis (Lv et al., 2008).

This chapter focuses on the taxonomy, life cycle, endemic and exotic intermediate hosts, natural vertebrate hosts and geographical distribution of these *Angiostrongylus* species together with diagnosis, treatment and prophylaxis of the diseases borne by them.

## 2. Systematic and general morphology

The system for classifying the *Angiostrongylus* genus basically relies on the morphological characteristics of the rays of the copulatory bursa, host group specificity and/or place where the adult worms are located in the host.

Dougherty (1946) considered the following genera to be synonyms for the genus *Angiostrongylus* Kamensky, 1905: *Haemostrongylus* Railliet and Henry, 1907; *Parastrongylus* Bayle, 1928; *Rodentocaulus* Shul'ts, Orlov and Kutas, 1933; *Pulmonema* Chen, 1935; and *Cardionema* Yamaguti, 1941. Drozd (1970) separated species of the genus *Angiostrongylus* into two subgroups based on morphological characteristics of the caudal bursa and systematized them into two subgenera – *Angiostrongylus* and *Parastrongylus* – based on the morphology of the lateral rays of the caudal bursa. *Angiostrongylus* has a ventrolateral ray arising independently from the mediolateral and posterolateral rays, which emerge as a single trunk, and is a parasite of the right heart and pulmonary artery of carnivores. In contrast, the subgenus *Parastrongylus* parasitizes rodents and has as taxonomic characteristics the lateral rays arising in a common trunk and a cleft at the same level. A third subgroup, parasitizing insectivores, was classified as belonging to the genus *Stefanskostrongylus*, comprising species with lateral rays similar to the subgenus *Parastrongylus*, but without the gubernaculum. Anderson (1978) accepted such systematic criteria but did not mention biological aspects such as host specificity or site of infection. Furthermore, Chabaud (1972) proposed eight different genera based on the morphology of the bursal rays, types of hosts and infection site. Ubelaker (1986) reorganized the Angiostrongylidae into six genera, based on bursal morphology and on specific host groups. Nevertheless, the host-specificity criteria need to be studied further since infection has been reported of non-human primates and carnivores by *A. costaricensis* (Miller et al., 2006).

In this chapter we accept the classification of Dougherty (1946). To date, 18 species of *Angiostrongylus* have been reported around the world. Four species have been described infecting carnivores: *Angiostrongylus vasorum* Baillet, 1866; *Angiostrongylus raillieti* Travassos, 1927; *Angiostrongylus gubernaculatus* Dougherty, 1946; and *Angiostrongylus chabaudi* Biocca, 1957. In rodents, 14 species have been described: *Angiostrongylus taterone* Baylis, 1928; *A. cantonensis*; *Angiostrongylus sciuri* Merdevenci, 1964; *Angiostrongylus mackerrasae* Bhaibulaya, 1968; *Angiostrongylus sandarsae* Alicata, 1968; *Angiostrongylus petrowi* Tarjymanova and Tschertkova, 1969; *Angiostrongylus dujardini* Drozd and Doby, 1970; *Angiostrongylus schmidtii* Kinsella, 1971; *A. costaricensis*; *Angiostrongylus malaysiensis* Bhaibulay and Cross, 1971; *Angiostrongylus ryjikovi* Jushkov, 1971; *Angiostrongylus siamensis* Ohbayashi, Kamiya, and Bhaibulaya, 1979; *Angiostrongylus morerae* Robles, Navone, and Kinsella, 2008; and *Angiostrongylus lenzii* Souza et al., 2009.

*Angiostrongylus costaricensis* was described from three female specimens and one male specimen, recovered from a patient during surgery. Chabaud (1972) raised the species to the new genus *Morerastrongylus*, but this proposal was not accepted by Anderson (1978) in revising the classification of nematodes. *A. costaricensis* (Figs. 1-3; 7) is a filiform nematode. The cephalic end is round and the esophagus is club-shaped (Fig. 1). The copulatory bursa is slightly asymmetric and well developed. The dorsal ray is short and bifurcates into arms terminating in sharp tips. On its ventral side, behind its bifurcation, there is a conspicuous papilla. The lateral rays emerge from a common trunk, widely separated from the ventral

rays, and the mediolateral and the posterolateral rays are fused in their proximal half. The anterolateral ray is thicker and separates form the common trunk just after its emergence from the trunk. The externodorsal ray arises close the lateral trunk and is well separated from the dorsal ray. Its distal end is knoblike. The ventral rays are fused except at the tips and the ventrolateral ray is slightly longer than the ventrolateral one. A gubernaculum is present with two branches that come together just before they terminate in the cloaca (Fig. 7). Behind the cloacal opening, there are three papillae. The spicules are slender, striated and of equal size. The caudal extremity of the female is roughly conical, with a small projection at the tip (Fig. 3) (Morera, 1973).

*Angiostrongylus cantonensis* was initially described as *Pulmonema cantonensis* Chen, 1935, a new genus, from specimens recovered from the lungs of naturally infected rats (*Rattus norvegicus* and *Rattus rattus*) collected in Canton, China. The adult worms of *cantonensis* (Figs. 4-6; 8) are characterized by a filiform body in both sexes, tapering at the anterior end. Females are larger and more robust than males. The cephalic vesicle is absent, the oral aperture is simple, circular and surrounded by six papillae (two dorsal, two lateral and two ventral) and two lateral amphids. The esophagus is claviform and the excretory pore is posterior to the esophagus (Fig. 4). The nerve ring is anterior to the middle of the esophagus, the male caudal bursa is small and slightly asymmetric, the ventroventral rays are smaller than the ventrolateral ones, with a common origin, bifurcated at the proximal half and do not reach the bursal margins. The dorsal ray is thick, bifurcating into three branches, with digitiform externodorsal rays separated at the base. The right mediolateral ray is thinner than the left one, with the right mediolateral and posterolateral rays bifurcating at the middle of the trunk and the left mediolateral and laterolateral rays at the distal third. The lateral rays arise from a common trunk, with the ventrolateral ray being cleft-shaped and smaller than the other lateral rays (Fig. 5). The gubernaculum is conspicuous and curved. Uterine tubules spiral around the blood-filled intestine, easily seen through the transparent cuticle. The tail is long and rounded without cuticle expansion and papillae, and is slightly ventrally curved (Fig. 6) (Thiengo et al., 2010).

	<i>Angiostrongylus costaricensis</i>		<i>Angiostrongylus cantonensis</i>	
	Male	Female	Male	Female
Body lenght	19.9	32.8	22.82	32.84
Width	0.28-0.31	0.32-0.35	0.35	0.48
Widht at the base of esophagus	0.12-0.14	0.14-0.15	0.04	0.05
Esophagus	0.18-0.23	0.23-0.26	0.31	0.34
Nerve ring	-	-	0.09	0.10
Excretory pore	-	-	0.43	0.40
Spicules	0.32-0.33	-	1.29	-
Gubernaculum	-	-	0.08x0.02	-
Vuva-tail	-	0.24-0.29	-	0.19
Anus-tail	-	0.06-0.07	-	0.06
Eggs	-	-	-	0.06

Table 1. Measurements comparasion of *Angiostrongylus costaricensis* from Costa Rica (Morera, 1973) and *Angiostrongylus cantonensis* from Brazil (Thiengo et al., 2010).

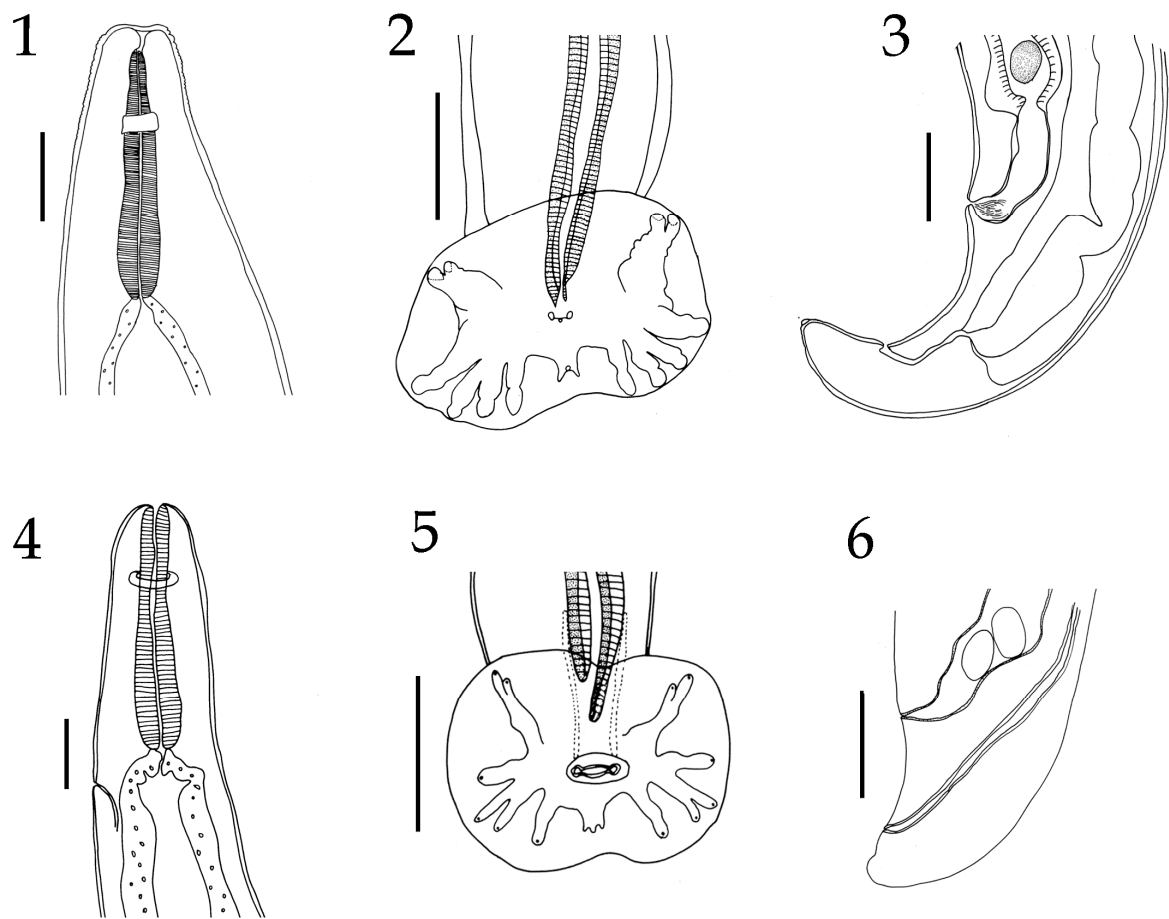


Fig. 1-3. *Angiostrongylus costaricensis*; 1. Anterior extremity, right lateral view, female. Scale bar: 50  $\mu$ m. 2. Male, caudal bursa, ventral view. Scale bar: 100 $\mu$ m .3. Female, posterior extremity, lateral view. Scale bar: 100 $\mu$ m. 4-6. *Angiostrongylus cantonensis*; 4. Anterior extremity, right lateral view, female. Scale bar: 100  $\mu$ m. 5. Male, caudal bursa, ventral view. 6. Female, posterior extremity, lateral view. Scale bar: 100  $\mu$ m.

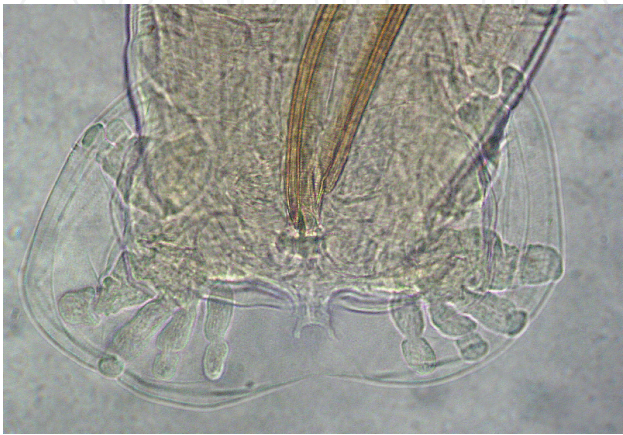


Fig. 7. Light microscopy of *Angiostrongylus costaricensis*. Scale bar: 100  $\mu$ m.





Fig. 8. Light microscopy of *Angiostrongylus cantonensis*. Scale bar: 100  $\mu$ m.

### 3. Life cycle of main species of *Angiostrongylus* infecting man

Species of *Angiostrongylus* cause a nematode infection in domestic dogs and wild mammals (Anderson, 1978). Some species can accidentally infect humans, causing characteristic clinical symptoms of the disease: *A. cantonensis* and *A. costaricensis*, which respectively cause eosinophilic meningoencephalitis and abdominal disease in humans (Graeff-Teixeira et al., 1991a; Wang et al., 2008). The biological cycle of these helminths requires an intermediate host, usually a snail, and a definitive host, most often a wild rodent. Humans participate in the biological cycle as accidental hosts, since the cycle does not complete itself in people.

Infection by *A. costaricensis* happens when the definitive host ingests the snail, which can be infected with third stage larvae ( $L_3$ ), or food contaminated with snail mucus. The larvae migrate to the ileocecal region, penetrating the intestinal wall and entering the lymphatic vessels, where they molt twice before migrating to the mesenteric arteries, where they reach sexual maturity. The females release eggs, which are carried by the bloodstream, causing embolisms in the arterioles and capillaries of the intestinal wall. The eggs hatch when they reach the first larval stage ( $L_1$ ), penetrating the intestinal lumen, where they are released in the feces. To continue the cycle, the  $L_1$  larvae must be ingested or actively penetrate the tissue of the intermediate host (Thiengo, 1996). After 19 days of the initial infection, the larvae will have molted twice (passing through the  $L_2$  and  $L_3$  stages, the latter of which is the infective stage for the definitive host). The wild rodents become infected by ingesting parasitized snails, mainly the species *Vaginulus (Sarasinula) plebeius* in Costa Rica (Morera, 1970) or *Phyllocaulis variegatus* (Semper, 1885) in Brazil (Graeff-Teixeira et al., 1989). The main rodent hosts are *Sigmodon hispidus* (Morera et al., 1970) and *Oligoryzomys nigripes* (Graeff-Teixeira et al., 1990) in these two countries, respectively. The worms reach sexual maturity in the mesenteric arterioles of the rodent *S. hispidus*, where they lay their eggs. The  $L_1$  larvae are found in the feces 24 days after experimental infection (Morera, 1973; Motta & Lenzi, 1995).

Humans become infected by eating raw infected snails or food contaminated by snail mucoid secretions containing  $L_3$  larvae. Although the helminth reaches sexual maturity and releases eggs that stimulate a granulomatous reaction in the infected person intestinal wall due to their degeneration, it does not produce  $L_1$  larvae, thus interrupting the biological cycle.

The nematode *A. cantonensis* is commonly known as the lungworm because its niche in the adult phase is in the pulmonary arteries of the definitive host, in general the rodents *R. rattus* and *R. norvegicus*. In experimental infection of *R. norvegicus*, the female worm lays eggs inside the pulmonary arterioles, where they develop into the first-stage larvae (L<sub>1</sub>), which then move to the interior of the alveoli. The larvae then migrate to the pharynx and are swallowed, pass through the gastrointestinal tract and are eliminated in the feces (Bhaibulaya, 1975; Yousif & Ibrahim, 1978). Land or freshwater snails are the principal intermediate hosts. They can become infected by ingestion of or penetration by L<sub>1</sub> larvae. The helminths then molt two times and become infective L<sub>3</sub> larvae, generally within 21 days after infection. Rats become infected by ingesting the intermediate hosts infected by L<sub>3</sub> larvae. These larvae then penetrate the intestinal wall and enter the bloodstream a few hours after being ingested. They reach the pulmonary circulation from the heart and are dispersed to various other organs by the arterial circulation. Many reach the brain and molt again, becoming L<sub>4</sub> larvae. The fifth molting into L<sub>5</sub> occurs in the subarachnoid space, from where after developing they migrate to the pulmonary arteries where they are found as of 25 days after infection. The worms then reach sexual maturity at around 35 days and the L<sub>1</sub> larvae can be found in the rodent's feces as of 42 days after the exposure to the previous generation of L<sub>1</sub> larvae (Weinstein et al., 1963; Bhaibulaya, 1975).

Humans become infected by eating raw or undercooked snails and slugs or through paratenic hosts (crabs, freshwater shrimps). In humans, the young larvae reach the brain, where they die rather than migrating further and terminating their development. This causes eosinophilic meningoencephalitis, which has neurological symptoms. Normally the infection is regenerative and does not kill the victim, but the parasitism can be serious enough to kill when there is massive exposure to infective L<sub>3</sub> larvae (Lima et al., 2009) (Fig. 9).

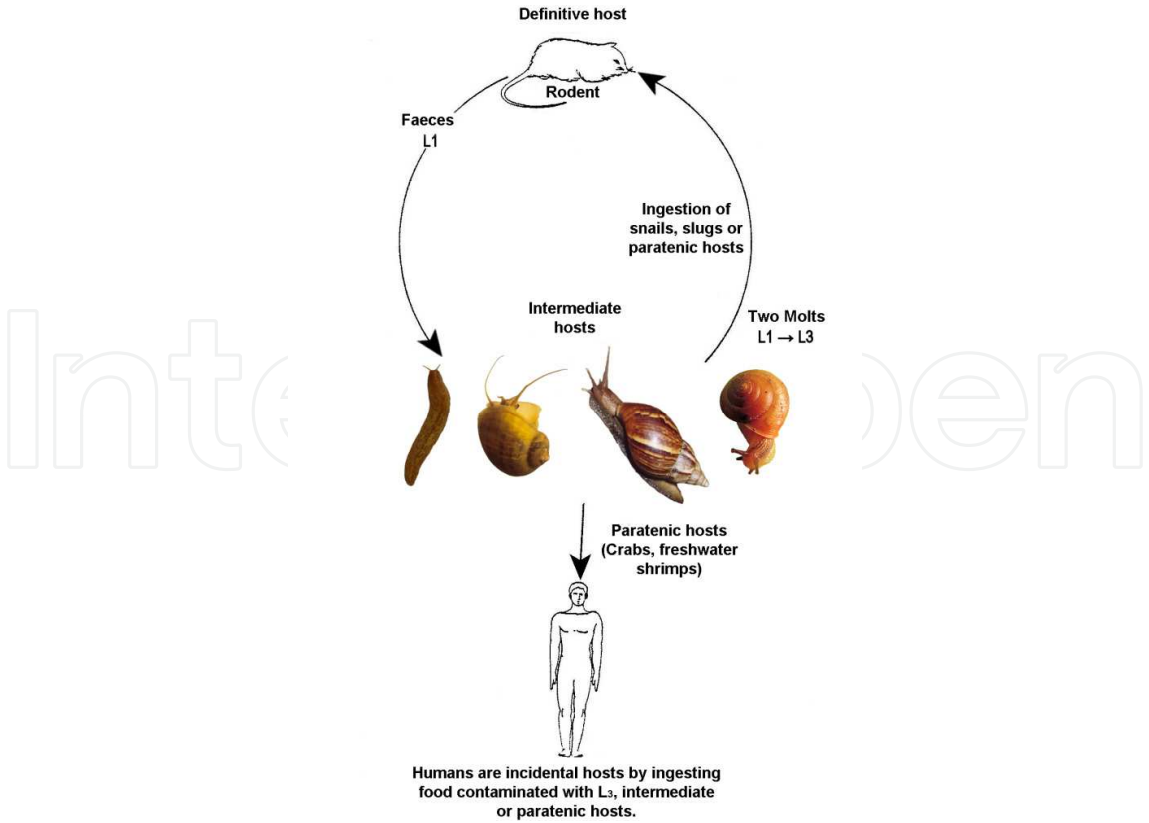


Fig. 9. Life cycle of *Angiostrongylus cantonensis*.

#### 4. Endemic and exotic mollusks as intermediate hosts

The life cycle of *A. cantonensis* (Fig. 9) involves different species of terrestrial and freshwater gastropods as intermediate hosts. Mollusks become infected either by ingestion of L<sub>1</sub> present in the rat feces or by penetration of these larvae through the body wall or respiratory pores. In the mollusk tissues the L<sub>1</sub> molts twice (L<sub>2</sub> and L<sub>3</sub>) and the period necessary for the development is around 15 days. Details of the life cycle may be seen in Cheng & Alicata, 1965, Chao et al. 1987 and Graeff-Teixeira et al. 2009.

Because the parasite displays broad nonspecificity for intermediate hosts, various species of terrestrial and freshwater mollusk species had been found naturally infected, such as: *Achatina fulica* Bowdich, 1822, *Bradybaena similaris* (Férussac, 1821), *Subulina octona* (Bruguière, 1792), *Pomacea canaliculata* (Lamarck, 1822), *Pomacea lineata* (Spix in Wagner, 1827); *Deroceras laeve* (Muller, 1774), *Pila* spp. (Wallace and Rosen, 1969; Malek and Cheng, 1974; Caldeira et al., 2007; Thiengo et al., 2010).

It is noteworthy in the epidemiology of the transmission of *A. cantonensis* the occurrence of paratenic hosts (or carrier hosts) such as land crabs, freshwater prawns, frogs and planarians. Those are passive hosts where the parasite does not undergo any development. However, they play an important role as they improve parasite opportunities (in time and space) to get the definitive host.

In China where *P. canaliculata* and *A. fulica* are widespread in the south of the country, the number of cases of eosinophilic meningoencephalitis has been increasing, and the transmission is linked to both species (Lv et al., 2008, 2009). In the last years, various outbreaks have been reported and the transmission in most of the cases was directly related to the consumption of *P. canaliculata*, considered currently the main cause of the spread of angiostrongyliasis in China (Lv et al. 2011).

The first cases of eosinophilic meningitis recorded to South America were to Brazil in 2007 and in 2008 and *A. fulica* was considered the vector for three out of the four reported cases. One of the cases reported to Pernambuco, Northeastern region, was attributed to the ingestion of undercooked *P. lineata* specimens (Caldeira et al., 2007; Lima et al., 2009; Thiengo et al., 2010). In fact, specimens of *A. fulica* have been found infected with *A. cantonensis* larvae from two of the main Brazilian regions, South and Southeast, in the last five years (Maldonado et al., 2010). Hence, the emergence of eosinophilic meningitis is a matter of concern in Brazil as it is currently experiencing the explosive phase of the invasion of *A. fulica*, recorded in 24 out the 26 states and the Federal District (Thiengo et al., 2007, Zanot et al., 2010).

The life cycle of *A. costaricensis* is quite similar to that of *A. cantonensis*, although paratenic hosts do not occur.

To continue the cycle, the L<sub>1</sub> larvae must be ingested or actively penetrate the tissue of the intermediate host (Thiengo, 1996). After 19 days of the initial infection, the larvae will have molted twice (passing through the L<sub>2</sub> and L<sub>3</sub> stages, the latter of which is the infective stage for the definitive host). The wild rodents become infected by ingesting parasitized snails, mainly the species *Vaginulus (Sarasimula) plebeius* in Costa Rica (Morera, 1970) or *Phyllocaulis variegatus* (Semper, 1885) in Brazil (Graeff-Teixeira et al., 1989; Motta & Lenzi, 1995).



5. Parasitism by *Angiostrongylus costaricensis* and *Angiostrongylus cantonensis* in naturally infected rat populations

The nematode *A. costaricensis* has little specificity for its definitive host. The main hosts involved in its life cycle in nature are rodents of the Cricetidae family, although rodents of the Heteromyidae and Muridae families have also been found to be infected (Table 2). The rodent *S. hispidus* has been indicated as the principal natural host due to its abundance, parasite prevalence rates in Panama and aspects of its ecology (Rodríguez et al., 2000).

Definitive Host	Family	Country	References
Rodentia			
<i>Sigmodon hispidus</i>	Cricetidae	Costa Rica; Panamá; United States	Morera, 1970; Tesh et al., 1973; Ubelaker & Hall, 1979
<i>Rattus rattus</i>	Muridae	Costa Rica; Panamá; Puerto Rico; Guadoulupe	Morera, 1970; Tesh et al., 1973; Andersen et al., 1986; Juminer et al., 1993;
<i>Rattus norvegicus</i>	Muridae	Guadoulupe; Dominican Republic; Puerto Rico	Juminer et al., 1993; Vargas et al., 1992; Andersen et al., 1986
<i>Liomys adspersus</i>	Heteromyidae	Panamá	Tesh et al., 1973
<i>Zygodontomys microtinus</i>	Cricetidae	Panamá	Tesh et al., 1973
<i>Oryzomys fulvescens</i>	Cricetidae	Panamá	Tesh et al., 1973
<i>Oryzomys caliginosus</i>	Cricetidae	Colombia	Malek, 1981
<i>Oligoryzomys nigripes</i> (= <i>Oryzomys eliurus</i> )	Cricetidae	Brazil	Graeff-Teixeira et al., 1990
<i>Sooretamys angouya</i> (= <i>Oryzomys Ratticeps</i> )	Cricetidae	Brazil	Graeff-Teixeira et al., 1990
<i>Proechimys</i> sp.	Echimyudae	Venezuela	Santos, 1985
Didelphimorphia			
<i>Didelphis virginiana</i>	Didelphidae	United States	Miller et.al, 2006
Carnivora			
<i>Nasua narica bullata</i>	Procyinidae	Costa Rica	Morera, 1970
<i>Procyon lotor</i>	Procyinidae	United States	Miller et.al, 2006
Primates			
<i>Hylobates syndactylus</i>	Hylobatidae	United States	Miller et.al, 2006
<i>Aotus nancymaae</i>	Aotidae	United States	Miller et.al, 2006
<i>Saguinus mystax</i>	Cebidae	Peru	Sly et al., 1982

Table 2. Vertebrate hosts infected with *Angiostrongylus costaricensis* in the Americas.

Other mammals have also been found naturally infected, such as the coati *Nasua narica bullata* in Costa Rica, in which parasitism by *A. costaricensis* was confirmed after experimental infection of *S. hispidus* from isolation of L<sub>1</sub> larvae obtained from the host’s feces, and in specimens of the marmoset *Saguinus mystax* imported from Peru after histopathological examination, which demonstrated the presence of the adult worm in the lamina propria of the host’s mesenteric artery.

Recently, *A. costaricensis* was reported parasitizing siamangs (*Hylobates syndactylus*), night monkeys (*Aotus nancymae*), raccoons (*Procyon lotor*) and opossums (*Didelphis virginiana*) in a zoo in the United States (Miller et al., 2006).

In Brazil, only two species of cricetids rodents, *O. nigripes* and *Sooretamys angouya*, are involved in transmission of *A. costaricensis*, in the Southern region of the country (Graeff-Teixeira et al., 1990). Although no evidence has been found of the participation of wild rodents in the Southeastern region (Graeff-Teixeira et al., 2010), there are various reports of abdominal angiostrongyliasis in the Midwestern and Southeastern regions (Pena et al., 1995; Magalhães et al., 1982).

In the Americas in general, the presence of *R. rattus* and *R. norvegicus* infected by *A. cantonensis* confirms the endemism of this zoonosis in Cuba, the United States, Jamaica, Puerto Rico, Dominican Republic, Haiti and Brazil (Table 3). The infection rate of these rodents is highly variable (Wang et al., 2008) and does not suggest specificity among the murids. Some findings of infected rodents in urban areas are associated with epidemiological investigations after the occurrence of cases of eosinophilic meningoencephalitis, such as in Cuba, Jamaica and Brazil (Aguiar et al., 1981; Lindo et al., 2002; Simões et al., 2011).

Definitive Host	Family	Country	References
Rodentia			
<i>Rattus rattus</i>	Muridae	Jamaica; Haiti	Lindo et al., 2002; Raccurt et al., 2003
<i>Rattus norvegicus</i>	Muridae	Cuba; United States; Jamaica; Haiti; Brazil	Aguiar et al., 1981; Campbell & Little, 1988; Lindo et al., 2002; Raccurt et al., 2003; Simões et al., 2011
<i>Neotoma floridanus</i>	Cricetidae	United States	Kim et al., 2002
Didelphimorphia			
<i>Didelphis virginiana</i>	Didelphidae	United States	Kim et al., 2002
Primates			
<i>Varecia variegata rubra</i>	Lemuridae	United States	Kim et al., 2002

Table 3. Vertebrate hosts infected with *Angiostrongylus cantonensis* in the Americas.

Kim et al. (2002) reported *A. cantonensis* infection in a lemur (*Varecia variegata rubra*), in a wood rat (*Neotoma floridanus*) and in 4 opossums (*Didelphis virginiana*) in Lousiana, United States.

How *A. cantonensis* arrived and became established in the Americas is not well established, but Diaz (2008) attributed the spread of *A. cantonensis* to the American continents to the introduction of *R. norvegicus* by containers carried by ships. In Brazil, two arrival routes of this parasite have been postulated: in parasitized rats during the country’s colonial period, when there was frequent contact with Africa and Asia (Maldonado et al., 2010) and/or by recent invasion of the African snail *A. fulica*, some two decades ago (Thiengo et al., 2007).

6. Geographic distribution of angiostrongyliasis in the Americas

The first report of abdominal angiostrongyliais was in 1952 in children in Costa Rica (Céspedes et al., 1967; Morera, 1967). Nearly 20 years later, in the same country, the parasite

was reported naturally infecting *S. hispidus* and *R. rattus* (Céspedes & Morera, 1971). Since the description of this parasite, various cases have been reported in both South and North America, in countries including Honduras (Sierra & Morera, 1972), Venezuela (Zambrano, 1973), Mexico (Zavala et al., 1974), El Salvador (Sauerbrey, 1977), Brazil (Ziliotto et al., 1975), Ecuador (Lasso, 1985), Nicaragua (Duarte et al., 1991) and Guatemala (Kramer et al., 1998).

In the United States (Ubelaker & Hall, 1979; Hulbert et al., 1992), Colombia (Malek, 1981), Panama (Tesh et al., 1973) and Caribbean islands (Juminer et al., 1993; Jeandel et al., 1998), reports of the presence of the parasite in the definitive host preceded the finding of cases of abdominal angiostrongyliasis. It is thus possible that the distribution of this zoonosis in the Americas and the world at large is more ample than currently known.

Angiostrongyliasis caused by *A. cantonensis* was originally reported in Asia. It has been postulated that this zoonosis spread to the Americas in the twentieth century (Pascual et al., 1981), where there have been reports of sporadic outbreaks. The first report of eosinophilic meningoencephalitis occurred in Cuba (Aguiar et al., 1981), followed by United States (News et al., 1995), Jamaica (Barrow et al., 1996), Brazil (Lima et al., 2009) and more recently Ecuador (Dorta-Contreras et al., 2011). After the reports of parasitism in humans, the naturally infected definitive host was identified, except in Ecuador. In contrast, in Puerto Rico, Dominican Republic and Haiti, only the parasite infecting snails and/or rats has been reported (Andersen et al., 1986; Vargas et al., 1992; Raccurt et al., 2003), with no cases of diseased reported so far.

## 7. Diagnostic methods for detection of abdominal angiostrongyliasis and eosinophilic meningoencephalitis

Abdominal angiostrongyliasis is caused by the presence of *A. costaricensis* worms in the mesenteric arteries of the ileocecal plexus, where they cause a predominantly eosinophilic granulomatous reaction in the mesentery, intestinal wall and lymph nodes. Although it is not generally a serious disease and frequently clears up spontaneously, its evolution to occlusion or perforation of the intestine can lead to death (Palomino et al., 2008). The main clinical signs include acute eosinophilic abdominal pain and occasionally fever (Morera, 1995). Palpation of the tumoral mass in the lower right abdominal quadrant, vomiting and anorexia suggest parasitism, but definitive diagnosis is only confirmed by observation of the worms inside the arteries after histological examination of biopsy material (Graeff-Teixeira et al., 1991). Laboratory diagnosis includes the serological latex agglutination test (Morera & Amador, 1998), enzyme-linked immunosorbent assay (ELISA) (Graeff-Teixeira et al., 1997) and indirect immunofluorescence assay (Abrahams-Sandi et al., 2011). Nevertheless, the choice of the antigen and specificity of the tests need improvement.

Presumptive diagnosis of angiostrongyliasis caused by *A. cantonensis* is mainly based on the clinical signs presented by the patients, which include eosinophilic meningitis, eosinophilic encephalitis and ocular angiostrongyliasis. The symptoms in general are not very specific and can include headache, vomiting, fever, history of paresthesia and neck stiffness (Sawanyawisuth & Sawanyawisuth, 2008). Results of laboratory analysis of the blood and cerebrospinal fluid showing readings of eosinophils above 10%, including serological tests, despite their low sensitivity (Eamsobhana & Yong, 2009), along with diagnosis by cerebral imaging, help to confirm the infection (Kampittaya et al., 2000). The information reported by

the patient, such as ingestion of the intermediate host snail or raw or undercooked paratenic hosts, is important to substantiate the diagnosis of eosinophilic meningoencephalitis caused by *A. cantonensis*. Confirmation of the parasitism by observation of the worm in the cerebrospinal fluid is not common (Yii, 1976; Punyagupta et al., 1975). More recently, infection has been confirmed by the presence of the helminth's DNA in the cerebrospinal fluid by real-time polymerase chain reaction (PCR) (Lima et al., 2009). The inflammatory process of the subarachnoid space and meninges is accompanied by intense eosinophilia and associated with an elevation in the number of eosinophils in the peripheral blood and cerebrospinal fluid (Tseng, et al., 2011).

## 8. Treatment of the infections and prophylaxis

The use of anthelmintics such as diethylcarbamazine, thiabendazole and levamisole to treat abdominal angiostrongyliasis is not recommended, because it can induce erratic migration of the worms and/or worsening of the lesions due to the inflammatory response to the death of the helminths at the infection sites (Morera & Bontempo, 1985). Therefore, any time possible, the treatment of choice is surgery (Cépedes et al., 1967).

The main procedure to treat eosinophilic meningoencephalitis is based on reduction of the symptoms by the use of analgesics and/or corticoids and careful removal of the cerebrospinal fluid (CSF) at frequent intervals (Slom et al., 2003). The combined use of albendazole and prednisolone for two weeks has been shown to be safe and effective (Chotmongkol et al., 2004). Generally, infections caused by *A. cantonensis* are slight or self-limiting and the prognosis is good. In a few weeks most of the symptoms disappear and rarely leave prolonged effects.

Prophylaxis for angiostrongyliasis requires some precautions: (a) consume snails or animals that can be intermediate or paratenic hosts only after adequate cooking; (b) do not consume raw vegetables that have not been hygienized by soaking in a sodium hypochlorite solution; (c) control the populations of snail vectors and synanthropic rats near houses and in planted fields; and (d) provide information to people on the ways *A. costaricensis* and *A. cantonensis* are transmitted as well as the measures to follow to minimize the risk of infection by the parasite.

## 9. Conclusion

Under public health point of view, the spread of *A. costaricensis* and *A. cantonensis* in the New World and the presence of rats and snails in the peridomestic area poses substantial risk for future outbreaks. Therefore, reinforce the need to awareness the population about the risk of contracting angiostrongyliasis and healthcare providers should consider these parasites in the American continent to detect in time and adequate medical response. Moreover, surveillance and control of intermediate and definitive host as well as health education should be done to avoid human infections.

As for eosinophilic meningitis the epidemiology of its transmission has got importance for travel medicine currently. The increasingly widespread travel of people worldwide has led to the detection of many imported cases of this zoonosis and noteworthy for the differential diagnosis of neurological disease in travel medicine (Graeff-Teixeira et al., 2009).



## 10. References

- Abrahams-Sandi, E., Mesén-Ramírez, P., Suarez-Chacón, D. & Fernández-Quesada, K. (2011). An indirect immunofluorescence antibody test employing whole eggs as the antigen for the diagnosis of abdominal angiostrongyliasis. *Memórias do Instituto Oswaldo Cruz*, Vol.106, No.4, pp. 303-304
- Acha, P. & Szyfres, B. (2003). *Zoonoses and Communicable Diseases Man and Animals* (Third edition). Pan American Health Organization, Scientific and Tech. Publications, Washington, DC
- Aguiar, P., Morera, P. & Pascual, J. (1981). First record of *Angiostrongylus cantonensis* in Cuba. *American Journal of Tropical Medicine and Hygiene*, Vol. 30, No. 5, pp. 963-965
- Alicata, J. & Jindrak, K. (1970). *Angiostrongylosis* in the Pacific and Southeast Asia. Chales C.Thomas, Springfield, Illinois.
- Alicata, J. (1965). Biology and distribution of the rat lungworm, *Angiostrongylus cantonensis*, and its relationship to eosinophilic meningoencephalitis and other neurological disorders of man and animals. *Advances in Parasitology*, Vol.3, pp. 223-248
- Alicata, J. (1991). The discovery of *Angiostrongylus cantonensis* as a cause of human eosinophilic meningitis. *Parasitology Today*, Vol.7, No. 6,pp.151-153
- Andersen, E., Gubler, D., Sorensen, K., Beddard, J. & Ash, L. (1986). First report of *Angiostrongylus cantonensis* in Puerto Rico. *American Journal of Tropical Medicine and Hygiene*, Vol. 35, No.2, pp. 319-322
- Anderson, R. C. 1978. Keys to genera of the Superfamily Metastrongyloidea, In *CIH Keys to the nematodes parasites of vertebrates*, R.C. Anderson, A.G. Chabaud & S. Willmott (Eds.), 1-40, Common wealth Agricultural Bureaux, Farnham Royal, Bucks, U. K.
- Archer, C. , Appleton, C. Mukaratirwa, S. & Hope, K. (2011). The rat lung-worm *Angiostrongylus cantonensis*: A first report in South Africa. *South Africa Medical Journal*, Vol.101, No.3, pp. 174-175
- Asato, R., Taira, K., Nakamura, M., Kudaka, J., Itokazu, K. & Kawanaka, M. (2004). Changing epidemiology of *Angiostrongylus cantonensis* in Okinawa Prefecture, Japan. *Japanese Journal of Infectious Diseases*, Vol.57, pp.184-186
- Ash, L. (1976). Observations on the role of mollusks and planarians in the transmission of *Angiostrongylus cantonensis* infection to man in New Caledonia. *Revista de Biologia Tropical*, Vol.24, No. 1, pp.163-174
- Bahaibulaya, M. (1975). Comparative studies on the life history of *Angiostrongylus mackerrasae* Bhaibulaya 1968 and *A. cantonensis* (Chen, 1935). *International Journal of Parasitology*, Vol.5, pp. 7-20
- Barrow, K., St Rose, A. & Lindo, J. (1996). Eosinophilic meningitis: is *Angiostrongylus cantonensis* endemic in Jamaica? *West Indian Medical Journal*, Vol. 45, No.2, pp. 70-71
- Caldeira, R., Mendonça, C., Gouveia, C., Lenzi, H., Graeff-Teixeira, C., Lima, W., Mota, E., Pecora, I., Medeiros, A. & Carvalho, O. (2007). First Record of molluscs naturally infected with *Angiostrongylus cantonensis* (Chen, 1935) (Nematoda: Mestastromylidae) in Brazil. *Memórias do Instituto Oswaldo Cruz*, Vol.102, No.7, pp.887-889

- Campbell, R. & Little, M. (1988). The finding of *Angiostrongylus cantonensis* en rats in New Orleans. *American Journal of Tropical Medicine and Hygiene*, Vol. 38, pp.568-573
- Céspedes, R., Salas, J., Mekbel, S., Troper, L., Mullner, F & Morera, P. (1967). Granulomas entéricos y linfáticos con intensa eosinofilia tisular producidos por um estrongilídeo (*Strongylata*). *Acta Médica Costarricense*, Vol. 10, pp. 235-255
- Chabaud, A. (1972). Description de *Stefanskostrongylus dubosti* n sp. parasite du Potamogale et essai de classification des Nématodes Angiostrongylinae. *Annales de Parasitologie Humaine et Comparée*, Vol. No., pp. 735-744
- Chao, D., Lin, C-C. & Chen, Y-A. (1987). Studies on growth and distribution of *Angiostrongylus cantonensis* larvae in *Ampullarium canaliculatus*. *Southeast Asian Journal of Tropical Medicine and Public Health*, Vol.18, No.7, pp. 248-252
- Chen, H.T., 1935. Un nouveau nematode pulmonare. *Pulmonema cantonensis*, N. G., N sp. des rats de Canton. *Annales de Parasitologie Humaine et Comparée*, Vol.13, No.4, 312-317
- Cheng, T. & Alicata, J. (1965). On the modes of infection of *Achatina fulica* by the larvae of *Angiostrongylus cantonensis*. *Malacologia*, Vol.2, pp.267-274
- Chotmongkol, V., Wongjitrat, C., Sawadpanit, K. & Sawanyawisuth, K. (2004). Treatment of eosinophilic meningitis with a combination of albendazole and corticosteroid. *Southeast Asian Journal of Tropical Medicine and Public Health*, Vol. 35, No. 1, pp.172-174
- Cross, J. & Chi, C. (1982). ELISA for the detection of *Angiostrongylus cantonensis* antibodies in patients with eosinophilic meningitis. *Southeast Asian Journal of Tropical Medicine and Public Health*, Vol.13, No. 1, pp. 73-76
- Cross, J. (1987). Public health importance of *Angiostrongylus cantonensis* and its relatives. *Parasitology Today*, Vol. 3, No. 12, pp.367-369
- Dorta-Contreras, A., Padilla-Docal, B., Moreira, J., Robles, L., Aroca, J., Alarcón, F. & Bu-Coifu-Fanego, F. (2011). *Arquivo de Neuropsiquiatria*, Vol. 69, No.3, pp. 466-469
- Diaz, J. (2008). Helminth eosinophilic meningitis: emerging zoonotoc diseases in the South. *Journal of the Louisiana State Medical Society*, Vol.160, No. 6, pp. 333-342
- Dougherty, E. (1946). The genus *Aelulostrongylus* Cameron, 1927 (Nematoda : Metastrongylidae) and its relatives withj description of parafilaroides gen. Nov., and *Angiostrongylus gubernaculatus* sp. nov. *Proceedings of the Helminthological Society of Washington*, Vol.13, pp. 16-26
- Drozdz, J. (1970). Révision de le systématique du genre *Angiostrongylus* Kamensky, 1905 (Nematoda :Matastronguloidea). *Annales de Parasitologie (Paris)*, Vol.45, No.5, pp. 597-603
- Duarte, Z., Moreira, P. & Vuong, P. (1991). Abdominal angiostrongyliasis in Nicaragua: a clinico-pathological study on a series of twelve case reports. *Annales de Parasitologie Humaine et Comparée*, Vol.66, No.6, pp. 259-262
- Eamsobhana, P. & Yong, H. (2009). Immunological diagnosis of human angiostrongyliasis due to *Angiostrongylus cantonensis* (Nematoda: Angiostrongylidae). *International Journal of Infectious Diseases*, Vol.13, No.4, pp. 425-31
- Foronda, P., López-González, M., Miquel, J., Torres, J., Segovia, M., Abreu-Costa, N., Casanova, J., Valladares, B., Mas-Coma, S., Bargues, M. & Feliu, C. (2010). Finding

- of *Parastrongylus cantonensis* (Chen, 1935) in *Rattus norvegicus* in Terrife, Canary Island (Spain). *Acta Tropica*, Vol.114, pp. 123-127, 2010
- Graeff-Teixeira, C., Camillo-Coura, L. & Lenzi, H. (1987). Abdominal angiostrongyliasis-an underdiagnosed disease. *Memórias do Instituto Oswaldo Cruz*, Vol.82, No.4, pp 353-354
- Graeff-Teixeira, C., Thomé, J., Pinto, S., Camillo-Coura, L. & Lenzi, H. (1989). *Phyllocaulis variegatus* – an intermediate host of *Angiostrongylus costaricensis* in South Brazil. *Memórias do Instituto Oswaldo Cruz*, Rio de Janeiro, Vol.84, No.1, pp. 65-68
- Graeff-Teixeira, C., Pires, F., Machado, R., Camillo-Coura, L. & Lenzi, L. (1990). Identificação de Roedores Silvestres como hospedeiros do *Angiostrongylus costaricensis* no sul do Brasil. *Revista do Instituto de Medicina Tropical de São Paulo*, Vol.32, No.3, pp. 147-150
- Graeff-Teixeira, C., Camillo-Coura, L., Lenzi, H. (1991a). Angiostrongilíase Abdominal – Nova Parasitose no Sul do Brasil. *Revista da Associação Médica do Rio Grande do Sul*, Porto Alegre, Vol.35, No.2, pp. 91-98
- Graeff-Teixeira, C., Camillo-Coura, L., Lenzi, H. (1991b). Histopathological criteria for the diagnosis on abdominal angiostrongyliasis. *Parasitology Research*, Vol.77, No.7, pp. 606-611
- Graeff-Teixeira, C., Agostini, A., Camillo-Coura, L. & Ferreira-da-Cruz, M. (1997). Seroepidemiology of abdominal angiostrongyliasis: the standardization of an immunoenzymatic assay and prevalence of antibodies in two localities in southern Brazil. *Tropical Medicine & International Health*, Vol.2, No.3, pp. 254-260
- Graeff-Teixeira, C., Silva, A. & Yoshimura, K. (2009). Update on Eosinophilic Meningoencephalitis and its Clinical Relevance. *Clinical Microbiology Reviews*, pp.322-348
- Jeandel, R., Fortier, G., Pitre-Delaunay, C. & Jouannele, A. (1988). *Angiostrongylus intetsinale* à *Angiostrongylus costaricensis*. A propôs d`um case em Martinique. *Gastroentérologie Clinique et Biologique*, Vol. 2, No. , pp. 390-393
- Juminer, B., Borel, G., Mauleon, H., Durette-Desset, M., Raccurt, C., Roudier, M., Nicolás, M. & Péres, J. (1993). Natural murine infestation by *Angiostrongylus costaricensis* Morera and Céspedes, 1971, in Guadalupe. *Bulletin de la Societé de Pathologie Exotique*, Vol.86, No.5, pp. 502-505
- Kaminsky, R., Caballero, R. & Andrews, K. (1995). Presencia de *Angiostrongylus costaricensis* en Honduras y sus relaciones agro-ecológicas y humanas. *Parasitología al Día*, Vol. 19, No. 1, pp. 81-90
- Kanpittaya, J., Jitipmolmard, S., Tiamkao, S. & Mairiang, E. (2000). MR findings of eosinophilic meningoencephalitis attributed to *Angiostrongylus cantonensis*. *Am. J. Neuroradiol*, Vol.21, No.6, pp. 1090-1094
- Kliks, M. & Palumbo, N. (1992). Eosinophilic meningitis beyond the Pacific basin: The global dispersal of a peridomestic zoonosis caused by *Angiostrongylus cantonensis*, the nematode lungworm of rats. *Social Science and Medicine*, Vol.34, No.2, pp.199-212
- Kramer, M., Greer, G., Quinonez, J., Padilla, N., Hernandez., Barana, B., Lorenzana, R., Moreira, P., Hightower, A., Eberhard, M. & Herwaldt, B. (1998). First reported outbreak of abdominal angiostrongyliasis. *Clinical Infectious Diseases*, Vol.26, No.2, pp. 365-372


- Lasso, R. 1985. Angiostrongyliasis em Ecuador. *Universidad de Guayaquil Comisión de Ciencia y tecnologia Boletín informativo*, No.3
- Lima, A., Mesquita, S., Santos, S., Aquino, E., Rosa, L., Duarte, F., Teixeira, A., Costa, Z. & Ferreira, M. (2009) Alicata disease: neuroinfestation by *Angiostrongylus cantonensis* in Recife, Pernambuco, Brazil. *Arquivos de Neuropsiquiatria*, Vol.67, No.4, pp. 1093-1096
- Lindo, J., Waugh, C., Hall, J., Cunningham-Myrie, C., Ashley, D., Eberhard, M., Sullivan, J., Bishop, H., Robinson, D., Holtz, T. & Robinson, R. (2002). Enzootic *Angiostrongylus cantonensis* in rats and snails after outbreak of human eosinophilic meningitis Jamaica. *Emerging Infectious Diseases*, Vol.8, No.3, pp. 324-326
- Lv S, Zhang Y, Steinmann P. & Zhou XN 2008. Emerging angiostrongyliasis in mainland China. *Emerging Infectious Diseases*, Vol.14, No.1, pp.161-164
- Lv, S., Zhang, Y, Liu H., Zhang, C., Steinmann, P., Zhou, X. & Utzinger, J. (2009). *Angiostrongylus cantonensis*: morphological and behavioral investigation within the freshwater snail *Pomacea canaliculata*. *Parasitology Research*, Vol.3, No.2, 368
- Lv, S., Zhang, Y., Steinmann, P., Yang, G-J., Yang, K., Zhou, X-N. & Utzinger, J. (2011). The emergence of angiostrongyliasis in the People's Republic of China: the interplay between invasive snails, climate change and transmission dynamics. *Freshwater Biology*, Vol.56, No.4, pp. 717-734
- Magalhães, A., Andrade, G., Koh, L., Soares, M., Alves, E., Tubino, P., Santos, F. & Raick, A. (1982). Novo caso de angiostrongilose abdominal. *Revista do Instituto de Medicina Tropical de São Paulo*, Vol.24, No.4, pp. 252-256
- Maldonado Jr., A, Simões, R., Oliveira, A., Motta, E., Fernandez, M., Pereira, Z., Monteiro, S., Torres, E., Thiengo, S. (2010) First report of *Angiostrongylus cantonensis* (Nematoda: Metastrongylidae) in *Achatina fulica* (Mollusca: Gastropoda) from Southeast and South regions of Brazil. *Memórias do Instituto Oswaldo Cruz* Vol.105, No.7, pp. 938-941
- Malek, E. & Cheng, T. (1974). *Medical and Economic Malacology*. Academic Press, New York, London
- Malek, E. (1981). Presence of *Angiostrongylus costaricensis* Morera and Cépedes, 1971 in Colombia. *The American Journal of Tropical Medicine and Hygiene*, Vol.30, No.1, pp. 81-83
- Miller, C., Kinsella, J., Garner, M., Evans, S., Gullet, P. & Schmidt, R. (2006). Endemic infections of *Parastrongylus* (= *Angiostrongylus*) *costaricensis* in two species of non human primates, raccons, and opossum from Miami, Florida. *Journal of Parasitology* Vol.92, No.2, pp. 406-408
- Morera, P. (1967). Granulomas entericos y linfaticos con intensa eosinophilia tisular producidos por um strongilideo (Strongylata; Railliet y Henry, 1913): II. Aspectos parasitológico. *Acta Médica Costarricense*, Vol. 10, pp. 257-265
- Morera, P. (1970). Investigación del huésped definitivo de *Angiostrongylus costaricensis* (Morera y Céspedes, 1971). *Boletín Chileno de Parasitología*, Santiago, Vol.25, pp.133-134
- Morera, P. (1973). Life History and Redescription of *Angiostrongylus costaricensis* Moreira and Céspedes. *The American Journal of Tropical Medicine and Hygiene*, Vol.22, No.5, pp. 613-621



- Morera, P. (1988). Angiostrongilosis abdominal: um problema de salud pública? *Revista de la Sociedad Guatemalteca de Parasitología y Medicina Tropical*, Vol.2, No.1, pp. 9-11
- Morera, P. (1995). Abdominal angiostrongyliasis, In: *Enteric infection: intestinal helminths*, P. Morera (Ed.), 225-230, Chapman & Hall, London
- Morera, P. & Céspedes, R. (1971). *Angiostrongylus costaricensis* n. sp. (Nematoda: Metastrongyloidea), a new lungworm occurring in man in Costa Rica. *Revista de Biología Tropical*, Vol.50, No.2, pp. 377-394
- Morera, P. & Bontempo, I. (1985). Accion de lagunos antohelminéticos sobre *Angiostrongylus costaricensis*. *Revista Medica del Hospital Nacional de Niños Costa Rica*, Vol.20, pp.165-174
- Morera, P. & Amador, J. (1998). Prevalencia de la angiostrongilosis abdominal y la distribución estacional de la precipitación. *Revista Costarricense de Salud Pública*, Vol.7, No.13, pp. 1-14, ISSN 1409-1429
- Motta, E. & Lenzi, H. (1995). *Angiostrongylus costaricensis* life cycle: a new proposal. *Memórias do Instituto Oswaldo Cruz*, Vol.90, No.6. PP.707-709
- Narain, K., Mahanta, J., Dutta, R. & Dutta, P. (1994). Paddy Field dermatitis in Assam: A cercarial dermatitis. *Journal of Communicable Disease*, Vol.26, No.1, pp.26-30
- Narain, K., Mahanta, J., Dutta, R. & Dutta, P. (1994). Paddy Field dermatitis in Assam: A cercarial dermatitis. *Journal of Communicable Disease*, Vol.26, No.1, pp.26-30
- New, D., Little, M. & Cross, J. (1995). *Angiostrongylus cantonensis* infection from eating raw snails. *The New England Journal of Medicine*, Vol.332, No.16, pp. 1105-1106
- Palominos, P., Gasnier, R., Rodriguez, R., Agostini, A. & Graeff-Teixeira, C. (2008). Individual serological follow-up of patients with suspected or confirmed abdominal angiostrongyliasis. *Memórias do Instituto Oswaldo Cruz*, Vol.103, No.1, pp. 93-97
- Pascual, J., Bouli, R. & Aguiar, H. (1981). Eosinophilic meningoencephalitis in Cuba, caused by *Angiostrongylus cantonensis*. *The American Journal of Tropical Medicine and Hygiene*, Vol. 30, No. 5, pp. 960-962
- Prociv, P., Spratt, D. & Carlisle, M. (2000). Neuro-angiostrongyliasis: unresolved issues. *International Journal of Parasitology*, Vol.30, No.12-13, pp.1295-1303
- Punyagupta, S., Juttijudata, P. & Bunnag, T. (1975). Eosinophilic meningitis in Thailand. Clinical studies of 484 typical cases probably caused by *Angiostrongylus cantonensis*. *The American Journal of Tropical Medicine and Hygiene*, Vol.21, No.6, pp. 921-931
- Raccurt, C., Blaise, J. & Durette-Desset, M. (2003). Présence d'*Angiostrongylus cantonensis* en Haïti. *Tropical Medicine and International Health*, Vol.8, No.5, pp. 423-426
- Rodríguez, B., Gonzáles, R. & Chinchilla, M. (2000). Helmintos parásitos de la rata *Sigmodon hispidus* (Rodentia: Cricetidae) de un hábitat estacional y otro perenne en Costa Rica. *Revista de Biología Tropical*, Vol.48, No. 1, pp. 121-123
- Sauerbrey, M. (1977). A precipitin test in the diagnosis of human abdominal angiostrongyliasis. *The American Journal of Tropical Medicine and Hygiene*, Vol. 26, No.6, pp. 1156-1158
- Sawanyawisuth, K. & Sawanyawisuth, K. (2008). Treatment of angiostrongyliasis. *Transaction of the Royal Society of Tropical Medicine and Hygiene*, Vol.102, No.10, pp. 990-996
- Sierra, E. & Morera, P. (1972). Angiostrongilosis abdominal. Primer caso humano encontrado em Honduras (Hospital Evangélico de Siguatepeque). *Acta Médica Costarricense*, Vol.14, pp. 95-99

- Simões, R., Monteiro, F., Sánchez, E., Thiengo, S., Garcia, J., Costa-Neto, S., Luque, J. & Maldonado Jr., A. (2011). Endemic Angiostrongyliasis, Rio de Janeiro, Brazil. *Emerging Infectious Diseases*, Vol.17, No.7, pp. 1331-1333
- Slom, T. & Johnson, S. (2003). Eosinophilic Meningitis. *Current Infection Disease Reports*, Vol.5, No.4, pp. 322-8
- Tesh, R., Ackermann, L., Dietz, W. & Williams, J. (1973). *Angyostrongylus costaricensis* in Panamá. Prevalence and Pathologic Findings in wild rodents infected with this parasite. *The American Journal of Tropical Medicine and Hygiene*, Vol.22, No.3, pp.348-356
- Thiengo, S. (1996). Mode of infection of Molluscs with *Angiostrongylus costaricensis* larvae (Nematoda). *Memórias do Instituto Oswaldo Cruz*, Vol.91, No.3, pp. 277-288
- Thiengo, S., Faraco, F., Salgado, N., Cowie, R. & Fernandez, M. (2007). Rapid spread of an invasive snail in South America: the giant African snail, *Achatina fulica*, in Brasil. *Biological Invasions*, Vol.9, No.6, pp.693-702
- Thiengo, S., Maldonado, A., Mota, E., Torres, E., Caldeira, R., Oliveira, A., Simões, R., Fernandez, M. & Lanfredi, R. (2010). The giant African snail *Achatina fulica* as natural intermediate host of *Angiostrongylus cantonensis* in Pernambuco, northeast Brazil. *Acta Tropica*, Vol.115, No.3, pp. 194-199
- Ubelaker, J. & Hall, N. (1979). First report of *Angiostrongylus costaricensis* Morera and Céspedes, 1971 in the United States. *Journal of Parasitology*, Vol.65, pp. 307, ISSN 0399-8320
- Ubelaker, J. (1986). Systematics of species referred to the genus *Angiostrongylus*. *Journal of Parasitology*, Vol.72, No.2, pp. 237-244
- Ubelaker, J., Bullick, G. & Caruso, J. (1980). Emergence of third-stage larvae of *Angiostrongylus costaricensis* Morera and Céspedes 1971 from *Biomphalaria glabrata* (Say). *Journal of Parasitology*, Vol.66, pp.856-857
- Vargas, M., Gomez Perez, J. & Malek, E. (1992). First record of *Angiostrongylus cantonensis* (Chen 1935) (Nematoda: Metastrongylidae) in the Dominican Republic. *Tropical Medicine and Parasitology*, Vol.43, No.4, pp. 253-255
- Wang, Q., Lai, D., Zhu, X., Chen, X. & Lun, Z. (2008). Human angiostrongyliasis. *The Lancet Infectious Diseases*, Vol.8, No.10, pp. 621-30
- Wallace, G. & Rosen, L. (1969). Studies on eosinophilic meningitis V- Molluscan hosts of *Angiostrongylus cantonensis* on Pacific Islands. *American Journal of Tropical Medicine and Hygiene*, Vol.18, No.2, pp.206-216
- Weinstein, P., Rosen, L., Laqueuer, G. & Sawyer, T. (1963). *Angiostrongylus cantonensis* infection in rats and rhesus monkeys, and observations on the survival of the parasite in vitro. *American Journal of Tropical Medicine and Hygiene*, Vol.12, pp. 358-377
- Yii, C. (1976). Clinical observations on eosinophilic meningitis and meningoencephalitis caused by *Angiostrongylus cantonensis* on Taiwan. *The American Journal of Tropical Medicine and Hygiene*, Vol.25, No.2, pp. 233-249
- Yousif, F. & Ibrahim, A. (1978). The first record of *Angiostrongylus cantonensis* from Egypt, Vol.56, pp. 73-80
- Zambrano, Z. (1973). Ileocolitis pseudotumoral eosinofílica de origen parasitario. *Revista Latinoamericana de Patología*, Vol.12, No., pp.43-50

- Zanol, J., Fernandez, M., Oliveira, A., Russo, C. & Thiengo S. (2010). The exotic invasive Snail *Achatina fulica* (Stylommatophora, Mollusca) in the State of Rio de Janeiro (Brazil): current status. *Biota Neotropica*, Vol.10, No.3, pp. 447-451
- Zavala, V., Ramírez, B., Reyes, P. & Bates, F. (1974). *Angiostrongylus costaricensis*. Primeiros casos Mexicanos *Revista de investigación clínica (Mexico)*, Vol.26, No. ,pp.389-394
- Zilioto, A., Kunzle, J., Rus Fernandes, L., Prates-Campos, C. & Britto-Costa, R. (1975). Angiostrongilíase: apresentação de um provável caso. *Revista do Instituto de Medicina Tropical de São Paulo*, Vol.17, No.5, pp. 312-318.



## **Zoonosis**

Edited by Dr. Jacob Lorenzo-Morales

ISBN 978-953-51-0479-7

Hard cover, 436 pages

**Publisher** InTech

**Published online** 04, April, 2012

**Published in print edition** April, 2012

Zoonotic diseases are mainly caused by bacterial, viral or parasitic agents although "unconventional agents" such as prions could also be involved in causing zoonotic diseases. Many of the zoonotic diseases are a public health concern but also affect the production of food of animal origin thus they could cause problems in international trade of animal-origin goods. A major factor contributing to the emergence of new zoonotic pathogens in human populations is increased contact between humans and animals. This book provides an insight on zoonosis and both authors and the editor hope that the work compiled in it would help to raise awareness and interest in this field. It should also help researchers, clinicians and other readers in their research and clinical usage.

### **How to reference**

In order to correctly reference this scholarly work, feel free to copy and paste the following:

Arnaldo Maldonado Jr., Raquel Simões and Silvana Thiengo (2012). Angiostrongyliasis in the Americas, Zoonosis, Dr. Jacob Lorenzo-Morales (Ed.), ISBN: 978-953-51-0479-7, InTech, Available from: <http://www.intechopen.com/books/zoonosis/angiostrongyliasis-in-the-americas>

**INTech**  
open science | open minds

#### **InTech Europe**

University Campus STeP Ri  
Slavka Krautzeka 83/A  
51000 Rijeka, Croatia  
Phone: +385 (51) 770 447  
Fax: +385 (51) 686 166  
[www.intechopen.com](http://www.intechopen.com)

#### **InTech China**

Unit 405, Office Block, Hotel Equatorial Shanghai  
No.65, Yan An Road (West), Shanghai, 200040, China  
中国上海市延安西路65号上海国际贵都大饭店办公楼405单元  
Phone: +86-21-62489820  
Fax: +86-21-62489821



© 2012 The Author(s). Licensee IntechOpen. This is an open access article distributed under the terms of the [Creative Commons Attribution 3.0 License](https://creativecommons.org/licenses/by/3.0/), which permits unrestricted use, distribution, and reproduction in any medium, provided the original work is properly cited.

IntechOpen

IntechOpen