

We are IntechOpen, the world's leading publisher of Open Access books Built by scientists, for scientists

6,900

Open access books available

186,000

International authors and editors

200M

Downloads

Our authors are among the

154

Countries delivered to

TOP 1%

most cited scientists

12.2%

Contributors from top 500 universities



WEB OF SCIENCE™

Selection of our books indexed in the Book Citation Index
in Web of Science™ Core Collection (BKCI)

Interested in publishing with us?
Contact book.department@intechopen.com

Numbers displayed above are based on latest data collected.
For more information visit www.intechopen.com



The Role of Altered Connective Tissue in the Causation of Pelvic Floor Symptoms

B. Liedl^{1,*}, O. Markovsky¹, F. Wagenlehner² and A. Gunnemann³

¹*Pelvic Floor Centre Munich,*

²*Urological Clinic of the University of Giessen,*

³*Urological Department Klinikum Detmold,
Germany*

1. Introduction

The pelvic floor consists of muscles and connective tissue. In the past, the components' relative contribution to the structural support of the pelvic floor and its functions has been a subject of controversy (Corton 2009). With increasing age women can develop vaginal and pelvic organ prolapse as well as symptoms such as stress urinary incontinence, voiding dysfunction, urgency and frequency and nocturia, and may also develop fecal incontinence, obstructive defecation and pelvic pain (Petros 2010). All of these symptoms can be associated - to a greater or lesser extent - with pelvic floor defects.

What events are responsible for these defects? One theory says that an important cause of prolapse and pelvic floor dysfunction is likely to be partial denervation (Swash et al 1985, Smith et al. 1989). But Pierce et al. (2008) demonstrated in nulliparous monkeys that bilateral transection of the levator ani nerve resulted in atrophy of denervated levator ani muscles but not in failure of pelvic support. This indicates that connective tissue components could compensate for weakened pelvic floor muscles. According to South et al. (2009), in up to 30 percent of all vaginal childbirths, pelvic floor muscles are partially denervated. However, such functions are known to recover and reinnervate often within months (Snooks et al 1984, Lin et al. 2010) .

In a direct test of the question, "connective tissue or muscle damage?", Petros et al 2008 performed a blinded prospective study with muscle biopsies of m.pubococcygeus taken at the same time as a midurethral sling operation for urinary stress incontinence (USI) was done, an operation which works by creating an artificial collagenous neoligament (Petros PE, Ulmsten U, Papadimitriou 1990). Out of 39 patients with histological evidence of muscle damage, 33 (85%) were cured immediately after surgery, indicating that connective tissue, not muscle damage was most likely the major cause of the USI.

Further, the muscle itself can change. It is known that the number and density of urethral striated muscle fibers declines with age (Huisman 1983, Perucchini et al. 2002), an idea that has been confirmed in studies about the vastus lateralis muscle (Lexell et al. 1988). Muscle

*Corresponding Author

avulsions have been reported at the pelvic floor (Dietz and Lanzarone 2005, Dietz et al. 2007), but it is more likely that the insertion areas of muscles are dislocated by connective tissue alterations than muscle tears (Petros 2008).

From a mechanical point of view, the pelvic floor is composed of both muscles and connective tissue. The muscles are the active components that are – through their contractions - responsible for all functions of the pelvic floor. The connective tissues, with their elastic and collagen fibres and their extracellular matrices, provide structural support for the vagina and other organs such as uterus, urethra, bladder and rectum (Abramowitch 2009). It has been shown, that connective tissue changes occur during pregnancy (Rechberger et al. 1988, Harkness 1959). Weakening of collagen cross bonding (Rechberger et al. 1988) added to dilatation of the vaginal canal at childbirth can lead to overdistension or rupture of connective tissue. Extracellular matrix proteases contribute to progression of pelvic organ prolapse in mice and humans (Budatha et al. 2011, Connell 2011). The first vaginal birth is especially associated with the development of a prolapse, whereas additional vaginal births do not show significant increases in the odds of prolapse (Quiroz et al. 2011). Aging is characterized by a loss of collagen, degeneration of the elastic fibre network and a loss of hydration as a result of imbalance between biosynthesis and degradation (Uitto und Bernstein 1998, Campisi 1998)

In addition to that, there is a significant variability of tissue due to inborn variations (Dietz et al 2004) and collagen-associated disorders (Lammers et al. 2011, Campeau et al. 2011).

Surgical procedures can reduce structural support of the organs, especially those which cut or displace the uterosacral and cardinal ligaments during hysterectomy or which partially resect vaginal tissue or perineal body during colporrhaphy.

Petros and Ulmsten (1993) stated that looseness or laxity of the vagina and its supporting ligaments can cause stress incontinence as well as urge. Since then the theory has been expanded to include other symptoms such as pelvic pain, voiding dysfunction and more recently, fecal incontinence and constipation (Petros & Swash 2008). In order to fix such loose ligaments Petros et al. (1990) have introduced alloplastic material for planned formation of an artificial neo-ligament. From this rather basic research, new surgical techniques have been developed, such as tapes for midurethral slings (TVT, TOT) and for repair of other pelvic floor ligaments (Petros and Ulmsten 1990, 1993). The new developments and the recent focus on connective tissue are important, not least because looseness of tissues can be repaired surgically..

2. Basic effect of altered connective tissues (looseness) on muscle function

Gordon (1966) studied the relation between muscle force and sarcomere length (figure 1). As a muscle fiber consists of a distinct number of sarcomeres, the determined relation can be leveraged for the full length of the muscle, for which the same relation can be assumed.

This implies that a muscle has a special range of lengths, in which it can perform its peak force. If the muscle is shortened, its force decreases and goes down towards zero. If a muscle is overlengthened, its force goes down, too, sometimes even all the way to zero, at a length half of the one that gives optimal force. This means that a fully innervated muscle with normal morphology can have very low or even no force when it is over-stretched. The same

process occurs in women with descending or prolapsing vaginal wall and pelvic organs. The muscles which attaches directly or indirectly to the vagina or the pelvic organs change their length and their direction of action. This alters muscle force and function according to the relation shown in Figure 1. After re-positioning of the prolapsed organs, the muscle can reach its normal length and function. Hence, atrophy of muscle by immobilization (Hvid et al. 2011) can be avoided at least with some patients.

A prime example of this principle is restoration of urethral closure by a midurethral sling which restores the integrity of the pubourethral ligament. In the original description of the „tension-free“ sling (Ulmsten et al 1996), the operation was performed under local anesthesia and the tape was lifted upwards while the patient was coughing, until the urine leakage ceased.

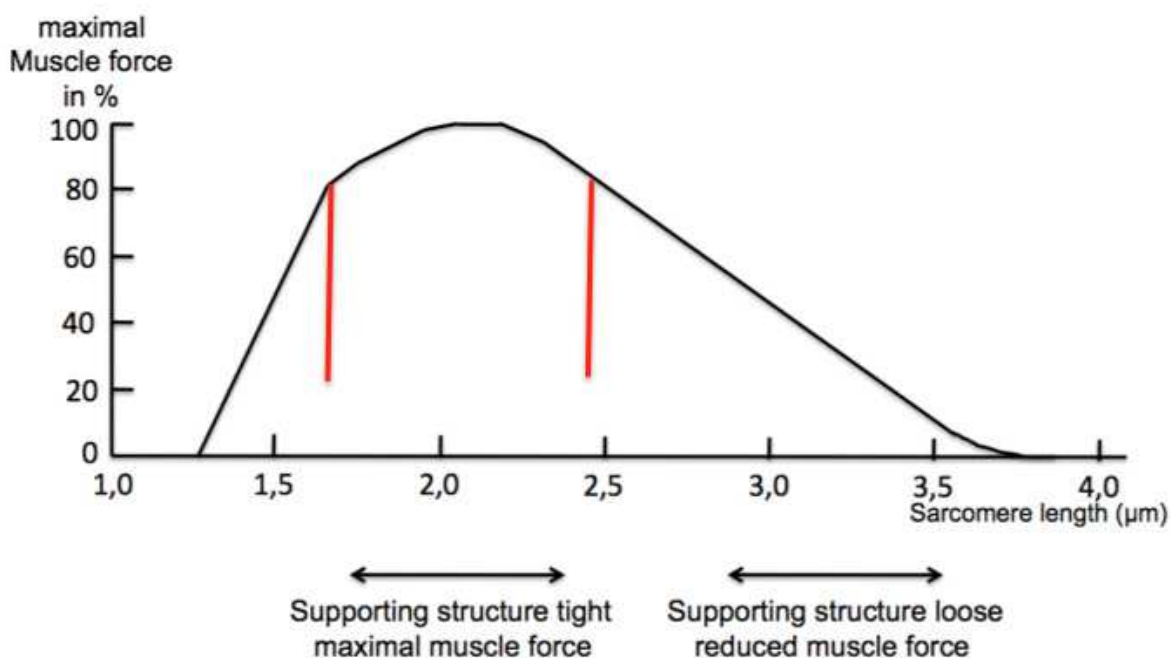


Fig. 1. Relationship of maximal muscle force to muscle (sarcomere)length (modified after Gordon 1966). Maximal muscle strength is exerted over a very short length (between red lines). Contractile strength falls rapidly with muscle lengthening and shortening, for example, due to lax connective tissue attachments.

3. Pelvic floor muscles and their functions (figure 2)

In many studies morphology of pelvic floor muscles has been explained with only few limited reference to muscle action. There is no doubt that the pelvic floor muscles and ligaments have immense importance for stress incontinence, micturition and anorectal functions. It was P. Petros who explained the directional muscle forces (Petros and Ulmsten 1993, Petros and Ulmsten 1997) and their significant role in pelvic floor dysfunctions.

From a functional and clinical aspect, it is important to consider 4 major muscle groups of the pelvic floor which are able to move the vaginal wall and pelvic floor organs (Petros 2010):

1. The anterior and medial portions of the pubococcygeus muscle (PCM) arise on either side from the inner surface of the pubic bone and attach to the lateral walls of the distal vagina (Zacharin 1963, Petros und Ulmsten 1997, Corton 2009). This muscle portion, called pubococcygeus muscle (PCM) by Petros and Ulmsten (1993) and pubovaginal muscle by Corton (2009) can pull the distal vagina forward to close the distal urethra during effort (coughing or straining). This muscle needs intact pubourethral ligaments for optimal action.
2. The levator plate in the upper layer runs horizontally, goes into the posterior wall of the rectum, and thus plays a major role in any backward movement of this organ. This muscle needs intact pubourethral and uterosacral ligaments and an intact perineal body to optimize its various actions.
3. The conjoint longitudinal muscle of the anus (LMA) is a striated muscle which constitutes the middle layer. It is vertically oriented, creates the downward force for bladder neck closure during effort and stretches open the outflow tract during micturition. It takes fibers superiorly from the levator plate (LP), the lateral part of the pubococcygeus and puborectalis muscle. It is well anchored by extra-anal sphincter (Courtney 1950). This muscle needs intact uterosacral ligaments for optimal action.
4. The puborectalis muscle (PRM) originates just medially to PCM and traverses all three muscle layers. It is orientated vertically and runs forward medially below PCM. It is closely applied to the lateral walls of the rectum and surrounds them (Courtney 1950).

The lower layer of pelvic floor muscles is an important anchoring layer. It consists of perineal membranes and component muscles - bulbocavernosus, ischiocavernosus and the deep and superficial transverse perinei muscles. The deep transverse perinei muscle anchors the upper part of the perineal body to the descending pubic ramus. It is a strong muscle and it stabilizes the perineal body laterally. The external anal sphincter acts as a tensor of the perineal body and represents the principal insertion point of the LMA. The bulbocavernosus muscle stretches and anchors the distal part of the urethra. The ischiocavernosus muscle helps stabilize the perineal membrane and may act to stretch the external urethral meatus laterally via its effect of the bulbocavernosus. Between the extra-anal sphincter and the coccyx lies the postanal plate, a tendinous structure which also contains striated muscles inserting into the extra-anal sphincter (Petros 2010).

The striated rhabdosphincter of the urethra surrounds the urethra in the middle third of its length for approximately 1,5 cm (Oelrich 1983).

4. Important connective tissue structures at the pelvic floor (figures 2 and 8)

At the pelvic floor at least 9 sites of connective tissue can be defined as loose. With regard to its function, P. Petros (2010) divides the connective tissue defects in three zones (figure 2).

The **anterior zone**, which reaches from the external meatus of the urethra to the bladder neck, embraces three important structures:

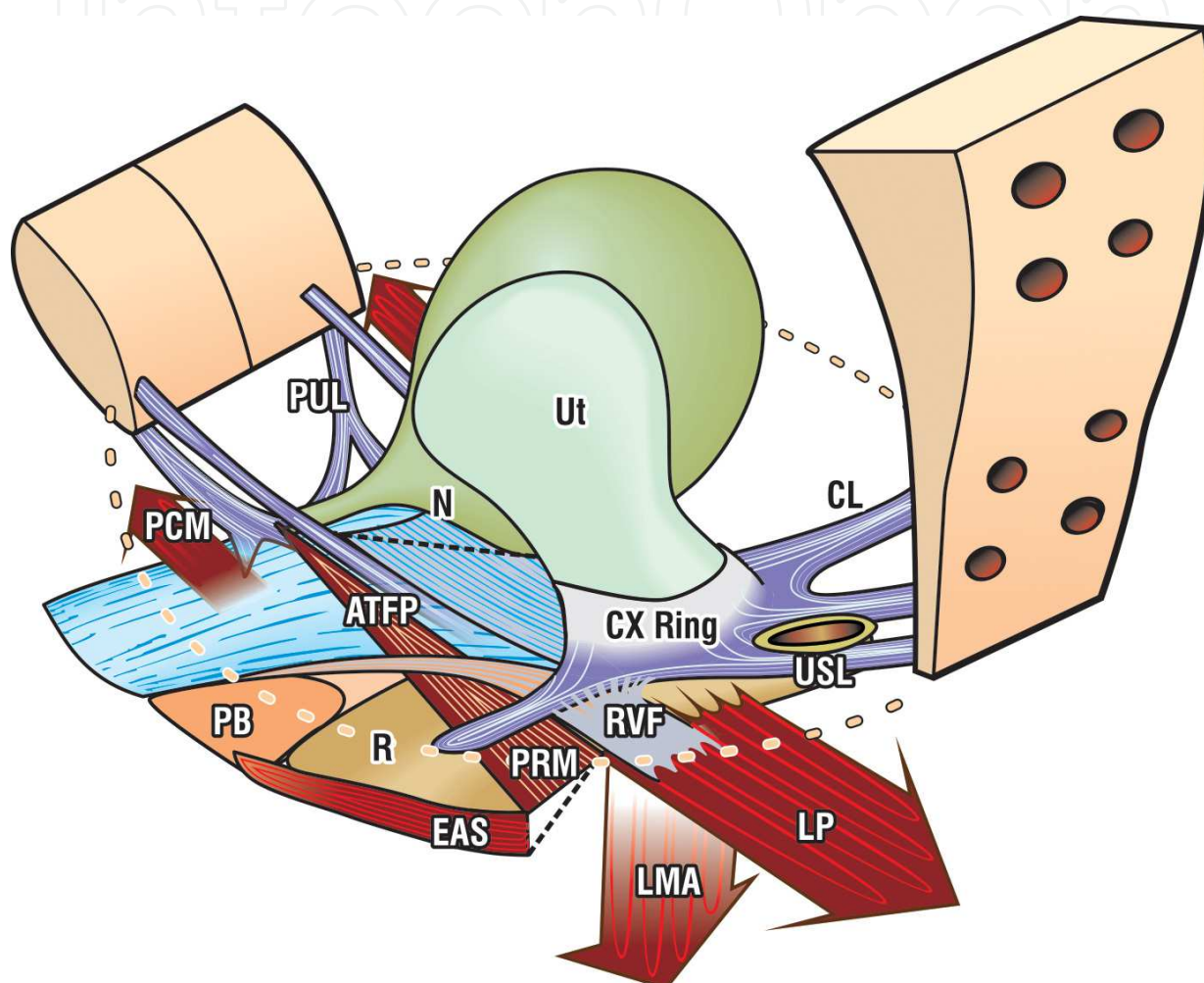
The extraurethral ligament runs from the pubis anteriorly to the meatus urethrae anterior to the perineal membrane.

The pubourethral ligament, a ligament with key relevance for stress urinary continence, originates from the lower end of the posterior surface of the pubic symphysis and descends

like a fan to insert into the pubococcygeus muscle and lateral part of the mid urethra (Zacharin 1963, Petros 1998).

The suburethral vagina acts as a hammock for the urethra. The antero-medial portion of the pubococcygeus muscles is attached laterally on each side of the hammock

In the **middle zone**, which reaches from the bladder neck to the cervix, three further structures are important:



PCM: pubococcygeus muscle, LP: levator plate, LMA: longitudinal muscle of the anus
 PRM: puborectalis muscle, EAS: extraanal sphincter
 PUL: pubourethral ligament, ATFP: Arcus tendineus fasciae pelvis, CL: cardinal ligament
 CX-Ring: cervical ring, USL: uterosacral ligament, RVF: rectovaginal fascia
 PB: perineal body, B: bladder, Ut: uterus, R: rectum
 N: stretch receptor at bladder base

Fig. 2. Important muscles and connective tissue structure at the pelvic floor (from P. Petros 2010, by permission)

The arcus tendineus fascia pelvis (ATFP) are horizontal ligaments which arise just superior to the pubourethral ligaments at the pubis symphysis and insert into the ischial spine. The vagina is suspended from the ATFP by its fascia, much like a sheet slung across two

washing lines (Nichols 1989). The cardinal ligaments are attached to the cervical ring and pubocervical fascia and extend laterally towards and above the ischial spine. The cervical ring surrounds the cervix and acts as an attachment point for the cardinal and uterosacral ligaments as well as the pubocervical and rectovaginal fascia. It consists mainly of collagen. The “pubocervical fascia” – a term still used by surgeons - stretches from the lateral sulci of the vagina to the anterior part of the cervical ring, it is a vaginal muscularis and fibromuscular wall (Corton 2009).

In the **posterior zone**, which reaches from the cervix to the anal canal, the following 3 structures can be loose.

The uterosacral ligaments arise from the sacral vertebrae S2,3,4 and attach to the cervical ring posteriorly. It is an effective insertion point of the downward muscle force, the longitudinal muscle of the anus (LMA). The rectovaginal fascia extends as a sheet between the lateral rectal pillars, from the perineal body below to the levator plate above. It is attached to the uterosacral ligaments (USL) and the fascia surrounding the cervix. The perineal body lies between the distal third of the posterior vaginal wall and the anus below the pelvic floor. It is 3-4 cm long. According to DeLancey (1999), it is formed primarily by the midline connection between the halves of the perineal membrane. It is the insertion point of bulbocavernosus muscle and deep and superficial transverse perineal muscles.

Micturition Broken line below bladder signifies relaxation of PCM; LP/LMA vectors actively open out the urethra exponentially decreasing frictional resistance to micturition

Defecation Broken line behind rectum signifies relaxation of PRM; LP/LMA vectors actively open out the anorectum, exponentially decreasing frictional resistance to defecation

5. Stress urinary continence and incontinence

During stress (coughing or straining) the intraurethral pressure rises in normal patients. The rise in pressure within the urethra precedes the rise in pressure in the bladder by 160-240 milliseconds (Enhörning 1961, Constantinou and Govan 1982, van der Kooi et al. 1984, Pieber et al. 1998). This means, that the increased pressure within the urethra during stress must be due to an active muscle contraction and cannot be a passive transmission of the abdominal pressure.

In addition to the contraction of the rhabdosphincter at midurethra, the PCM pulls the distal vagina forward to close the distal urethra (figure 3). Furthermore, the bladder and posterior vaginal wall is pulled backwards (by levator plate) and downwards (by LMA). With intact pubourethral ligament the urethra is stretched and angulated to “kink” the proximal urethra (Petros and Ulmsten 1995). This action is an important closing mechanism, which, as known, helps many patients maintain continence after excision of the distal urethra.

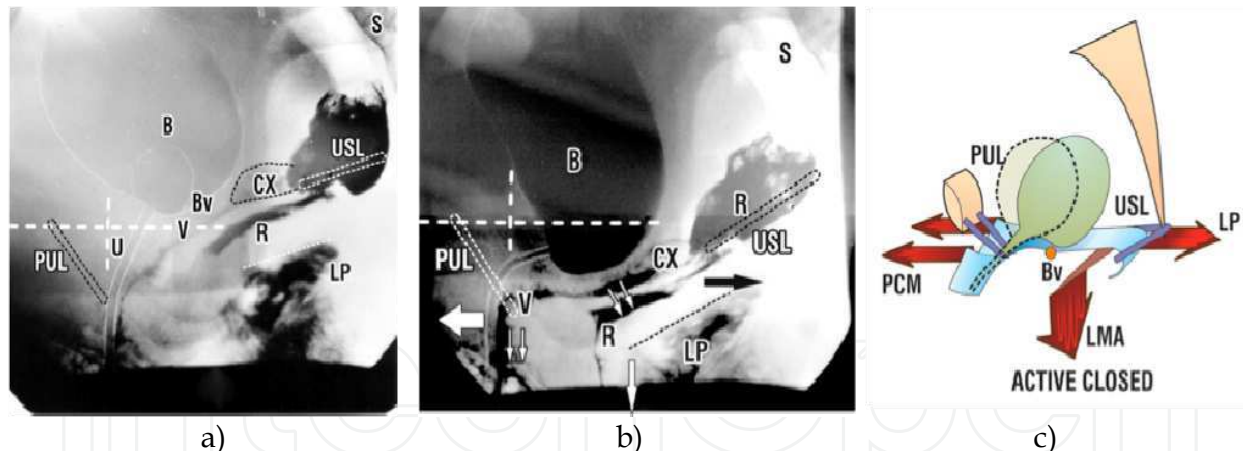
The Integral Theory (1990, 1993) states that „stress urinary incontinence ... derives mainly from laxity in the vagina or its supporting ligaments, a result of altered collagen/elastin“. A hypermobile urethra results from loose connective tissue. In stress situations,

abdominal forces stretch loose tissues in the anterior zone (pubourethral ligament, extraurethral ligament, hammock), leading to overlengthening of the rhabdosphincter. According to Gordon's relation between muscle length and muscle force, as soon as the muscle force diminishes ... (by half/etc), the patient is stress incontinent. Overstretched connective tissue leads also to an increased radius within the rhabdosphincter and the urethra. According to Laplace's law, the pressure within the urethra correlates inversely to the radius within the rhabdosphincter. In loose connective tissue, the pressure within the urethra thus diminishes in line with the increasing radius. The Hagen-Poiseuille's law is also helpful in describing continence. The resistance to flow within the urethra in stress situations correlates directly to the length of the urethra and indirectly to the radius within the urethra in the 4th power (Bush et al. 1997). Stress in patients with loose connective tissue will open the urethra. The stress flow then correlates to the radius of the urethra in 4th power.

In other words, loose connective tissue can lead to reduced muscle force by overstretching the muscle, reduced urethral pressure by increasing the radius within the rhabdosphincter, and reduced resistance to flow by widening the urethral radius.

These correlations have a major impact on interpretation of urodynamic results and should be considered in the future.

Petros has been developing the midurethral sling since 1986 based on research on the laxities of the vagina and supporting ligaments and loose connective tissue. (Petros and Ulmsten 1990, 1993)



B=bladder; U=urethra; V=vagina; CX=cervix; R=rectum; PUL=pubourethral ligament; Bv=attachment of bladder base to vagina; LMA= conjoint longitudinal muscle of the anus; LP=levator plate; USL=uterosacral ligament.

Fig. 3. Directional movements of bladder and urethra during effort. a) Lateral xray in resting position, sitting. b) Lateral xray during straining, same patient, shows forward movement of distal vagina and urethra and backward/ downward rotation of proximal vagina and urethra ,around the pubourethral ligament (PUL) at the midurethral point. c) Muscle actions during effort- schematic view. PCM pulls the distal vagina forwards to close the distal urethra; LP/LMA stretch the proximal vagina and urethra backwards/downwards to close off the proximal urethra. (From PPetros 2010, by permission).

6. Normal micturition and abnormal emptying of the bladder

Micturition is another complex mechanism that has to be understood when performing pelvic floor surgery. Thus, not only sphincter relaxation and detrusor contraction have to be taken into consideration. EMG-measurements in the posterior fornix have demonstrated commencement of muscle contraction prior to commencement of voiding (Petros 2010). Radiologically, it was shown that the anterior vaginal wall is stretched and moved backward and downward during micturition (figures 4b). The bladder also moves backward and downward and the proximal urethra funnels (figure 4a). This can only be explained by active muscle contractions of levator plate (LP) and longitudinal muscle of anus (LMA). Relaxation of the forward force (PCM) and relaxation of urethral sphincter allows the backward and downward forces to open up the outflow tract (figure 4c)

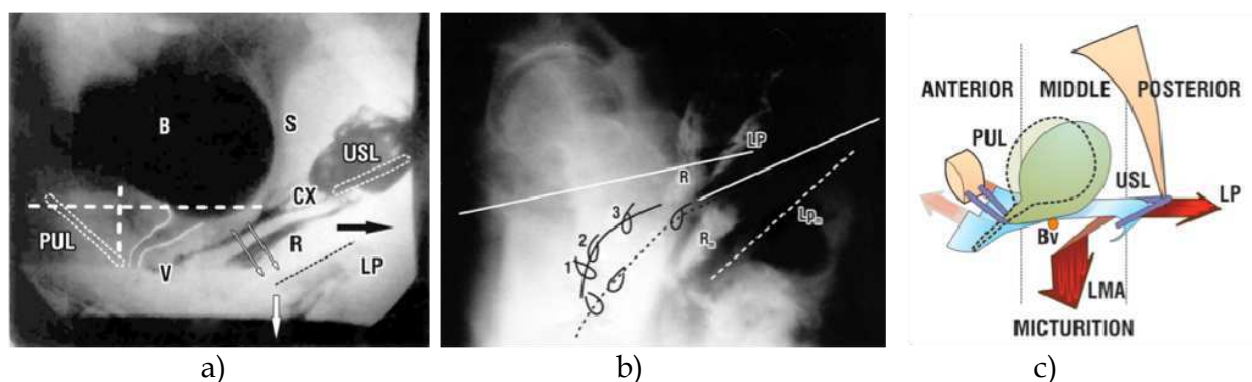


Fig. 4. Normal micturition. a) Lateral xray, same patient as fig. 3. During micturition, the bladder and vagina move backwards and downward, opening out the posterior urethral wall. b) Superimposed lateral xray.s At rest (unbroken lines) and micturition (broken lines) vascular clips placed at midurethra "1", bladder neck "2" and bladder base "3". c) Muscle actions during micturition . PCM relaxes. This allows the posterior muscle forces LP/LMA (red arrows) to stretch vagina and posterior urethral wall backwards/ downwards to open out the outflow tract. Same labelling as fig. 3. (From P Petros 2010, by permission).

The posterior muscles (LP and LMA) only contribute in opening the bladder neck and urethra when the connective tissue architecture and its insertion points are intact in a way that they can pull normally (see figure 1). If the uterosacral ligaments are loose (insertion points of the LMA) or a cystocele is present the posterior forces cannot pull normally, the muscles are shortened or overstretched and have reduced force. Even a minor degree of prolapse can be the cause of defective micturition. Kinking of the urethra by prolapse can also be a cause of abnormal emptying of the bladder. A location of the tape too high up the bladder neck or proximal urethra as well as anterior fixation of the bladder neck after colposuspension can disturb funnelling of the urethra.

7. Stability at the bladder base by a tensioned vaginal wall, urgency and frequency

In their first publication of the "Integral theory" Petros and Ulmsten (1990) stated that "symptoms of stress and urge derive mainly from laxity in the vagina or its supporting ligaments, a result of altered collagen/elastin". Following their publication, evidence was

increasingly found that supported their claim that a correlation between the prolapse and an overactive bladder exists (de Boer et al. 2010).

Figures 2, 3b and 5 show that the bladder lies on the vaginal wall. With effort the posterior vaginal wall is orientated horizontally and the bladder lies on this part of tensioned vaginal wall (figure 3b), which acts as a “trampoline”. The vagina is attached to the pelvic rim by the uterosacral ligaments posteriorly, the arcus tendineus and the cardinal ligaments laterally as well as the pubourethral ligament anteriorly. Anterior and posterior muscle forces (red arrows in figure 5) add to tension the vaginal wall. While the slow twitch fibres are active when at rest, the fast twitch fibres are active during effort. At the bladder base stretch receptors are present which are connected by afferent nerves to the cortex (Wyndaele et al. 2008, Everaerts et al. 2008, Petros & Ulmsten 1990). Efferent nerves can activate the pelvic floor musculature (figure 5).

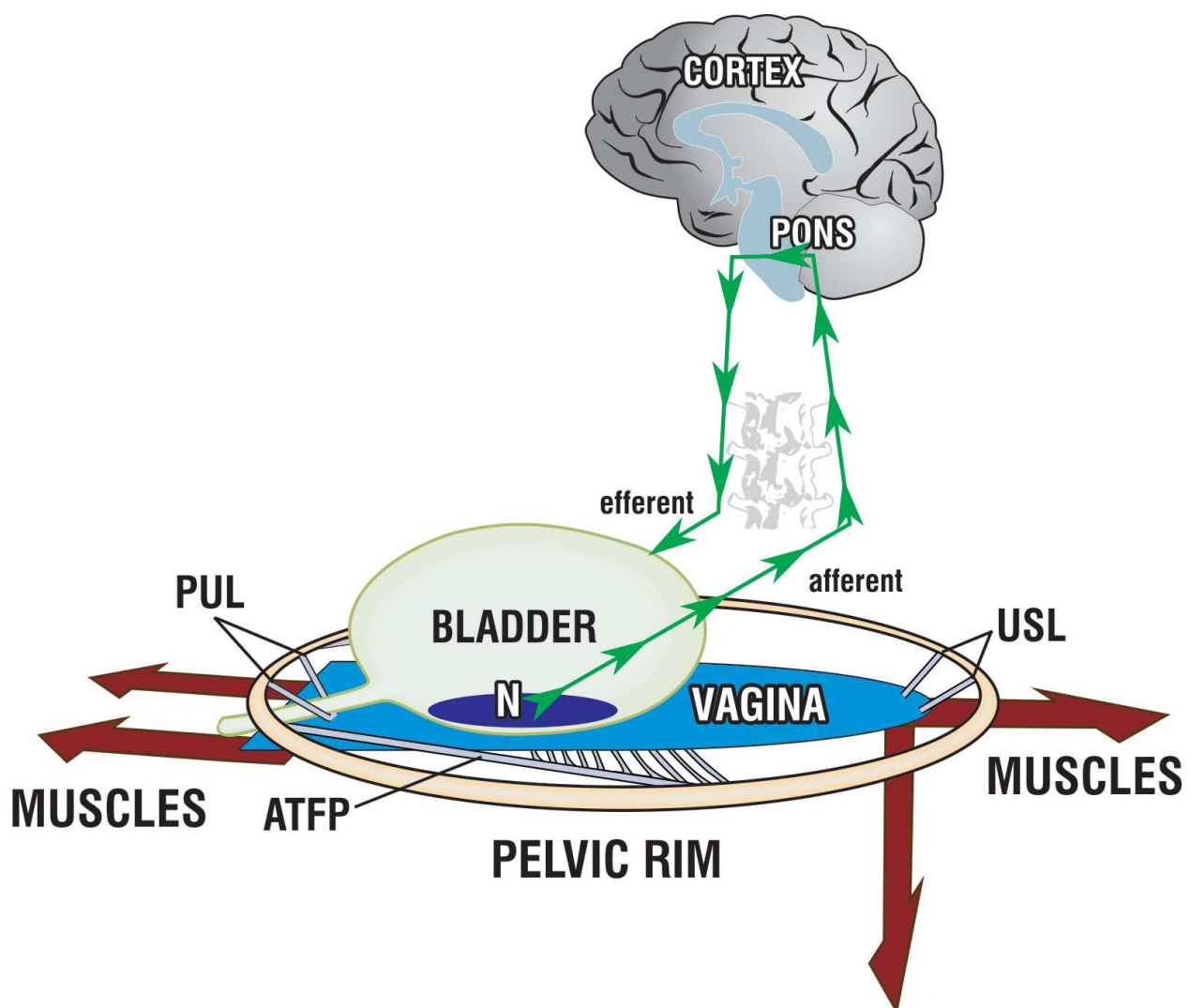


Fig. 5. Stability at the bladder base by a tensioned vaginal wall “Trampoline Analogy”. (From P Petros 2010, by permission).

Petros and Ulmsten (1993) postulated that urgency could lead to a premature activation of the micturition reflex. A lax vagina at the anterior, middle or posterior zone reduces the

tension of the vagina below the bladder base, the stretch receptors can be activated by afferent nerves, the cortex gets the information of full bladder and this creates the sensation of urge. Prematurely the micturition reflex can be activated and even urge incontinence can occur.

8. Nocturia

Many patients with vaginal vault or uterine prolapse – even if of a minor degree – complain about nocturia. Figure 6 explains the mechanism that leads to nocturia.. When the patient is asleep, the force of gravity pulls down the bladder base. Normally, with firm uterosacral ligaments, the bladder is held high (dotted line in Figure 6). When the patient is asleep and the uterosacral ligaments are loose, the pelvic floor muscles are relaxed, the bladder descends posteriorly, the bladder base is stretched and the stretch receptors “N” are stimulated.

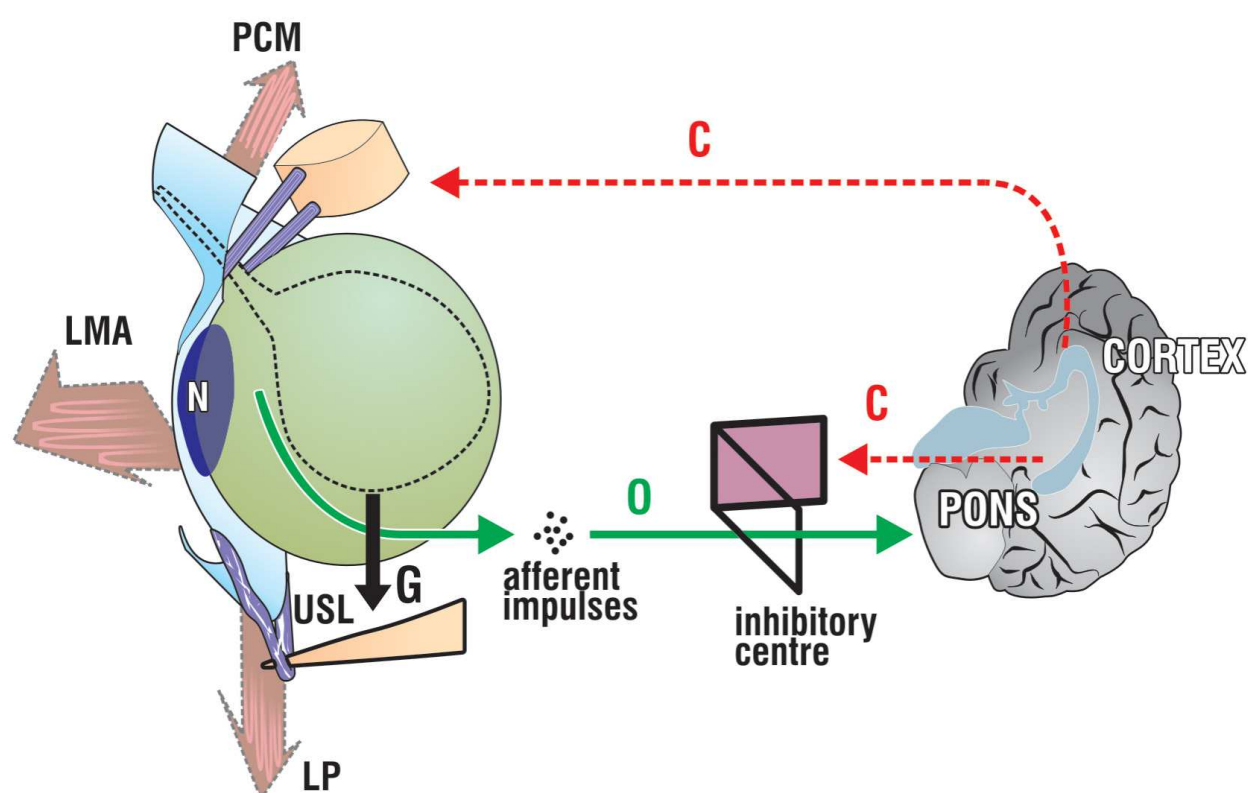


Fig. 6. Mechanism of nocturia- schematic view- patient asleep. The pelvic muscles (arrows) are relaxed. As the bladder fills, it is pulled downwards by the force of gravity ‘G’. In the normal patient, bladder descent is limited by the uterosacral ligaments “USL”. If “USLs” are loose, the bladder descends more, the stretch receptors “N” are stimulated, the micturition reflex is activated at a low bladder volume, “nocturia”. (from P Petros 2010, by permission)

9. Anorectal function, fecal incontinence and obstructive defecation

The anecdotal observation that midurethral slings and repair of loose uterosacral ligaments can cure fecal incontinence has led Petros and Swash (2008) to establish a new theory of anorectal function. A new complex musculo-elastic sphincter mechanism was detected. Its

mechanism is similar to that of bladder neck closure. Directional muscle forces stretch the rectum backwards and downwards around an anus firmly anchored by the puborectalis muscle. Anorectal closure occurs when the backward muscle forces of LP and LMA stretch the rectum around the anus, which is anchored by PRM-contraction. Upon comparing Figure 3b with Figure 3a, the rectum above the anal canal has been markedly angulated (and closed) by muscle actions during effort. Upon relaxation of PRM, LP/LMA vectors open out the anal canal for evacuation (broken lines, Fig2)

Fecal incontinence can occur when connective tissue at the anterior zone is loose. Then the insertion points of the puborectalis muscle are dislocated and the muscle is weak. Furthermore, the anterior insertion points of the levator plate are loose and the muscle is weak and the anorectal closure is weak, also.

When connective tissue at the posterior zone is loose, the muscles also cannot act optimally and fecal incontinence can occur. Lax uterosacral ligaments can explain rectal intussusception and obstructive defecation. The levator plate cannot tension the rectovaginal fascia. The perineal body is an important anchoring point and, if loose, it can contribute to fecal incontinence and obstructive defecation (Petros 2010, Abendstein and Petros 2008).

10. Pelvic pain

Many patients with vaginal vault prolapse or uterus prolapse report pelvic pain, a low abdominal dragging pain which occurs mainly in an upright position and is generally relieved in a lying position. This pain may be associated with vulvodynia. Both types of pain have been temporarily relieved by injection of local anaesthetic into the uterosacral ligaments (Bornstein et al 2005, Petros et al 2004), supporting the hypothesis that this pain is a referred pain arising from the inability of lax uterosacral ligaments to support the nerves running along the ligament (figure 7). These nerves are stretched by gravity or during intercourse to cause pain. This pain is almost invariably associated with other symptoms deriving from posterior zone laxity, Figure 8. In a recent study, restoration of uterosacral ligament tension using a posterior tensioned sling showed improvement in posterior zone symptoms as follows: nocturia >2/night 83%; urge-incontinence >2/day 78%; abnormal emptying, 73% ; pelvic pain, 86% fecal incontinence, 87% (Petros PEP, Richardson PA, 2010)

11. The association of pelvic floor dysfunctions and different zones of connective tissue looseness at the pelvic floor (figure 8)

The three zones of connective tissue looseness (see above) are associated with different symptoms. Petros (2010) developed the diagnostic algorithm (Figure 8) through considering the pathophysiology of dysfunctions and through practical experiences with the patients that had different forms and degrees of descensus/prolapse of the vaginal wall.

Many symptoms are associated with these different forms of descensus/prolapse: stress urinary incontinence, abnormal emptying of the bladder, urgency and frequency, nocturia, faecal incontinence, obstructed defecation and pelvic pain.

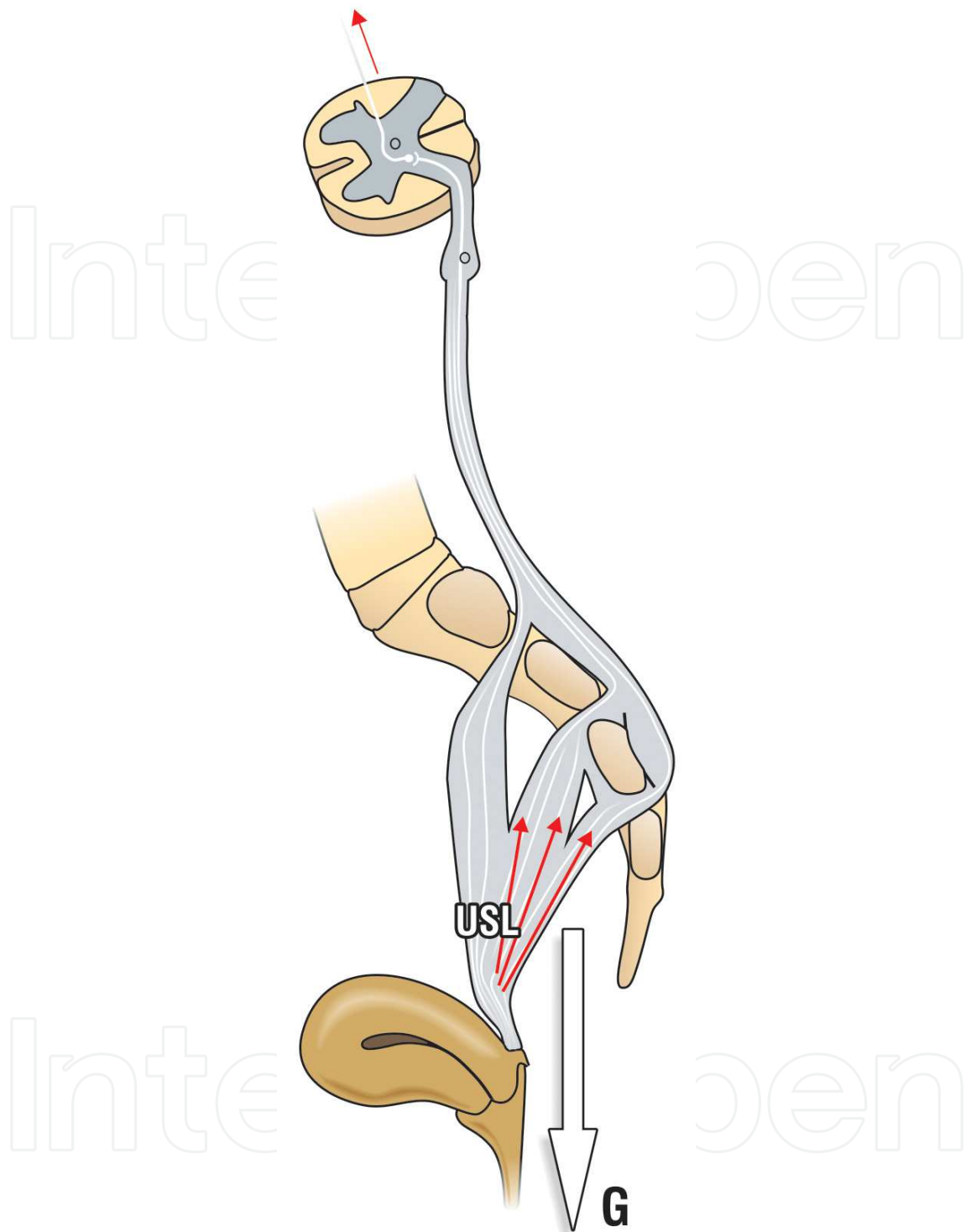


Fig. 7. Pelvic pain caused by loose uterosacral ligaments (USL). Especially in the standing position, the uterus or vaginal vault prolapses under the influence of gravity 'G'. The unmyelinated nerves which run along the USLs are stretched by 'G', causing pain. (from P Petros 2010, by permission)

This algorithm summarizes the relationship between structural damage (prolapse) in the three zones and the respective functions (symptoms). The size of the bar gives an approximate

indication of the prevalence (probability) of the symptom. Stress urinary incontinence is mainly caused by anterior defects. Defects in the posterior zone cause different dysfunctions like abnormal emptying of the bladder, frequency and urgency, nocturia, fecal incontinence, obstructed defecation, pelvic pain known as the “posterior fornix syndrome” (Petros & Ulmsten 1993). Nocturia and pelvic pain are specific for posterior zone. Cystoceles mainly are associated with symptoms of abnormal emptying of the bladder and frequency and urgency. The significance of the association between zones and the respective symptoms has been shown by Hunt et al. (2000) using Bayesian networks and decision trees.

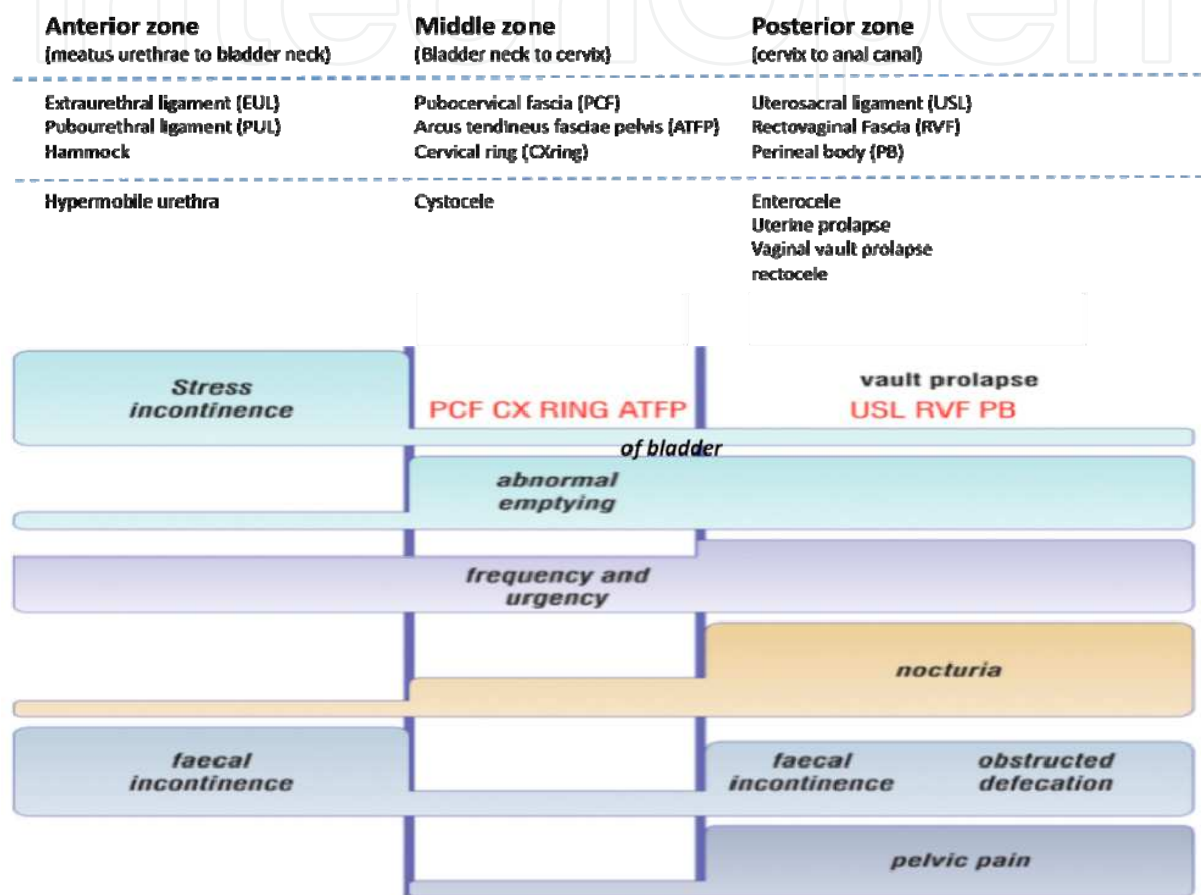


Fig. 8. Diagnostic algorithm. Pictorially elaborates the association between connective tissue looseness at different zones, their relationship with specific prolapses and symptoms, and how repair of the ligaments/fascia in each zone may cure or improve both the prolapse and the symptom(s). The size of the bars gives an approximate indication of the prevalence (probability) of the symptom. (modified after Petros 2010, by permission)

12. Consequences of the diagnostic algorithm for surgical treatments

In the past surgery has only been performed for prolapse and stress incontinence. We now recognise that symptoms of different degrees and combinations can be present in different forms and degrees of prolapse, as seen in Figure 8. Because of the peripheral neurological origin of some symptoms such as urgency and pain, major symptoms may occur with only minimal prolapse. Therefore the new anatomical and functional findings, as summarized in Figure 8 have to be considered in modern pelvic floor surgery.

In daily practice, first, the different symptoms have to be identified with the help of a standardized questionnaire, for instance using Petros's questionnaire (Petros 2010, pages 270-273). Then the existing pelvic floor defects are assessed. Very helpful are the diagnostic algorithm (Figure 8) and "simulated operations" (Petros 2010) to indicate the appropriate surgery. An example of a "simulated operation" is the controlled urine loss on coughing by applying unilateral digital pressure at midurethra (Pinch-Test). Another is exposure of latent stress incontinence by pushing the prolapse back into the vagina, and asking the patient to cough.

"Restoration of form (structure) leads to restoration of function" (Petros 2010). This principle directly applies Gordon's Law: exact restoration of the insertion points of the pelvic floor muscles allows the muscles to act optimally. The function – even if complex – should thus have the optimal chance to recover.

When repair of weak tissues by conventional techniques such as suturing is not possible (for example repair of a pubourethral ligament for cure of USI), or the recurrence rate is too high, the use of alloplastic materials is an option. Because normal function requires a neurologically complex co-ordination of smooth and striated muscle, any surgery must mimic the natural anatomy as closely as possible if it is to restore function.

The axis of the posterior vagina is nearly horizontal because the uterosacral ligaments insert dorsally between S2-4. Elevation of the vagina to the promontorium is too cranial, while fixation of the vagina to the sacrospinous ligament is too caudal. It is a surgical compromise to use these areas for easy and safe fixation but the site of the uterosacral ligament remains the optimal site for its reconstruction. The uterus needs to be conserved whenever possible. It is the central anchoring point for the posterior ligaments, the rectovaginal fascia and the pubocervical fascia. The descending branch of the uterine artery is a major blood supply for these structures, and should be conserved where possible even if subtotal hysterectomy is performed.

It is important to understand that tissue structure is often displaced laterally (e. g. cardinal ligaments, uterosacral ligaments, rectovaginal fascia, pubocervical fascia, hammock, perineal body). Surgical techniques, which bring the tissues together in the midline or bridge it with alloplastic tapes at the anatomically correct position, should be applied and further developed. Simply applying a large mesh provides a barrier to the prolapse and does not restore the damaged anatomy or function. Instead, such meshes have the tendency to shrink and reduce elasticity of tissues. Furthermore, they obliterate the organ spaces. This may cause pain, dyspareunia, and erosions and may negatively affect the dissection required in cases where the patient develops rectal or bladder carcinoma. The use of alloplastic materials has to be reduced to the necessary amount and their application sites carefully considered. The conventional techniques have to be evaluated following these fundamental principles (Liedl 2010, Wagenlehner et al. 2010)

In order to minimize pain, surgery to the perineal skin and tension when suturing the vagina should be avoided. Vaginal excision should be avoided even in patients with large bulging prolapse. After repair of underlying ligamentous fascial defects, the vaginal wall contracts and will be more elastic than after excision. Tightness or elevation of the bladder neck area of the vagina as well as indentation of the urethra with a midurethral sling should be avoided in order to avoid urinary retention.

Looking at the bladder neck closure mechanism the midurethral tape should be positioned along the pubourethral ligament, which inserts retropubically. This seems especially important in patients with severe stress urinary incontinence or recurrence.

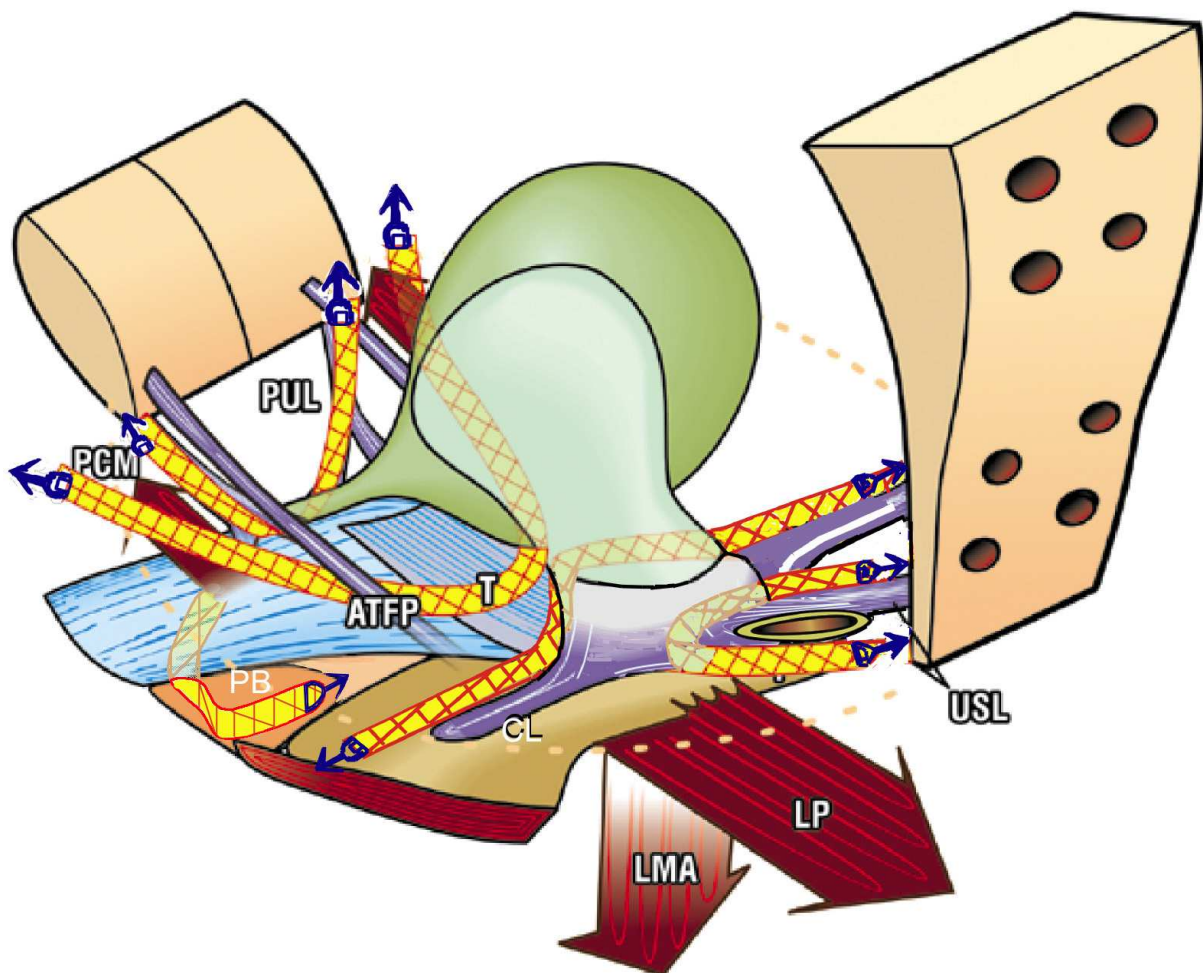


Fig. 9. The use of tensioned tapes to strengthen the principal connective tissue structures which support the vagina, bladder, uterus and rectum: pubourethral ligament (PUL), arcus tendineus fascia pelvis (ATFP), cardinal ligament (CL), uterosacral ligaments (USL), perineal body (PB). These 5 structures are the effective insertion points of the directional muscle forces (arrows) which support the organs, and which open and close the urethra and anorectum, anteromedial part of pubococcygeus muscle (PCM), levator plate (LP) and longitudinal muscle of the anus (LMA). (from P Petros 2010, by permission)

The transobturatoric approach for tape insertion may be an option for mild and moderate cases. New techniques using mini tissue anchors are promising. The TFS (Tissue Fixation System) tensioned tapes (Petros 2010) accurately reinforce the main suspensory ligaments – pubourethral (PUL), uterosacral (USL), cardinal (CL), arcus tendineus fascia pelvis (ATFP) and perineal body (PB) while bringing the laterally displaced tissues towards the midline (figure 9). This action more precisely restores the musculoelastic tension required to also restore function. The meshes with sling fixation transobturatorially or at the sacrospinous ligaments only produces long lasting barriers. At the moment the pelvic floor surgery is in a


fundamental development to a minimal invasive surgery. It should be the aim to restore the defects in a way which optimizes the pelvic floor muscles and the functions.

13. References

- Abramowitch SD (2009) Tissue mechanics, animal models, and pelvic organ prolapse: A review. *Eur J Obstet Gynecol Reprod Biol* 144S: S146-S156
- Abendstein B, Petros PE, Richardson PA, Goeschen K, Doderio D (2008) The surgical anatomy of rectocele and anterior rectal wall intussusception. *Int Urogynecol J Pelvic Floor Dysfunct* 19: 705-710
- Bornstein J, Zarfati, D, Petros PEP, Causation of vulvar vestibulitis *ANZJOG* 2005, 45: 538-541
- Budatha M, Roshanrava S, Zheng Q, Weislander c, Chapman SL, Davis EC, Starcher B, Word A, Yanagisawa H (2011) Extracellular matrix proteases contribute to progression of pelvic organ prolapse in mice and humans. *J Clin Invest* 121:2048-2059
- Bush MB, Petros P, Barrett-Lennard BR (1997) On the flow through the human urethra. *Biomechanics* 30: 967-969
- Campisi J (1998) The Role of Cellular Senescence in Sin Aging. *Journal of Investigative Dermatology Symposium Proceedings* 3:1-5
- Campeau L, Gorbachinsky I, Badlani GH, Andersson KE (2011) Pelvic floor disorders: linking genetic risk factors to biochemical changes. *BJU Int* Aug 26 (Epub ahead of print)
- Connell KA (2011) Elastogenesis in the Vaginal Wall and Pelvic-Organ Prolapse. *N Engl J Med* 364 (24):2356-2358
- Constantinou CE, Govan DE (1982) Spatial distribution and timing of transmitted and reflexly generated urethral pressures in healthy women. *J Urol* 127:964-969
- Corton MM (2009) Anatomy of Pelvic Floor Dysfunction. *Obstet Gynecol Clin N Am* 36:401-319
- Courtney H (1950) Anatomy of the pelvic diaphragm and ano-rectal musculature related to sphincter preservation in ano-rectal surgery. *American Journal Surgery* 79:155-173
- De Boer TA, Salvatore S, Cardozo L, Chapple C et al. (2010) Pelvic Organ Prolapse and Overactive Bladder. *Neurourol Urodynam* 29: 30-39
- DeLancey JOL (1999) Structural anatomy of the posterior pelvic compartment as it relates to rectocele. *Am J Obstet Gynecol* 180:815-823
- Dietz HP, Eldridge A, Grace M, Clarke B (2004) Pelvic organ descent in young nulligravid women. *Am J Obstet Gynecol* 191:95-99
- Dietz HP, Lanzarone V (2005) Levator trauma after vaginal delivery. *Obstet Gynecol* 106:707-712
- Dietz HP, Gillespie AV, Phadke P (2007) Avulsion of the pubovisceral muscle associated with large vaginal tear after normal delivery at term. *Aus N Z J Obstet Gynaecol* 47: 341-344
- Enhörning G. Simultaneous recording of intravesical and intraurethral pressure. *Acta Chir Scandinavica*, (1961), (Supplement) Vol. 27:61-68.
- Everaerts W, Gevaert T, Nilius B, De Ridder D (2008) On the origin of bladder sensing: Tr(i)ps in urology. *Neurourol Urodyn* 27:264-273
- Gordon AM, Huxley AF, Julian FJ (1966) The variation in isometric tension with sarcomere length in vertebrate muscle fibers. *J Physiol* 184: 170-192
- Harkness MLR, Harkness RD (1959) Changes in the Physical Properties of the Uterine Cervix of the Rat during Pregnancy. *J Physiol* 148:524-547

- Hunt M, von Kinsky B, Venkatesh S, Petros P (2000) Bayesian Networks and Decision Trees in the Diagnosis of Female Urinary Incontinence. Engineering in Medicine and Biology Society 2000. Proceedings of the 22nd Annual International Conference of the IEEE. Volume 1 Issue: 551-554
- Huisman AB. Aspects on the anatomy of the female urethra with special relation to urinary continence. *Contr Gynecol & Obstets.*, (1983), Karger Basel, Vol.10:1-31.
- Hvid LG, Ortenblad N, Aagaard P, Kjaer M, Suetta C (2011) Effects of aging on single muscle fibre contractile function following short-term immobilisation. *J Physiol* 2011 Aug 8 (Epub ahead of print)
- Lammers K, Lince SL, Spath MA, van Kempen LC, Hendriks JC, Vierhout ME, Kluivers KB (2011) Pelvic organ prolapse and collagen-associated disorders. *Int Urogynecol J* Aug 3 (Epub ahead of print)
- Lexell J, Taylor C., Sjöström M (1988) What is the cause of the ageing atrophy? Total number, size and proportion of different fiber types studied in whole vastus lateralis muscle from 15- to 83-year-old men. *J Neurol Sci* 84:275-294
- Liedl B (2010) Male and female urinary incontinence from the viewpoint of the pelvic floor surgeon. *Urologe A* 49:289-303
- Lin YH, Liu M, Xiao N, Daneshgari F (2010) Recovery of continence function following simulated birth trauma involves repair of muscle and nerves in the urethra in the female mouse. *Eur Urol* 57:506-512
- Nichols DH & Randall CL (1989) *Vaginal Surgery*, 3rd Ed, Williams Wilkins, Baltimore. 1-46
- Oelrich TM (1983) The striated urogenital sphincter muscle in the female. *The Anatomical Record* 205:223-232
- Perucchini D, DeLancey JO, Asthon-Miller JA, Peschers U, Kataria T (2002) Age effects on urethral striated muscle. I. Changes in number and diameter of striated muscle fibers in the ventral urethra. *Am J Obstet Gynecol* 186:351-355
- Petros PE and Bornstein J Vulvar vestibulitis may be a referred pain arising from laxity in the uterosacral ligaments- a hypothesis based on 3 prospective case reports , *ANZJO&G* (2004) 44: 483-486
- Petros PEP, Richardson PA, TFS posterior sling improves overactive bladder, pelvic pain and abnormal emptying, even with minor prolapse –a prospective urodynamic study, (2010) *Pelviperrineology* 29: 52-55
- Petros PE, Ulmsten U (1990) An Integral Theory of female incontinence. *Acta Obstetrica et Gynecologica Scandinavia*, Supplement 153, Vol 69: 1-79
- Petros PE, Ulmsten U (1993) An Integral Theory and its Method for the Diagnosis and Management of Female Urinary Incontinence. Part II. The biomechanics of vaginal tissue, and supporting ligaments with special relevance to the pathogenesis of female urinary incontinence. *Scand J Urol Nephrol Supp.* 153: 29-40
- Petros PE, Ulmsten U, Papadimitriou J (1990) The Autogenic Neoligament procedure: A technique for planned formation of an artificial neo-ligament. *Acta Obstetrica et Gynecologica Scandinavia*, 69 (Suppl. 153) 43-51
- Petros PE, Ulmsten U (1993) An Integral Theory and its Method for the Diagnosis and Management of Female Urinary Incontinence. Part I. Theory, morphology, radiographic correlations and clinical perspective. *Scand J Urol Nephrol Supp.* 153: 5-28
- Petros P, Ulmsten U (1993) Bladder instability in women: A premature activation of the micturition reflex. *Neurourol Urodynam* 12:235-239
- Petros PE, Ulmsten U (1995) Urethral and bladder neck closure mechanisms. *Am J Obstet Gynecol* 173: 346-347

- Petros PE, Ulmsten U (1997) Role of the Pelvic Floor in Bladder Neck Opening and Closure I: Muscle Forces. *Int Urogynecol J* 8:74-80
- Petros PE (1998) The pubourethral ligament - an anatomical and histological study in the live patient. *Int J Urogynecology* 9:154-157
- Petros PE (2010) *The Female Pelvic Floor. Function, Dysfunction and Management According to the Integral Theory*. Springer-Verlag, Berlin-Heidelberg
- Petros PE (2008) Pubovisceral muscle avulsion. *Aust N Z J Gynaecol* 48:124
- Petros PE, Swash M (2008) The Musculoelastic Theory of anorectal function and dysfunction. *J Pelviperineology* 27:89-93
- Petros P, Swash M, Kakulas B The Musculo-Elastic Theory of anorectal function and dysfunction, Experimental Study No. 8: Stress urinary incontinence results from muscle weakness and ligamentous laxity in the pelvic floor *Pelviperineology* 2008; 27: 106 -109
- Pierce LM, Coates KW, Kramer LA, Bradford JC, Thor KB, Kuehl TJ (2008) Effects of bilateral levator ani nerve injury on pelvic support in the female squirrel monkey. *Am J Obstet Gynecol* 198: 585.e1-585.e8
- Pieber D, Zivkovic F, Tamussino K (1998) Timing of urethral pressure pulses before and after continence surgery. *Neurourol Urodyn* 17:9-23
- Quiroz LH, Munoz A, Shippey SH, Gutman RE, Handa VL (2010) Vaginal parity and pelvic organ prolapse. *J Reprod Med* 55:93-98
- Rechberger T, Ulbjerg N, Oxlund H. (1988) Connective tissue Changes in the Cervix During Normal Pregnancy and Pregnancy Complicated by Cervical Incompetence. *Obstet Gynecol* 71:563-567
- Smith ARB, Hoskel GL, Warrel DW (1989) The role of partial denervation of the pelvic floor in the etiology of genitourinary prolapse and stress incontinence of urine: a neurophysiologic study. *Br J Obstet Gynaecol* 96:24-28
- South MM, Stinnett SS, Sanders DB, Weidner AC (2009) Levator ani denervation and reinnervation 6 months after childbirth. *Am J Obstet Gynecol* 200:519.e1-7
- Snooks S J, Swash M, Setchell M and Henry M M. Injury to innervation of pelvic floor sphincter musculature in childbirth. *LANCET* 1984 2 546-550.
- Swash M, Henry MM, Snooks SJ Unifying concept of pelvic floor disorders and incontinence. *Journal of the Royal Society of Medicine*, (1985),78: 906-911.
- Ulmsten U, Henriksson L, Johnson P, and Varhos G An ambulatory surgical procedure under local anesthesia for treatment of female urinary incontinence, *Int Urogynecol J* (1996); 7: 81-86.
- Uitto J, Bernstein EF (1998) Molecular Mechanisms of Cutaneous Aging: Connective Tissue Alterations in the Dermis. *Journal of Investigative Dermatology Symposium Proceedings* 3:41-44
- Van der Kooi JB, van Wanroy PJ, De Jonge MC, Kornelis JA (1984) Time separation between cough pulses in bladder, rectum and urethra in women. *J Urol* 132: 1275-1278
- Wagenlehner F, Bschleipfer T, Liedl B, Gunnemann A, Petros P, Weidner W. (2010) Surgical reconstruction of pelvic floor descent: Anatomic and functional aspects. *Urologia internationalis* 84: 1-9.
- Wyndaele JJ, De Wachter S (2008). The sensory bladder (1): an update on the different sensations described in the lower urinary tract and the physiological mechanisms behind them. *Neurourol Urodyn* 27: 274-278
- Zacharin RF (1963) A suspensory mechanism of the female urethra. *Journal of Anatomy* 97:423-427



Urinary Incontinence

Edited by Mr. Ammar Alhasso

ISBN 978-953-51-0484-1

Hard cover, 324 pages

Publisher InTech

Published online 04, April, 2012

Published in print edition April, 2012

Management strategies are framed within a multidisciplinary team structure and as such a range of specialists ranging from psychologists, specialist nurses, gynaecologists and urologists author the chapters. There are some novel methods outlined by the authors with their clinical application and utility described in detail, along with exhaustive research on epidemiology, which is particularly relevant in planning for the future.

How to reference

In order to correctly reference this scholarly work, feel free to copy and paste the following:

B. Liedl, O. Markovsky, F. Wagenlehner and A. Gunnemann (2012). The Role of Altered Connective Tissue in the Causation of Pelvic Floor Symptoms, Urinary Incontinence, Mr. Ammar Alhasso (Ed.), ISBN: 978-953-51-0484-1, InTech, Available from: <http://www.intechopen.com/books/urinary-incontinence/connective-tissue-looseness-and-development-of-pelvic-floor-dysfunction-and-symptoms>

INTech
open science | open minds

InTech Europe

University Campus STeP Ri
Slavka Krautzeka 83/A
51000 Rijeka, Croatia
Phone: +385 (51) 770 447
Fax: +385 (51) 686 166
www.intechopen.com

InTech China

Unit 405, Office Block, Hotel Equatorial Shanghai
No.65, Yan An Road (West), Shanghai, 200040, China
中国上海市延安西路65号上海国际贵都大饭店办公楼405单元
Phone: +86-21-62489820
Fax: +86-21-62489821

© 2012 The Author(s). Licensee IntechOpen. This is an open access article distributed under the terms of the [Creative Commons Attribution 3.0 License](https://creativecommons.org/licenses/by/3.0/), which permits unrestricted use, distribution, and reproduction in any medium, provided the original work is properly cited.

IntechOpen

IntechOpen