

We are IntechOpen, the world's leading publisher of Open Access books Built by scientists, for scientists

6,900

Open access books available

186,000

International authors and editors

200M

Downloads

Our authors are among the

154

Countries delivered to

TOP 1%

most cited scientists

12.2%

Contributors from top 500 universities



WEB OF SCIENCE™

Selection of our books indexed in the Book Citation Index
in Web of Science™ Core Collection (BKCI)

Interested in publishing with us?
Contact book.department@intechopen.com

Numbers displayed above are based on latest data collected.
For more information visit www.intechopen.com



Surgical Management of Prolonged Air Leak in Patients with Underlying Emphysema

Boon-Hean Ong¹, Bien-Keem Tan² and Chong-Hee Lim¹

¹*Department of Cardiothoracic Surgery,
National Heart Centre Singapore*

²*Department of Plastic, Reconstructive and Aesthetic Surgery,
Singapore General Hospital
Singapore*

1. Introduction

Prolonged air leak is one of the most common post-operative complications encountered after thoracic surgical operations involving mobilization or resection of lung parenchyma. Air leak typically manifests as persistent bubbling in a chest tube drainage system, but may also present with increasing subcutaneous emphysema or pneumothorax in a post-operative patient. No universal consensus exist as to the exact duration of air leak which constitutes a prolonged air leak, but it is generally regarded to exist if it is present for more than 5 days(1-4) or 7 days(2, 5-7) after initial surgery. It is an important complication that results in increased length of stay(8-15) and has been associated with other post-operative complications such as pneumonia(12, 14, 16), empyema(9, 10, 16) and ICU re-admission(12).

Patients with emphysema form a significant proportion of patients which will undergo thoracic surgical operations. Chronic smoking and emphysema predisposes an individual to developing a pneumothorax(17, 18) or carcinoma of the lung(19, 20) that may require surgical intervention for treatment. In addition, lung volume reduction surgery plays a role in the management of certain patients with advanced emphysema(21). Conversely, emphysema is regarded as a risk factor for developing prolonged air leak in cases where patients with emphysema require an operation(7). This is presumably because the underlying lung substrate in patients with emphysema is more easily injured during surgery and takes longer to heal.

The role of emphysema as a risk factor for prolonged air leak has been inferred from numerous surgical case series which reliably demonstrate that patients noted pre-operatively to have emphysema will have a higher incidence of prolonged air leak. However, a major weakness of these studies, is that they are heterogenous in their definition of prolonged air leak, patient population (eg age, definition of impaired lung function), type of operation performed (eg video assisted vs open, chemical vs mechanical pleurodesis, type/extent of resection) and methods used to prevent air leak (eg use of pleural tenting), which limits the ability to compare between individual studies. In addition, several studies analyzing the specific risk factors for developing this complication have consistently shown

that low FEV1 or FEV1/FVC will increase the risk of developing prolonged air leak after either pulmonary resection or lung volume reduction surgery (see below for details).

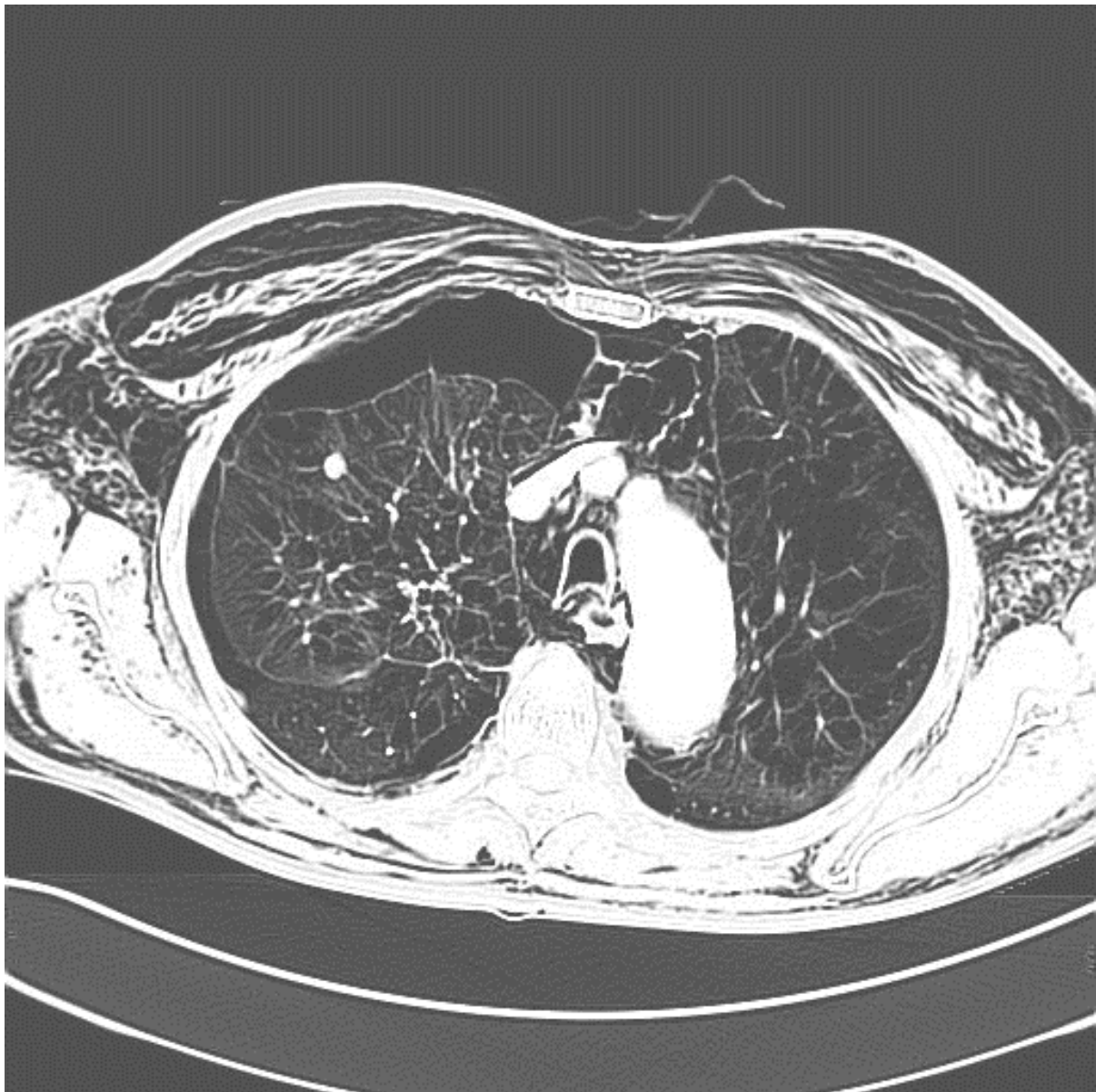


Fig. 1. Severe subcutaneous emphysema in a patient with underlying emphysema with prolonged air-leak.

For surgical pleurodesis, several authors have described their experience in performing this operation on both primary spontaneous pneumothorax and secondary spontaneous pneumothorax (which mainly consist of patients with underlying emphysema). The reported incidence of prolonged air leak in patients with primary spontaneous pneumothorax undergoing surgical pleurodesis has been reported to range from 0-3.8%, while it has been reported to range from 7.1-29.1% for patients with secondary spontaneous pneumothorax. A similar trend is also demonstrable in patients undergoing pulmonary resection for carcinoma of the lung, with an incidence of prolonged air leak of 4.2-18.2% in patients without underlying emphysema, compared to 5.4-44% in patients with underlying emphysema.

Author	Patient population	Type of pleurodesis	Definition of prolonged air leak (PAL)	Incidence of PAL in primary spontaneous pneumothorax	Incidence of PAL in secondary spontaneous pneumothorax
Hatz et al. (22)	95 patients with primary spontaneous pneumothorax requiring surgery 14 patients with secondary spontaneous pneumothorax requiring surgery (5 COPD patients)	VATS, excision of blebs, pleurectomy or talc powder (mechanical or chemical pleurodesis)	>2 days	2.1%	7.1%
Mouroux et al. (23)	75 patients with primary spontaneous pneumothorax requiring surgery 22 patients with secondary spontaneous pneumothorax requiring surgery (13 COPD patients)	VATS, excision of blebs, pleural abrasion or pleurectomy (mechanical pleurodesis)	>7 days	0 (excluded 1 patient who required conversion to open thoracotomy)	16.7% (excluded 4 patients who required conversion to open thoracotomy)
Noppen et al. (24)	28 patients with 31 episodes primary spontaneous pneumothorax requiring surgery 20 patients with 23 episodes of secondary spontaneous pneumothorax requiring surgery (6 COPD patients)	VATS, bleb ablation by electrocautery, talc powder (chemical pleurodesis)	>24 hours	0	26%
Passlick et al. (25)	65 patients with primary spontaneous pneumothorax requiring surgery 34 patients with secondary spontaneous pneumothorax requiring surgery (24 COPD patients)	VATS, excision of blebs, pleural abrasion ± pleurectomy (mechanical pleurodesis)	>7 days	1.7% (excluded 6 patients who required conversion to open thoracotomy)	16.6% (excluded 10 patients who required conversion to open thoracotomy)
Shaikhreza et al. (26)	480 patients with 550 episodes of primary spontaneous pneumothorax requiring surgery 89 patients with 94 episodes of secondary spontaneous pneumothorax requiring surgery (all patients with COPD)	VATS, excision of blebs, pleural abrasion, pleurectomy or talc powder (mechanical or chemical pleurodesis)	>5 days	3.8%	14.9%

Author	Patient population	Type of pleurodesis	Definition of prolonged air leak (PAL)	Incidence of PAL in primary spontaneous pneumothorax	Incidence of PAL in secondary spontaneous pneumothorax
Tanaka et al. (27)	130 patients with 100 episodes of primary spontaneous pneumothorax requiring surgery 67 patients with 24 episodes of secondary spontaneous pneumothorax requiring surgery (22 COPD patients)	Open thoracotomy, excision of blebs, pleural abrasion	>5 days	3%	29.1%

Table 1. Studies comparing the incidence of prolonged air leak in patients with primary versus secondary spontaneous pneumothorax undergoing surgical pleurodesis.

Author	Patient population	Type of pulmonary resection	Definition of prolonged air leak (PAL)	Incidence of PAL in patients without COPD	Incidence of PAL in patients with COPD
Lee et al. (28)	133 patients with FEV1 >80% predicted 104 patients with FEV1<80% predicted	Pneumonectomy (9.8% vs 10.6%), bilobectomy (4.5% vs 6.7%), lobectomy (84.2% vs 81.7%), wedge resection (1.5% vs 1.0%)	Not defined	6.7% (excludes pneumonectomy patients)	5.4% (excludes pneumonectomy patients)
Santambrogio et al. (29)	45 patients with FEV1 >80% predicted 43 patients with FEV1 <80% predicted	Upper lobectomy (64.4% vs 58.1%), other lobectomy (35.6% vs 41.9%)	>7 days	13.3%	16.2%
Sekine et al. (30)	166 patients with FEV1 >70% predicted & FEV1/FVC>70% 78 patients with FEV1 <70% predicted & FEV/FVC<70%	Pneumonectomy (13.9% vs 18%), bilobectomy (13.9% vs 19.2%), lobectomy (68.7% vs 58.8%), segmentectomy and wedge resection (2.4% vs 3.9%)	>10 days	4.2% (excludes pneumonectomy patients)	18.8% (excludes pneumonectomy patients)
Subotic et al. (31)	47 patients with FEV1/FVC >70% 35 patient with FEV1/FVC<70%	Pneumonectomy (53.2% vs 28.6%), upper lobectomy (23.4% vs 34.3%), other lobectomy (23.4% vs 37.1%)	Not defined	18.2% (excludes pneumonectomy patients)	44% (excludes pneumonectomy patients)

Table 2. Studies comparing the incidence of prolonged air leak in patients with COPD versus those without COPD undergoing pulmonary resection.

Author	Patient population	Type of lung volume reduction surgery	Type of intra-operative adjuncts used	Definition of prolonged air leak (PAL)	Incidence of PAL
Cicccone et al. (32)	250 patients, mean pre-op FEV1 26% of predicted	Bilateral LVRS via median sternotomy	Pleural tenting	>7 days	45.2%
DeCamp et al. (12)	580 patients, mean pre-op FEV1 26.8% of predicted	Bilateral VATS (30%) Bilateral LVRS via median sternotomy (70%)	Variety of methods (not standardized) including buttressing, sealants, tenting and pleurodesis	>7 days	45%
Ledrer et al. (33)	23 patients, mean pre-op FEV1 25% of predicted	Bilateral VATS (61%) Bilateral LVRS via median sternotomy (39%)	Buttressed staple lines	>7 days	39%

Table 3. Studies reporting the incidence of prolonged air leak in patients undergoing lung volume reduction surgery.

For lung volume reduction surgery, the incidence of prolonged air leak is much higher, ranging from 39-45.2%. This is expected, as the operation is conducted on both lungs, and usually on patients with more advanced underlying lung disease.

This review will discuss the pathogenesis, risk factors, intra-operative and post-operative management strategies for prolonged air leak in patients with emphysema based on current available literature. In addition, we propose an algorithm for the management of prolonged air leak in this group of patients based on this discussion, and also define specific criteria for surgical intervention for prolonged air leak that we follow at our institution. Several recent reviews have previously discussed the problem of prolonged air leaks, but do not focus specifically on patients with emphysema(3, 4) or neglect to discuss the utility of surgical intervention in greater detail(2, 34) which we believe plays an important role for this challenging clinical problem, particularly in the small number (but no less important) of patients who are refractory to all other forms of therapy.

2. Pathogenesis and factors influencing incidence of prolonged air leak in patients with emphysema

Some degree of post-operative air leak is generally unavoidable in operations involving pulmonary resection or mobilization, usually reflective of an alveolo-pleural fistula arising from exposed alveoli, whereas more severe leaks suggest fistulas arising from larger, more proximal bronchi(5, 7). The duration of the leak is related to the severity of the air leak as

well as the time taken for the exposed parenchyma to heal, which occurs via an inflammatory reaction that results in granulation tissue formation and fibrin deposition(7). Moreover, this process is widely accepted to be facilitated by re-expansion of the lung to allow contact between the lung and parietal pleura.

Thus, it would follow that factors that would increase the risk of prolonged air leak include impaired wound healing (older age, more severe underlying emphysema), greater intra-operative surgical trauma (re-operations, extensive adhesions) and incomplete lung expansion post-operatively. This has been confirmed by a number of studies on patients undergoing pulmonary resection which have looked at specific factors that influence the incidence of prolonged air leak, summarized below.

Though no study looked specifically at risk factors for prolonged air leak in patients with emphysema undergoing pulmonary resection, DeCamp and colleagues(12) analyzed the data from the surgical arm of the National Emphysema Treatment Trial and found that the following factors increase the risk developing air leak after lung volume reduction surgery:

- Caucasian race (however, only 4.7% of trial participants were from minorities, so there may be an element of selection bias)
- Inhaled (but not oral) steroid use
- Poorer pulmonary function (lower FEV1 predicted or DLCO predicted)
- Upper lobe disease
- Pleural adhesions

Whether this can be extrapolated to patients with emphysema undergoing other forms of thoracic operations has not been demonstrated.

Author	Patient population	Definition of prolonged air leak	Incidence of prolonged air leak	Risk factors identified
Abolhoda et al. (11)	100 patients undergoing open upper lobectomy	>7 days	26%	- FEV1/FVC <50%
Brunelli et al. (16)	588 patients undergoing open lobectomy or bilobectomy	>7 days	15.6%	- low predicted post-operative FEV1 - pleural adhesions - upper lobectomy
Brunelli et al. (35)	658 patients undergoing open lobectomy	>5 days	13%	- age >65 - FEV1 <80% predicted - pleural adhesions - BMI < 25.5
Cerfolio et al. (36)	669 patients undergoing lobectomy, segmentectomy or wedge resection	>4 days	8%	- male gender - FEV1 <79% predicted - steroid use - lobectomy as opposed to lesser resection
Isowa et al. (37)	138 patients undergoing open lobectomy or segmentectomy	>10 days	18.1%	- diabetes - low serum albumin

Author	Patient population	Definition of prolonged air leak	Incidence of prolonged air leak	Risk factors identified
Lee et al. (38)	580 patients undergoing open lobectomy or segmentectomy	>7 days	18.6%	- low FEV1 predicted - low DLCO2 predicted - pleural adhesions
Liberman et al. (14)	1393 patients undergoing open lobectomy or bilobectomy	>5 days	5.6%	- female gender - history of smoking - low FEV1 predicted
Rivera et al. (39)	24,113 patients undergoing open lobectomy, bilobectomy, segmentectomy, bulla resection or LVRS	>7 days	6.9%	- male gender - low BMI - high dyspnea score - pleural adhesions - upper lobe disease - type of resection (LVRS > bilobectomy > lobectomy / segmentectomy > bulla resection)
Stolz et al.(13)	134 patients undergoing open lobectomy	>7 days	9.7%	- FEV1 <70% and FEV/FVC<70%

Table 4. Studies analyzing risk factors for prolonged air leak in patients undergoing pulmonary resection.

Based on the above mentioned factors, methods geared to the prevention of prolonged air leaks aim to minimize intra-operative surgical trauma or ensure more complete lung expansion. These approaches can be broadly divided into intra-operative and post-operative strategies.

3. Intra-operative strategies for prevention of prolonged air leak

3.1 General

The thoracic surgeon should ensure that lung tissue is handled as carefully as possible during dissection and manipulation to ensure minimal trauma, particularly in patients with emphysema, where the underlying lung is fragile. Any obvious parenchymal tears that are identified during surgery should be repaired meticulously. In addition, the remaining lung should be completely mobilized and decortication should be performed if necessary to aid maximal re-expansion of remaining lung tissue after pulmonary resection.

3.2 Fissureless technique for lobectomy

Conventional lobectomy involves dissection of lung parenchyma within the fissures by sharp or blunt dissection for exposure of the pulmonary artery that may result in air leaks. The fissureless technique involves exposing the pulmonary artery without such dissection, only using staplers for division of lung parenchyma when it is required(40, 41).

Although the efficacy of this technique has not been studied in patients with emphysema specifically, two previous studies on a general population of patients undergoing

pulmonary resection have shown that this technique significantly decreases the incidence of prolonged air leak. Gomez-Caro and associates(42) demonstrated in a randomized prospective study of 63 patients undergoing either lobectomy or bilobectomy, that the incidence of prolonged air leak (>5 days) in patients whom a fissureless technique was employed was 3.2%, compared to 21.8% for those in whom conventional dissection was performed. A more recent retrospective case control study by Ng et al.(43) looking at 93 patients undergoing right upper lobectomy only, revealed similar results, with patients in the fissureless technique group having an incidence of prolonged air leak (>7 days) of 7.6%, compared to 22.2% in patients in the conventional lobectomy group.

3.3 No cut plication (non-resectional) technique for lung volume reduction surgery

For lung volume reduction surgery, an alternative technique involving no cut plication has been described by various authors as having lower rates of prolonged air leak while having short to intermediate term improvement in pulmonary function comparable to conventional lung volume reduction surgery(44-47). With this alternative technique, lung tissue is folded up or pushed down onto itself before being stapled together instead of performing staple excision of lung tissue in traditional lung volume reduction surgery.

Swanson and colleagues reported that in their series of 50 procedures performed on 32 patients, the incidence of prolonged air leak (>7 days) was only 8.6%(44). In a series of 20 patients operated by Iwasaki and associates, they reported that no patient had an air leak beyond 5 days(45). The largest reported series of 66 patients at Tor Vergata University by Tacconi, Pompeo and Mineo, demonstrated an incidence of prolonged air leak (>7 days) of 18% in patients undergoing non-resectional lung volume reduction surgery under thoracic epidural anaesthesia, compared to 40% of patients in a control group undergoing conventional lung volume reduction surgery under general anaesthesia(48).

Moreover, Pompeo and colleagues at the Tor Vergata University also recently published a randomized control trial comparing 32 patients undergoing non-resectional lung volume reduction surgery with thoracic epidural anaesthesia against 31 patients undergoing conventional lung volume reduction surgery with general anaesthesia and found that the incidence of prolonged air leak in the former was 18.8% compared to 48.4% for the latter, while survival and improvement in post-operative pulmonary function were similar in both groups (49). The same group also compared the results of 41 patients undergoing non-resectional lung volume reduction surgery under thoracic epidural anaesthesia against 19 patients undergoing non-resectional lung volume reduction surgery under general anaesthesia, and found that the occurrence of prolonged air leak was similar between the two groups (12.1% vs 26.3%, $p=0.26$), which suggests that the type of lung volume reduction surgery rather than the type of anaesthesia was the main factor in determining risk of prolonged air leak(50).

The above published data indicate that this technique may potentially be superior to the traditional lung volume reduction surgical approach in terms of reducing morbidity from prolonged air leak. However, the long-term durability of pulmonary function improvement after plication is still not known, as the studies so far have only involved small numbers of patients and only limited follow-up, thus more research on this technique is required before its widespread adoption can be recommended.

3.4 Buttress material for staple lines

Another area of study in the intra-operative prevention of air leaks during thoracic surgery has been the use of buttress material for staple lines, which in theory would help reinforce the fragile staple lines and thus prevent air leak from these areas of weakness. A variety of buttress materials have been described for this purpose, both synthetic (eg polytetrafluoroethylene(51), polydioxanone(52)) and biological [bovine pericardial strips(53-56), bovine collagen(57), autologous parietal pleura(58)]. However, only a few have been investigated in clinical practice, the most widely studied of which are bovine pericardial strips. Unfortunately, the cost of using these are high(57), and the few small studies that have been performed on a general population of patients undergoing pulmonary resection have not shown a clear benefit(53, 54). Several studies directed at emphysema patients specifically have been performed with more consistent results, but these are limited to those undergoing lung volume reduction surgery or bullectomy(55, 56, 58). On the other hand, an analysis of factors influencing post-operative air leak in patients undergoing lung volume reduction surgery in the National Emphsema Treatment Trial did not find that use of staple line buttressing (regardless of material) helpful in preventing or shortening duration of air leak(12).

In summary, current evidence suggest that the use of buttressing staple lines in patients with emphysema undergoing lung volume reduction surgery or bullectomy may be useful in reducing incidence of prolonged air leak, but its use in other operations, particularly pulmonary resection has not been demonstrated.

A table summarizing the results of the various studies mentioned above is presented below.

Author	Buttress material	Patient population	Definition of prolonged air leak	Incidence of prolonged air leak	Time to chest tube removal (mean)	Length of stay (mean)
Miller et al.(53)	Bovine pericardial strips + stapler vs stapler alone	80 patients undergoing open lobectomy (65) or segmentectomy (15)	N/A	N/A	5.9 vs 6.3 days, p=0.62	8 vs 9 days, p=0.24
Venuta et al.(54)	Bovine pericardial strips + stapler vs stapler alone vs conventional cautery, clamp and ties	30 patients undergoing open lobectomy	>7 days	0% vs 20% vs 10%	N/A	4.4 vs 7.8 vs 7.2 days
Hazelrigg et al.(55)	Bovine pericardial strips + stapler vs stapler alone	123 patients with emphysema undergoing unilateral VATS LVRS	N/A	N/A	7.9 vs 10.4 days, p=0.04	8.6 vs 11.4 days, p=0.03
Stammberger et al.(56)	Bovine pericardial strips + staplers vs stapler alone	65 patients with emphysema undergoing bilateral VATS LVRS	Not defined	15.6% vs 21.2%	7.6 vs 9.7 days, p=0.045	12.7 vs 15.7 days, p=0.14

Author	Butress material	Patient population	Definition of prolonged air leak	Incidence of prolonged air leak	Time to chest tube removal (mean)	Length of stay (mean)
Baysungur et al.(58)	Autologous pleura + stapler vs stapler alone	22 patients with emphysema undergoing open bullectomy	>7 days	0% vs 8.3%	2.7 vs 4.8 days, p=0.04	4.2 vs 5.9 days, p=0.09
Fischel et al.(57)	Bovine pericardial strips + staples vs Bovine collagen + staples	56 patients with emphysema undergoing bilateral VATS LVRS	>7 days	35.7% vs 44.6%	8.6 vs 10.4 days	N/ A

Table 5. Studies comparing the utility of buttressing staple lines in preventing prolonged air leak.

3.5 Pulmonary sealants

Pulmonary sealants have been the focus of a large amount of research in the area of intra-operative prevention air leaks, with over a dozen studies on various types of sealants including fibrin glue(59-62), PEG-based sealants(63-70) and coated collagen patches(71-73). However, as with studies on other strategies, these papers have generally not focused on patients with emphysema, and individually these studies each have small cohort sizes with very mixed patient populations as well as varying methods for reporting efficacy.

Moreover, the overall results of these studies so far have found no clear advantage in their routine use on all patients(74). Thus, the use of sealants should best be reserved for patients at highest risk for developing post-operative prolonged air leak(35, 38), especially since rare complications, particularly empyema(63, 67, 75) may arise from the use of pulmonary sealants. Indeed, the studies which have focused on patients with emphysema have more consistently shown a significant reduction in the incidence of post-operative prolonged air leak and length of stay(62, 73).

Author	Surgical sealant	Patient population	Definition of prolonged air leak	Incidence of prolonged air leak	Time to chest tube removal (mean)	Length of stay (mean)
Fleisher et al.(59)	Fibrin glue vs none	28 patients undergoing open lobectomy	>7 days	14.3% vs 7.1%	6.0 vs 5.9 days, p=0.95	9.8 vs 11.5 days, p=0.21
Wong et al.(60)	Fibrin glue vs none	66 patients undergoing open lobectomy, segmentectomy or decortication	N/ A	N/ A	6 vs 6 days, p=0.8 (median)	8 vs 9 days, p=0.57 (median)
Fabian et al.(61)	Fibrin glue vs none	100 patients undergoing open bilobectomy, lobectomy, segmentectomy or wedge resection	>7 days	2% vs 16%, p=0.015	3.5 vs 5.0 days, p=0.02	4.6 vs 4.9 days, p=0.318

Author	Surgical sealant	Patient population	Definition of prolonged air leak	Incidence of prolonged air leak	Time to chest tube removal (mean)	Length of stay (mean)
Porte et al.(63)	PEG based sealant vs none	124 patients undergoing open bilobectomy or lobectomy	>6 days	13% vs 22%, p=not significant	N/ A	9.2 vs 8.6 days, p=not significant
Wain et al.(64)	PEG based sealant vs none	172 patients undergoing open bilobectomy, lobectomy, segmentectomy or wedge resection	>7 days	2.5% vs 7%	4.5 vs 5.2 days, p=0.41	7.4 vs 10.1 days, p=0.78
Allen et al.(65)	PEG based sealant vs none	161 patients undergoing open bilobectomy, lobectomy, segmentectomy, wedge resection, decortications or LVRS	>7 days	14% vs 12%, p=0.813	6.8 vs 6.2 days, p=0.679 (median)	6 vs 7 days, p=0.04 (median)
De Leyn et al.(66)	PEG based sealant vs none	121 patients undergoing open lobectomy or segmentectomy	N/ A	N/ A	3.90 vs 3.92 days, p=0.559 (median)	13 vs 12 days, p=0.292 (median)
Macchiarini et al.(67)	PEG based sealant vs none	24 patients undergoing open bilobectomy, lobectomy or wedge resection	N/ A	N/ A	6.1 vs 6.9 days, p=0.9	13 vs 14.4 days, p=0.4
Venuta et al.(68)	PEG based sealant vs none	50 patients undergoing lobectomy	>7 days	8% vs 20%	5.6 vs 10 days, p=0.03	8 vs 11.6 days, p=0.009
D' Andrilli et al.(69)	PEG based sealant vs none	203 patients undergoing open bilobectomy, lobectomy, segmentectomy or wedge resection	N/ A	N/ A	N/ A	5.7 vs 6.2 days, p=0.18
Tan et al.(70)	PEG based sealant vs none	121 patients undergoing open bilobectomy, lobectomy or wedge resection	N/ A	N/ A	4 vs 3 days (median)	6 vs 7 days (median)
Lang et al.(71)	Coated collagen patch vs none	189 patients undergoing open lobectomy	Not defined	4.2% vs 3.2%	N/ A	N/ A
Anegg et al.(72)	Coated collagen patch vs none	173 patients undergoing open lobectomy or segmentectomy	>7 days	24% vs 32.46%, p=0.282	5.1 vs 6.3 days, p=0.022	6.2 to 7.7 days, p=0.01

Author	Surgical sealant	Patient population	Definition of prolonged air leak	Incidence of prolonged air leak	Time to chest tube removal (mean)	Length of stay (mean)
Rena et al.(73)	Coated collagen patch vs none	60 patients with COPD undergoing open lobectomy or segmentectomy	>7 days	3.3% vs 26.7%, p=0.029	3.53 vs 5.9 days, p=0.002	5.87 vs 7.5 days, p=0.01
Moser et al.(62)	Fibrin glue vs none	25 patients with emphysema undergoing bilateral VATS LVRS	>7 days	4.5% vs 31.8%, p=0.031	2.83 vs 5.88 days, p<0.001	N/ A
Tansley et al.(76)	Bovine based surgical adhesive vs none	52 patients undergoing open lobectomy, segmentectomy or other resection	N/ A	N/ A	4 vs 5 days, p=0.012 (median)	6 vs 7 days, p=0.004 (median)
Belcher et al. (75)	Bovine based surgical adhesive vs fibrin glue	102 patients undergoing open bilobectomy, lobectomy, segmentectomy, or other resection	>7 days	18% vs 23%, p=0.627	5 vs 5 days, p=0.473	8 vs 7 days, p=0.382

Table 6. Studies comparing the utility of pulmonary sealants in preventing prolonged air leak.

3.6 Minimizing post-resectional spaces

Minimizing the potential space left behind after pulmonary resection allows for a more complete apposition of the lung surface with the parietal pleura to encourage the resolution of any post-operative air leak. Usually this can be accomplished with straightforward means such as the proper placement of chest tubes, division of the inferior pulmonary ligament and lysis of all adhesions at the conclusion of surgery or the use of adequate analgesia, chest physiotherapy or bronchoscopy to clear the airways of mucus and blood post-operatively to promote maximal re-expansion of the residual lung (7). In the event that the above mentioned methods are insufficient, several techniques have been described, including the creation of a pleural tent, creation of a pneumoperitoneum or deliberate diaphragmatic paralysis.

Again, interpretation of the results of studies on these methods to reduce post-resectional spaces is complicated by the heterogenous inclusion criteria and method of reporting outcomes in these studies. Furthermore, almost none have looked specifically at patients with emphysema, thus making it difficult to simply extrapolate the results of these studies to patients with emphysema.

Nonetheless, amongst the methods mentioned previously, pleural tenting has been the most widely studied technique for preventing prolonged air leak by minimizing post-resectional spaces. This involves stripping the parietal pleural over the apex, which is then resutured over the chest wall to produce an extrapleural space(7, 77). It has been used as a means for

controlling the size of the potential space post-pulmonary resection in the upper thoracic cavity, and thus has been predominantly studied in patients undergoing upper lobectomy.

In a retrospective review on risk factors for prolonged post-operative air leak, Brunelli and associates(16) noted that patients with upper lobectomies who underwent a pleural tent had a significantly decreased duration of air leak compared to those who did not undergo a similar adjunctive procedure. Nevertheless, he later published a retrospective case matched analysis comparing patients with prolonged air leak after pulmonary resection and those without, which did not demonstrate that pleural tenting conferred any protective effect(9). DeCamp et al.(12) in reviewing the factors influencing air leak post-lung volume reduction surgery in patients from the National Emphysema Treatment Trial also did not find a significant decrease in incidence or duration of air leak in patients who underwent tenting compared to those who did not undergo tenting.

In addition, a number of randomized prospective studies have also been performed to assess its efficacy, and in general, the studies conducted on pleural tenting have shown an overall beneficial effect in terms of decreasing incidence of air leak, time to chest tube removal and length of stay. However, this procedure adds to operative time and may cause bleeding(35) though these were not shown to be significantly increased compared to controls in the studies below.

The table below summarizes the results of the randomized prospective studies performed to evaluate this technique.

Author	Patient population	Definition of prolonged air leak	Incidence of prolonged air leak	Time to chest tube removal (mean)	Length of stay (mean)
Brunelli et al.(77)	200 patients undergoing open upper lobectomy or bilobectomy (100 with tenting vs 100 without)	>7 days	14% vs 32% p=0.003	7 vs 11.2 days, p<0.0001	8.2 vs 11.6 days, p<0.0001
Allama et al.(78)	48 patients undergoing open upper lobectomy (23 with tenting vs 25 without)	>5 days	9% vs 40%, p=0.02	4.6 vs 5.6 days, p=0.11	4.96 vs 5.7 days, p=0.05
Okur et al.(79)	40 patients undergoing open upper lobectomy or bilobectomy (20 with tenting vs 20 without)	>5 days	0 vs 30%	4.3 vs 7.4 days, p<0.0001	7.6 vs 9.35 days, p=0.024

Table 7. Studies comparing the utility of pleural tenting in preventing prolonged air leak.

Conversely, the creation a pneumoperitoneum has been utilized to minimize the post-resectional space in the lower thoracic cavity. This has been described as both an intra-operative adjunct to prevent prolonged air leak(80) as well as a post-operative technique(81-83) to treat it. It can be accomplished through instillation of air into the peritoneal cavity by

a variety of means, including under direct vision through a transdiaphragmatic opening made in the diaphragm during surgery(80), via insertion of a peritoneal dialysis catheter under local anesthesia(81), or with the aid of a Veres needle under local anesthesia(82, 83) .

A small randomized prospective trial by Cerfolio and colleagues(80) studied 16 patients undergoing right middle and lower bilobectomy, dividing them into a group who underwent intra-operative pneumoperitoneum creation and a group who did not undergo this procedure. 0/8 patients with an intra-operative pneumoperitoneum had air leak by POD3, compared to 4/8 patients who did not have an intra-operative pneumoperitoneum ($p<0.001$). Moreover, patients in the former group had a median hospitalization stay of 4 days compared to 6 days for patients in the latter group ($p<0.001$). Thus, this is an interesting technique, but conclusions on its efficacy are difficult to draw based on the limited data available. The results of post-operative pneumoperitoneum creation will be discussed later in the section on post-operative strategies for management of prolonged air leak.

Deliberate diaphragmatic paralysis is an alternative method used to decrease the potential space in the lower thoracic cavity to allow for more rapid resolution of air leak. Several means are available to achieve this, including infiltration of the phrenic nerve with local anesthetic, phrenic nerve crush or sectioning. The main drawback of diaphragmatic paralysis is the compromise in ventilatory function and cough mechanism. Thus, the use of para-phrenic local anesthetic has the advantage over phrenic nerve crush or sectioning, in that it only resulting in temporary paralysis, so that diaphragmatic function may recover after the effect of the local anesthetic wears off. A recent case report by Clavero and associates(84) explains how an epidural catheter can be placed in close proximity of the phrenic nerve through video-assisted thoracoscopic surgery or thoracotomy, so that the managing physician can dictate the exact duration of diaphragmatic paralysis required to resolve the air leak before reversing the effect of the local anesthetic infusion. However, no large studies specifically describing the use of diaphragmatic paralysis for preventing prolonged air leaks are available.

4. Post-operative strategies for management of prolonged air leak

4.1 Bronchoscopy and endobronchial techniques

Bronchoscopy plays an important role in the post-operative management of prolonged air leak. It can be used to clear the airways of mucus and blood to aid maximal re-expansion of the lung to promote resolution of air leaks. Furthermore, it should be performed in all patients with persistent air leak to exclude stump dehiscence, as its presence will often necessitate surgery to treat the problem. Should surgery be contraindicated for whatever reason, a large number of endobronchial approaches have been studied as an alternative therapeutic option for bronchopleural fistulas, including the use of glue(85, 86), polidocanol(87), tetracycline(88), coils(89), surgicel(90), gelfoam(91), tracheobronchial stents(92), atrial septal defect closure devices(93) and even lasers(94). Unfortunately, experience with these techniques have been limited to mostly case reports and case series, with no controlled studies comparing the different methods or comparing them against surgical therapy. A recent systematic review of several of the larger case series by West et al. (95) showed that among 85 patients with post-pneumonectomy bronchopleural fistulas, endobronchial therapy (40 fibrin glue, 15 cyanoacrylate glue, 19 polidocanol, 6 lasers, 5

stents) succeeded in treating only 30% of them. Overall mortality was 40%, with many patients requiring multiple bronchoscopic procedures or additional surgical drainage.

In addition, the placement of endobronchial valves is a new technique that has emerged recently for the treatment of persistent air leak in patients with underlying lung disease such as emphysema that are not candidates for more extensive procedures such as surgery(96, 97). Endobronchial one-wave valves inserted via bronchoscopy were initially developed as an investigational technique to treat emphysema by promoting atelectasis of emphysematous lungs distal to the valve, which would allow air to exit via the valve but not re-enter. They have now been used in selected patients with persistent air leaks, in hope that they accelerate closure of the leak by minimizing flow of air through the leak(98).

The procedure can be performed either under sedation or general anesthesia, using either a flexible or rigid bronchoscope. A balloon tipped catheter is used to provide selective bronchial occlusion to determine the segmental or subsegmental airway that results in the greatest decrease in air leak. The endobronchial valve is then inserted in these airways (98, 99). The results of the two largest series on endobronchial valve placement are summarized below, and the overall conclusion is it is a promising mode of therapy particularly for patients with no other therapeutic options.

Author	Patient population	Duration of air leak prior to valve placement (median)	Number of patients with improvement	Duration of chest tube drainage after valve placement (median)	Duration of hospitalization after valve placement (median)	Complications
Travaline et al.(98)	40 patients with underlying lung disease (30% COPD) that had persistent air leaks (17.5% post-operative)	20 days	37 (92.5%)	7.5 days	11 days	6 (valve expectoration, malpositioning of the valve requiring redeployment, pneumonia, oxygen desaturation and MRSA colonization)
Gillespie et al.(99)	7 patients with underlying lung disease (71% COPD) that had persistent air leaks (71% post-operative)	28 days	7 (100%)	16 days	3 days	Nil

Table 8. Studies reporting the efficacy of endobronchial valve placement in the treatment of prolonged air leak.

4.2 Bedside pleurodesis

Instillation of a sclerosing agent into the pleural space elicits an inflammatory reaction in the pleura that allows for the obliteration of the pleural space and resolution of an air leak. A variety of agents have been described for this purpose, including silver nitrate(100), quinacrine(101), minocycline(102), tetracycline(103), doxycycline(104), erythromycin(105), bleomycin(106), iodopovidone(107), talc powder(14) and autologous blood(108-111). Be that as it may, contemporary literature has mainly focused on autologous blood for treatment of persistent post-operative air leaks, so the utility of the other agents for this clinical context are not as well known. Also, these studies were not limited to patients with emphysema, so their results may not be directly applicable for these patients with persistent post-operative air leaks. However, based on available published data, bedside pleurodesis is a reasonably efficacious modality of treatment with few adverse effects, so it is often used as first line therapy for patients with prolonged air leak, even in our own institution.

Several small observational studies have demonstrated the efficacy and safety of autologous blood in treating post-operative prolonged air leak(108-110). In these studies, patients with prolonged air leak (>5-10 days) after undergoing a variety of operations (lobectomy, wedge resection, bullectomy, lung volume reduction or decortication) were treated with 1-2 injections of autologous blood pleurodesis with resolution of air leak in all patients within 48 hours of therapy. No major complications occurred except for fever, pneumonia or prolonged pleural effusion in a minority of patients.

In addition, Shackcloth et al.(111) performed a randomized prospective study on 20 post-lobectomy patients with prolonged air leak (>5 days) to evaluate autologous blood pleurodesis compared to controls. They showed that there was a statistically significant ($p<0.001$) reduction in median time to chest tube removal (6.5 vs 12 days) and hospital discharge (8 vs 13.5 days) with autologous blood pleurodesis. One patient in the pleurodesis arm however developed an empyema.

As for the other forms of chemical pleurodesis, Liberman and associates(14) reported their experience with 41 patients who underwent chemical pleurodesis (30 talc, 7 doxycycline, 1 doxycycline+talc, 1 bleomycin, 1 bleomycin+talc) for prolonged air leak (>5 days) after undergoing lobectomy or bilobectomy. Sclerosis was successful in 40 patients (97.6%), with the remaining one patient having to undergo a pectoralis major flap for persistent air leak despite talc pleurodesis. Also, one patient developed empyema after talc pleurodesis.

As indicated above, complications of bedside pleurodesis include mainly consist of fever, pain and empyema. In addition, the most feared complication of talc pleurodesis is a systemic inflammatory response to talc that can result in acute respiratory distress syndrome(112, 113) particularly if the talc particle size is small(114). However, it has previously been found to be not associated with increased mortality in a meta-analysis of patients with malignant pleural effusion undergoing talc pleurodesis(115).

4.3 Post-operative creation of pneumoperitoneum

As mentioned previously, the creation of a pneumoperitoneum has been described as both an intra-operative as well as a post-operative method of controlling prolonged air leaks. This involves the instillation of air into the peritoneal cavity via insertion of a peritoneal

dialysis catheter under local anesthesia(81), or with the aid of a Veres needle under local anesthesia(82, 83). The creation of a pneumoperitoneum is often combined with a form of pleural sclerosis, such as talc(81, 82) or autologous blood(83), to aid the resolution of air leak. Several potential disadvantages of this technique include the risk of insertion of peritoneal dialysis catheter / Veres needle (eg bleeding, injury to intra-abdominal viscera) and possible respiratory compromise from the creation of the pneumoperitoneum.

Not many studies have been performed to evaluate this modality of therapy, except for a few isolated case reports, so the technique has shown promise in treatment of some patients but has not been evaluated on a large scale basis. Handy and associates(81) reported the successful use of this technique to resolve a persistent air leak of more than 3 weeks duration in a patient with emphysema who underwent lung volume reduction surgery. De Giacomo and colleagues(82) described the use of post-operative pneumoperitoneum to manage persistent air leak (>5 days) in 14 patients who underwent pulmonary resection for lung cancer, with resolution of the air leak occurring within 4-12 (mean 8) days after the procedure. The most recent paper assessing this technique by Korasidis et al.(83) demonstrated that combined post-operative pneumoperitoneum and autologous blood patch was able to control prolonged air leak (>3 days) present in 39 patients who underwent pulmonary resection for lung cancer within 144 hours of therapy. No major complications with the technique were reported by any of the above studies.

4.4 Optimal chest tube management and outpatient chest tube management

Appropriate chest tube management has also been shown to influence the duration of post-operative air leak. With respect to chest tube suction, it may be viewed in one of two ways. Firstly, chest tube suction may promote pleural apposition to decrease duration of air leaks, or alternatively, suction may cause tension on suture lines to prolong air leaks. The experience in lung volume reduction surgery had previously demonstrated that duration of prolonged air leak was decreased by avoiding routine chest tube suction in these patients(116).

This was subsequently investigated in several randomized prospective studies to see if this also held true in patients undergoing other forms of thoracic operations. For patients undergoing apical pleurectomy following primary spontaneous pneumothorax, Ayed demonstrated that converting to water seal (no suction) after a period of initial active suction significantly decreased the risk of prolonged air leak and duration of chest tube drainage compared to active suction throughout(117). A similar benefit of converting to water seal after a period of initial active suction for patients undergoing pulmonary resection (lobectomy, segmentectomy or wedge resections) was demonstrated by two separate groups(118, 119). However, a comparable study by Brunelli and associates(120) showed that water seal had no advantage over active suction when limited to a population of patients undergoing lobectomy. A follow-up study demonstrated that in patients undergoing lobectomy, alternate suction (at night) and water seal (during the day) was better than water seal alone(121).

A different approach was evaluated by Alphonso and colleagues, who studied a mixed cohort of patients undergoing a variety of operations (VATS as well as open lobectomy, wedge resections, lung biopsies or pneumothorax operations) and found that adopting

water seal immediately after surgery showed no difference in air leak duration compared to active suction(122).

Whether these approaches are applicable to patients with underlying emphysema undergoing pulmonary resection or pleurodesis has yet to be conclusively demonstrated, but a strategy of minimizing duration of chest tube suction or alternating it with water seal would be prudent based on evidence available so far. In addition, it should be noted that patients on water seal, particularly those with large air leaks, should be monitored for evidence of increasing subcutaneous emphysema or enlarging pneumothorax, as these patients will need to be placed back on active suction to prevent clinical deterioration(118).

Author	Patient population	Chest tube management	Definition of prolonged air leak	Incidence of prolonged air leak	Time to chest tube removal (mean)
Ayed(117)	100 patients undergoing VATS pleurodesis for primary spontaneous pneumothorax	Initial chest tube suction, then water seal vs active suction throughout	>5 days	2% vs 14% (p=0.03)	2.7 vs 3.8 days (p=0.004)
Cerfolio et al.(118)	33 patients undergoing bilobectomy, lobectomy, segmentectomy or wedge resection	Initial chest tube suction, then water seal vs active suction throughout	NA	NA	NA
Marshall et al.(119)	68 patients undergoing lobectomy, segmentectomy or wedge resection	Initial chest tube suction, then water seal vs active suction throughout	NA	NA	3.33 vs 5.47 days (p=0.06)
Brunelli et al.(120)	145 patients undergoing bilobectomy or lobectomy	Initial chest tube suction, then water seal vs active suction throughout	>7 days	27.8% vs 30.1% (p=0.8)	11.5 vs 10.3 (p=0.2)
Brunelli et al.(121)	94 patients undergoing bilobectomy or lobectomy	Initial chest tube suction, then water seal vs alternating suction (at night) and water seal (during the day)	>7 days	19% vs 4% (p=0.02)	8.6 vs 5.2 days (p=0.002)
Alphonso et al.(122)	239 patients undergoing lobectomy, segmentectomy, wedge resection or pneumothorax operations	Immediate water seal vs active suction throughout	>6 days	10.1% vs 7.8% (p=0.62)	NA

Table 9. Studies comparing the utility of chest tube management strategies in preventing prolonged air leak.

An alternative strategy to prolonged air leaks is the use of Heimlich valves or portable chest drainage systems to allow for early discharge of patients who are otherwise ready to be discharged from hospital apart from their prolonged air leak. Heimlich valves are one way valves originally used for the outpatient management of a pneumothorax, and two studies have shown that they can be successfully used to discharge select patients with prolonged air leak early with relatively few complications(123, 124). Portable chest tube drainage systems have an additional advantage over Heimlich valves in that they are able to handle fluid drainage in addition to air leak and can also be connected to active suction when required(125). In conclusion, outpatient chest tube management appears to be an acceptable approach that is fairly safe for managing most patients with prolonged air leak if they are reliable enough to handle their Heimlich valve or portable chest tube system on their own at home.

Author	Patient population	Type of outpatient chest tube management	Duration of outpatient chest tube management (mean)	Complications
McKenna et al.(124)	25 patients post-lung volume reduction surgery with prolonged air leak (> 5 days)	Heimlich valve	7.7 days	Nil
Ponn et al.(123)	45 patients post lobectomy, wedge resection or bullectomy with prolonged air leak (not defined)	Heimlich valve	7.5 days	1 pneumonia
Rieger et al.(125)	36 patients post-lobectomy, segmentectomy, wedge resection, pleurodesis, pericardial window, mediastinal dissection or esophagogastrectomy with prolonged air leak or excessive drainage	Portable chest tube system with suction	11.2 days	1 cellulitis, 1 localized empyema, 1 recurrence of pneumothorax

Table 10. Studies reporting the use of Heimlich valves or portable chest tube systems in the outpatient treatment of prolonged air leak.

As to which patients with prolonged air leak are suitable for discharge without suction, Cerfolio and colleagues(126) reported that they successfully discharged 199 post-pulmonary resection patients with a suctionless portable device safely without complications as long as there was no development of a new or enlarging pneumothorax or subcutaneous emphysema after converting the original chest tube suction to water seal. More importantly, most of these patients had their air leak resolve by the end of 2 weeks of outpatient chest tube therapy, and for the remaining 57 who still had air leak, the chest tube was safely removed if these patients were asymptomatic, had no increase in pneumothorax or new subcutaneous emphysema on the outpatient device. There were no complications except for the development of empyema in 3 of these 57 patients (5.7%), but these 3 patients were immunocompromised and were on chronic steroid therapy.

4.5 Re-operation

If all else fails, in cases of persistent air leak that is refractory to methods described above, re-operation can be considered to look for the source of air leak and perform therapeutic maneuvers. Often this can be accomplished with video assisted thoracoscopy, such as described by Suter and associates(127), who managed to identify the source of air leak thoracoscopically in 3 patients who had prolonged air leak after pulmonary resection. The air leaks were subsequently sealed with direct application of fibrin glue or pleurodesis with silver nitrate.

However, patients with massive, severe prolonged air leaks, particularly those with a concomitant large pleural space problem, usually require a more extensive operation such as a thoracoplasty or muscle flap transposition via an open thoracotomy. Thoracoplasty, the reduction of thoracic cavity by removal of ribs, is rarely done as it results in thoracic deformity, restriction in shoulder mobility and decreased respiratory function(7, 128). As such, muscular flap transpositions have become the preferred technique, and we have developed the combined latissimus dorsi-serratus anterior transposition flap for this purpose. We have previously described 5 patients who underwent this technique (two COPD patients with pneumothorax refractory to conservative management, one COPD patient with prolonged air leak post lung volume reduction surgery, two patients with bronchopleural fistula/empyemas), with resolution of air leak that allows the chest tubes to be removed within 5 days after surgery and no recurrence of air leak noted at 1 year follow-up(129).

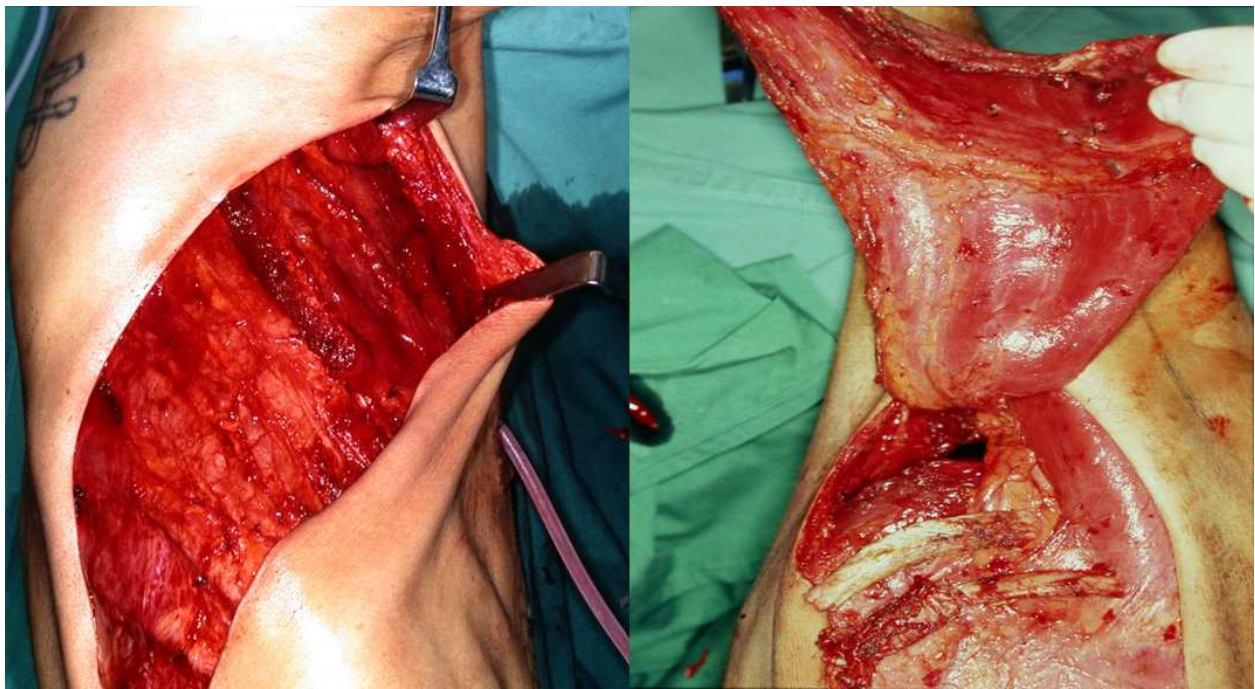


Fig. 2. (a) The latissimus dorsi and proximal slips of the serratus anterior are raised as pedicled flaps via a lazy S incision from mid-axillary line to the inferior limit of the latissimus dorsi. An axillary window is then created by resecting the 2nd and 3rd ribs superior to the serratus anterior.

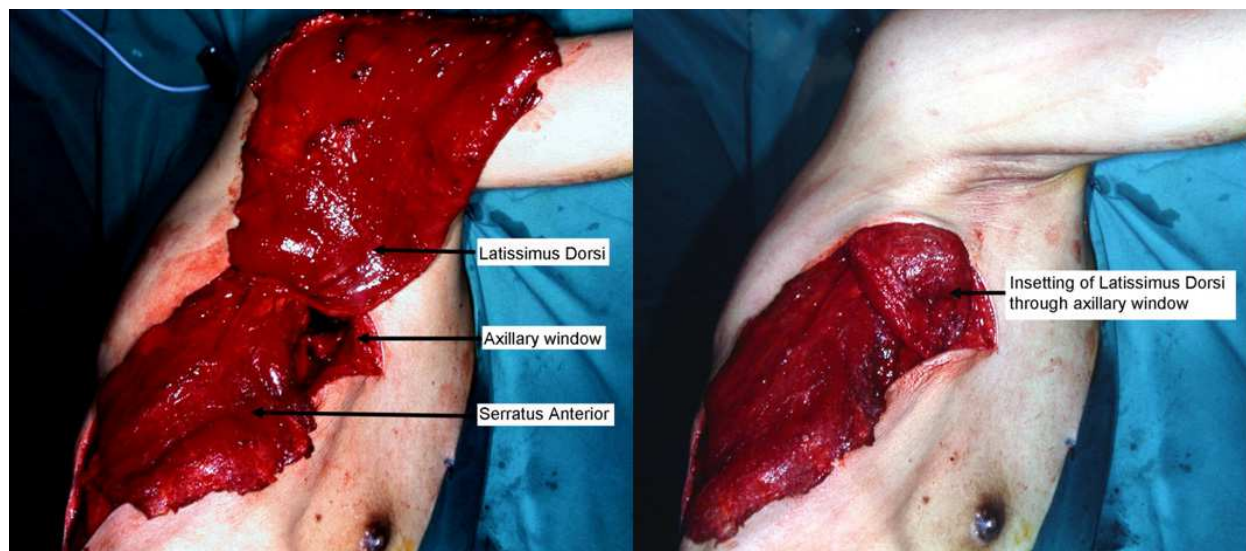

Fig. 2. (b) Latissimus dorsi and serratus anterior reflected to demonstrate the axillary window. The latissimus dorsi flap is then passed through the axillary window and laid over the lung to obliterate the pleural space and seal the air leak.

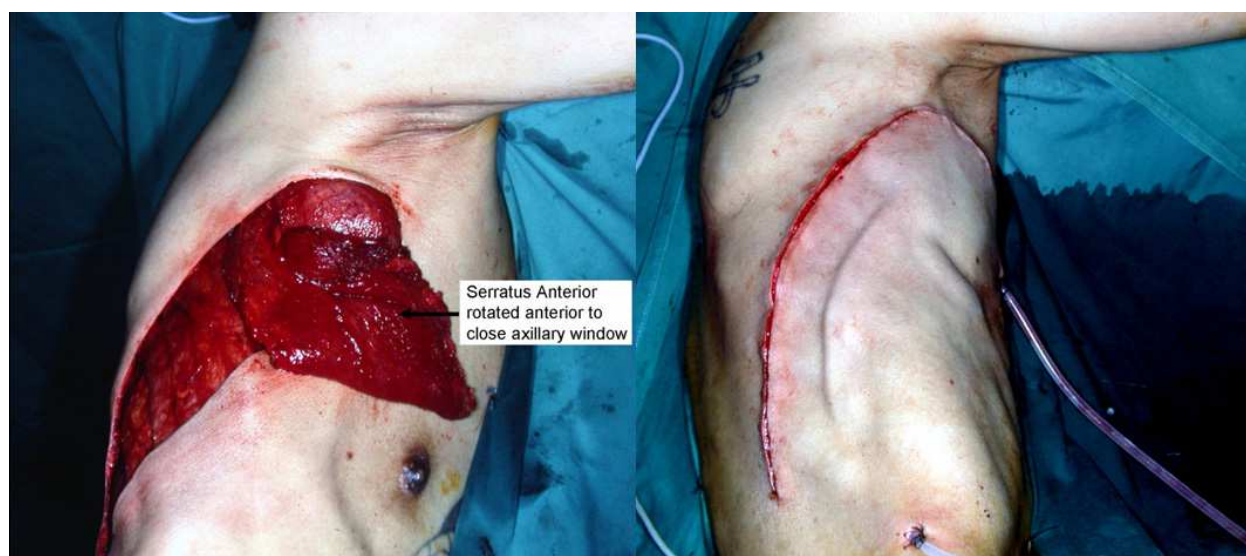

Fig. 2. (c) Serratus anterior flap is rotated anteriorly over the latissimus dorsi flap to close the axillary window. Primary closure of the incision was then performed.

At our institution, our indications for surgical air leak repair with flap reconstruction are (1) severe air leaks (high leak rate or continuous leak despite application of chest tube suction), (2) persistent air leak exceeding 4 weeks despite conservative management (or beyond 1 week for patients with underlying lung disease such as COPD), and (3) significant pleural dead space defined radiologically by absence of pleural-pleural contact despite maximal re-expansion efforts(16, 36, 130).

The operation is performed via a muscle sparing posterolateral thoracotomy with a lazy-S incision extending from the axilla to the lumbar region. Then, the latissimus dorsi and the serratus anterior muscle flaps are raised, with care taken to ensure that the serratus anterior

flap is sufficient to cover the intended axillary window (usually by raising muscle slips from the 2nd to 4th ribs) but sparing the lower slips of muscle that insert into the scapula to avoid scapular winging. Creation of the axillary window involves resection of the second to fourth ribs centered over the mid-axillary line which allows good exposure of the underlying lung for surgical treatment (eg suture repair of parenchymal tears, decortication) and allows the latissimus dorsi to be passed through without compressing its vascular pedicle. The latissimus dorsi is loosely anchored over the lung and a chest tube is inserted after a final check for air leak. The axillary window is then closed with the serratus anterior muscle flap and the skin incision is closed over a subcutaneous drain.

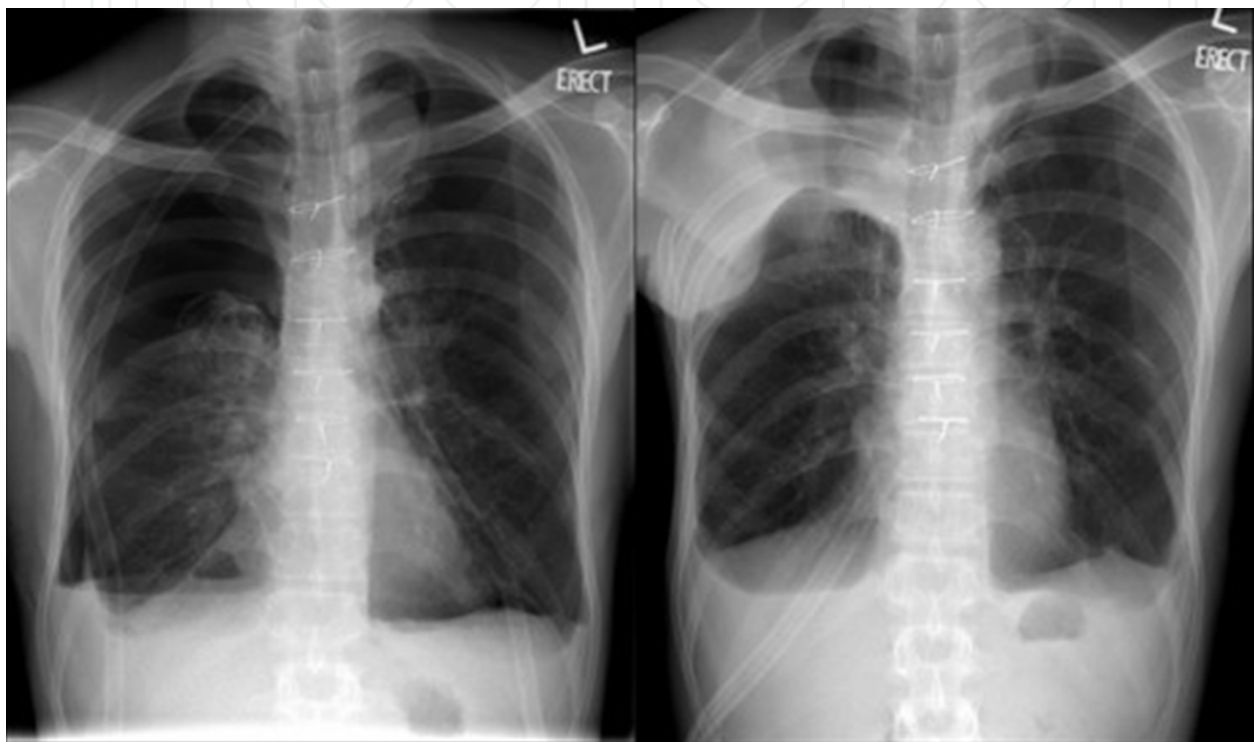


Fig. 3. Pre-operative chest x-ray (left) showing a large potential pleural space with resulting persistent air leak in this patient who had undergone bilateral lung volume reduction surgery, and post-operative chest x-ray (right) showing effective re-expansion of the right lung after the placement of the latissimus dorsi flap.

We believe our technique has several distinct advantages, as firstly it offers direct visualization for repair of diseased lung parenchyma via an open thoracotomy. Secondly, the latissimus dorsi flap provides a large, well vascularised surface for the lung to adhere to for healing. Moreover, the large mass of the muscle eliminates any pleural dead space and facilitates subsequent controlled re-expansion of the lung with time. Finally, the serratus anterior flap compartmentalizes the pleural cavity from the large subcutaneous space created by the latissimus dorsi harvest to prevent seroma formation or spread of infection between compartments. Minimal functional disability occurs after these muscle harvests, and scapular winging is prevented by sparing the lower slips of the serratus anterior muscle and the long thoracic nerve. This is in contrast to other methods for reducing pleural dead space which may only be sufficient to deal with a small volume of space (pleural tenting,

pneumoperitoneum), or reduces the patient's functional lung reserve (phrenic nerve paralysis, thoracoplasty).

Other muscular flaps that have been described in contemporary literature to eliminate potential pleural spaces (though these have been traditionally ascribed for managing empyema spaces rather than persistent air leaks) include isolated pectoralis major (14, 131), latissimus dorsi (131, 132), serratus anterior (131), rectus abdominis (131, 133) and the trapezius flaps (131, 134). However, we have found in our own experience that these flaps either lack the reach or necessary bulk in order to properly treat the large pleural space problems that we have encountered. Thus, we feel that this combination muscle flap technique is an important and useful tool in the thoracic surgeon's armamentarium in dealing with recalcitrant post-operative air leaks in a variety of situations, particularly in patients with a background of impaired respiratory function such as severe emphysema.

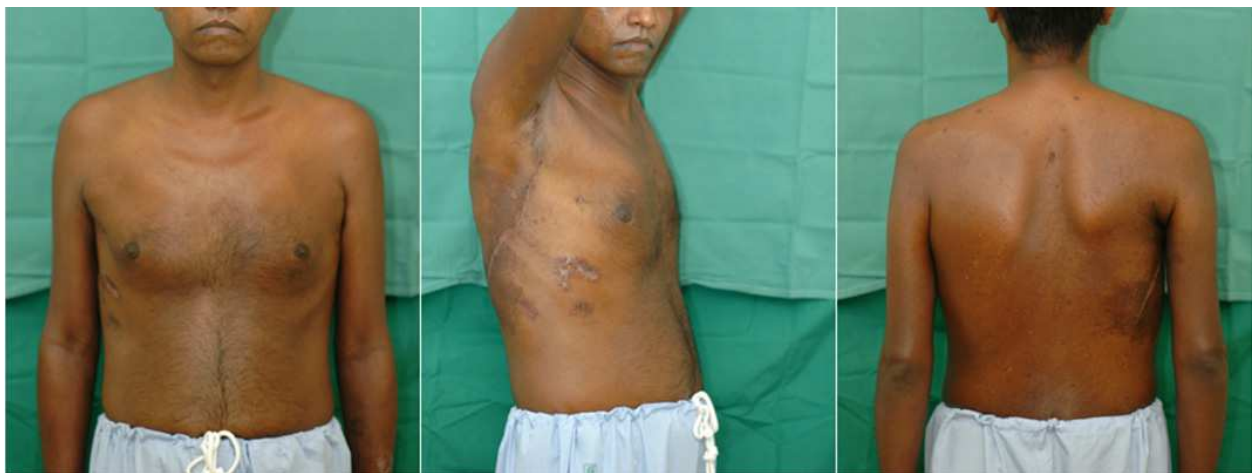

Fig. 4. Two months after the initial operation, this patient has good recovery of shoulder function.

5. Summary

In summary, prolonged air leak is a common problem for patients with emphysema undergoing thoracic surgery that is associated with significant morbidity. Clinicians involved in the surgical care of this group of patients should be aware of the various factors which can further increase the risk of this complication occurring and need to know the various measures that should be employed to prevent this problem, as well as the treatment options available should prolonged air leak occur even if preventive measures are taken. Based on the review of best available evidence as discussed previously, we propose a suggested algorithm for the management of prolonged air leaks in patients with emphysema with gradual progression of therapy similar to what has been proposed by others (2-4) but that also takes into account criteria for surgical intervention as we have mentioned earlier.

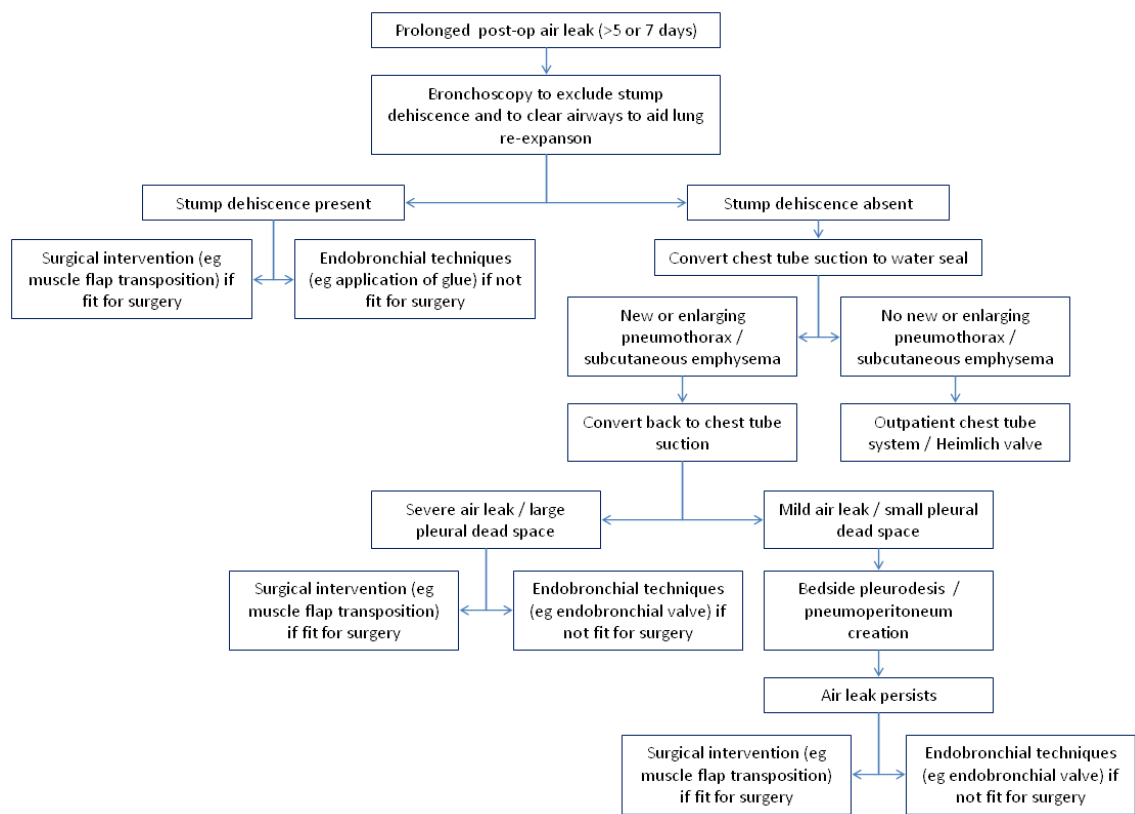


Fig. 5. Proposed algorithm for the management of prolonged air leaks in patients with emphysema.

6. References

[1] Haithcock BE, Feins RH. Complications of pulmonary resection. In: Shields TW, LoCicero J, Reed CE, Feins RH, editors. General Thoracic Surgery. 7th ed. Philadelphia: Lippincott Williams & Wilkins; 2009. p. 552-9.

[2] Shrager JB, DeCamp MM, Murthy SC. Intraoperative and postoperative management of air leaks in patients with emphysema. Thorac Surg Clin. 2009 May;19(2):223-31, ix.

[3] Singhal S, Ferraris VA, Bridges CR, Clough ER, Mitchell JD, Fernando HC, et al. Management of alveolar air leaks after pulmonary resection. Ann Thorac Surg. 2010 Apr;89(4):1327-35.

[4] Merritt RE, Singhal S, Shrager JB. Evidence-based suggestions for management of air leaks. Thorac Surg Clin. 2010 Aug;20(3):435-48.

[5] Burke SJ, Faber LP. Complications of pulmonary resection. In: Little AG, editor. Complications in Cardiothoracic Surgery: Avoidance and Treatment. 1st ed. New York: Futura; 2004. p. 67-91.

[6] Dexter EU, Kohman LJ. Perioperative care of patients undergoing thoracic surgery. In: Sellke FW, del Nido PJ, Swanson SJ, editors. Sabiston & Spencer Surgery of the Chest. 7th ed. Philadelphia: Saunders; 2004. p. 43-57.

[7] Deslauriers J, Mehran R. Handbook of Perioperative Care in General Thoracic Surgery. Philadelphia: Mosby; 2005.

[8] Okereke I, Murthy SC, Alster JM, Blackstone EH, Rice TW. Characterization and importance of air leak after lobectomy. Ann Thorac Surg. 2005 Apr;79(4):1167-73.

- [9] Brunelli A, Xiume F, Al Refai M, Salati M, Marasco R, Sabbatini A. Air leaks after lobectomy increase the risk of empyema but not of cardiopulmonary complications: a case-matched analysis. *Chest*. 2006 Oct;130(4):1150-6.
- [10] Varela G, Jimenez MF, Novoa N, Aranda JL. Estimating hospital costs attributable to prolonged air leak in pulmonary lobectomy. *Eur J Cardiothorac Surg*. 2005 Feb;27(2):329-33.
- [11] Abolhoda A, Liu D, Brooks A, Burt M. Prolonged air leak following radical upper lobectomy: an analysis of incidence and possible risk factors. *Chest*. 1998 Jun;113(6):1507-10.
- [12] DeCamp MM, Blackstone EH, Naunheim KS, Krasna MJ, Wood DE, Meli YM, et al. Patient and surgical factors influencing air leak after lung volume reduction surgery: lessons learned from the National Emphysema Treatment Trial. *Ann Thorac Surg*. 2006 Jul;82(1):197-206; discussion -7.
- [13] Stolz AJ, Schutzner J, Lischke R, Simonek J, Pafko P. Predictors of prolonged air leak following pulmonary lobectomy. *Eur J Cardiothorac Surg*. 2005 Feb;27(2):334-6.
- [14] Liberman M, Muzikansky A, Wright CD, Wain JC, Donahue DM, Allan JS, et al. Incidence and risk factors of persistent air leak after major pulmonary resection and use of chemical pleurodesis. *Ann Thorac Surg*. 2010 Mar;89(3):891-7; discussion 7-8.
- [15] Irshad K, Feldman LS, Chu VF, Dorval JF, Baslaim G, Morin JE. Causes of increased length of hospitalization on a general thoracic surgery service: a prospective observational study. *Can J Surg*. 2002 Aug;45(4):264-8.
- [16] Brunelli A, Monteverde M, Borri A, Salati M, Marasco RD, Fianchini A. Predictors of prolonged air leak after pulmonary lobectomy. *Ann Thorac Surg*. 2004 Apr;77(4):1205-10; discussion 10.
- [17] Noppen M, De Keukeleire T. Pneumothorax. *Respiration*. 2008;76(2):121-7.
- [18] Sahn SA, Heffner JE. Spontaneous pneumothorax. *N Engl J Med*. 2000 Mar 23;342(12):868-74.
- [19] Rooney C, Sethi T. The epithelial cell and lung cancer: the link between chronic obstructive pulmonary disease and lung cancer. *Respiration*. 2011;81(2):89-104.
- [20] Molina JR, Yang P, Cassivi SD, Schild SE, Adjei AA. Non-small cell lung cancer: epidemiology, risk factors, treatment, and survivorship. *Mayo Clin Proc*. 2008 May;83(5):584-94.
- [21] Criner GJ, Cordova F, Sternberg AL, Martinez FJ. The NETT: Part II- Lessons Learned about Lung Volume Reduction Surgery. *Am J Respir Crit Care Med*. 2011 Jun 30.
- [22] Hatz RA, Kaps MF, Meimarakis G, Loehe F, Muller C, Furst H. Long-term results after video-assisted thoracoscopic surgery for first-time and recurrent spontaneous pneumothorax. *Ann Thorac Surg*. 2000 Jul;70(1):253-7.
- [23] Mouroux J, Elkaim D, Padovani B, Myx A, Perrin C, Rotomondo C, et al. Video-assisted thoracoscopic treatment of spontaneous pneumothorax: technique and results of one hundred cases. *J Thorac Cardiovasc Surg*. 1996 Aug;112(2):385-91.
- [24] Noppen M, Meysman M, d'Haese J, Monsieur I, Verhaeghe W, Schlessen M, et al. Comparison of video-assisted thoracoscopic talcage for recurrent primary versus persistent secondary spontaneous pneumothorax. *Eur Respir J*. 1997 Feb;10(2):412-6.
- [25] Passlick B, Born C, Haussinger K, Thetter O. Efficiency of video-assisted thoracic surgery for primary and secondary spontaneous pneumothorax. *Ann Thorac Surg*. 1998 Feb;65(2):324-7.

- [26] Shaikhrezai K, Thompson AI, Parkin C, Stamenkovic S, Walker WS. Video-assisted thoracoscopic surgery management of spontaneous pneumothorax--long-term results. *Eur J Cardiothorac Surg*. 2011 Jul;40(1):120-3.
- [27] Tanaka F, Itoh M, Esaki H, Isobe J, Ueno Y, Inoue R. Secondary spontaneous pneumothorax. *Ann Thorac Surg*. 1993 Feb;55(2):372-6.
- [28] Lee SA, Sun JS, Park JH, Park KJ, Lee SS, Choi H, et al. Emphysema as a risk factor for the outcome of surgical resection of lung cancer. *J Korean Med Sci*. 2010 Aug;25(8):1146-51.
- [29] Santambrogio L, Nosotti M, Baisi A, Ronzoni G, Bellaviti N, Rosso L. Pulmonary lobectomy for lung cancer: a prospective study to compare patients with forced expiratory volume in 1 s more or less than 80% of predicted. *Eur J Cardiothorac Surg*. 2001 Oct;20(4):684-7.
- [30] Sekine Y, Behnia M, Fujisawa T. Impact of COPD on pulmonary complications and on long-term survival of patients undergoing surgery for NSCLC. *Lung Cancer*. 2002 Jul;37(1):95-101.
- [31] Subotic DR, Mandaric DV, Eminovic TM, Gajic MM, Mujovic NM, Atanasijadis ND, et al. Influence of chronic obstructive pulmonary disease on postoperative lung function and complications in patients undergoing operations for primary non-small cell lung cancer. *J Thorac Cardiovasc Surg*. 2007 Nov;134(5):1292-9.
- [32] Ciccone AM, Meyers BF, Guthrie TJ, Davis GE, Yusem RD, Lefrak SS, et al. Long-term outcome of bilateral lung volume reduction in 250 consecutive patients with emphysema. *J Thorac Cardiovasc Surg*. 2003 Mar;125(3):513-25.
- [33] Lederer DJ, Thomashow BM, Ginsburg ME, Austin JH, Bartels MN, Yip CK, et al. Lung-volume reduction surgery for pulmonary emphysema: Improvement in body mass index, airflow obstruction, dyspnea, and exercise capacity index after 1 year. *J Thorac Cardiovasc Surg*. 2007 Jun;133(6):1434-8.
- [34] Nicotera SP, Decamp MM. Special situations: air leak after lung volume reduction surgery and in ventilated patients. *Thorac Surg Clin*. 2010 Aug;20(3):427-34.
- [35] Brunelli A, Varela G, Refai M, Jimenez MF, Pompili C, Sabbatini A, et al. A scoring system to predict the risk of prolonged air leak after lobectomy. *Ann Thorac Surg*. 2010 Jul;90(1):204-9.
- [36] Cerfolio RJ, Bass CS, Pask AH, Katholi CR. Predictors and treatment of persistent air leaks. *Ann Thorac Surg*. 2002 Jun;73(6):1727-30; discussion 30-1.
- [37] Isowa N, Hasegawa S, Bando T, Wada H. Preoperative risk factors for prolonged air leak following lobectomy or segmentectomy for primary lung cancer. *Eur J Cardiothorac Surg*. 2002 May;21(5):951.
- [38] Lee L, Hanley SC, Robineau C, Sirois C, Mulder DS, Ferri LE. Estimating the risk of prolonged air leak after pulmonary resection using a simple scoring system. *J Am Coll Surg*. 2011 Jun;212(6):1027-32.
- [39] Rivera C, Bernard A, Falcoz PE, Thomas P, Schmidt A, Benard S, et al. Characterization and prediction of prolonged air leak after pulmonary resection: a nationwide study setting up the index of prolonged air leak. *Ann Thorac Surg*. 2011 Sep;92(3):1062-8.
- [40] Temes RT, Willms CD, Endara SA, Wernly JA. Fissureless lobectomy. *Ann Thorac Surg*. 1998 Jan;65(1):282-4.
- [41] Nomori H, Ohtsuka T, Horio H, Naruke T, Suemasu K. Thoracoscopic lobectomy for lung cancer with a largely fused fissure. *Chest*. 2003 Feb;123(2):619-22.

- [42] Gomez-Caro A, Calvo MJ, Lanzas JT, Chau R, Cascales P, Parrilla P. The approach of fused fissures with fissureless technique decreases the incidence of persistent air leak after lobectomy. *Eur J Cardiothorac Surg.* 2007 Feb;31(2):203-8.
- [43] Ng T, Ryder BA, Machan JT, Cioffi WG. Decreasing the incidence of prolonged air leak after right upper lobectomy with the anterior fissureless technique. *J Thorac Cardiovasc Surg.* 2010 Apr;139(4):1007-11.
- [44] Swanson SJ, Mentzer SJ, DeCamp MM, Jr., Bueno R, Richards WG, Ingenito EP, et al. No-cut thoracoscopic lung plication: a new technique for lung volume reduction surgery. *J Am Coll Surg.* 1997 Jul;185(1):25-32.
- [45] Iwasaki M, Nishiumi N, Kaga K, Kanazawa M, Kuwahira I, Inoue H. Application of the fold plication method for unilateral lung volume reduction in pulmonary emphysema. *Ann Thorac Surg.* 1999 Mar;67(3):815-7.
- [46] Mineo TC, Pompeo E, Mineo D, Tacconi F, Marino M, Sabato AF. Awake nonresectional lung volume reduction surgery. *Ann Surg.* 2006 Jan;243(1):131-6.
- [47] Pompeo E, Mineo TC. Two-year improvement in multidimensional body mass index, airflow obstruction, dyspnea, and exercise capacity index after nonresectional lung volume reduction surgery in awake patients. *Ann Thorac Surg.* 2007 Dec;84(6):1862-9; discussion -9.
- [48] Tacconi F, Pompeo E, Mineo TC. Duration of air leak is reduced after awake nonresectional lung volume reduction surgery. *Eur J Cardiothorac Surg.* 2009 May;35(5):822-8; discussion 8.
- [49] Pompeo E, Rogliani P, Tacconi F, Dauri M, Saltini C, Novelli G, et al. Randomized comparison of awake nonresectional versus nonawake resectional lung volume reduction surgery. *J Thorac Cardiovasc Surg.* 2011 Nov 4.
- [50] Pompeo E, Tacconi F, Mineo TC. Comparative results of non-resectional lung volume reduction performed by awake or non-awake anesthesia. *Eur J Cardiothorac Surg.* 2011 Apr;39(4):e51-8.
- [51] Roberson LD, Netherland DE, Dhillon R, Heath BJ. Air leaks after surgical stapling in lung resection: a comparison between stapling alone and stapling with staple-line reinforcement materials in a canine model. *J Thorac Cardiovasc Surg.* 1998 Aug;116(2):353-4.
- [52] Juettner FM, Kohek P, Pinter H, Klepp G, Friehs G. Reinforced staple line in severely emphysematous lungs. *J Thorac Cardiovasc Surg.* 1989 Mar;97(3):362-3.
- [53] Miller JL, Jr., Landreneau RJ, Wright CE, Santucci TS, Sammons BH. A comparative study of buttressed versus nonbuttressed staple line in pulmonary resections. *Ann Thorac Surg.* 2001 Jan;71(1):319-22; discussion 23.
- [54] Venuta F, Rendina EA, De Giacomo T, Flaishman I, Guarino E, Ciccone AM, et al. Technique to reduce air leaks after pulmonary lobectomy. *Eur J Cardiothorac Surg.* 1998 Apr;13(4):361-4.
- [55] Hazelrigg SR, Boley TM, Naunheim KS, Magee MJ, Lawyer C, Henkle JQ, et al. Effect of bovine pericardial strips on air leak after stapled pulmonary resection. *Ann Thorac Surg.* 1997 Jun;63(6):1573-5.
- [56] Stammberger U, Klepetko W, Stamatis G, Hamacher J, Schmid RA, Wisser W, et al. Buttressing the staple line in lung volume reduction surgery: a randomized three-center study. *Ann Thorac Surg.* 2000 Dec;70(6):1820-5.

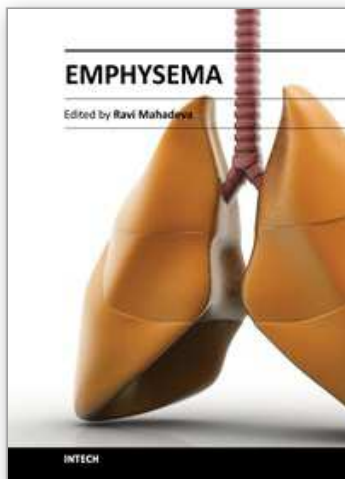
- [57] Fischel RJ, McKenna RJ, Jr. Bovine pericardium versus bovine collagen to buttress staples for lung reduction operations. *Ann Thorac Surg.* 1998 Jan;65(1):217-9.
- [58] Baysungur V, Tezel C, Ergene G, Sevilgen G, Okur E, Uskul B, et al. The autologous pleural buttressing of staple lines in surgery for bullous lung disease. *Eur J Cardiothorac Surg.* 2010 Dec;38(6):679-82.
- [59] Fleisher AG, Evans KG, Nelems B, Finley RJ. Effect of routine fibrin glue use on the duration of air leaks after lobectomy. *Ann Thorac Surg.* 1990 Jan;49(1):133-4.
- [60] Wong K, Goldstraw P. Effect of fibrin glue in the reduction of postthoracotomy alveolar air leak. *Ann Thorac Surg.* 1997 Oct;64(4):979-81.
- [61] Fabian T, Federico JA, Ponn RB. Fibrin glue in pulmonary resection: a prospective, randomized, blinded study. *Ann Thorac Surg.* 2003 May;75(5):1587-92.
- [62] Moser C, Opitz I, Zhai W, Rousson V, Russi EW, Weder W, et al. Autologous fibrin sealant reduces the incidence of prolonged air leak and duration of chest tube drainage after lung volume reduction surgery: a prospective randomized blinded study. *J Thorac Cardiovasc Surg.* 2008 Oct;136(4):843-9.
- [63] Porte HL, Jany T, Akkad R, Conti M, Gillet PA, Guidat A, et al. Randomized controlled trial of a synthetic sealant for preventing alveolar air leaks after lobectomy. *Ann Thorac Surg.* 2001 May;71(5):1618-22.
- [64] Wain JC, Kaiser LR, Johnstone DW, Yang SC, Wright CD, Friedberg JS, et al. Trial of a novel synthetic sealant in preventing air leaks after lung resection. *Ann Thorac Surg.* 2001 May;71(5):1623-8; discussion 8-9.
- [65] Allen MS, Wood DE, Hawkinson RW, Harpole DH, McKenna RJ, Walsh GL, et al. Prospective randomized study evaluating a biodegradable polymeric sealant for sealing intraoperative air leaks that occur during pulmonary resection. *Ann Thorac Surg.* 2004 May;77(5):1792-801.
- [66] De Leyn P, Muller MR, Oosterhuis JW, Schmid T, Choong CK, Weder W, et al. Prospective European multicenter randomized trial of PleuraSeal for control of air leaks after elective pulmonary resection. *J Thorac Cardiovasc Surg.* 2011 Apr;141(4):881-7.
- [67] Macchiarini P, Wain J, Almy S, Darteville P. Experimental and clinical evaluation of a new synthetic, absorbable sealant to reduce air leaks in thoracic operations. *J Thorac Cardiovasc Surg.* 1999 Apr;117(4):751-8.
- [68] Venuta F, Diso D, De Giacomo T, Anile M, Rendina EA, Coloni GF. Use of a polymeric sealant to reduce air leaks after lobectomy. *J Thorac Cardiovasc Surg.* 2006 Aug;132(2):422-3.
- [69] D'Andrilli A, Andreetti C, Ibrahim M, Ciccone AM, Venuta F, Mansmann U, et al. A prospective randomized study to assess the efficacy of a surgical sealant to treat air leaks in lung surgery. *Eur J Cardiothorac Surg.* 2009 May;35(5):817-20; discussion 20-1.
- [70] Tan C, Utley M, Paschalides C, Pilling J, Robb JD, Harrison-Phipps KM, et al. A prospective randomized controlled study to assess the effectiveness of CoSeal(R) to seal air leaks in lung surgery. *Eur J Cardiothorac Surg.* 2011 Aug;40(2):304-8.
- [71] Lang G, Csekeo A, Stamatis G, Lampl L, Hagman L, Marta GM, et al. Efficacy and safety of topical application of human fibrinogen/thrombin-coated collagen patch (TachoComb) for treatment of air leakage after standard lobectomy. *Eur J Cardiothorac Surg.* 2004 Feb;25(2):160-6.

- [72] Anegg U, Lindenmann J, Matzi V, Smolle J, Maier A, Smolle-Juttner F. Efficiency of fleece-bound sealing (TachoSil) of air leaks in lung surgery: a prospective randomised trial. *Eur J Cardiothorac Surg*. 2007 Feb;31(2):198-202.
- [73] Rena O, Papalia E, Mineo TC, Massera F, Pirondini E, Turello D, et al. Air-leak management after upper lobectomy in patients with fused fissure and chronic obstructive pulmonary disease: a pilot trial comparing sealant and standard treatment. *Interact Cardiovasc Thorac Surg*. 2009 Dec;9(6):973-7.
- [74] Belda-Sanchis J, Serra-Mitjans M, Iglesias Sentis M, Rami R. Surgical sealant for preventing air leaks after pulmonary resections in patients with lung cancer. *Cochrane Database Syst Rev*. 2010(1):CD003051.
- [75] Belcher E, Dusmet M, Jordan S, Ladas G, Lim E, Goldstraw P. A prospective, randomized trial comparing BioGlue and Vivostat for the control of alveolar air leak. *J Thorac Cardiovasc Surg*. 2010 Jul;140(1):32-8.
- [76] Tansley P, Al-Mulhim F, Lim E, Ladas G, Goldstraw P. A prospective, randomized, controlled trial of the effectiveness of BioGlue in treating alveolar air leaks. *J Thorac Cardiovasc Surg*. 2006 Jul;132(1):105-12.
- [77] Brunelli A, Al Refai M, Monteverde M, Borri A, Salati M, Sabbatini A, et al. Pleural tent after upper lobectomy: a randomized study of efficacy and duration of effect. *Ann Thorac Surg*. 2002 Dec;74(6):1958-62.
- [78] Allama AM. Pleural tent for decreasing air leak following upper lobectomy: a prospective randomised trial. *Eur J Cardiothorac Surg*. 2010 Dec;38(6):674-8.
- [79] Okur E, Kir A, Halezeroglu S, Alpay AL, Atasalihi A. Pleural tenting following upper lobectomies or bilobectomies of the lung to prevent residual air space and prolonged air leak. *Eur J Cardiothorac Surg*. 2001 Nov;20(5):1012-5.
- [80] Cerfolio RJ, Holman WL, Katholi CR. Pneumoperitoneum after concomitant resection of the right middle and lower lobes (bilobectomy). *Ann Thorac Surg*. 2000 Sep;70(3):942-6; discussion 6-7.
- [81] Handy JR, Jr., Judson MA, Zellner JL. Pneumoperitoneum to treat air leaks and spaces after a lung volume reduction operation. *Ann Thorac Surg*. 1997 Dec;64(6):1803-5.
- [82] De Giacomo T, Rendina EA, Venuta F, Francioni F, Moretti M, Pugliese F, et al. Pneumoperitoneum for the management of pleural air space problems associated with major pulmonary resections. *Ann Thorac Surg*. 2001 Nov;72(5):1716-9.
- [83] Korasidis S, Andreotti C, D'Andrilli A, Ibrahim M, Ciccone A, Poggi C, et al. Management of residual pleural space and air leaks after major pulmonary resection. *Interact Cardiovasc Thorac Surg*. 2010 Jun;10(6):923-5.
- [84] Clavero JM, Cheyre JE, Solovera ME, Aparicio RP. Transient diaphragmatic paralysis by continuous para-phrenic infusion of bupivacaine: a novel technique for the management of residual spaces. *Ann Thorac Surg*. 2007 Mar;83(3):1216-8.
- [85] Hollaus PH, Lax F, Janakiev D, Lucciarini P, Katz E, Kreuzer A, et al. Endoscopic treatment of postoperative bronchopleural fistula: experience with 45 cases. *Ann Thorac Surg*. 1998 Sep;66(3):923-7.
- [86] Scappaticci E, Ardisson F, Ruffini E, Baldi S, Revello F, Coni F. As originally published in 1994: Postoperative bronchopleural fistula: endoscopic closure in 12 patients. Updated in 2000. *Ann Thorac Surg*. 2000 May;69(5):1629-30.
- [87] Varoli F, Roviario G, Grignani F, Vergani C, Maciocco M, Rebuffat C. Endoscopic treatment of bronchopleural fistulas. *Ann Thorac Surg*. 1998 Mar;65(3):807-9.

- [88] Martin WR, Siefkin AD, Allen R. Closure of a bronchopleural fistula with bronchoscopic instillation of tetracycline. *Chest*. 1991 Apr;99(4):1040-2.
- [89] Ponn RB, D'Agostino RS, Stern H, Westcott JL. Treatment of peripheral bronchopleural fistulas with endobronchial occlusion coils. *Ann Thorac Surg*. 1993 Dec;56(6):1343-7.
- [90] Sprung J, Krasna MJ, Yun A, Thomas P, Bourke DL. Treatment of a bronchopleural fistula with a Fogarty catheter and oxidized regenerated cellulose (surgicel). *Chest*. 1994 Jun;105(6):1879-81.
- [91] Jones DP, David I. Gelfoam occlusion of peripheral bronchopleural fistulas. *Ann Thorac Surg*. 1986 Sep;42(3):334-5.
- [92] Watanabe S, Shimokawa S, Yotsumoto G, Sakasegawa K. The use of a Dumon stent for the treatment of a bronchopleural fistula. *Ann Thorac Surg*. 2001 Jul;72(1):276-8.
- [93] Kramer MR, Peled N, Shitrit D, Atar E, Saute M, Shlomi D, et al. Use of Amplatzer device for endobronchial closure of bronchopleural fistulas. *Chest*. 2008 Jun;133(6):1481-4.
- [94] Kiriyaama M, Fujii Y, Yamakawa Y, Fukai I, Yano M, Kaji M, et al. Endobronchial neodymium:yttrium-aluminum garnet laser for noninvasive closure of small proximal bronchopleural fistula after lung resection. *Ann Thorac Surg*. 2002 Mar;73(3):945-8; discussion 8-9.
- [95] West D, Togo A, Kirk AJ. Are bronchoscopic approaches to post-pneumonectomy bronchopleural fistula an effective alternative to repeat thoracotomy? *Interact Cardiovasc Thorac Surg*. 2007 Aug;6(4):547-50.
- [96] Mitchell KM, Boley TM, Hazelrigg SR. Endobronchial valves for treatment of bronchopleural fistula. *Ann Thorac Surg*. 2006 Mar;81(3):1129-31.
- [97] Feller-Kopman D, Bechara R, Garland R, Ernst A, Ashiku S. Use of a removable endobronchial valve for the treatment of bronchopleural fistula. *Chest*. 2006 Jul;130(1):273-5.
- [98] Travaline JM, McKenna RJ, Jr., De Giacomo T, Venuta F, Hazelrigg SR, Boomer M, et al. Treatment of persistent pulmonary air leaks using endobronchial valves. *Chest*. 2009 Aug;136(2):355-60.
- [99] Gillespie CT, Sterman DH, Cerfolio RJ, Nader D, Mulligan MS, Mularski RA, et al. Endobronchial valve treatment for prolonged air leaks of the lung: a case series. *Ann Thorac Surg*. 2011 Jan;91(1):270-3.
- [100] Andersen I, Nissen H. Results of silver nitrate pleurodesis in spontaneous pneumothorax. *Dis Chest*. 1968 Sep;54(3):230-3.
- [101] Janzing HM, Derom A, Derom E, Eeckhout C, Derom F, Rosseel MT. Intrapleural quinacrine instillation for recurrent pneumothorax or persistent air leak. *Ann Thorac Surg*. 1993 Feb;55(2):368-71.
- [102] Chen JS, Hsu HH, Chen RJ, Kuo SW, Huang PM, Tsai PR, et al. Additional minocycline pleurodesis after thoracoscopic surgery for primary spontaneous pneumothorax. *Am J Respir Crit Care Med*. 2006 Mar 1;173(5):548-54.
- [103] Almassi GH, Haasler GB. Chemical pleurodesis in the presence of persistent air leak. *Ann Thorac Surg*. 1989 May;47(5):786-7.
- [104] Read CA, Reddy VD, O'Mara TE, Richardson MS. Doxycycline pleurodesis for pneumothorax in patients with AIDS. *Chest*. 1994 Mar;105(3):823-5.

- [105] Balassoulis G, Sichletidis L, Spyrtos D, Chloros D, Zarogoulidis K, Kontakiotis T, et al. Efficacy and safety of erythromycin as sclerosing agent in patients with recurrent malignant pleural effusion. *Am J Clin Oncol*. 2008 Aug;31(4):384-9.
- [106] Patz EF, Jr., McAdams HP, Erasmus JJ, Goodman PC, Culhane DK, Gilkeson RC, et al. Sclerotherapy for malignant pleural effusions: a prospective randomized trial of bleomycin vs doxycycline with small-bore catheter drainage. *Chest*. 1998 May;113(5):1305-11.
- [107] Olivares-Torres CA, Laniado-Laborin R, Chavez-Garcia C, Leon-Gastelum C, Reyes-Escamilla A, Light RW. Iodopovidone pleurodesis for recurrent pleural effusions. *Chest*. 2002 Aug;122(2):581-3.
- [108] Rivas de Andres JJ, Blanco S, de la Torre M. Postsurgical pleurodesis with autologous blood in patients with persistent air leak. *Ann Thorac Surg*. 2000 Jul;70(1):270-2.
- [109] Lang-Lazdunski L, Coonar AS. A prospective study of autologous 'blood patch' pleurodesis for persistent air leak after pulmonary resection. *Eur J Cardiothorac Surg*. 2004 Nov;26(5):897-900.
- [110] Droghetti A, Schiavini A, Muriana P, Comel A, De Donno G, Beccaria M, et al. Autologous blood patch in persistent air leaks after pulmonary resection. *J Thorac Cardiovasc Surg*. 2006 Sep;132(3):556-9.
- [111] Shackcloth M, Poullis M, Page R. Autologous blood pleurodesis for treating persistent air leak after lung resection. *Ann Thorac Surg*. 2001 Apr;71(4):1402-3.
- [112] Brant A, Eaton T. Serious complications with talc slurry pleurodesis. *Respirology*. 2001 Sep;6(3):181-5.
- [113] Kuzniar TJ, Blum MG, Kasibowska-Kuzniar K, Mutlu GM. Predictors of acute lung injury and severe hypoxemia in patients undergoing operative talc pleurodesis. *Ann Thorac Surg*. 2006 Dec;82(6):1976-81.
- [114] Baron RD, Milton R, Thorpe JA. Pleurodesis using small talc particles results in an unacceptably high rate of acute lung injury and hypoxia. *Ann Thorac Surg*. 2007 Dec;84(6):2136.
- [115] Shaw P, Agarwal R. Pleurodesis for malignant pleural effusions. *Cochrane Database Syst Rev*. 2004(1):CD002916.
- [116] Cooper JD, Patterson GA, Sundaresan RS, Trulock EP, Yusem RD, Pohl MS, et al. Results of 150 consecutive bilateral lung volume reduction procedures in patients with severe emphysema. *J Thorac Cardiovasc Surg*. 1996 Nov;112(5):1319-29; discussion 29-30.
- [117] Ayed AK. Suction versus water seal after thoracoscopy for primary spontaneous pneumothorax: prospective randomized study. *Ann Thorac Surg*. 2003 May;75(5):1593-6.
- [118] Cerfolio RJ, Bass C, Katholi CR. Prospective randomized trial compares suction versus water seal for air leaks. *Ann Thorac Surg*. 2001 May;71(5):1613-7.
- [119] Marshall MB, Deeb ME, Bleier JL, Kucharczuk JC, Friedberg JS, Kaiser LR, et al. Suction vs water seal after pulmonary resection: a randomized prospective study. *Chest*. 2002 Mar;121(3):831-5.
- [120] Brunelli A, Monteverde M, Borri A, Salati M, Marasco RD, Al Refai M, et al. Comparison of water seal and suction after pulmonary lobectomy: a prospective, randomized trial. *Ann Thorac Surg*. 2004 Jun;77(6):1932-7; discussion 7.

- [121] Brunelli A, Sabbatini A, Xiume F, Refai MA, Salati M, Marasco R. Alternate suction reduces prolonged air leak after pulmonary lobectomy: a randomized comparison versus water seal. *Ann Thorac Surg.* 2005 Sep;80(3):1052-5.
- [122] Alphonso N, Tan C, Utley M, Cameron R, Dussek J, Lang-Lazdunski L, et al. A prospective randomized controlled trial of suction versus non-suction to the under-water seal drains following lung resection. *Eur J Cardiothorac Surg.* 2005 Mar;27(3):391-4.
- [123] Ponn RB, Silverman HJ, Federico JA. Outpatient chest tube management. *Ann Thorac Surg.* 1997 Nov;64(5):1437-40.
- [124] McKenna RJ, Jr., Fischel RJ, Brenner M, Gelb AF. Use of the Heimlich valve to shorten hospital stay after lung reduction surgery for emphysema. *Ann Thorac Surg.* 1996 Apr;61(4):1115-7.
- [125] Rieger KM, Wroblewski HA, Brooks JA, Hammoud ZT, Kesler KA. Postoperative outpatient chest tube management: initial experience with a new portable system. *Ann Thorac Surg.* 2007 Aug;84(2):630-2.
- [126] Cerfolio RJ, Minnich DJ, Bryant AS. The removal of chest tubes despite an air leak or a pneumothorax. *Ann Thorac Surg.* 2009 Jun;87(6):1690-4; discussion 4-6.
- [127] Suter M, Bettschart V, Vandoni RE, Cottat JF. Thoracoscopic pleurodesis for prolonged (or intractable) air leak after lung resection. *Eur J Cardiothorac Surg.* 1997 Jul;12(1):160-1.
- [128] Stefani A, Jouni R, Alifano M, Bobbio A, Strano S, Magdeleinat P, et al. Thoracoplasty in the current practice of thoracic surgery: a single-institution 10-year experience. *Ann Thorac Surg.* 2011 Jan;91(1):263-8.
- [129] Woo E, Tan BK, Lim CH. Treatment of recalcitrant air leaks: the combined latissimus dorsi-serratus anterior flap. *Ann Plast Surg.* 2009 Aug;63(2):188-92.
- [130] Chee CB, Abisheganaden J, Yeo JK, Lee P, Huan PY, Poh SC, et al. Persistent air-leak in spontaneous pneumothorax--clinical course and outcome. *Respir Med.* 1998 May;92(5):757-61.
- [131] Michaels BM, Orgill DP, Decamp MM, Pribaz JJ, Eriksson E, Swanson S. Flap closure of postpneumonectomy empyema. *Plast Reconstr Surg.* 1997 Feb;99(2):437-42.
- [132] Abolhoda A, Bui TD, Milliken JC, Wirth GA. Pedicled latissimus dorsi muscle flap: routine use in high-risk thoracic surgery. *Tex Heart Inst J.* 2009;36(4):298-302.
- [133] Jiang L, Jiang GN, He WX, Fan J, Zhou YM, Gao W, et al. Free rectus abdominis musculocutaneous flap for chronic postoperative empyema. *Ann Thorac Surg.* 2008 Jun;85(6):2147-9.
- [134] Watanabe H, Imaizumi M, Takeuchi S, Murase M, Hasegawa T. Treatment of empyema by transposition of contralateral lower trapezius flap. *Ann Thorac Surg.* 1997 Mar;63(3):837-9.



Emphysema

Edited by Dr. Ravi Mahadeva

ISBN 978-953-51-0433-9

Hard cover, 134 pages

Publisher InTech

Published online 30, March, 2012

Published in print edition March, 2012

Chronic Obstructive pulmonary disease (COPD) is an important cause of morbidity and mortality world-wide. The most common cause is chronic cigarette smoke inhalation which results in a chronic progressive debilitating lung disease with systemic involvement. COPD poses considerable challenges to health care resources, both in the chronic phase and as a result of acute exacerbations which can often require hospital admission. At the current time it is vital that scientific resources are channeled towards understanding the pathogenesis and natural history of the disease, to direct new treatment strategies for rigorous evaluation. This book encompasses some emerging concepts and new treatment modalities which hopefully will lead to better outcomes for this devastating disease.

How to reference

In order to correctly reference this scholarly work, feel free to copy and paste the following:

Boon-Hean Ong, Bien-Keem Tan and Chong-Hee Lim (2012). Surgical Management of Prolonged Air Leak in Patients with Underlying Emphysema, Emphysema, Dr. Ravi Mahadeva (Ed.), ISBN: 978-953-51-0433-9, InTech, Available from: <http://www.intechopen.com/books/emphysema/surgical-management-of-prolonged-air-leak-in-patients-with-underlying-emphysema-and-diseased-lung->

INTECH
open science | open minds

InTech Europe

University Campus STeP Ri
Slavka Krautzeka 83/A
51000 Rijeka, Croatia
Phone: +385 (51) 770 447
Fax: +385 (51) 686 166
www.intechopen.com

InTech China

Unit 405, Office Block, Hotel Equatorial Shanghai
No.65, Yan An Road (West), Shanghai, 200040, China
中国上海市延安西路65号上海国际贵都大饭店办公楼405单元
Phone: +86-21-62489820
Fax: +86-21-62489821

© 2012 The Author(s). Licensee IntechOpen. This is an open access article distributed under the terms of the [Creative Commons Attribution 3.0 License](https://creativecommons.org/licenses/by/3.0/), which permits unrestricted use, distribution, and reproduction in any medium, provided the original work is properly cited.

IntechOpen

IntechOpen