

We are IntechOpen, the world's leading publisher of Open Access books Built by scientists, for scientists

6,900

Open access books available

186,000

International authors and editors

200M

Downloads

Our authors are among the

154

Countries delivered to

TOP 1%

most cited scientists

12.2%

Contributors from top 500 universities



WEB OF SCIENCE™

Selection of our books indexed in the Book Citation Index
in Web of Science™ Core Collection (BKCI)

Interested in publishing with us?
Contact book.department@intechopen.com

Numbers displayed above are based on latest data collected.
For more information visit www.intechopen.com



Unilateral Transpedicular Balloon Kyphoplasty for the Osteoporotic Vertebral Compression Fracture

Kyoung-Suok Cho and Sang-Bok Lee

*Uijongbu St. Mary's Hospital, The Catholic University School of Medicine
Korea*

1. Introduction

The National Osteoporosis Foundation has estimated that more than 100 million people worldwide are at a risk for the development of fractures secondary to osteoporosis.^{15, 16}

Osteoporotic Vertebral compression fractures (OVCFs) constitute a major health care problem in western countries, not only because of the high incidence of these lesions but also due to their direct and indirect negative consequences for patient health-related quality of life and the costs to the health care system. Compression fractures lead to a loss of height of the vertebral segment, and the resulting spinal deformity can lead to a decrease in pulmonary capacity, malnutrition, decreased mobility, and depression. Kyphosis secondary to osteoporotic vertebral compression fractures is associated with a 2 to 3 times greater incidence of death due to pulmonary causes.^{5,11,13,17}

Although usual treatment of an osteoporotic vertebral compression fracture consists of bed rest, analgesics, and bracing, some fractures go on to progressive deformity and debilitating pain.

Vertebroplasty (VP) and kyphoplasty (KP) are not only relatively simple procedures, but also less traumatic procedures for OVCF as compared to extensive stabilization surgery. Several techniques have been developed for simpler and safer procedures during the last 2 decades. Techniques of vertebral body augmentation have been developed in an effort to treat these refractory cases. The high-pressure injection of low viscosity of polymethylmethacrylate (PMMA) has potential risk for neural compromise and pulmonary embolism by uncontrolled leakage. Therefore, balloon kyphoplasty and vertebroplasty using a large cannula low-pressure injection of PMMA in a high viscosity state (so called osteoplasty) has been introduced. Percutaneous kypoplasty (PKP) is a recently developed, minimally invasive surgical treatment for OVCF. It is designed to address the fracture-related pain and the associated spinal deformity (figure 1). PKP with acrylic cement (PMMA) is a procedure aimed at preventing vertebral body collapse and pain in patients with pathologic vertebral bodies. PKP is a promising therapeutic technique for pain control in patients with bone failure. PKP for OVCFs is typically performed by delivering double balloons via a bilateral transpedicular approach, and both balloons are inflated simultaneously for elevating the end plate for accompanying vertebral body height balanced

restoration. The deformity is purportedly corrected by the insertion and expansion of a balloon in a fractured vertebral body. After reduction of the fracture bone, cement is then deposited into the cavity created by the balloon to repair the fracture. Good clinical outcomes as well as restoration of vertebral body height have been reported with kyphoplasty.^{3,9,12}

The unilateral single balloon technique (via the unipedicular or extrapedicular route) has been developed (Fig. 1A, B). This technique reduces trauma to the patient, procedure time, costs and radiation exposure of a patient and an operator. In particular, the needle traverses a short distance of the bony structure in the extrapedicular approach, therefore, this approach causes less pain as compared to transpedicular approach and can avoid the sclerotic area of the vertebra. In the literature, there exists a detailed anatomical understanding at the thoracic level, but not the lumbar level. Theoretically, an alternative unipedicular approach would reduce by 50% the risk associated with cannulation of the pedicles, while also reducing operative time, radiation exposure, and costs. There is some technical report about the unilateral transpedicular approach, but limited data about the effects of unilateral transpedicular kyphoplasty on clinical and radiological outcome in large patients group is available. The purpose of this chapter to describe the performance of a procedure known as inflatable bone tamp via a unilateral transpedicular approach and determine the efficacy of unipedicular transpedicular approach and the clinical and radiological outcomes.

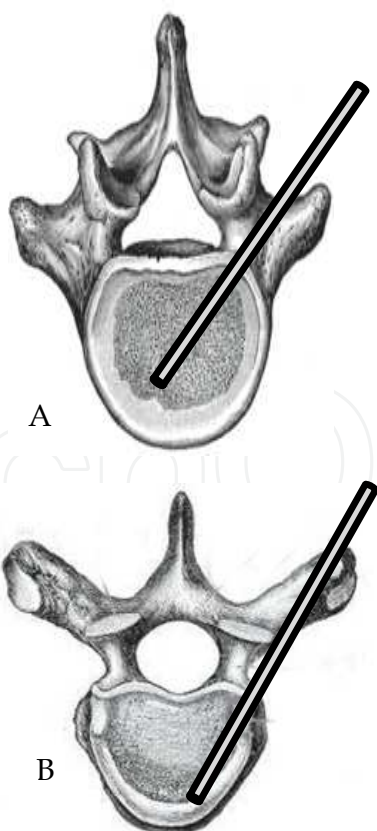


Fig. 1. Drawings views demonstrate the transpedicular approach (A) in lumbar vertebra and extrapedicular approach (B) in thoracic vertebra.

2. Principle

The analgesic effect of cement cannot be explained by the consolidation of pathologic bone alone (Fig 2). The origin of the pain in a patient with vertebral benign or malignant collapse or fracture is mostly related to the stretching of the periosteal fibers or nervous structures compression with transmission of the pain to the paravertebral nervous plexus, through the nerve ganglion and spinothalamic-parietal-cortical tract. In fact, good pain relief is obtained after injection of only 2 mL of PMMA in metastases. In these cases, the consolidation effect is minimal. The methylmethacrylate is cytotoxic because of its chemical and thermal effects during polymerization. The temperature during polymerization is high enough to produce coagulation of tumoral cells. Therefore, good pain relief can be obtained with a small volume of cement.

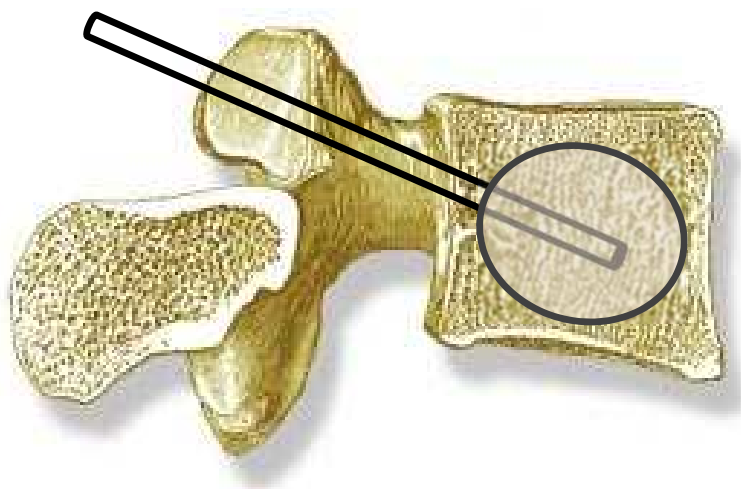


Fig. 2. Drawing demonstrates the principle of percutaneous cementoplasty at the lumbar level, showing vertebral puncture via the posterolateral route and vertebral filling.

3. Inclusion criteria

Clinical indications for kyphoplasty should be based on a detailed medical history and careful examination of the patient. Patients with acute spine thoracic or lumbar pain generally refer to a physician that, after a clinical evaluation, will suggest a medical therapy and a short-term follow-up. If the back pain does not decrease, physician should be performed radiograph examinations to find normal findings or the presence of an initial vertebral fracture. After at least 4 to 6 weeks from the beginning of clinical symptomatology, if the pain does not subside in spite of maximum medical treatment, MRI evaluation is suggested to distinguish between benign versus malignant are well known, but sometimes differential diagnosis is not simple, especially in cases of vertebral fracture related to multiple myeloma. In patients with metastatic disease, a bone scan is useful for a systemic oncological balance. However, many patients have multiple fractures and lack sufficient imaging studies to document the age of some or all of the fractures. Others have several adjacent fractures in which it is difficult to determine, by physical examination, the fracture that is symptomatic. In such instances, magnetic resonance (MR) imaging with gadollium enhancement is helpful, with edema within the marrow space of the vertebral body best visualized on sagittal T2-weighted images. Bone scans can be used to help differentiate the

symptomatic level from incidentally discovered fractures. The ideal candidate for kyphoplasty presents within 3 months of fracture and has midline, non-radiating back pain that increases with weight bearing and can be exacerbated by manual palpation of the spinous process of the involved vertebra. Selection criteria for kyphoplasty were described in Table 1.

3.1 Contraindications

- 1. Hemorrhagic diathesis.
- 2. Infection.
- 3. Lesions with epidural extension. These require careful injection to prevent epidural overflow and spinal cord compression by the cement or displaced epidural tissue.

The absolute contraindications are the presence of local or systemic infections, the presence of an epidural or foraminal extension associated with neurologic deficit and uncorrectable coagulation disorders. Vertebra plana, mixed secondary lesion, disruption, or epidural extension of the posterior vertebral wall are relative contraindications related to physician’s experience in most cases.

Indications
Vertebral fracture pain
Sufficient pain to impair activities of daily living
Failure of reasonable medical therapy and time
Comprehensive medical evaluation of osteoporotic vertebral compression fractures
Technical feasibility
Sufficient medical stability to tolerate general anesthesia
Absence of contraindication
Contraindications
Hemorrhagic diathesis
Infection
Lesions with epidural extension

Table 1. Indication for Unilateral transpedicular balloon kyphoplasty.

4. Operative technique

The operative procedure was performed under aseptic conditions in an operating room while blood pressure, heart rate, electrocardiography, and pulse oximetry parameters were continuously monitored. Before the procedures, 25 mg of Demerol was injected intravenously to control pain. Percutaneous kyphophoplasty was performed using fluoroscope via a unilateral transpedicular approach. Usually, a right-handed operator stood on the left side of a patient for a left-side approach. PKP must be performed in sterile conditions and intravenous antibiotics are generally administrated few hours before the procedure. In most cases, local anesthesia can be administered by injection (ie, 2 to 3 mL of 2% lidocaine hydrochloride) at the skin level and deeper, to include the periosteum, with a 22-gauge spinal needle. Occasionally, conscious sedation can be useful for uncooperative patients or in poor clinical conditions. After conscious sedation and the patient was carefully positioned prone on the fluoroscopy table. The authors recommended targeting the tip of a

needle in the vertebra was in the mid-line and anterior one-third of the vertebra body for vertebroplasty and in the center of the body for balloon kyphoplasty (Fig. 3).

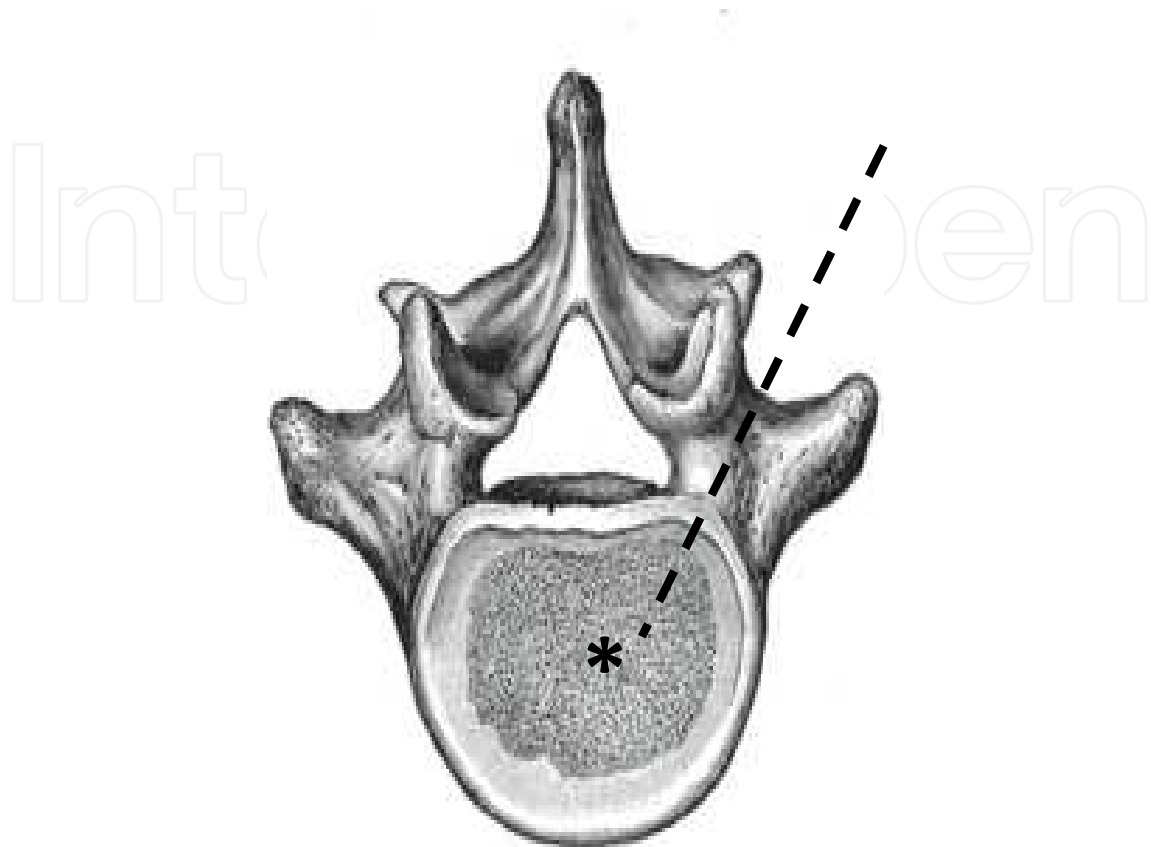


Fig. 3. In the lower lumbar area, the lateral wall of the pedicle (dotted line) can be used for an entry point due to the greater width of the lower lumbar pedicle. (* target point).

The trajectory line was made between the target point of the needle tip and the skin entry point through the transverse process (TP). Once the skin incision for the entry point was made, adjusting the direction of the needle was limited due to large lumbar dorsal muscles which were larger than thoracic muscles. After incision of the skin, an 11-gauge Jamshidi needle was placed through the left-side pedicle into the posterior vertebral body. The needle was inserted through the cortex by tapping its back end with a hammer. If the end of the needle reached the inside boundary of the ipsilateral pedicle in the AP view, the lateral view should be checked to see if the end of the needle did not compromise the spinal canal, and safely arrived inside the vertebral body. The entry point of bone was usually made at lateral or supero-lateral wall of the pedicle and there was no artery or nerve (Fig. 4A, B).

Special care was taken to achieve a medial trajectory of the needle and a final midline position of the needle tip in the vertebral body (Fig. 5A, B).

The inflatable bone tamp (IBT) was then positioned within the vertebral body and expanded using direct fluoroscopy and manometric parameters. Inflation continued until vertebral body height was restored, the inflatable bone tamp contacted a vertebral body cortical wall, the IBT reached 250 psi, or the maximal balloon volume was reached. PMMA was prepared with additional barium sulfate. When satisfactory consistency was achieved, PMMA was

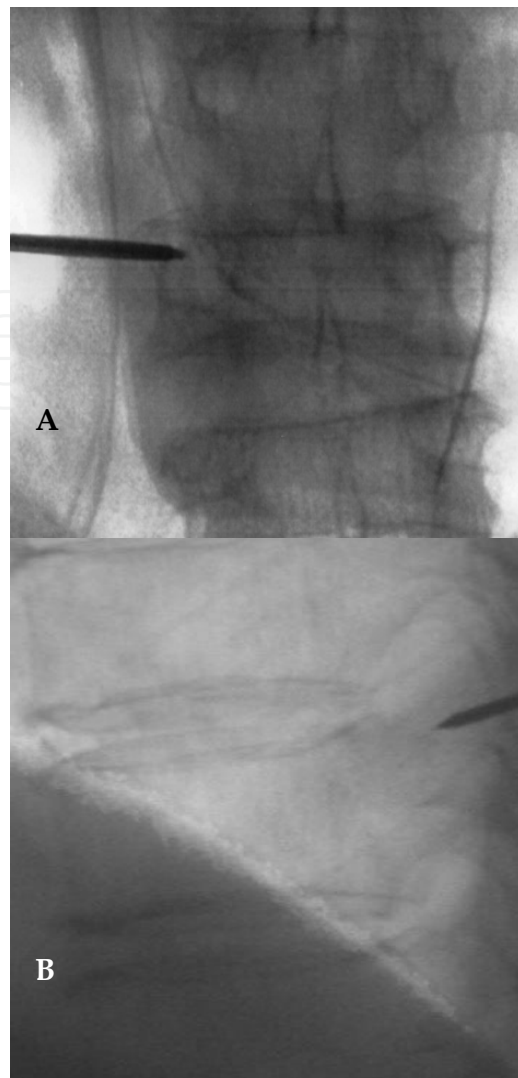


Fig. 4. A-B. Radiographs shows fluoroscopic images at the bone entry point. The needle is anchored at the superolateral area of the pedicle. An anteroposterior view (A) and a lateral view (B).

injected using a commercially available cement delivery system kit under direct fluoroscopic visualization into the cavity in the vertebral body created by an inflatable bone tamp. Cement was administered which produced an excellent filling of the vertebral body cavity (Fig. 6A, B).

The amount of cement injected in the vertebral body is extremely variable—between 3 and 6 mL depending on the metamer, to treat (thoracic or lumbar) and the degree of the collapsed vertebra.

The injection needs to be suspended or terminated if venous, disk space, or epidural extravasation is encountered. Post-procedural CT evaluation is useful to assess correct vertebral PMMA injection and to evaluate complications. All instrumentation removed at the end of the procedure. After the procedure, the patient remains in strict bed rest for 2 hours and is discharged from the hospital after regaining the ability to perambulate, normally the same procedural day.

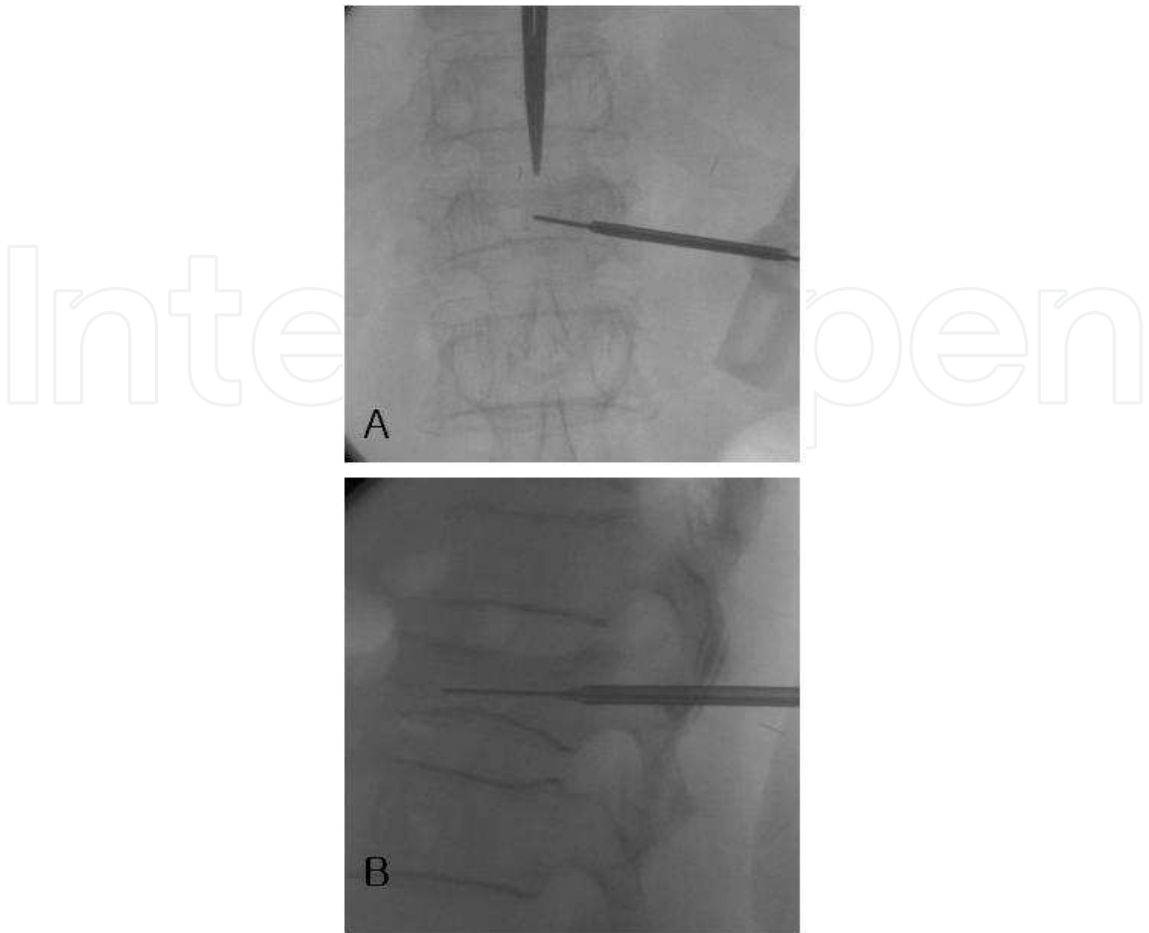


Fig. 5. A-B. Antero-posterior, image of inflatable bone tamp in the midline of the fractured vertebral body.

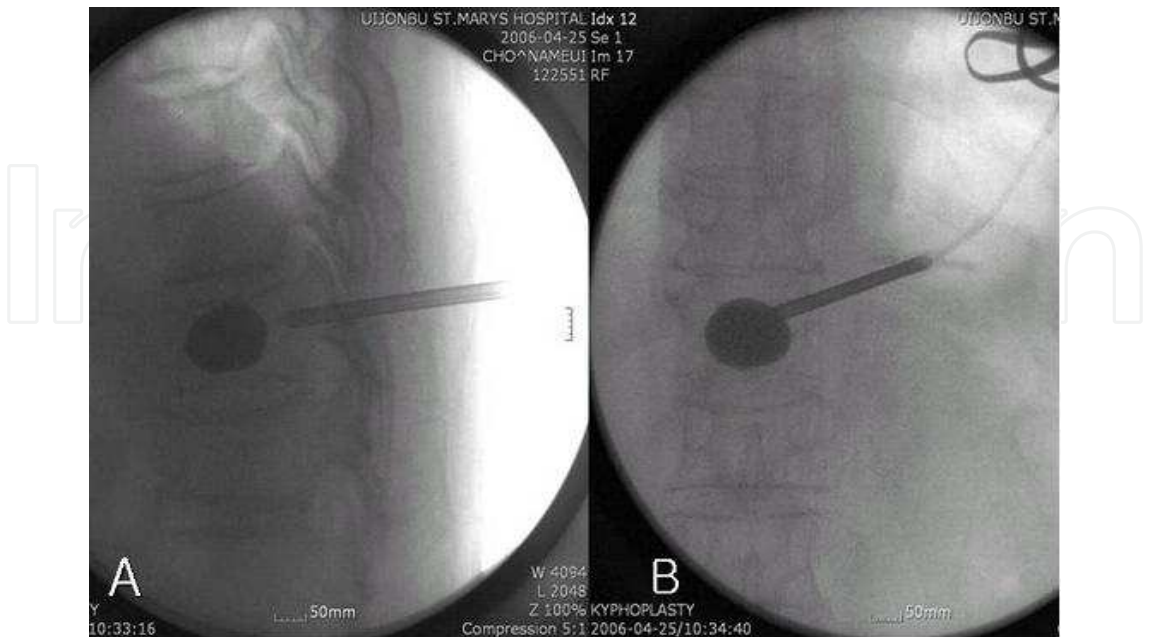


Fig. 6. A) lateral, and B) antero-posterior fluoroscopic image of polymethylmethacrylate filling the cavity within the fractured vertebral body.

5. Postoperative observation and disposal

The vital signs of patients, the cement distribution in the vertebral body and the cement leakage are monitored during the operation. Antibiotics were routinely used within 48 hours. All instrumentation removed at the end of the procedure. After the procedure, the patient remains in strict bed rest for 2 hours and the patients begin to walk on the ground after 6–12 hours. Patients are discharged from the hospital after regaining the ability to perambulate, normally the same procedural day.

6. Technical tip

The key of the single balloon cross-midline expansion with a unipedicular approach is delivering the balloon into the midline position of the vertebral body. A puncturing approach should be made through observing carefully the pedicular route and diameter on the imaging examination before operation. The C-arm was then rotated 10°–20° in an oblique angle ipsilateral with respect to the back being punctured. At this angle, the medial cortex of the pedicle could be visualized clearly. The entry of the needle into the bone should be targeted to a starting point just on the superior and lateral edge of the pedicle projection on the oblique view, so that the maximum transverse angle can be achieved in the pedicular stenotic space without penetrating the media wall of the pedicle. We think the appropriate transverse angle between the needle and the oblique angle of the C-arm was between 3°–5°. This oblique view provided an excellent view of the pedicle during the entire period of needle advancement. Ideally, the IBT should be placed inside the anterior two-thirds of the vertebral body on the lateral view while the tip of the drill overlapped the spinous process of the vertebra under the AP fluoroscopy.

7. Complications

The first step in which it is possible to observe complications is needle and working cannula positioning. The most serious complication is abnormal cement distribution with disk, epidural, or vascular leakage. However, more often leakages are completely asymptomatic. Some types of leakages (intraforaminal, radicular vein) can determine transient radicular pain or thecal sac compression, whereas vascular leakage, in most cases asymptomatic, can lead to symptomatic pulmonary emboli, cerebral infarct, or heart and vascular dissection. This risk is minimized by monitoring the bone filling with a high-quality fluoroscopic unit and by having adequate radiopacity (tantalum) in the cement. Radiculopathy is the major risk with neural foramina leaks (Fig. 7).

Spinal cord compression is an emergency, and urgent surgery is mandatory to prevent neurologic complications. The injection of acrylic cement should be performed under a high-quality fluoroscopic unit. The injection should be immediately interrupted if the cement reaches the posterior cortex of the vertebral body. Adequate radiopacity of acrylic cement (with the addition of tantalum, barium, or tungsten) is mandatory, and the cement should be injected during its pasty polymerization phase.

The filling of an epidural vein and neural foramina cause intercostal neuralgia. Radiculopathy is the major risk with neural foramina leaks. Radiculopathy is particularly difficult to treat at the cervical and lumbar levels. Epidural vein filling does not necessarily cause neuralgia. This complication can be successfully treated with a series of intercostal

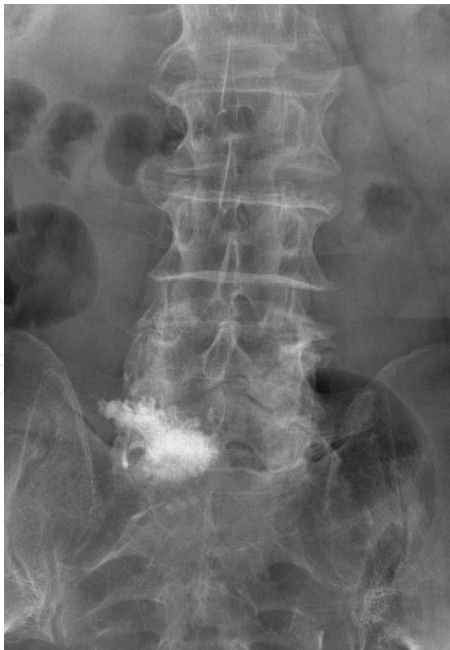

Fig. 7. Antero-posterior X-ray imaging shows leaks toward right neural foramen.

steroid infiltrations. Cement leaks toward the disk usually do not have clinical consequence; however, these leaks may increase the risk of adjacent vertebral collapse.

Leak into paravertebral veins can lead to pulmonary cement embolism (Fig. 8). To avoid major pulmonary infarction, the cement should be injected slowly under fluoroscopic control during its pasty polymerization phase, and the injection should be immediately stopped if a venous leak is observed. Cement leaks into paravertebral soft tissues have no clinical significance.

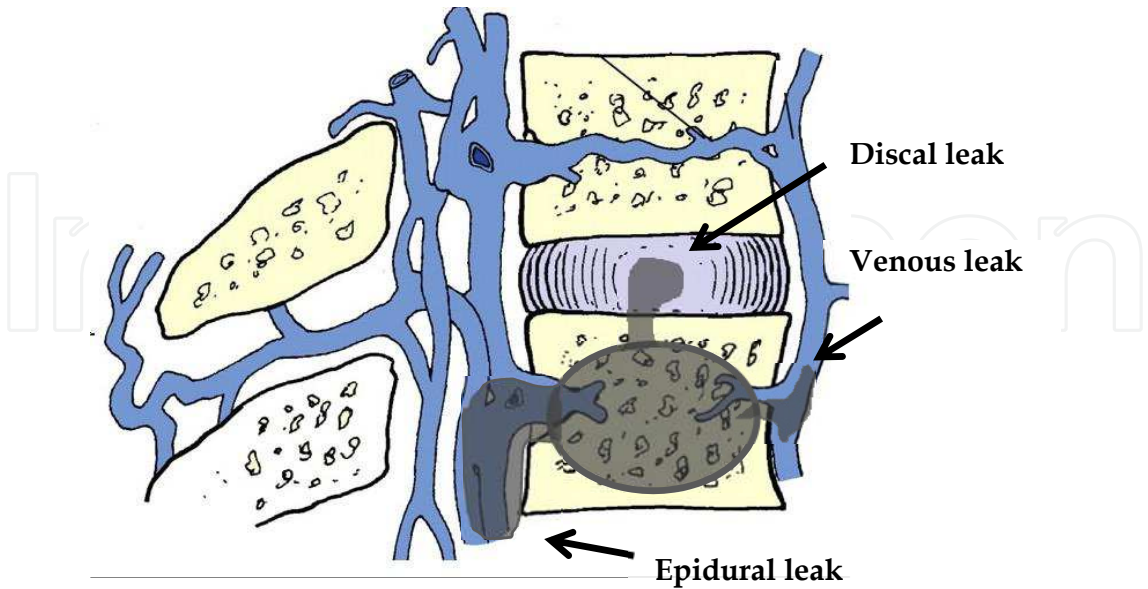


Fig. 8. Drawings show leaks in the sagittal planes.

The second most serious complication is infection. Strict sterility during the intervention is mandatory. Temporary pain can occur after the procedure. Patients are usually free of pain after 24 hours. Post-procedural pain is usually proportional to the volume of cement injected. Most of these patients have good packing of the vertebral body with more than 4 mL of cement injected.

8. Discussion

Percutaneous vertebral augmentation techniques performed with VP or PKP are safe and effective for the treatment of osteoporotic VCF, primary or secondary spine tumors, and selected traumatic fractures. In most cases, VP alone is sufficient to achieve pain relief and quality of life improvement. The advantages of PKP over VP are low-pressure cement injection, the use of high-density cement, and a lower rate of vascular and disk leakage. The disadvantages of KP compared to VP are related to its higher invasiveness, the higher cost (four times higher), the need for deep sedation and time required. The results of the present study indicate that PKP is a minimally invasive procedure aimed at restoring strength, stiffness and is effective in reduction of spinal deformity and in short-term improvement of pain in selected patients with osteoporotic vertebral compression fracture. PKP is a successful technique for pain management and consolidation of pathologic vertebral bodies. The most critical elements for successful PKP are proper patient selection, correct needle placement, good timing of cement injection, strict fluoroscopic control of injection, and operator's experience. The good pain relief obtained with this technique is not correlated with the volume of cement injected, especially in spine metastasis, where 1.5 mL of cement is usually enough to considerably reduce the patient's pain.

The rationale of bilateral transpedicular approach is to achieve adequate endplate elevation with two inflatable bone tamp and to create a large enough cavity for maximal cement filling. With conventional needle trajectories, the inflatable bone tamp remain ipsilateral, thus necessitating bilateral inflatable bone tamp to cover the expanse of the vertebral body.

Previous studies have been suggested that unipedicular kyphoplasty might lead to unilateral wedging or that it would not be as effective in restoring vertebral body height.^{1,2,10} Steinmann et al in an ex vivo biomechanical study comparing a bipedicular approach to unipedicular approach in the treatment of vertebral compression fractures, found no significant lateral wedging associated with unipedicular injections.¹⁰ The unipedicular approach is effective in restoring the vertebral height and vertebral body height was successfully restored by unipedicular kyphoplasty to 96% of fracture levels in our cases. Furthermore, kyphoplasty by unipedicular approach markedly reduced pain and spinal deformity with osteoporotic vertebral compression fracture. A midline-positioned inflatable bone tamp can be inflated to create a large enough cavity in the midline of the vertebral body. Unilateral transpedicular approach has many advantages. This procedure reduced the risk associated with large needle placement. These risks include pedicle fracture, medial transgression of the pedicle or transgression into the spinal canal, nerve injury, cement leakage along the cannula tract, and spinal epidural hematoma.

The key of the single balloon cross-midline expansion with a unipedicular approach is delivering the balloon into the midline position of the vertebral body. First, a puncturing

approach should be made through observing carefully the pedicular route and diameter on the imaging examination before operation. Secondly, it was key to try to place the uninflated balloon at the most anterior extent of the vertebral body according to the two fiducial markers denoting the proximal and distal extents of the balloon. Thirdly, those with fractures within two weeks, or back pain exacerbation within two weeks during a longer painful back history, or with a hyper-signal on T2WI in the injured vertebral body on MRI examination, or hypo-signal on both T1WI and T2WI, or with fracture lines and vacuum signs of injured vertebral body on CT scan that predicated old compression fracture and nonunion, i.e. Kümmell's disease are indicated for this technique because the aforementioned are usually signs of fresh fracture or complicated severe osteoporosis. The balloon can be expanded successfully because the resistance of the inflated balloon through liquid pressure was lower.

Even if complications of kyphoplasty are very rare, in previous studies, many authors reported such adverse complication. Coumans et al ⁷ described a large series of 188 kyphoplasty procedures. There were five cases of complication such as, cement extravasation along the canal. Garfin et al retrospectively reviewed 2194 vertebral compression fractures, finding 3 cases of instrument insertion through the medial pedicle wall, resulting in neurologic injury.⁸

Nussbaum et al ¹⁴ also reviewed complications associated with vertebroplasty and kyphoplasty as reported. Kyphoplasty may have an increased risk of pedicle fracture that can lead to spinal compression. It associated with breakage of the pedicle during insertion of the cannula. Theoretically, the incidence of such events may be reduced if unilateral rather than bilateral cannulas are placed. By cannulating only 1 pedicle, one can reasonably assume a considerable reduction in operative time, radiation exposure, and cannulation risks with the unipedicular kyphoplasty when compared to the bipedicular approach. In the procedure that we described, the time required for the procedure was less than 35 minutes and also save the cost about 30% compare to the bipedicular approach.

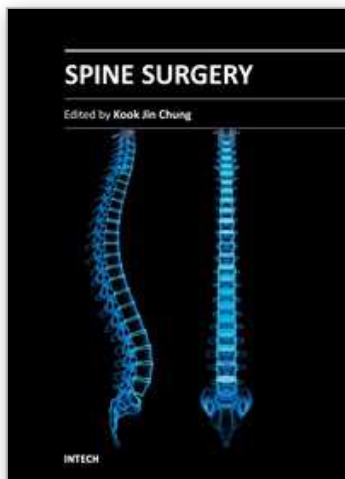
This procedure has limitation that it is difficult and dangerous to perform the unilateral transpedicular approach in high thoracic level, particularly over the 6th thoracic vertebra, because of small pedicle size and narrow canal. In that case, extrapedicular approach is more safe and convenient. The surgeon is not satisfied with the inflatable bone tamp position or the extent of inflation or cavity created by using a unipedicular approach, a second contralateral balloon can be placed using the conventional technique. The key to the unilateral approach is the medial trajectory of the needle and the final midline position of the balloon.

9. Conclusion

Balloon kyphoplasty can be performed using a unilateral balloon tamp via a unilateral transpedicular approach for osteoporotic vertebral body compression fracture. There was no greater risk for lateral wedging in the unipedicular group. Given the advantages of a unipedicular approach with respect to vertebral pedicle cannulation risk, operative time, radiation exposure, and cost, this study would support the use of a unilateral transpedicular approach to kyphoplasty in the treatment of osteoporotic vertebral compression fractures.

10. References

- [1] Belkoff SM, Mathis JM, Deramond, et al. (2001). An ex vivo biomechanical evaluation of a hydroxyapatite cement for use with kyphoplasty. *Am J Neuroradiol* 22:1212–6.
- [2] Belkoff SM, Mathis JM, Fenton DC, et al. (2001). An ex vivo biomechanical evaluation of an inflatable bone tamp used in the treatment of compression fracture. *Spine* 26:151–5.
- [3] Berlemann U, Franz T, Orler R, et al. (2004). Kyphoplasty for treatment of osteoporotic vertebral fractures: a prospective non-randomized study. *Eur Spine J* 13:496– 501.
- [4] Chiras J. (1997). Percutaneous vertebral surgery: techniques and indications. *J Neuroradiol* 24:45–52.
- [5] Cook DJ, Guyatt GH, Adachi JD, et al. (1993). Quality of life issues in women with vertebral fractures due to osteoporosis. *Arthritis Rheum* 36:750–6.
- [6] Cotton A, Dewatre F, Cortet B, et al. (1996). Percutaneous vertebroplasty for osteolytic metastases and myeloma: effects of the percentage of lesion filling and the leakage of methyl methacrylate at clinical follow-up. *Radiology* 200:525–30.
- [7] Coumans JV, Reinhardt MK, Lieberman IH. (2003). Kyphoplasty for vertebral compression fractures: 1-year clinical outcomes from a prospective study. *J Neurosurg* 99: 44-50.
- [8] Garfin S, Lin G, Lieberman I, et al. (2001). Retrospective analysis of the outcomes of balloon kyphoplasty to treat vertebral compression fracture refractory to medical management. *Eur Spine J* 10(suppl 1):S7.
- [9] Garfin SR, Yuan HA, Reiley MA. (2001). New technologies in spine: kyphoplasty and vertebroplasty for the treatment of painful osteoporotic compression fractures. *Spine* 26:1511–5.
- [10] John Steinmann, DO, Craig T. Tingey, MD, Qian Dai, PhD. (2005). Biomechanical Comparison of Unipedicular Versus Bipedicular Kyphoplasty. *Spine* 30: 201–5.
- [11] Kado DM, Browner WS, Palermo L, et al. (1999). Vertebral fractures and mortality in older women. *Arch Intern Med* 159:1215–20.
- [12] Lieberman IH, Dudeney S, Reinhardt MK, et al. (2001). Initial outcome and efficacy of kyphoplasty in the treatment of painful osteoporotic vertebral compression fractures. *Spine* 26: 1631–8.
- [13] Lyles KW, Gold DT, Shipp KM, et al. (1993). Association of osteoporotic vertebral fractures with impaired functional status. *Am J Med* 94:595–601.
- [14] Nussbaum DA, Gailloud P, Murphy K. (2004). A review of complications associated with vertebroplasty and kyphoplasty as reported to the Food and Drug Administration medical device related web site. *J Vasc Interv Radiol* 15:1185-92.
- [15] Riggs BL, Melton LJ.(1995). The worldwide problem of osteoporosis: insights afforded by epidemiology. *Bone* 17 (5 Suppl):505S–511S
- [16] Rollingshoff M, Sobottke R, Koy T, Delank KS, Eysel P. (2008). Minimally invasive surgery of the lumbar spine. *Z Orthop Unfall* 146:395–408.
- [17] Silverman SL. (1992). The clinical consequences of vertebral compression fracture. *Bone* 13(suppl 2):27–31.



Spine Surgery

Edited by Dr. Kook Jin Chung

ISBN 978-953-51-0469-8

Hard cover, 148 pages

Publisher InTech

Published online 28, March, 2012

Published in print edition March, 2012

"Spine Surgery" is an authoritative and didactic textbook on the various fields of spine. It is written by many authors, internationally honorable experts to share their opinions with you. The chapters cover from anatomy of spine, spinal imaging technique, biology of spine, bone graft substitute, minimally invasive spinal surgery to even spinal deformity. It has many up to date results to help readers including university graduate students, medical instrumentation developers, and medical professionals including orthopaedic and neurosurgeons, rehabilitative professionals. The readers are provided with precious information and valuable guide in your daily practice.

How to reference

In order to correctly reference this scholarly work, feel free to copy and paste the following:

Kyoung-Suok Cho and Sang-Bok Lee (2012). Unilateral Transpedicular Balloon Kyphoplasty for the Osteoporotic Vertebral Compression Fracture, Spine Surgery, Dr. Kook Jin Chung (Ed.), ISBN: 978-953-51-0469-8, InTech, Available from: <http://www.intechopen.com/books/spine-surgery/unilateral-transpedicular-balloon-kyphoplasty-for-osteoporotic-vertebral-compression-fracture>

INTECH
open science | open minds

InTech Europe

University Campus STeP Ri
Slavka Krautzeka 83/A
51000 Rijeka, Croatia
Phone: +385 (51) 770 447
Fax: +385 (51) 686 166
www.intechopen.com

InTech China

Unit 405, Office Block, Hotel Equatorial Shanghai
No.65, Yan An Road (West), Shanghai, 200040, China
中国上海市延安西路65号上海国际贵都大饭店办公楼405单元
Phone: +86-21-62489820
Fax: +86-21-62489821

© 2012 The Author(s). Licensee IntechOpen. This is an open access article distributed under the terms of the [Creative Commons Attribution 3.0 License](https://creativecommons.org/licenses/by/3.0/), which permits unrestricted use, distribution, and reproduction in any medium, provided the original work is properly cited.

IntechOpen

IntechOpen