

# We are IntechOpen, the world's leading publisher of Open Access books Built by scientists, for scientists

6,900

Open access books available

185,000

International authors and editors

200M

Downloads

Our authors are among the

154

Countries delivered to

TOP 1%

most cited scientists

12.2%

Contributors from top 500 universities



WEB OF SCIENCE™

Selection of our books indexed in the Book Citation Index  
in Web of Science™ Core Collection (BKCI)

Interested in publishing with us?  
Contact [book.department@intechopen.com](mailto:book.department@intechopen.com)

Numbers displayed above are based on latest data collected.  
For more information visit [www.intechopen.com](http://www.intechopen.com)



# Peripheral Nerve Surgery: Indications, Surgical Strategy and Results

Jörg Bahm<sup>1,2</sup> and Frédéric Schuind<sup>2</sup>

<sup>1</sup>Euregio Reconstructive Microsurgery Unit, Franziskushospital Aachen,

<sup>2</sup>Department of Orthopaedics and Traumatology,  
ULB University Hospital Erasme, Brussels,

<sup>1</sup>Germany

<sup>2</sup>Belgium

## 1. Introduction

So far, peripheral nerve surgery is not a recognized surgical speciality or competence and is currently performed by dedicated colleagues trained either in neurosurgery, plastic and/or hand surgery, or general surgery all over the world. Like the vascular surgeon who needs sound understanding of blood flow dynamics when planning and performing a macro- or microvascular anastomosis, the peripheral nerve surgeon must be aware of the increasing knowledge on *nerve regeneration*, a complex and multifactorial biological repair process with a defined time course and known actors, promoters and inhibitors.

Surgery of peripheral nerves is always *microsurgery*, therefore addressing the microscopic anatomy of the nerves (42), the need for magnification loops or a microscope and specific instruments, and the necessary skill to handle the structures carefully when performing neurolysis, nerve sutures and grafts with a high technical standard, an important factor to provide a good functional outcome.

Basic knowledge in peripheral nerve surgery has already been established for over twenty years. The reader should be familiar with basics like the microanatomy of a peripheral nerve (12), the technique of end to end and end to side anastomosis, and the indications and techniques of neurolysis, as described by Millesi (35). Furthermore, sound understanding of neurophysiologic examination techniques (46) (including various nerve conduction studies like conduction velocity, distal latency, sensory and motor evoked potentials, and special stimulation techniques like transcranial magnetic stimulation) and neuropathologic nerve staining techniques (42) are also mandatory. Refined imaging techniques (ultrasound, MRI) and new image processing technologies like tension- weighted tractography should be looked at, as they may increase our preoperative knowledge and thus may change reconstructive strategies in the near future.

Why then another article on that topic? The aim of this chapter is a *personal view* summarizing clinical skills and regular surgical experience in peripheral nerve surgery and especially brachial plexus operations of the last 15 years. For the novice, both the anatomy of neural networks like the brachial or lumbosacral plexus and the surgical strategy might look

complex and fastidious. Our aim is to insist on specific landmarks, clinical decision points, and important technical details - all of which should help to improve the functional outcome for our patients.

## **2. Nerve regeneration (12,17,43,54)**

After a severe nerve injury and/or transection, Wallerian degeneration occurs at the distal nerve stump as a clearing process to prepare for reinnervation (arrival of the growth cones). This degenerative process removes axonal debris and myelin and is initiated by the Schwann cells, and complemented by activated macrophages. Schwann cells proliferate and arrange into clusters (bands of Büngner) which will orientate the newly arriving growth cones. In addition, the remaining connective tissue basal membrane forms endoneural tubes. On the proximal edge, the neuronal cell body undergoes chromatolysis with peripheral migration of the nucleus and changes in the endoplasmic reticulum characteristic of the production of molecules for growth and repair. Growth cones emerge from the proximal edge into the nerve segment distal to the lesion and migrate down to the target, thereby progressively reconstructing the nerve structure and function.

Neurotrophic factors like Nerve Growth Factor (NGF), Ciliary Neurotrophic Factor (CNTF) and Insulin-like Growth Factors (IGFs) and neurite-promoting factors including laminin, fibronectin, neural cell adhesion molecules (N-CAM) and N-cadherin are nerve growth promoting factors. They act locally or within the neural cell conducted there by retrograde axoplasmic transport.

## **3. Patient examination and decision making**

Peripheral nerve trauma occurs in the upper or lower limb, as an isolated or combined injury.

The birth process might be complicated by shoulder dystocia in a macrosomic child, and lead to an upper or total obstetric brachial plexus palsy (3). Children may undergo soft tissue laceration by broken glass and suffer from undiscovered peripheral nerve section, or present progressive paralysis of muscle groups after a fall (like weakness of shoulder abductors due to an unrecognized axillary nerve lesion within the quadrangular space, deep in the axilla). Young adults are at risk to become polytraumatized victims of motorcycle accidents including severe injury to the brachial plexus. Pelvic fractures affect the lumbosacral plexus (12, 23). At all ages, bone or soft tissue tumours growing inside the extremities may create nerve lesions, by compression or structural invasion, with progressive destruction of the nerve morphology and function.

Especially brachial plexus lesions in adults and children require a particular consideration, taking also into account in neonates the disturbances in growth (table 1).

Any major peripheral nerve injury needs a quick assessment including a complete patient examination and a complete motor and sensory evaluation.

Of course, the difficult clinical condition of a polytraumatized patient, including alterations of consciousness and/or hemodynamic instability, must be considered. Some initial neurologic deficiencies also resolve spontaneously within the first days after the trauma. Recently, Wiberg (53) stressed that a substantial brachial plexus lesion in an adult is a

diagnostic emergency, as the most proximal root lesions induce neuronal cell apoptosis in the anterior medullar horn and thus preclude later motor nerve regeneration.

Adult	Child
High velocity injury (motorcycle)	Traction forces (shoulder dystocia)
Avulsions and ruptures	(partial) ruptures, rare avulsions
Polytrauma	Isolated, rare bone trauma
Slow & incomplete nerve regeneration	Fast regeneration, cortical plasticity
„Fixed“ anatomy	Growing, adaptative anatomy
Adult limb	Growing limb, proportional muscle masses
Organized lifeplan	Progressive task development
Highly compliant	Non compliant

Table 1. Comparison of brachial plexus lesions in adult and children

This paradigm is in clear contradiction with the actual daily practice in most Traumatology departments, where the polytraumatized patient is stabilized, multi-operated, then eventually sent for rehabilitation and left with a flail arm, often even without imagery and clear strategy about exposure and repair of the brachial plexus or nerve trunk injuries. We propose the following guidelines for any (hypothetic or proven) severe peripheral nerve injury:

3.1 Complete clinical (neurological) examination

As early as possible, and then after two weeks (identification of neurapraxia), six weeks and three months.

3.1.1 Signs of severity

Any *rapid muscle waste* is a sign of a severe nerve dysfunction or nerve root avulsion. *Deafferentation neuropathic pain* also signs avulsion of sensitive rootlets. *Horner’s sign* associated to complete brachial plexus palsy signs an avulsion of the Th1 root and is even alone a reason for surgical exploration.

3.1.2 Pain

Where children suffering an obstetric brachial plexus palsy don’t experience pain, adult patients are mostly concerned by severe, untreatable, excruciating neuropathic pain attacks, sometimes making discussion about a sound reconstructive strategy impossible unless the pain is managed correctly.

3.1.3 General patient condition

When preparing one or more reconstructive procedures for severe nerve injury, especially when including exposure of the brachial or lumbosacral plexus with the need for harvesting donor nerves, patients will undergo longlasting and iterative procedures. This strategy should be adapted to the general health situation, the extent of the polytrauma and related surgeries, and the social background.

### 3.1.4 Neurophysiology

There is still controversy about a regular use of nerve conduction studies and CMAP (EMG) recordings, as global findings do very rarely help for surgical decisions. After a severe isolated nerve injury, signs of early recovery might be an argument to delay surgery and to repeat the measurements after four to six weeks. In severe plexus root injuries, the signs distinguishing pre- and postganglionic injuries might be of help when planning a reconstructive strategy. Presence of muscle fibrillations is a strong indicator that a given muscle is still re-innervatable and that thus neurotisation is still of worth. SSEP and MEP are of limited value to judge nerve root quality; we therefore prefer a combination of imagery and intraoperative macro- and microscopic findings.

### 3.1.5 Imagery

In suspected nerve root avulsions (breech presentations in babies, high velocity motorway injuries), we ask for a MyeloCT or an MRI. Frequently, patients arrive at the first consultation with already performed imagery of variable quality. Ultrasound examination, eventually combined with intraoperative assessment, is a new and promising strategy to assess lesions-incontinuity. Diffusion MRI technique measuring water diffusion along preferential guiding structures ("tractography" of peripheral nerves) (16) may show functional connections and the progression of reinnervation along defined axes (nerve trunks).

## 4. Counselling

The patient needs a good understanding of the extent of the nerve trauma, global nerve function, the aim of the reconstructive surgery and the anticipated maximal and minimal results. Sometimes, primary or secondary procedures compete for a same clinical issue. An example is a proximal radial nerve injury (associated to a humeral shaft fracture) where we have to decide between a cable graft, selective nerve transfers or a classic tendon transfer procedure. There is no golden standard so far and the pro's and con's will have to be outlined more clearly. The final decision has to be taken as a consent between the patient and the surgical staff, including a summary of postoperative and rehabilitation requirements.

In adults, important socio- professional requirements must be clarified. Waiting for the recovery of a nerve graft may take six or nine months at minimum, severely increasing the work's leaves, where a tendon transfer might be functional six to eight weeks after surgery.

## 5. Team organisation

Any "emergent" or early indication should be operated on according to that rationale, which could cause important organisation challenges and eventual postposure of other patients with regular, not time-dependant surgeries. The Operation Room crew should be aware of the potential time schedule (a brachial plexus exposure and reconstruction in an adult patient may take easily eight to eleven hours). Sometimes a two-team approach is helpful (eg when harvesting donor nerves at the lower leg or when performing a free functional muscle transfer). After a longlasting procedure, we prefer to observe the patient the first night under cardiovascular monitoring at the intensive care unit.

5.1 Primary nerve surgery: Exposure and techniques

Every nerve should be exposed according to its topography (22), allowing clear identification of the lesion itself and the unaffected proximal and distal ends.

As these surgeries may require a long operation time, prevention of pressure sores using special cushions and monitoring of the body temperature including the use of heating envelopes may be mandatory.

Our preferred exposure of the brachial plexus in adults and children is a straight supraclavicular approach, dividing the platysma lateral to the sternocleidomastoideus muscle with reclination of the adipolymphatic pad to discover the interscalenic triangle with the nerve trunks and the subclavian artery (3,6,8). In rare conditions, we have to isolate the clavicle, separating the insertions of the pectoralis major muscle and hooking up the bone on a silicone loop to explore the retro- and infraclavicular spaces. An osteotomy of the clavicle is rarely mandatory. An additional delto-pectoral approach might be helpful in extended injuries in the adult patient.

For elective nerve transfers, other more direct approaches might be useful (22), including a dorsal approach to the suprascapular and spinal accessory nerve for a classic extraplexic XI onto SSC neurotisation (7).

After the exposure of the traumatized nerve segment(s) and clear identification of healthy proximal (if feasible) and distal edges, a careful *neurolysis* is performed under magnification according to Millesi’s classification of nerve fibrosis (table 2) (35). Type C fibrosis and non-conducting neuromas are resected. Direct electrical stimulation on both proximal and distal areas with decreasing current intensity (from 5 to 1 mA by 1mA steps, and from 1 down by 0.1 steps) is helpful to make the decision, when there is a lack of electrical conductivity and insufficient distal motor response. After resection of the injured segment, the remaining stumps are prepared for grafting and donor nerves are harvested, while waiting for the neuropathologic examination results.

Type A: epifascicular epineurium	epineurotomy
Type B: interfascicular epineurium	epi- or interfascicular epineuriectomy
Type C: perineurium and endoneurium	nerve grafting

Table 2. Sites of nerve fibrosis and surgical treatment according to Millesi (35)

Considering the extent of resection of a neuroma, there is still controversy on how far the back-cut should be. On the distal edge, fascicular pattern should be visible on magnification and, for the beginner, a pathological quality assessment is useful. At the proximal level, where the remaining nerve stump or plexus root is a precious part of the potential reinnervation source, the morphologic appearance and indirect information about the reinnervation potential are of very high importance and correlate directly to the functional prognosis. We rely on a reduced amount of perineural and endoneural fibrosis, a homogenous fascicular architecture and a sufficient density of newly built myelin sheaths, which constitute indirect signs of reinnervation by the growth cone advancements (42). Peripheral microfascicles should not be too numerous, as they are representative of the neuroma and its disorganized fascicular pattern. Eventually, a more proximal back-cut is performed, although we have to assume that if the remnant of a plexus root is near the



foramen, the grafting becomes technically difficult and the lesion might extend into the foramen, represent a very proximal rupture responsible for more neuronal apoptosis or an in situ root avulsion. We don't trust this type of root quality; and the stump becomes a second line donor, eg for the middle trunk.

Some neurosurgeons used to perform (hemi)laminectomies perform a dorsal neck approach to evaluate the root quality and confirm the diagnosis of root avulsions suspected on MRI images, and even perform rootlet reimplantations (13,14).

**5.2 Neuropathologic examination of proximal and distal nerve stumps: Technique of harvest and microscopic examination**

All specimens to be sent are cut with a fresh surgical knife, marked either proximally or distally using a vital blue pen, and sent on a moist swab.

The neuropathologist performs an immediate (fast) examination and a more remote appreciation. We receive a phone call discussing the fast result after some 50 minutes and a written report 10 to 14 days later, including an analysis of all staining techniques.

The fast examination is performed on frozen sections (Cryostat), after Hematoxylin Eosin (HE) and trichrome Gomorri staining. Morphometry is performed on these specimens to evaluate the size of the fascicles, the thickness of myeline sheaths, and their proportion in a nerve section area. The delayed examination of Epon imbedded tissue cut into semi-thin slices after toluidine blue staining is aimed to confirm the structural observations made within the first examination and concludes the written report.

While waiting for the neuropathologic appreciation of the stump quality, *grafts* are harvested from the lower legs (one or two sural nerves), the cervical subcutaneous tissue or the ipsilateral forearm (superficial branch of the radial nerve). All grafts are conditioned in a wet swab and brought into the defect without tension, in an antidromic direction, to avoid lost collateral sprouting during the reinnervation. Simple nerve gaps are bridged by an interfascicular cable graft, made of numerous graft segments to fill the gap. If there is information about the clockwise orientation of fascicles within the proximal and distal segment, this information is integrated to avoid any mismatch. The longer the gap, the more “hazardous” is the topographic reinnervation due to the intraneural plexiform arrangement of the different fascicles, a well known microanatomical characteristic more present in the proximal nerve segments than in the distal parts, close to the target.

<i>number of roots</i>	<i>children</i>	<i>adult</i>
one	LT, lat UT, XI-MC	UT, IC-R, XI-SSC
two	LT+MT, UT	UT, MT
three or more	Anatomic reconstruction	

UT upper trunk, MT middle trunk, LT lower trunk (lat=lateral part) XI spinal accessory nerve, MC musculocutaneous nerve, R radial nerve, IC intercostal nerves

Table 3. Priorities of reinnervation in brachial plexus repair

A brachial plexus repair is normally made out of a combination of intraplexic (“anatomic”) and extraplexic repair (3,8,12):

*Intraplexic repair* is performed by cable grafts, without tension, including very precise positioning and fibrin glue fixation, between the remaining roots of good morphological quality and the preferential distal nerve targets (priorities are given in table 3).

### 5.3 Extraplexic adjuncts

Are either added in the same procedure (when they can be performed within reasonable time and access limits, like the transfer of the distal branch of the spinal accessory nerve onto the suprascapular nerve) or in a second procedure (eg multiple intercostal nerve transfers for elbow flexion or extension). An overview of routine extraplexic nerve transfers is given in table 4, summarizing the currently used nerve transfer procedures (34,37).

### 5.4 Nerve coaptation technique

End-to-end coaptation of nerve ends requires very precise tissue arrangement and absence of tension. When fascicular groups may be arranged according to the cross sectional pattern, more direct and complete regeneration is expected. The microsurgical technique using epi-perineural stitches is actually believed to be the gold standard; but fibrin glue used as a *peripheral* stump fixation substance (creating a stable peripheral sheath around both stumps which should be perfectly coapted) has proven its high quality. We use fibrin glue for every nerve coaptation, either in addition to the sutures, to create a smooth and protective environment to the anastomosis, either as the only fixation, especially in children and for interposition grafts when there is no tension at all on the stumps. In nerve transfers, sometimes tiny fascicles have to be coaptated to selective motor or sensory fibers and this connexion is crucial for the good functional outcome: then we use 10 or 11 /0 sutures and very high magnification under the microscope. On the other hand, when repairing very proximal root ruptures after brachial plexus injury, the proximal stump might be so close to the foramen that sutures are impossible and than fibrin glue alone will allow to fix the coaptation. The only drawback with fibrin glue is that once the site is glued, there is no further visual control possible. We never would use fibrin glue as an *interposition* substance between nerve stumps, as this would impair the nerve regeneration through the local fibrosis. Unfortunately, there is so far evident lack of experimental data comparing the use of stitches and fibrin glue under ideal (no tension) conditions.

### 5.5 Nerve imbedding

Nerve grafts are made of newly denervated fresh nerve segments which need concomittant revascularization to insure good reinnervation. Therefore, a healthy, not scarred and well vascularized surrounding tissue is mandatory. In a longer cable graft, fascicles might be separated to favour the revascularization. Longer interposition nerve grafts, like those for a free functional muscle transfer, should be placed in an unconstrained, well vascularized environment like an unoperated subcutaneous layer, as we already have observed severe graft constriction and increasing fibrosis when the graft was positioned between muscles, eg between delto-pectoral muscle layers.

*Immobilisation* of the head-neck segment is mandatory for three weeks postoperatively.



5.6 Nerve transfers

This concept includes a growing group of specific fascicle transfer techniques (26,37,39,48,50) where a donor nerve (harvest of redundant fascicles sorted out by an intraoperative selective low intensity electrostimulation) is transferred to a specific motor or sensitive target. A selective end-to-side anastomosis with an epineural window is the final achievement of this selective transfer concept (36).

Table 4 gives an overview of the actually known nerve transfers in the reconstruction of upper limb nerve defects.

In specific indications, motor nerve ends may be directly implanted into target muscles (24).

Donor nerve	Target nerve	Author
XI	SSC (spinati)	Malessy 2004 (32), Bahm 2005 (7), Pondaag 2005 (41)
XI	MC (biceps)	Narakas (37)
IC	MC (biceps)	Malessy 1998 (30)
IC	AX (deltoid)	Malungpaishrope 2007 (33)
U	MC (biceps or brachialis)	Oberlin 2002 (38), Teboul 2004 (49), Liverneaux 2006 (27)
U	R (triceps)	Gilbert 2011 (18)
M	MC (biceps or brachialis)	Oberlin 2008 (39)
M	R (PIN)	Mackinnon 2007 (29), Bertelli 2010 (11)
R	AX (deltoid)	Leechavengvongs 2003 (25), Colbert and McKinnon 2006 (15), Bertelli 2007 (10)
MC (brachialis)	M (finger flexion)	Palazzi 2006 (40)
ThD	ThL (serratus ant.)	Uerpaiojkit 2009 (52)
Ph	MC	Gu 1989 (20), Siqueira 2009 (45)
Ph	SSC	Sinis 2009 (44)
cC7	multiple	Gu 1987 (19,21), Songcharoen 2001 (47), Terzis 2009 (51)

Table 4. Currently performed nerve transfers

6. Principles of secondary surgery

Most indications of secondary corrections arise once the reinnervation process after the primary nerve reconstruction comes to an end, dependant on the distance between the proximal nerve stump / fascicle donor and the motor target, i.e. generally after one to three years (5). When the functional result of a primary nerve surgery is expected to be poor (e.g. grafting of a proximal radial nerve lesion), a secondary procedure with tendon transfers may be indicated early; and the eventual gain from reinnervation will improve the result of tendon transfers.

Only some rare clinical conditions in children with soft tissue contractures and joint subluxations need sometimes an early decision, without considering the nerve recovery, but focusing on potential joint and bone growth disturbances (9). Secondary surgery may be directed at:

- tendon and/ or muscle transfer(s) to increase or balance key muscle functions in the affected extremity,
- correct soft tissue contractures at the shoulder or elbow level,
- newly orientate a limb segment by (de)rotational osteotomy,
- recreate a mandatory limb function by functioning free muscle transfer,
- increase protective sensibility in special skin areas by distal nerve transfers (eg using the intercostobrachialis nerve to supply the lateral part of the median nerve);
- perform corrections at the hand level, e.g. correction of clawing, difference of flexion power between long fingers, increasing thumb mobility (e.g. opposition).

In the growing child, muscle transfers are best performed before school age, when the limb weight is still not prohibitive for the transferred muscle to achieve good active ROM against gravity (minimum M3 recovery).

Specific technical points concern:

- the tendon suture(s) (preferred interweaving Pulvertaft technique),
- the tendon re-attachment to the bone (direct suture into the periosteum or using a bone anchor).

After six weeks of immobilisation, specific rehabilitation is prescribed for a minimum of 6-12 months and, later on, strengthening exercises are mandatory.

## 7. Results

A good result is characterized by a useful return of function in sensory and/or motor skills. Indications for primary and secondary surgery focus on this expectation: any reconstructive surgery in this field is acceptable only when a real functional goal can be met.

Results remain very individual, present several facets and depend on many factors. Therefore, evidence based medicine criteria don't apply easily to this individualized surgery.

Ongoing reinnervation might be clinically detected by a progressing Hofmann-Tinel sign along the nerve axis. In a near future, repetitive diffusion tensor imaging (16) should be able to visualize the progressing line of growth cones by the intense metabolic activity.

Recovery of motion is measured by the increase of the active range of motion (aROM) in the powered joint; and force by the BRMC grading system (M1 to M5). It is accepted today that only a motor power above M3 (movement against gravity) is of functional worth. Recent developments in video-assisted motion analysis of the upper limb (4) allow parallel recordings of the motion pattern, active ROM and EMG, and also forces and torques applied to the analyzed joints. These multifactorial records are useful once conducted under repeatable and objective measurement conditions (e.g. using a robot arm for a standardized movement sequence) both before an operation and within the postoperative rehabilitation period. Nevertheless, muscle strength and fatigue-resistance, important characteristics when looking at activities of daily life, are rarely studied so far.

Measurements of recovery of sensation and the value of sensitive rehabilitation are a wide field of research and beyond the scope of this review (12,28).

From the patient's view, recoveries of activities useful in his private and professional life are important. Questionnaires about performance of activities in daily living and pain intensity altogether with functional scores may address some of these particular issues, but any general conclusion drawn from these might be hazardous, as so many – controlled and also unknown – factors interfere with the outcome.

One also has to consider that the possible ergonomic and financial compensations existing in Western culture countries, making some extended surgeries less accepted here, as patients with very severe nerve injury (a young adult suffering a total brachial plexus palsy with four or five root avulsions) may prefer a rehabilitation program associated with social help and reintegration much better than repetitive and longlasting surgeries with sometimes doubtful outcomes.

The literature is made of presentations of techniques and often small retrospective clinical series restricted to one technique or a specific injury pattern or target. Some contributions would make believe that there are more or less good nerves, as far as regeneration or recovery is concerned. In fact, we have to remember the microanatomy: anastomosis or grafting of a mixed nerve, containing motor and sensory fibers, always will be hazardous concerning fiber redistribution and functional outcome; the same applies to end-to-side connections between mixed nerves. The main negative predictive factors are the severity of injury, the amount of intraneural fibrosis, the delay for surgery and the distance to the target. These factors all interfere with the surgical technical attempts to restore motor or sensory function.

## 8. Scientific purposes and future directions

Especially at the upper limb level, movements are executed by groups of muscles working together as a team. Furthermore, agonist and antagonist activities should harmonize for a goal-directed motion. Therefore, we should perhaps look more at muscle groups, like the analytic work in physiotherapy and ongoing research in motion analysis starts to show.

Sensation is a very complex topic and should not been treated as a second-choice subject in reconstructive nerve surgery and rehabilitation (12,14,28).

The interface between the human body, its muscles and myoelectric prostheses has gained new interest through multi-channel, highly specialized “bionic prostheses”, aiming at restoration of multiple degree of freedom movements (2). The sensory glove (28) represents one field of research of rehabilitation of a sensory loss introducing other CNS functions like audition to complement the sensorial lack within the recovery process.

Another field concerns the experimental and clinical work around nerve root reimplantation (13,14) achieving motion (although parasitized by cocontractions) and restoration of simple reflex arcs.

Bioartificial nerve grafts and also allografts could increase our capacity to bridge numerous and large nerve defects in the adult (e.g. long defect of a sciatic nerve), but are at present worthless in numerous indications and especially in children.

The pain management in adult patients with severe nerve injury may be very challenging. Sometimes, this priority is higher than the functional reconstruction, as the patient not only is totally incapacitated by the pain in his daily living, but also has to consider the numerous side effects of a longlasting treatment with multiple drugs. Finally, cortical plasticity after reconstructive neurosurgery is a promising field to understand how we learn to use nerve transfers and adapt to newly recreated functions (1,31).

## 9. Acknowledgement

We want to express our gratitude to Baxter Germany represented by S. Ehrle MD who supported the manuscript edition financially and thus concretized the publication.

## 10. References

- [1] Anastakis DJ, Malessy MJ, Chen R, Davis KD, Mikulis D: Cortical plasticity following nerve transfer in the upper extremity. *Hand Clinics* 2008 24 425-444
- [2] Aszmann OC, Dietl H, Frey M: Selective nerve transfers to improve the control of myoelectrical arm prostheses. *Handchir Mikrochir Plast Chir* 2008 40 60-65
- [3] Bahm J : Obstetric brachial plexus palsy - clinics, pathophysiology and surgical treatment. *Handchir Mikrochir Plast Chir* 2003 35 83-97
- [4] Bahm J, Meinecke L, Brandenbusch V, Rau G, Disselhorst-Klug C : High spatial resolution electromyography and video-assisted movement analysis in children with obstetric brachial plexus palsy. *Hand Clinics* 2003 19 393-399
- [5] Bahm J : Secondary procedures in obstetric brachial plexus lesions. *Handchir Mikrochir Plast Chir* 2004 36 37-46
- [6] Bahm J, Becker M, Disselhorst-Klug C, Williams C, Meinecke L, Müller H, Sellhaus B, Schröder JM, Rau G : Surgical Strategy in Obstetric Brachial Plexus Palsy - the Aachen Experience. *Seminars in Plastic Surgery* 2004 18 285-299
- [7] Bahm J, Noaman H, Becker M : The dorsal approach to the suprascapular nerve in neuromuscular reanimation for obstetric brachial plexus lesions. *Plast Reconstr Surg* 2005 115 240-244
- [8] Bahm J, Ocampo-Pavez C, Noaman H : Microsurgical technique in obstetric brachial plexus repair : a personal experience in 200 cases over 10 years. *J Brachial Plexus Peripheral Nerve Injury* 2007 2 1-7
- [9] Bahm J, Wein B, Alhares G, Dogan C, Radermacher K, Schuind F : Assessment and treatment of glenohumeral joint deformities in children suffering from obstetric brachial plexus palsy. *J Ped Orthop* 2007 16B 243-251
- [10] Bertelli JA, Santos MA, Kechele PR, Ghizoni MF, Duarte H: Triceps motor nerve branches as a donor or receiver in nerve transfers. *Neurosurgery* 2007 61:333-338
- [11] Bertelli JA, Ghizoni MF: Transfer of supinator motor branches to the posterior interosseous nerve in C7-T1 brachial plexus palsy. *J Neurosurg* 2010 113 129-132
- [12] Birch R, Bonney G, Wynn Parry CB: *Surgical Disorders of the Peripheral Nerves*. Churchill Livingstone Edinburgh 1998
- [13] Carlstedt T: *Central Nerve Plexus Injury*. Imperial College Press London 2007

- [14] Carlstedt T: Spinal Cord Surgery Restores Motor and Sensory Function in Patients with Brachial Plexus Avulsion Injury. Invited lecture at the FESSH congress Oslo May 2011
- [15] Colbert SH, Mackinnon S: Posterior approach for double nerve transfer for restoration of shoulder function in upper brachial plexus palsy. *Hand* 2006 1 71-77
- [16] Filler A: Magnetic Resonance Neurography and Diffusion Tensor Imaging: Origins, History, and Clinical Impact of the First 50 000 Cases With An Assessment of Efficacy and Utility in A Prospective 5000-Patient Study Group. *Neurosurgery* 2009 65 A29-A43
- [17] Frostick SP, Yin Q: Schwann cells, neurotrophic factors, and peripheral nerve regeneration. *Microsurgery* 1998 18: 397-405
- [18] Gilbert A: personal communication at the Narakas meeting Lisboa 2011
- [19] Gu YD, Wu MM, Zhen YL et al: Microsurgical treatment for root avulsion of the brachial plexus. *Chin Med J* 1987 100 519-522
- [20] Gu YD, Wu MM, Zhen YL et al: Phrenic nerve transfer for treatment of brachial plexus root avulsion. Report at Brachial Plexus Symposium Lausanne 1989
- [21] Gu YD, Zhang GM, Chen DS et al: Cervical nerve root transfer from healthy side for treatment of brachial plexus root avulsion. Report at Brachial Plexus Symposium Lausanne 1989
- [22] Kline DG, Hudson AR, Kim DH: Atlas of peripheral nerve surgery Saunders Philadelphia 2001
- [23] Lang EM, Borges J, Carlstedt T: Surgical treatment of lumbosacral plexus injuries. *Neurosurg* 2004 1:64-71
- [24] Lassner F, Becker M, Fansa H, Mawrin C; Pallua N: [Reconstruction of defects at the neuromuscular junction]. *Handchir Mikrochir Plast Chir* 2003 35: 127-131
- [25] Leechavengvongs S, Witoonchart K, Uerpaiojkit C, Thuvasethakul P: Nerve transfer to deltoid muscle using the nerve to the long head of the triceps. Part II A report of 7 cases. *J Hand Surg Am* 2003 28 633-638
- [26] Leechavengvongs S, Witoonchart K, Uerpaiojkit C; Thuvasethakul P; Malungpaishrope K: Combined nerve transfers for C5 and C6 brachial plexus avulsion injury. *J Hand Surg Am* 2006 31 183-189
- [27] Liverneaux PA, Diaz LC, Beaulieu JY, Durand S, Oberlin C: Preliminary results of double nerve transfer to restore elbow flexion in upper type brachial plexus palsies. *Plast Reconstr Surg* 2006 117 915-919
- [28] Lundborg G: Nerve Injury and Repair (2<sup>nd</sup> edition) Churchill Livingstone New York 2005
- [29] Mackinnon SE, Roque B, Tung TH: Median to radial nerve transfer for treatment of radial nerve palsy. Case report. *J Neurosurg* 2007 107666-671
- [30] Malesy MJ, Thomeer RT: Evaluation of intercostals to musculocutaneous nerve transfer in reconstructive brachial plexus surgery. *J Neurosurg* 1998 88 266-271
- [31] Malesy MJ, Thomeer RT, van Dijk JG: Changing central nervous system control following intercostals nerve transfer. *J Neurosurg* 1998 89 568-574

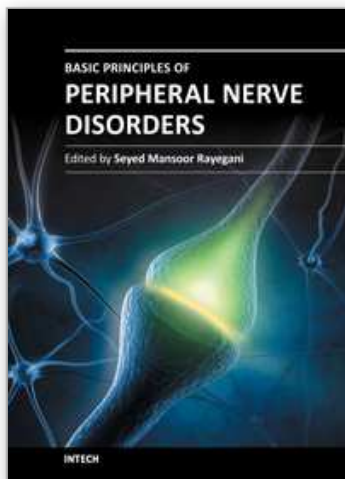


- [32] Malessy MJ, de Ruiters GC, de Boer KS, Thomeer RT: Evaluation of suprascapular nerve neurotisation after nerve graft or transfer in the treatment of brachial plexus traction lesions. *J Neurosurg* 2004 101 377-389
- [33] Malungpaishrope K, Leechavengvongs S, Uerpaiojkit C, Witoonchart K, Jitprapaikulsaarn S, Chongthammakun S: Nerve transfer to deltoid muscle using the intercostal nerves through the posterior approach: an anatomic study and two case reports. *J Hand Surg Am* 2007 32 218-224
- [34] Merrell GA, Barrie KA, Katz DL, Wolfe SW: Results of nerve transfer techniques for restoration of shoulder and elbow function in the context of a meta-analysis of the English literature. *J Hand Surg Am* 2001 26 303-314
- [35] Millesi H: Neurolysis. In Boome RS (ed): *The Brachial Plexus. The Hand and Upper Extremity* (volume 14) Churchill Livingstone New York 1997
- [36] Millesi H, Schmidhammer R: Nerve fiber transfer by end-to-side coaptation. *Hand Clin* 2008 24 461-483
- [37] Narakas AO: Neurotization in the treatment of brachial plexus injuries. In: Gelberman RH (ed): *Operative nerve repair and reconstruction*. JB Lippincott Company Philadelphia 1991 (1329-1358)
- [38] Oberlin C, Ameer NE, Teboul F, Beaulieu JY, Vacher C: Restoration of elbow flexion in brachial plexus injury by transfer of ulnar nerve fascicles to the nerve to the biceps muscle. *Tech Hand Up Extrem Surg* 2002 6 86-90
- [39] Oberlin C, Durand S, Belheyar Z, Shafi M, David E, Asfazadourian H: Nerve transfers in brachial plexus palsies. *Chir Main* 2008 25 S1297-1302
- [40] Palazzi S, Palazzi JL, Caceres JP: Neurotization with the brachialis muscle motor nerve. *Microsurg* 2006 26 330-333
- [41] Pondaag W, de Boer R, van Wijlen-Hempel MS, Hofstede-Buithuis SM; Malessy MJ: External rotation as a result of suprascapular nerve neurotization in obstetric brachial plexus lesions. *Neurosurgery* 2005 57 530-537
- [42] Schröder JM: *Pathology of Peripheral Nerves* Springer Berlin 2001
- [43] Schuind F, Phan QD, Cermak K, El Kazzi W, Bahm J: Stimulation biologique de la régénération axonale. *Cours européen de pathologie chirurgicale du membre supérieur et de la main* Paris January 2011
- [44] Sinis N, Boettcher M, Werdin F, Kraus A, Schaller HE: Restoration of shoulder abduction function by direct muscular neurotization with the phrenic nerve fascicles and nerve grafts: a case report. *Microsurgery* 2009 29 552-555
- [45] Siqueira MG, Martins RS: Phrenic nerve transfer in the restoration of elbow flexion in brachial plexus avulsion injuries: how effective and safe is it? *Neurosurgery* 2009 65 A125-131
- [46] Smith SJM: The role of neurophysiological investigation in traumatic brachial plexus injuries in adults and children. *J. Hand Surgery* 1996 21B 145-148
- [47] Songcharoen P, Wongtrakul S; Mahaisavariya B; Spinner RJ: Hemi-contralateral C7 transfer to median nerve in the treatment of root avulsion brachial plexus injury. *J Hand Surg Am* 2001 26 1058-1064
- [48] Songcharoen P, Wongtrakul S, Spinner RJ: Brachial plexus injuries in the adult. nerve transfers: the Siriraj Hospital experience. *Hand Clin* 2005 21 83-89



- [49] Teboul F, Kakkar R, Ameur N, Beaulieu JY; Oberlin C: Transfer of fascicles from the ulnar nerve to the nerve to the biceps in the treatment of upper brachial plexus palsy. *J Bone Joint Surg Am* 2004 86 1485-1490
- [50] Terzis JK, Kostas I, Soucacos PN: Restoration of shoulder function with nerve transfers in traumatic brachial plexus palsy patients. *Microsurg* 2006 26 316-324
- [51] Terzis JK, Kokkalis ZT: Selective contralateral c7 transfer in posttraumatic brachial plexus injuries: a report of 56 cases. *Plast Reconstr Surg* 2009 123 927-938
- [52] Uerpaiojkit C, Leechavengvongs S, Witoonchart K, Malungpaishorpe K, Raksakulkiat R: Nerve transfer to serratus anterior muscle using the thoracodorsal nerve for winged scapula in C5 and C6 brachial plexus root avulsions. *J Hand Surg Am* 2009 34 74-78
- [53] Wiberg M, Vedung S, Stalberg E: Neuronal loss after transection of the facial nerve: a morphological and neurophysiological study in monkeys. *Scand J Plast Reconstr Surg Hand Surg* 2001 35 135-140
- [54] wikipedia: Overview of events in peripheral regeneration ([http://en.wikipedia.org/wiki/Peripheral\\_nerve\\_injury](http://en.wikipedia.org/wiki/Peripheral_nerve_injury))
- [55] wikipedia: Muscular fibrillation (<http://en.wikipedia.org/wiki/Fibrillation>)

IntechOpen



### **Basic Principles of Peripheral Nerve Disorders**

Edited by Dr. Seyed Mansoor Rayegani

ISBN 978-953-51-0407-0

Hard cover, 278 pages

**Publisher** InTech

**Published online** 28, March, 2012

**Published in print edition** March, 2012

Peripheral nerve disorders are comprising one of the major clinical topics in neuromusculoskeletal disorders. Sharp nerve injuries, chronic entrapment syndromes, and peripheral neuropathic processes can be classified in this common medical topic. Different aspects of these disorders including anatomy, physiology, pathophysiology, injury mechanisms, and different diagnostic and management methods need to be addressed when discussing this topic. The goal of preparing this book was to gather such pertinent chapters to cover these aspects.

#### **How to reference**

In order to correctly reference this scholarly work, feel free to copy and paste the following:

Jörg Bahm and Frédéric Schuind (2012). Peripheral Nerve Surgery: Indications, Surgical Strategy and Results, Basic Principles of Peripheral Nerve Disorders, Dr. Seyed Mansoor Rayegani (Ed.), ISBN: 978-953-51-0407-0, InTech, Available from: <http://www.intechopen.com/books/basic-principles-of-peripheral-nerve-disorders/peripheral-nerve-surgery-indications-surgical-strategy-and-results>

**INTECH**  
open science | open minds

#### **InTech Europe**

University Campus STeP Ri  
Slavka Krautzeka 83/A  
51000 Rijeka, Croatia  
Phone: +385 (51) 770 447  
Fax: +385 (51) 686 166  
[www.intechopen.com](http://www.intechopen.com)

#### **InTech China**

Unit 405, Office Block, Hotel Equatorial Shanghai  
No.65, Yan An Road (West), Shanghai, 200040, China  
中国上海市延安西路65号上海国际贵都大饭店办公楼405单元  
Phone: +86-21-62489820  
Fax: +86-21-62489821

© 2012 The Author(s). Licensee IntechOpen. This is an open access article distributed under the terms of the [Creative Commons Attribution 3.0 License](https://creativecommons.org/licenses/by/3.0/), which permits unrestricted use, distribution, and reproduction in any medium, provided the original work is properly cited.

IntechOpen

IntechOpen