

# We are IntechOpen, the world's leading publisher of Open Access books Built by scientists, for scientists

6,900

Open access books available

186,000

International authors and editors

200M

Downloads

Our authors are among the

154

Countries delivered to

TOP 1%

most cited scientists

12.2%

Contributors from top 500 universities



WEB OF SCIENCE™

Selection of our books indexed in the Book Citation Index  
in Web of Science™ Core Collection (BKCI)

Interested in publishing with us?  
Contact [book.department@intechopen.com](mailto:book.department@intechopen.com)

Numbers displayed above are based on latest data collected.  
For more information visit [www.intechopen.com](http://www.intechopen.com)



## Renal Effects of Preeclampsia

Kuang-Yu Jen and Zoltan G. Laszik  
*University of California, San Francisco,  
 USA*

### 1. Introduction

Dramatic hemodynamic alterations occur during a normal, healthy pregnancy with the kidneys playing a major role to ensure that these adaptive changes occur properly. Therefore, it is not surprising that a significant number of women may develop new onset renal dysfunction or exacerbation of preexisting renal disease during pregnancy. Perhaps the most commonly encountered gestational disorder is hypertension, which can lead to significant complications for both the mother and the fetus when left untreated. A variety of factors may cause or contribute to the development or worsening of hypertension during pregnancy; nevertheless, clinically, hypertensive disorders of pregnancy can be divided into four major categories as recommended by the National High Blood Pressure Education Program Working Group on High Blood Pressure in Pregnancy: preeclampsia, chronic/preexisting hypertension, preeclampsia superimposed upon chronic hypertension, and gestational hypertension [1]. Of particular importance in defining these categories is the time of onset of hypertension during pregnancy, whether the women had preexisting hypertension prior to pregnancy, and whether proteinuria is present. Hypertension prior to pregnancy or occurring before 20 weeks of gestation indicates chronic/preexisting hypertension while hypertension occurring after 20 weeks of gestation but without proteinuria defines gestational hypertension. Preeclampsia is gestational hypertension with the additional feature of proteinuria. Of these hypertensive disorders of pregnancy, preeclampsia is the most common and can cause devastating systemic consequences including substantial renal injury. In this chapter, we discuss the pathologic manifestations and molecular pathogenesis of preeclampsia with a special emphasis on the renal effects of this disease.

### 2. Clinical definition, epidemiology, and presentation

Preeclampsia is a systemic syndrome of pregnancy defined by new onset hypertension (systolic  $\geq 140$  mmHg or diastolic  $\geq 90$  mmHg) and proteinuria of  $\geq 0.3$  grams per 24-hour occurring after 20 weeks of gestation in a previously normotensive woman [1, 2]. The incidence of preeclampsia is somewhat variable depending on the study population, but estimates generally range from 3 to 7% of all pregnancies [3-6], making it the leading cause of maternal and fetal morbidity and mortality and perhaps the most frequently encountered glomerular disease worldwide. Many factors have been associated with an increased risk of developing preeclampsia including prior history or family history of preeclampsia,

nulliparity, multigestational pregnancy, long time interval between pregnancies, obesity, age >40 years, diabetes mellitus, and preexisting history of other medical conditions such as chronic hypertension and renal disease, among others [7-10].

Preeclampsia can be subdivided into mild and severe, with severe forms exhibiting more prominent signs and symptoms of end-organ damage that may result in life-threatening disease. Multiple organ systems may be affected in severe preeclampsia including dysfunction of the central nervous system (i.e. blurred vision, altered mental status, severe headache, cerebrovascular accident), liver (i.e. elevated serum transaminases), cardiovascular system (i.e. systolic blood pressure  $\geq 160$  mm Hg or diastolic  $\geq 110$  mm Hg), lungs (i.e. pulmonary edema, cyanosis), and/or kidneys (i.e. proteinuria of  $\geq 5$  grams in 24 hours, oliguria of <500 mL in 24 hours) [1, 11]. Other notable disease features include potential manifestation of microangiopathic hemolytic anemia, thrombocytopenia, and severe fetal growth restriction [12]. Preeclampsia with concurrent symptom of grand mal seizures with no other attributable cause supports the diagnosis of eclampsia. HELLP syndrome, a life-threatening variant of preeclampsia, may develop in approximately 10 to 20% of women with severe preeclampsia [13]. The additional laboratory findings of microangiopathic hemolysis, elevated liver enzymes, and a low platelet count (thrombocytopenia) establish the diagnosis of HELLP syndrome and represent more prominent and systemic end-organ injury.

Typically, women with preeclampsia display mild proteinuria; however, nephrotic range proteinuria and slight hematuria may be seen in severe preeclampsia and represents a significantly increased risk for complications [11]. Although edema can be present in preeclamptic patients, normal pregnancies often will induce edema, making this finding unreliable for the diagnosis of preeclampsia. A dramatic decrease in glomerular filtration rate may occur in preeclampsia although serum creatinine is generally close to baseline levels or may be slightly elevated. Acute renal failure is highly unusual. Other potential clinical features include hyperuricemia and hypercalciuria.

Since renal diseases, especially those of glomerular origin, often present with hypertension and proteinuria, the clinical differential diagnosis of preeclampsia is broad and includes various glomerular diseases. Chronic glomerulonephritis, minimal change nephrotic syndrome, focal segmental glomerulosclerosis, membranous nephropathy, postinfectious glomerulonephritis, diabetic nephropathy, and sickle cell nephropathy should be considered. In severe cases of preeclampsia with significant microangiopathic hemolytic anemia and thrombocytopenia, hemolytic-uremic syndrome (HUS) and thrombotic thrombocytopenic purpura (TTP) should also be included in the differential diagnosis [12].

### 3. Pathologic findings

Although preeclampsia is a clinical diagnosis based on new onset hypertension and proteinuria, as mentioned earlier, the specificity of these features is low and a renal biopsy may be helpful to confirm the suspicion of preeclampsia. Since many other forms of renal diseases may arise during pregnancy, the utility of the renal biopsy is also to exclude (or include) other pathologic processes of the kidney that may mimic preeclampsia clinically.

Typically, preeclampsia manifests morphologically as thrombotic microangiopathy (TMA) on renal biopsy, a pattern of renal injury commonly seen in association with endothelial cell injury. It should be stressed that TMA is a histologic and ultrastructural pattern that develops in response to renal injury and is not a specific disease. Many etiologies of TMA exist, including but not limited to TTP, HUS, malignant hypertension, scleroderma/systemic sclerosis, drugs/medications, antibody-mediated rejection (in allografts), and preeclampsia/eclampsia. Although a few subtle morphologic features appear to be seen more often in renal biopsies from patients with preeclampsia (discussed below); overall, these findings remain relatively non-specific and are not entirely reliable as morphologic indicators to distinguish preeclampsia from other etiologies of TMA.

### 3.1 Light microscopy

Since TMA is a disease that results from small vessel endothelial cell injury, the major morphologic findings reside within the glomeruli and/or the arterioles, the hallmark of which is that of fibrin platelet thrombi within these small vessels. However, unlike other etiologies of TMA, preeclampsia typically does not exhibit platelet fibrin thrombi within glomerular capillary lumina. Instead, the most characteristic glomerular feature of preeclampsia is that of prominent glomerular endothelial cell swelling, termed endotheliosis. This process results in occlusion of the glomerular capillary lumina without an appreciable increase in cellularity and generally gives the glomerular tuft a lobularly accentuated appearance (Figure 1). Overall, glomerular volume is slightly increased, yet since glomerular cellularity remains relatively unchanged, an impression of somewhat hypocellular glomeruli that take on a “bloodless” appearance is classically described in preeclampsia due to the endotheliosis. Variable degrees of mesangiolysis are commonly noted, but significant mesangial matrix widening or mesangial hypercellularity is not typically present. The glomerular tuft may also often exhibit capillary loop wrinkling with mild collapse/shrinkage of the glomerular tuft characteristic of acute ischemic changes. This feature is frequently seen in association with severe arteriolar changes in the afferent arteriole and most likely is due to hypoperfusion of the glomeruli from compromised arteriolar blood flow. Prominence of the visceral epithelial cells may be observed due to proteinuria; however, this finding may be quite variable and may, to a certain degree, depend on the severity of the proteinuria. The glomeruli can be either segmentally or globally involved, and the kidney may be focally or diffusely affected, depending on the severity of the disease.

In chronic stages of TMA (including preeclampsia), the glomeruli typically display extensive glomerular capillary basement membrane replication, a feature similar to the “tram tracking” seen in membranoproliferative glomerulonephritis (MPGN) or in transplant nephropathy of renal allografts. Therefore, this morphologic feature is non-specific and is a consequence of long term glomerular endothelial cell injury. However, unlike MPGN where subendothelial immune deposits are present on immunofluorescence and electron microscopy and sometimes can even be appreciated on light microscopy, chronic stages of TMA show no evidence of an immune complex-mediated process. In allografts, chronic changes of TMA are indistinguishable from transplant glomerulopathy.

Arteriolar pathology is also often present along with the glomerular changes. Arterioles commonly display striking intimal swelling/edema with substantial luminal closure. Fibrin platelet thrombi and/or schistocytes may be seen within the narrowed lumina. As mentioned earlier, this feature may markedly compromise afferent blood flow into the glomeruli resulting in glomerular ischemia. In the subacute phase, the intimal swelling becomes replaced by scarring. At first, appreciable numbers of cells are seen within the early intimal concentric scar giving an "onion skin" appearance. As scarring becomes more established, intimal fibroplasia sets in and is essentially indistinguishable from severe arteriosclerosis seen in other etiologies of chronic vascular disease.

### 3.2 Immunofluorescence microscopy

Immunofluorescence microscopy shows no specific features for TMA or TMA as a result of preeclampsia. Fibrin, IgM, and to a lesser extent, complement components, may be positive within glomeruli along the capillary walls, in the mesangium, and in arterioles especially during acute stages of the disease, the latter of which corresponds to intravascular fibrin platelet thrombi seen on light microscopic evaluation [14-16]. The immunofluorescence intensity somewhat correlates to the severity/activity of the disease [15]. Although TMA can show fibrin positivity within the glomerular intracapillary lumina, preeclampsia rarely displays this finding. IgG is minimally positive if present, and IgA is usually negative.

### 3.3 Electron microscopy

Similar to the light and immunofluorescence microscopic findings, ultrastructural characteristics of TMA are similar regardless of the etiology. In the acute phase, electron microscopic examination of renal tissue from patients with TMA (including those with preeclampsia) reveal thickening of the glomerular capillary walls due to a combination of subendothelial widening, endothelial cell swelling, and occasional mesangial cell interposition. Often, the widened subendothelial space, represented as an expanded lamina rara interna, takes on a pale and flocculent appearance with irregular collections of slightly electron-dense material, typically without appreciable fibrin. Similar material can occasionally be seen within the mesangium, resulting in mesangial prominence with slight mesangial cell swelling. Electron-dense immuno-type deposits should be absent, and if present, should prompt further investigation into an immune complex-mediated process instead of or concurrent with TMA. As mentioned above, one slightly more distinguishing feature of preeclampsia is that of endotheliosis or endothelial cell swelling, which can be observed occluding much of the glomerular capillary lumina in severe cases (Figure 2). The endothelial cells in this instance lose their characteristic fenestrations. Although rarely seen in preeclampsia, intracapillary thrombi containing amorphous osmiophilic material admixed with fibrin, platelets, deformed red blood cells, and inflammatory cells can be present in other forms of TMA. Finally, podocyte foot processes often show at least focal, if not widespread, effacement.

In chronic stages, nonspecific glomerular capillary basement membrane wrinkling and thickening may be appreciated. Often, new glomerular basement membrane material is also present giving rise to basement membrane reduplication and architectural "complexity", features similar to that seen in transplant glomerulopathy in allograft kidney biopsies. Variable mesangial cell interposition can be observed.



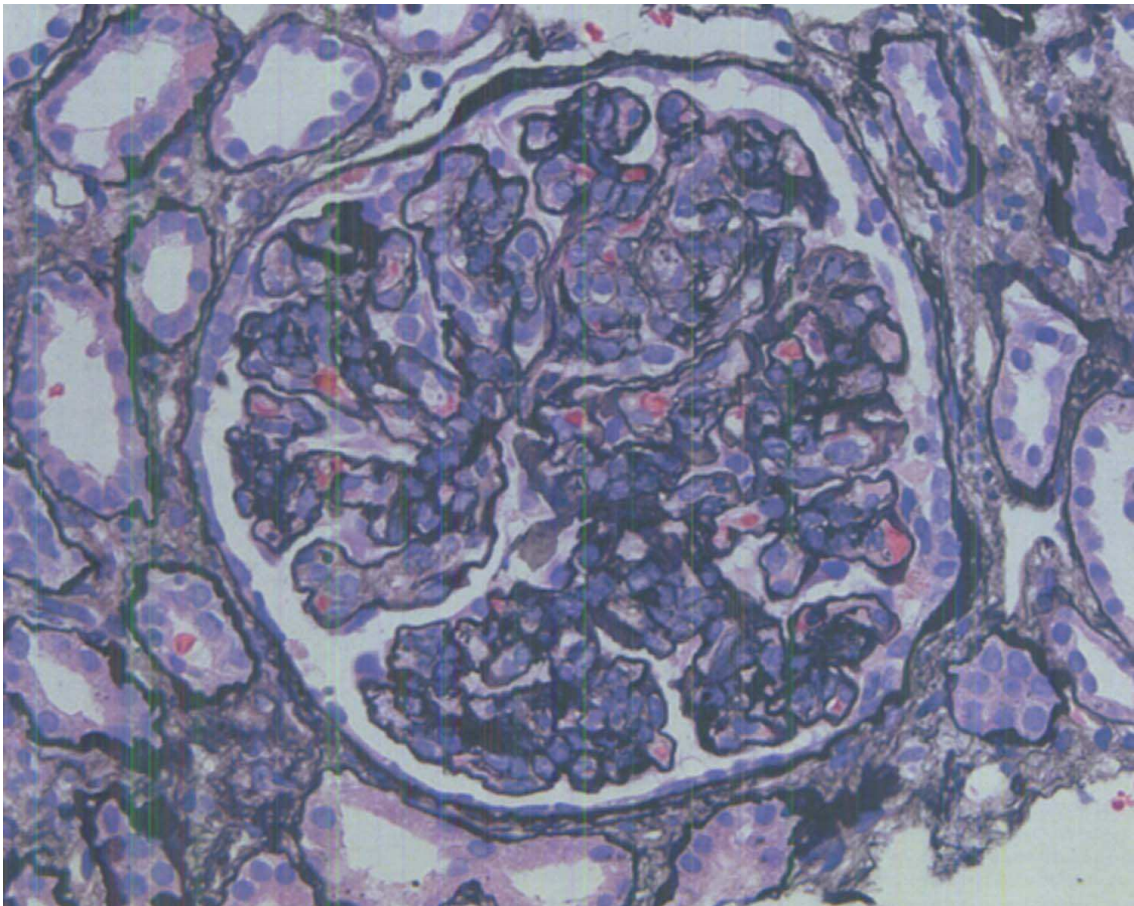


Fig. 1. Preeclampsia, light microscopy. The glomerular capillary tufts are distended with closure of the capillary lumina due to swollen endothelial cells. The glomerular appearance is slightly lobular. (Jones' methenamine silver, x400) (Courtesy of Dr. Patrick Walker and Nephropath, Little Rock, AK).

## 4. Pathogenesis

Microvascular endothelial cell injury appears to play a central role in the pathogenesis of preeclampsia. Therefore, as expected, end organ damage is generally directed towards organ systems highly dependent on the microvasculature for normal function including the kidney, liver, and central nervous system (including the eyes), among others. In order to fully comprehend the pathogenesis and renal consequences of preeclampsia, an understanding of renal physiology is required.

### 4.1 Renal physiology

The kidneys act as filters that eliminate waste products within the blood, and thus, receive up to 25% of the cardiac output. To accomplish this function, systemic blood flow enters the kidneys and is directed into the glomeruli through the afferent arterioles. Filtration occurs through the glomerular capillary loops, which constitute the glomerular filtration barrier (GFB) and consist of the glomerular capillary basement membrane (GBM) flanked by visceral epithelial cells (also known as podocytes) on the side of the Bowman space and glomerular capillary endothelial cells along the glomerular capillary lumina (Figure 3). The

glomerular ultrafiltrate travels from the glomerular capillary lumina, through the endothelial cell fenestrations, through the GBM, and finally through the slit diaphragms between the podocyte foot processes, into the Bowman space. The integrity of the GFB prevents leakage of serum proteins into the Bowman space. However, when any component of the GFB is compromised, proteinuria arises.

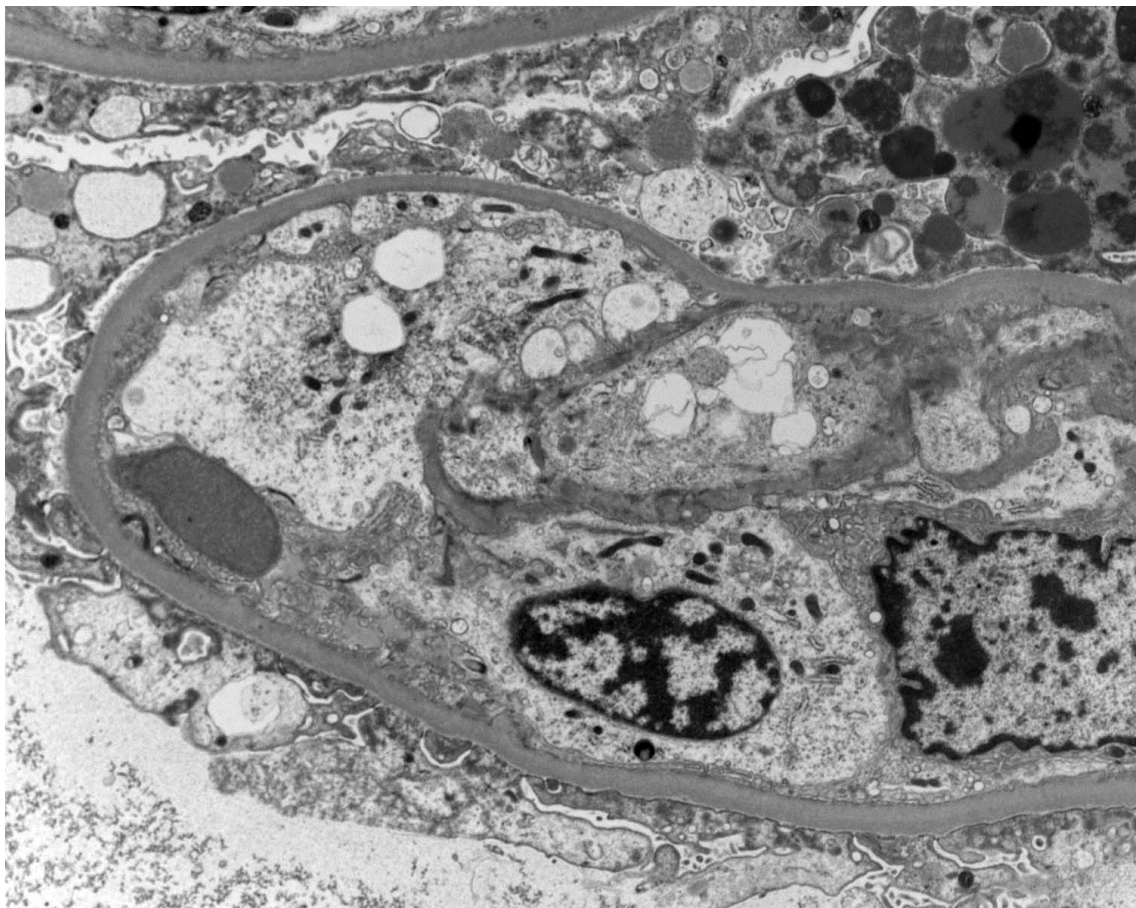


Fig. 2. Characteristic ultrastructural findings of preeclampsia. The glomerular capillary endothelial cells are swollen with occlusion of the capillary lumina. Note the significant effacement of the foot processes and the numerous protein resorption droplets within the visceral epithelial cells. (Electron microscopy, original magnification  $\times 4,800$ )

The glomerular consequences of preeclampsia can be understood in terms of disruption of the GFB through glomerular capillary endothelial cell injury. Not only does endothelial damage result in endotheliosis and loss of endothelial cell fenestrations, the podocytes are disrupted as well since these remarkably specialized cells are highly dependent on signals derived from the glomerular endothelial cells to maintain foot process structure and the slit diaphragms. Ultimately, glomerular endothelial cell injury causes the breakdown of multiple components of the GFB, which leads to proteinuria and hypertension. Arteriolar endothelial injury also occurs in preeclampsia and may induce significant narrowing of arteriolar lumina. Consequently, glomerular filtration is compromised and results in glomerular hypoperfusion and diminished glomerular filtration rate with renal compensation manifesting as elevated blood pressure.



## 4.2 Molecular mechanism of preeclampsia

Recently, extraordinary progress has been made in adding to our understanding of the molecular mechanism of preeclampsia. As mentioned earlier, the root of preeclampsia as a disease process lies in microvascular endothelial cell injury. Much of the data point to abnormal placentation or other causes of aberrant placental vascular development as the initiating event, which leads to placental hypoxia and subsequently triggers the release of placenta-derived factors into the maternal circulation. Consequently, these factors, most of which have antiangiogenic properties, cause damage to the microvascular endothelium by altering local angiogenic and vasodilatory signals.

Several circulating factors have been implicated in the pathogenesis of preeclampsia, perhaps the best studied of which is soluble Flt-1 (sFlt1). This secreted form of vascular endothelial growth factor (VEGF) receptor-1 is able to bind and sequester angiogenic factors such as VEGFA and placental growth factor (PlGF), acting as an endogenous inhibitor of VEGF-receptor signaling. In preeclampsia, excessive levels of sFlt1, thought to originate from the placenta, appears to disrupt VEGF-receptor signaling, which is essential for the maintenance of endothelial health (Figure 3). As a result, tipping the endothelial environment towards an antiangiogenic state leads to generalized damage to the endothelium. In the glomeruli, glomerular endothelial cell injury results in disruption of the GFB with clinical consequences to the kidney as described earlier. In support of this mechanism of preeclampsia, several studies have shown that women with established preeclampsia display elevated levels of serum sFlt1 and that this increase may occur even before the onset of hypertension [17, 18]. Additionally, animal models overexpressing sFlt1 produce clinical signs and glomerular lesions reminiscent of human preeclampsia [17]. Similar observations have been reported in rodents when neutralizing antibodies to VEGFA are administered [19]. On the other hand, exogenous administration of VEGFA alleviates this preeclampsia-like phenotype in rats without apparent harm to the fetus [20]. Likewise, renal damage induced in mice by adenoviral overexpression of sFlt1 is alleviated by reducing circulating sFlt1 through co-expression of VEGF [21].

Some studies indicate that soluble endoglin (sEng) may act in a similar manner as sFlt1 in the pathogenesis of preeclampsia. Just as in the case of sFlt1, sEng likely produced by the placenta is also elevated in the sera of women with preeclampsia and correlates with disease severity [22, 23]. Interestingly, although overexpression of sEng alone in animal models gives only mild proteinuria when compared to sFlt1 overexpression, concurrent elevation of these factors leads to severe preeclampsia with evidence of HELLP syndrome [22]. The effects of sEng may be propagated through the disruption of transforming growth factor beta 1 (TGFB1) signaling with subsequent impairment of TGFB1-mediated activation of endothelial nitric oxide synthetase (eNOS) (Figure 3) [22]. Since eNOS is of prime importance in regulating vascular tone and also displays angiogenic properties, abrogation of eNOS as a result of elevated sEng levels induces endothelial cell injury and defects in vasodilatation. Of note, hypoxia up-regulates the placental expression of endoglin [24]. Therefore, placental hypoxia due to abnormal placentation may give rise to sEng elevation, and in combination with other antiangiogenic factors like sFlt1, may result in the development of preeclampsia or HELLP syndrome.



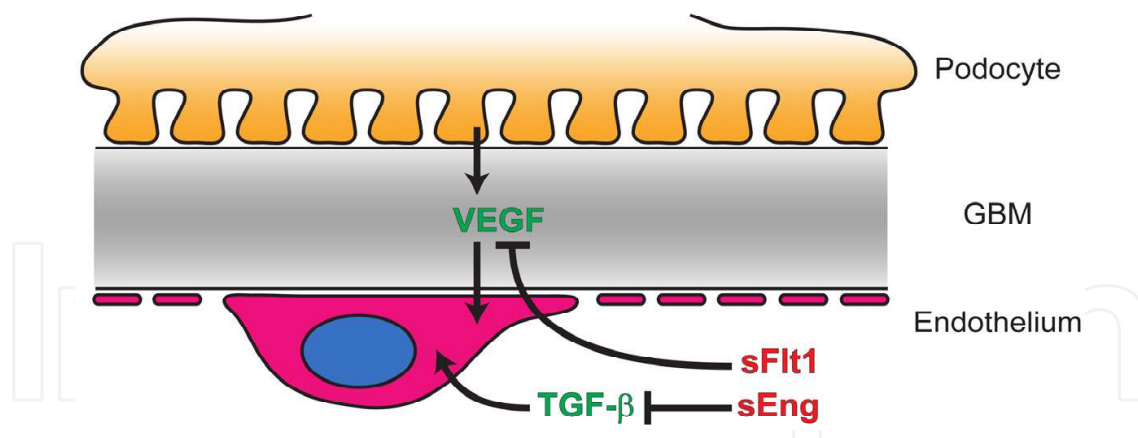


Fig. 3. VEGF produced by the podocytes is required to maintain healthy endothelial cells. Circulating sFlt1, likely originating from the placenta, is able to bind and sequester VEGF, resulting in endothelial cell damage. Similarly, the pro-endothelial effects of circulating TGF- $\beta$  are inhibited by sEng, leading to endothelial injury.

## 5. Prognosis and treatment

At this time, delivery of the neonate and placenta is the only definitive cure of preeclampsia; however, fetal morbidity and mortality is highly dependent on the gestational age at the time of delivery. Therefore, a crucial decision must be made to weigh the benefits of delivery for the mother against the risks of prematurity for the neonate. Generally, quick resolution of both hypertension and proteinuria follows delivery.

If delivery is not a viable option, management with antihypertensive medications and prophylactic seizure treatment with intravenous magnesium sulfate may be initiated [25-27]. If preterm delivery prior to 34 weeks is considered, betamethasone is commonly given to the mother to hasten fetal lung development [28]. In severe cases of preeclampsia/eclampsia where preterm delivery is not a viable option, maternal symptoms of significant microangiopathic hemolytic anemia, thrombocytopenia, renal failure, and/or neurologic abnormalities may be treated with plasma exchange with variable benefit [12].

Currently, treatment for preeclampsia is largely supportive, requiring careful obstetric management. As we make significant progress in elucidating the molecular mechanisms of preeclampsia, the hope of future targeted therapies to ameliorate or even prevent the development of preeclampsia appears to inch closer to reality. Given the immense health impact of preeclampsia due to its high worldwide prevalence, progress in this field has the potential to greatly improve global women's health in a relatively short period of time.


## 6. References

- [1] Report of the National High Blood Pressure Education Program Working Group on High Blood Pressure in Pregnancy. *Am J Obstet Gynecol*, 2000. 183(1): p. S1-S22.
- [2] Roberts, J.M., et al., *Summary of the NHLBI Working Group on Research on Hypertension During Pregnancy*. *Hypertension*, 2003. 41(3): p. 437-45.
- [3] Stillman, I.E. and S.A. Karumanchi, *The glomerular injury of preeclampsia*. *J Am Soc Nephrol*, 2007. 18(8): p. 2281-4.

- [4] Saftlas, A.F., et al., *Epidemiology of preeclampsia and eclampsia in the United States, 1979-1986*. Am J Obstet Gynecol, 1990. 163(2): p. 460-5.
- [5] Sibai, B.M., et al., *Risk factors for preeclampsia in healthy nulliparous women: a prospective multicenter study. The National Institute of Child Health and Human Development Network of Maternal-Fetal Medicine Units*. Am J Obstet Gynecol, 1995. 172(2 Pt 1): p. 642-8.
- [6] Zhang, J., S. Meikle, and A. Trumble, *Severe maternal morbidity associated with hypertensive disorders in pregnancy in the United States*. Hypertens Pregnancy, 2003. 22(2): p. 203-12.
- [7] Duckitt, K. and D. Harrington, *Risk factors for pre-eclampsia at antenatal booking: systematic review of controlled studies*. BMJ, 2005. 330(7491): p. 565.
- [8] Xiong, X., W.D. Fraser, and N.N. Demianczuk, *History of abortion, preterm, term birth, and risk of preeclampsia: a population-based study*. Am J Obstet Gynecol, 2002. 187(4): p. 1013-8.
- [9] Nilsson, E., et al., *The importance of genetic and environmental effects for pre-eclampsia and gestational hypertension: a family study*. BJOG, 2004. 111(3): p. 200-6.
- [10] van Rijn, B.B., et al., *Outcomes of subsequent pregnancy after first pregnancy with early-onset preeclampsia*. Am J Obstet Gynecol, 2006. 195(3): p. 723-8.
- [11] Lindheimer, M.D., S.J. Taler, and F.G. Cunningham, *Hypertension in pregnancy*. J Am Soc Hypertens, 2010. 4(2): p. 68-78.
- [12] McMinn, J.R. and J.N. George, *Evaluation of women with clinically suspected thrombotic thrombocytopenic purpura-hemolytic uremic syndrome during pregnancy*. J Clin Apher, 2001. 16(4): p. 202-9.
- [13] Karumanchi, S.A., et al., *Preeclampsia: a renal perspective*. Kidney Int, 2005. 67(6): p. 2101-13.
- [14] Gonzalo, A., et al., *Hemolytic uremic syndrome with hypocomplementemia and deposits of IgM and C3 in the involved renal tissue*. Clin Nephrol, 1981. 16(4): p. 193-9.
- [15] Petrucco, O.M., et al., *Immunofluorescent studies in renal biopsies in pre-eclampsia*. Br Med J, 1974. 1(5906): p. 473-6.
- [16] Gaber, L.W., B.H. Spargo, and M.D. Lindheimer, *Renal pathology in pre-eclampsia*. Baillieres Clin Obstet Gynaecol, 1994. 8(2): p. 443-68.
- [17] Maynard, S.E., et al., *Excess placental soluble fms-like tyrosine kinase 1 (sFlt1) may contribute to endothelial dysfunction, hypertension, and proteinuria in preeclampsia*. J Clin Invest, 2003. 111(5): p. 649-58.
- [18] Levine, R.J., et al., *Circulating angiogenic factors and the risk of preeclampsia*. N Engl J Med, 2004. 350(7): p. 672-83.
- [19] Sugimoto, H., et al., *Neutralization of circulating vascular endothelial growth factor (VEGF) by anti-VEGF antibodies and soluble VEGF receptor 1 (sFlt-1) induces proteinuria*. J Biol Chem, 2003. 278(15): p. 12605-8.
- [20] Li, Z., et al., *Recombinant vascular endothelial growth factor 121 attenuates hypertension and improves kidney damage in a rat model of preeclampsia*. Hypertension, 2007. 50(4): p. 686-92.
- [21] Bergmann, A., et al., *Reduction of circulating soluble Flt-1 alleviates preeclampsia-like symptoms in a mouse model*. J Cell Mol Med, 2010. 14(6B): p. 1857-67.
- [22] Venkatesha, S., et al., *Soluble endoglin contributes to the pathogenesis of preeclampsia*. Nat Med, 2006. 12(6): p. 642-9.

- [23] Levine, R.J., et al., *Soluble endoglin and other circulating antiangiogenic factors in preeclampsia*. N Engl J Med, 2006. 355(10): p. 992-1005.
- [24] Yinon, Y., et al., *Severe intrauterine growth restriction pregnancies have increased placental endoglin levels: hypoxic regulation via transforming growth factor-beta 3*. Am J Pathol, 2008. 172(1): p. 77-85.
- [25] Sibai, B.M., *Magnesium sulfate prophylaxis in preeclampsia: Lessons learned from recent trials*. Am J Obstet Gynecol, 2004. 190(6): p. 1520-6.
- [26] Lain, K.Y. and J.M. Roberts, *Contemporary concepts of the pathogenesis and management of preeclampsia*. JAMA, 2002. 287(24): p. 3183-6.
- [27] Wagner, L.K., *Diagnosis and management of preeclampsia*. Am Fam Physician, 2004. 70(12): p. 2317-24.
- [28] Szabo, I., M. Vizer, and T. Ertl, *Fetal betamethasone treatment and neonatal outcome in preeclampsia and intrauterine growth restriction*. Am J Obstet Gynecol, 2003. 189(6): p. 1812-3; author reply 1813.

IntechOpen



## **Microangiopathy**

Edited by Prof. Raimondo De Cristofaro

ISBN 978-953-51-0419-3

Hard cover, 82 pages

**Publisher** InTech

**Published online** 23, March, 2012

**Published in print edition** March, 2012

Microangiopathies are pathological processes causing degenerative disorders of small vessels. The circulatory problems caused by microangiopathies may be responsible for failure of individual or multiple organs. These pathological processes are indeed one of the most common disorders characterized by high morbidity and mortality in the affected patients. Many studies have revealed very complicated processes both at cellular and molecular level. However, much work remains to define the diversity of different pathogenetic mechanisms leading to microangiopathic disorders to provide appropriate prevention and treatment strategies. The aim of this volume is providing illustrative examples of relevant mechanisms responsible for different forms of microangiopathies and how this body of evidences can be harnessed to define new strategies of therapeutic intervention.

### **How to reference**

In order to correctly reference this scholarly work, feel free to copy and paste the following:

Kuang-Yu Jen and Zoltan G. Laszik (2012). Renal Effects of Preeclampsia, Microangiopathy, Prof. Raimondo De Cristofaro (Ed.), ISBN: 978-953-51-0419-3, InTech, Available from:

<http://www.intechopen.com/books/microangiopathy/renal-effects-of-preeclampsia>

**INTech**  
open science | open minds

### **InTech Europe**

University Campus STeP Ri  
Slavka Krautzeka 83/A  
51000 Rijeka, Croatia  
Phone: +385 (51) 770 447  
Fax: +385 (51) 686 166  
[www.intechopen.com](http://www.intechopen.com)

### **InTech China**

Unit 405, Office Block, Hotel Equatorial Shanghai  
No.65, Yan An Road (West), Shanghai, 200040, China  
中国上海市延安西路65号上海国际贵都大饭店办公楼405单元  
Phone: +86-21-62489820  
Fax: +86-21-62489821



© 2012 The Author(s). Licensee IntechOpen. This is an open access article distributed under the terms of the [Creative Commons Attribution 3.0 License](https://creativecommons.org/licenses/by/3.0/), which permits unrestricted use, distribution, and reproduction in any medium, provided the original work is properly cited.

IntechOpen

IntechOpen