

# We are IntechOpen, the world's leading publisher of Open Access books Built by scientists, for scientists

6,900

Open access books available

186,000

International authors and editors

200M

Downloads

Our authors are among the

154

Countries delivered to

TOP 1%

most cited scientists

12.2%

Contributors from top 500 universities



WEB OF SCIENCE™

Selection of our books indexed in the Book Citation Index  
in Web of Science™ Core Collection (BKCI)

Interested in publishing with us?  
Contact [book.department@intechopen.com](mailto:book.department@intechopen.com)

Numbers displayed above are based on latest data collected.  
For more information visit [www.intechopen.com](http://www.intechopen.com)



## Urological Surgical Procedures Under Local Anesthesia

M. Hammad Ather<sup>1</sup>, Ammara Mushtaq<sup>2</sup> and M. Nasir Sulaiman<sup>1</sup>

<sup>1</sup>*Dept of Surgery, Aga Khan University*

<sup>2</sup>*Dow University of Health Sciences  
Pakistan*

### 1. Introduction

Surgical procedures under local anesthesia provide unique advantages. They are associated with less patient anxiety antecedent with the use of general or major regional anesthesia. It is also associated with quicker recovery, less day care recovery room stay and earlier returns to work. It is therefore not surprising that there is considerable interest both among patients and surgeons. The impetus for this has been to maximize anesthetic and postoperative resources by increasing patient turnover in the operating room and discharging patients more efficiently on the same day. Patients with significant co-morbidities, with relative or absolute contra-indication to general or major regional anesthesia can also undergo procedures safely. The use of local anesthesia has continued to expand the ability of urologists to perform a variety of procedures in a safer fashion, particularly in high-risk patients. Most of the local procedures are performed in an operating room setting with a nurse anesthetist in attendance that may administer small amounts of additional intravenous sedation during the procedure. The main goal is to have the patient comfortable during the procedure, but also to be awake and conversant. The local anesthesia techniques vary according to site and procedure. Patient selection is critical for the success of any procedure under local anesthesia. The patient must not be overly anxious and must be willing to accept the surgical technique and anesthesia that is described in detail during the preoperative discussion.

Most of the endourological procedures are done as day cases. Some of these can be performed under local anesthesia. The advantage of using local anesthesia includes performing these in the office. This can potentially decrease the cost and lessen the burden on the operating room and recovery room. Some of the standard procedures currently being done include transrectal guided biopsy, flexible cystoscopy, percutaneous nephrostomy, percutaneous cyst aspiration, renal biopsy, and various scrotal procedures. Some of the other procedures that are being done include optical urethrotomy, rigid cystoscopy, bladder biopsy, ureteroscopy, transurethral incision and resection of the prostate, ureteral meatotomy, and resection of primary and recurrent bladder tumors. More recently transurethral needle ablation of the prostate has also been successfully performed under sedoanalgesia. There are few reports on performing percutaneous nephrolithotomy under local anesthesia for selected patients with renal stones. Other transurethral procedures like laser vaporization have also been performed under sedoanalgesia.

The safety profile of local anesthetic agents is well established, however, there are few rare but serious complications. Local anesthesia is sometimes associated with systemic toxicity. This local anesthetic systemic toxicity (LAST) has been a topic of contemporary interest. Although the exact cause and management of LAST (particularly local anesthetic cardiotoxicity) is unclear, there have been some recommendations. Current data suggests that the LAST cardiotoxicity occurs primarily at sodium channels. Lipid emulsion is a reasonably well-tolerated and effective treatment, and there may be qualitative differences in cardiotoxicity caused by low and high-potency local anesthetics (Wolfe and Butterworth, 2011). Treatment is mostly supportive and includes ventilation; oxygenation, and chest compressions, lipid emulsion therapy should be a primary modality in the treatment of cardiovascular LAST. The use of epinephrine and vasopressin should be tailored and doses should be kept as low as possible while still achieving the desired effects (Wolfe and Butterworth, 2011). Seizure suppression is essential to management, and it is further recommended that an earlier communication with a perfusion team for possible cardiopulmonary bypass (Weinberg, 2010).

This chapter deals with focused literature review on the use of local anesthesia for various urological procedures.

2. Inguino-scrotal procedures

Many inguino-scrotal procedures both in the pediatric and adults can be safely performed under local anesthesia. These procedures include simple inguinal hernia repair, inguinal lymph node biopsy, hydrocelectomy, testicular biopsy, testicular fixation, orchidectomy and scrotal exploration (Magoa, 1998). See table 1

Inguino scrotal procedures	Technique
Hydrocelectomy	Cord block and local infiltration
Vasectomy	Cord block and local infiltration
Varicocelectomy	Local infiltration
Testicular biopsy	Cord block and local infiltration or local infiltration alone
Orchidectomy	Cord block and local infiltration
Orchidopexy, inguinal hernia	Cord block and local infiltration
Circumcision	Penile block and local infiltration

Table 1. Some of the common inguino scrotal procedures and technique of anesthesia

These procedures are performed under local anesthesia using various quantities of local anesthetics with or without adrenaline depending on the procedure. Local anesthesia is in the form of spermatic cord block and/or local infiltration nerve blocks. Generally no

premedication is required except for anxious patients. Many authors have studied the safety of local anesthetic agents. Magoha (Magoha, 1998) did not report any complication directly attributed to the anesthetic agent used or the technique of spermatic cord and nerve blocks employed. In his reported work majority (97%) of the patients' were treated as a day case. The additional use of spermatic cord block along with local infiltration with xylocaine  $\pm$  adrenaline is simple, safe and effective technique that should be used more widely in outpatient urological and general surgical settings in inguino-scrotal surgeries.

In a randomized, double-blind controlled study, in 48 patients undergoing day-case testicular surgery under general anesthesia, Burden and colleagues (Burden et al., 1997) in addition to incision site infiltration gave 22 of these patients 10 mL of 0.5% plain bupivacaine into the spermatic cord at the conclusion of surgery. The visual-analogue pain scores were significantly lower in the immediate recovery period in patients receiving the spermatic-cord block.

## 2.1 Hydrocelectomy

Collection of fluid in the layers of tunica vaginalis has traditionally been treated by surgery. Use of systemic anesthesia with its attendant risks rarely over weigh the discomfort related with this benign condition. Surgeries under local anesthesia and sclerotherapy have become attractive alternative to hydrocelectomy. Aspiration and sclerotherapy is considered cheaper, less invasive and safe compared to hydrocelectomy. However, the outcomes are inconsistent because of lack of uniformity in methods and sclerosing agents used (Khaniya et al., 2009). In another study Beiko et al. (Beiko et al., 2003) similarly concluded that in the treatment of hydroceles, aspiration and sclerotherapy with sodium tetradecylsulfate represents a minimally invasive approach that is simple, inexpensive, and safe but less effective than hydrocelectomy. Sclerotherapy was used in recurrent cases of hydrocele but nowadays due to allergic reaction to sclerosant substances this procedure is not recommended

Hydrocelectomy under local anesthetic is performed in the day care operating room. Patients are continually monitored for hemodynamic stability EKG, blood pressure and oximeter. Any of the local anesthetic agents can be used for local infiltration into the spermatic cord and the site of incision on the scrotal wall. Surgical techniques range from dissection to scission of the bag until partial eversion, requiring the use of reabsorbable suture and a careful hemostasis to avoid drainage. Marchal and colleagues (Marchal et al., 1993) noted that anesthetics tolerance has been highly satisfactory in 52 patients (94%), good in one patient (2%) and unsatisfactory in two cases (4%). Recorded complications in their series included: severe bradycardia and hypotension in one case (2%), persistent right renoureteral pain in one case (2%), scrotal hematoma in 5 cases (9%) and suture dehiscence in another patient (2%). They concluded that surgical management of vaginal collection with local anesthetics is feasible, and reduces the immediate postoperative period also avoiding morbidity derived from a more aggressive anesthetic technique.

## 2.2 Vasectomy

Vasectomy is advancement in male contraception method keeping in view the increasing number of unwanted or unplanned pregnancies (Page et al., 2008). In Vasectomy, the vasa deferentia are severed. It is the most effective and the most long-term acting form of male contraception (Shih et al., 2011). This surgical procedure performed under local anesthesia is

more reliable than classical condoms and timely withdrawal. It is cost-effective, successful and simple when compared to other modes of contraception.

### 2.2.1 Techniques

After induction of local anesthesia, the procedure involves exposing the vasa to occlude it. Based on the review of surgical techniques by Labrecque and associates (Labrecque et al., 2004), no-scalpel vasectomy (NSV) had less surgical complications than other incisional techniques. Other approaches to access vas deferens for vasectomy include pinhole or keyhole, lateral incisions and electro-cautery techniques but they are still investigational in nature. However, the technique used to expose the vas does not relate to effectiveness of the procedure, rather it is the ligation method used that affects its success (Sokal and Labrecque, 2009). The effectiveness of vasectomy is mainly gauged by post-vasectomy semen analysis and at times, by the rates of pregnancy (Sokal and Labrecque, 2009). No-scalpel vasectomy provides additional advantage in terms of pain control and recovery. Shih and colleagues in 2010 (Shih et al., 2010) reported outcome in pain control by using a mini-needle technique provides excellent anesthesia for no-scalpel vasectomy. They noted that it compares favorably to the standard vasal block and other anesthetic alternatives with the additional benefit of minimal equipment and less anesthesia.

### 2.3 Varicocelelectomy

Varicocele surgery is most commonly performed for infertility secondary to deranged seminal parameters in men with varicocele. Rarely varicocelelectomy is also performed for refractory orchalgia secondary to varicocele not responding to conservative management. It seems that this procedure is not effective. The standard management of varicocele repair is the subject of ongoing controversy. In a comparative study of three surgical methods of varicocele treatment Watanabe and colleagues (Watanabe et al., 2005) compared various minimally invasive method. They compared retroperitoneal high ligation under lumbar anesthesia, laparoscopic ligation under general anesthesia, and subinguinal microscopic ligation under local anesthesia. They concluded that subinguinal microscopic varicocelelectomy could be a minimally invasive procedure compared to the other two techniques and a worthy method for treating male infertility due to clinical varicocele. In a metanalysis Cayan and colleagues (Cayan et al., 2009) also concluded that the microsurgical varicocelelectomy technique has higher spontaneous pregnancy rates and lower postoperative recurrence and hydrocele formation than conventional varicocelelectomy techniques in infertile men. Microscopic subinguinal varicocele ligation can be safely performed under local anesthesia. Local infiltration with 1% lidocaine and additional use of cord block provides satisfactory analgesia during the procedure.

In another work Hsu and colleagues (Hsu et al., 2005) performed high ligation of the internal spermatic vein for treatment of a varicocele testis under a regional block in which a precise injection of 0.8 % lidocaine solution was delivered to involved tissues after exact anatomical references were made. They noted that the procedure is simple, effective, reliable and reproducible, and a safe method with minimal complications. It offers the advantages of more privacy, lower morbidity, with no notable adverse effects resulting from anesthesia, and a more rapid return to regular physical activity with minor complications.



## 2.4 Testicular biopsy, orchidopexy and orchidectomy

Almost all testicular procedures can be safely performed using local anesthesia. The technique used in most cases includes infiltration of local anesthetic at the site of incision on the testicular wall prior to which local anesthesia is given for blocking of the spermatic cord. This technique provides a highly satisfactory pain control as demonstrated by many studies. Slight variation in which testicular parenchyma and tunical albuginea is blocked in place of spermatic cord has also been described. Fahmy and colleagues (Fahmy et al., 2005) described a simple technique to deliver local anesthetic for percutaneous testis biopsies. With the testis held firmly, a 25 gage needle is used to inject lidocaine, without epinephrine, into the skin and dartos superficial to the testis, then the needle is advanced through the tunica albuginea and 0.5 mL to 1.0 mL of lidocaine is injected directly into the testis. The testis becomes slightly more turgid with the injection. A percutaneous biopsy is then immediately performed. The investigators (Fahmy et al., 2005) concluded that intra-testicular lidocaine appears to be a simple, rapid and safe method to provide anesthesia for a percutaneous testis biopsy.

Orchidectomy is most commonly performed as a method of hormonal ablation in advanced prostate cancer. It is either performed as total or subcapsular techniques. In a comparison of the two techniques Roosen and colleagues (Roosen et al., 2005) noted that subcapsular orchidectomy is associated with significantly fewer postoperative complications than total orchidectomy. Desmond and colleagues (Desmond et al., 1988) operated on 100 patients with carcinoma of the prostate by bilateral subcapsular orchidectomy under local anesthesia over a 5-year period. They noted that the procedure is simple, effective and well tolerated by the patients. Inguinal orchidectomy performed for testicular cancer can also be similarly performed under local infiltration and cord block. However, due to inadequate muscle relaxation this technique is not an appropriate procedure for both patient and surgeon.

Pediatric inguino-scrotal procedures like circumcision, inguinal hernia and orchidopexy can be safely performed with caudal block. In an open study by Taylor and colleagues (Taylor et al., 2003) designed to assess the efficacy and safety of 0.25% levobupivacaine administered as a caudal injection at a dose of 2 mg·kg<sup>-1</sup> to 49 pediatric patients aged less than 2 years old undergoing circumcision (group 1), or hernia repair or orchidopexy (group 2). They noted that adequate analgesia (an increase of <20% in pulse or respiratory rate compared with baseline and an absence of gross movement on application of surgical stimulus) was achieved in 43/48 patients evaluable for efficacy (89.6%). All 22 patients in the circumcision group had adequate analgesia, and two of these patients did not require additional analgesics.

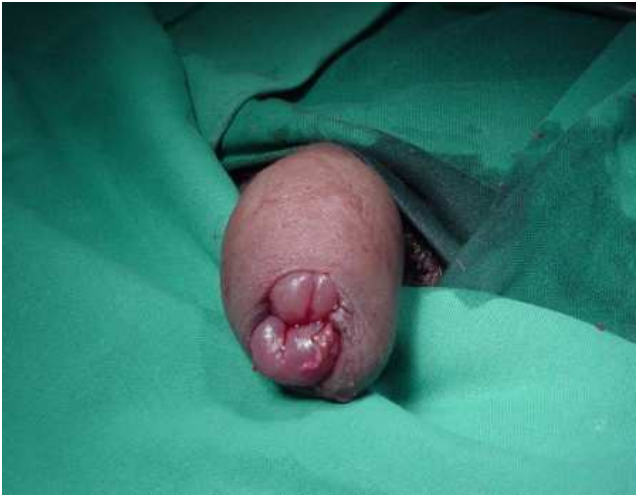In an interesting work by Kiesling et al. (Kiesling et al., 1984) of using spermatic cord block and manual reduction as a primary treatment for spermatic cord torsion. A total of 16 consecutive cases of acute torsion of the spermatic cord less than 24 hours in duration are presented. All patients were diagnosed and treated initially by spermatic cord blockade and attempted manual detorsion. Of the 16 patients, 15 underwent successful detorsion under local anesthesia. All patients underwent subsequent bilateral orchidopexy. Testicular salvage was 93 per cent in those patients who underwent successful detorsion by manipulation. In complicated torsion cases it is emphasized that the scrotum should be opened and after detorsionizing the testis, cord should be fixed.

3. Penile procedures

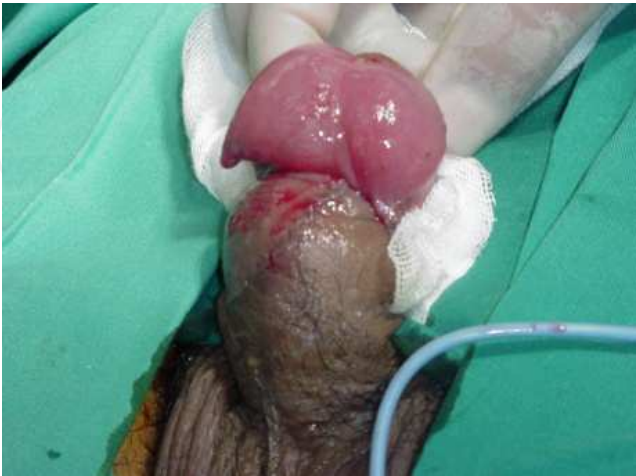Many penile procedures like penile prostheses implantation, modified Nesbit procedure, dorsal slit (Fig 1), venous surgery, venous patches, and arterial revascularization can be safely performed under pure local anesthesia (Hsu et al., 2007).

Penile procedures under local anesthesia	Technique(s)
Circumcision	Penile block and local infiltration
Meatotomy	Spongiosal block and local infiltration
Prosthesis insertion	Crural block and local infiltration
Dorsal slit	Penile block and local infiltration
Penile vascular procedures	Penile block and local infiltration

Table 2. Some of the common penile procedures performed under local anesthesia and technique of anesthesia



(a)



(b)

Fig. 1. A young man presented in emergency with paraphimosis (a) and had Dorsal slit surgery (b) under local anesthesia

Local anesthesia for penile implants has been substantially reported; its methodology, simplicity and reliability left room for improvement. Hsu and colleagues (Hsu et al., 2004) reported an innovative penile crural block using local anesthesia in patients who underwent penile implantation as outpatient surgery. In 21 men with erectile dysfunction surgery was performed under pudendal nerve block as an outpatient procedure. A proximal dorsal nerve block with peripenile infiltration and penile crural block was developed to replace the anesthesia method of pudendal nerve blocks in 137 consecutive patients (aged from 35 to 83 years) undergoing penile implants. The anesthetic effects and postoperative results with the crural block were very satisfactory. Common immediate side effects included puncture of the vessels, subcutaneous ecchymosis, transient palpitations and dilation pain, but there were no significant late complications. This new anesthetic method proved to be reliable, simple, and safe with fewer complications. It offers the advantages of less morbidity, preservation of patient's privacy, reduced adverse effects of anesthesia, and a more-rapid return to activity with minimal complications. Hsu and colleagues (Hsu et al., 2003) performed 29 men with penile deformity, venous patch for morphologic correction. They received autologous grafting of the deep dorsal vein under local anesthesia as an outpatient procedure. The anesthetic effect and postoperative results were satisfactory. The common immediate side effects included puncture of the vessels, subcutaneous ecchymosis, and transient palpitation, but there were no significant late complications. All patients returned home uneventfully. This has been proven to be a cost-effective, simple, and safe method with fewer complications. It offers the advantages of lower morbidity, fewer adverse effects of anesthesia, and a more rapid return to activity with minimal complications.

4. Endoscopic per urethral procedures (table 3)

Endoscopic perurethral procedures	Technique(s)
Cystoscopy	Surface anesthesia
Urethrotomy	Surface anesthesia + Spongiosal block
Ureteroscopic stone fragmentation	Sedoanalgesia and surface anesthetic
Cystolitholapexy	Sedoanalgesia and surface anesthetic
Prostate surgery for BPH	Peri prostatic block(10cc 1%lidocaine at the prostatic apex) and surface anesthesia (perianal-intrarectal lidocaine-prilocaine cream) ± sedoanalgesia

Table 3. Endourological procedures under local anesthesia and technique of anesthesia



## 4.1 Cystoscopy

Cystoscopy is performed both as a diagnostic and therapeutic maneuver. It is frequently used as a surveillance tool for patients with non-muscle invasive bladder cancer. The conventional radiological imaging techniques lack in detection of small lesions in the urinary bladder. In cystoscopy, the urinary bladder is evaluated through urethra with the help of a telescope or microscope attached to the tip of cystoscope, with local anesthesia administered for it most of the times. It is indicated for investigations in cases of urinary tract infections, hematuria, and incontinence, pain during urination, prostate hypertrophy, and calculus in the urinary tract, among others.

Flexible cystoscopy under local anesthesia has been favored against rigid cystoscopy under general anesthesia. On comparing the two with regards to the patient preference, morbidity and post-operative symptoms, the flexible cystoscopy proved to be better (Denholm et al., 1990).

Cystoscopy is chiefly risk-free but may result in urinary tract infection post-procedure (Clark and Higgs, 1990). The procedure is well tolerated and we recently showed that patients if allowed to view the video monitor of the procedure report lower pain on the visual analogue scale (Soomro et al., 2011).

### 4.1.1 Diagnostic uses

Ranking 4<sup>th</sup> in the list of most common cancers, bladder cancer has the tendency to recur. The fact given, it is imperative to make maximum efforts to early diagnose the cancer and to not miss out any case during examination. Detection of bladder cancers by different techniques of cystoscopy has been the focus of research for a long time. On comparing hexaminolevullinate (HAL) fluorescence cystoscopy with standard cystoscopy, the former proved to be significantly better for detection of bladder tumors particularly, carcinoma in situ since HAL fluorescence cystoscopy poses no additional complications, it has also been recommended to be an adjunct procedure with standard cystoscopy (Schmidbauer et al., 2004; Jichlinski et al., 2003). In phase III trial, there was one case of bladder cancer that was detected by HAL fluorescence cystoscopy that was missed by white light cystoscopy (Grossman et al., 2007). Study on efficacy of virtual cystoscopy in patients with bladder tumors shows that its use is still in its infancy and has not yet reached the acceptable quality of fiberoptic examination (Merkle et al., 1998). Yet another study found that in comparison with standard cystoscopy, narrow-band imaging could better detect “non-muscle-invasive bladder tumors” (Herr and Donat, 2008). Cystoscopy has specially been advocated for patients with spinal spinal cord injuries with either chronic or recurrent urinary tract infection to check for squamous cell cancer of the urinary bladder (Navon et al., 1997).

#### 4.1.1.1 Hematuria

Cystoscopy as initial diagnostic modality in subjects with asymptomatic microscopic hematuria has its merits even in outpatient clinics despite increased cost of the procedure (Hong et al., 2001), though concerns have been raised on its invasiveness. Work-up on patients with hematuria revealed that virtual cystoscopy is comparable to conventional

cystoscopy to detect masses (Fenlon et al., 1997). The most common cause of microscopic hematuria is a tumor in the urinary tract.

#### 4.1.2 Anesthesia during cystoscopy

Due to patient discomfort experienced under local anesthesia during cystoscopy, there at times is a need to resort to general anesthesia. There have been efforts underway to make the procedure more patient-friendly. Choong and associates demonstrated that anesthesia with 20mL of 2% lignocaine gel is more effective when left on for a longer period of time than current practices (Choong et al., 1997). It has been demonstrated that if lignocaine is applied slowly to administer local anesthesia, the patient discomfort lessens (Khan et al., 2002). In a comparison of 2% lignocaine gel with plain lubricating gel during cystoscopy, there was no analgesic difference noted between the two (Birch et al., 1994). It has been suggested that chemical content in lignocaine is the cause of pain during delivery in cystoscopy (Ho et al., 2003). One significant finding in this regard is that if the gel is refrigerated to 4°C, it reduces the discomfort caused by instillation of Lidocaine gel into male urethra (Goel and Aron, 2003).

#### 4.2 Urethrotomy

A study compared the efficacy of optical internal urethrotomy and dilatation for treating urethral strictures, both being carried out under local anesthesia (Steenkamp et al., 1997). In the light of this publication, both procedures fared equally well, reflecting onto the success of local anesthesia. During internal urethrotomy, the complications and failures are more frequent for men that have longer or multiple strictures and those that have positive urine culture. Patients with traumatic strictures and those that haven't undergone any treatment for strictures previously also resulted in lesser success in the same study.

Recently, optical urethrotomy was shown to be a feasible choice with 91% success even in patients with severe urethral strictures. This procedure under local anesthesia was very well tolerated with extremely low complication rate (Munks et al., 2010). Comparatively lesser success was shown in 1993 with topical lidocaine anesthesia that gave a success of 83% (Kreder et al., 1993).

Non-randomized trial on safety and efficacy of optical urethrotomy using local anesthesia, spongiosum block with sedation, (figure 2) for anterior urethral stricture demonstrated that compared to major regional or general anesthesia, this method was equally effective and safe (Ather et al., 2009). Merits of local anesthesia could be shorter operating time and cost-effectiveness (Ather et al., 2009). A new local anesthetic technique of intracorporeal spongiosum anesthesia was tested on subjects with anterior urethral stricture and showed promising outcomes with 95.7% patients showing no signs of pain during the procedure and only one case experienced very mild and tolerable pain (Ye and Rong-gui et al., 2002). Analgesia lasted for 1.5 hours by intracorporeal spongiosum as opposed to 1 hour in spongiosum block with sedation.

Optical internal urethrotomy was successful in 92.9% cases with short stricture length reported in 2007. This minimally invasive procedure was suggested to be safe and comfortable and yet, inexpensive (Altinova and Turkan, 2007).

A new tool of using the diode laser to treat urethral strictures has been proposed, which was tolerated by only 3 out of 22 patients under local anesthesia. The rest were operated on under general or spinal anesthesia (Kamal, 2001). The procedure has been advocated as a first line treatment.

Another method of local anesthesia, the transperineal urethrosphincteric block using 1% lidocaine showed favorable results in treating anterior urethral strictures, with 92% patients very satisfied with the procedure. No post-operative complications were noted and there was absolutely no need of additional analgesia during the procedure (Al-Hunayan et al., 2008).

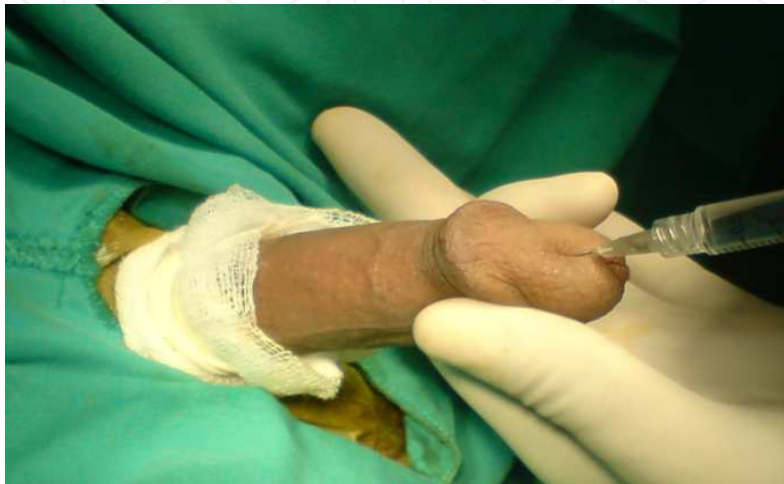

Fig. 2. Spongiosum block being administered using 1% lidocaine without epinephrine in the corpus spongiosum

Urethrotomy should be used only for selected cases to have ideal success rate. Otherwise, an overall low success rate of  $\pm 60\%$  has been reported. Only minor complications occur during or following internal urethrotomy, like infections and hemorrhage. The procedure also has other advantages like ease, simplicity and high speed (Naude and Heyns, 2005). Urethroplasty has a higher success rate than urethrotomy, but is not a cost-effective procedure.

Urethral strictures very often recur, and stricture in penile urethra of greater length being a significant risk for recurrence (Zehri et al., 2009). Patients with these risks should undergo alternative procedures.

The reported success of the procedure varies from 66% to 90%. In case of recurrence that occurs very commonly, repeat direct vision internal urethrotomy is of no value at all. But since the procedure is easy, simple and can be done in outpatient setting under local anesthesia, there's evidence that the procedure is being used excessively and inappropriately. Successful management in cases of obliterative strictures less than 1 cm has been demonstrated using flexible cystoscopy guided- internal urethrotomy (Hosseini et al., 2008).

#### 4.2.1 Complications

Common complications following the procedure are: recurrence of stricture which at times, can be worse than the previous one; pain if the procedure is under local anesthesia or pain post-operatively; infections; periurethral abscess; urethral fistula; and bleeding

#### 4.2.2 Success

Despite all its popularity, concerns have been raised recently on its poor performance. The first or any of the repeated urethrotomies didn't have a success that exceeded 9% (Santucci and Eisenberg, 2010). There was one randomized trial testing the efficacy of Mitomycin C application in internal urethrotomy, which showed its success in reducing the rate of recurrence of strictures (Mazdak, 2007).

#### 4.3 Ureteroscopic stone fragmentation

The ureter receives a rich autonomic nerve supply. Unmyelinated nerve fibers are located in the lamina propria, muscle coat, and adventitia of the ureter. The ureter receives preganglionic sympathetic input from the T10 through L2 spinal segments. Postganglionic fibers arise from several ganglia in the celiac, aorticorenal, mesenteric, superior, and inferior hypogastric (pelvic) autonomic plexuses. The upper ureter receives parasympathetic input from vagal fibers by means of the celiac plexus and the lower ureter from the S2 through S4 spinal segments. Afferent nerves from the upper portion of the ureter reach the spinal cord with the sympathetic fibers from the T10 through L2 spinal segments. Afferents from the lower ureter travel by way of the pelvic plexus to the S2 through S4 spinal segments.

Ureterorenoscopy (URS) is an important tool in the diagnosis and management of most uretero renal pathologies. URS with local anesthesia (LA) and intravenous (IV) sedation can be performed as a diagnostic procedure or to manage ureteral and renal calculi, ureteropelvic junction (UPJ) obstruction, ureteral strictures, and small upper tract transitional cell carcinoma (TCC) recurrences. With advances in ureteroscopic design and the introduction of short-acting anesthetics, URS can now be performed efficiently with high patient satisfaction and minimal post operative recovery time. Recently, URS under local anesthesia, with or without sedation, has become a viable option for a high percentage of correctly selected patients.

For URS in selected patients only anesthesia used is surface anesthesia for the urethra. This may be complemented with IV sedation and analgesia. Use of Midazolam has an added advantage that most patients even with fair pain control have modest recollection of the events. Patient selection is vital to a successful procedure. Women with shorter urethra are preferred over men. Distal ureteral stone rather than proximal ureteral stone should be performed under LA. Balloon dilatation is well tolerated but preference should be to use smaller diameter ureteroscopes ( $\leq 7.5$  Fr).

#### 4.4 Cystolithotripsy

Bladder stones in modern urologic practice are often smaller stones from the upper urinary tract. Larger stones are mostly primary bladder stones as a consequence of neglected bladder outlet obstruction secondary to BPH or neurogenic bladder. Kara and colleagues (Kara et al., 2009) treated 13 patients with transurethral holmium laser cystolithotripsy (HLC) with a flexible cystoscope under local anesthesia. All patients were rendered stone free, regardless of stone size. The mean stone size was 3.6 cm (range 3-5) and the mean operative time was 51 minutes (range 45-65). The whole procedure was well tolerated and no significant differences were found in the mean pain score between the HLC group and a group of male patients that underwent flexible cystoscopy under local anesthesia (2.15

versus 1.86, respectively;  $p = 0.467$ ). No major intraoperative complication occurred. Results of percutaneous approach to bladder stone have similarly been reported with good tolerability and high stone free rate (Tzortzis et al 2006).

#### **4.5 Prostate surgery for BPH**

Bladder outlet obstruction secondary to benign prostatic hyperplasia is one of the commonest disorders of the ageing men. Medical management with alpha-blockers and 5 alpha reductase inhibitors has become the first line in majority of the patients; still significant numbers do require surgical intervention. Open prostatectomy and TURP are considered the gold standard, however, newer less invasive modalities like various forms of laser prostatectomy, trans urethral needle ablation, micro wave thermotherapy, focused ultrasound treatment, ethanol ablation, etc. have been introduced in recent years. Although TURP provides durable results, it is associated with considerable morbidity (Hong et al., 2011). This is of particular concern as most patients needing TURP are old and have multiple co-morbidities.

One of the major advantages of some of these minimally invasive procedures is the ability to perform them under local anesthesia. Transurethral ethanol ablation of the prostate (TEAP) has been introduced as a minimally invasive alternative treatment for patients with BPH. El-Husseiny and Buchholz (El-Husseiny and Buchholz, 2011) used dehydrated ethanol in a concentration of 95% to 98%, which was injected transurethrally by means of the Postajet Ethanol Injection System using a rigid cystoscope. They reported that there was sufficient response in 73% of their patients, while the remaining 27% showed an insufficient response and needed alternative treatment. Microwave thermotherapy is another minimally invasive therapy for BPH. It can either be performed perurethrally (TUMT) or transperineally. Bartolleti and colleagues (Bartolleti et al., 2008) evaluated the tolerability and safety of a newly designed probe for trans-perineal microwave thermoablation (TPMT) of the prostate in patients with BPH, and the in vivo microwave effects on prostatic tissue using local anesthesia. They reported that no adverse events from TPMT treatment were noted. In particular, no patients reported local, pelvic, or abdominal pain during the procedure or subsequent alterations of defecation rhythm, ano-rectal/intestinal problems, or hematuria. No differences in quality of life or in sexual function were reported. Use of radiofrequency for the treatment of BPH has evolved considerably in the recent years with introduction of newer generation of transurethral needle ablation (TUNA) devices. In the reported work by Zlotta and colleagues (Zlotta et al., 2003) patients were treated using the TUNA II or TUNA III catheters under local anesthesia only without general or spinal anesthesia. The authors reported that TUNA is effective and provides good long-term clinical improvement at 5-year follow-up. TUNA treatment stands the test of time at 5-year follow-up with low and acceptable failure rates. More than 75% of the patients do not need additional treatment for BPH on the long run.

### **5. Interventional stone treatment**

#### **5.1 Extracorporeal shock wave lithotripsy**

It was the struggle with urinary tract stones that shaped urology as a separate medical specialty. With the advancement in technology, the role of open surgery has decreased



considerably over decades with minimally invasive techniques now the treatment of choice for surgeons (Ather et al., 2001). The minimally invasive procedure of extracorporeal shock-wave lithotripsy (ESWL) was introduced in 1980s and since then, has revolutionized the management of urolithiasis providing virtually ideal outcomes. After extensive trials in vivo and on animal models, its first human trial was carried out in 1980 and its success led to more hope for management of urolithiasis. It is the most commonly undertaken procedure to treat renal stones with a 90% success rate (Ather et al., 2004).

### 5.1.1 Anesthetic techniques

The entry of shockwaves into the body through water is the most painful part of the procedure, necessitating analgesia. If the power of lithotripter is reduced, the procedure can be conducted without anesthesia but it results in a higher incidence of re-treatments (D'Addessi et al., 2008). For that reason, ESWL is carried out under general anesthesia, epidural anesthesia and spinal anesthesia (Rickford et al., 1988). Initially the procedure was mainly carried out under general anesthesia but with improvement in technology, reports of ESWL with local anesthesia were shown (Madbouly et al., 2011). General anesthesia though faster and more reliable results in more post-operative complications like nausea, vomiting and sore throat (Rickford et al., 1988). A downside of spinal anaesthesia is that a significant proportion of patients suffer from postspinal headache (Rickford et al., 1988). Regional and local anesthesia has obvious advantages of having a conscious patient that can assist in the procedure (Rickford et al., 1988). Hypotension during placement in hoist is observed with both general and regional anesthesia (Rickford et al., 1988). A very recent randomized trial tested the efficacy of sub-cutaneous local versus intramuscular opioid sedation and found that the former alone was effective (Madbouly et al., 2011). A eutectic mixture of local anesthetics has been suggested to induce analgesia during ESWL, with clinical use in cases where intravenous analgesia is contraindicated (Bierkens et al., 1991; Keller and Elliot, 1994). Successful experience with local anesthesia for lithotripsy has been reported multiple times (Loening et al., 1987; Keller and Elliot, 1994).

Local anesthesia in carefully selected patients' works well for stones that are moderate size and are not too hard in consistency (Aeikens et al., 1986). Investigators have made the comparison between different techniques for local anesthesia. One such comparison was made between eutectic mixture of local anesthetics and dimethyl sulfoxide with lidocaine (lignocaine), with the latter significantly proven to be better (Demir et al., 2007; Kumar et al., 2010). On the other hand, there have been reports showing that local anesthesia does not decrease the requirement of intravenous analgesia in patients with renal and ureteral stones when using second-generation lithotripter (Turker and Ozgen et al., 2000).

### 5.2 Percutaneous nephrostolithotomy

Larger renal stone (> 20mm) and those in the lower pole calyx even of 15mm size are preferentially now treated by percutaneous nephrostolithotomy (PCNL). PCNL is typically performed in prone position under general anesthesia. Anesthesia during PCNL for staghorn and large renal stones is a challenge because of the possibility of fluid absorption (Rozentsveig et al., 2007) dilutional anemia, hypothermia, or significant blood loss. There have been few series of PCNL under spinal anesthesia (Mahrabi et al., 2010). In a series of 160 consecutive patients the authors have reported that PCNL under spinal anesthesia is

safe and effective for performing PCNL and is a good alternative for general anesthesia in adult patients (Mahrabi et al., 2010). The other complicating factor particularly in obese patients is tube displacement, nerve compression, etc during prone positioning following intubation. Wu and colleagues (Wu et al., 2009) described a technique of awake intubation and prone patient self-positioning before PCNL. They reported that the technique of awake intubation with prone patient self-positioning can be helpful for positioning morbidly obese patients before PCNL and has been safe and effective in properly selected patients. Obesity or prone positioning should not impact efficacy of PCNL and morbidity minimized provided that surgical and anesthesia teams understand and safeguard against potential complications (Wu et al., 2009). In another interesting work Aravantinos and colleagues (Aravantinos et al., 2009) used multimodal anesthesia in order to avoid complications related to general anesthesia. The multimodal analgesic regime used included paracetamol, a COX (2) inhibitor, epidural morphine, and infiltration of the surgical field with local anesthetics (Aravantinos et al., 2009). The use of our multimodal analgesia regime is a well-tolerated and safe alternative to general or regional anesthesia for patients undergoing PCNL.

Aravantinos and colleagues (Aravantinos et al., 2007) performed PCNL under local anesthesia in twenty-four patients with unilateral renal obstruction due to pelvic stones  $\geq 2.0$  cm. A 16 Ch percutaneous nephrostomy was placed to decompress the obstructed kidney under local anesthesia for 1 week prior to definitive procedure. The tract and the renal parenchyma was infiltrated with lignocaine, dilatation of the nephrostomy tract was performed. Subsequently, PCNL was done using a 24-Fr rigid nephroscope and a ballistic lithotripter. All patients were pre medicated with pethidine HCl intramuscularly 30 min before the beginning of both stages. Diazepam was given (0.1mg/kg orally) to patients before the second stage. Pain scores were collected using 10-cm linear visual analogue scale (VAS) after the completion of both procedures. They noted that the mean VAS score was 38 mm (range: 17-60 mm) for the first stage and 36 mm (13-69 mm) for the second stage. The mean operative time, including both stages, was 127 min (85-155 min). Authors reported no anesthesia-related complications. In another interesting work (Chen et al., 2011) described the feasibility of minimally invasive PCNL under peritubal anesthesia. They performed ureteral catheterization under 1% Lidocaine surface analgesia with pethidine pre medication. The tract was infiltrated with 1% Lidocaine using spinal needle from renal parenchyma, capsule to skin surface. The authors reported that the procedure is well-tolerated and feasible alternative to general and epidural anesthesia.

## 6. Conclusion

The impetus for urological procedures under local anesthesia has been to maximize anesthetic and postoperative resources by increasing patient turnover in the operating room and discharging patients' home more efficiently on the same day. This is of particular importance due to increasing burden on the health care structure. In addition, patients with significant co morbidities, with relative or absolute contra indication to general or major regional anesthesia can also undergo procedures safely. The use of local anesthesia has continued to expand the ability of urologists to perform a variety of procedures in a safer fashion, particularly in high-risk patients. Additional advantages of local anesthesia include the avoidance of postoperative nausea and vomiting with early

resumption of a normal diet, an enhanced ability to perform the surgical procedure on an outpatient basis with early discharge, a lower risk of intra operative complications (cardiac and pulmonary), the ability to communicate with the patient during the procedure, and an enhanced perception that the procedure will not be associated with a prolonged postoperative recovery period.

## 7. References

- Aeikens, B., Fritz, KW. & Hoehne, E. (1986). Initial experience with local anesthesia in extracorporeal shock wave lithotripsy, *Urol Int*. Vol.41(No. 4): 246-7
- Al-Hunayan, A., Al-Awadi, K., Al-Khayyat, A. & Abdulhalim, H. (2008). A pilot study of transperineal urethrosphincteric block for visual internal urethrotomy in patients with anterior urethral strictures, *J Endourol* Vol.22(No.5): 1017-20.
- Altinova, S. & Turkan, S. (2007). Optical urethrotomy using topical anesthesia, *Int Urol Nephrol* Vol.39(No.2): 511-2.
- Amory, JK., Jessen, JW., Muller, C. & Berger, RE. (2010). Vasectomy by epithelial curettage without suture or cautery: a pilot study in humans, *Asian J Androl* Vol.12(No. 3): 315-21
- Aravantinos, E., Kalogeras, N., Stamatiou, G., Theodorou, E., Moutzouris, G., Karatzas, A. & Melekos, M. (2009). Percutaneous nephrolithotomy under a multimodal analgesia regime, *J Endourol* Vol.23(No. 5): 853-6.
- Aravantinos E, Karatzas A, Gravas S, Tzortzis V. & Melekos M. (2007) Feasibility of percutaneous nephrolithotomy under assisted local anaesthesia: a prospective study on selected patients with upper urinary tract obstruction. *Eur Urol*. Vol. 51, (No.1):pp.224-7
- Ather, MH., Faruqui, N., Akhtar, S. & Sulaiman, MN. (2004). Is an excretory urogram mandatory in patients with small to medium-sized renal and ureteric stones treated by extra corporeal shock wave lithotripsy? *BMC Med* Vol.28(No. 2):15.
- Ather, MH., Paryani, J., Memon, A. & Sulaiman, MN. (2001). A 10-year experience of managing ureteric calculi: changing trends towards endourological intervention-- is there a role for open surgery? *BJU Int* Vol.88(No. 3): 173-7
- Ather, MH., Zehri, AA., Soomro, K. & Nazir, I. (2009). The safety and efficacy of optical urethrotomy using a spongiosum block with sedation: a comparative nonrandomized study, *J Urol* Vol.181(No. 5): 2134-8.
- Bartoletti, R., Cai, T., Tinacci, G., Longo, I., Ricci, A., Massaro, MP., Tosoratti, N., Zini, E. & Pinzi, N. (2008). Transperineal microwave thermoablation in patients with obstructive benign prostatic hyperplasia: a phase I clinical study with a new mini-choked microwave applicator, *J Endourol* Vol.22(No. 7): 1509-17.
- Beiko, DT., Kim, D. & Morales, A. (2003). Aspiration and sclerotherapy versus hydrocelectomy for treatment of hydroceles, *Urology* Vol.61(No. 4): 708-12.
- Bierkens, AF., Maes, RM., Hendriks, JM., Erdos, AF., de Vries, JD. & Debruyne, FM. (1991). The use of local anesthesia in second generation extracorporeal shock wave lithotripsy: eutectic mixture of local anesthetics, *J Urol* Vol.146(No. 2): 287-9.

- Birch, BR., Ratan, P., Morley, R., Cumming, J., Smart, CJ. & Jenkins, JD. (1994). Flexible cystoscopy in men: is topical anaesthesia with lignocaine gel worthwhile? *Br J Urol* Vol.73(No. 2): 155-9.
- Burden, RJ., O'Kelly, SW., Sutton, D. & Cumming, J. (1997). Spermatic-cord block improves analgesia for day-case testicular surgery, *Br J Urol* Vol.80(No. 3):472-5.
- Cayan, S., Shavakhabov, S. & Kadioğlu, A. (2009). Treatment of palpable varicocele in infertile men: a meta-analysis to define the best technique, *J Androl* Vol.30(No. 1): 33-40.
- Chen, Y., Zhou, Z., Sun, W., Zhao, T. & Wang, H. (2011). Minimally invasive percutaneous nephrolithotomy under peritubal local infiltration anesthesia, *World J Urol* DOI 10.1007/s00345-0011-0730-z
- Choong, S., Whitfield, HN., Meganathan, V., Nathan, MS., Razack, A. & Gleeson, M. (1997). A prospective, randomized, double-blind study comparing lignocaine gel and plain lubricating gel in relieving pain during flexible cystoscopy, *Br J Urol* Vol.80(No. 1): 69-71.
- Clark, KR. & Higgs, MJ. (1990). Urinary infection following out-patient flexible cystoscopy, *Br J Urol* Vol.66(No. 5): 503-5.
- D'Addessi, A., Bongiovanni, L., Sasso, F., Gulino, G., Falabella, R. & Bassi, P. (2008). Extracorporeal shockwave lithotripsy in pediatrics, *J Endourol* Vol.22(No. 1): 1-12.
- Demir, E., Kilciler, M., Bedir, S., Erten, K. & Ozgok, Y. (2007). Comparing two local anesthesia techniques for extracorporeal shock wave lithotripsy, *Urology* Vol.69(No. 4): 625-8.
- Denholm, SW., Conn, IG., Newsam, JE. & Chisholm, GD. (1990). Morbidity Following Cystoscopy: Comparison of Flexible and Rigid Techniques, *Br J Urol* Vol.66(No. 2): 152-4
- Desmond, AD., Arnold, AJ. & Hastie, KJ. (1998). Subcapsular orchiectomy under local anesthesia. Technique, results and implications, *Br J Urol* Vol.61(No. 2): 143-5.
- El Hussainey, T. & Buchholz, N. (2011). Transurethral ethanol ablation of the prostate for symptomatic benign prostatic hyperplasia: long-term follow-up, *J Endourol* Vol.25(No. 3): 477-80
- Fahmy, I., Kamal, A., Aboulghar, M., Mansour, R., Serour, GI. & Shamloul, R. (2004). Percutaneous aspiration biopsy using an intravenous catheter for testicular sperm retrieval in patients with obstructive azoospermia, *Reprod Biomed Online* Vol.9(No. 1): 102-5.
- Fenlon, HM., Bell, TV., Ahari, HK. & Hussain, S. (1997). Virtual cystoscopy: early clinical experience, *Radiology* Vol.205(No. 1): 272-5..
- Goel, R. & Aron, M. (2003). Cooled lignocaine gel: does it reduce urethral discomfort during instillation? *Int Urol Nephrol* Vol.35(No. 3): 375-7.
- Grossman, HB. (2007). Improving the management of bladder cancer with fluorescence cystoscopy, *J Environ Pathol Toxicol Oncol* Vol.26(No. 2): 143-7.
- Herr, HW. & Donat, SM. (2008). A comparison of white-light cystoscopy and narrow-band imaging cystoscopy to detect bladder tumour recurrences, *BJU Int* Vol.102(No. 9): 1111-4.



- Ho, KJ., Thompson, TJ., O'Brien, A., Young, MR. & McCleane, G. (2003). Lignocaine gel: does it cause urethral pain rather than prevent it? *Eur Urol* Vol.43(No. 2): 194-6.
- Hong, SK., Ahn, C. & Kim, HH. (2001). The value of cystoscopy as an initial diagnostic modality for asymptomatic microscopic hematuria, *J Korean Med Sci* Vol.16(No. 3): 309-12.
- Hong, JY., Yang, SC., Ahn, S. & Kil HK. (2011). Preoperative comorbidities and relationship of comorbidities with postoperative complications in patients undergoing transurethral prostate resection, *J Urol* Vol.185(No. 4): 1374-8.
- Hosseini, SJ., Kaviani, A. & Vazirnia, AR. (2008). Internal urethrotomy combined with antegrade flexible cystoscopy for management of obliterative urethral stricture, *Urol J* Vol.5(No. 3): 184-7.
- Hsu, GL., Hsieh, CH., Wen, HS., Chen, SC., Chen, YC., Liu, LJ., Mok, MS. & Wu, CH. (2004). Outpatient penile implantation with the patient under a novel method of crural block, *Int J Androl* Vol.27(No. 3): 147-51.
- Hsu, GL., Hsieh, CH., Chen, HS., Ling, PY., Wen, HS., Liu, LJ., Chen, CW. & Chua, C. (2007). The advancement of pure local anesthesia for penile surgeries: can an outpatient basis be sustainable? *J Androl* Vol.28(No. 1): 200-5.
- Hsu, GL., Hsieh, CH., Wen, HS., Hsieh, JT. & Chiang, HS. (2003). Outpatient surgery for penile venous patch with the patient under local anesthesia *J Androl* Vol.24(No. 1): 35-9.
- Hsu, GL., Ling, PY., Hsieh, CH., Wang, CJ., Chen, CW., Wen, HS., Huang, HM., Einhorn, EF. & Tseng GF. (2005). Outpatient varicocelectomy performed under local anesthesia, *Asian J Androl* Vol.7(No. 4): 439-44
- Jichlinski, P. (2003). New diagnostic strategies in the detection and staging of bladder cancer, *Curr Opin Urol* Vol.13(No. 5): 351-5.
- Kamal, BA. (2001). The use of the diode laser for treating urethral strictures, *BJU Int* Vol.87(No. 9): 831-3.
- Kara, C., Resorlu, B., Cicekbilek, I. & Unsal, A. (2009). Transurethral cystolithotripsy with holmium laser under local anesthesia in selected patients, *Urology* Vol.74(No. 5): 1000-3.
- Keller, RJ. & Elliott, C. (1994). Eutectic mixture of local anesthetic cream--topical anesthesia for extracorporeal shock wave lithotripsy, *CRNA* Vol.5(No. 4): 136-8.
- Khan, MA., Beyzade, B., Tau, W., Viridi, JS. & Potluri, BS. (2002). Effect of the rate of delivery of lignocaine gel on patient discomfort perception prior to performing flexible cystoscopy, *Urol Int* Vol.68(No. 3): 164-7
- Khaniya, S., Agrawal, CS., Koirala, R., Regmi, R. & Adhikary, S. Comparison of aspiration-sclerotherapy with hydrocelectomy in the management of hydrocele: a prospective randomized study, *Int J Surg* Vol.7(No. 4): 392-5.
- Kiesling, VJ Jr., Schroeder, DE., Pauljev, P. & Hull, J. (1984). Spermatic cord block and manual reduction: primary treatment for spermatic cord torsion, *J Urol* Vol.132(No. 5): 921-3.
- Kumar, A., Mohanty, NK., Jain, M., Prakash, S. & Arora, RP. (2010). A prospective randomized comparison between early (<48 hours of onset of colicky pain)




- versus delayed shockwave lithotripsy for symptomatic upper ureteral calculi: a single center experience. *J Endourol* Vol.24(No. 12): 2059-66.
- Kreder, KJ., Stack, R., Thrasher, JB. & Donatucci, CF. (1993). Direct vision internal urethrotomy using topical anesthesia, *Urology* 42(No. 5): 548-50.
- Labrecque, M., Dufresne, C., Barone, MA. & St-Hilaire, K. (2004). Vasectomy surgical techniques: a systematic review, *BMC Medicine* Vol.2: 21
- Loening, S., Kramolowsky, EV. & Willoughby, B. (1987). Use of local anesthesia for extracorporeal shock wave lithotripsy, *J Urol* Vol.137(No. 4): 626-8.
- Madbouly, K., Alshahrani, S., Al-Omar, T., Matrafi, HA. & Mansi, M. (2011). Efficacy of local subcutaneous anesthesia versus intramuscular opioid sedation in extracorporeal shockwave lithotripsy: a randomized study, *J Endourol* Vol.25(No. 5): 845-9.
- Magoha, GA. (1998). Local infiltration and spermatic cord block for inguinal, scrotal and testicular surgery, *East Afr Med J* Vol.75 (No. 10): 579-81.
- Marchal Escalona, C., Chicharro Molero, JA., Martín Morales, A., Del Rosal Samaniego, JM., Díaz Ramírez, F., Ruiz Domínguez, JL. & Burgos Rodríguez, R. (1993). Local anesthesia in the surgical management of hydrocele and cysts of the spermatic cord, *Actas Urol Esp* Vol.17(No. 1): 68-72.
- Mazdak, H., Meshki, I. & Ghassami, F. (2007). Effect of mitomycin C on anterior urethral stricture recurrence after internal urethrotomy, *Eur Urol* Vol.51(No. 4): 1089-92;
- Mehrabi, S. & Karimzadeh Shirazi, K. (2010). Results and complications of spinal anesthesia in percutaneous nephrolithotomy, *Urol J* Vol.7(No. 1): 22-5.
- Merkle, EM., Wunderlich, A., Aschoff, AJ., Rilinger, N., Görich, J., Bachor, R., Gottfried, HW., Sokiranski, R., Fleiter, TR. & Brambs, HJ. (1998). Virtual cystoscopy based on helical CT scan datasets: perspectives and limitations, *Br J Radiol* Vol.71(No. 843): 262-7.
- Munks, DG., Alli, MO. & Goad, EH. (2010). Optical urethrotomy under local anaesthesia is a feasible option in urethral stricture disease, *Trop Doct* Vol.40(No. 1): 31-2.
- Navon, JD., Soliman, H., Khonsari, F. & Ahlering, T. (1997). Screening cystoscopy and survival of spinal cord injured patients with squamous cell cancer of the bladder, *J Urol* Vol.157(No. 6): 2109-11.
- Naudé, AM. & Heyns, CF. (2005). What is the place of internal urethrotomy in the treatment of urethral stricture disease? *Nat Clin Pract Urol* Vol.2(No. 11): 538-45.
- Park, H., Park, M. & Park, T. (1998). Two-year experience with ureteral stones: extracorporeal shockwave lithotripsy v ureteroscopic manipulation, *J Endourol* Vol.12(No. 6): 501-4
- Rickford, JK., Speedy, HM., Tytler, JA. & Lim M. (1988). Comparative evaluation of general, epidural and spinal anaesthesia for extracorporeal shockwave lithotripsy, *Ann R Coll Surg Engl* Vol.70(No. 2): 69-73.
- Roosen, JU., Klarskov, OP. & Mogensen, P. (2005). Subcapsular versus total orchiectomy in the treatment of advanced prostate cancer: a randomized trial, *Scand J Urol Nephrol* Vol.39(No. 6): 464-7.

- Quintero, RA., Johnson, MP., Romero, R., Smith, C., Arias, F., Guevara-Zuloaga, F., Cotton, DB. & Evans, MI. (1995). In-utero percutaneous cystoscopy in the management of fetal lower obstructive uropathy, *Lancet* Vol.346(No. 8974): 537-40.
- Quintero, RA., Hume, R., Smith, C., Johnson, MP., Cotton, DB., Romero, R. & Evans, MI. (1995). Percutaneous fetal cystoscopy and endoscopic fulguration of posterior urethral valves, *Am J Obstet Gynecol* Vol.172(No. 1 Pt 1): 206-9.
- Rozentsveig, V., Neulander, EZ., Roussabrov, E., Schwartz, A., Lismer, L., Gurevich, B., Klein, Y. & Weksler, N. (2007). Anesthetic considerations during percutaneous nephrolithotomy *J Clin Anesth* Vol.19(No. 5): 351-5.
- Santucci, R. & Eisenberg, L. (2010). Urethrotomy has a much lower success rate than previously reported, *J Urol* Vol.183(No. 5): 1859-62.
- Schmidbauer, J., Witjes, F., Schmeller, N., Donat, R., Susani, M., Marberger, M. & Hexvix PCB301/01 Study Group. (2004). Improved detection of urothelial carcinoma in situ with hexaminolevulinate fluorescence cystoscopy, *J Urol* Vol.171(No. 1): 135-8
- Shih, G., Njoya, M., Lessard, M. & Labrecque, M. (2010). Minimizing pain during vasectomy: the mini-needle anesthetic technique, *J Urol* Vol.183(No. 5): 1959-63.
- Sokal, DC. & Labrecque, M. (2009). Effectiveness of vasectomy techniques. *Urol Clin North Am* Vol.36(No. 3): 317-29.
- Soomro, KQ., Nasir, AR., Ather, MH. (2011). Impact of patient's self-viewing of flexible cystoscopy on pain using a visual analog scale in a randomized controlled trial, *Urology* Vol. 77(No. 1): 21-3.
- Steenkamp, JW., Heyns, CF. & de Kock, ML. (1997). Internal urethrotomy versus dilation as treatment for male urethral strictures: a prospective, randomized comparison, *J Urol* Vol.157(No. 1): 98-101.
- Taylor, R., Eyres, R., Chalkiadis, GA. & Austin, S. (2003). Efficacy and safety of caudal injection of levobupivacaine, 0.25%, in children under 2 years of age undergoing inguinal hernia repair, circumcision or orchidopexy, *Paediatr Anaesth* Vol.13(No. 2): 114-21.
- Türker, AK. & Ozgen S. (2000). Local anesthesia for extracorporeal shock wave lithotripsy: a double-blind, prospective, randomized study, *Eur Urol* Vol.37(No. 3): 331-3.
- Tzortzis, V., Aravantinos, E., Karatzas, A., Mitsogiannis, IC., Moutzouris, G. & Melekos, MD. (2006). Percutaneous suprapubic cystolithotripsy under local anesthesia, *Urology* Vol.68(No. 1): 38-41.
- Watanabe, M., Nagai, A., Kusumi, N., Tsuboi, H., Nasu, Y. & Kumon, H. (2005). Minimal invasiveness and effectivity of subinguinal microscopic varicocelectomy: a comparative study with retroperitoneal high and laparoscopic approaches, *Int J Urol* Vol.12(No. 10): 892-8.
- Weinberg, GL. (2010). Treatment of local anesthetic systemic toxicity (LAST), *Reg Anesth Pain Med* Vol.35(No. 2): 188-93.
- Wolfe, JW. & Butterworth, JF. (2011). Local anesthetic systemic toxicity: update on mechanisms and treatment, *Curr Opin Anaesthesiol* [Epub ahead of print].
- Wu, SD., Yilmaz, M., Tamul, PC., Meeks, JJ. & Nadler, RB. (2009). Awake endotracheal intubation and prone patient self-positioning: anesthetic and positioning

- considerations during percutaneous nephrolithotomy in obese patients, *J Endourol* Vol.23(No. 10): 1599-602.
- Ye, G. & Rong-gui, Z. (2002). Optical urethrotomy for anterior urethral stricture under a new local anesthesia: intracorporeal spongiosum anesthesia, *Urology* Vol.60(No. 2): 245-7.
- Zehri, AA., Ather, MH. & Afshan, Q. (2009). Predictors of recurrence of urethral stricture disease following optical urethrotomy, *Int J Surg* Vol.7(No. 4): 361-4.
- Zlotta, AR., Giannakopoulos, X., Maehlum, O., Ostrem, T. & Schulman, CC. (2003). Long-term evaluation of transurethral needle ablation of the prostate (TUNA) for treatment of symptomatic benign prostatic hyperplasia: clinical outcome up to five years from three centers, *Eur Urol* Vol.44(No. 1): 89-93.

IntechOpen



## **Clinical Use of Local Anesthetics**

Edited by Dr. Asadolah Saadatniaki

ISBN 978-953-51-0430-8

Hard cover, 102 pages

**Publisher** InTech

**Published online** 23, March, 2012

**Published in print edition** March, 2012

Local anesthetics are being increasingly applied in different surgeries. Lower side effects of neuroaxial anesthesia, regional anesthesia, and field block, in comparison to general anesthesia (volatile and intravenous agents), are the main reasons why physicians prefer to conduct surgeries under local anesthesia, especially in outpatient and day care surgeries. It is important to emphasize the presence of an anesthesiologist, and vigilant monitoring of the hemodynamic parameters, in decreasing a patient's anxiety, exerting other modalities for analgesia and increasing the safety margin in many procedures.

### **How to reference**

In order to correctly reference this scholarly work, feel free to copy and paste the following:

M. Hammad Ather, Ammara Mushtaq and M. Nasir Sulaiman (2012). Urological Surgical Procedures Under Local Anesthesia, Clinical Use of Local Anesthetics, Dr. Asadolah Saadatniaki (Ed.), ISBN: 978-953-51-0430-8, InTech, Available from: <http://www.intechopen.com/books/clinical-use-of-local-anesthetics/common-urological-procedures-under-local-anesthesia>

**INTECH**  
open science | open minds

### **InTech Europe**

University Campus STeP Ri  
Slavka Krautzeka 83/A  
51000 Rijeka, Croatia  
Phone: +385 (51) 770 447  
Fax: +385 (51) 686 166  
[www.intechopen.com](http://www.intechopen.com)

### **InTech China**

Unit 405, Office Block, Hotel Equatorial Shanghai  
No.65, Yan An Road (West), Shanghai, 200040, China  
中国上海市延安西路65号上海国际贵都大饭店办公楼405单元  
Phone: +86-21-62489820  
Fax: +86-21-62489821

© 2012 The Author(s). Licensee IntechOpen. This is an open access article distributed under the terms of the [Creative Commons Attribution 3.0 License](https://creativecommons.org/licenses/by/3.0/), which permits unrestricted use, distribution, and reproduction in any medium, provided the original work is properly cited.

IntechOpen

IntechOpen