

# We are IntechOpen, the world's leading publisher of Open Access books Built by scientists, for scientists

6,900

Open access books available

185,000

International authors and editors

200M

Downloads

Our authors are among the

154

Countries delivered to

TOP 1%

most cited scientists

12.2%

Contributors from top 500 universities



WEB OF SCIENCE™

Selection of our books indexed in the Book Citation Index  
in Web of Science™ Core Collection (BKCI)

Interested in publishing with us?  
Contact [book.department@intechopen.com](mailto:book.department@intechopen.com)

Numbers displayed above are based on latest data collected.  
For more information visit [www.intechopen.com](http://www.intechopen.com)



# Local Anesthesia for Cosmetic Procedures

Dhepe V. Niteen

*Dermatosurgery Taskforce, IADVL, SkinCity, Post Graduate  
Institute of Dermatology and Lasers, Solapur, Maharashtra  
India*

## 1. Introduction

In recent years the number of cosmetic procedures is continuously increasing. Cosmetic procedure/surgery is an elective procedure. It is not an emergency. Hence not only final result but the overall comfort and satisfaction of the patient are equally important. Majority of the procedures are carried out under local anesthesia; so thorough knowledge of local anesthetic agents, types, techniques and their side effects becomes very much important for the aesthetic physicians.

### 1.1 Learning objectives

At the end of reading of this chapter, reader should be able to understand the scope of various types of local anesthesia in his aesthetic practice, able to choose appropriate local anesthesia according to indication, able to do modification in various techniques according to the demand of situation to give pleasant and comfortable experience to patient during the aesthetic procedure while keeping in mind the possible adverse effects of the anesthesia.

### 1.2 Mechanism of local anesthetic activity

Studies have shown that local anesthetics inhibit depolarization of the nerve by interfering with the influx of  $\text{Na}^+$  ions. Although the exact mechanism of local anesthetic action is not known, several theories postulate that anesthetics diffuse across the neural membrane and somehow alter the activity of the  $\text{Na}^+$  channel. Local anesthetics are thought to stabilize the membrane at resting potential, increase the threshold for electrical excitation, and reduce the propagation of an excitatory impulse, thereby blocking nerve conduction.<sup>1</sup>

The sensation of pain is carried via small unmyelinated nerve fibers (C fibers). These fibers are more sensitive to the actions of local anesthetics as compared to larger nerve fibers that carry other sensations. Consequently patients may be able to feel sensations such as pressure and vibration, while being insensitive to pain.<sup>2</sup>

### 1.3 Classification of local anesthetics

Local anesthetics possess a basic chemical structure that gives it amphipathic characteristics. Its structure can be divided into three distinct parts: an aromatic portion (lipophilic),

intermediate chain, and amine group (hydrophilic). The intermediate chain connects the aromatic group to the amine group. It is also the basis of local anesthetic classification as either esters or amides (Table 1).

Ester anesthetics are metabolized via the plasma enzyme, pseudocholinesterase. Hydrolysis is rapid and the by-products are excreted in the urine.

Amide anesthetics are metabolized primarily by the liver. They should be used with caution in patients with liver disease.<sup>3</sup>

For detailed discussion on pharmacology of local anesthetic agents, kindly refer to the related chapter in this book.

Group	Generic name	Trade name	Onset of anesthesia	Duration of anesthesia	Available Concentration (%)
Amides	Lidocaine	Xylocaine	Rapid	Moderate	0.5, 1.0, 2.0
	Mepivacaine	Carbocaine	Rapid	Moderate	1.0, 2.0
	Bupivacaine	Marcaine	Slow	Long	0.25, 0.5, 0.75
	Etidocaine	Duranest	Rapid	Long	0.5, 1.0
Esters	Procaine	Novacaine	Rapid	Short	0.5, 1.0, 2.0
	Tetracaine	Pontocaine	Slow	Long	0.1,0.25

Table 1. Common Local Anesthetics Used in Dermatology<sup>2, 4</sup>

1.4 Combination of Local anesthetics and adrenaline<sup>5, 6</sup>

Many times local anesthetic is administered along with vasoconstrictor like adrenaline with beneficial results. This combination offers following advantages:

- 1. Decrease anesthetic absorption and systemic toxicity with improved efficacy and smaller amounts required.
- 2. Prolonged duration of action (almost doubled), especially with lignocaine and procaine
- 3. Less bleeding at operative site, especially useful on vascular areas with better visualization of operative field.

Adrenaline may potentially induce adverse effects. Therefore its use must be carefully considered in patients with heart disease and those patients concomitantly taking  $\beta$ -blockers.<sup>7</sup>

	Symptoms	Treatment
	Central nervous system	
Lidocaine	Drowsiness, circumoral numbness, tingling of tongue, metallic taste, diplopia, blurred vision, tinnitus, slurred speech, muscle twitching, shivering, seizure, respiratory arrest	Intravenous diazepam, oxygen
Epinephrine	Nervousness, tremors, headaches	
	Cardiovascular system	
Lidocaine	Progressive myocardial depression, prolonged conduction time, arteriovenous block, bradycardia vasomotor depression, hypotension, hypoxia, acidosis	Cardiopulmonary, resuscitation, oxygen, vasopressors, intravenous fluids
Epinephrine	Tachycardia, palpitations, chest pain, hypertension	Vasodilators (hydralazine, clonidine, sublingual nifedipine)
	Allergic	
Lidocaine	Urticaria, angioedema, anaphylaxis	Antihistamines, subcutaneous epinephrine, oxygen, steroids
	Psychogenic	
		Cold compresses on forehead and neck, Trendelenburg position, fan patient, ammonia ampule
	Vasovagal response	

Table 2. Adverse Effects of Lidocaine with Epinephrine<sup>8</sup>

2. Types of local anesthesia for cosmetic procedures

2.1 Topical anesthesia<sup>9</sup>

Topical anesthesia is the surface application of a LA to the skin or mucous membrane by means of a spray, spreading of an ointment,). Lidocaine 2% jelly, EMLA cream, or iontophoresis of lidocaine can allow one to perform simple procedures such as shave biopsies, electro-cauterization of epidermal growths or superficial laser surgery. Topical

anesthetics can also provide surface anesthesia to permit painless insertion of a needle, especially in children, and on painful areas such as the nose, lips and genitalia.<sup>10</sup>

### 2.1.1 Mucosal agents

Topical anesthetics agents are useful on mucosal surfaces include cocaine 4%, benzocaine 5-20%, tetracaine 0.5% and lidocaine 2-5% (jelly, ointment), lidocaine 10% aerosol etc.

### 2.1.2 Cutaneous agents

Creams: for producing an anesthesia on intact skin, creams of lidocaine (30%) or EMLA – eutectic mixture of local anesthetics have to be applied for variable period of time (30min to 2 hours) according to the composition of the EMLA. This EMLA has to be applied under occlusion for its optimum effect. The list of commonly available topical anesthetic is given in Table 3.

Special delivery techniques for topical anesthesia

- Iontophoresis<sup>11</sup>

The introduction of various ions into the skin through the use of electricity has been increasingly used to provide pain relief in outpatient procedures. It uses an electric current to overcome some of the barriers of the skin and assist the penetration through the movement of ions into the skin via sweat glands, hair follicles and sebaceous glands.

Iontophoresis can be used to deliver chemicals to both superficial and deeper layers of the skin.

Advantages are

1. It avoids pain associated with injections.
2. It prevents the variation in absorption seen with oral medications
3. It bypasses first-pass elimination
4. Drugs with shorter half life can be delivered directly to the tissue

Disadvantages are

1. Discomfort and erythema at the site of iontophoresis secondary to pH changes
2. There is also potential of skin irritation and burn

- Laser assisted delivery of Topical anesthetics:

A research in 2003 indicates that a single pass of the Er:YAG laser (wave length 2940 nm) enhanced the absorption and penetration of lidocaine by disrupting the stratum corneum.<sup>12</sup>

Although this technique may not be adequate for invasive procedures, it may minimize pain and discomfort for more superficial cutaneous procedure, such as hypodermic needle insertion. This is a well known fact that reapplication of topical anesthetic after first pass of ablative lasers produce quicker and deeper anesthesia.

Interest in laser assisted drug delivery was reemerged after advent of fractional lasers. Narrow but deep vertical channels of ablation into skin created by fractional CO<sub>2</sub> laser were used to successfully deliver a drug, methyl 5-aminolevulinate (MAL) to a uniform depth into skin.<sup>13</sup> The absorption was uniform and full thickness indicating drug delivery from lateral walls of the tunnel. Currently trials are under progress to use this method to deliver local anesthetic agent to skin.

Table 3. Drugs used for topical anesthesia<sup>14</sup>

Anesthetic	Ingredients	Vehicle	Application Dose	Occlusion required	FDA approved	Advantages
Betacain-LA	Lidocaine Prilocain Dibucaine	Vaseline ointment	60-90	No	No	Anecdotal reports of rapid onset
LMX	4% Lidocaine	Liposomal	60	No	Yes	Liposomal delivery long duration of action
LMX 5	5% Lidocaine	Liposomal	30	No	Yes	Rapid onset of action
EMLA	2.5% Lidocaine 2.5% Prilocain	Oil in water	60	Yes	Yes	Proven efficacy and safety profile
Tretracaine gel	4% Tretracaine Gel	Lecithin gel	60-90	Yes	No	Anecdotal reports of rapid onset
Amethocaine	4% Tretracaine		40-60	Yes	No	Rapid onset prolonged effect
Topicaine	4% Lidocaine	Microemulsion	30-60	Yes	Yes	Rapid onset Cost effective
S-Caine	2.5% Lidocaine 2.5% Tretracaine	Oil in water	30-60	No	Phase III clinical trails	Unique delivery system

- **Needle-less Dermajet**  
This is a needleless pressure injection syringe for the intradermal infiltration of drugs in a soluble state. This technique achieves almost painless tissue infiltration with a high velocity microspray in single or multiple doses of 0.1 cc. to a depth of 2 to 5 mm. without actual contact with the site of injection. A fine jet emitted under great pressure punctures the tissue without coring, with a minimum amount of trauma, raising instantaneously a well-defined pinpoint wheal. Besides giving local anesthesia this mode of drug delivery is useful in intralesional steroid injection in case of keloid and hypertrophic scar, in mass vaccinations<sup>15</sup> etc.
- **Microporation**  
Iontophoresis applies a small low voltage (typically 10 V or less) continuous constant current (typically 0.5 mA/cm<sup>2</sup> or less) to push a charged drug into skin or other tissue. In contrast, electroporation applies a high voltage (typically, >100 V) pulse for a very short ( $\mu$ s-ms) duration to permeabilize the skin.<sup>16</sup> Low frequency ultrasound is also used as 'sonoporation'.

## 2.2 Infiltration anesthesia<sup>9</sup>

This is the most commonly used method of anesthetizing the skin. It consists of injecting the anesthetic agent into the tissue to be cut. The injection may be intradermal, when the anesthesia is almost immediate, or into the subcutaneous tissue, when the anesthesia is usually delayed and has a shorter duration. However, an intradermal injection is more painful. The pain of a LA injection into the skin can be reduced by adding freshly prepared sodium bicarbonate (8.4%) solution to the LA solution in a 1:10 dilution. Local pain can also be reduced by injecting the drug slowly, while pinching the neighboring skin to distract the patient. The infiltration may distort the operative site; this can be minimized by gentle massage after the injection.

## 2.3 Field blocks<sup>9</sup>

A field or ring block is a variation of infiltration anesthesia. The LA agent is placed around the operative site, anesthetizing the nerve fibers leaving from the area. A ring block is useful when direct needle entry into a lesion such as a cyst is not desirable. The LA has to be placed in both superficial and deep planes. Start injecting from proximal to distal end. This also limits the amount of LA needed to anesthetize the operative site. This is a particular advantage when a large area has to be anesthetized.

## 2.4 Peripheral nerve blocks

A nerve block involves placing the local anesthetic solution in a specific location at or around the main nerve trunk that will effectively depolarize that nerve and obtund sensation in the area of sensory distribution of that particular nerve. In dermatological surgery, the commonly employed nerve blocks are for the digits and for the central face, because both areas are painful to anesthetize using local infiltration. Peripheral nerve blocks are difficult to perform and complications include laceration of the nerve, intravascular injection of LA and hematoma formation may occur.



Advantages of nerve blocks include the fact that a single accurately placed injection can obtund large areas of sensation without tissue distortion at operative site.

Disadvantages of peripheral nerve blocks include the sensation of numbness in areas other than the operative site and the lack of hemostasis at the operative site from the vasoconstrictor component of the local anesthetic injection.

Since many nerves are accompanied by corresponding veins and arteries, pre-injection aspiration should always be performed to prevent intra vascular injection. Use of local anesthetics with vasoconstrictors will prolong anesthesia.

### 3. Sensory nerves and respective dermatomes of face and their block

#### 3.1 Fig 1a and 1b Sensory innervations of face and neck area

##### Trigeminal nerve

Often referred to as “the great sensory nerve of the head and neck”, the trigeminal nerve is named for its three major sensory branches. The ophthalmic nerve (V1), maxillary nerve (V2), and mandibular nerve (V3) are literally ‘three twins’ (trigeminal) carrying sensory information of light touch, temperature, pain, and proprioception from the face and scalp to brainstem. The main branches of the trigeminal nerve supply sensation to the well defined and consistent facial areas.

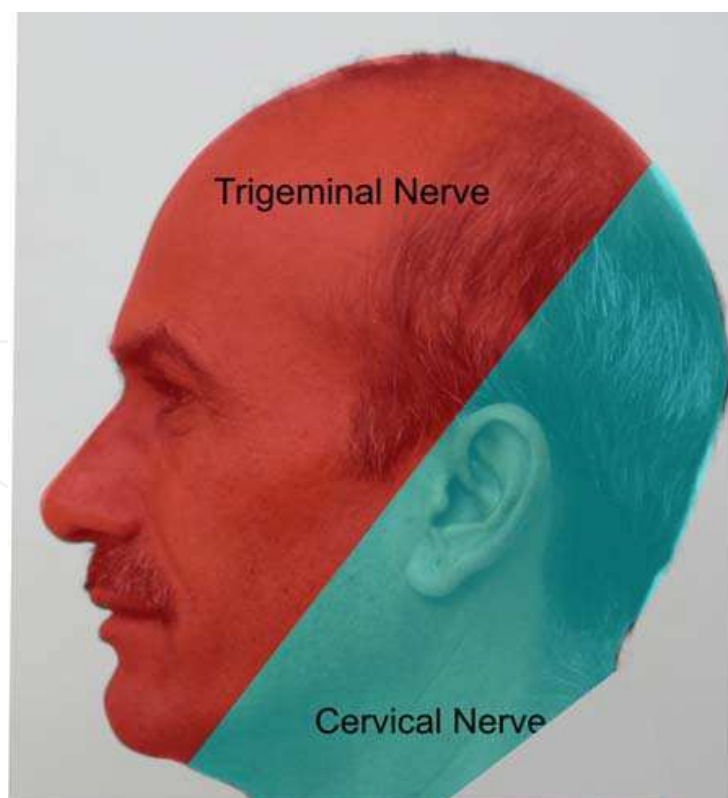


Fig. 1a.



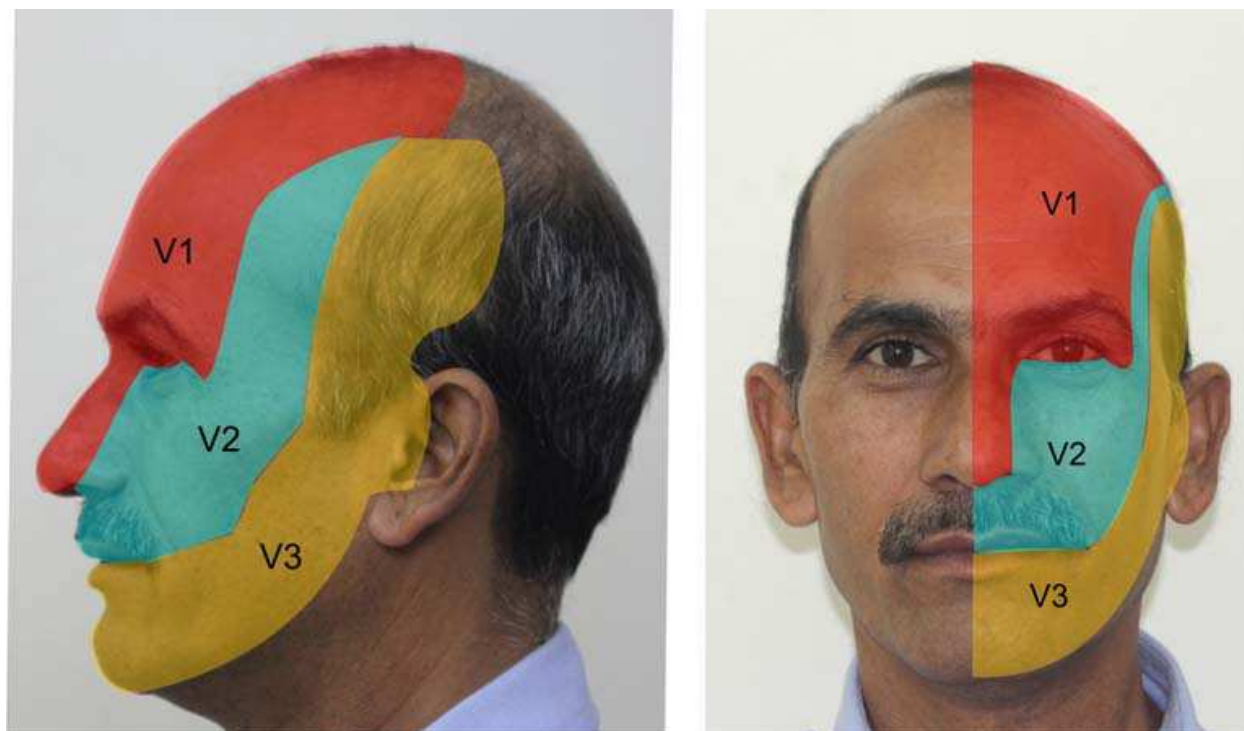


Fig. 1b.

### 3.2 Anatomic arrangement of facial foramina

Successful nerve block anesthesia is largely dependent upon knowing the position of the nerve foramina. The surgeon can take advantage of the alignment of the major facial foramina as they relate to a vertical line through the mid pupillary line with the eye in the primary position of natural forward gaze.

### 3.3 Common nerve blocks<sup>17</sup>

#### 1. Supraorbital nerve

The supraorbital nerve exits through a notch (in some case a foramen) on the superior orbital rim approximately 27 mm lateral to the glabellar midline. This supraorbital notch is readily palpable in most patients. After existing the notch or foramen, the nerve traverses the corrugator supercilii muscles and branches into a medial and lateral portion. The lateral branches supply the lateral forehead and the medial branches supply the scalp.

#### 2. Supratrochlear nerve and Supraorbital

The supratrochlear nerve exits a foramen approximately 17 mm from the glabellar midline and supplies sensation to the middle portion of the forehead. The infratrochlear nerve exits a foramen below the trochlea and provided sensation to the medial upper eyelid, canthus, medial nasal skin, conjunctiva, and lateral lacrimal apparatus.

When injecting this area it is prudent to always use the nondominant hand to palpate the orbital rim to ensure that the needle tip is exterior to the bony orbital margin. To anesthetize this area, the supratrochlear nerve is measured 17 mm from the glabellar midline and 1-2 mL of local anesthetic is injected. The **supraorbital nerve** is blocked by palpating the notch (and/or measuring 27 mm from the glabellar midline) and injecting 1-2 mL of local

anesthetic solution. The infratrochlear nerve is blocked by injecting 1-2 mL of local anesthetic solution at the junction of the orbit and the nasal bones.

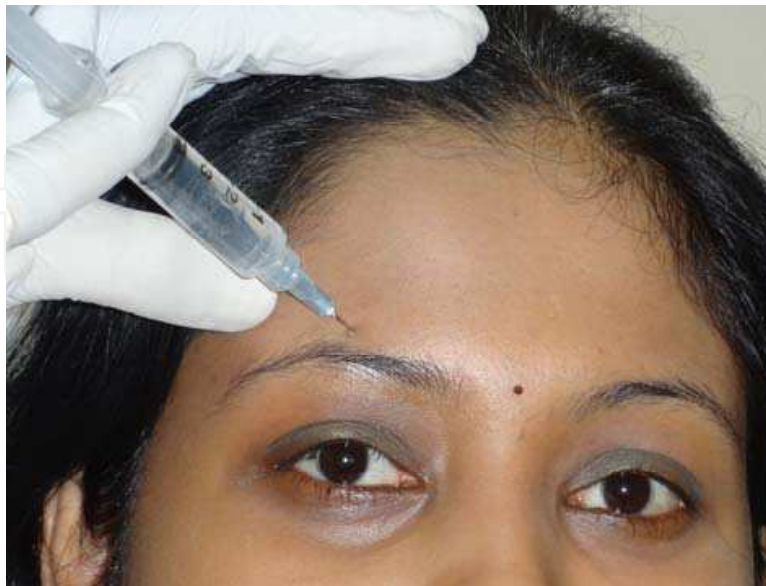

Fig. 2. Supra orbital nerve block

### 3.4 Infraorbital nerve block

This block is one of the most commonly utilized facial blocks in order to anesthetize the upper lip and upper nasolabial fold for injection of fillers. Obviously, a bilateral block must be performed to achieve anesthesia on both sides of the lip.

The Infraorbital nerve exits the Infraorbital foramen 4-7 mm below the orbital rim in an imaginary line dropped from the midpupillary midline. The anterior superior alveolar nerve branches from the Infraorbital nerve before it exits the foramen, and thus some patients will manifest anesthesia of the anterior teeth and gingival if the branching is closed to the foramen. Areas anesthetized include the lateral nose, anterior cheek, lower eyelid, and upper lip on the injected side. This nerve can be blocked by intraoral or extraoral routes.

To perform an Infraorbital nerve block from an **intraoral** approach, (fig 3) topical anesthesia is placed on the oral mucosa at the vestibular sulcus just under the canine fossa (between the canine and first premolar tooth) and left for several minutes. The lip is then elevated and a ½ inch 30 gauge needle is inserted in the sulcus and directed superiorly towards the Infraorbital foramen. Bending the needle at 45 degree angle upward can facilitate the needle insertion. The needle needs only to approach the vast branching around the foramen to be effective. It is important to use the other hand to palpate the inferior orbital rim to avoid injecting superiorly the orbit. 2-4 mL of 2% lidocaine is injected in this area for the Infraorbital block and the palpating finger can feel the local anesthetic bolus below the Infraorbital rim, confirming the correct are of placement.

The Infraorbital nerve can also be very easily blocked by the **transcutaneous facial approach** and may be the preferred rout in dental phobic patients. (fig 4). A 32 gauge ½ inch needle is used and is placed through the skin and aimed at the foramen in a perpendicular direction. Between 2 and 4 mL of local anesthetic solution is injected at or close to the foramen. Again,

the other hand must constantly palpate the inferior orbital rim to prevent inadvertent injection into the orbit. Care must be taken in this approach to avoid superficial vessels that may cause noticeable bruising.

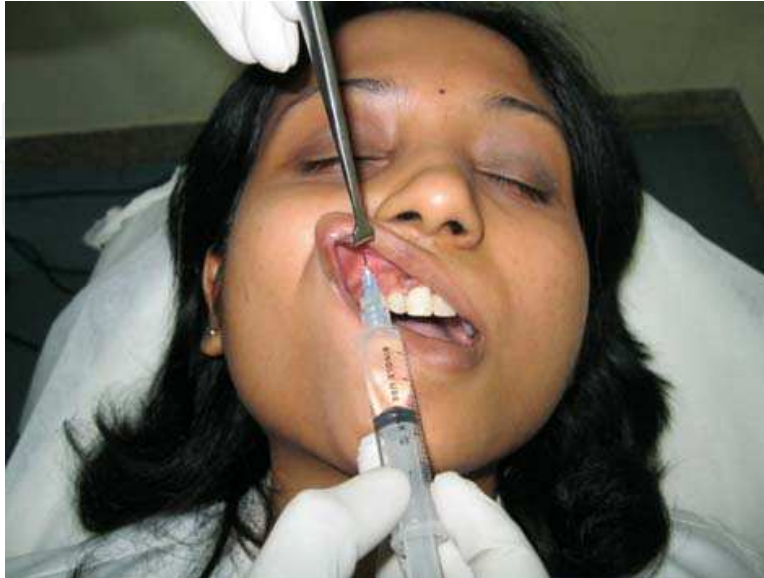

Fig. 3.

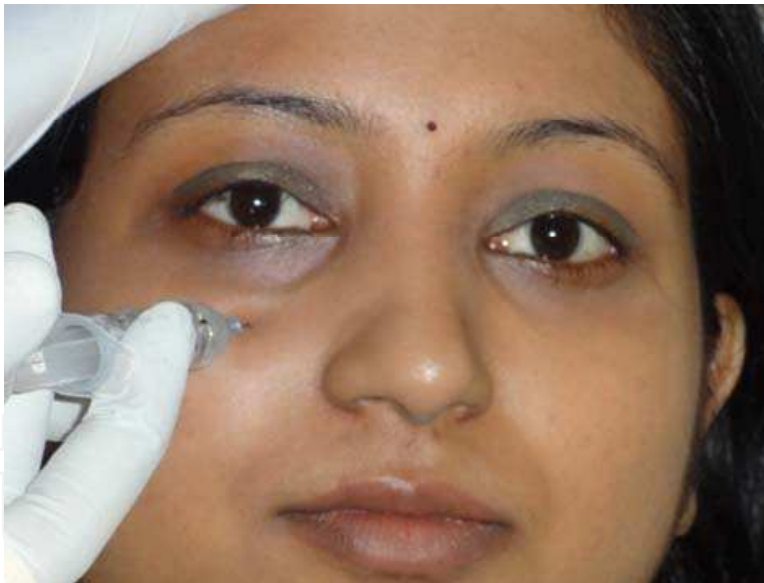

Fig. 4.

A successful Infraorbital nerve block will anesthetize the Infraorbital cheek, the lower palpebral area, the lateral nasal area, and superior labial regions as shown in figure.

### 3.5 Zygomaticotemporal nerve block

Two uncommon facial local anesthetic blocks are the zygomaticotemporal and zygomaticofacial nerves. This may assist the injection of fillers in facial rhytides on the lateral temporal and lateral canthal areas or in the malar areas. These nerves represent the terminal

branches of the zygomatic nerve. The zygomaticotemporal nerve emerges through a foramen located on the anterior wall of the temporal fossa. This foramen is actually behind the lateral orbital rim posterior to the zygoma at the approximate level of the lateral canthus.

To orient for this injection it is necessary to palpate the lateral orbital rim at the level of the frontozygomatic suture (which is frequently palpable). With the index finger in the depression of the posterior lateral aspect of the lateral orbital rim (inferior and posterior to the frontozygomatic suture), the operator places the needle just behind the palpating finger (which is about 1 cm posterior to the frontozygomatic suture). The needle is then 'walked' down the concave posterior wall of the lateral orbital rim to approximate level of the lateral canthus. After aspirating, 1-2mL of 2% lidocaine is injected in this area with a slight pumping action to ensure deposition of the local anesthetic solution at or about the foramen. Again, it is important to hug the back concave wall of the lateral orbital rim with the needle when injecting.

Blocking the zygomaticotemporal nerve causes anesthesia in the area superior to the nerve, including lateral orbital rim and the skin of the temple from above the zygomatic arch to the temporal fusion line.

### **3.6 Zygomaticofacial nerve block**

The zygomaticofacial nerve exits through a foramen (or foramina in some patients) in the inferior lateral portion of the orbital rim at the zygoma. If the surgeon palpates the junction of the inferior lateral portion of the lateral orbital rim, the nerve emerges several millimeters lateral to this point. By palpating this area and injecting just lateral to the finger, this nerve is successfully blocked with 1-2mL of local anesthetic. Blocking this nerve will result in anesthesia of a triangular area from the lateral canthus and the malar region along the zygomatic arch and some skin inferior to this area.

### **3.7 Mental nerve block**

The mental nerve exits the mental foramen on the hemimandible at the base of the root of the second premolar (many patients may be missing a premolar due to orthodontic extraction). The mental foramen is on average 11 mm inferior to the gum line. There is variability with this foramen, but by injecting 2-4 mL of local anesthetic solution about 10 mm inferior to gum line or 15 mm inferior to top of the crown of the second premolar tooth the block is usually successful. In a patient without teeth, the foramen is often times located much higher on the jaw and can sometimes be palpated. This block is performed more superiorly in the denture patient. As stated earlier, the foramen does not need to be entered as a sufficient volume of local anesthetic solution in the general area will be effective. By placing traction on the lip and pulling it away from the jaw, the labial branches of the mental nerve can be seen traversing through the thin mucosa in some patients. The mental nerve gives off labial branches to the lip and chin.

Alternatively, the mental nerve may be blocked through the skin of the cheek with a facial approach, aiming for the same target.

When anesthetized the distribution of numbness will be the unilateral lower lip to the midline and laterally to the mentolabial fold, and in some patients the anterior chin and cheek depending on the individual furcating anatomy of that patient's nerve.



As mentioned earlier, sometimes patients may perceive pain despite bilateral nerve block in the upper or lower lips. When injecting fillers in the lower lip and bilateral mental nerve blocks are not totally effective, a supplemental infiltration of several milliliters of local anesthetics region of the mandibular labial frenulum can assist the block.

### **Anesthesia for aesthetic lip augmentation<sup>17</sup>**

Although in theory a bilateral Infraorbital block should anesthetize the entire upper lip, some patients may still perceive pain for various anatomic (or sometimes psychological) reasons. It is recommended that the injection of 1.0mL of local anesthetic solution in the maxillary labial frenum. This can also be performed in the lower lip labial frenum area to augment bilateral mental blocks.

### **3.8 Digital nerve block<sup>9</sup>**

This is commonly performed nerve block by dermatosurgeons for nail surgeries, acral vitiligo correction, multiple verrucae on fingers, etc.

Each digit is innervated by two dorsal and two ventral branches of nerve as follows:

- Fingers – Radial and ulnar nerves on dorsal surface.  
Median and ulnar nerve on palmar surface
- Toes – Peroneal nerve on dorsal surface.  
Tibial nerve on planter surface.  
Rarely, Saphenous nerve on dorsal aspect of great toe.

Two methods exist for achieving a digital block viz. ring block and metacarpal/metatarsal head technique (anesthetizing the nerves before they enter the digits). Ring block is more commonly used in day to day practice.

#### **Ring block**

The 0.5-1 mL of local anesthetic (without adrenaline) is injected with the help of 26 gauge ½ inch needle at the dorsolateral margin of the desired digit at the level of webspace. The needle is advanced further across the dorsal aspect of the digit and the anesthetic solution injected in superficial (subcutaneous) and then deep plane (close to the bone). It is then withdrawn up to the insertion point and rerouted along the palmar surface in a similar manner and after depositing 0.5-1mL, the needle is completely removed. The hand is turned over and needle inserted at the palmar medial surface at level of webspace of the same digit. It is pushed across laterally and solution injected, withdrawn to insertion point, redirected medially to complete the block.

#### **Metacarpal/metatarsal head technique**

The needle is introduced in the space between the heads of the metacarpals / metatarsals, proximal to the webspace and perpendicular to skin. It is advanced in a similar direction towards the palmar / plantar aspect of the hand/foot, till it reaches the subcutaneous level here.

The local anesthetic solution is then injected thus blocking the digital nerves at the level before they enter the digit. The needle is withdrawn and the procedure repeated on the other side of the respective metacarpal/metatarsal head.

Since the blood supply to digits is by terminal arteries, adrenaline should not be mixed with local anesthetic. The volume injected to produce block should not exceed 8mL as larger volume can produce mechanical compression on vasculature results in ischemia and digital necrosis.

Sometimes, the anesthesia achieved is unsatisfactory; the reason for this could be failure to infiltrate the local anesthetic close to bone, where nerve lies; or failure to anesthetize adequate length of the nerve. Both causes can be avoided by using higher concentration solutions.

#### **Reducing the pain of local anesthesia<sup>10</sup>**

The introduction of needle and infiltration of anesthetic are many times very painful and may provoke intense anxiety and can lead to an unpleasant surgical experience for the patient.

The pain experienced during the administration of local anesthetics may be attributed to the needle puncture of the skin, tissue irritation from the solution, and tissue distention from the infiltration.

To minimize pain physician should be reassuring, distracting patients through conversation or slightly vibrating the skin may decrease their perception of pain. For extremely anxious patients, mild sedation with a benzodiazepine may be helpful.

##### **a. Reducing the needle prick pain<sup>18</sup>**

- Explanation of procedure,
- Use of mild sedation
- Use of topical anesthetic cream can be helpful to minimize pain.
- Use of small diameter needle can be less painful compare to larger diameter needle.
- Longer needle should be used when anesthetizing large areas to avoid multiple pricks
- Use of long acting local anesthetic helps to avoid repeated pricks if procedure is more time taking.
- Slow introduction of needle, introduction of needle through accentuated pore (on face), reinsert needle in an area already anesthetized are other way to reduce the pain associated with needle prick.

##### **b. Reducing the pain associated with tissue distension**

Slow injection of anesthetic solution, only required amount to be injected, inject into subcutaneous fat, use of field block, being injecting the drug proximally and advanced distally (produce anesthesia distal to needle tip reducing the pain of advancing injection needle).

##### **c. Reducing the pain due to tissue irritation**

The tissue irritation from local anesthetics is primarily due to the acidity of the anesthetic solution. The anesthetics are acidified to increase their solubility, as well as their chemical stability. To decrease irritation produced by local anesthetics, the solution may be buffered through several means:

- Mix lidocaine with adrenaline with plain lidocaine in equal part.
- Mixed plain lidocaine (10 mL) with adrenaline (0.1mL). The subsequent solution is lidocaine with adrenaline, but at same pH as plain lidocaine.
- Add sodium bicarbonate to the anesthetic solution (lidocaine with adrenaline: sodium bicarbonate in 10:1) to increase the pH of local anesthetics to near tissue fluid levels.<sup>19</sup>

#### 4. Tumescence anesthesia<sup>20</sup>

This is a technique of local anesthesia which involves the subcutaneous injection of large volumes of dilute LA in combination with adrenaline and other agents is used for dermabrasion, skin grafting, rhinophyma correction, liposuction and hair transplant procedures, most common being liposuction. The plasma concentrations may peak more than 8-12 hours after infusion. Clinicians are advised to exercise great caution in administering additional local anesthesia by infiltration or other routes for at least 12-18 hours following the use of this technique.

##### 4.1 Tumescence fluid – Composition<sup>21</sup>

Normal Saline 1000 cc  
Lidocaine (2%) 50 cc  
Adrenaline (1:1000) 1 cc  
Sodium bicarbonate (8.4%) 10 cc  
Effective concentration of lidocaine – 0.1%

(Safe up to 55 mg/kg, according to the American Academy of Dermatology guidelines of care for liposuction.)

##### 4.2 Advantages<sup>20,21</sup>

1. The injection is almost painless as it is placed subcutaneously, where the lax tissue is easily distensible
2. It pushes up or stretches the skin and the area to be operated and provides a cushioning effect to deeper structures, so less chance of their damage.
3. Provides very good hemostasis due to large volume of anesthetic compresses the subcutaneous vasculature.
4. It causes hydrodissection at subcutaneous layer and provide safer plane for dissection like in donor strip harvesting in hair transplantation, due to volume of anesthetic injected and also helps to preserve the dermal tissue architecture since injection is placed at deeper level.
5. Smaller quantity of actual anesthetic agent is required for desired action which reduces the possibility of systemic side effects.
6. Prolonged area of several hours' duration occurs as a result of a reservoir effect of local anesthetic.
7. The addition of adrenaline increases the duration of action<sup>5</sup>, while sodium bicarbonate helps to adjust the pH of the formulation to a level very close to that of the tissue fluid, which reduces the tissue irritation and pain during the injection of Tumescence anesthesia.
8. Elimination of general anesthesia, hospital operating facilities, and hospital overnight stays also result in a favorable impact on costs when this technique is employed.

##### 4.3 Disadvantages<sup>20</sup>

1. Since the prepared solution is placed subcutaneously, there is more diffusion in this highly distensible compartment and faster absorption through this vascular tissue.
2. Onset of anesthetic action takes 10-15 minutes due to time taken to penetrate the dermal nerves from deeper plane.



4.4 Calculation of maximal tumescent technique lidocaine dose for 70 kg liposuction patient

$$(55\text{mg/kg})(80\text{kg}) = 4400 \text{ mg}$$

If 0.1% lidocaine solution is used, then

$$(4400 \text{ mg})/(1\text{mg/L}) = 4.400 \text{ L}$$

**4400 mL of 0.1% solution**

4.5 Tumesence infiltration technique

Tumescent fluid is infiltrated in tissue either by a syringe with needle or by infusion canula.

Skin is gently numbed by infiltration of same tumescent solution at places of anticipated adits. Small access openings are made to insert infusion canula attached either to a lure locked syringe or infusion pump. Tumescent fluid in infiltrated till the skin shows pallor. Rate of infusion should be slow to avoid discomfort due to rapid stretching of skin.

Tumesence solutions: concentration, volume, used for various body areas<sup>21</sup>

Area	volume of tumescent Solution ml	Lidocaine (mg/L)	Lidocaine (mg)
Jowels	25-75	1250	30-95
Chin and Neck	50-150	1250	60-190
Male breast	400-1400	1250	500-1750
Upper arms	500-1200	1000	500-1200
Male flanks	500-1100	1000	500-1100
Waist	400-1000	1000	400-1000
Hips	600-1200	750	450-1080
Abdomen, upper	500-1200	1000	500-1200
Abdomen, lower	600-1500	1000	600-1500
Medial thighs	800-1500	750	600-1125
Lateral thighs	400-1300	750	300-975
Knees	200-400	750	150-300

Discomfort during the infusion may be due to<sup>21</sup>

- Too high infusion rate – decrease the rate
- Advancing an infusing cannula too rapidly- consider slower advancement, consider needle infusion, or initiating infusion with needle prior to using infusion cannula

- Skin surface inadequately numbed – re numb the skin.

#### **Local Anesthesia in Hair Transplantation<sup>22</sup>**

- Anesthesia for strip removal
  - Infiltration with lidocaine 1cm lower than lower incision line
  - Tumescant fluid infiltration
- Anesthesia in frontal (donor) area
  - Nerve blocks for supra-orbital and supratrochlear
  - Tumescant fluid infiltration
- Anesthesia for FUE donor site
  - Field block
  - Tumescant fluid infiltration

### **5. Non pharmacological anesthesia**

#### **a. Hypnosis, talkesthesia**

Many patients may be benefited just by soothing verbal and tactile reinforcement from doctor as well as family members. This works on principle of hypnosis as a tool to enhance the patient's tolerance level. The patient is asked to relax and be calm. Sometimes physician can ask the patient to concentrate on breathing – slow steady inspiration and expiration to the count of 'one-the-three'. – This maneuver helps the majority of the patient to relax and calm. Holding the patient's hand, with or without gentle stroking, is also a calming precedure.<sup>23</sup>

#### **b. Vibration anesthesia<sup>24</sup>**

Vibration has been used for many years to reduce pain in disciplines such as dentistry and physiotherapy, and is now becoming recognized as a simple, safe and effective form of anesthesia in dermatology. Vibration anesthesia can be explained by the 'gate theory of pain control'.<sup>25</sup> popularized by Melzack and Wall in the 1960s. Noxious nerve impulses evoked by injuries are influenced in the spinal cord by other nerve cells that act like gates, either preventing the impulses from getting through, or facilitating their passage. Without vibratory modulation, noxious impulses are carried through small C fibers uninhibited through a 'gate' in the spinal cord that ultimately sends the signal to the brain. When applied simultaneously, vibratory stimulation excites large A fibers, which activates inhibitory interneurons at the gate and mitigates the perception of pain in the brain.

Any vibratory massager can be used to produce the vibratory stimulation. A study has shown that pain sensitivity gradually declines as vibration amplitude increases, but no specific frequency is more effective in interference with nociception. The vibratory massager should be applied approximately 2-3 seconds prior to the injection or laser application and 1-2 cm from the site, and continue throughout the procedure.

#### **c. Cooling<sup>26,27</sup>**

Cooling can be achieved using sprays, cold air, ice, ice packs, and gels. Cooling can reduce the discomfort of many procedures. Both pain and temperature sensation travel in the same nerve pathway. If this nerve pathway is overloaded by the cold sensation, pain is less likely to be felt in the same area.

Refrigerant spray: It is a form of cryoanesthesia, which works on 'gate theory' of pain control.<sup>25</sup> It is a spray containing ethyl chloride or dichlorotetrafluoroethane. The refrigerant is sprayed for 2-5 seconds, depending upon the distance from the skin until a white frost is seen and then immediately the short procedure has to be carried out

### 5.1 Cooling methods for various lasers<sup>28</sup>

Cooling in laser procedures acts not only as numbing agent but a epidermal protector. Following are various ways to cool epidermis while achieving changes in deeper part of skin.

- Icing before laser
- Cool air flow (Zimmer Cryo)
- DCD spray
- Sapphire tip contact cooling
- Metal tip contact cooling
- Cool gel

### 5.2 Role of anesthesia in outcome of aesthetic procedure:

Anesthesia in aesthetic procedures has not only a functional role but also has a great psychological impact on perception of the procedure by the patient. Successful anesthesia and analgesia makes the aesthetic procedure a pleasant experience for the patients and encourage them to go for such repeated procedures.


## 6. Summary

Local anesthesia makes cosmetic procedures not only appealing but cost effective also by making them day care ones. A topical anesthetic cream with occlusion is most common technique of local anesthesia. Field block is achieved by infiltration of LA in and around area to be treated. It is modified to target an innervating nerve trunk by various nerve blocks. Tumescence local anesthesia is a state of art modification of LA to anesthetize a very large volume of tissue for prolonged period without significant adverse effects. Mastering the art and science of local anesthesia is very much essential in successful outcome of aesthetic procedures.

## 7. References

- [1] Strichartz GR. Neural physiology and local anesthetic action. In: Cousins MJ, Bridenbaugh PO, eds. Neural blockade in clinical anesthesia and management of pain. Philadelphia: JB Lippincott, 1988:25-45.
- [2] Auletta MJ. Local anesthesia for dermatologic surgery. *Semin Dermatol* 1994;13:35-42.
- [3] Tucker GT, Mather LE. Properties, absorption, and deposition of local anesthetic agents. In: Cousins MJ, Bridenbaugh PO, eds. Neural blockade in clinical anesthesia and management of pain. Philadelphia: JB Lippincott, 1988:47-110.
- [4] Auletta MJ, Grekin RC. Local anesthesia for dermatologic surgery. New York: Churchill Livingstone, 1991:1-40.
- [5] Satoskar RS, Bhandarkar SD: Pharmacology and Pharmacotherapeutics 12<sup>th</sup> edn., Bombay: Popular Prakashan Pvt. Ltd. 1992; 189-194.

- [6] Covino BG, Vassallo HG. Local anesthetics: mechanisms of action and clinical use. New York: Grune & Stratton, 1976:1-148.
- [7] Dzubow LM. The interaction between propranolol and epinephrine as observed in patients undergoing Moh's surgery. J Am Acad Dermatol 1986;15:71-5.
- [8] Glinert RJ, Zachary CB. Local anesthesia allergy. J Dermatol Surg Oncol 1991;17:491-6.
- [9] Auletta Mj, Grekin RC: Clinical application of local anesthesia. Local Anesthesia for Dermatologic Surgery 1<sup>st</sup> edn., New York: Churchill Livingstone 1991;41-78
- [10] Auletta Mj, Grekin RC: Tricks to make the delivery of local anesthesia less painful. Local anesthesia for Dermatologic Surgery 1<sup>st</sup> edn., New York: Churchill Livingstone 1991; 79-84.
- [11] Green SS. Iontophoresis as a tool for anesthesia in dermatology surgery: an overview. Dermatol Surg 2001; 27:1027-30
- [12] Baron Elma, Harris Lisbeth, Redpath William S et al. Laser assisted penetration of topical anesthetics in adults. Arch Dermatol 2003; 139:1288-90
- [13] Hædersdal, M., Sakamoto, F. H., Farinelli, W. A., Doukas, A. G., Tam, J. and Anderson, R. R. (2010), Fractional CO<sub>2</sub> laser-assisted drug delivery. Lasers in Surgery and Medicine, 42: 113-122.
- [14] Friedman PM., Mafong E, Friedman E et al. Topical anesthetic update: Emla and beyond. Dermatol Surg 2001; 27:1019-26.
- [15] Splinter W.M, 'Needle-Free' Delivery of Local Anesthesia: A Valuable Option in Pediatrics. Pediatric Drugs 2002; 4: 349-52.
- [16] Banga AK, Bose S, Ghosh TK. Iontophoresis and electroporation: comparisons and contrasts, International Journal of Pharmaceutics. 1999; 179(2): 1-19
- [17] Carruthers J, Carruthers A. (Eds). *Soft Tissue Augmentation*, New Delhi: Elsevier 2006, 155-159.
- [18] Arndt KA, Burton C, Noe JM. Minimizing the pain of local anesthesia. Plast Reconstr Surg 1993;72:676-9.
- [19] Skidmore RA, Patterson JD, Tomsick RS. Local anesthetics. Dermatol Surg 1996;22:511-22.
- [20] Klein JA: Anesthesia for liposuction in dermatologic surgery. J Derm Surg Oncol 1988; 14: 1124-32.
- [21] William Hanke C, Sattler G (Eds). *Liposuction*. New Delhi: Elsevier 2007; 21-32.
- [22] Seager DJ, Simmons C. Local Anesthesia in Hair Transplantation. Dermatologic Surgery. 2002; 28: 320-328.
- [23] Spiegel H, Spiegel D. Trance and treatment clinical use of hypnosis. New York: Basic Books; 1978
- [24] Smith KC, Comite SL, Balasubramanian S. Vibration anesthesia: A noninvasive method of reducing discomfort prior to dermatologic procedures. Dermatology Online Journal 10 (2): 1
- [25] Melzack R, Wall PD. Pain mechanisms: a new theory. Science. 1965 Nov 19;150(699):971-9.
- [26] Chan HH, Lam LK, Wong DS, Wei WI. Role of skin cooling in improving patient tolerability of Q-switched Alexandrite (QS Alex) laser in nevus of Ota treatment. Lasers Surg Med. 2003;32(2):148-51
- [27] Kauvar AN, Frew KE, Friedman PM, Geronemus RG. Cooling gel improves pulsed KTP laser treatment of facial telangiectasia. Lasers Surg Med. 2002;30(2):149-53.
- [28] Nanni CA, Alster TS. Laser-assisted hair removal: Side effects of Q-switched Nd:YAG, long-pulsed ruby, and alexandrite lasers. J Am Acad Dermatol. 1999;41:165-71.



## **Clinical Use of Local Anesthetics**

Edited by Dr. Asadolah Saadatniaki

ISBN 978-953-51-0430-8

Hard cover, 102 pages

**Publisher** InTech

**Published online** 23, March, 2012

**Published in print edition** March, 2012

Local anesthetics are being increasingly applied in different surgeries. Lower side effects of neuroaxial anesthesia, regional anesthesia, and field block, in comparison to general anesthesia (volatile and intravenous agents), are the main reasons why physicians prefer to conduct surgeries under local anesthesia, especially in outpatient and day care surgeries. It is important to emphasize the presence of an anesthesiologist, and vigilant monitoring of the hemodynamic parameters, in decreasing a patient's anxiety, exerting other modalities for analgesia and increasing the safety margin in many procedures.

### **How to reference**

In order to correctly reference this scholarly work, feel free to copy and paste the following:

Dhepe V. Niteen (2012). Local Anesthesia for Cosmetic Procedures, *Clinical Use of Local Anesthetics*, Dr. Asadolah Saadatniaki (Ed.), ISBN: 978-953-51-0430-8, InTech, Available from:  
<http://www.intechopen.com/books/clinical-use-of-local-anesthetics/anesthesia-for-cosmetic-procedures>

**INTECH**  
open science | open minds

### **InTech Europe**

University Campus STeP Ri  
Slavka Krautzeka 83/A  
51000 Rijeka, Croatia  
Phone: +385 (51) 770 447  
Fax: +385 (51) 686 166  
[www.intechopen.com](http://www.intechopen.com)

### **InTech China**

Unit 405, Office Block, Hotel Equatorial Shanghai  
No.65, Yan An Road (West), Shanghai, 200040, China  
中国上海市延安西路65号上海国际贵都大饭店办公楼405单元  
Phone: +86-21-62489820  
Fax: +86-21-62489821

© 2012 The Author(s). Licensee IntechOpen. This is an open access article distributed under the terms of the [Creative Commons Attribution 3.0 License](https://creativecommons.org/licenses/by/3.0/), which permits unrestricted use, distribution, and reproduction in any medium, provided the original work is properly cited.

IntechOpen

IntechOpen