

We are IntechOpen, the world's leading publisher of Open Access books Built by scientists, for scientists

6,900

Open access books available

185,000

International authors and editors

200M

Downloads

Our authors are among the

154

Countries delivered to

TOP 1%

most cited scientists

12.2%

Contributors from top 500 universities



WEB OF SCIENCE™

Selection of our books indexed in the Book Citation Index
in Web of Science™ Core Collection (BKCI)

Interested in publishing with us?
Contact book.department@intechopen.com

Numbers displayed above are based on latest data collected.
For more information visit www.intechopen.com



Endovenous Laser Treatment of Incompetent Superficial and Perforator Veins

Suat Doganci and Ufuk Demirkilic
*Gulhane Military Academy of Medicine,
Department of Cardiovascular Surgery
Turkey*

1. Introduction

Varicose veins are a common disorder and occur in about 40% of men and 32% of women. However the prevalence of the varicose veins has variability according to the age, gender, duration of reflux, and localization (superficial and/or deep veins). According to the Bonn Vein Study according to the duration of reflux (>500 ms) prevalence of the varicose veins in all veins was 35.3% (superficial veins: 21.0%, deep veins: 20.0%). The effect of venous insufficiency on patients' quality of life is comparable with other common chronic diseases such as arthritis, diabetes and cardiovascular disease. (1, 2)

Traditional treatment of great saphenous vein (GSV) varicosities includes ligation of the sapheno-femoral junction (SFJ) combined with GSV stripping (complete/partial). (3) For the small saphenous vein (SSV) and the perforator veins, situation is a little more complicated. Due to their anatomic challenges and variations, surgery for the SSV and the incompetent perforator veins is sometimes very difficult and may cause adverse events and complications.

Conventional surgery for SSV incompetence presents a high incidence of recurrence (up to 52% at 3 years) and is frequently associated with neurovascular injury. (4) In many instances this is the result of inaccurate ligation of saphenopopliteal junction (SPJ). Even in experienced hands saphenopopliteal ligation is not always technically successful. This is mainly due to the diverse anatomic anomalies of the SPJ and its proximity to the tibial and sural nerves. (5) Unlike the saphenofemoral junction of GSV which is almost constant, the SPJ is variable in terms of level, site of implantation into the popliteal vein, as well as termination and tributaries. (6) Rashid et al. (7) have shown that ligation of the SPJ is not achieved in 30% of the cases, even if the junction is marked pre-operatively under ultrasound guidance. The incision made in the popliteal fossa is associated with wound healing problems and infection in 19-23% of cases. (5)

Incompetent perforator veins (IPVs) are also a significant source of venous hypertension and it is important to treat IPVs. (8) Traditional methods such as Linton procedure and the

modifications have a relatively high incidence of wound complications ranging from 20% to 40%. (9) These procedures require general or regional anesthesia and involve a hospital stay of 3-5 days. Postoperative pain significant and may require narcotics. Subfacial endoscopic perforator surgery (SEPS) overcomes some of Linton's limitations but have some of its own. (10) Percutaneous ablation of IPVs by using laser energy is a relatively new technique and has been performed very recently.

Associated morbidity and patient dissatisfaction associated with the traditional surgical treatment have led to the development of alternative techniques. (3) Endovenous treatment modalities (laser ablation, radiofrequency ablation, steam, and foam sclerotherapy) have been readily accepted by both patients and doctors.

2. Historical background

Endovenous laser ablation (EVLA) of the GSV was first described by Puglisi (11) in 1989 in the International Union of Phlebology and the first successful results were reported by Navarro (12) in 2001. Although no multicenter clinical trials of the safety and efficacy of this procedure in humans have been published, many case series and some analysis of pathophysiological effects have been published subsequently.

Endovenous laser treatment of GSV was approved by FDA in 2002 and SSV was approved in 2003. (13, 14) However, percutaneous laser treatment of IPVs is a very new procedure. Proebstle (15) published early results of this procedure in 2007.

3. Technological issues

Lots of manufacturers produce laser generators, all of which seems to be effective in the thermal ablation of the incompetent varicose veins.

Semiconductor (diode) lasers have been the main laser type employed for this treatment although some reports have mentioned the neodymium: yttrium-aluminium-garnet (Nd:YAG) laser. Laser wavelengths reported include 810nm, 940nm, 980nm, 1064nm, 1320 nm and 1470 nm. (3, 16)

Clinical trial experience with diode lasers has produced extremely low rates of deep vein thrombosis (DVT) and paraesthesia, a low risk of skin burns, and no documented cases of pulmonary embolism; both paraesthesia and skin burns have been associated with 1064 nm laser treatment. The most common side effects seen with all laser types are bruising, localised pain, induration and discomfort along the treated vein, and superficial phlebitis. (17) Longer wavelengths (>1000nm) show greater water absorption but are overall less strongly absorbed in blood than shorter wavelengths and may have some advantages for endovenous laser ablation. (18-20) The 1470 nm diode laser operates at a relatively new wavelength for this treatment and has been in use since 2006. (16)

There has also been progress in the field of laser fibers (Figure 1). Recently, new fibre tips (jacket-tip fibres, glass, metal, ceramic, diffusion, radial, and tulip) were developed. There are promising results with radial laser fibers. (21) These new generation fibers also more echogenic than the old bare-tip fibers and can easily be seen on Doppler ultrasound.

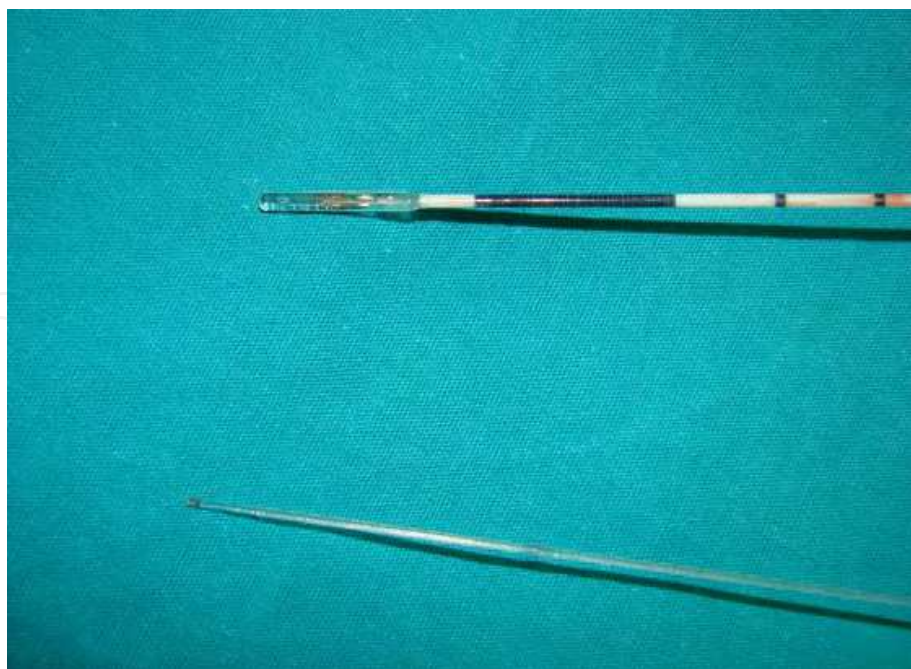

Fig. 1. Picture of bare-tip and radial laser fibers.

With the evolving technology, nowadays it is very difficult to follow technologic advances in the field of endovenous treatment modalities. However, we believe that in the near future technologic advances will overcome all the limitations of these procedures and endovenous procedures will definitely take the place of traditional surgical methods in the treatment of venous insufficiency.

4. Patient selection

Inclusion criteria consist of symptoms and signs of venous insufficiency. Any patient that has the indication for treatment of varicose veins can be treated by endovenous laser ablation method.

In our clinical experience, we perform EVLA for patients other than absolute contraindications (22) (arteriovenous malformation, deep vein thrombosis and restricted immobility). Although there are some relative contraindications (22) documented in the literature such as deep vein reflux, previous treatment, large-vein diameter, anticoagulant therapy, hormone replacement therapy, tortuous vein, and aneurysmal vein segments, in our clinical practice we perform EVLA to all these patients with our increasing clinical experience. In our clinical experience deep vein reflux (less than 6 seconds) without extremity diameter increase (more than 3 cm) is not a contraindication for EVLA.

EVLA may also be performed in patients not really suitable for surgical therapies. Such patients are patients taking anticoagulant therapy for various reasons (i.e. atrial fibrillation, mechanical valve prosthesis etc.). Those patients can be treated with EVLA without cessation of anticoagulation. In a study, Theivacumar et al. (23) evaluated the effects of Coumadin usage on surgical outcomes and recanalization rates. They reported no major complication and a slight difference in recanalization rate in Coumadin group.

Presence of very tortuous or dilated veins does not prevent endovenous laser ablation. Besides the new laser fibers (such as radial fibers) and the longer wavelengths (1320 nm and

1470 nm), tumescent anesthesia and Trendelenburg position during the ablation procedures make endovenous laser ablation procedure possible for even the most dilated veins by shrinkage and circumferential ablation of the vein. It is sometimes difficult to advance the laser fiber in very tortuous veins. Skin stretching and positioning the vein sometimes help to advance the laser fiber. However, a second vein puncture may be necessary to complete the whole segment ablation of the diseased vein. By help of these techniques, we can simply say that almost every vein can be treated by EVLA.

Another problematic issue is the veins that are located very subdermally. Laser ablation of this vein is not a problem. However at the postoperative period patients may feel the presence of these ablated veins as a palpable cord just under the skin and may also feel stretching. Sometimes those veins may cause hyperpigmentation in the long-term period. In order to prevent these negative effects such subdermal veins may be ablated until the end of the deeper part and the superficial subdermal part may be removed surgically.

5. Procedure and technique

Endovenous laser ablation of the varicose veins may be divided into four sections:

1. Anesthesia regimen
2. Vein puncture and positioning the laser fiber
3. Ablation procedure
4. Postoperative care

5.1 Anesthesia regimen

It is possible to perform EVLA under any kind of anesthesia; however it is contrary to the nature of this minimal invasive procedure to perform under general or spinal anesthesia. Tumescent local anesthesia is sufficient for this procedure. If concomitant phlebectomies are performed, additional local anesthesia is applied to the area of varicosities. Tumescent local anesthesia should be applied under ultrasound control into the interfascial space around the saphenous vein. If correctly applied, tumescent anesthesia forms a heat shield around the vein and protects the perivascular tissues (i.e. nerves) and the skin from the high temperatures caused by the laser energy. The temperature at the tip of the laser fibre may reach 720 °C and although tumescent anaesthesia reduces heat transfer to adjacent tissue irreversible nerve injury may occur at temperatures above 45 °C. In a previous study measurements adjacent to the GSV have confirmed that following adequate infiltration of tumescent anaesthesia the perivenous temperature reaches a median of 34.5 °C and thus nerve injury should be avoided. (24) This is particularly important when treating SSVs which is very close to the different nerves (posterior femoral nerve, tibial nerve, common peroneal nerve and sural nerve) due to its anatomic course. The authors recently published their experience for the importance of puncture site selection in the prevention of postoperative nerve injuries following SSV EVLA. (24) Different mixtures of solutions have been reported for tumescent anesthesia. Either lidocaine or prilocaine are suitable in concentrations between 0.05 and 0.2%. In our clinical experience we prefer to use the following mixture: 1000 ml saline 0.9%, 50 ml lidocaine 2%, 1 ml Epinephrine 1:1000, 10 mEq NaHCO₃. A total volume of 100-500 cc is given according to length of the vein is reported in the literature. We

use a simple formula for the amount of tumescent anesthesia and give an amount of 10 ml/treated vein centimeter. There are different techniques for administering tumescent anesthesia. But according to authors' experience, injection of the solution by the help of a motor pump is an easy method. However, if this is not available then the solution can be injected via syringes under the ultrasound guidance.

5.2 Vein puncture and positioning the laser fiber

For a successful vein puncture there are some important rules. There should be a comfortable temperature in the surgical suit. Cold environment may cause vein spasm especially in sensitive patients. Patient also should be positioned in the reverse Trendelenburg position in order to fill the vein. Then the patient is cleaned. The ultrasound probe covered sterile and taken into the operating field. To preserve the minimal invasive nature of the procedure vein should be punctured percutaneously under ultrasound guidance. In the experienced hands it very easy to cannulate the vein percutaneously. Until gaining experience in the percutaneous cannulation, biopsy apparatus of Doppler probes may help to ease your cannulation. However if this is not possible, vein access can be done via stab incision and hooking of the saphenous vein.

After gaining access to the vein, a guide-wire inserted (Figure 2) through the needle and 5 or 6-F introducer sheath was placed over the guide-wire into the GSV. If a radial laser fiber is

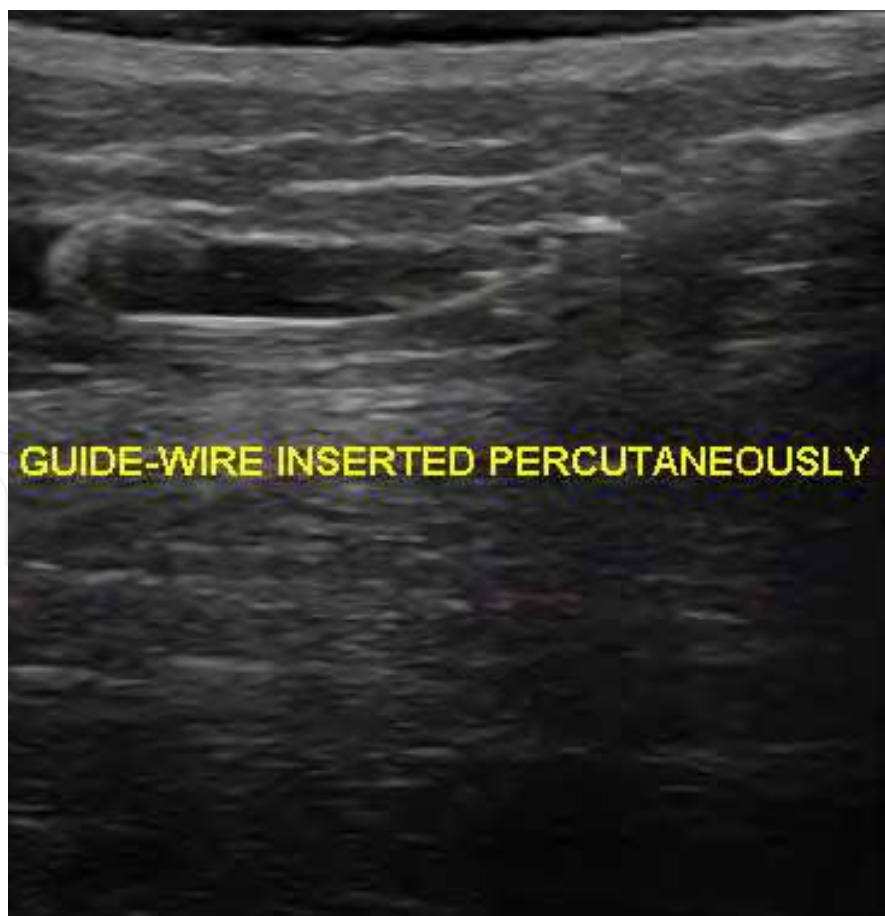

Fig. 2. Guide-wire in the saphenous vein.

used a short guide-wire and short introducer is enough to advance the fiber in GSV. However if it is preferred to use a bare-tip fiber, long guide-wires and sheaths must be used. Regardless the type of the used laser fiber, fiber is advanced till a safe distance from the saphenofemoral junction (SFJ) under the ultrasound guidance. This distance is changing in the published literature between 1-2 cm and 3-4 cm. In our experience, with 980 nm and bare-tip laser fiber we keep the distance 1-2 cm below SFJ. However we can go up till 0.5-1 cm below the SFJ with 1470 nm and radial laser fiber (Figure 3). For SSV ablation the distance from the saphenopopliteal junction should be decided according to the connection place and type of the SSV with popliteal vein. According to classification by Kosinski and Creton, SSV connects to the popliteal vein in very different types. (6) And incidence of nerve injury increase as the saphenopopliteal junction goes up to the popliteal crease. Usually as a simple rule at least a 2 cm distance should be kept between saphenopopliteal junction and the fiber for positioning.

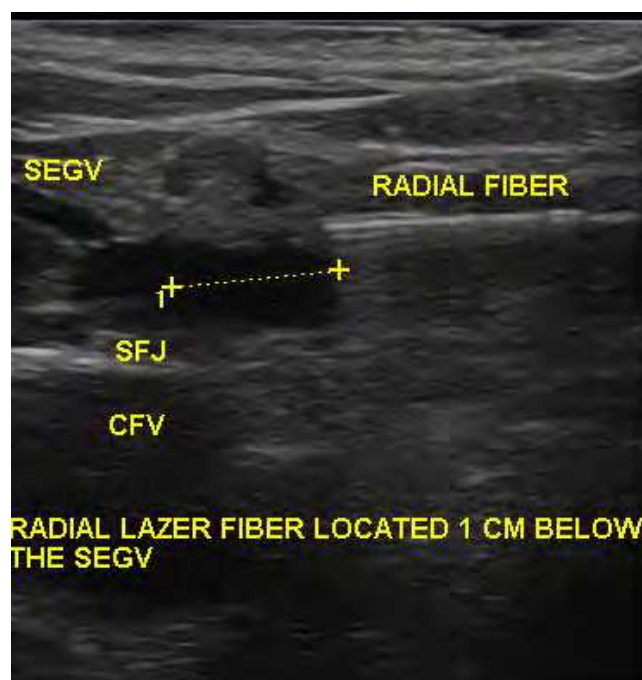


Fig. 3. Radial fiber in the saphenofemoral junction.

Sometimes it is difficult to advance the fiber in tortuous veins. Usually straightening of the leg or guiding the fiber by external manipulation and compression may solve the problem. If these maneuvers do not solve the problem a second puncture of the above the impeded vein segment is necessary to achieve a complete ablation.

The correct positioning of the fiber (just inferior to the entrance of the superficial epigastric vein into the GSV for GSV treatment and just inferior to the deep penetration of the SSV) is a very important step which must be done very cautiously to prevent any adverse event related with the procedure. The position must also be confirmed after injection of tumescent anesthesia, just before the beginning of the ablation (Figure 4). Since the echogenity of the bare-tip fibers is not so good, it needs good ultrasound skills and experience. Especially after the injection of tumescent solution, it is sometimes difficult to see the fiber due to the confounding effect of the solution. The radial fiber is more Doppler friendly and can also be seen easily after tumescent solution. (Figure 5)

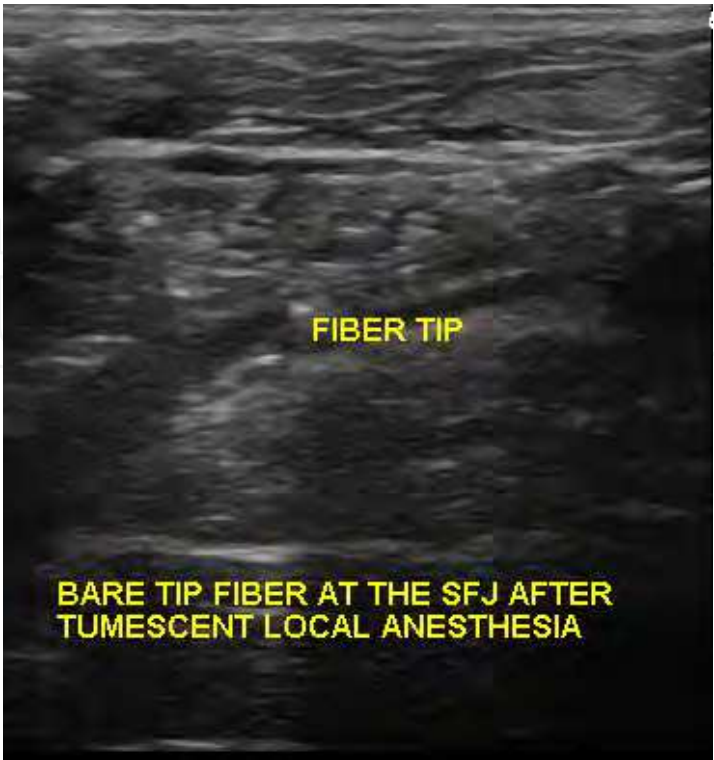

Fig. 4. Control of the position of laser fiber at the saphenofemoral junction.

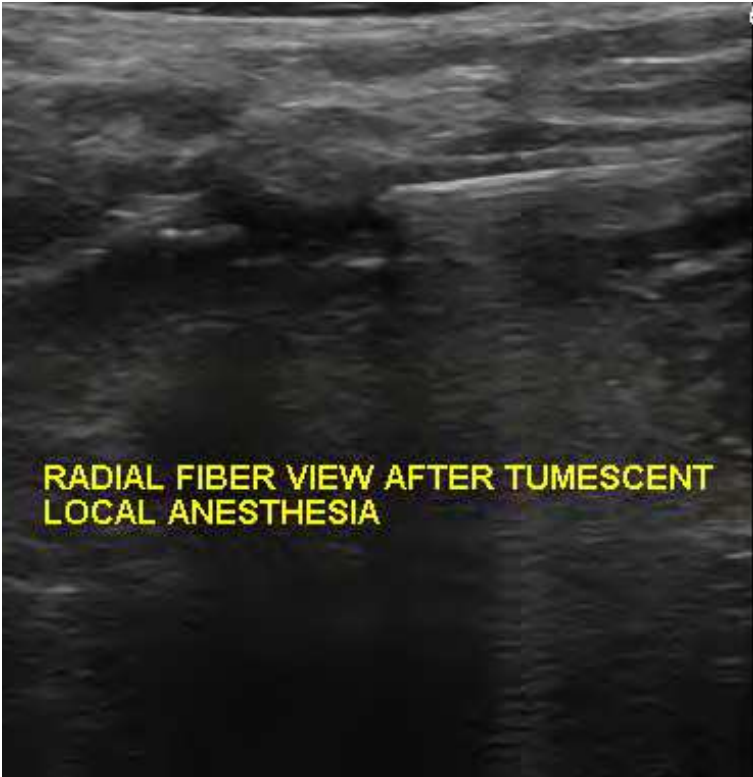


Fig. 5. View of radial fiber after tumescent local anesthetic solution.

5.3 Ablation procedure

After confirming the correct position of the fiber, patient is placed in Trendelenburg position to further empty the vein. This is especially important in treating the dilated veins.

Ablation procedure may be performed in a pulsed or continuous fashion. In our experience we prefer continuous method. (Figure 6, 7) The fiber and/or sheath are withdrawn at a speed of 1-3 mm per second. This speed is determined by the given energy to treated vein centimeter. This is called as Linear Endovenous Energy Density (LEED). Generally 60-100 J/cm LEED is delivered to the vein wall according to the diameter of the treated vein. Withdrawal speed should be a little slower at the proximal part than the distal part. During the withdrawal of the fiber, external hand compression over the ablated vein segment may help ever further narrowing the vein wall for increasing the vein wall laser energy interaction. Our goal is to achieve successful ablation while minimizing the rate of adverse events such as pain and bruising.

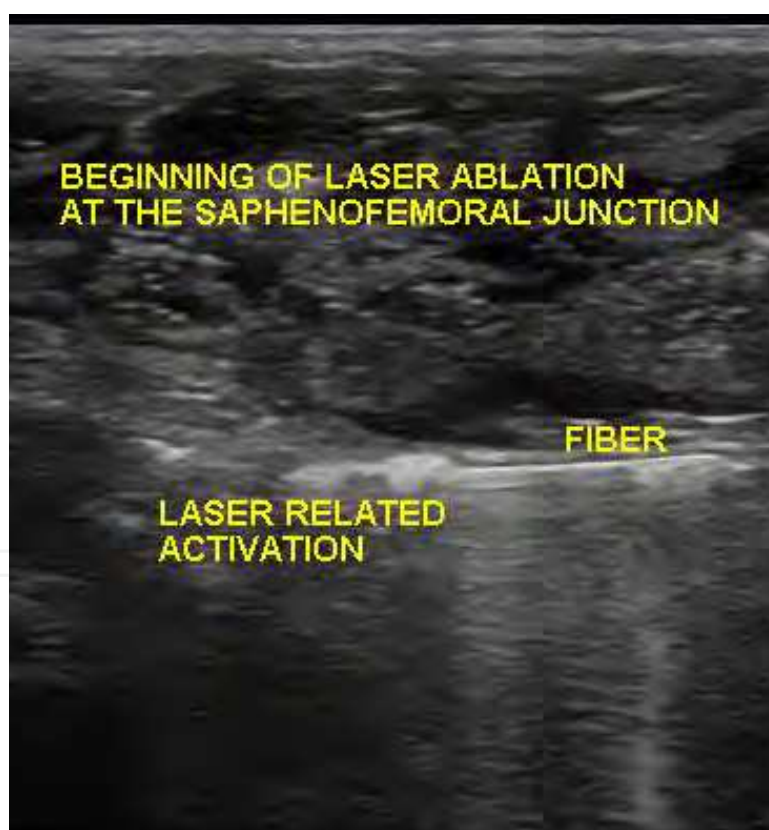


Fig. 6. Beginning of the laser ablation at the safenofemoral junction.

On the conclusion of the ablation procedure immediate Doppler confirmation is crucial. (Figure 8) Patencies of the deep veins (femoral vein, popliteal vein) as well as occlusion of the treated saphenous veins are recorded.

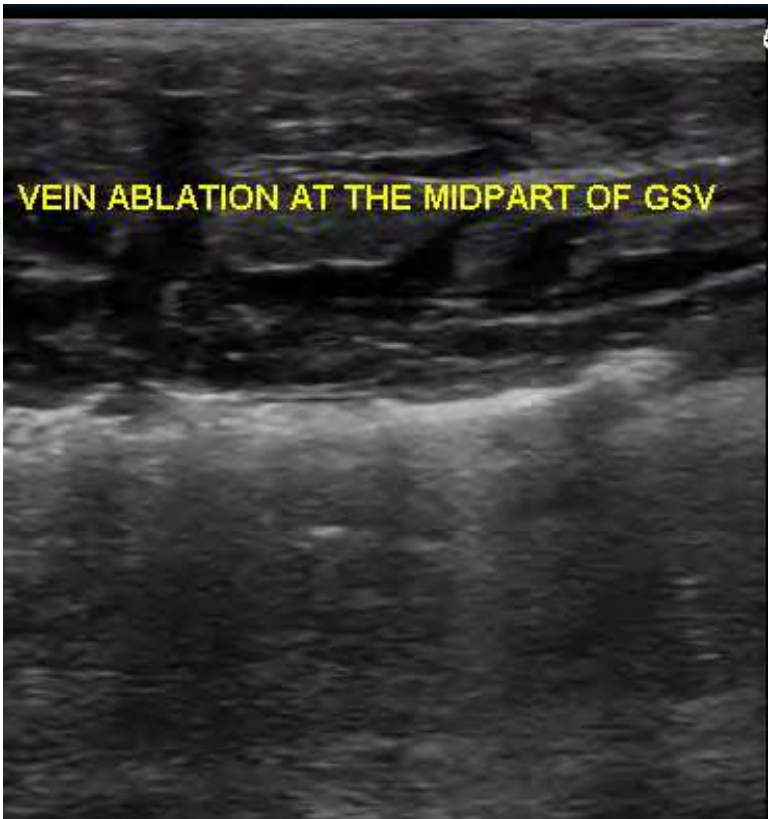


Fig. 7. Ablation at the midpart of great saphenous vein.

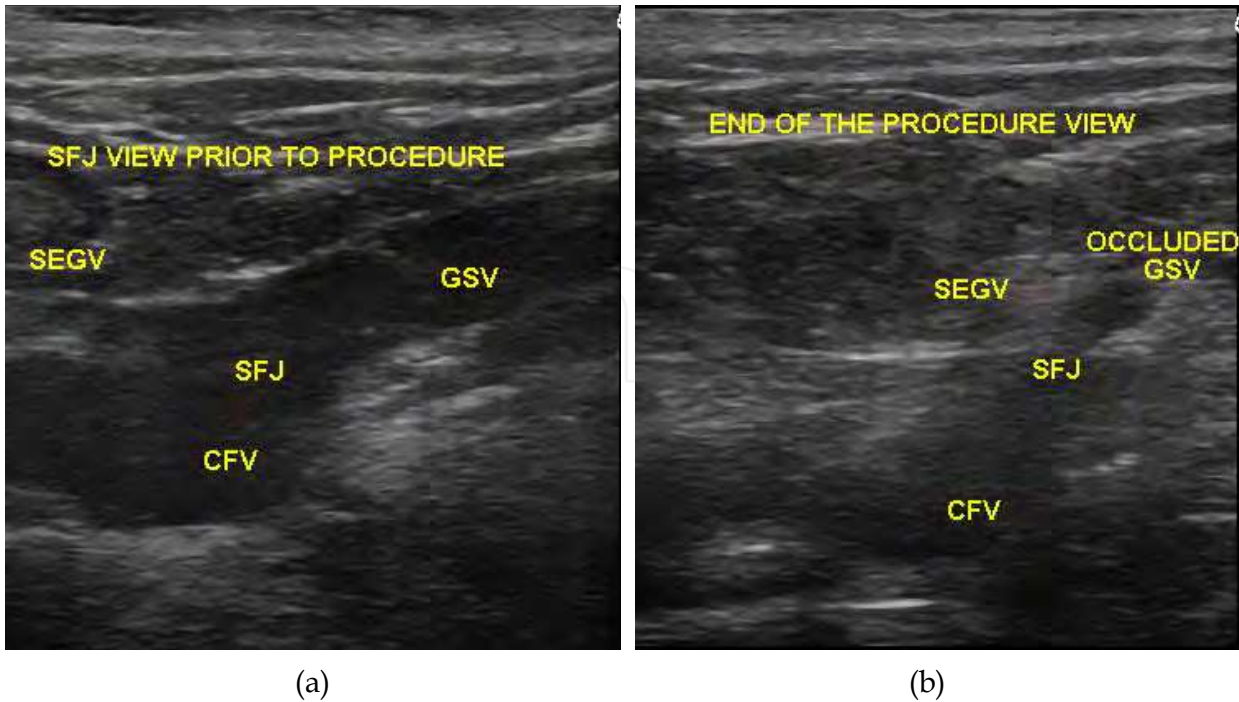


Fig. 8. Picture showing the saphenofemoral junction preoperative (a) and immediate (b) after the procedure.

EVLA for incompetent perforator veins (IPVs) is a more demanding procedure when compared to GSV and SSV ablation. The key point in the EVLA of perforator vein is the vein access. Patient is placed in a reverse Trendelenburg position and a direct puncture is made under ultrasound guidance with a 21 Gauge micropuncture needle or 16 Gauge angiocatheter. There is no specific catheter or fiber system for treating perforator veins. However, 400 μ m, 600 μ m fibers can be used. Recently, Biolitec Company introduced a 200 μ m slim radial fiber for the treatment of IPVs. After gaining access, confirmation is performed by aspiration of the blood. Then the laser fiber should be positioned at the fascia level. Following the confirmation of the correct position, tumescent local anesthesia is administered around the vein. Then energy is applied to the vein. External compression with ultrasound probe may help to increase vein wall the contact. In our clinical experience, while treating IPVs we do not use continuous pull back, rather we prefer pulsed mode. Since there are conflicting results and high recanalization rates in the literature, we prefer to ablate every vein segment twice and to treat the possible longest vein segment. (8) After completion of laser ablation a compression should be applied over the vein for several minutes. Following the compression, confirmation of the occlusion of the vein is made with ultrasound and recorded.

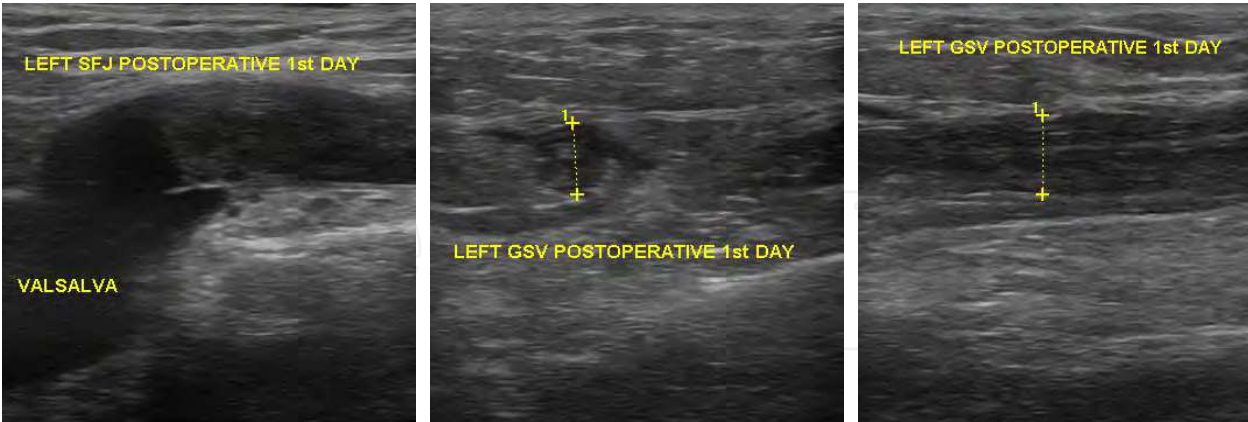
5.4 Postoperative care

After the completion of the ablation procedure, patients should be placed on compression therapy. There are different compression therapy protocols in the literature. In our clinical experience, we have two different policies which are determined by the applied procedure. In the patient that we performed concomitant extensive phlebectomies, we use the external compression bandages (short-stretch) for the following 24 hours and then we use 23-32 mmHg compression stockings (thigh high) for the following 4 weeks. If we do not perform concomitant phlebectomies, we directly use compression stockings for the following 4 weeks. There are different conflicting recommendations about the duration and the need for the postoperative compression therapy. In a preliminary study by Berland et al., (26) it was reported that no detrimental effect was shown with the absence of post-procedural compression therapy.

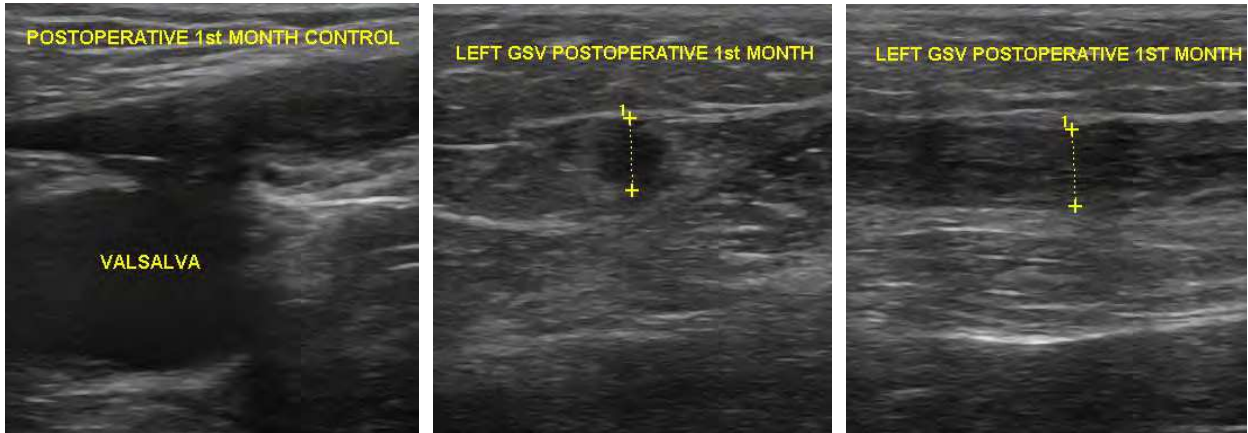
In the earlier studies low molecular weight heparin was recommended for the 8days following the procedure. In the beginning of our experience we also used this protocol. However after gaining experience, we do not use low molecular weight heparin in our patients excluding patients with obesity and older age. We use non steroid antiinflammatory drugs (i.e. diclofenac potassium, 75 mg, bid, p.o.), if necessary. Patients are advised to walk regularly during recovery from treatment.

6. Follow-up

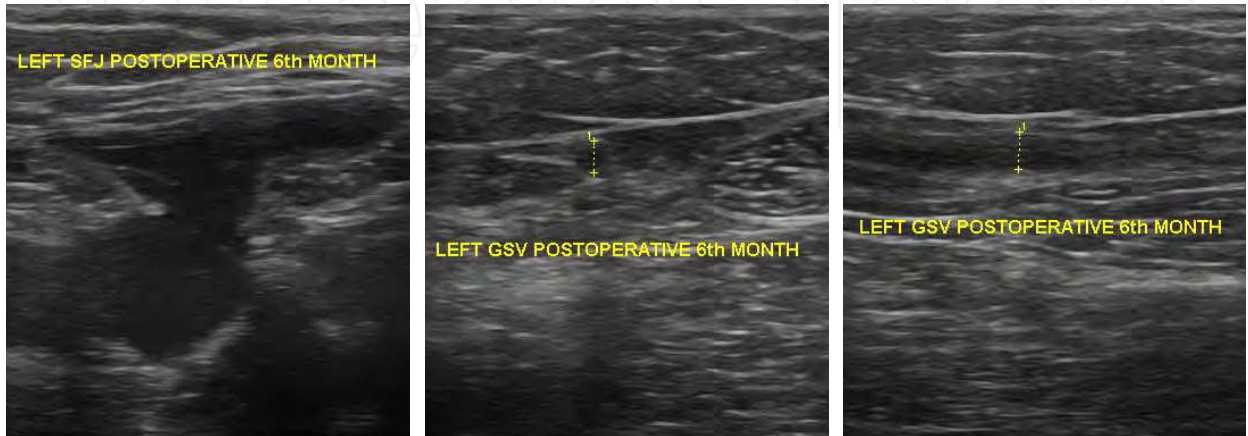
Since there is the possibility of recanalization and/or incomplete ablation, patients should be controlled at appropriate intervals with physical examination and color-flow Doppler ultrasound. In the physical examination, any recurrent and/or new refluxing tributaries are recorded. Any signs or symptoms related with chronic venous insufficiency are also recorded. With the color-flow Doppler ultrasound occlusion of the ablated vein is examined. In our clinical protocol patients are seen at 1st week, 1st month, 3rd month, 6th month, 1st year and yearly thereafter. (Figure 9)



(a)



(b)



(c)

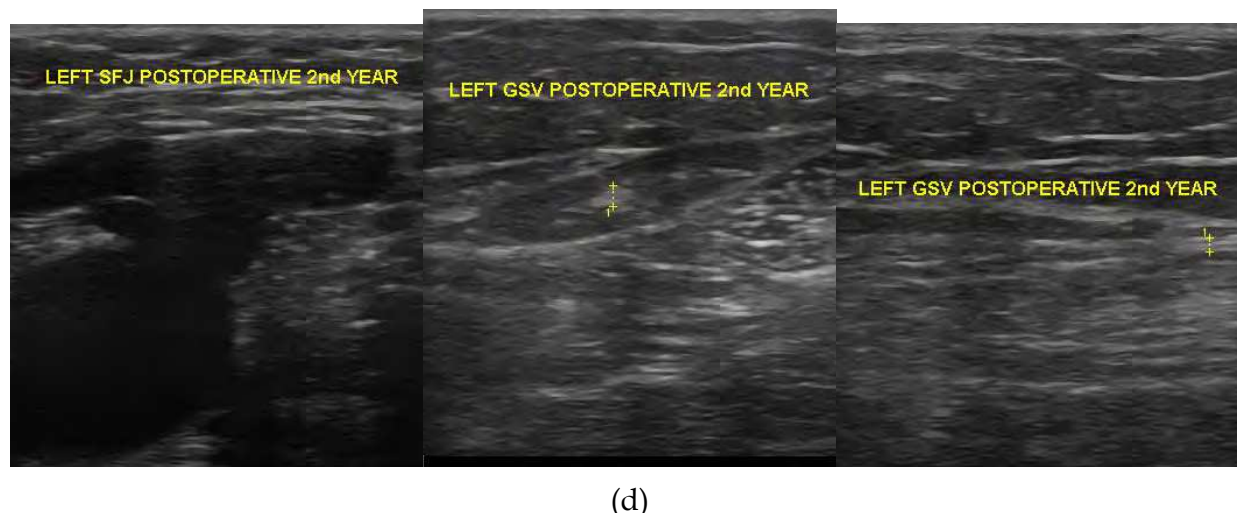


Fig. 9. Postoperative follow-up doppler images of the same patients postoperative 1st day (a), postoperative 1st month (b) 6th month (c), 2nd year (d)

7. Complications

Complications of EVLA may be divided as procedure related and post-procedural events. Procedure related complications are generally related with technical difficulties. These are vein access and fiber advancement problems. As mentioned above warm and comfortable operating rooms may solve the problems related with venospasm. Also determining the most suitable place for puncture by Doppler ultrasound is important. A straight and appropriate size vein segment usually solves the problem.

Postoperative bruising, pain, paresthesia, and induration are the most common adverse events. However, there are also other adverse events such as superficial thrombophlebitis, skin burn, deep vein thrombosis, infection, arteriovenous fistula and skin burn. Although these later adverse events are literally possible, they are uncommon. (16)

Bruising is generally minimal and self-limiting and usually lasts less than two weeks period. (Figure 10) There are different rates of bruising in the literature (between 11-100%). (26) Bruising rates are higher with wavelengths that use hemoglobin as chromophore such as 810 nm and 980 nm. However, Laser systems with emission wavelengths of 1320 nm and 1470 nm have their main absorption in water. There are reduced postoperative pain and bruising with 1320 nm when compared to shorter wavelengths. In our previous randomized study, we compared 1470 nm with 980 nm for early postoperative adverse events and found that 1470 nm wavelength was superior with reduced postoperative pain, bruising, and paresthesia. Furthermore patient satisfaction was also higher with 1470 nm. (27)

Incidence of postoperative paresthesia is reported between 7 and 9.5%. Paresthesia is also mild and usually resolves average an 8 week period. It is mainly seen following the full length ablation of the GSV. However the situation is different for SSV which has very close relationship with nerves along with its anatomic course. In some studies temporary paraesthesia is reported as frequently as in 40% of limbs following the EVLA for the SSV. (25) In our clinical experience, incidence of paresthesia following EVLA for GSV with 1470 nm is very low (1/54 limbs). The incidence may be reduced with partial (over the knee)

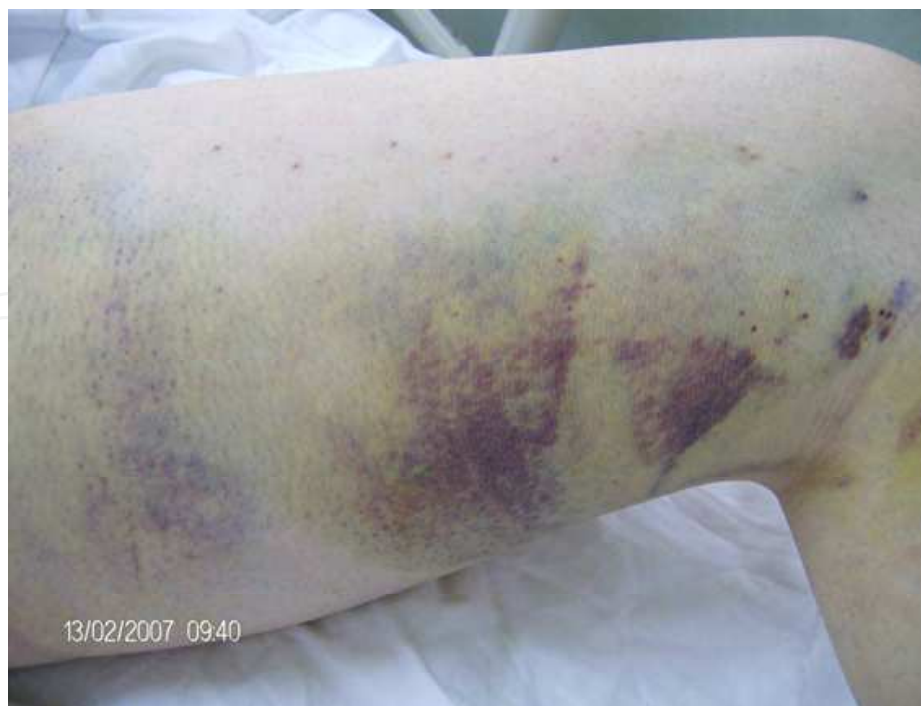

Fig. 10. Postoperative bruising. (980 nm and bare-tip fibre)

ablation and accurate administered perivenous tumescent local anesthesia. In another study, we compared the postoperative nerve injury following SSV EVLA. Puncture site from the midcalf level was shown to decrease the paresthesia. (25).

Indurations happen along the treated veins after EVLA that resembles either a palpable cord or the feeling of a shortened muscle at the medial part of the thigh. According to our study induration is more common with bare tip fibers, shorter wavelengths (i.e. 810nm, 980 nm), and higher LEED levels. Since they ablated the vein only the places that they contact the vein wall, bare tip fibers especially at the higher LEEDs may perforate the vein and extravasation of the leukocytes cause pain and the induration. Nowadays with use of radial fibers, longer wavelengths (such as 1470 nm), and lower LEED levels, the incidence of induration decreased dramatically. (28)

Skin burn is very rare complication. In the literature excluding the study by Chang et al. (29) in which no tumescent anesthesia was used, only nine cases of burns have been reported; two occurred when no local anesthetic was used and two during treatment of tributaries. This situation emphasizes the importance of tumescent local anesthesia, especially in the very superficial veins. In our experience, we have never seen skin burns.

Infection is very rare complication. However, there is a case report of septic thrombophlebitis following EVLA. (30) With adequate sterile technique infection is avoided. Skin burn is also a rare complication. This can be avoided by scrupulous technique plus injection of correct and adequate amount of tumescent local anesthesia. We have never seen infection and skin burn related with the EVLA procedure so far.

Although it is rare, deep vein thrombosis is the most severe complication. In our experience no deep vein thrombosis was recorded so far. Endothermal Heat Induced Thrombosis (EHIT) (Regardless of the energy, either laser or radiofrequency) is now used for the propagation of

thrombus in to the deep system as a new terminology. (Table 1) EHIT II is considered to be significant, since it is a precursor to deep vein thrombosis. In a study by Sadek et al. incidence of EHIT II in patients treated with endovenous laser and radiofrequency was evaluated. They concluded that there was no significant difference between laser and radiofrequency for the incidence of EHIT II, and upon identification it should be treated using anticoagulation. (31)

Hyperpigmentation along the ablated vein occurs in up to 12% patients, although most authors report a much lower incidence. It usually improves in time. (27)

I	Thrombosis to the level of the saphenofemoral (SF) junction
II	Extension into the deep venous system, cross-sectional area $\leq 50\%$
III	Extension into the deep venous system, cross-sectional area $\geq 50\%$
IV	Occlusion of the femoral vein

Table 1. Endothermal Heat Induced Thrombosis (EHIT) classes (30)

Complications related with the laser ablation of the incompetent perforator veins are also similar with great/small saphenous veins such as skin injury, nerve injury and deep vessel injury. However there is no clear data about the prevalence of these complications due to the limited number of studies with limited patient volumes. In one study, redness, numbness or blistering was reported as complication. (8)

8. Outcomes

Since the first publication of Navarro et al. in 2001, (12) many authors reported their experience on different wavelengths, fibers and veins. Also Van den Bos et al. (3) published the first review of endovenous therapies of lower extremity varicosities in 2009. There are almost similar results with successful ablation and low adverse events rates. Some of the studies and their results are summarized in Table 2.

In some studies EVLA was compared to surgical stripping. Especially in the randomized trials, it was suggested that abolition of GSV reflux, improvements in quality of life, patient satisfaction and cosmetics are similar for both treatment modality. Although pain levels appear similar in both techniques, return to normal activity or work was reported earlier after EVLA. (3)

Importance of wavelength is also matter of question. There is not so much data regarding the effects of wavelengths that can be used for a decision-making tool for the treatment of varicose veins. Proebstle et al. (19) compared 1320 nm Nd:YAG laser with 940 nm diode laser and concluded that endovenous laser treatment using a 1320 nm Nd:YAG laser causes fewer side effects compared with 940 nm diode laser. In our randomized clinical study we compared the 1470 nm diode laser with commonly used 980 nm diode laser for the adverse event and the varicose venous clinical severity scores (VCSS). At early postoperative period 1470 nm diode laser was superior in both adverse events and VCSSs. (28)

There is now also experience in patients with recurrent varicosities. Theivacumar et al. (32) reported their experience on 104 limbs of 95 patients with recurrent varicose veins. They successfully ablated these varicosities and concluded that EVLA was a safe and effective

Author	Number of limbs	Occlusion Rate (%)	Follow-up Period
GSV			
810 nm	499	93	2 year
Min, 2003	1076	97	3 years
Agus, 2006			
940 nm			
Ravi, 2006	990	97	3 years
Proebstle, 2003	41	95	6 months
980 nm			
Gibson, 2007	210	96	4 months
Pannier, 2008	67	88.1	2.2 years
1470 nm			
Pannier, 2009	128	100	1 year
Doganci, 2010	54	100	6 months
SSV			
810 nm			
Huisman	169	98	3 months
980 nm			
Desmyttere, 2009	147	97	1 years
Park, 2008	55	100	3 years
1470 nm			
Doganci, 2011	68	100	6 months

Table 2. Outcomes following endovenous laver ablation

option for the treatment of recurrent varicose veins. In our clinical experience between February 2010 and February 2011, we treated 46 limbs of 39 patients with recurrent varicose veins. Our results are also similar to Theivacumar’s results. Treatment of recurrent varicosities especially in patients with previous surgical stripping is very easy and safe. As a simple rule it can be said that “if you cannulate, you can treat any vein” with indication of treatment.

Due to its anatomic localization treatment of incompetent SSV with endovenous laser ablation is superior to surgical stripping. Rashid et al. (7) have shown that ligation of the saphenopopliteal junction (SPJ) is not achieved in 30% of the cases, even if the junction is marked pre-operatively under ultrasound guidance. In the endovenous laser ablation, there is not a problem like that. If there is anatomic SPJ, you can treat the incompetent SSV without having any surgical difficulties. As it is summarized in Table 2 the results are very promising so far.

In the review by Van Den Bos et al. (3) success rate of EVLA after a five year period was 95.4%. Although there are articles with very promising results, there is still a need for randomized controlled studies with long term results.

In our clinical experience (not published yet), we treat 717 patients (1066 limbs) with 1470 nm diode laser and radial laser fiber between September 2009 and March 2011. There was no recanalization so far in this cohort of patients during the follow-up period.

Results for endovenous treatment of IPVs are not so much as it is in GSVs. Kabnick et al. (33) presented data using a 980 nm wavelength. Twenty-five IPVs with an average size of

4.4 mm were treated. Closure rate was 85% at a 4 month period. In another study Murphy et al. (34) reported 100% closure rate at a 6 months period.

9. Discussion

Traditional surgical methods to treat varicose veins are associated with significant complications, high recurrence rates and some patient dissatisfaction. In a randomized trial of SFJ ligation methods for primary saphenous incompetence, the two year clinical recurrence rate was 33% and Doppler ultrasound (DUS) proven recurrence was up to 22%. However, the clinical benefits and cost-effectiveness of surgery are well established. (35)

Minimally invasive techniques such as EVLA are a popular choice for patients and doctors because of the low risk of complications, short “downtime,” and excellent cosmetic results. When applied properly, these techniques also seem to be effective and safe. For efficacy and safety, it is essential that professionals well trained in phlebology and ultrasound examination perform these complex procedures, but pain and ecchymoses seem to be inherent to all (minimally invasive) procedures of varicose veins including EVLA. (17)

In recently published studies, high success rates after EVLA have been reported. These have been based mainly on duplex US assessment of the treated veins.

Three recent systematic reviews, two with meta-analysis, have attempted to analyse all of the relevant literature comparing surgical outcomes to UGFS, RFA and EVLA, and another has compared safety and efficacy of EVLA and surgery. The largest meta-analysis examined 64 eligible studies, which included over twelve thousand limbs, with DUS findings as outcome. Average follow-up was 32 months and estimated pooled success rates at 3 years were highest for EVLA with 94%, followed by RFA (84%), surgery (78%) and foam sclerotherapy (77%). EVLA was significantly superior to all other methods to abolish saphenous incompetence. (3, 35) RFA and UGFS were equally effective as surgery. This analysis has had some criticism, as most studies reviewed had not used survival analysis, so the success rates are probably inflated. In a separate meta-analysis, the improved effectiveness of EVLA is confirmed over surgery, with better post-operative outcomes. However venous clinical severity scores (VCSS) were equivalent between EVLA and surgery at end of followup. Another systematic review compared safety and efficacy of all treatments, new and old, where articles reported comparisons between at least two treatments. This review demonstrated better safety records for both EVLA and RFA compared to surgery, although major surgical complications were rare. Surgery consistently caused more post-operative bruising overall and more post-operative pain than both EVLA and RFA. Paraesthesia was the most common serious adverse event associated with surgery occurring at a median rate of 11.7% (4.1-30.3%) reported among 517 limbs and ten studies. (35)

In the EVVERT study comparing laser and radiofrequency, 810 nm laser and bare-tip laser fibers compared with VNUS ClosureFast catheter. As it is expected in the result part, pain scores was lower in the radiofrequency group, and bruising was greater in the laser group. (36) However, it is comparison is not well balanced. Simply saying, in this study the authors compared the brand new catheter of VNUS (ClosureFast) with the oldest laser technology. There is now new generation laser and fiber system commercially in use from a very long time. And the conclusion should not be laser generates greater perioperative bruising and pain than radiofrequency. Instead, it should be as 810 nm laser and the bare-tip fiber

generates greater bruising and pain than radiofrequency. Thus, this study should be designed to compare the new generation laser systems (i.e. 1470 nm diode or 1320 Nd:YAG lasers and radial laser fibers). In our previous study, 1470 nm diode laser and radial laser fibers were compared with 980 nm and bare-tip fibers in randomized controlled groups. We found that side effects such as pain, induration (14 vs 3 (radial)), ecchymosis (13 vs 2 (radial)) and paraesthesia (9 vs 1 (radial)) were significantly reduced with the 1470 nm laser and radial catheter system compared to the 980 nm bare-tip laser fibre.

In the review by Van den Bos et al., (3) besides anatomic success rates, patient-reported outcomes such as health related quality of life (HRQOL), treatment satisfaction, symptom relief, and side effects were analyzed. Compared with surgery, EVLA-treated patients appreciated EVLA more than surgery because they reported fewer side effects and their HRQOL improved better and faster.

In our study, patient satisfaction and patient preference were questioned. Most of the patients in 1470 nm and radial laser-fiber group replied as "very satisfied-satisfied" and "definitely-probably yes". The difference was statistically significant ($p < 0.05$). Venous Clinical Severity Scores also evaluated. VCSSs in the first month were also favorably lower in 1470 nm and radial laser fiber group.

In another study which is similar to ours, Gerard JL et al. (37) questioned "Is bare-tip fiber out-dated?" in their study. They used 1470 nm diode laser and compared bare-tip fiber with radial fiber. As a conclusion they declared that protected fibers should be recommended as bare-tip fibers have proved to be out-dated.

Laser fibers are evolving with the technological advances. Nowadays after learning the importance of fibers, many fibers come-out. Direct vein wall contact of the tip of the fiber cause carbonization of the wall. This can induce perforations leading to bruising and pain related to white blood cell extravasation. (28) For avoiding direct wall contact of the fiber many manufacturers produced alternative fibers such tulip, jacket-tip and radial fibers.

Another point is the amount of delivered energy. There are many different formulas to calculate the amount of energy per centimeter which is known as LEED. As a simple rule a minimum of 10 J/cm/diameter is an effective amount. In our experience we generally use this formula.

In our clinical experience, after gaining experience and seeing results of our patients; we gradually decreased our watt and LEED levels. At the beginning of our 1470 nm and radial fiber experience, we begin with 15 Watts and 90 J/cm LEED level. There was no recanalization, and minimal postoperative morbidity. Then we gradually decreased our watt level to 12 W and LEED level to 70 J/cm. These parameters are very effective. They do not affect the recanalization rates. Furthermore our adverse event rate is nearly approach to minimum. With these improvements we are now gradually decreasing the amount of tumescent local anesthesia.

These improvements increase the office-based nature of the endovenous laser treatment modality. Patients tolerate this procedure well.

However there is still a need for the long-term results and strong evidences, especially in the area of HRQOL and follow-up protocols. There is still an ongoing competition between the

endovenous treatment modalities. Recently steam ablation and the mechanochemical ablation devices (ClariVein) added to this competition area. The results of these new modalities are also beginning to come.

Evolving Doppler ultrasound technology will also help the physicians to increase their success in endovascular techniques by providing excellent diagnostics and perioperative imaging options.

In our opinion next decade will witness the outcome of some other new techniques. Long-term result of the treatment modalities will be available and by these results strong evidences will also be available.

According to the American Venous Forum Guidelines (4.10.0) recommendation endovenous laser therapy of GSV is safe and effective and has a grade 1A recommendation level. Recommendation for the IPV (4.21.0) has a lower evidence level and is grade 2C. (8, 22)

10. Summary

Endovenous laser ablation is a safe and effective treatment modality in the treatment of incompetent great and small saphenous veins. With an obsessive approach to all technical steps and patient selection criterion, incidence of adverse events and complication is very low. Although we still need long-term result and strong evidences longer wavelengths and new generation laser fibers seem superior to the shorter wavelengths and bare-tip fibers. Multicenter randomized controlled trials with larger patient volume and standard long-term follow-up protocols are still needed to answer our questions.

However, with the available results and patient/physician preferences it can be said that conventional high ligation plus stripping of the incompetent saphenous veins is no longer the gold standard treatment choice.

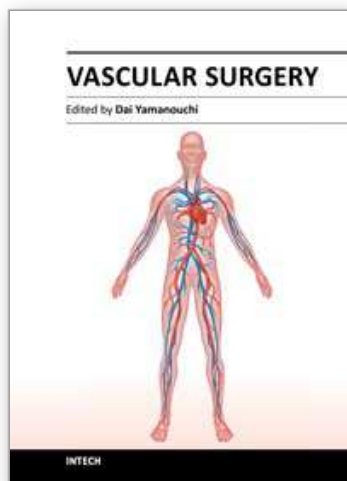
In the very near future, reticular veins, incompetent tributary veins, perforator veins beside main trunk varicosities will be treated by endovenous modalities and the patients will have the opportunity to have these procedures in best cosmetic and the least invasive ways without having stab incisions.

11. References

- [1] Maurins U, Hoffman BH, Lösch C, Jöckel KH, Rabe E, Pannier F. Distribution and prevalence of reflux in the superficial and deep venous system in the general population--results from the Bonn Vein Study, Germany. *J Vasc Surg*. 2008 Sep;48(3):680-7.
- [2] Evans CJ, Fowkes FGR, Ruckley CV, Lee AJ. Prevalence of varicose veins and chronic venous insufficiency in men and women in the general population: Edinburgh vein Study. *J Epidemiol Community Health* 1999;53:149-53.
- [3] Van den Bos R, Arends L, Kockaert M, Neumann M, Nijsten T. Endovenous therapies of lower extremity varicosities: a metaanalysis. *J Vasc Surg* 2009 Jan;49(1):230-9.
- [4] van Rij AM, Jiang P, Solomon C, Christie RA, Hill GB. Recurrence after varicose vein surgery: a prospective long-term clinical study with duplex ultrasound scanning and air plethysmography. *J Vasc Surg* 2003;38:935-43.

- [5] Huisman LC, Bruins RM, van den Berg M, Hissink RJ. Endovenous laser ablation of the small saphenous vein: prospective analysis of 150 patients, a cohort study. *Eur J Vasc Endovasc Surg* 2009; 38:199-202.
- [6] Gerard JL. Small saphenous vein ablation: particularities and precautions. In: Becquemin JP, Alimi YS, Gerard JL, editors. *Controversies and updates in vascular surgery* 2009. Torino:Edizioni Panminerva Medica; 2009. p. 450-4.
- [7] Rashid HI, Ajeel A, Tyrrell MR. Persistent popliteal fossa reflux following saphenopopliteal disconnection. *Br J Surg* 2002;89:748-51.
- [8] Elias S. Percutaneous ablation of perforating veins. In: Gloviczki P, editors. *Handbook of venous disorders*. London:Hodder Arnold; 2009. P. 536-44.
- [9] Sato DT, Goff CD, Gregory RT. Subfascial perforator vein ablation: comparison versus endoscopic techniques. *J Endovasc Surg* 1999;6:147-54
- [10] Nezlen D. Prospective study of safety, patient satisfaction and leg ulcer healing following saphenous and subfascial endoscopic perforator surgery. *Br J Surg* 2008; 87:86-91.
- [11] Puglisi B, Tacconi A, San Filippo F. L'application du laser ND-YAG dans le traitement du syndrome variqueux. [Application of theND-YAG laser in the treatment of varicose syndrome]. In: Davey A, Stemmer R, editors. *Phlebology'* 89. London: J Libby Eurotext; 1989. p. 39-842.
- [12] Navarro L, Min RJ, Bone C. Endovenous laser: a new minimally invasive method of treatment for varicose veins: preliminary observations using an 810 nm diode laser. *Dermatol Surg* 2001; 27:117-22.
- [13] Forrestal MD, Min RJ, Zimmet SE, Isaacs MN, Moeller MR. Endovenous laser treatment (EVLTTM) for varicose veins—A review. In: *Today's Ther Trends*. Princeton Junction, NJ: Communications Media for Education. 2002. 20(4): 299–310.
- [14] Proebstle TM, Gül D, Kargl A, Knop J. Endovenous laser treatment of the lesser saphenous vein with a 940 nm diode laser—Early results, *Dermatol Surg*. 2003. 29: 357–361.
- [15] Proebstle TM, Herdeman S. Feasibility of incompetent perforator vein ablation by endovenous laser treatment. In: Presented at the German Phlebologic Society Annual Meeting, September 2005
- [16] Pannier F, Rabe E, Maurins U. First results with a new 1470-nm diode laser for endovenous ablation of incompetent saphenous veins. *Phlebology* 2009;24:26-30.
- [17] Van Den Bos RR, Neumann M, De Roos KP, Nijsten T. Endovenous laser ablation-induced complications: review of the literature and new cases. *Dermatol Surg* 2009 Aug;35(8):1206-14.
- [18] Van den Bos RR, Kockaert MA, Neumann HA, Nijsten T. Technical review of endovenous laser therapy for varicose veins. *Eur J Vasc Endovasc Surg* 2008;35:88-95.
- [19] Proebstle TM, Moehler T, Gul D, Herdemann S. Endovenous treatment of the great saphenous vein using a 1320 nm Nd:YAG laser causes fewer side effects than using a 940 nm diode laser. *Dermatol Surg* 2005;31:1678-83.
- [20] Almeida J, Mackay E, Javier J, Mauriello J, Raines J. Saphenous laser ablation at 1470 nm targets the vein wall, not blood. *Vasc Endovascular Surg*; 2009 Jul 23.
- [21] Kabnick LS, Caruso JA. No-wall touch laser fiber vs bare-tip laser fiber for endothermal venous ablation of great saphenous vein: are the results the same? In: Gerard JL, editor. *Controversies and updates in vascular surgery*. 1st ed. Torino: Edizioni Panminerva Medica; 2008. p. 401-2.

- [22] Morrison N. Laser treatment of the incompetent saphenous vein. In: Gloviczki P, editor. Handbook of venous disorders. London:Hodder Arnold; 2009. P. 418-28.
- [23] Theivacumar NS, Gough MJ. Influence of warfarin on the success of endovenous laser ablation (EVLA) of the great saphenous vein (GSV). *Eur J Vasc Endovasc Surg.* 2009 Oct;38(4):506-10
- [24] Theivacumar NS, Beale RJ, Mavor AI, Gough MJ. Initial experience in endovenous laser ablation (EVLA) of varicose veins due to small saphenous vein reflux. *Eur J Vasc Endovasc Surg* 2007; 33:614-8.
- [25] Doganci S, Yildirim V, Demirkilic U. Does puncture site affect the rate of nerve injuries following endovenous laser ablation of the small saphenous veins? *Eur J Vasc Endovasc Surg.* 2011 Mar;41(3):400-5.
- [26] Berland T, Kabnick L, Rudarakanchana N, Chasin C, Sadeck M, Rockman C, Maldonado T, Cayne N, Jacobowitz G, Lamparillo P, Mussa F, Adelman M. Compression vs. no compression after endovenous ablation of the great saphenous vein. In: Jean-Pierre Becquemin, editor. *Controversies and Updates in Vascular Surgery* 2011. Torino (Italy): Edizioni Minerva Medica; 2011.p. 622-26.
- [27] Darwood RJ, Gough MJ. Endovenous laser treatment for uncomplicated varicose veins. *Phlebology.* 2009;24 Suppl 1:50-61.
- [28] Doganci S, Demirkilic U. Comparison of 980 nm laser and bare-tip fibre with 1470 nm laser and radial fibre in the treatment of great saphenous vein varicosities: a prospective randomised clinical trial. *Eur J Vasc Endovasc Surg.* 2010 Aug;40(2):254-9
- [29] Chang CJ, Chua JJ. Endovenous laser photocoagulation (EVLP) for varicose veins. *Lasers Surg Med* 2002;31: 257-62
- [30] Dunts K, Huemer G, Wayant W, Shamiyeh A. Diffuse phlegmonos phlebitis after endovenous laser treatment of the greater saphenous vein. *J Vasc Surg* 2006; 43:1056-8.
- [31] Sadek M, Kabnick L, Berlant T, Chasin C, Rudarakanchana N, Rockman C, Maldonado T, Cayne N, Jacobowitz G, Lamparillo P, Musa F, Adelman M. Vein thrombosis induced by laser or radiofrequency: the winner is... In: Jean-Pierre Becquemin, editor. *Controversies and Updates in Vascular Surgery* 2011. Torino (Italy): Edizioni Minerva Medica; 2011.p. 653-57.
- [32] Theivacumar NS, Gough MJ. Endovenous laser ablation (EVLA) to treat recurrent varicose veins. *Eur J Vasc Endovasc Surg.* 2011 May;41(5):691-6.
- [33] Kabnick L. Perforator vein treatment. In: Presented at the Vein Meeting, Uncasville CT, June 2006.
- [34] Murphy R. Comparison of radiofrequency and laser for perforator treatment. American College of Phlebology, Poster Session, November, 2006.
- [35] McBride KD. Changing to endovenous treatment for varicose veins: how much more evidence is needed? *Surgeon.* 2011 Jun;9(3):150-9.
- [36] Nordon IM, Loftus IM. EVVERT comparing laser and radiofrequency: An update on endovenous treatment options. In: Greenhalgh RM, editor. *Vascular and Endovascular consensus update.* London. BIBA Publishing; 2011.p.381-88.
- [37] Gerard JL, Daoud M. Is bare-tip fiber out-dated? ... In: Jean-Pierre Becquemin, editor. *Controversies and Updates in Vascular Surgery* 2011. Torino (Italy): Edizioni Minerva Medica; 2011.p. 648-52.



Vascular Surgery

Edited by Dr. Dai Yamanouchi

ISBN 978-953-51-0328-8

Hard cover, 262 pages

Publisher InTech

Published online 04, April, 2012

Published in print edition April, 2012

This book aims to provide a brief overview of conventional open vascular surgery, endovascular surgery and pre- and post-operative management of vascular patients. The collections of contributions from outstanding vascular surgeons and scientists from around the world present detailed and precious information about the important topics of the current vascular surgery practice and research. I hope this book will be used worldwide by young vascular surgeons and medical students enhancing their knowledge and stimulating the advancement of this field.

How to reference

In order to correctly reference this scholarly work, feel free to copy and paste the following:

Suat Doganci and Ufuk Demirkilic (2012). Endovenous Laser Treatment of Incompetent Superficial and Perforator Veins, Vascular Surgery, Dr. Dai Yamanouchi (Ed.), ISBN: 978-953-51-0328-8, InTech, Available from: <http://www.intechopen.com/books/vascular-surgery/endovenous-laser-treatment-of-incompetent-superficial-and-perforator-veins>

INTech
open science | open minds

InTech Europe

University Campus STeP Ri
Slavka Krautzeka 83/A
51000 Rijeka, Croatia
Phone: +385 (51) 770 447
Fax: +385 (51) 686 166
www.intechopen.com

InTech China

Unit 405, Office Block, Hotel Equatorial Shanghai
No.65, Yan An Road (West), Shanghai, 200040, China
中国上海市延安西路65号上海国际贵都大饭店办公楼405单元
Phone: +86-21-62489820
Fax: +86-21-62489821

© 2012 The Author(s). Licensee IntechOpen. This is an open access article distributed under the terms of the [Creative Commons Attribution 3.0 License](https://creativecommons.org/licenses/by/3.0/), which permits unrestricted use, distribution, and reproduction in any medium, provided the original work is properly cited.

IntechOpen

IntechOpen