

We are IntechOpen, the world's leading publisher of Open Access books Built by scientists, for scientists

6,900

Open access books available

186,000

International authors and editors

200M

Downloads

Our authors are among the

154

Countries delivered to

TOP 1%

most cited scientists

12.2%

Contributors from top 500 universities



WEB OF SCIENCE™

Selection of our books indexed in the Book Citation Index
in Web of Science™ Core Collection (BKCI)

Interested in publishing with us?
Contact book.department@intechopen.com

Numbers displayed above are based on latest data collected.
For more information visit www.intechopen.com



Minimal Invasive Surgery in Head and Neck Video-Assisted Technique

Jorge O. Guerrissi

Department of Plastic Surgery,

Argerich Hospital, Buenos Aires,

Medicine Faculty of Buenos Aires University (UBA)

Plastic Surgery Academic Unit Buenos Aires University

Argentina

1. Introduction

The recent advent of endoscopic procedures has compelled to plastic surgeons to reconsider the conventional methods by which the excision different type of head and neck tumors are classically achieved. Endoscopic resection is a safe and minimally invasive approach and spares unnecessary discomfort to the patient.

The introduction of endoscopy into surgical practice is one of the biggest successes in the history of medicine; the recent advents of endoscopic procedures have revolutionized the practice of surgery in many specialties.

The outcome achieve with endoscopic techniques in other surgical areas has permitted to considerer this technique in head and neck offering more advantages than the classic approaches. (1)(2)(3)(4)(5).

Plastic surgeons have been compelled to consider the video-assisted surgical technique as a safe and effective technique in the treatment of benign tumor in head and neck.

This technique has many advantages as minimal morbidity; significantly decreased scarring and it also enhance the surgeon's ability to view the area decreasing the danger of injuring anatomical structures.

In Department of Plastic Surgery at Argerich Hospital in Buenos Aires, Argentina from 1999 to 2007 video-assisted approaches were used in the treatment of 108 patients whom presented: 1. Frontocygomatoc cysts; 2. Benign subcutaneous tumors in frontal, nasal and facial areas; 3. Benign tumors and sialolithiasis of submandibular gland; 4. Wharton duct obstruction by sialolith; 5. Benign tumors in sublingual gland, and 5. Branchiogenic cervical cysts and 6. Cervical lipomas.

In this paper to be described not only endoscopic techniques for several diseases in head and neck , but also project the use of natural orifice surgery (NOS) as a procedure with spectrum of innovative operations .(5)

2. Material and method

One hundred eight patients were operated from August 1999 to September 2007 in the Department of Plastic Surgery at Argerich Hospital of Buenos Aires, Argentine using video-assisted surgery.

Of the 108 patients 19 (18%) were more than 55 years old and the other 89 remaining patient's ages range from 11 to 55 years old (82%).

Seventy eight patients were female (70%) and 30 (30%) were males.

Thirty-six patients (20 %) presented branchiogenic cysts; 18 (50%) found 14 on the right and the remains 18 on the left; 2 lateral cervical cystic hygromas were found in the right upper third of the neck. (Figs. 1 and 2)

In the frontal area were located thirty-two tumors (18%); 16 of them were (50%) frontozygomatic cysts (Figs. 3 and 4); 8 lipomas (12,5%) and 8 osteomas (12,5%).

Three nasal epidermic cysts (4%) were detected in the middle line of the upper nasal dorsum; a transnasal approach was used as a rhinoplasty, using natural orifice surgery (NOS) (Figs. 5 and 6)

Transoral technique was used as a basic approach in Wharton obstruction, submandibular and sublingual glands tumor resections.

Wharton lithiasis was operated en 12 cases and 12 adenomas of the submandibular gland were resected 7 in right gland and 5 in left one.

Two ranulas and 1 benign adenoma were resected in sublingual gland.

In all 108 cases no severe complications were observed; in 4 cases (4,3 %) were detected hematomas, in other 2 cases wound infection and in other 2 transitory disesthesia of lingual nerve. (Table 1)

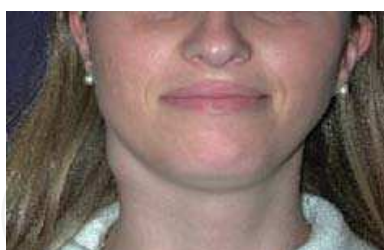

Fig. 1. Preop. Branchial cyst in right side of the neck

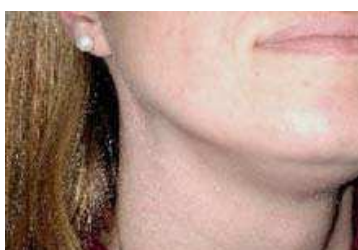

Fig. 2. Postop. Six months after surgery: Inconspicuous scar
The incision is planned on domes of the cyst in natural wrinkle.

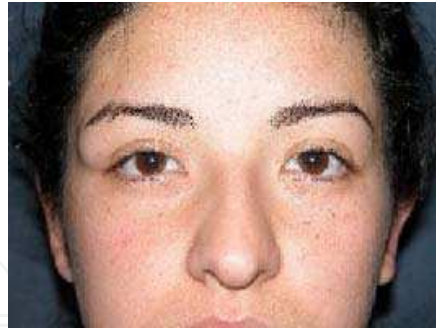

Fig. 3. Preop. Left frontocigomatic cyst

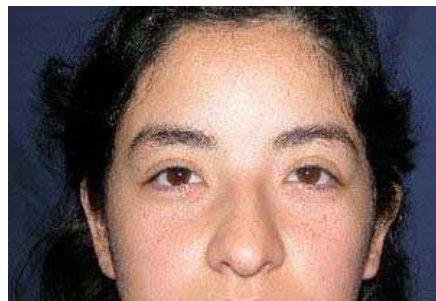

Fig. 4. One year postoperative.

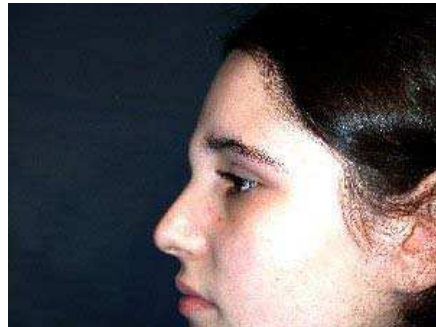

Fig. 5. Epidermic congenital nasal cyst located in the middle line

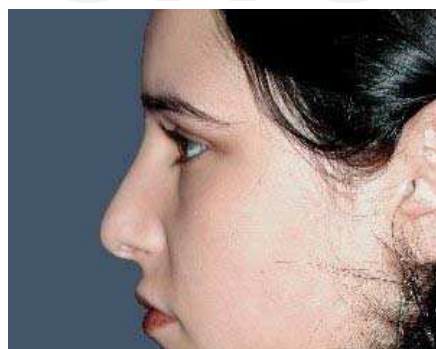

Fig. 6. After 18 months

PATHOLOGY	CASES	TECHNIQUE	NOS *	COMPLICATIONS
CERVICAL CYSTS	36	VIDEO-ASSISTED		YES WOUND INFECTION (2) HEMATOMA (1)
CERVICAL LIPOMAS	8			
HYGROMA NECK	2	IDEM		NO
FRONTOCYGOMATIC CYSTS	16	IDEM		YES HEMATOMA (2)
FRONTAL LIPOMAS	8	IDEM		NO
FRONTAL OSTEOMAS	8	IDEM		NO
NASAL CYSTS	3	IDEM	YES	NO
SUBMANDIBULAR GLAND TUMOR	12	IDEM	YES	YES HEMATOMA. (1) DISESTESIS LINGUAL NERVE (2)
SUBLINGUAL GLAND TUMOR	3	IDEM	YES	NO
WHARTON LITHIASIS	12	IDEM	YES	NO

*NOS: Natural Orifices Surgery

Table 1. Clinic Clases

3. Surgical endoscopic techniques

In all cases three basic endoscopic surgical steps were planned: 1. Incision; 2. Exposure of the tumor and 3.Resection.

An endoscope of 20 cm long with a diameter of 4 mm and vision angle of 0° and 30° was used.

A subcutaneous endoretractor permitted the stabilization of endoscope, maintaining the optical cavity and subcutaneous retraction. Special dissectors were used, as also delicate conventional or endoscopic scissors, clamps and forceps.

3.1 Branchiogenic cysts

Incision was placed in a natural wrinkle, over the middle of the protruding dome of the cyst; not more than 1,5 cm of length. The exposure of the cyst was made whit concave blades retractors placement over both cyst walls and anatomical elements around of the cyst, permitting liberation of adherences round of the cyst. (Fig. 7) Resection of cysts was carried out after liberation of carotid and internal jugular vein. (Fig. 8) (6)

In large cysts a complete aspiration was made to facilitate not only the dissection but also the extirpation.

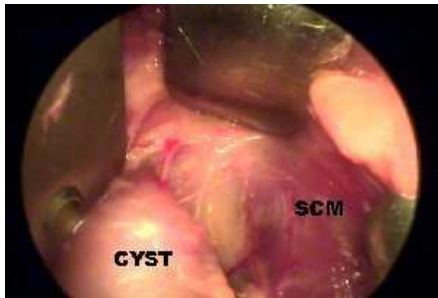


Fig. 7. Exposition and liberation of the sternocleidomastoid muscle

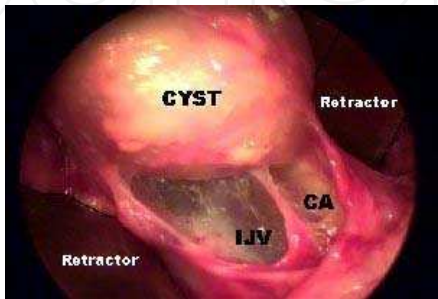


Fig. 8. Endoscopic view: Great vessels with IJV (Internal Jugular Vein) and CA (Carotid Artery) are separated of the external layer of the cyst.

3.2 Frontal tumors

Incisions (1 or 2) were placed behind of hair line (Fig 9). A subperiostic dissection was carried out in the frontal area from incisions to the tumor; tumor resection was carefully performed avoiding the injury frontal nerve. In frontocygomastic cyst resection an additional dissection on superficial temporal fascia was necessary widening operative field; the cystic liberation was carried out from orbicularis oculis muscle and the supraorbital nerve. (Fig. 10)

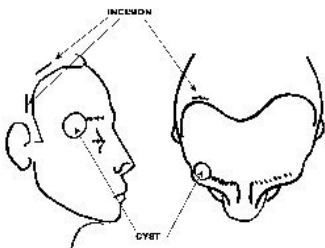


Fig. 9. Incisions placement behind of hairline.

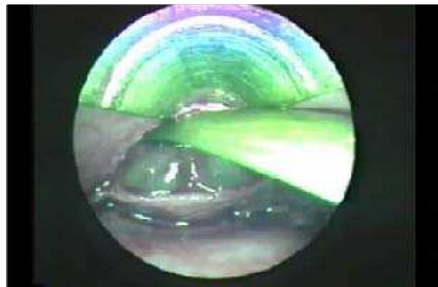


Fig. 10. Intraoperative view shows exposition and resection of the cyst.

3.3 Nasal cysts

In all 3 cases of congenital epidermic nasal cysts, a transnasal approach as a rhinoplasty was used.(Fig. 11) Cysts were exposed and resected after conventional subperiosteal skeletonizing of the nose was carried out (Fig 12).

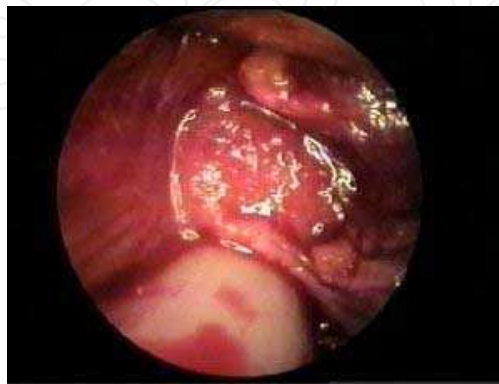

Fig. 11. Endoscopic exposition of the nasal congenital cyst.

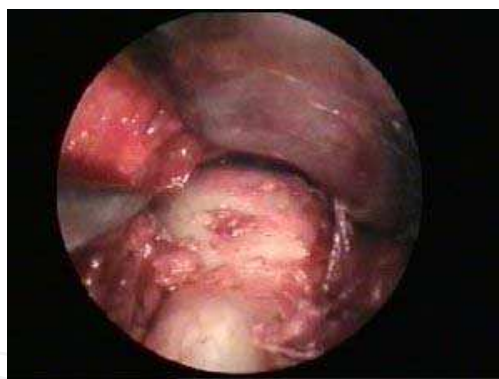

Fig. 12. After cystic resection a tumor impress on nasal bone can be observed.

3.4 Submandibular tumor resection

An incision in mandibular-lingual sulcus was preferred, after were exposed: the sublingual gland; the Wharton duct; the lingual nerve and the mylohyoid muscle.

Two oblique retractors placement over mylohyoid muscle and lingual nerve allowed the creation the “new” space with excellent submandibular gland visualization (Fig. 13). This technique had two principal “surgical key”; the first is the anatomical relation between Wharton duct and lingual nerve and the second is the posterior pole of the gland where facial vessels running.

The sublingual gland can be excised to provide optimal exposure; another useful maneuver is the digital elevation of the gland from skin to surgical field permitting an intraoral gland exposition. (Fig. 14)

Either complete gland or isolated tumor exceresis was made.

Sublingual Gland resection and Wharton sialolithiasis

Better visualization and magnified view of the sublingual gland and Wharton duct were the more important advantages. Both structures are widening exposed and surrounding anatomical landmark was protected while exceresis is carried out.

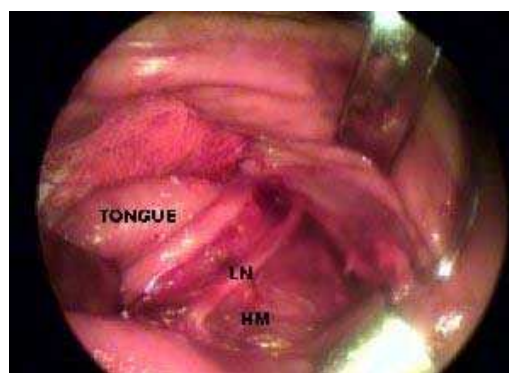


Fig. 13. “New space” where anatomical elements as lingual nerve and hypoglossal muscle are identifies.

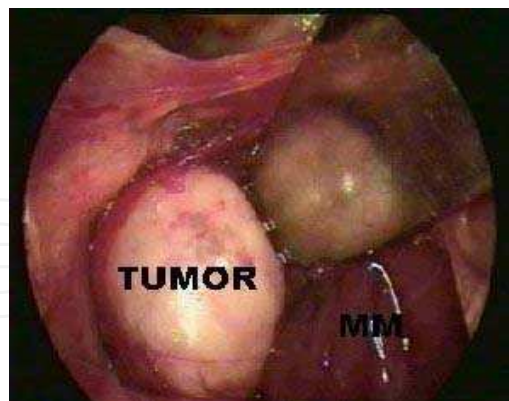


Fig.14. The mylohyoid muscle is retracted and the gland tumor is clearly exposed into surgical field.

4. Discussion

The recent advent of endoscopic procedures has compelled to plastic surgeon to reconsider the conventional methods of excision of different type of tumors placed in head and neck

areas are classically achieved. (5) In head and neck areas the use of transnasal and transoral areas are the most feasible approaches of NOS.

Benign tumors, sialoadenitis and sialolithiasis of submandibular gland are current pathologies which can be successfully treated by endoscopic surgery.

The surgery of this gland has been traditionally, performed through a cervical incision; this is a safe procedure, but some complications such a pathologic scarring and injury of the marginal mandibular nerve can occur between 1 to 7 % of cases (7) (8). Conventional intraoral approach was described in 1960 by Dawnton and Qvist (9) and Yoel in 1961. (11). In 2001 was described the use of video-assisted surgery of the submandibular gland using a transoral approach. (11). Principal advantages are good illumination and magnification providing clear and sharply vision permitting safe anatomical dissections. Technical difficulties are a reduced operative field between the tongue and mandible and a hardly dissection of the facial vessels in "posterior pole" of the gland. Three complications (25 %) were detected in all 12 patients operated with this technique: 1 hematoma and 2 transitory lingual nerve disesthesia with spontaneous recuperation 6 months later.

In the cases of the tumors located in frontal region as lipomas, osteomas and principally frontozygomatic cysts, the use of video-assisted techniques avoid visible frontal scars, hidden behind of hairline. An excellent visualization permits a dissection in avascular planes avoiding injuries of frontal nerve; subperiosteal plane provides the necessary optical cavity for operation.

In all frontozygomatic cysts additional dissection on anterior third of the temporal muscle must be performed widening surgical field. (11).

The anatomy of the nasal area is ideally suited for application of endoscopic principles; it is an expandable cavity with avascular planes of dissection and direct visualization. Hide intranasal incision is the most important advantages this technique.

According to conventional rhinoplasty technique the skeletonizing permits to achieve to cyst after scoring the periosteum over dorsum as high as nasofrontal area; a compression dressing prevent formation of a hematoma and facilitate tissue adhesion.

The ideal treatment of a branchial cleft cyst is the complete resection. One of the most evident advantages of the endoscopic resection is the use of a small incision onto a natural wrinkle; the length of it is no more than 1,5 cm.

This incision permits to introduce both endoscope and surgical instruments.

The identification and protection of nerves and vessels around cysts is most important surgical maneuver. While a concave retractor is placed on the cyst wall, another retractor is in front of it protecting identified anatomical elements.

In large cysts, the content must be partially aspirated to facilitate the surgical maneuvers of dissection and exceresis. In all 35 cases of branchiogenic cysts, no severe complications were observed.

Two patients (13%) presented partial wound infections, which healed leaving a more evident scar.

In 32 patients (90%), the final scars were inconspicuous and remain occluded in a natural cervical fold.

In all 108 patients minimal or no pain was reported, and analgesic drugs were only necessary in the first postoperative hours; any kind of discomfort was claimed by patients.

The anatomy of the head and neck areas is ideal for application of endoscopic principles; its soft tissues can transform in an expandable cavity with avascular planes of dissection.

5. Conclusion

Advantages of endoscopic resection are: 1. Better visualization and magnified view of the dissection areas: as a consequence the injury of important anatomical landmark, nerves and vessel can be avoided; 2. Small incision; 3. Inconspicuous or hide scar; 4. Excellent postoperative comfort; and 5. Short hospital stay.

Disadvantages are: 1. It is necessary to have an endoscope and special instruments and 2. Specific surgical training must be made by surgeons.

With the arrival the new surgical techniques, surgeon experience and advanced endoscopic instruments, the video-assisted surgery can be a safe method of choice in the treatment of the several diseases of head and neck

6. References

- [1] Mangnan J, Chays A, Lepetre C et al. Surgical perspective of endoscopic of the cerebellopontine angle Am. J. Otol 1994;15: 366-370.
- [2] Breant AS. Endoscopic approach to benign tumors of the paranasal sinuses. In Wackym PA, Rice DH and Schaefer SD (eds) In Minimally Invasive Surgery of the Head and Neck and Cranial Base. Philadelphia, Lippincott Williams & Wilkins. 2002: 297-310.
- [3] Litynski GS. Endoscopic surgery: the history, the pioneers. World J Surg 1999; 23:745-753.
- [4] Davis CJ. A history of endoscopic surgery. Surg. Laparosc Endosc. 1992; 2: 16-23.
- [5] Benhidjeb T, Witzel K, Barlehner E, et al. The natural orifice surgery concept. Vision and rationale for a paradigm shift. Chirurg. 2007; 78: 537-542.
- [6] Guerrissi JO. Innovation and Surgical Technique. Endoscopic Resection of Cervical Branchiogenic Cysts. J. Craniofac. Surg. 2002; 13: 478-482.
- [7] Goh YH, Sethi DS Submandibular gland excision: 5 years review. J Laryngol Otol 1998; 112: 269-272.
- [8] Ellies M, laskawi R, Aregeble C at al. Surgical management of nonneoplastic diseases of the submandibular gland. Int J Oral Maxillofac Surg 1996; 35: 285-289.
- [9] Downton D, Qvist G. Intra-oral excision on the submandibular gland. Proc R Soc Med 1960; 53: 543-546.
- [10] Guerrissi JO, Taborda G. Endoscopic excision of the submandibular gland by an intraoral approach. J Craniofac Surg 2001; 13: 299-303.

- [11] Rhee JS, Gallo JF, Constantino PD. Endoscopic facial rejuvenation. In Wackym PA, Rice DH and Schaefer SD.(eds) In Minimally Invasive Surgery of the Head and Neck , and Cranial Base. Philadelphia, Lippincott Williams & Wilkins. 2002: 356-366.

IntechOpen

IntechOpen



Current Concepts in Plastic Surgery

Edited by Dr. Frank Agullo

ISBN 978-953-51-0398-1

Hard cover, 264 pages

Publisher InTech

Published online 23, March, 2012

Published in print edition March, 2012

Plastic surgery continues to be a rapidly growing field in medicine. There have been multiple recent advancements in the field. Specifically, there has been a continuously growing interest in fat grafting, body contouring, minimally invasive surgery, and plastic surgery education. At the same time, there have been continued advances and modifications in surgical techniques, which translate into better and improved results for our patients while increasing safety and efficacy. The title of the book is Current Concepts in Plastic Surgery and, as such, it highlights some of the "hot topics" in recent years. We have invited renowned specialists from around the world to share their valued expertise and experience. Most of the chapters will expose the reader to multiple techniques for achieving desired results, with emphasis on the author's preferred methodology.

How to reference

In order to correctly reference this scholarly work, feel free to copy and paste the following:

Jorge O. Guerrissi (2012). Minimal Invasive Surgery in Head and Neck Video-Assisted Technique, Current Concepts in Plastic Surgery, Dr. Frank Agullo (Ed.), ISBN: 978-953-51-0398-1, InTech, Available from: <http://www.intechopen.com/books/current-concepts-in-plastic-surgery/minimal-invasive-surgery-in-head-and-neck-video-assisted-technique>

INTech
open science | open minds

InTech Europe

University Campus STeP Ri
Slavka Krautzeka 83/A
51000 Rijeka, Croatia
Phone: +385 (51) 770 447
Fax: +385 (51) 686 166
www.intechopen.com

InTech China

Unit 405, Office Block, Hotel Equatorial Shanghai
No.65, Yan An Road (West), Shanghai, 200040, China
中国上海市延安西路65号上海国际贵都大饭店办公楼405单元
Phone: +86-21-62489820
Fax: +86-21-62489821

© 2012 The Author(s). Licensee IntechOpen. This is an open access article distributed under the terms of the [Creative Commons Attribution 3.0 License](https://creativecommons.org/licenses/by/3.0/), which permits unrestricted use, distribution, and reproduction in any medium, provided the original work is properly cited.

IntechOpen

IntechOpen