

# We are IntechOpen, the world's leading publisher of Open Access books Built by scientists, for scientists

6,900

Open access books available

186,000

International authors and editors

200M

Downloads

Our authors are among the

154

Countries delivered to

TOP 1%

most cited scientists

12.2%

Contributors from top 500 universities



WEB OF SCIENCE™

Selection of our books indexed in the Book Citation Index  
in Web of Science™ Core Collection (BKCI)

Interested in publishing with us?  
Contact [book.department@intechopen.com](mailto:book.department@intechopen.com)

Numbers displayed above are based on latest data collected.  
For more information visit [www.intechopen.com](http://www.intechopen.com)



# Recurrent Oral Squamous Papilloma in a HIV Infected Patient: Case Report

Helena Lucia Barroso dos Reis<sup>1,\*</sup>, Mauro Romero Leal Passos<sup>1</sup>,  
Aluizio Antônio de Santa Helena<sup>2</sup>, Fernanda Sampaio Cavalcante<sup>3</sup>,  
Arley Silva Júnior<sup>1</sup> and Dennis de Carvalho Ferreira<sup>3</sup>

<sup>1</sup>*Fluminense Federal University (UFF)*

<sup>2</sup>*UNIABEU University*

<sup>3</sup>*Federal University of Rio de Janeiro (UFRJ)*  
*Brazil*

## 1. Introduction

The Human Papillomavirus (HPV) is a DNA virus of the Papillomaviridae family that cannot be cultivated. It is a small, non-enveloped virus of about 55nm in diameter. It is comprised of 72 capsomers in one capsid of icosahedral symmetry.(1) It presents considerable tropism for epithelial and mucous tissues having a variable incubation period that can last from three weeks to an indeterminate period (2, 3). This virus may be associated to sexual transmission ranging from oral lesions to the formation of cervical cancer, constituting high-impact pathology (4).

More than 100 HPV genotypes have already been described so far and, among these, 24 genotypes have been associated with oral lesions (HPV-1, 2, 3, 4, 6, 7, 10, 11, 13, 16, 18, 30, 32, 33, 35, 45, 52, 55, 57, 59, 69, 72 e 73)(5). Terai et al (1999) in a PCR-based study on HPV prevalence highlighted the presence of HPV 18 in a normal mucous membrane, suggesting that the oral cavity may be a virus reservoir and that the association with other factors, such as alcohol and smoking, could induce the appearance of lesions(6).

Various types of HPV has been described, with oncogenic potential and associated to oral lesions: Squamous papilloma (SP), condyloma acuminatum (CA) and focal epithelial hyperplasy (FEH) are the most frequent pathological entities associated to HPV, and this virus has been identified and correlated to the lichen planus (LP), Pemphigus vulgaris (PV), squamous cell carcinoma (SCC) and verrucose carcinoma (VC) (7). Currently oral manifestations of the HPV infection have increased in patients infected with HIV/AIDS, including children patients (8).

This report discusses the vulnerability of HIV infected individuals to HPV infection as well as the knowledge required by clinicians. As such, the objective of this study is to relate a

---

\*Corresponding Author

case of a HIV-infected patient with a recurrent oral lesion associated to HPV, monitored at the Oral Pathology department of Federal University from Rio de Janeiro (UFRJ), under informed consent of the patient.

## 2. Case report

A white male patient, 44 years was referred to the Department of Oral Pathology at Rio de Janeiro Federal University, complaining of swelling on tip of tongue, started seven months earlier. During anamnesis the patient related a history of multiple sexual partners, and practice of unprotected oral, vaginal and anal sex, with previous episodes of sexually-transmitted diseases (STD) (gonorrhea and syphilis) adequately treated.

The patient reported being HIV-infected for 10 years and no antiretroviral therapy. Blood evaluation showed a CD4 T lymphocyte count of 640 cells/mm<sup>3</sup> and viral load of 585 copies/ml. Oral examination revealed a red verrucous 3 mm diameter lesion, on the left side of the tongue, suggestive of oral SP (figure 1). An excisional biopsy was carried out, and postoperative advise given.

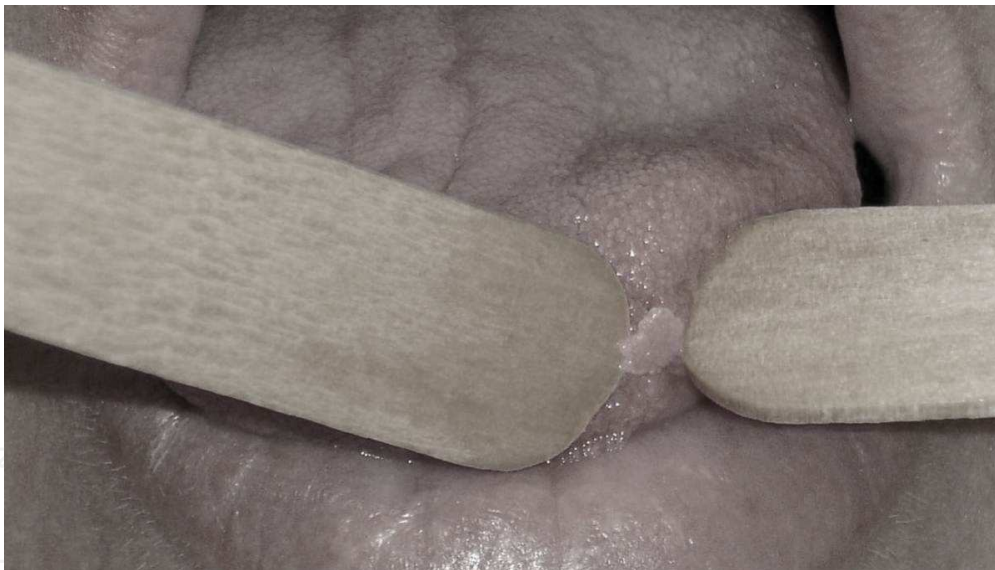

Fig. 1. Verrucose lesion on the left side of the tongue.

The histopathology showed morphology compatible with SP (figure 2), and the patient was informed about HPV infection, the risk of relapse, the risk of oral-genital transmission, and the importance of periodic monitoring. Two months after, a further vegetative 2 mm diameter verrucous lesion on the same site was revealed, indicating relapse. A repeat excisional biopsy was taken, and the histopathology indicated SP. At present the patient is under periodic clinical check-up.

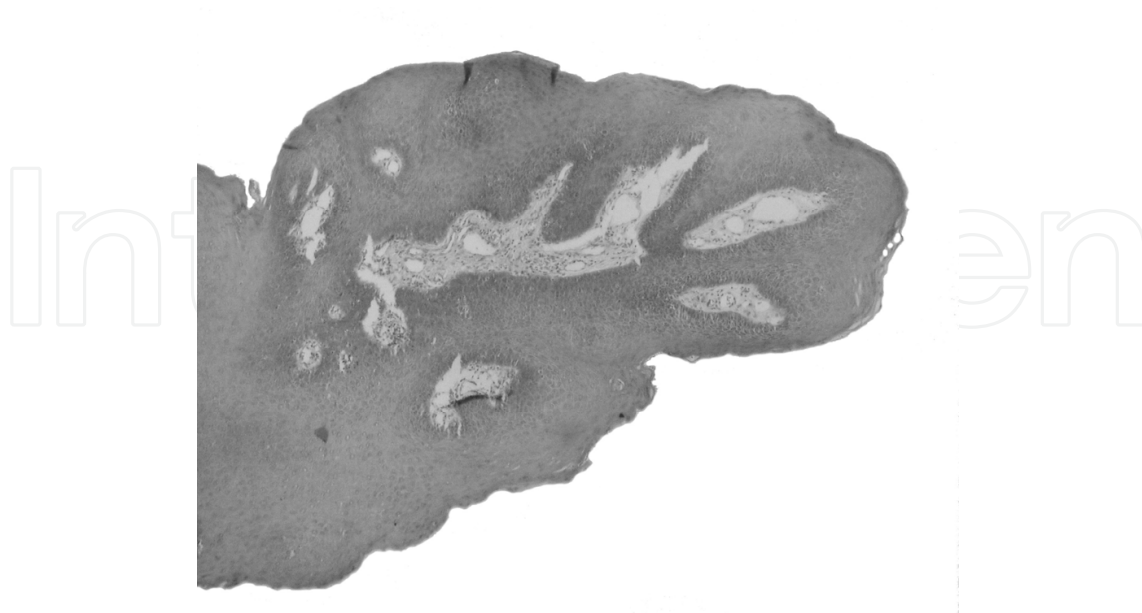


Fig. 2. Proliferative papillomatose and parakeratose lesion.

### 3. Discussion

The high number of different sexual partners, immunologic deficiency and STDs make the incidence of HPV infection increasingly high (2). This infection often occurs on oral mucosa and the sites most involved are labial mucosa, with 55% of cases, the palate, jugal mucosa, gums, tonsils, uvula and roof of the mouth (9). Although the tongue is not commonly affected, the case presented both lesions on the tip of this organ.

One study evaluated clinical and histopathological features in 12 oral lesions of SP - being the tongue - and found that the time development of these lesions ranged from 2 months to 20 years, being the tongue the most prevalent site, with lesions about 3 mm in diameter, with rounded appearance (10). SP can be further divided into several types: isolated, solitary and multiple-recurring (11). The findings observed in this study showed that lesion development (about 7 months), in the lingual site as the most frequent and round lesion.

HPV infection can occur in three ways: transitory infection in 50% of cases; spontaneous regress lesions in 30% of cases; and persistent infections, with constant relapses. Clinically the lesions normally have a verrucous aspect that may be not detected by visual inspection, but through magnification techniques such as colposcopy. Different laboratory techniques for diagnosis should read as cytology, biopsy, immunohistochemistry and molecular techniques (2, 3).

The oral SP is a benign entity presented as an exophytic lesion, with a rugose red or white surface, sessile or pediculed (12). It can be granular, fingerlike and may be asymptomatic. (11). In this case both lesions were clinically considered verrucous, vegetative and sessile.

The classical manifestations of HPV infection is the CA followed by verruca vulgaris (VV) and FEH. However, the virus has been identified in other oral afflictive entities such as VP, LP and leukoplasias, probably representing a coincidence of tissue infection and not a causal factor.

As for its differential diagnosis, the literature shows that other diseases may be an oral challenge to diagnose as condyloma acuminatum, verruca vulgaris, focal epithelial hyperplasia (Heck disease), papillary hyperplasia and verruciformis, because they are among a clinically and/or histopathological the injuries that present similarities although the feature distinct, it needs an sufficient training for the health professional to perform an adequate approach to these lesions (13)

Although many oral SP appear to be of viral etiology, the infectivity of the HPV must be of a very low order. The route of transmission of the virus is unknown for oral lesions, although direct contact would be favoured as in the present case. Surgical removal is the treatment of choice by either routine excision or laser ablation. Other treatment modalities include electrocautery, cryosurgery, and intralesional injections of interferon. Recurrence is uncommon, except for lesions in patients infected with human immunodeficiency virus (HIV) (10,11).

HPV related lesions are usual in HIV infected patients, in both genital and oral sites (14). Morphologically, hyperkeratosis, koilocytosis, diskeratosis, papillomatosis and acanthosis, whenever present in papilloma lesions suggest HPV infection (15, 16). However, other benign oral lesions such as VV, CA and FEH more readily present cytopathic effects induced by HPV than papilloma (17). Papillomavirus was also found for the first time in endodontic abscesses (18).

A report showed that the prevalence of HPV in HIV-infected adults is greater (36.4%) than in HIV-negative patients (6.1%) (19). However, a study in children, showed a prevalence of 3.6% in HIV+ patients against 12.3% of those not infected (20). Therefore, more studies into HPV infection and prevalence among the HIV+ individuals are needed in order to clarify the significance of these lesions. It seems that an emphasis on HIV treatment rather than on the HIV immunosuppression has had a noticeable role in oral HPV infections in HIV + individuals. (CAMERON 2005). (21)

Owing to the oncogenic role of certain types of HPV, the relation between this virus and carcinogenesis in oral mucosa is still controversial. Various studies have identified HPV in biopsies of oral SCC and VC (4, 9, 12). Among HPV types found in the oral mucosa, types 6 and 11 are more prevalent in benign lesions on the oral epithelium and types 16 and 18 more prevalent in malignant lesions. In this case HPV identification was not done as the material sent for analysis was scarce (4, 9).

The methods of HPV identification in human tissue vary in sensitivity include electronic microplasy, immunohistochemistry, immunofluorescence, hybridization in situ, Southern blot, dot blot, reverse blot hybridization and polymerase chain reaction (PCR) (22). Morphological analysis cannot typify the virus, but can suggest its presence, being useful in public health policies (12, 23).

The table below shows HPV identification studies as well as the types most frequently found.

Methods	Number of positive cases/population evatuated	HPV types	Reference	Year
<i>In situ</i> DNA-hybridization	7/20	2, 6, 11	Eversole & Laipis(24)	1986
<i>In situ</i> DNA-hybridization applied on paraffin sections	4/7	4, 6, 11	Syrjanen, Syrjanen & Lamseng(25)	1986
PCR Dot blot	4/19 13/19	6, 11 6, 11	Ward <i>et al.</i> (26)	1995
PCR	11/27	6, 13, 16	Jimenez <i>et al.</i> (27)	2001

Table 1.

The treatment of oral SP may be clinical, by the use of keratolytic agents such as trichloroacetic acid (40 - 90%), a podophyllum 25%, 5-fluoracil and imiquimod; or surgical, by cold, electrical or laser excision. Surgical removal is recommended in few lesions presentations and when histopathological analysis is desired (2, 3, 9).

The patient should be monitored for 6 (six) months after treatment of lesions, which is a critical period for recurrence (2, 3). This data is in agreement to the present report, as relapse occurred in the second month of outpatient monitoring.

One study showed that majority of men do not seek medical care or advice when they have advanced symptoms of HPV infection, and especially when it causes some discomfort. The major concern of infected individuals is in the consequences of this infection in terms of their social and sexual lives. Fear and pain are also raising questions present feelings and anxieties, and consequently suffering. The men in general are very dependent on their sexuality and regard penis as the main organ of the body (28,29).

The patient infected by HPV has affected sex life leading to insecurity in all aspects of life, going to be afraid of losing their jobs if discovered, fear of rejection from their partner, fear of betrayal and fear of comment friends (28,29).

A nested case-control study conducted with 2194 HIV-positive patients showed no association between changes in CD4 cell count and risk of oral warts (30).

The main causes of transmission of HPV infection are the lack of prevention information, prejudices, early onset of sexual activity, multiple partners, not using condoms. Health professionals should play a role through educational activities, working with sexual health promotion and prevention information, encouraging protected sex practices, while respecting the socio-cultural needs of each individual and promoting the biopsychosocial help (28,29). At the present moment, there are two types of HPV prophylactics vaccines, a bivalent that protect against HPV-16/18 and the quadrivalent (HPV-6,11,16). These vaccines

are available globally. There is no reason to believe that the vaccine don't work against HPV at the oral mucosa or another anatomical site (31,32,33).

#### 4. Conclusion

Oral lesions may represent an important significance for professionals who treat HPV infection or other STDs. Research into oral cavity lesions should be given value by the dental surgeon or other health professionals who treat HPV infection cases or other STDs. Furthermore, prevention is the most efficient strategy for HPV infection control, including HPV vaccination for oral and genital infection, through suitable sexual guidance in order to reduce situations of vulnerability.

#### 5. References

- [1] Scheurer ME, Tortolero-Luna G, Adler-Storthz K. Human papillomavirus infection: biology, epidemiology, and prevention. *Int J Gynecol Cancer* 2005; 15: 727-746.
- [2] Brasil. Ministério da Saúde. Secretaria de Projetos Especiais de Saúde. Coordenação de Doenças Sexualmente Transmissíveis e AIDS. Manual de Controle das Doenças Sexualmente Transmissíveis. 4 ed. Brasília:2006.
- [3] Passos MRL. Deesetologia no bolso: o que deve saber um profissional que atende DST. Niterói: RQV; 2004. p. 70-5.
- [4] Café MEM, Gontijo B, Silva CMR, Pereira LB. Formas de transmissão do vírus papiloma humano em lesões anogenitais na infância. Comitê de Dermatologia Pediátrica da Sociedade Mineira de Pediatria. Belo Horizonte, 2006.
- [5] Oliveira MC, Soares RC, Pinto LP, Costa A de LL. HPV e carcinogênese oral: revisão bibliográfica. *Rev Bras Otorrinolaringol* 2003 jul/ago; 69(4): 553-9.
- [6] Terai M, Hashimoto K, Yoda K, Sata T. High prevalence of human papilomavíruses in the normal oral cavity of adults. *Oral Microbiol and Immunology* 1999; 14:201-5.
- [7] Nonnenmacher B, Breitenbach V, Villa LL, Prolla JC, Bozzetti MC. Genital human papillomavirus infection identification by molecular biology among asymptomatic women. *Rev. Saúde Pública*. 2002 Feb;36(1):95-100.
- [8] Summersgill KF. et al. *Human papillomavirus in the oral cavities of children and adolescents. Oral Surg Oral Med Oral Pathol Oral Radiol Endod.* v.91, p.62-69, 2001.
- [9] Padayachee A. Human papillomavirus (HPV) types 2 and 57 in oral verrucae demonstrated by in situ hybridization. *J Oral Pathol Med* 1994; 23:413-7
- [10] Carneiro TE, Marinho SA, Verli FD, Mesquita AT, Lima NL, Miranda JL. Oral squamous papilloma: clinical, histologic and immunohistochemical analyses. *J Oral Sci*. 2009; 51(3):367-72.
- [11] Jaju PP, Suvana PV, Desai RS. Squamous Papilloma: Case Report and Review of Literature. *Int J Oral Sci*. 2010; 2(4): 222-225.
- [12] Heard I, Palefsky JM, Kazatchkine MD. The impact of HIV antiviral therapy on human papillomavirus (HPV) infections and HPV-related diseases. *Antiviral Therapy*. Paris, 2004. 9:13-22.
- [13] Dos Reis HB, Rabelo PC, De Santana MF, Ferreira DC, Filho AC. Oral squamous papilloma and condyloma acuminatum as manifestations of buccal-genital infection by human papillomavirus. *Indian J Sex Transm Dis*. 2009; 30: 40-42.

- [14] Fakhry C, Sugar E, D'Souza G, Gillison M. *Two-Week versus Six-Month Sampling Interval in a Short-Term Natural History Study of Oral HPV Infection in an HIV-Positive Cohort. 2010 ; PLoS ONE 5(7): e11918.*
- [15] Frega A. Human papillomavirus in virgins and behaviour at risk. *Cancer Letters*, v.194, p.21, 2003.
- [16] Castro TPPG, Bussoloti Filho I. Prevalence of human papillomavirus (HPV) in oral cavity and oropharynx. *Rev. Bras. Otorrinolaringol.* 2006 Apr; 72(2): 272-282.
- [17] Greenspan, J.S.; Greenspan, D.; Lenette, E.T. Replication of Epstein -Barr virus within the epithelial cells of Oral" hairy" leukoplakia an AIDS-Associated lesions *N Engl J Med*, v. 313, n. 25, p. 1564-71, 1985
- [18] Ferreira DC, Paiva S S, Carmo FL, Rôças IN, Rosado AS, Santos KRN, Siqueira Jr. JF. Identification of herpesviruses types 1 to 8 and human papillomavirus in acute apical abscesses..*Journal of Endodontics*, v. 37, p. 10-16, 2011.
- [19] Cameron JE, Hagensee ME. Oral HPV complications in HIV-infected patients. *Curr HIV/ AIDS Rep.* 2008 Aug; 5(3):126-31.
- [20] Jeftha AD, Dhaya D, Marais D, et al. Comparing Oral HPV types in HIV Positive and Negative Children. Annual Meeting and Exhibition of the AADR San Antonio. 2003.
- [21] Cameron JE, Mercante D, Gaffiga AM, Leigh JE, Fidel PL jr, Hagensee ME. The impact of highly active antiretrotherapy and immunodeficiency on human papillomavirus infection of the oral cavity of human immunodeficiency virus seropositive adults. *Sex Trans Dis* 2005 nov; 32(11):703-9
- [22] Venturi Beatriz da Rocha Miranda, Cabral Márcia Grillo, Lourenço Simone de Queiroz Chaves. Oral squamous cell carcinoma - contribution of oncogenic virus and some molecular markers in the development and prognosis of the lesion: a review. *Rev. Bras. Otorrinolaringol.* 2004; 70(3):385-392.
- [23] Syrjänen, K. et al. Morphological and immunohistochemical evidence suggesting human papillomavirus (HPV) involvement in oral squamous cell carcinogenesis. *Int. J. Oral Surg.* v.12, p.418-424, 1983.
- [24] Eversole LR, Laipis PJ. Oral squamous papillomas: Detection of HPV DNA by in situ hybridization. *Oral Surgery, Oral Medicine, Oral Pathology.* 1988; 65(5):545-550.
- [25] Syrjänen SM, Syrjänen KJ, Lamberg MA. Detection of human papillomavirus DNA in oral mucosal lesions using in situ DNA-hybridization applied on paraffin sections. *Oral Surgery, Oral Medicine, Oral Pathology.* 1986; 62(6): 660-667.
- [26] Ward KAR, Napier SS, Winter PC, Maw RD, Dinsmore WW. Detection of human papilloma virus DNA sequences in oral squamous cell papillomas by the polymerase chain reaction. *Oral Surgery, Oral Medicine, Oral Pathology.* 1995; 80(1): 63-66.
- [27] Jimenez C, Correnti M, Salma N, Cavazza ME and Perrone M: *Detection of human papillomavirus DNA in benign oral squamous epithelial lesions in Venezuela.* *J Oral PatholMed*30: 385-388, 2001.
- [28] Arcoverde MAM, Wall ML. Assistência "prestada ao ser" masculino portador do HPV: contribuições de enfermagem. *DST - J brasileiro Doenças Sex Transm.* 2005; 17(2): 133-7.

- [29] Santos C, de Souza LRF, de Jesus MLA, Souza RR, Cortez EA, Veneu ACS. Nursing Performance in Health assistance and HPV prevention in man. *Rev. de Pesq.: cuidado é fundamental* Online 2009; 1(2): 372-383.
- [30] King MD, Reznik DA, O'Daniels CM, Larsen NM, Osterbolt D, Blumberg HM. Human Papillomavirus-Associated Oral Warts among Human Immunodeficiency Virus-Seropositive Patients in the Era of Highly Active Antiretroviral Therapy: An Emerging Infection. *Clin Infect Dis.* (2002) 34(5): 641-648
- [31] Brotherton, JML; Gertig DM. Primary prophylactic human papillomavirus vaccination programs: future perspective on global impact. *Expert Rev. Anti Infect. Ther.* 9(8), 627-639 (2011).
- [32] Weiss, TW; Rosenthal, SL; Zimet ZD. Attitudes toward HPV Vaccination among Women Aged 27 to 45. *International Scholarly Research Network ISRN Obstetrics and Gynecology* Volume 2011, Article ID 670318, 6 pages.

IntechOpen



## **Sexually Transmitted Infections**

Edited by Prof. Nancy Malla

ISBN 978-953-51-0258-8

Hard cover, 244 pages

**Publisher** InTech

**Published online** 21, March, 2012

**Published in print edition** March, 2012

Sexually transmitted infections (STIs) are infections that are spread primarily through person to person sexual contact. There are more than 30 different sexually transmissible bacteria, viruses and parasites. STIs lead to high morbidity and complications. This book entitled as Sexually Transmitted Infections is not a text book but provides useful information for general reference work for physicians, researchers and students interested in the subject. Each chapter is abundant in tips useful to general readers as well. It also includes the Introductory chapter providing an overview with special emphasis on syndromic approach to the management of STIs in clinical setting.

### **How to reference**

In order to correctly reference this scholarly work, feel free to copy and paste the following:

Helena Lucia Barroso dos Reis, Mauro Romero Leal Passos, Aluizio Antônio de Santa Helena, Fernanda Sampaio Cavalcante, Arley Silva Júnior and Dennis de Carvalho Ferreira (2012). Recurrent Oral Squamous Papilloma in a HIV Infected Patient: Case Report, Sexually Transmitted Infections, Prof. Nancy Malla (Ed.), ISBN: 978-953-51-0258-8, InTech, Available from: <http://www.intechopen.com/books/sexually-transmitted-infections/recurrent-oral-squamous-papilloma-in-a-hiv-infected-patient-case-report>

**INTech**  
open science | open minds

### **InTech Europe**

University Campus STeP Ri  
Slavka Krautzeka 83/A  
51000 Rijeka, Croatia  
Phone: +385 (51) 770 447  
Fax: +385 (51) 686 166  
[www.intechopen.com](http://www.intechopen.com)

### **InTech China**

Unit 405, Office Block, Hotel Equatorial Shanghai  
No.65, Yan An Road (West), Shanghai, 200040, China  
中国上海市延安西路65号上海国际贵都大饭店办公楼405单元  
Phone: +86-21-62489820  
Fax: +86-21-62489821

© 2012 The Author(s). Licensee IntechOpen. This is an open access article distributed under the terms of the [Creative Commons Attribution 3.0 License](#), which permits unrestricted use, distribution, and reproduction in any medium, provided the original work is properly cited.

IntechOpen

IntechOpen