

# We are IntechOpen, the world's leading publisher of Open Access books Built by scientists, for scientists

6,900

Open access books available

186,000

International authors and editors

200M

Downloads

Our authors are among the

154

Countries delivered to

TOP 1%

most cited scientists

12.2%

Contributors from top 500 universities



WEB OF SCIENCE™

Selection of our books indexed in the Book Citation Index  
in Web of Science™ Core Collection (BKCI)

Interested in publishing with us?  
Contact [book.department@intechopen.com](mailto:book.department@intechopen.com)

Numbers displayed above are based on latest data collected.  
For more information visit [www.intechopen.com](http://www.intechopen.com)



# Clinical Applications of Quantitative MRA in Neurovascular Practice

Aaron R. Ducoffe<sup>1</sup>, Angelos A. Konstas<sup>2</sup>,  
John Pile-Spellman<sup>3</sup> and Jonathan L. Brisman<sup>3</sup>

<sup>1</sup>*Emory University School of Medicine*

<sup>2</sup>*University of California, Los Angeles*

<sup>3</sup>*Neurological Surgery, P.C.  
USA*

## 1. Introduction

QMRA, quantitative magnetic resonance angiography, is currently the only non-invasive modality with which to quantify blood flow in the human vasculature. Dr. Fady Charbel, a vascular neurosurgeon at the University of Chicago, spearheaded the application of this technology to the cerebrovascular system. Knowledge and experience garnered through years of research by Dr. Charbel and others on computer modeling and circulatory fluid dynamics culminated in the development of computer software referred to as non-invasive optimal vessel analysis (NOVA) (Zhao et al., 2000). QMRA uses traditional time-of-flight and phase-contrast MRI to visualize extracranial and intracranial vascular anatomy and measure volumetric blood flow. VasSol Inc., through which the software is now commercially available, acquired pre-market FDA approval for the technology in 2002.

NOVA is currently in use at 24 centers throughout this country and in only six centers outside the United States. Just a few publications have appeared using this technology. Reports on NOVA have been published demonstrating its use as a decision-making tool for patients with vertebrobasilar ischemia (Amin-Hanjani et al., 2005), as a means to document vascular bypass patency (Amin-Hanjani et al., 2007), as a means to evaluate in-stent stenosis after intracranial stent placement (Prabhakaran et al., 2009), as a measure of successful embolization of Vein of Galen malformations (Langer et al., 2006b), as a means to determine whether patients will tolerate carotid occlusion (Charbel et al., 2004), as a means to study vertebrobasilar flow in patients with subclavian steal syndrome (Bauer et al., 2008), as a means to quantify blood volume from leptomeningeal collaterals in patients with anterior circulation stenoses (Ruland et al., 2008), as a means to quantify carotid blood flow changes after carotid endarterectomy and carotid angioplasty and stenting for atherosclerotic disease (Ghogawala et al., 2008) and as a means to understand a difficult case of hemispheric ischemia and subclavian stenosis and plan treatment (Langer et al., 2006a). Most recently, we published on the reproducible use of NOVA to demonstrate arterial waveform changes both before and after a neurovascular intervention in ten patients (Brisman et al., 2011).

This chapter documents the use of NOVA for a cohort of 19 patients with a variety of cerebrovascular diseases. Nineteen cases treated over an 18-month period are discussed, 10

of whom had arterial waveform data previously reported (Brisman et al., 2011). The benefits, limits and potential pitfalls of the technology are evaluated.

## 2. Patients and methods

All NOVA procedures were performed on a 1.5 Tesla MRI. NOVA can study the intracranial, cervical and/or aortic vasculature, as well as the vascular system of other body parts such as the kidneys. Gadolinium is not required for NOVA, but would be given if it were deemed worthwhile for the MRA (which is always obtained as part of the NOVA test) or if an additional brain or spine MRI was performed that required it. On average, NOVA added 25-40 minutes to the MRI scan time, depending on technical experience and complexity of the case.

Retrospective review of all NOVA studies was approved by the IRB of the treating institution. Each NOVA was given one of three scores by the authors based on its perceived clinical utility as follows: CD (Clinical Decision-making) = NOVA results altered decision-making for the patient in a substantial way. This generally meant that a procedure was or was not offered to the patient based on NOVA results or that the type of procedure performed was decided based on NOVA; HP (Hypothesized Pathophysiology) = NOVA results were consistent with the clinical picture such that the authors felt that NOVA further supported the management strategy but the results did not alter treatment. This score also was given in situations where the NOVA findings had no bearing on decision-making but reflected what one would expect from the disease entity, i.e. a brain AVM showing increased flow in feeding arteries and draining veins, or an area of significant stenosis showing decreased flow; NUD (No Useful Data) = NOVA yielded data that was confusing or contrary to what is generally understood about a particular disease entity. The NUD score was also given in instances where there was no apparent alteration of flow that may have simply reflected the disease entity considered, i.e. NOVA results on a patient with a small intracranial aneurysm.

Note was also made of results for blood vessels separate from the region of interest that were abnormal with no ready explanation, which for simplicity we will call "false positive" data. Abnormal values were grouped into those that were 10-50 cc/min higher or lower than the expected normal baseline values and those that were 50 cc/min higher or lower than the expected normal values (Table 1). The distinction between "false positive" data, and data that would result in a NUD designation is that "false positive" values were typically recorded for blood vessels distinct from the region of pathologic interest. A patient with HP data for the region of interest, for example, might also have values for vessels that the were felt to be unrelated in a straightforward fashion to the region of interest and therefore while these specific values might be hard to interpret they did not necessarily affect the overall designation of the study.

## 3. Results

Twenty-Nine NOVA studies were performed over an 18 month period on 19 patients for a wide variety of cerebrovascular pathologies including vasospasm after aneurysmal SAH (1 patient), gamma knife radiosurgery of brain AVMs (3), carotid stenosis from fibromuscular dysplasia (2), high-flow (1) and low-flow bypass (1), angioplasty and stenting using the

Wingspan Stent (2), Neuroform-stenting and coiling of aneurysms (2), and conservatively treated atherosclerotic intracranial disease (2) (Table 1). Two patients with non-vascular pathology were also studied. In 13/19 (68%) patients an intervention was performed after the initial NOVA study; of those 10/13 (77%) had post-procedure repeat NOVA studies. NOVA was found to be CD in 4/19 patients (21%), HP in 12/19 (63%) and NUD in 3/19 (16%). The test was CD or HP in 10/10 cases in which NOVA was performed before and after an intervention. False positive values were found in 12/29 (41%) studies, nine of which had an abnormal value 50 cc/min less than or greater than normal.

Age/Sex	Pathology	QMRA BaL	Intervention	QMRA PP	QMRA Score	False Positive
61F	Paraclinoid Aneurysm	Normal	Stent/Coil	NA	NUD	BA↓↓84, LMCA↓99
63F	SAH/ Acomm Aneurysm	RMCA↓↓62	Clipping “Triple H”	RMCA119	HP	
56F	Hydrocephalus Colloid Cyst	Normal	VPS	NA	NUD	
72M	Carotid Stenosis	RICA↓117	CAS	NA	HP	
66F	Basilar Aneurysm Subclavian Stenosis	LVA↓-30, BA↓↓74, LPCA↓29, RPCA40	Subclavian Angioplasty/Stent Aneurysm Stent/Coil	LVA122, BA145, LPCA56, RPCA77	CD	LCCA↓↓253 RCCA↓↓220 LACA↓↓33 LMCA↓91
79F	Basilar Stenosis	BA↓40	None	NA	HP	LVA↓31 RVA↓68
62M (Case 2)	LCCA Occlusion	LMCA↓65, LCCA↓↓0	Subclavian/Carotid Bypass	Bypass 242, LICA↓164, LMCA 111	HP	RCCA↓↓158 RCCA↓↓243 BA↓143
49F	LICA FMD	LCCA↓↓146, LICA↓↓63, RICA↑↑443, LACA↓↓-99, RACA↑↑188, LPCA↑112	None	NA	HP	
39F (Case 1)	R Temporal AVM	RCCA↑↑448, RPCA↑↑130, LTS 215, RTS 871, STS 542, BVR 405	GKR	RCCA↑↑397 SSS 343, LTS 487, RTS 661, STS 487, BVR 341	HP	
65F	Basilar Stenosis	BA↓↓18	None	NA	HP	
65F	Subfrontal AVM	LTS 132, RTS 573, STS 117, SAS 510	GKR	RCCA 271, SSS 402, LTS 102, RTS 354, STS 83	HP	
36F (Case 5)	RICA FMD	RCCA↓↓160, RICA↓↓74	RCAS	RICA 212, BA 143	HP	RACA↓↓29 LVA↑197
31F	R Parietal AVM	RMCA↑↑741, LACA↑238, SSS 724, STS 81, RTS 656, LTS 325	GKR	RMCA↑↑541, RICA↑↑457, LICA↑↑500, LACA↑↑249, RTS 605, LTS 424, SSS 738, STS 101, DV 30	HP	

Age/Sex	Pathology	QMRA BaL	Intervention	QMRA PP	QMRA Score	False Positive
70F	Meningioma Resection	LICA↓↓↓154, RICA↓↓↓132			NUD	BA↓↓↓114 RPCA↓36
63F	R TS Dural Fistula	Normal	None	NA	NUD	LICA↓↓↓168 RICA↓↓↓142 BA↓↓↓122
54F	RICA Occlusion	<b>RICA↓↓↓0, RCCA↓↓↓115, RMCA↓↓↓44, LACA↓↓↓-195, RACA↓↓↓-45, RPCA↑140, LMCA 206</b>	STA/MCA Bypass	RMCA↓↓↓27, RCCA↓↓↓146, LMCA 249, LACA-261, RACA-18, RPCA 108 (Normal)	HP	LVA↑206 LACA↓↓↓-261
52M (Case 3)	Multiple Sx. BL Vertebral Stenoses	<b>LVA↓↓↓26, RVA↓↓↓58, BA↓↓↓5</b>	VA/Stent	BA1↓40, LVA 179, RVA↓↓↓26	CD	RCCA↓288, LICA↓165, LACA↓40
55M	SAH/Pcomm Aneurysm	NA	Stent/Coil	Normal (X mos.)	NUD	
69M (Case 4)	Sx. Right Vertebral Stenosis	<b>RVA↓↓↓26, (BA157)</b>	VA/Stent	RVA 73, (BA 166)	HD	RACA↓41, RCCA↓287, LVA↑189, LACA↓↓↓-306, LICA↑↑366, LPCA↑115

Table 1. QMRA Cases: Key: False Positive = the results of NOVA had no simple explanation based on the pathology and could not be explained by the authors. Note: in instances where there was False Positives and two NOVA studies had been performed, one before and one after an intervention, boldface was used to clarify which study the data was from. BaL = baseline, PP = postprocedureless, BL = bilateral, NA = not available, ↓ or ↑= between 10-50ml/ min outside normal expected QMRA values in the direction of the arrow, ↓↓ or ↑↑ = greater than 50ml/ min beyond the normal expected QMRA values in the direction of the arrows, GKR = gamma knife radiosurgery, CAS = carotid angioplasty and stinting, Sx. = symptomatic.

4. Case illustrations

4.1 Case 1

The patient is a 39-year-old otherwise healthy woman who presented five years previously with headaches and was found to have a right medial temporal arteriovenous malformation. She was offered intervention at that time, including surgical excision, but because of the quoted risks of the procedure the patient declined. She more recently presented to medical attention when she developed an acute onset headache associated with nausea and lightheadedness. CT scan of the brain showed a small subarachnoid hemorrhage adjacent to the AVM. Angiography showed the lesion to be fed primarily from enlarged branches of the posterior communicating artery and posterior cerebral artery. Venous egress was deep to an enlarged basal vein of Rosenthal and then to a dominant right transverse sinus (TS) (Figure



1A). NOVA analysis showed increased flow in the carotid artery and posterior cerebral artery on the side of the lesion with high flow in the draining basal vein of Rosenthal and the right TS relative to the left (Figure 1B-E).

After consideration of different treatment strategies, the patient was treated with gamma knife radiosurgery. Six months later, the MRI appearance was without change. NOVA analysis, however, showed a decrease in the flow through the carotid artery on the right as well as a decrease in the flow through the right TS and draining basal vein (Figure 1F-G).

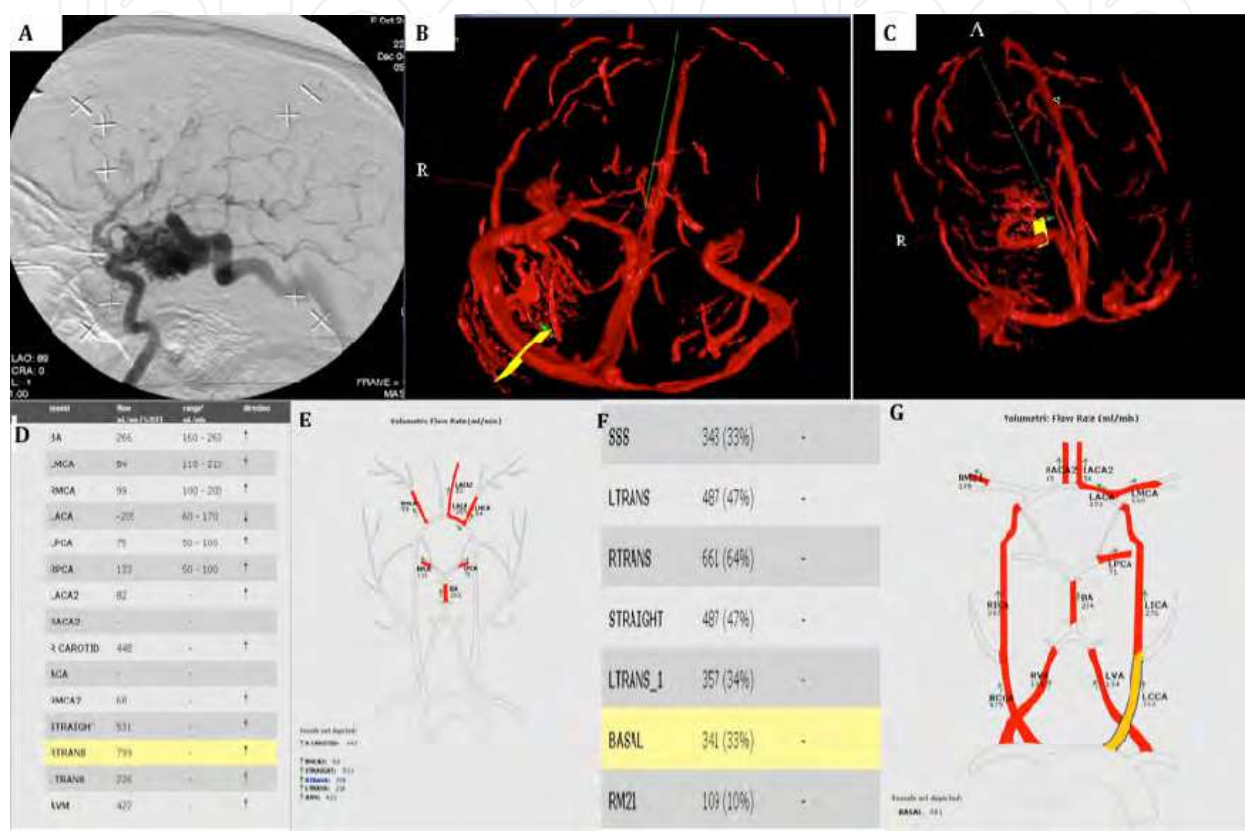


Fig. 1. Case 1 Images: A, Lateral angiogram, right internal carotid injection (postero-anterior view) shows a medio-temporal AVM nidus fed by the posterior communicator, its perforators and the posterior cerebral artery and its perforators and draining through the basal vein of Rosenthal to the deep venous system and ultimately to the transverse sinus. B, C, NOVA 3D surface rendering shows the AVM nidus with the yellow cursor demonstrating where the flow was measured in the right transverse sinus (B) and basal vein of Rosenthal (C). D,E, NOVA baseline table (D) and vessel map (E) pre-radiosurgery demonstrates abnormally increased flow in the right posterior cerebral artery (PCA) and internal carotid artery (ICA) with marked asymmetry of flow in the right transverse sinus compared with the left. Flow in the basal vein is denoted "AVM" and is also quantitated. F, G NOVA baseline table (F) and vessel map (G) six months post-radiosurgery shows marked decreased in flow in the basilar, right ICA, basal vein of Rosenthal and transverse sinus.

4.2 Case 2

This 62-year-old man presented to an outside facility with the acute onset of a right hemiparesis, affecting the arm more than the leg, and accompanied by slurred speech. MRI

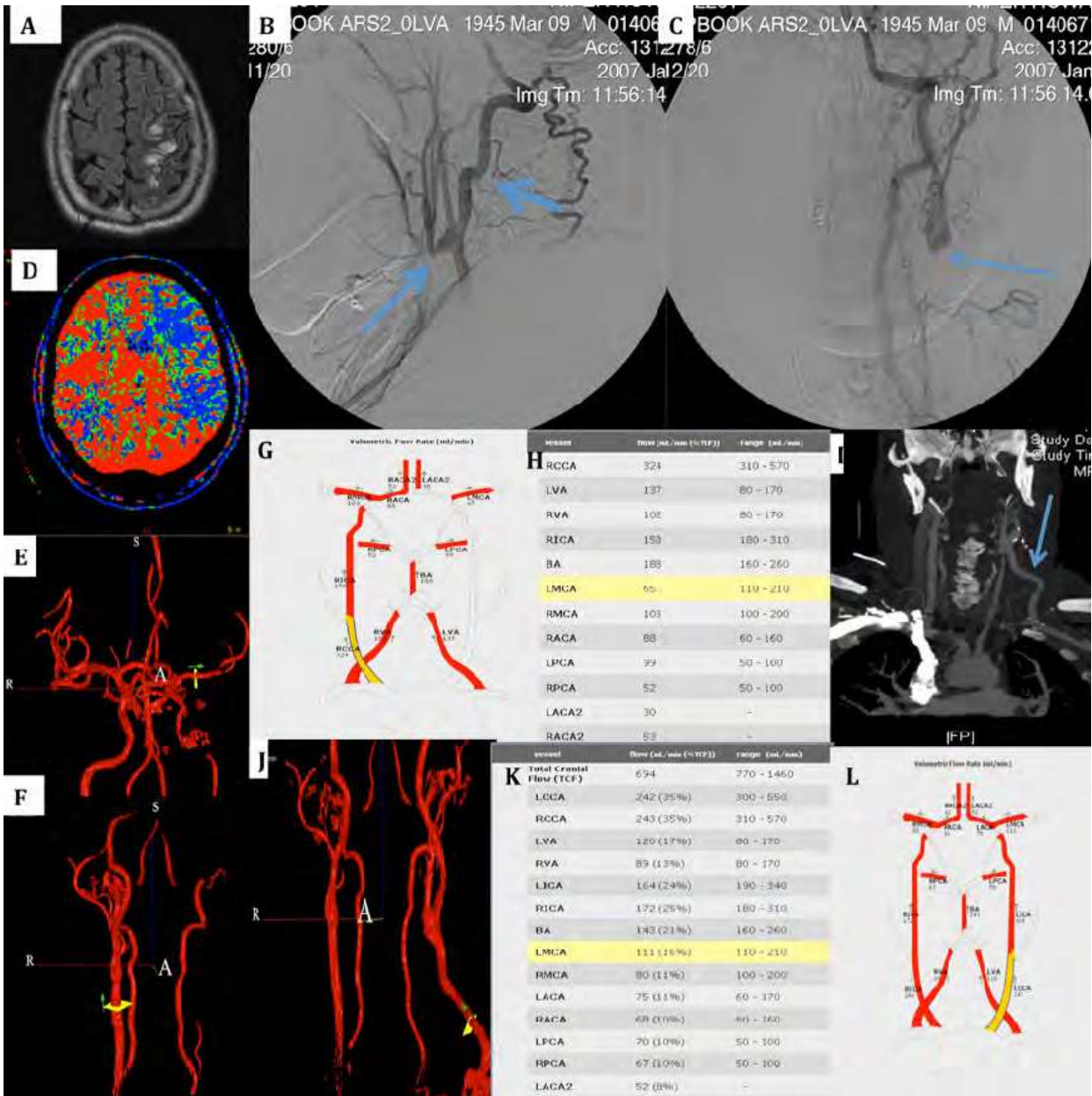


Fig. 2. Case 2 Images: A, Flair sequence MRI, axial section, shows a left hemisphere infarct. B, C, Lateral (B) and posterior-anterior (C) left vertebral angiogram shows reconstitution of the occluded left common carotid artery via cervicomuscular collaterals. D, CT perfusion scan after acetazolamide administration demonstrates decreased perfusion in the left MCA distribution. E, F, Pre-bypass NOVA 3D surface rendering shows absence of the left carotid artery in the cervical region and poor intracranial flow. G,H, Pre-bypass NOVA vessel map (G) and baseline table (H) show markedly abnormal flow in the left MCA and no flow in the left carotid artery. I, Coronal CTA after subclavian to carotid bulb bypass clearly demonstrates bypass patency. J, NOVA 3D rendering post-bypass shows the bypass with the cursor placed to measure flow. K, L, Post-bypass NOVA baseline table (K) and vessel map (L) demonstrate increased flow in the left MCA post-bypass, which is now in the normal range.

revealed an acute stroke in the left corona radiata consistent with a watershed infarction (Figure 2A). Further workup, including angiography, revealed an acute left common carotid occlusion with reconstitution of the carotid artery in the region of the carotid bulb via vertebral artery collaterals (Figure 2B,C). The patient was discharged home after near complete resolution of his hemiparesis and was referred for further evaluation because of the known carotid occlusion and daily recurrent episodes of visual loss in the left eye.

CT perfusion with acetazolamide challenge showed a persistent deficit in the left MCA territory (Figure 2D) and fundoscopy revealed optic neuropathy consistent with a chronic low-flow state. NOVA analysis showed decreased flow in the left MCA and no flow in the left common carotid (Figure 2E-H). The patient underwent a subclavian to common carotid bypass (Figure 2I). The patient's visual symptoms immediately resolved. Post-bypass NOVA showed good replacement flow in the bypass itself, good flow in the left ICA and normalization of flow in the left MCA (Figure 2J-L).

### 4.3 Case 3

This 52-year-old man with a history of hypertension, diabetes, hypercholesterolemia, coronary artery disease, and tobacco use had been placed on clopidogrel and aspirin after having multiple episodes of diplopia associated with hemisensory symptoms without infarct seen on MRI. After one such episode, imaging revealed bilateral occipital lobe, left cerebellar and right pontine acute infarctions (Figure 3A,B). Workup including CTA of the aortic arch, head and neck revealed multiple areas of irregular stenoses in the bilateral extracranial vertebral arteries. NOVA revealed diminished flow in both vertebral arteries with severely reduced flow in the left vertebral artery and basilar artery (Figure 3C).

Under general anesthesia, the patient underwent diagnostic angiography which confirmed the multiple irregular stenoses in the vertebral arteries and sluggish flow into the basilar artery and its distal branches (Figure 3D-E). The patient underwent balloon angioplasty of the left extracranial vertebral artery at the C1 level, the area felt to harbor the most severely stenotic and irregular segment. Balloon angioplasty was performed using the recently FDA-approved non-compliant Gateway balloon (Boston Scientific, Target) and was followed by placement of two telescoping recently FDA-approved WingSpan (Boston Scientific, Target) stents. This resulted in excellent angiographic dilatation with marked increased flow into the basilar artery and its tributaries (Figure 3F). This was confirmed by post-procedure NOVA (Figure 3G). The patient was discharged on clopidogrel and aspirin and did well with one readmission four months later for transient left facial numbness not associated with infarction. CTA performed at that time failed to reveal in-stent stenosis and MRI did not show an acute infarct and the patient was discharged home (Brisman, 2008).

### 4.4 Case 4

This 69 year old gentleman has a history of hypertension, hyperlipidemia and diabetes and three months prior to the current admission had an episode of vertigo and was found to have a right cerebellar and very small left cerebellar acute infarction (Fig. 4A). He made a good recovery and was discharged on clopidogrel. He was readmitted with episodes of diplopia and feeling unbalanced while walking. MRI showed bilateral cerebellar and occipital lobe small acute infarctions. CTA revealed a very focal area of vertebral artery



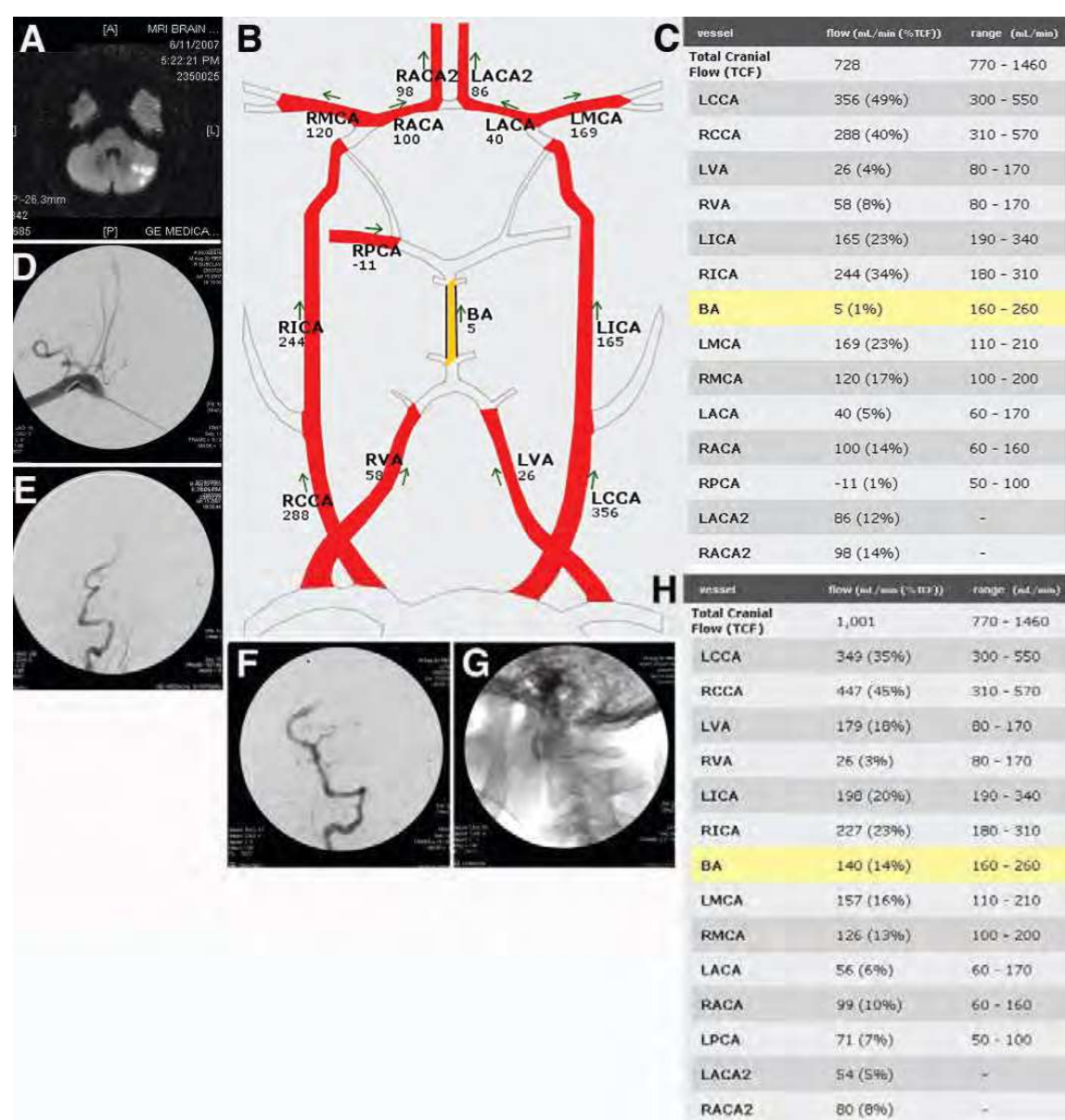


Fig. 3. Case 3 Images: A: Diffusion-weighted brain MRI showing acute left cerebellar hemisphere infarction. B: QMRA (NOVA) flow map showing markedly diminished flow in both vertebral arteries (26 and 58 cc/min) and in the basilar (5 cc/min). R = right; L = left; MCA = middle cerebral artery; ACA = anterior cerebral artery; CCA = common carotid artery; ICA = internal carotid artery; BA = basilar artery and VA = vertebral artery. Directionality of blood flow is also given (arrows). C: QMRA (NOVA) flow table giving the values seen in the flow map with the “range” column representing expected normal values. D: Right subclavian artery angiogram, postero-anterior view, demonstrates severe right vertebral origin stenosis. E: Magnified oblique view of the left vertebral artery angiogram demonstrating stenotic irregular plaque in the high cervical vertebral artery. F: Successful angiographic reconstruction post-stent placement is seen on this left vertebral artery angiogram, oblique view. G: Cervical spine lateral x-ray demonstrates the two telescoping WingSpan stents placed at the C1 level of the vertebral artery. H: QMRA (NOVA) flow table demonstrating the marked increase in the left vertebral artery flow after stenting with resultant increase in basilar flow.

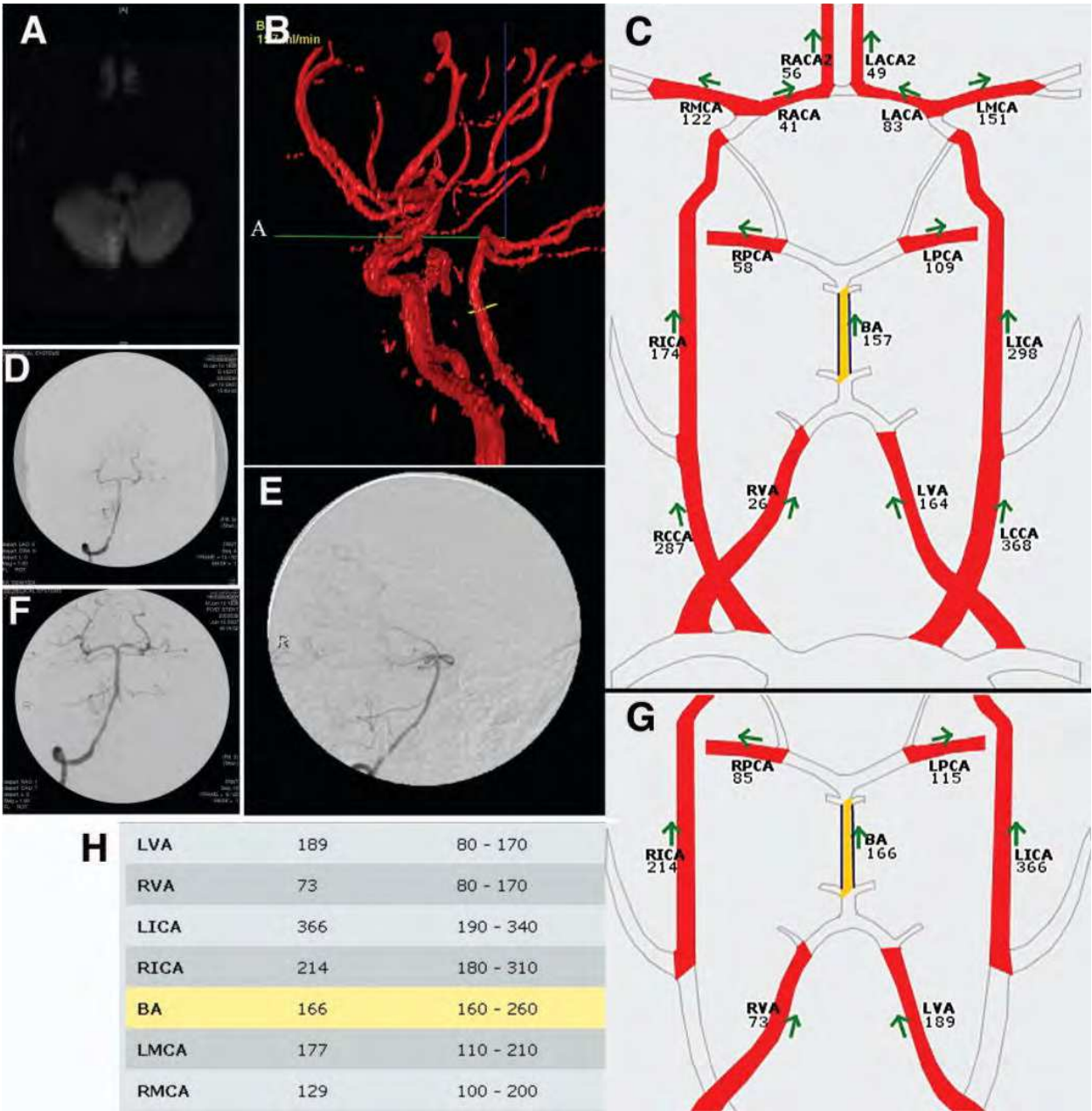


Fig. 4. Case 4 Images: A: Diffusion-weighted brain MRI showing acute right cerebellar medial hemispheric infarction. B: NOVA MRA shows the region on the basilar artery (yellow line) where the flow was measured. Flow is normal (157 ml/min). C: QMRA (NOVA) flow map shows very low flow in the right vertebral artery (26 ml/min) compared with the non-stenotic left vertebral artery (164 ml/min). Again, normal flow in the basilar artery is seen. Abbreviations as defined in figure 2. D: Right vertebral artery postero-anterior angiogram demonstrates severe right vertebral stenosis proximal to its entrance intracranially. E: Right vertebral artery angiogram, lateral view, again demonstrates the stenotic lesion. F: Right vertebral artery angiogram, magnified lateral view, shows good angiographic result post-angioplasty and stent placement. G: QMRA (NOVA) flow map shows increased flow in the right vertebral artery post-stenting. H: QMRA (NOVA) flow table demonstrates that the flow in the right vertebral artery post-stenting approaches the expected normal values.

stenosis a small distance prior to its entrance into the foramen magnum. QMRA showed markedly diminished flow in the right vertebral artery compared with the left with normal basilar flow (Fig. 4B,C). The patient was taken for diagnostic angiography which confirmed one single very severe stenosis just proximal to the entrance of the vertebral artery into the posterior fossa (Fig. 4D,E).

Under full heparinization, a 6 French Envoy was navigated into the right vertebral artery and the Gateway balloon measuring 3.5mm X 15mm was used to perform angioplasty of the stenotic segment. Using the same 0.14 microguidewire for support, a WingSpan stent measuring 3mm X 15mm was deployed across the stenosis with good angiographic result (Fig. 4F). The QMRA documented increased flow in the right vertebral artery (Fig. 4G,H). The patient has remained symptom-free at the five-month follow-up (Brisman, 2008).

#### 4.5 Case 5

This 36-year-old woman with history of migraine headaches was evaluated by a vascular surgeon for MRA findings suggestive of fibromuscular dysplasia (FMD). She was treated conservatively until she had two episodes of left hand incoordination over several months followed by several more episodes of left hand numbness and tingling. The attacks were often associated with anxiety and sometimes headaches and the diagnoses of complicated migraine and seizures were entertained. Her EEG did not suggest seizure activity and the episodes continued despite anticonvulsants.

Her MRA showed moderate right internal carotid stenosis over a long segment and mild left internal carotid stenosis with an associated kinking and small pseudoaneurysm (Figure 5A). NOVA showed significantly reduced flow in the internal carotid artery on the right with normal flow in the internal carotid artery on the left (Figure 4B). Formal angiography confirmed this (Figure 5C). She underwent right internal carotid artery angioplasty with good angiographic result (Figure 5D) and has not had further symptoms. NOVA post-procedure confirmed increased flow in the RICA (Figure 5E,F).

### 5. Discussion

The main finding of this chapter's research is that the NOVA commercially available software was used in a variety of different cerebrovascular disease processes and found to accurately represent the diagnosed pathophysiology and to reflect the expected changes of a therapeutic intervention. Excessive unexplained values outside of the company's quoted normal ranges render interpretation in a given study difficult and limit its utility at present. Since this study was completed, the company has issued more specific and hopefully more accurate normal control values based on their research suggesting alteration of expected normal values in different age populations. This study expands on a recently published study involving a subset of the current cohort in which arterial waveform analysis was shown to correlate with a neurovascular intervention (Brisman et al., 2011) We look forward to further evaluation of this technology using these new baselines. Although there are currently several good imaging modalities with which to study the cervico-cerebral vasculature (including ultrasound, CTA, MRA), these tests yield static images at one point in time. Catheter-based angiography can offer additional information about pace of blood flow and collateralization, but because of the invasiveness of the procedure there continues



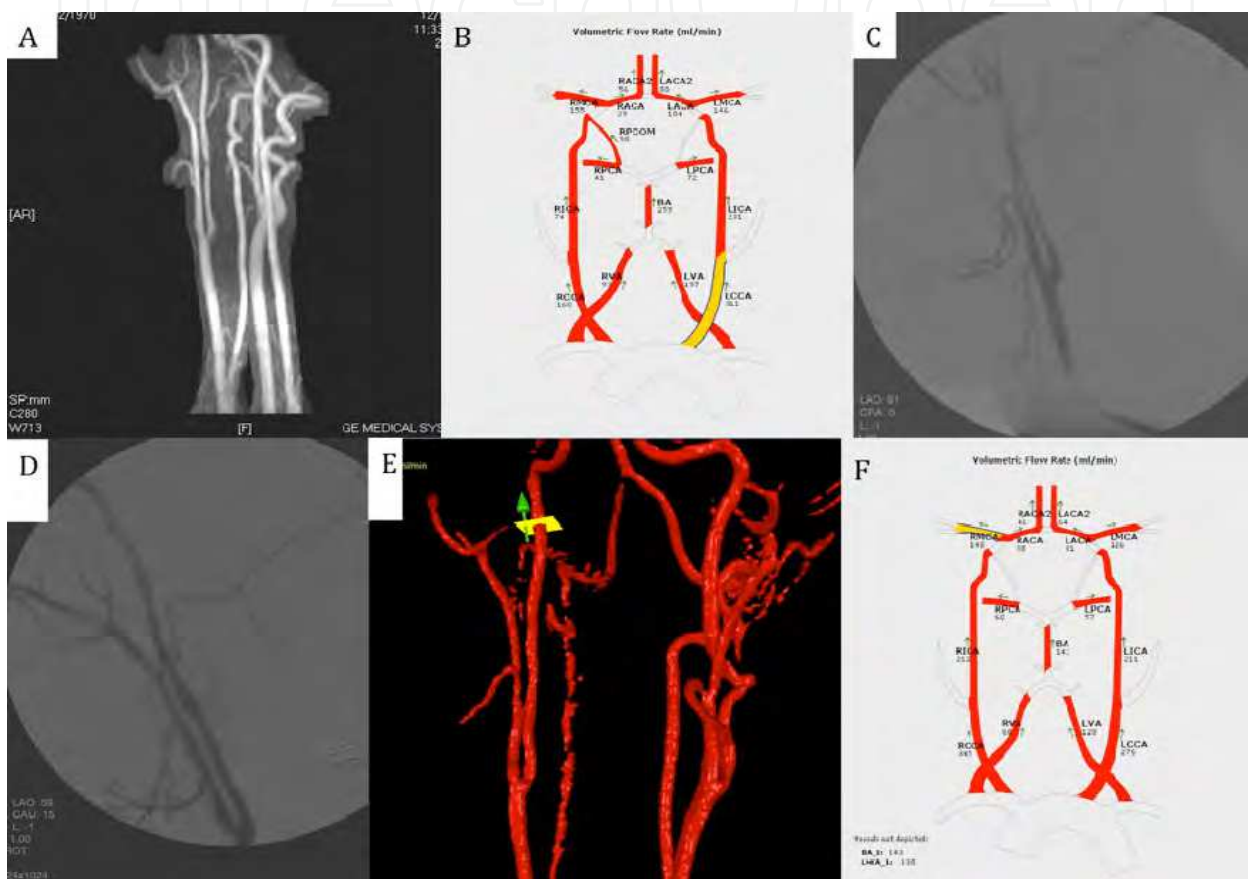


Fig. 5. Case 5 Images: A, MRA of the cervical vasculature demonstrates a right internal carotid long segment narrowing with a focal area of severe stenosis as well as a left internal carotid artery kink with an associated aneurysm in this patient with presumed FMD. B, Pre-angioplasty NOVA vessel map documents marked decrease in flow in the right internal carotid artery. C, Right common carotid angiogram, oblique view, pre-angioplasty (C) and post-angioplasty (D) shows excellent revascularization. E, NOVA 3D surface rendering of the cervical vasculature post-angioplasty appears strikingly similar to the angiogram in D. F, NOVA vessel map post-angioplasty documents marked increase in flow in the right internal carotid artery.



to be a search for less invasive modalities that can give similar or better information. Techniques such as SPECT, Xenon-CT, TCD, PET, CT Perfusion, and MR Perfusion offer an assessment of cerebrovascular physiology, but do not give quantitative information of blood flow in specific vessels. NOVA represents the only commercially available method to quantify cervico-cerebral blood flow utilizing standard MRI platforms.

## **5.1 NOVA in specific disease entities**

### **5.1.1 Radiosurgery of brain AVMs**

This represents the first demonstration of QMRA for brain AVMs as well as the first demonstration of QMRA changes after radiosurgery in brain AVMs. Prior attempts to noninvasively measure blood flow in vascular malformations have been restricted to the use of ultrasound. In one study NOVA was used to demonstrate the efficacy of endovascular embolization of Vein of Galen Malformations (Langer et al., 2006b). In the two reported cases NOVA performed before and after embolization documented marked decrease in blood flow in draining veins that correlated with angiographic findings.

In the current report, two out of three patients with brain AVMs demonstrated marked increased flow in the main arterial inputs to the malformation with asymmetric increased blood flow in the transverse sinus system receiving the AVM venous drainage. Currently NOVA offers no baseline values for blood flow in the dural venous sinuses. Therefore, the interpretation of changes in blood flow in the venous sinus system six months after radiosurgery is based on relative and not absolute values and is of unclear significance. Clear decreases in blood flow in all three cases in the draining sinuses, more pronounced on the side of the AVM in the two non-midline lesions, was used to counsel these patients that despite no change in the AVM appearance on routine brain MRI, that the radiosurgery may be having an effect as evidenced by decreased blood flow in the venous drainage.

### **5.1.2 Fibromuscular dysplasia and carotid stenosis**

This represents the first study documenting NOVA flow measurements in two patients with FMD and carotid stenosis (CS) and the first to demonstrate changes in NOVA after carotid angioplasty in one affected patient. Ghogawala et al. (2008) demonstrated increased flow following carotid endarterectomy in a patient with carotid stenosis using NOVA. They also showed that diminished blood flow from carotid stenosis correlated with improved cognitive outcomes after revascularization and suggested that quantification of blood flow before and after revascularization using NOVA may be an important way to study the effects of the intervention (Brisman, 2008). While CS secondary to atherosclerotic disease has been well studied, carotid steno-occlusive disease in patients with fibromuscular dysplasia is a less familiar entity. Whereas CS from atherosclerosis is felt to cause symptoms from thrombo-embolism, this is not the case with FMD, where decreased flow may play more of a role. This probably reflects the different histologic pathology between the two diseases. As a result, treatment options for patients with CS and FMD have been more controversial, reflecting our lack of understanding of the natural history risks as well as the treatment risk of either open or endovascular options.

Various open surgical treatments have been used historically for CS in patients with FMD, ranging from surgical exposure and angioplasty under direct vision to excision of the diseased segment and patching. Currently, endovascular angioplasty is the most popular treatment for symptomatic CS in FMD patients and its success parallels that in the renal vasculature of such patients. FMD patients with asymptomatic CS represent a group in which no clear recommendations exist. In cases of moderate to severe stenosis, NOVA may provide the best way to follow such patients. At what point to intervene based on changes in NOVA flow remains an unanswered question. Based on our two cases, NOVA documented clearly decreased flow with marked increase after angioplasty in the one patient treated.

### 5.1.3 Vasospasm after SAH

Cerebral vasospasm after aneurysmal subarachnoid hemorrhage remains the most significant source of morbidity and mortality in these patients, with an estimated one sixth of all patients developing permanent disability. While the exact etiology and pathophysiology of the process is unknown, screening and detection using transcranial dopplers, computed tomographic angiography and catheter angiography are well described and important as treatment options that may avert stroke are available.

By quantifying blood flow in spastic vessels, NOVA may be a better method with which to detect and follow vasospasm as well as assess instituted therapies. Transcranial doppler ultrasonography and CTA yield anatomic information only and are therefore poor predictors of who will develop symptomatic vasospasm. Angiography is somewhat invasive, is impractical to perform multiple times during the vasospasm period and also generates mostly anatomic information.

NOVA appeared to correlate with CTA and angiography in the one patient studied. This is the first demonstration of vasospasm using NOVA. A modified abridged version of the NOVA was performed on this patient in which only three vessels were studied: the basilar artery and both MCA arteries. The intent was to reduce the time required for the test (to under 10 minutes) such that it would be practical for critically ill patients such as those who have suffered subarachnoid hemorrhage and may have vasospasm. Additionally it made sense to study only these vessels as it is only in these vessels that balloon angioplasty is generally performed in cases of medically refractory vasospasm. Further studies evaluating larger numbers of patients and looking at additional vessels, particularly the anterior cerebral and supraclinoid carotid arteries, might also be important.

### 5.1.4 Vascular bypass for ischemia

NOVA was used to study two patients who underwent extracranial-intracranial bypass as part of a cerebrovascular augmentation procedure in the setting of unilateral carotid occlusion, ipsilateral symptoms and documented poor cerebrovascular reserve. The use of NOVA to study the integrity and potential utility of bypass for occlusive ischemic disease has been previously studied by Amin-Hanjani et al. when they reviewed 101 bypasses in which they performed NOVA before and after. They showed that NOVA was a good way to document the integrity of the graft and to follow it over time (Amin-Hanjani et al., 2007).

In our patient with a subclavian-carotid bypass, NOVA readily measured flow in the graft and documented increased intracranial flow compared to the patient's presurgical state. In the patient with the STA-MCA bypass, despite patency on angiographic imaging, NOVA could not measure flow in the graft, suggesting that the flow was too low to be detected or technical error of the NOVA. NOVA requires a certain size vessel to obtain measurements. As the graft matures, future NOVA studies may be able to detect and measure flow.

### 5.1.5 Atherosclerotic disease and endovascular revascularization

NOVA was used in four patients with vertebrobasilar ischemia, two from severe basilar artery stenosis and two from extradural vertebral stenosis. In three out of four patients, the authors considered NOVA to be CD. One of the patients with vertebral disease had a solitary focus and the other had multiple lesions. In the two patients with basilar stenosis and very low flow in the basilar artery (cases 3 and 4), results of NOVA were used to recommend balloon angioplasty and stent placement despite the patients not having failed maximal medical therapy. The justification for this was based on the results of one study that used NOVA flow in the basilar and posterior cerebral arteries to predict which patients with vertebrobasilar ischemia would benefit from posterior circulation revascularization as opposed to medical therapy (Amin-Hanjani et al., 2005). Both patients declined interventional treatment.

Cases 3 and 4 document the utilization of the new WingSpan stent and Gateway balloon system to treat two patients with medically refractory vertebrobasilar ischemia secondary to cervical vertebral artery stenosis. The self-expanding nitinol stent is designed for use after balloon angioplasty using a specially designed balloon and has not been previously described in the treatment of extracranial vertebral artery disease (Brisman, 2008).

This is the first description of the use of this novel stent for the treatment of the extracranial vertebral arteries as well as the first documentation of QMRA before and after WingSpan stenting of any vessel (Brisman, 2008).

Historically, extracranial vertebral artery disease had been treated with surgical bypass (Spetzler et al., 1987) but has since given way to endovascular approaches. This shift reflects the technical difficulty and unfamiliarity of most neurosurgeons with the former and the improved success and experience with the latter. Stenting and angioplasty has been well described for the extracranial vertebral arteries (Ko et al., 2004 & Malek et al., 1999) with some success with both balloon-mounted coronary stents and self-expanding stents designed for non-cerebral revascularization. Such stents can be difficult to navigate due to the tortuosity of the cervico-cerebral vasculature and associated with complication rates (4.8% major morbidity in one series) (Malek et al., 1999) that may relate to the difficulty with stent delivery, overly aggressive balloon angioplasty and/or excessive radial force during deployment or afterwards. Recurrent events post-stenting (persistent in 9.5% in one series) (Malek et al., 1999) and high rates of restenosis (10-43%) (Ko et al., 2004) suggest that current endovascular options may be improved upon. The WingSpan stent system and Gateway balloon were specifically designed to access and treat more fragile intracranial vessels. The seminal safety study of this stent used in 45 patients with medically refractory intracranial stenosis was recently published (Bose et al., 2007). Although not specifically designed for

extracranial disease, the system was employed with technical ease and success in the two patients here described.

In addition to this technical success associated with very acceptable angiographic results, QMRA demonstrated expected increases in flow in the treated vertebral artery in both patients. That said, one patient did have an episode several months later of transient facial numbness that may have represented a posterior circulation transient ischemic attack. This patient, however, has multiple risk factors for vasculopathic disease and stenting was directed to the most stenotic and irregular region of the vertebral artery. If such episodes persist, consideration may be given to treatment of his additional vertebral stenoses. Another caveat of this system is the issue of in-stent restenosis, which has been well described for vertebral artery stents, and which was not addressed in this report. As the clinical follow-up is short and no catheter angiographic follow-up has been presented, the durability of the WingSpan stent in the extracranial vertebral arteries remains unknown. QMRA may prove useful to follow such patients post-stenting as decreased flows may herald restenosis.

Currently there are several very good imaging modalities with which to study the anatomy of the cervico-cerebral vasculature. These include ultrasound (carotid duplex and transcranial duplex), CTA, MRA and catheter angiography and range from non-invasive (duplex, MRA) to minimally invasive (CTA) to invasive with low risk (catheter angiography). Those studies that are minimally or non-invasive, however, yield static images, and despite tremendous advances in the ability to manipulate these images, the studies do not give more than a picture of the vascular anatomy at one point in time. Catheter angiography offers specific additional information about cervico-cerebral vascular pathology such as pace of blood flow and collateralization. Because of the invasiveness of the procedure, however, there has been a continued search for less invasive modalities that might offer similar or better information. Additional modalities have been developed, therefore, using a wide range of techniques, that attempt to give some assessment of cerebrovascular physiology. Such techniques include SPECT, Xenon-CT, TCD, PET, CT Perfusion, and MR Perfusion. None of these studies gives quantitative information of blood flow. NOVA is a software package that represents the only commercially available technique to quantify cervico-cerebral blood flow utilizing standard MRI platforms. It has been shown to effectively risk-stratify patients with vertebrobasilar ischemia based on distal flow in the basilar and posterior cerebral arteries (Amin-Hanjani et al., 2005).

In these two cases, vessel dilatation post-procedure was associated with an expected increase in flow values. Interestingly, in one of the two cases, basilar flow was normal, suggesting the lesion was not flow-limiting. Stent placement in that patient might have more efficacy as an intimal stabilizer against further thrombo-embolic events, whereas in the other patient flow-limitation and thrombo-embolism were both probably contributing to ischemia (Brisman, 2008).

## 5.2 Caveats to this study and limitations of NOVA

Some of the findings of this study are objective, such as the common occurrence of abnormal values that lacks a simple explanation. Our study surprisingly showed a 41% false positive



rate, bringing into question the validity of the software. It is possible, however, that we did not appreciate that the abnormal flow in a given vessel was part of the pathologic process. Additionally, it is possible that the defined “normal values” from the company need adjustment. The more subjective part of this report involves the designation of HP, CD or NUD to a given NOVA test. This designation is multifactorial and incorporates our understanding of the disease process, the kinds of patients evaluated and referred for NOVA testing and threshold for intervention.

There are quite a few limitations of the NOVA technology, some of which likely are preventing its adoption into mainstream cerebrovascular care. The most prominent problem is the lack of properly defined baseline normal values, as mentioned above. The baseline values provided by the company are based on a large cohort of healthy volunteers. The company is currently studying another large group of volunteers in an effort to better define baseline values (personal communication). Particular clarification is needed with regard to defining the range of normal values and what, if any, adjustments should be made for certain patient-specific factors such as age (which has recently been addressed), cardiac dysfunction or dehydration, to name just a few. Is there a range of fluctuation in NOVA values that is acceptable for a given individual at different periods of the day or seasonally? Do NOVA results vary in relation to meals or with patients who are febrile, diabetics or smokers? All these questions will need to be answered in order to make the appropriate adjustments such that true pathologic states can be ascertained across a wide spectrum of patients. These caveats notwithstanding, we do believe that the findings here of alteration in flow in an expected manner for those patients undergoing an intervention is significant but agree that further validation of the basic software is in order.

## 6. Conclusion

NOVA represents the only currently available method to non-invasively quantify blood flow in the human cervico-cerebral vasculature and will likely play a more prominent role in cerebrovascular care as research better defines expected values for different patient populations at baseline and in disease states. This study represents the largest clinical experience using NOVA in a routine cerebrovascular practice encompassing diverse pathologies. Analyses of NOVA in certain conditions, such as radiosurgery of brain AVMs, carotid stenosis from fibromuscular dysplasia, and vasospasm after aneurysmal subarachnoid hemorrhage have not been previously described. We found NOVA to accurately reflect expected blood flow changes before and after a neurovascular intervention in all cases. Further research into this new technology that better defines expected normal and disease state values will likely result in increased incorporation into mainstream cerebrovascular practice.

## 7. References


Amin-Hanjani S, Du X, Zhao M, Walsh K, Malisch TW, & Charbel FT. (2005). Use of quantitative magnetic resonance angiography to stratify stroke risk in symptomatic vertebrobasilar disease. *Stroke*, 36:1140-1145.

- Amin-Hanjani S, Shin JH, Zhao M, Du X, & Charbel FT. (2007). Evaluation of extracranial-intracranial bypass using quantitative magnetic resonance angiography. *J Neurosurg*, 106:291-298.
- Bauer AM, Amin-Hanjani S, Alaraj A, & Charbel FT. (2008). Quantitative magnetic resonance angiography in the evaluation of the subclavian steal syndrome: Report of 5 patients. *J Neuroimaging*.
- Bose A, Hartmann M, Henkes H, Liu HM, Teng MH, Szikora I, et al. (2007). A novel, self-expanding, nitinol stent in medically refractory intracranial atherosclerotic stenoses: The WingSpan Study. *Stroke*, 38:1531-7.
- Brisman JL. (2008). Wingspan stenting of symptomatic extracranial vertebral artery stenosis and perioperative evaluation using quantitative magnetic resonance angiography: report of two cases. *Neurosurg Focus*, 24:E14.
- Brisman JL, Pile-Spellman J, & Konstas AA. (2011). Clinical utility of quantitative magnetic resonance angiography in the assessment of the underlying pathophysiology in a variety of cerebrovascular disorders. *European Journal of Radiology*, in press/e-published.
- Charbel FT, Zhao M, Amin-Hanjani S, Hoffman W, Du X, & Clark ME. (2004). A patient-specific computer model to predict outcomes of the balloon occlusion test. *J Neurosurg*, 101:977-988.
- Ghogawala Z, Westerveld M, & Amin-Hanjani S. (2008). Cognitive outcomes after carotid revascularization: the role of cerebral emboli and hypoperfusion. *Neurosurgery*, 62:385-395.
- Ko YG, Park S, Kim JY, Min PK, Choi EY, Jung JH, et al. (2004). Percutaneous interventional treatment of extracranial vertebral artery stenosis with coronary stents. *Yonsei Med J*, 45(4):629-634.
- Langer DJ, Lefton DR, Ostergren L, Brockington CD, Song J, Niimi Y, Bhargava P, & Berenstein A. (2006 (a.)). Hemispheric revascularization in the setting of carotid occlusion and subclavian steal: a diagnostic and management role for quantitative magnetic resonance angiography? *Neurosurgery*, 58:528-533.
- Langer DJ, Song JK, Niimi Y, Chwajol M, Lefton DR, Brisman JL, Molofsky W, Kupersmith MJ, & Berenstein A. (2006 (b.)). Transarterial embolization of vein of Galen malformations: the use of magnetic resonance imaging noninvasive optimal vessel analysis to quantify shunt reduction. Report of two cases. *J Neurosurg*, 104:41-45.
- Malek AM, Higashida RT, Phatouros CC, Lempert TE, Meyers PM, Gress DR, et al. (1999). Treatment of posterior circulation ischemia with extracranial percutaneous balloon angioplasty and stent placement. *Stroke*, 10:2073-85.
- Prabhakaran S, Warrior L, Wells KR, Jhaveri MD, Chen M, & Lopes DK. (2009). The utility of quantitative magnetic resonance angiography in the assessment of intracranial in-stent stenosis. *Stroke*.
- Ruland S, Ahmed A, Thomas K, Zhao M, Amin-Hanjani S, Du X, & Charbel FT. (2008). Leptomeningeal collateral volume flow assessed by quantitative magnetic resonance angiography in large-vessel cerebrovascular disease. *J Neuroimaging*.

- Spetzler RF, Hadley MN, Martin NA, Hopkins LN, Carter LP, & Budny J. (1987). Vertebrobasilar insufficiency. Part 1: Microsurgical treatment of extracranial vertebrobasilar disease. *J Neurosurg*, 66(5):648-61.
- Zhao M, Charbel FT, Alperin N, Loth F, & Clark ME. (2000). Improved phase-contrast flow quantification by three-dimensional vessel localization. *Magn Reson Imaging*, 18:697-706.

IntechOpen

IntechOpen



## **Magnetic Resonance Angiography Basics to Future**

Edited by Prof. Wael Shabana

ISBN 978-953-51-0401-8

Hard cover, 94 pages

**Publisher** InTech

**Published online** 21, March, 2012

**Published in print edition** March, 2012

As MRI has paved its role in diagnostic angiography. MRA has the potential to provide more physiological and pathophysiological data over the disease in addition to the anatomical information. This book is divided into three sections. The first section discusses the basics of MRI angiography. It starts with focus on the contrast agents that are mainly used in MR angiography with detailed discussion of advantage and limitations of different types of contrast. The second chapter is oriented more towards the technical consideration that contribute to good quality examination, both the non contrast and contrast based sequences from black to bright blood imaging , contrast enhanced MRA, review of clinical application of MRA in different body systems and MR venography. The second section reviews the clinical application of MRI mainly in the head and neck and brain ischemia imaging. The new high resolution intracranial plaque imaging of the branch athermanous disease, to the hemodynamic of intracranial atherosclerotic stroke and quantitative MRA imaging in neurovascular imaging, are the topics in this section. Also this section covers the future prospective and the new frontiers MRI angiography is exploring. In the third section, MRA of aortic disease in children with emphasis on cardiac MRA.

### **How to reference**

In order to correctly reference this scholarly work, feel free to copy and paste the following:

Aaron R. Ducoffe, Angelos A. Konstas, John Pile-Spellman and Jonathan L. Brisman (2012). Clinical Applications of Quantitative MRA in Neurovascular Practice, Magnetic Resonance Angiography Basics to Future, Prof. Wael Shabana (Ed.), ISBN: 978-953-51-0401-8, InTech, Available from: <http://www.intechopen.com/books/magnetic-resonance-angiography-basics-to-future/clinical-applications-of-quantitative-mra-in-neurovascular-practice>

**INTech**  
open science | open minds

### **InTech Europe**

University Campus STeP Ri  
Slavka Krautzeka 83/A  
51000 Rijeka, Croatia  
Phone: +385 (51) 770 447  
Fax: +385 (51) 686 166  
[www.intechopen.com](http://www.intechopen.com)

### **InTech China**

Unit 405, Office Block, Hotel Equatorial Shanghai  
No.65, Yan An Road (West), Shanghai, 200040, China  
中国上海市延安西路65号上海国际贵都大饭店办公楼405单元  
Phone: +86-21-62489820  
Fax: +86-21-62489821



© 2012 The Author(s). Licensee IntechOpen. This is an open access article distributed under the terms of the [Creative Commons Attribution 3.0 License](https://creativecommons.org/licenses/by/3.0/), which permits unrestricted use, distribution, and reproduction in any medium, provided the original work is properly cited.

IntechOpen

IntechOpen