

We are IntechOpen, the world's leading publisher of Open Access books Built by scientists, for scientists

6,900

Open access books available

186,000

International authors and editors

200M

Downloads

Our authors are among the

154

Countries delivered to

TOP 1%

most cited scientists

12.2%

Contributors from top 500 universities



WEB OF SCIENCE™

Selection of our books indexed in the Book Citation Index
in Web of Science™ Core Collection (BKCI)

Interested in publishing with us?
Contact book.department@intechopen.com

Numbers displayed above are based on latest data collected.
For more information visit www.intechopen.com



Effects of Blood Transfusion on Retinopathy of Prematurity

Ebrahim Mikaniki, Mohammad Mikaniki
and Amir Hosein Shirzadian
*Babol University of Medical Sciences
Iran*

1. Introduction

Retinopathy of prematurity (ROP) is a vasoproliferative retinal disorder, which represents the main cause of visual impairment and blindness in preterm infants (Drack,1998).ROP develops in 84% of premature survivors born at <28 weeks of gestation (Palmer et al,1991). Fortunately, it resolves in most cases (80%) without visual loss from retinal detachment or scars (Palmer et al, 1991; Cryotherapy for retinopathy of prematurity cooperative group, 1994). In this study, the total ROP incidence was 0.17% overall and 15.58% for premature infants with length of stay of more than 28 days (Lad et al, 2009). The increased survival of very small premature infants has led to the resurgence of this potentially blinding disease (Kinsey et al 1977; Shohat et al 1983)The pathogenesis of ROP isn't fully known. The altered regulation of vascular endothelial growth factor from reported episodes of hyperoxia and hypoxia is an important factor in the pathogenesis of ROP (Chow et al 2003). Apparently, any severe physiologic stress may damage the developing capillaries in immature retina and in response to ischemia, new vessel (neovascular) growth resumes (Phelps, 1992).ROP appears to be a multifactorial disease. Given the multifactorial nature of ROP and close relation of the most risk factors to prematurity, it is difficult to define the specific role of any individual factor in the pathogenesis of ROP (Hesse et al 1997).

Blood transfusion has been identified as a risk factor for ROP in several studies (Shohat et al,1983;Cats& Tan KEW ,1985 ;Clark et al ,1981; Cooke et al ,1993;Sacks et al ,1981;Yu & Hookham& Nave ,1982);Some investigator, however, could not confirm this associating (Bossi et al, 1984; Brown,1987 ;Lechner& Kalina& Hodson,1977).The damaging effects of blood transfusion on the retina are mediated via an increase in free iron that may catalyze fenton reactions, which produce free hydroxyl radicals capable of damaging the retina (Sullivan, 1988).Preterm infants are particularly susceptible to iron overload because of frequent transfusions and low levels of iron - binding proteins (Sullivan, 1988).In an effort to limit the risks associated with RBC transfusion, many neonatal units have adopted more restrictive guidelines for transfusing preterm infants (Widness et al ,1996 ;Alugappan& Shattuck& Malloy ,1998;Maies et al 2000 ;Franz & Pohlandt,2001),but the safety or potential benefits of restricting transfusions have not been adequately tested.

2. Retinopathy of prematurity

2.1 History

ROP was first described by Terry in 1942 as retrolental fibroplasias (Terry, 1942) and a few years later was recognized as one of the leading causes of infant blindness (Zacharias,1952).The indiscriminate use of oxygen from the 1940s to the mid-1950s was associated with a very high incidence of ROP. After the widespread adoption of the New York city health departments recommendation to restrict supplemental O₂ concentrations to 40% ,the incidence of ROP decreased dramatically (James & Lamman,1976). During the 1960s it became obvious that although ROP incidences had decreased ,the oxygen restriction appeared to be associated with a significant increase of infant morbidity and mortality from hyaline membrane disease (Avery& Oppenheimer, 1960) and brain injury (McDonald, 1963). Oxygen supplementation was therefore liberalized in the late 1960s, and incidence of ROP began to rise again.

In the late 1960s, the incidence of ROP began to rise again. This increase continued during the 1970s and 1980s, likely as a result of the improved survival rate of very low birth weight infants associated with advances in neonatal medicine (Valentine et al, 1991).However, with improved technology and new techniques in neonatal nursing care, very low birth weight infants are now surviving with decreasing morbidity, and it is possible that the recent advances, that produced this change have also had an effect on ROP incidence (Bullord et al, 1998).

2.2 Incidence and risk factors

Kinsey et al found the incidence of ROP to be 38% in infants weighing 1200 g or less (Kinsey et al 1977.The CRYO-ROP trials reported an incidence of 65.8%,Infants weighing less than 1251 g and 81.6% in those less than 1000 g (Palmer et al, 1991). Many other studies reported ROP incidence ranging from 10% to 66% in infants with low birth weights in the United States and worldwide (Shohat et al 1983;Cats& Tan KEW ,1985; Bullord et al,1998;Fledelius& Dahl ,2000;Akkoyun et al,2006;Rowlands et al 2001;Hussain&Clive& Bhandori,1999;Wright et al,1998;Custick et al 2006;Yang et al 2006).

Chiang and associates have reported that the incidences of ROP were 20.3%, 27.3% and 33.2% in infants with a length of stay of more than 28 days with birth weight of less than 1500 g, 1200 g and 1000 g respectively (Chiang et al. 2004).

More recently Lad et al. in a large retrospective study based on the national Inpatient sample from 1997 through 2005 reported ROP incidence of 15.58% for premature infants with length of stay of more than 28 days (Lad et al, 2009).

Several risk factors have been associated with ROP .The major risk factors are prematurity (low birth weight, low gestational age at delivery).An inverse relationship was found between birth weight and the incidence and severity of retinopathy of prematurity (Lad et al, 2009; Kinsey et al 1977; Shohat et al. 1983; Bossi et al, 1984; Gunn et al,1980;Hammer et al,1986;Patz,1969).This finding emphasize, that the degree of immaturity of the eye is the main predictive factor for the devolvement of ROP.

Immature and underdeveloped retinal blood vessels in premature infants may be more vulnerable to postnatal environmental influences such as hyperoxic or hypoxic tissue injury,

hypercarbia, and metabolic acidosis (Quinn, 1998). Moreover, these adverse conditions have a better opportunity to affect retinal vascular development if more development is left to occur under their influence. For many years it was thought that oxygen therapy increased the risk of ROP in preterm infants, however (Reynolds et al, 1998), ROP can occur even with careful control of oxygen therapy (Akkoyun et al, 2006). In fact, the role of oxygen has been overemphasized in the past and excessive oxygen administration has not been identified as an independent risk factor (McColm & Fleck, 2001). A reasonable working hypothesis is that the developing retina is highly sensitive to any disturbance in its oxygen supply either hyperoxemic or hypoxemic (Lucey & Dangman, 1984).

Other proposed risk factors that are under study and may not be causally linked to ROP include: metabolic acidosis (Bossi et al, 1984), metabolic alkalosis (Shohat et al 1983), hypercarbia (Bauer & Windmayer, 1981), hypocarbia (Brown, 1987), transfusions (Brown, 1987; Clark et al, 1981), light (Glass et al, 1985), intraventricular hemorrhages (Brown, 1987), white race (Saunders et al, 1997), chronic lung disease (Biglan et al, 1984), seizures (Biglan et al, 1984), sepsis (Gunn et al, 1980), xanthine administration (Hammer et al, 1986), magnesium and copper deficiency (Caddell, 1995), Vitamin E deficiency (Owens & Owens, 1949), selenium deficiency (Papp & Nemeth & Pelle, 1993), and multiple gestations (Bossi et al, 1984). Any change that affects the incidence or nature of one or more of these risk factors might also affect the incidence and severity of ROP.

2.3 Pathogenesis

ROP is a condition confined to the immature retinal vascular system. The likelihood of developing retinopathy is related to the degree of vascular development so that once the retina is fully vascularized the risk of developing ROP has passed. Normally, retinal vascular development progresses from the 16th week of gestation to the 40th week in a central to peripheral wave at a rate of about 0.1 mm/day (Payne & Patz, 1979).

ROP alters this normal developmental progression, which instead follows a two-staged pathophysiologic course: an initial phase of vasoconstriction and arrested vessel growth, followed by a second phase of abnormal vessel proliferation. The onset of ROP generally requires two conditions. The first is incomplete retinal vascular development. ROP incidence and severity is directly proportional to the degree of prematurity that is, ROP outcome correlates with the size of the area of retinal avascularity at onset (Kinsey et al 1977, Schaffer et al, 1993, Kalina & Kari, 1982). The second condition involves exposure of the developing retina to an abnormal environmental influence and several have been suggested (Quinn, 1998). Most prominent among these is retinal hyperoxia resulting from postnatal hyperoxemia in infants receiving supplemental oxygen to compensate for inadequate pulmonary function. This condition, alone or in combination with other as yet unidentified results, leads to cessation of retinal vessel development. The retinal vasculature then enters a quiescent phase for days or weeks, while the formation of a ridge-like structure develops, separating the central vascularized region of the retina from the peripheral avascular region. This structure, which is pathognomonic of ROP, historically consists of mesenchymal and endothelial cells. Concomitant development of retinal neurons with advancing postnatal age results in increasing oxygen requirements, which cannot be met by attenuated vessel complement in retinal hypoxia (Weiter & Zucherman & Schepens 1982). As a result of hypoxia another as yet undefined stimulus, angiogenic growth factor induction occurs,

followed by rapid growth of new vessels within the ridge .The new vessels can regress by involution and remodeling into a nearly normal vascular pattern or the growth can progress to extraretinal neovascularization (Nelson,1790). These extraretinal vessels are weak and prone to leakage. The result is vitreous hemorrhage, scarring and contraction, leading to retinal folds or detachments and vision (loss Foos, 1985).

ROP is called stage 1 when the growing vessels end abruptly at a noticeable line separating the vascular and avascular retina takes on height and width ,it becomes a ridge and casts a little shadow; the ridge is stage 2 ROP .When the bunched up vessels in a stage 2 eye erupt into the vitreous ,The ROP becomes stage 3 and can be of variable severity .The greater the amount of extraretinal neovascularization vertically, and the greater the extent of the disease's spread around the retina, the stage 3 will be more sever. If the ROP progresses further, exudative and tractional retinal detachments occur and may be partial (stage 4) or complete (stage 5) (Phelps, 1992).

In the premature infants, the developing capillaries without a basement membrane or supporting predicts completely ablate during a prolonged period of absent retinal flow .it remains in dispute whether the vascular ablation in the premature infants is due to direct oxidative injury of the growing endothelium (Chan- Ling& Gock & Stone, 1995) Or is nearly the consequence of prolonged vasoconstriction due to a disturbed auto regulatory mechanism of the retinal vessels (Ashton & Cook,1954).The level of antioxidative in the immature retina is relatively low and therefore oxygen radicals which accumulate in the preterm baby's retina may play an important role in the pathogenesis of ROP (Hesse et al, 1997).

2.4 Terminology of ROP

The severity of ROP is described by four parameters: stage, location, extent and plus disease (table 1).

2.5 Screening for ROP

Since 1988, following the demonstration by the CRYO-ROP trial, sever ROP can be successfully treated so the ophthalmologists have had a duty to screen for this condition. The focus of screening is to identify ROP that requires treatment, at the appropriate point in the disease progression. The indication for treatment which has been reported in the CRYO-ROP study is threshold ROP. The term threshold denotes the ROP stage at which spontaneous and complete resolution is unlikely and the risk of blindness is predicted to be close to 50% (Cryotherapy for retinopathy of Prematurity Cooperative Group, 1988).The CRYO-ROP study divided all the diseases of the stage 3 into two categories: pre-threshold (or moderate ROP) and threshold (or severe ROP).Any disease of the stage 3 less than threshold was considered pre-threshold. Threshold ROP was defined as stage 3 ROP in zones one and two, in the presence of plus disease. Further studies such as that published recently by the Early Treatment for Retinopathy of Prematurity Cooperative Group (ETROP) recommends treating eyes before threshold because the outcomes of some eyes treated once they have develop threshold disease has been poor (ET-ROP,1997).

Parameter	Description
Stage 1	Demarcation line at the advancing edge of the retinal blood vessels
2	Ridge
	Stage 1 and 2 are referred to as mild ROP as they often undergo spontaneous resolution and do not result in visually disabling ophthalmic sequelae
3	Ridge with Extraretinal Fibrovascular proliferation .This is the first stage of ROP that presents a significant risk of poor structural or visual outcome and thus represents serious disease. Shunt lesions are well developed at the demarcation line and are often associated with “plus” (posterior retinal congestion). Further progression is characterized by development of secondary vitreous haze which heralds the onset of vitreoretinopathy leading to more sight threatening sequelae
4	Retinal detachment and partial retinal detachment a) the macula is attached b) the macula is detached
5	Total Funnel Retinal detachment
	Stage IV and V result in some permanent visual impairment despite surgical intervention
Location Zone 1-3	This predictable pattern of retinal vascularisation was formally recognized by the international classification of retinopathy (ICROP) in 1984 and 1987, which divided the retina into progressive concentric zones. The location of ROP is described in terms of these three arbitrarily defined ICROP zones which are centered around the optic disk
Extent 1-12	This is described by clock hours by 30 degree sectors.
Plus disease	Plus disease is characterized by active progression and at a more advanced stage the iris becomes congested resulting in poor pupil dilatation. The presence of the disease is an urgent indication for treatment

Table 1. Terminology of retinopathy of prematurity (ROP)

3. Blood transfusion in preterm infants

Preterm infants, especially those with very low birth weight (VLBW) prematurity, often need multiple blood transfusions during hospitalization. Over 50-80% of VLBW preterm infants receive at least one blood transfusion during their neonatal intensive care unit (NICU) stay (Strauss, 1997). In addition to phlebotomy losses causing low hematocrit, most VLBW infants develop the anemia of prematurity (AOP) a hypoproliferative anemia marked by inadequate production of erythropoietin (EPO). Treatment of AOP include red blood cell transfusions which are given to preterm infants based on indications and guidelines (hematocrit/ hemoglobin levels, ventilation and oxygen) that are relatively non-specific (Bishara,2008).

Transfusions to VLBW premature infants could increase weight gain, improve oxygenation and decrease lactic acidosis (Ohls, 2000). The complications and potential risk of blood transfusions include blood – transmitted infection, metabolic and cardiovascular complications, graft versus host disease, iron overload and increased oxidative stress, which

are thought to be related to complications in premature infants such as chronic lung disease (CLD) and retinopathy of prematurity (ROP) (Cooke et al ,1997;Saugstad ,2003;Englert et al ,2001;Wheatley et al ,2002)considering the available evidence, many neonatal units have adopted more restrictive transfusion guidelines to reduce the frequency of transfusions and donor exposure (Windes et al, 1996; Alagappan& Shattuck& Malloy,1998; Maier et al, 2000;Franz & Pohlandt ,2001)But, these changes in practice have not been accompanied by systematic examination of the safety or potential benefits of restricting transfusions. Limiting RBC transfusion in preterm infants may reduce the potential risk of transfusion, but the resulting low hemoglobin levels may result in the morbidities associated with chronic anemic hypoxemia as recommended by some studies that advocate more than liberal transfusion guidelines to prevent apnea (Ross et al, 1989), to foster weight gain (Meyer & sive & Jacobs, 1993). More recent trials have been performed to determine the safety and efficacy of more restrictive transfusion guidelines.

Bifano was the first to evaluate neonatal transfusion guideline in prospective fashion [76]. This study compared the clinical outcomes of two groups of Extremely Low Birth Weight (ELBW) infants who were randomly assigned to restrictive or liberal transfusion criteria, based on hemoglobin thresholds for transfusion. There were no differences between groups in growth, morbidities, or mortality during hospitalization. At 12 months follow up, there were no differences in overall neurodevelopmental impairment. This study suggested that a restrictive transfusion strategy was not associated with adverse outcomes.

Bell et al. conducted a randomized trial of liberal versus restrictive guidelines for bronze baby syndrome (BBS) transfusion in preterm infants and showed that restrictive transfusions may be harmful to preterm infants in the restrictive group which had a greater incidence of intraparenchymal brain hemorrhage or periventricular leukomalacia and more frequent episodes of apnea (Bell et al, 2005).

Bednerek et al. in a prospective study examined the relationships of high and low transfusion practice styles on neonatal outcomes (Bednerek et al ,1998).Multivariate analyses showed that infants cared for in the lower transfer NICU did not have an increased risk for several adverse outcomes including IVH, NEC, BPD, Lesser weight gain, and longer hospitalizations. Kirpalani et al, performed a study to determine whether extremely low birth weight infants transfused at lower hemoglobin thresholds versus higher thresholds have different rates of survival or morbidity at discharge (Kirpalani et al, 2006).These investigators concluded that, in ELBW infants, maintaining a higher hemoglobin level result in more infants receiving transfusions but confer little evidence of benefit. This study provided evidence that transfusion thresholds in ELBW infants can be moved downward at least 10g/L, without incurring a clinically important increase in the risk of death or major neonatal morbidity.

However, most of the neonatal studies published up to the present measured what infants received, regardless of actual need for red cells. Transfusion guidelines and practices would benefit from studies that identify a useful transfusion marker, preferably one that requires minimal to no blood (Ohls, 2008).

4. The effect of blood transfusion on ROP

The role of blood transfusions as a risk factor for ROP was first suggested by Shohat et al (Shohat et al 1983), and other authors subsequently confirmed this association(Shohat et al

1983; Cats & Tan KEW, 1985; Clark et al, 1981; Cooke et al, 1993; Sacks et al, (1981); Ebrahim Mikaniki et al, 2010; Yu & Hookham & Nave, 1982), some investigators, however, could not confirm it (Bossi et al, 1984; Brown, 1987; Cooke et al; Lechner et al, 1977). multivariate regression analysis found that only gestational age and frequency of blood transfusions are independently associated with the risk of occurrence of ROP (Cooke et al, 1993). They reported a 9% increase in the risk of ROP with each transfusion given (95% CI 1.0-1.18). But data on iron metabolism were not analyzed and no information was given about the actual volume of transfused blood. Hesse et al demonstrated by the same statistical method, that blood transfusions are an independent risk factor for ROP. In this study, the relative risk of developing ROP was 6.4 (95% CI 1.2-33.4) for infants who received 16-45 ml/kg, and 12.3 (1.6-92.5) for those who had received more than 45 ml/kg of blood (reference, 0-15 ml/kg) (Hesse et al 1997). In contrast, there was no independent relationship between ROP and any of the parameters on iron metabolism analysis. Inder et al after multivariate regression analysis, showed that an elevation of serum iron and transferrin saturation at 7 days of age is associated with an increased risk of ROP: they could not demonstrate an independent role of blood transfusions as a risk factor for ROP, but demonstrated that the iron status and the amount of transfused blood are highly correlated factors (Inder et al, 1997). Bossi et al, in another study, could not confirm an independent role of blood transfusion on development of ROP (Bossi et al, 1984).

Brooks et al, through a randomized, controlled trial, found that there was no association between hemoglobin or hematocrit ratios and ROP incidence or severity and transfusion limitation policy do not import a significant different risk for ROP (Brooks et al 1999). However in this study, the risk of ROP was related to the number and not the volume of blood transfusion, and the incidence of ROP in the studied population was so high (76%) that it seems to be difficult to decrease the occurrence of ROP only by limiting the blood transfusions. More recently, Dani et al. showed that gestational age, blood transfusion volume and iron load by transfusions are associated with the risk of occurrence of ROP in infants with a birth weight of less than 1250 g. in this study, logistic regression analysis demonstrated that transfusion volume during the first week (OR 1.16; 95% CI 1.03-1.3) and during the first 2 months of life (OR 2.93; 95% CI 1.52-5.62), and iron intake during the first week of life (OR 1.15; CI 1.01-1.32) and during the first 2 months of life (OR 2.93; 95% CI 1.52-5.62) were associated with the development of ROP [87]. Two mechanisms by which blood transfusion could contribute to the development of ROP are discussed. First, Transfusions increase oxygen carrying capacity and a decrease in oxygen affinity caused by an increase in the proportion of adult hemoglobin. Second, transfusion increase iron load.

Sullivan Pointed out that the transfusion of 10 ml of packed red blood cells will increase the premature infant's total body iron by 20%, and that packed red blood cells contain 450 times as much hemoglobin iron as the plasma total iron-binding capacity (Sullivan, JL, 1988). This, in conjunction with the reduced iron-binding capacity of preterm infants (due to their low transferrin and ceruloplasmin levels) and postnatal depression of erythrocyte production, makes preterm infants who are repeatedly transfused extremely susceptible to an accumulation of increased amounts of free iron. Free iron could catalyze fenton reactions which produce highly reactive oxygen-derived free radicals and are assumed to play an important role in the pathogenesis of ROP.

5. Conclusion

The increased survival of very small premature infants in modern NICUs led to increasing the incidence of ROP (Gibson et al, 1990; Gibson et al, 1990). Since ROP may produce serious sequel of infant blindness, all efforts must be made to prevent the development of advanced ROP. Identification of ROP risk factors will help to understand and predict ROP development in premature newborns (Akkoyun et al, 2006). One such risk factor may be multiple blood transfusions. Studies on the role of blood transfusion in ROP however have been hampered by the multifactorial nature of this disease and by the fact that most risk factors For ROP, including blood transfusions, are closely related to prematurity and are thus highly interdependent. This makes it different to define the specific role of any individual factor in the pathogenesis of ROP (Hesse et al 1997).

Using multivariate regression analysis ,which provides a helpful tool in such a situation, some studies demonstrated that blood transfusion had a strong and dose-dependent influence on the development of ROP (Hesse et al 1997; Cooke et al, 1993; Dani et al , 2001).Otherwise, some investigators reported that the limitation of blood transfusion dose not affect ROP incidence(Bossi et al, 1984;Brooks et al 1999).

The reported mechanisms by which blood transfusions could contribute to the development of ROP are (1) the increase of Oxygen delivery to the retina (James&Greenough&Naik, 1997) due to lower oxygen affinity of adult hemoglobin in pack red cell (Cooke et al, 1993), and (2) the secondary iron overload.

The reduced iron-binding capacity of preterm infants due to their low transferrin levels (Scott et al, 1975) makes preterm infants who are repeatedly transfused extremely susceptible to an accumulation of increased amounts of free iron. This problem catalyze Fenton reactions which produce free hydroxyl radicals capable of damaging the retina (Wardle et al, 2002).Despite a strong and independent association between ROP and blood transfusions, parameter suggestive of increased free iron, such as low transferrin or high ferritin levels, there not found to be independently associated with ROP in the one of related studies (Hesse et al 1997). It cannot be concluded from this data that a more restrictive transfusion policy will reduce the incidence of ROP, particularly as there is evidence that low levels of tissue oxygenation, which would be expected if VLBW infants are transfused less frequently, may also be a risk for ROP (Bauer & Windmayer, 1981). Otherwise, transfusion practices may differ considerably among both institutions and individual physicians because of a lack of uniformly accepted physiologic or evidence-based transfusion criteria (Brown &Berman&Luckey, 1990).

Decisions about transfusing VLBW infants with RBCs should be based on the risks and benefits of applying various transfusions guidelines and further refining based on the clinical status of individual infants .Recent studies suggests that frequent transfusions did not offer a detectable advantage and restricted transfusion did not have an increased risk for major brain injury as reported in previous studies (Ross et al, 1989; Chen et al, 2009)

Albeit, these results must be interpreted with caution, because they may be related to other co practices in the specific NICU.

Further studies will be required to clarify whether as reduction in the number of transfusions will ultimately result in a reduced incidence of ROP without any significant difference in clinical outcome

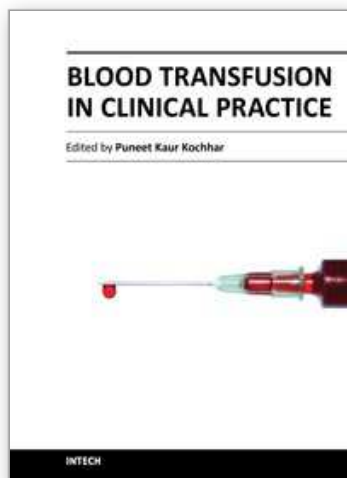
6. References

- Akkoyun, I.& et al. (2006). Risk factors in the development of mild and sever retinopathy of prematurity. *J AA*, vol.10 pp. 449-453
- Alagappan, A., Shattuck, KE.& Malloy, MH. (1998).Impact of transfusion guidelines on neonatal transfusion. *J perinatal*, vol.18, pp.92-7
- Alugappan, A., Shattuck, KG.& Malloy, MN. (1998). Impact of transfusion guidelines a neonatal transfusion. *J Perinatal* vol 18 pp 92-97
- Ashton, N.& Cook, C.,(1954) Direct Observation of the effect of oxygen on developing vessels: Preliminary report. *Br J Ophthalmol* vol 38 pp 433-440
- Avery, ME.& Oppenheimer, EH.(1960). Recent increase in mortality from hyaline membrane disease. *J Pediatr*. Vol 57 pp 553-9
- Bauer, CR.& Windmayer, SM.(1981). A relationship between PaCo₂ and retrolental fibroplasia. *Pediatr Res*, vol. 15, pp. 649-45
- Bell, EF& et al.(2005). Randomized trial of liberal versus restrictive guidelines for blood cell transfusions in preterm infants. *Pediatrics*, vol.115, pp.1685-91
- Bednarek, FJ& et al.(1998). Variations in blood transfusion among newborn intensive care units. *J Pediatr*, vol.133, pp.601-7
- Bifano, EN, Bode, MM.&Eugenio, DB.(2002) Prospective randomized trial of high vs. low hematocrit in ELBW infants: one-year growth and neurodevelopmental outcome. *Pediatr Res*, vol.51, pp.325A
- Biglan, AW.&et al. (1984). Risk factors associated with retrolental fibroplasia. *Ophthalmology*, vol. 91,pp. 1504-1511
- Bishara, N.& ohls, RK.(2008).current Controversies in the management of the anemia of prematurity. *Semin perinatal*, vol.33 pp.29-34
- Bossi, E.&et al.(1984) Retinopathy of prematurity: a risk factor analysis with univariate and multivariate statistics. *Helv paediatr Acta* pp 307-317
- Brooks, SE& et al.(1999).The effect of blood transfusion protocol on retinopathy of prematurity :a prospective randomized study ,*pediatrics* ,vol.104,p.514-518
- Brown, DR.(1987) Retinopathy of prematurity. Risk factors in a live- year cohort of critically ill premature neonates. *Am J Dis child* vol 141 pp 154-160
- Brown, MS,Berman, ER.&Luckey D.(1990).prediction of need for transfusion during anemia of prematurity .*J Pediatr*,vol.116, pp.773-8
- Bullord, SR.& et al.(1998) The decreasing incidence and severity of retinopathy of prematurity. *Journal of AAOPOS* vol 3 pp 46-52
- Caddell, JL.(1995). Hypothesis: the possible role of magnesium and copper deficiency in retinopathy of prematurity. *Magnes Res*, vol. 8, pp. 261-267
- Cats, BP., Tan KEW.(1985) Retinopathy of prematurity: review of a four-year period. *Br J Ophthalmol* vol 69 pp 500-503
- Chan- Ling, T., Gock, B.& Stone, J.(1995) The effect of oxygen on vaseformation cell division: Evidence that the physiological hypoxia is the stimulus for normal retinal vasculogenesis. *Invert Ophthalmol Vis Sci* vol 36, pp. 1201- 1214
- Chen, HL& et al.(2009).Effect of blood transfusion on the outcome of very low body weight preterm infants under two different transfusion criteria.*pediatr Neonatal* ,vol.50,pp.110-116
- Chiang, MF.& et al.(2004). Incidence of retinopathy of prematurity from 1996 to 2000. *Ophthalmology*, vol. 111, pp.1317-1325

- Chow, LC., Wright, KW& Sola A (2003). Can changes in clinical practice decrease the incidence of sever retinopathy of prematurity in very low birth weight infants? *Pediatrics* vol 111 pp 339-345
- Clark J.& et al.(1981) Blood Transfusion: a possible risk factor in retrolental fibroplasia. *Acta Paediatr Scand.* vol 70 pp 535-539
- Cooke, RW.& et al.(1997). Blood transfusion and chronic lung disease in preterm infants. *Eur j Paediatr*, vol, pp.156:45-50
- Cryotherapy for retinopathy of Prematurity Cooperative Group Multi Center trial of cryotherapy for retinopathy of prematurity, preliminary results (1988). *Arch Ophthalmol*, vol.106, pp.471-479
- Cryotherapy for retinopathy of prematurity cooperative group.(1994). The natural ocular outcome of premature birth and retinopathy: status at 1 year. *Arch Ophthalmol*. Vol 112: 903-912
- Custick, M.& et al.(2006). Anatomical and visual results of vitreoretinal surgery for stage 5 retinopathy of prematurity. *Retina*, vol. 26, pp.729-735
- Dani, C.& et al. (2001)The role of blood transfusions and iron intake on retinopathy of prematurity. *Early Human Development*, vol 62, pp.57-63
- Drack, AV.(1998). Preventing blindness in premature infants. *N. Engl. J. Med.* 338: 1620-1621
- Early Treatment for Retinopathy of Prematurity Cooperative Group (ETROP).(1997).Revised indications for the treatment of retinopathy of prematurity. *Arch Ophthalmol* ,vol.121, pp.1684-1696
- Englert, JA.& et al.(2001) .The effect of anemia on retinopathy of prematurity in extremely low birth weight infants. *J perinatal*, vol.21, pp.21-6
- Fledelius, HC., Dahl, H.(2000). Retinopathy of prematurity, a decrease in frequency and severity. Trends over 16 years in a Danish Country. *Acta Ophthalmol Scand*, vol. 78 pp. 359-361
- Foos, RY.(1985). Chronic retinopathy of prematurity. *Ophthalmology* .vol 92 pp 573- 574
- Franz, AR.& Pohlandt, F.(2001). Red blood cell transfusions in very and extremely low birth weight infants under restrictive transfusion guidelines: is exogenous erythropoietin necessary? *Arch Dis child Fetal Neonatal* vol 84 pp 96-100.
- Franz, AR.& Pohlandt, F .(2001).Red blood cell transfusion in very and extremely low birth weight infants under restrictive transfusion guidelines: is exogenous erythropoietin necessary? *Arch fetal neonatal*, vol.84, pp.96-100.
- Gibson, DL.& et al .(1990).Retinopathy of prematurity -induced blindness: birth weight -specific survival and the new epidemic. *Pediatrics*, vol.86, pp.405-412.
- Glass. P.& et al.(1985). Effect of bright light in the hospital nursery on the incidence of retinopathy of prematurity. *N Eng J Med*, vol. 313,pp. 410-414
- Gunn, TR.& et al.(1980). Risk factors in retrolental fibroplasia. *Pediatrics* vol 65, pp. 1096-1100.
- Hammer, ME.& et al.(1986). Logistic analysis of risk factors in acute retinopathy of prematurity. *Am J Ophthalmol* vol. 102, pp. 1-6.
- Hesse, L. et al (1997). Blood Transfusion: Iron load and retinopathy of prematurity. *Eur J Paediatr*, vol 156, pp 465-470.
- Hussain, N., Clive, J.& Bhandori, V.(1999). Current incidence of retinopathy of prematurity, 1989- 1997. *Pediatrics*, vol 104, pp. 26.33.
- Inder, TE .& et al.(1997).High iron status in very low birth weight infants is associated with an increased risk of retinopathy of prematurity, *J Paediatr* ,vol.131,pp.541-544.
- James L, Greenough A, Naik S.The effect of blood transfusion on oxygenation in premature ventilated neonates, *Eur.J.paediatr* .1997;156:139-141.

- James, LS.& Lamman, JT.(1976). History of oxygen therapy and retrolental fibroplasia. *Pediatrics* vol 57 pp 591-642.
- Kalina, RE.& Kari, DJ.(1982). Retrolental Fibroplasia: experience over two decades in one institution. *Ophthalmology* vol 89 pp 91-95.
- Kinsey, VE. et al.(1977). Pa O₂ levels and retrolental fibroplasias: a report of the cooperative study. *Pediatrics*. Vol 60 pp 655-668.
- Kirpalani, H,et al .(2006).A randomized controlled trial of a restrictive (low) versus liberal(high) transfusion threshold for extremely low birth weight infants. The PLNT study.*J Pediatr*, vol.149, pp.301-7.
- Lad, EM.et al (2009). Incidence of retinopathy of prematurity in the United States: 1997 through 2005. *American Journal of ophthalmology*.vol 148, pp 451-58.
- Lechner, D., Kalina, RE.& Hodson, WA.(1977). Retrolental Fibroplasia and factors influencing oxygen transport. *Pediatrics*, vol 59 pp 916-91.
- Lechner, D., Kokina, RE.&Hodson, WA.(1977)Retrolental fibroplasia and factors influencing oxygen transport .*pediatrics*, vol.59, pp.916-918.
- Lucey, JF.& Dangman, B.(1984). A reexamination of the role of oxygen in retrolental fibroplasia. *Pediatrics*.vol. 73, pp. 82-96.
- Maier, RF.& et al.(2000).Changing practices of red blood cell transfusion in infants with birth weight less than 1000 g .*J Pediatr*,vol.136,pp.220-4.
- Maies, RF.& et al.(2000). Changing practices of red blood cell transfusions in infants with birth weight less than 1000 g. *J Pediatr* vol 136 pp 220-224.
- Mccolm, JR.& Fleck, EW.(2001). Retinopathy of prematurity: Causation. *Semin Neonatal*, vol. 6, pp. 453-460.
- McDonald, AO.(1963) Cerebral palsy in children of very low birth weight. *Arch Dis child*. vol 38 pp 579-88.
- Meyer, J.,sive, A.&Jacobs, P. (1993) Empiric red cell transfusion in asymptomatic preterm infants .*Acta paediatr*,vol.82,pp.30-4.
- Mikaniki, E., Rasoulinejad, SA.& Mikaniki M.(2010).Incidence and Risk factors of retinopathy of prematurity in Babol, North of Iran. *Ophthalmic Epidemiology*, vol.17, pp.166.70.
- Nelson, L. (1790). Disorders of the Eye, In: *Nelson textbook of pediatrics*, Vol.15, pp. 1790, Saunders, London
- Ohls, RK.(2008).why when and how should we provide red cell transfusions to neonates ,In *Hematology, Immunology and infections disease*, ohls R,Yoder MC,pp.44-57,Elisevir, Philadelphia
- Ohls, Rk.(2000). The use of erythropoietin in neonates. *Clin perinatal*, Vol.27. pp.681-696.
- Owens, WC.& Owens, EV.(1949). Retrolental Fibroplasia in premature infants: the use of alpha tocopherol acetate. *Am J Ophthalmol*, vol. 32, pp.1631-1637.
- Palmer, EA, RJ, et al. (1991). Incidence and early course of retinopathy of prematurity. The cryotherapy for retinopathy of prematurity cooperative group. *Ophthalmology* vol 98 pp 1628-1640.
- Papp, A., Nemeth, I.& Pelle Z.(1993). Retrospective biochemical study of the preventive property of antioxidants in retinopathy of prematurity. *Orv Hetil*, vol. 134, pp.1021-1026.
- Patz, A. (1969). Retrolental fibroplasia. *Surv Ophthalmol* vol. 14, pp. 1-29.40
- Payne, JW.& Patz, A.(1979). Current states of retrolental fibroplasias. *Ann Clin Res*, vol. 11, pp. 205-211.
- Phelps DL.(1992).Retinopathy of prematurity. *Current problems in pediatrics*. pp. 349-371.
- Quinn, G.(1998). Retinal development and the pathophysiology of retinopathy of prematurity. *Polin and fox fetal and neonatal physiology*. Vol 2 London: Saunders pp 2252

- Reynolds, JD.& et al.(1998). Lack of efficacy of light reduction in preventing retinopathy of prematurity. Light reduction in retinopathy of prematurity (LIGHT-ROP) Cooperative group. *N Eng J Med* vol. 338, pp. 1572-6.
- Ross, MP.& et al .(1989).A randomized trial to develop criteria for administering erythrocyte transfusions to anemic preterm infants 1 to 3 months of age. *J perinatal*, vol.9,pp.246-53.
- Rowlands, E.& et al.(2001). Reduced incidence of retinopathy of prematurity. *Br J Ophthalmol*, vol. 85,pp. 933-935.
- Sacks LM.& et al.(1981) Retrolental fibroplasia and blood transfusion in very low- birth-weight infants. *Pediatrics* vol 68 pp 770-774.
- Saugstad, OD.(2003) Bronchopulmonary dysplasia-oxidative stress and antioxidants .*Semin Neonatal*, vol 8 ,pp.39-49.
- Saunders, RA.& et al.(1997). Racial Variation in retinopathy of prematurity: the cryopathy for retinopathy of prematurity cooperative Group. *Arch Ophthalmol*, vol. 115, pp. 604-608.
- Schaffer, DB.& et al.(1993). Prognostic factors in the natural course of retinopathy of prematurity. *Ophthalmology*, vol. 100, pp. 230-7
- Scott, PH &et al.(1975).Effect of gestational age and intrauterine nutrition on plasma transfusion and iron in the newborn. *Arch Dis child*.vol.50 pp.796-798.
- Shohat, M. et al.(1983). Retinopathy of prematurity: Incidence and risk factors. *Pediatrics*. 1983; 72: 159-163.
- Strauss, RG.(1997). Practical issues in neonatal transfusion practice. *Am J Clin Pathol*, vol.107,pp.557-563.
- Sullivan, JL.(1988) Iron, Plasma antioxidants, and the oxygen radical disease of prematurity. *Am J Dis Child*.vol 142 pp 1341-1344.
- Terry, TL.(1942).Extreme prematurity and fibroblastic overgrowth of persistent vascular sheath behind each crystalline lens. *Am J Ophthalmol* vol 25 pp 203-204.
- Valentine, PH.& Et al .(1991) Increased survival of low birth weight infants: impact on the incidence of retinopathy of prematurity. *Pediatrics* vol 84 pp 442-5.
- Wardle, SP.& et al.(2002).Effect of blood transfusion lipid proxidation in preterm infants. *Arch dis child fetal neonatal*, vol.86, pp.46-8.
- Weiter, JJ., Zucherman, R.& Schepens, CL.(1982). A Model for the pathogenesis of retrolental fibroplasia based on the metabolic control of blood vessel development. *Ophthalmic Surg* vol. 13 pp. 1013-1017.
- Wheatley, CM.& et al.(2002). Retinopathy of prematurity: recent advances in our understanding. *Arc Dis child Fetal Neonatal*, vol.87, pp.78-82.
- Widness, JA.& et al.(1996) changing patterns of red blood cell transfusion in very low birth weight infants. *J Pediatr* vol 129 pp 680-7.
- Windes, JA.& et al.(1996).Changing patterns of red blood cell transfusion in very low birth weight infants *J Pediatr*, vol.129 ,pp.680-7.
- Wright, K.& et al.(1998). Should fewer premature infants be screened for retinopathy of prematurity in the managed care era? *Pediatrics*, vol.102, pp. 31-34.
- Yang, MB.& et al.(2006). Race, Gender, and clinical risk index for babies (CRIB) Score as predictors of severe retinopathy of prematurely. *J AAPOS*, vol 10 pp. 253-261.
- Yu, VY.,Lim, CT.&Downe, LM.(1990).A 12-years experience of retinopathy of prematurity in infants ≤ 28 weeks gestation or ≤ 1000 g birth weight. *J Pediatr child health*, vol.26, pp.205-208.
- Yu, VYH., Hookham, DM.& Nave JRM.(1982) Retrolental fibroplasias- controlled study of 4 years' experience in a neonatal intensive care unit. *Arch Dis Child* vol 57 pp 247-252.
- Zacharias, L.(1952) Retrolental fibroplasias survey. *Am J Ophthalmol*. Vol 35 pp 1427-1454.



Blood Transfusion in Clinical Practice

Edited by Dr. Puneet Kochhar

ISBN 978-953-51-0343-1

Hard cover, 272 pages

Publisher InTech

Published online 16, March, 2012

Published in print edition March, 2012

Blood Transfusion in Clinical Practice focuses on the application of blood transfusion in different clinical settings. The text has been divided into five sections. The first section includes a chapter describing the basic principles of ABO blood group system in blood transfusion. The second section discusses the use of transfusion in various clinical settings including orthopedics, obstetrics, cardiac surgery, etc. The third section covers transfusion transmitted infections, while section four describes alternative strategies to allogenic blood transfusion. The last section speculates over immunomodulatory effects of blood transfusion.

How to reference

In order to correctly reference this scholarly work, feel free to copy and paste the following:

Ebrahim Mikaniki, Mohammad Mikaniki and Amir Hosein Shirzadian (2012). Effects of Blood Transfusion on Retinopathy of Prematurity, Blood Transfusion in Clinical Practice, Dr. Puneet Kochhar (Ed.), ISBN: 978-953-51-0343-1, InTech, Available from: <http://www.intechopen.com/books/blood-transfusion-in-clinical-practice/effects-of-blood-transfusion-on-retinopathy-of-prematurity>

INTECH
open science | open minds

InTech Europe

University Campus STeP Ri
Slavka Krautzeka 83/A
51000 Rijeka, Croatia
Phone: +385 (51) 770 447
Fax: +385 (51) 686 166
www.intechopen.com

InTech China

Unit 405, Office Block, Hotel Equatorial Shanghai
No.65, Yan An Road (West), Shanghai, 200040, China
中国上海市延安西路65号上海国际贵都大饭店办公楼405单元
Phone: +86-21-62489820
Fax: +86-21-62489821

© 2012 The Author(s). Licensee IntechOpen. This is an open access article distributed under the terms of the [Creative Commons Attribution 3.0 License](https://creativecommons.org/licenses/by/3.0/), which permits unrestricted use, distribution, and reproduction in any medium, provided the original work is properly cited.

IntechOpen

IntechOpen