

We are IntechOpen, the world's leading publisher of Open Access books Built by scientists, for scientists

6,900

Open access books available

185,000

International authors and editors

200M

Downloads

Our authors are among the

154

Countries delivered to

TOP 1%

most cited scientists

12.2%

Contributors from top 500 universities



WEB OF SCIENCE™

Selection of our books indexed in the Book Citation Index
in Web of Science™ Core Collection (BKCI)

Interested in publishing with us?
Contact book.department@intechopen.com

Numbers displayed above are based on latest data collected.
For more information visit www.intechopen.com



Anatomy and Clinical Importance of the Epidural Space

Sotonye Fyneface-Ogan

*Department of Anaesthesiology, Faculty of Clinical Sciences,
College of Health Sciences, University of Port Harcourt,
Nigeria*

1. Introduction

The epidural space is one of the most explored spaces of the human body. This exploration demands a good knowledge of the relevant anatomy and contents of the space. First described in 1901 (Corning JL, 1901), the epidural space is an anatomic compartment between the dural sheath and the spinal canal. In some areas it is a real space and in others only a potential space.

Various methods have been used to study the anatomy of the epidural space by investigators. Methods such as epiduroscopy in cadavers and patients, anatomical dissection, Magnetic Resonance Imaging (MRI), Computerized Tomographic epidurography (Yan et al., 2010), epidural injections of resins and the use of cryomicrotome sectioning in cadavers frozen soon after death (Hogan QH, 1991), have been used to demonstrate the inner layout of the space.

The use of the term 'space' has been controversial amongst anatomists. It is argued that the term would be more appropriate for the subarachnoid space than the epidural. It is claimed that the epidural space is not an open anatomical space whether in life or death. The only time a space is present is when the dura mater is artificially separated from the overlying vertebral canal by injection of contrast media or solutions of local anesthetics (Parkin & Harrison, 1985).

2. Embryology of the epidural space

Histological transverse sections of human lumbar spines of adults and fetuses aged 13, 15, 21, 32 and 39 weeks (menstrual age) were studied (Hamid et al., 2002). It was found that at the 13th week the epidural space had been filled with connective tissue and the dura mater was attached to the posterior longitudinal ligament. By the 13th week of embryonic development, three distinct stages had been formed and differentiate progressively within the connective tissue (Rodionov et al., 2010).

These are:

- the primary epidural space (embryos of 16-31 mm crown-rump length (CRL));
- reduction of the primary epidural space (embryos of 35-55 mm CRL);

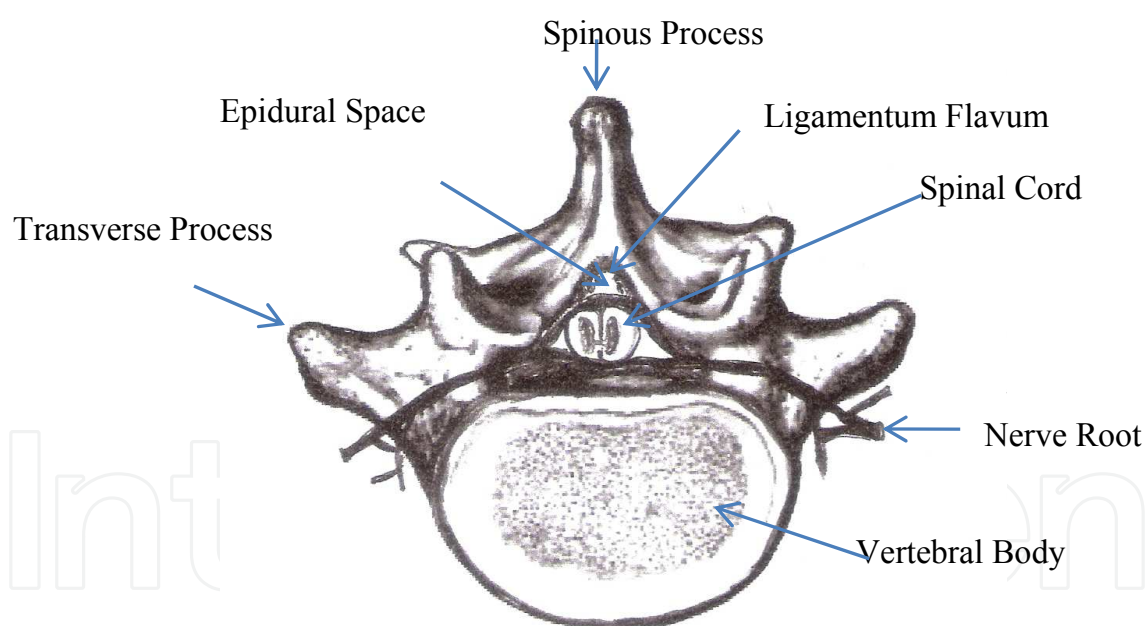
- the secondary epidural space (embryos of 60-70 mm CRL and fetuses of 80-90 mm CRL).

It has been found that the morphogenesis of the primary epidural space is determined by the formative influence of the spinal cord and its dura mater, while that of the secondary epidural space is determined by the walls of the vertebral canal (Rodionov et al., 2010).

Within this period of embryonic life, the posterior longitudinal ligament (PLL) attaches to the vertebral body beside the midline, and to the posterior edge of intervertebral disc. The anterior internal vertebral venous plexus is formed and located anterolaterally and anteromedially. At 15 weeks, the posterior longitudinal ligament develops better into deep and superficial layers. At 21 weeks, the attachment between the dura mater and PLL was ligament-like at the level of the vertebral body (Hamid et al., 2002). At 32 weeks, the dura mater was adherent to the superficial layer of PLL. At 39 weeks, groups of adipocytes begin to develop.

3. Anatomy

The vertebral column is made up of 24 individual vertebrae comprising 7 cervical, 12 thoracic and 5 lumbar while 5 sacral vertebrae are fused and the 3-5 coccygeal bones, though fused, remain rudimentary. These vertebrae house the epidural and the subarachnoid spaces.

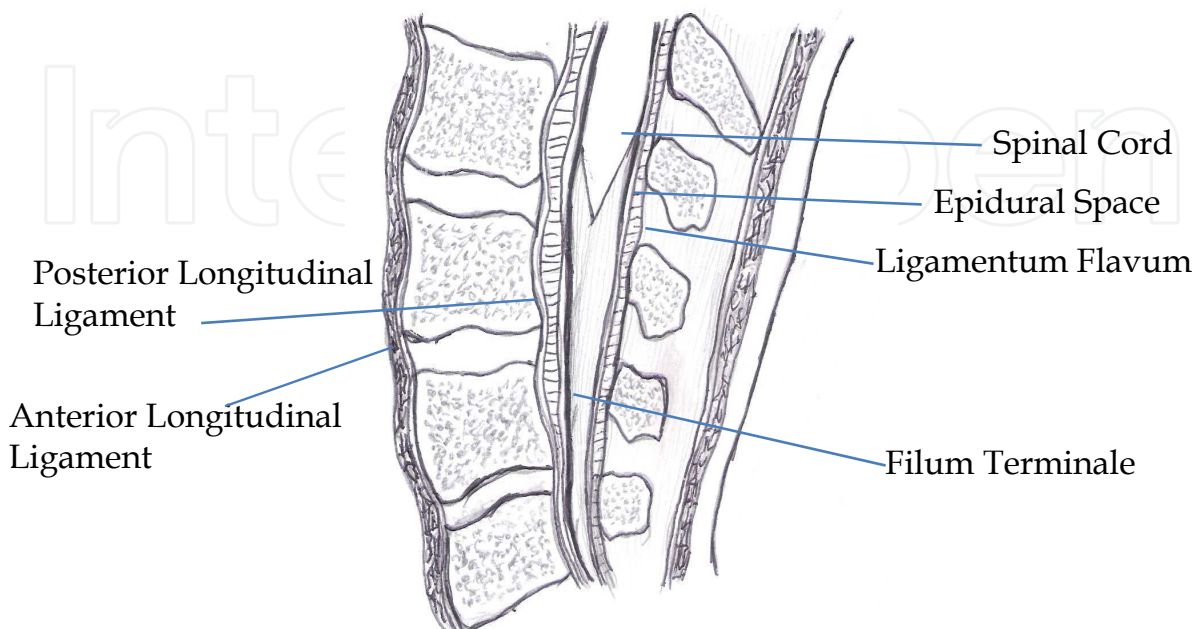


Transverse Section of the Lumbar Vertebra

3.1 Measurement of the epidural space

The epidural space is most roomy at the upper thoracic levels. The epidural space at the posterior space in the adult measures about 0.4 mm at C7-T1, 7.5 mm in the upper thoracic region, 4.1 mm at T11-12 region and 4-7 mm in the lumbar region, (Nickallis & Kokri, 1986). The space is far greater than that of the subarachnoid space at the same level. It takes about

1.5 – 2.0 ml of a local anesthetic to block a spinal segment in the epidural space while the volume (0.3 ml) is far less in the subarachnoid space for a similar block. It has been shown (Macintosh and Lee, 1973) that the paravertebral spaces, both serially and contralaterally, communicate with each other in the epidural space.



Sagittal section of the Lumbar Region

3.2 Shape and size of the epidural space

These are largely determined by the shape of the lumbar vertebral canal and the position and size of the dural sac within it. It has been suggested that though merely a potential space (Bromage, 1978) it could be up to 5 mm in depth (Husemeyer & White, 1980).

3.3 Types of epidural space

The epidural space can be categorized into cervical, thoracic, lumbar and sacral epidural spaces. These spaces can be defined according to their margins. At the cervical epidural space, there is a fusion of the spinal and periosteal layers of dura mater at the foramen magnum to lower margin of the 7th cervical vertebra. While the thoracic epidural space is formed by the lower margin of C7 to the upper margin of L1, the lumbar epidural space is formed by the lower margin of L1 vertebra to the upper margin of S1 vertebra. The sacral epidural space is formed by the upper margin of S1 to sacrococcygeal membrane.

3.4 Boundaries of the epidural space

The epidural space is bounded superiorly by the fusion of the spinal and periosteal layers of the dura mater at the foramen magnum. Inferiorly, it is bound by the sacrococcygeal membrane. The space is bounded anteriorly by the posterior longitudinal ligament, vertebral bodies and discs while the pedicles and intervertebral foraminae form the lateral boundary. The ligamentum flavum, capsule of facet joints and the laminae form the posterior boundary of the epidural space.

3.5 Pressure of the epidural space

The epidural space with the exception of the sacral region is said to be under negative pressure. The significance of the negative pressure has been a point of considerable argument. It has been hypothesized that the initial or 'true' negative pressure encountered when a needle first enters the epidural space could be due to initial bulging of the ligamentum flavum in front of the advancing needle followed by its rapid return to the resting position once the needle has perforated the ligament. The bulging has been confirmed to occur in fresh cadavers, and pressure studies carried out during performance of epidural blocks in patients lend weight to this hypothesis (Zarzur E, 1984).

Negative pressure can be magnified by increasing and reduced by decreasing the flexion of the spine. The negative pressure appears to be positive when the vertebral column is straightened. Depending on the position of the needle, two different components of negative pressure have been recognized. A basal value ranging from -1 to -7 cmH₂O could be observed when entering the epidural space. It remains stable providing the patient is well relaxed. An artefactual component up to -30 cmH₂O could appear if needle is further advanced against the dural sac (Usubiaja et al., 1967).

The epidural space identification is frequently dependent on the negative pressure within this space. It has been demonstrated that the epidural pressure is more negative in the sitting position than in the lateral decubitus position especially in the thoracic region. It therefore suggests that the space is better identified in the sitting position when the hanging drop technique is used to identify the epidural space (Gil et al., 2008).

3.6 The contents of the epidural space

This space contains semi-liquid fat, lymphatics, arteries, loose areolar connective tissue, the spinal nerve roots, and extensive plexus of veins. The epidural contents are contained in a series of circumferentially discontinuous compartments separated by zones where the dura contacts the wall of the vertebral canal (Hogan, 1998).

3.6.1 Fat

The distribution of the epidural fat has been studied. It is now known that the epidural space contains abundant epidural fat that distributes along the spinal canal in a predictable pattern (Reina et al., 2006). Fat cells are also abundant in the dura that forms the sleeves around spinal nerve roots but they are not embedded within the laminae that form the dura mater of the dural sac. The fat in the epidural space buffers the pulsatile movements of the dural sac and protects nerve structure, creates a reservoir of lipophilic substances, and facilitates the movement of the dural sac over the periosteum of the spinal column during flexion and extension. The epidural fat has a continuous pattern of distribution that assumes a metameric pattern especially in the adult human (Reina et al., 2006). Drugs stored in fat, inside dural sleeves, could have a greater impact on nerve roots than drugs stored in epidural fat, given that the concentration of fat is proportionally higher inside nerve root sleeves than in the epidural space, and that the distance between nerves and fat is shorter.

Similarly, changes in fat content and distribution caused by different pathologies may alter the absorption and distribution of drugs injected in the epidural space (Reina et al., 2009).

The fat is largely distributed along the dorsal margin of the space, where it assumes triangular capsular shapes and linked to the midline of the ligamentum flavum by a vascular pedicle. The clinical significance of the fat distribution is related to the pharmacokinetics of drugs including local anesthetics injected into the space leaving a minute quantity of the agent to react with the nerve roots, and the slight resistance experienced during the insertion of an epidural catheter.

3.6.2 Lymphatics

The lymphatics of the epidural space are concentrated in the region of the dural roots where they remove foreign materials including microorganisms from the subarachnoid and epidural spaces.

3.6.3 Vertebral venous plexus

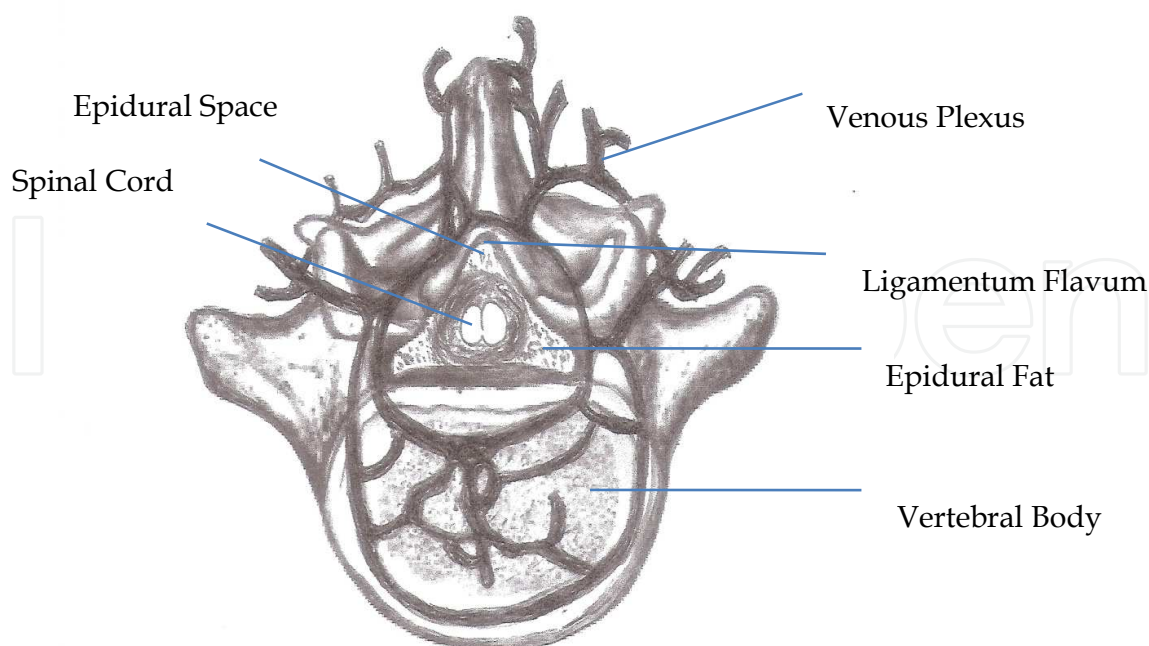
The internal vertebral venous plexus has been extensively studied and found to be located in the epidural space (Domisse, 1975; Parkin and Harrison, 1985; Brockstein et al., 1994). This plexus of veins is thought to be frequently involved in a bloody or traumatic tap (Mehl, 1986) during needle placement in the epidural space. The internal vertebral venous plexus consists of four interconnecting longitudinal vessels, two anterior and two posterior. The external vertebral plexus (EVP) in contrast, lies peripheral to the vertebrae and is made of the anterior and posterior external vertebral plexuses (Williams et al., 1989). The EVP is situated anterior to the vertebral bodies and in relation to the laminae, spinous processes, transverse processes and articular processes respectively.

These veins communicate with the segmental veins of the neck, the intercostal, azygos and lumbar veins. With the veins of bones of the vertebral column, the internal and external vertebral plexuses form Batson's plexus (Domisse, 1975). These veins are predominantly in the antero-lateral part of the epidural space, and ultimately drain into the azygous system of veins. As the whole system is valveless, increased intrathoracic or intra-abdominal pressure (e.g. ascites, pregnancy) can lead to major congestion and vessel enlargement within the spinal canal. The epidural venous plexus is surrounded by sparse quantity of fat.

The anterior epidural space is entirely occupied by a rich venous plexus (valveless system of veins). The plexus communicates with the intracranial sigmoid, basilar venous sinuses, basivertebral vein, occipital vein, and the azygous system. The plexus is linked to the abdominal and thoracic veins by the intervertebral foramina and through this connection transmit intraabdominal and intrathoracic pressure to the epidural space. The rich venous plexus is also connected to the iliac veins through the sacral venous plexus. Obstruction of the inferior vena cava, advanced pregnancy or intraabdominal tumors can cause distension of the venous plexus leading to an increased risk of being traumatized during needle and/or catheter placement in the epidural space.

3.6.4 Epidural arteries

The epidural arteries located in the lumbar region of the vertebral column are branches of the ilio-lumbar arteries. These arteries are found in the lateral region of the space and therefore not threatened by an advancing epidural needle.



Transverse Section of Lumbar Region at L1

4. Identification of the epidural space

Identification of the epidural space is of crucial importance as it is technically demanding. The first demonstration of this space was about 78 years ago (Dogliotti, 1933). The accuracy in the location of the space however, determines the functionality of the epidural analgesia. The epidural needle, if inserted in the midline, pierces the skin and traverses the subcutaneous tissue, supraspinous ligament, interspinous ligament and through the ligamentum flavum to reach the space. The depth of the epidural space has been defined as the distance from overlying skin to the tip of the needle just penetrating into the epidural space (Lai et al., 2005). The depth can pose some difficulties during the location of the epidural space particularly in the obese patient.

To improve the success rate, the distance from skin to the epidural space and its correlation with body mass index (BMI) have been studied (Ravi et al., 2011). This study showed that as the BMI increased, the depth of the epidural space increased significant. The study was based on a predictive equation of depth of epidural space from skin in relation to BMI based on linear regression analysis as: $\text{Depth (mm)} = a + b (\text{BMI})$. Where $a = 17.7966$ and $b = 0.9777$.

4.1 Methods of identification

Various methods have been used in identifying the epidural space. Most of these traditional methods of locating the epidural space depend on the negative pressure exhibited during the introduction of the epidural needle into the space. Any techniques identifying the epidural space should be simple and straightforward, effective, safe, and reliable to minimize the number of complications associated with it.

One of the most reliable methods in identifying the space depends on loss of resistance (LOR). This method of identification uses either air or a liquid such as saline or a local anesthetic to achieve it. The technique applies continuous or intermittent pressure on the piston of an epidural glass or plastic syringe towards the barrel, and the loss of resistance is where it becomes possible to inject through the syringe attached to the epidural needle, so the piston can easily move into the barrel. This technique works because the ligamentum flavum is extremely dense, and injection into it is almost impossible. The syringe may contain air or saline. The principles are the same, but the specifics of the technique are different due to the greater compressibility of air with respect to saline or lidocaine.

The identification of the epidural space with LOR to air has been found to be more difficult and caused more dural punctures than with lidocaine or air plus lidocaine techniques. Additionally, sequential use of air and lidocaine had no advantage over lidocaine alone (Evron et al., 2004). The techniques of LOR to air or saline are also associated with some complications. While LOR to air has been linked to paraplegia (Nay et al., 1993), pneumocephalus (Nafiu & Bullough, 2007), LOR to saline is frequently associated with dilution of the injected local anesthetic (Okutomi & Hoka, 1998).

The epidural space has also been identified using a modified drip method (Michel & Lawes, 1991). In this study, a saline infusion was prepared, leaving the distal 40 cm of infusion tubing full of air, and then attached to the hub of a Tuohy needle. Accurate identification of the epidural space was accomplished in less than one minute in 95% of cases. This technique showed some advantages over the hanging drop and the manual loss of resistance techniques.

A technique described as “Membrane in Syringe” has been described (Lin et al., 2002). This is a modification of the loss of resistance technique for identifying the epidural space during epidural anesthesia. A plastic membrane is placed halfway inside a syringe dividing the syringe into two compartments. The saline compartment encompasses the nozzle of the syringe (the distal compartment). The plunger is installed in the opposite half of the hollow cylinder. Air is trapped in the space between the membrane and the rubber plunger (air compartment). Lin et al described this technique as having a two-fold advantage. Firstly when the syringe is filled with both normal saline and air, it can prevent injection of the air into the epidural space during identification while at the same time it does not molest the feel of compressibility. Secondly, with the membrane separating the normal saline and air, correct placement of the needle tip can also be ascertained with loss of resistance while, as will be seen, the plastic membrane will wrinkle when saline is released into the epidural space.

A clinical experience with Macintosh epidural balloon in identifying the epidural space has also been described (Fyreface-Ogan & Mato, 2008). The study compared the identification characteristics between the use of LOR to air and the epidural balloon. It showed that epidural space was identified more often at the first attempt, and more swiftly, with the epidural balloon than the LOR to air (having a greater propensity for accidental dural puncture). Though cost implication of the use of epidural balloon is more than the LOR to air, it obviously offered better advantage over the traditional use of air.

The use of Epidrum®, an optimal pressure, loss of resistance device has been described for the identification of the epidural space (Samada et al., 2011). This device is designed to operate at a high enough pressure to discharge into the epidural space but a low enough

pressure to minimise premature leaking into the patients' tissues. The optimal pressure is generated by the extremely thin diaphragm on top of the device that acts as the meniscus of a manometer, so allowing the operator to interpret the diaphragm's signal to identify the position of the tip of the needle. Epidrum has been known to offer the following benefits:

- Relatively simple (offering shorter training periods). The trainer can monitor the signal when the trainee is performing the procedure
- It is safe, effective and reliable
- It allows the use of a smaller needle to: reduce post dural puncture headache and reduce epidural haematoma formation
- It offers a visual endpoint
- Optimised, low, constant pressure - minimizes false positive error
- Easily observed cerebral spinal fluid (CSF) in the event of a dural tap

Samada et al showed that Tuohy needle control was significantly easier in the Epidrum group than in the control group and concluded that Epidrum is very useful in performing epidural space identification quickly while obtaining good Tuohy needle control.

The Episure syringe® has been described as a useful tool in the identification of the epidural space (Riley & Carvalho, 2007). This is a unique spring-loaded loss-of-resistance (LOR) syringe with a coaxial compression spring within a Portex Pulsator® LOR syringe. This syringe supplies a constant pressure while the operator is advancing the Tuohy needle.

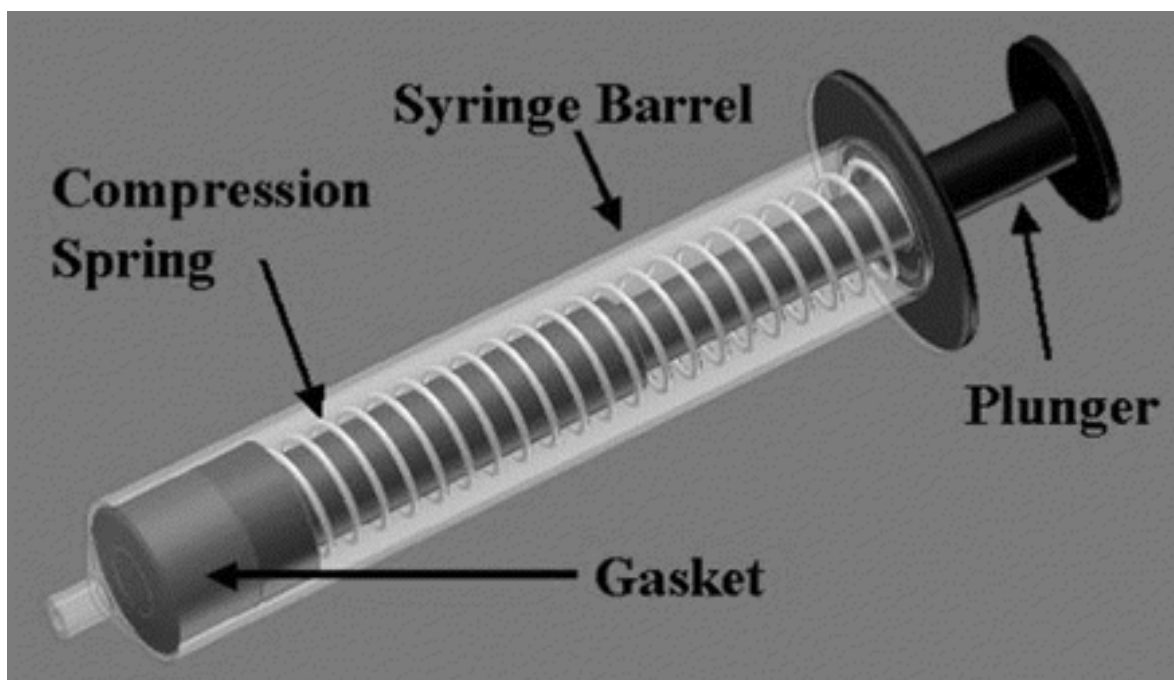
One application for this syringe may be to facilitate teaching of the epidural technique to clinicians. Both the student and the teacher will get an objective, visual signal when the needle tip enters the epidural space. The spring-loaded syringe may assist attending physicians in more closely supervising residents doing an essentially “blind,” subjective procedure. While it has been extensively recommended as a useful tool in epidural space identification (Riley & Carvalho, 2007), another group of workers (Habib et al., 2008) showed that the episure syringe did not appear to have major disadvantages over the standard glass syringe amongst parturients.

One study (Rodiera et al., 1995) demonstrated the use of a mathematical analysis in identifying the epidural space. In this study pressure variations within an injection system during the epidural puncture were measured and pressure curves analyzed for amplitude and rate of decay after entry of the needle into the epidural space. The study showed that pressure changes were observed as the epidural needle traversed the skin, subcutaneous fat and muscle. The change in pressure observed when the needle entered the epidural space fitted a negative exponential function. In the study, Rodiera et al concluded that pressures within the injection system for epidural puncture can rise as high as 1100 cmH₂O. The location of the space is characterized by an exponential decay to an end-residual pressure below 50 cm H₂O.

Another method of objective identification of the epidural space for correct needle placement has been suggested (Ghelber et al., 2008). This study evaluated continuous pressure measurement during low speed injection with a computerized injection pump to locate the epidural space.

Neuraxial ultrasonography is a recent development in regional anesthesia practice particularly in epidural space identification (Perlas, 2010). Most clinical studies and data however, emanate from very few centres with highly skilled operators. It is a useful adjunct

to physical examination, allowing for a highly precise identification of regional landmarks and a precise estimation of epidural space depth, thus facilitating epidural catheter insertion.



The Episire Syringe

One of such ultrasonographic studies has been shown to facilitate accurate identification of the intervertebral level and to predict skin-to-epidural depth in the lumbar epidural space with reliable precision (Rasoulia et al., 2011). A pre-puncture ultrasound for localization of the thoracic epidural space measuring the skin-to-epidural depth has been shown to correlate with the actual depth observed during epidural catheterization (Rasoulia et al., 2011). This study showed that the limits of agreement are wide, which restricts the predictive value of ultrasound-based measurements.

The use of imaging techniques has also involved the application of Magnetic Resonance Imaging (MRI) in the epidural space identification. One study has shown that the use of ultrasound showed good correlation with MRI, which is a standard imaging technique for the depiction of the spine (Grau et al., 2011). Generally, the epidural space is variable in size along its length. The space between the C7 and T1 is relatively consistent and prominent in size. A sagittal MRI with T1 sequencing is frequently known by bright signal displayed by the epidural fat in the space.

5. Clinical importance of the epidural space

The epidural space has been subjected to many clinical manipulations for purposes of anesthesia and analgesia. Injection into this space can be by a single shot, intermittent, continuous or under the control of the patient (Patient controlled epidural analgesia (PCEA)). Intermittent or continuous injections into the space are carried out through an epidural catheter. The epidural space is catheterized in a wide range of clinical reasons.

5.1 Epidural space steroid injection

Epidural injection of corticosteroids is one of the most commonly used interventions in managing radicular pain caused by nerve irritation (Mulligan & Rowlingson, 2001). Steroids placed in the epidural space have a very potent anti-inflammatory action that can decrease pain and allow patients to improve function. Although steroids do not change the underlying condition, they can break the cycle of pain and inflammation and, allow the body to compensate for the condition.

5.2 Labor and postoperative pain management

The administration of local anesthetics with or without opioids into the epidural space provides and maintains pain relief during labor, abdominal surgery, pelvis or lower limb. It is also used for pain management in conditions associated with chronic pain (including back pain, and palliation for intractable pain of neoplastic origin). It has also been found useful in the extension of regional anesthesia/analgesia during prolonged intraoperative period.

6. Conclusion

A good knowledge of the anatomy of the epidural space is imperative in the exploration of this space. The identification of this space demands some skill due to its complexity. Inadequate knowledge of the anatomy of the space and lack of skill to identify it can expose the patient to avoidable hazards such as accidental dural puncture. The dural puncture in turn leads to intractable headache following cerebrospinal fluid leakage and traction on the meninges.

The space has been manipulated in several ways for the purposes of anesthesia, analgesia and drug treatment such as steroid injection. The space, when catheterized, has been used to prolong pain relief and regional anesthesia intraoperatively. Its importance in postoperative pain management cannot be under-emphasized.

7. Conflict of interest

None.

8. Acknowledgement

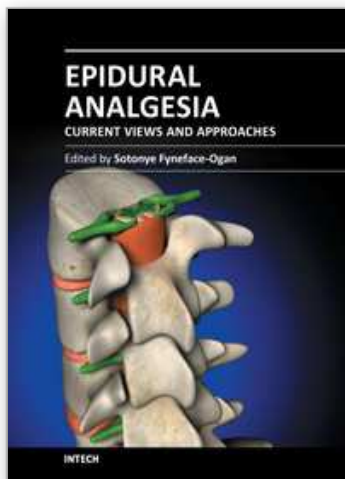
I thank Mrs. Gloria Sotonye-Ogan for the excellent secretarial work in preparing this manuscript.

9. References

- Blomberg RG & Olsson SS. (1989). The lumbar epidural space in patients examined with epiduroscopy. *Anesthesia & Analgesia*, Vol. 68, pp. (157-160)
- Brockstein B, Johns L & Gewertz BL. (1994). Blood supply to the spinal cord: anatomic and physiologic correlations. *Ann Vasc Surg*, Vol. 8, pp. (394 -399)
- Bromage, PR. (1978). Epidural analgesia. Philadelphia: WB Saunders, pp. 191-196.
- Corning, JL. (1885). Spinal anesthesia and local medication of the cord. *N Y Med J*, Vol. 42, p. (483)

- Danelli G, Ghisi D, Bellinghieri F, Borghi B, Fanelli G & Chelly JE. (2011). The nerve stimulation technique versus the loss of resistance technique for the posterior approach to lumbar plexus block: a randomized, prospective, observer-blinded, pilot study. *Minerva Anestesiologica*, Vol. 77, pp. (959-963)
- Dogliotti AM. (1933). Research and clinical observations on spinal anaesthesia: with special reference to the peridural technique. *Anesthesia & Analgesia*, Vol. 12, pp. (59-65)
- Domisse GF. (1975). The arteries and veins of the human spinal cord from birth. Edinburgh: Churchill Livingstone. pp. (81-96)
- Evron S, Sessler D, Sadan O, Boaz M, Glezerman M & Ezri T. (2004). Identification of the Epidural Space: Loss of Resistance with Air, Lidocaine, or the Combination of Air and Lidocaine. *Anesthesia & Analgesia*, Vol. 99, pp. (245-250)
- Fyneface-Ogan S & Mato CN. (2008). A clinical experience with epidural balloon in the localization of the epidural space in laboring parturients. *Nig Q J Hosp Med*, Vol. 18, pp. (166-169)
- Ghelber O, Gebhard RE, Vora S, Hagberg CA & Szmuk P. (2008). Identification of the epidural space using pressure measurement with the compuflo injection pump - a pilot study. *Reg Anesth Pain Med*, Vol. 33, pp. (346-352)
- Gil NS, Lee JH, Yoon SZ, Jeon Y, Lim YJ & Bahk JH. (2008). Comparison of thoracic epidural pressure in the sitting and lateral decubitus positions. *Anesthesiology*, Vol. 109, pp. (67-71).
- Grau T, Leipold RW, Delorme S, Martin E & Motsch J. (2002). Ultrasound imaging of the thoracic epidural space. *Reg Anesth Pain Med*, Vol. 27, pp. (200-206)
- Habib AS, George RB, Allen TK & Olufolabi AJ. (2008). Pilot Study to Compare the Episure® Autodetect® Syringe with the Glass Syringe for Identification of the Epidural Space in Parturients. *Anesthesia & Analgesia*, Vol. 106, pp. (541-543)
- Hamid M, Fallet-Bianco C, Delmas V & Plaisant O. (2002). The human lumbar anterior epidural space: morphological comparison in adult and fetal specimens. *Surg Radiol Anat* Vol. 24, pp. (194-200)
- Hogan, QH. (1991). Lumbar epidural anatomy: a new look by cryomicrotome section. *Anesthesiology*, Vol. 75, pp. (767-775)
- Hogan QH. (1998). Epidural anatomy: new observations. *Can J Anaesth*, Vol. 45, pp. (40-48)
- Husemeyer RP & White DC. (1980). Topography of the lumbar epidural space. A study in cadavers using injected polyester resin. *Anaesthesia*, Vol 35, pp. (7-11)
- Lai HC, Liu TJ, Peng SK, Lee KC, Luk HN & Lee SC. (2005). Depth of the thoracic epidural space in paramedian approach. *J Clin Anaesth*, Vol. 17, pp. (339-343)
- Lin BC, Chen KB, Chang CS, Wu KC, Liu YC, Chen CC & Wu RS. (2002). A 'membrane in syringe' technique that allows identification of the epidural space with saline while avoids injection of air into the epidural space. *Acta Anaesthesiol Sin*, Vol. 40, pp. (55-60)
- Mackintosh, RR.; & Lee, JA. (1973). Lumbar puncture and spinal analgesia, Churchill Livingstone. 3rd ed. ISBN 0-443-00997-X
- Mehl AL. (1986). Interpretation of traumatic lumbar puncture. *Clin Pediatr* Vol. 25, pp. (523-526)
- Michel MZ & Lawes EG. (1991). Identification of epidural space by drip method. *Reg Anesth*, Vol. 16, pp. (236-239)
- Mulligan KA & Rowlingson JC. (2001). Epidural steroids. *Curr Pain Headache Rep*, Vol. 5, pp. (495-502)

- Nafiu OO & Bullough AS. (2007). Pneumocephalus and Headache After Epidural Analgesia: Should We Really Still Be Using Air? *Anesthesia & Analgesia*, Vol. 105, pp. (1172-1173)
- Nay PG, Milaszkiewicz R & Jothilingam S. (1993). Extradural air as a cause of paraplegia following lumbar analgesia. *Anaesthesia*, Vol. 48, pp. (402- 404)
- Nickallis RWD & Kokri MS. (1986). The width of posterior epidural space in obstetric patients. *Anaesthesia*, Vol. 41 pp. (432-433)
- Okutomi T & Hoka S. (1998). Epidural saline solution prior to local anaesthetic produces differential nerve block. *Can J Anaesth* Vol. 45, pp. (1091-1093)
- Parkin IG & Harrison GR. (1985). The topographical anatomy of the lumbar epidural space. *Journal of Anatomy*, Vol. 141, pp. (211-217)
- Perlas A. (2010). Evidence for the use of ultrasound in neuraxial blocks. *Reg Anesth Pain Med*, Vol. 35, pp. (S43-46)
- Rasoulilian A, Lohser J, Najafi M, Rafii-Tari H, Tran D, Kamani AA, Lessoway VA, Abolmaesumi P & Rohling RN. (2011). Utility of prepuncture ultrasound for localization of the thoracic epidural space. *Can J Anaesth*, Vol. 58, pp. (815-823)
- Ravi KK, Kaul TK, Kathuria S, Gupta S & Khurana S. (2011). Distance from skin to epidural space: Correlation with body mass index (BMI). *J Anaesthesiol Clin Pharm*, Vol. 27, pp. (39-42)
- Reina MA, Franco CD, Lopez A, De Andres JA & van Zundert A. (2009). Clinical implications of epidural fat in the spinal canal. A scanning electron microscopic study. *Acta Anesthesiol Belg*, Vol. 60, pp. (7-17)
- Reina MA, Pulido P, Castedo J, Villanueva MC, López A & Sola RG. (2006). Characteristics and distribution of normal human epidural fat. *Rev Esp Anestesiología y Reanimación*, Vol. 53, pp. (363-372)
- Riley ET & Carvalho B. (2007). The Episure™ Syringe: A Novel Loss of Resistance Syringe for Locating the Epidural Space. *Anesthesia & Analgesia*, Vol. 105, pp. (1164-1166)
- Rodiera J, Calabuig R, Aliaga L, Espinosa W, Hobeich F, Oferil F & Gual A. (1995). Mathematical analysis of epidural space location. *International Journal of Clinical Monitoring and Computing*, Vol. 12, pp. (213-217)
- Sawada A, Kii N, Yoshikawa Y & Yamakage M. (2011). Epidrum®: a new device to identify the epidural space with an epidural Tuohy needle. *J Anesth* Nov 13.
- Usubiaga, JE.; Moya, F & Usubiaga, LE. (1967). A note on the recording of epidural negative pressure. *Canadian Anaesthesia Society Journal*, Vol. 14, pp. (119-122)
- Williams PL, Warwick R, Dyson M & Bannister LH. (1989). Gray's anatomy. 37th Ed. Edinburgh: Churchill Livingstone. pp. (1123-1143)
- Yan L, Li J, Zhao W, Cui Z, Wang H & Xin L. (2010). The study of epidurography and multispinal CT scanning examinations in the diagnosis of lumbar nerve root canal stenosis. *Orthopedics*, Vol. 33, pp. (732). doi: 10.3928/01477447-20100826-05.
- Zarzur, E. (1984). Genesis of the 'true' negative pressure in the lumbar epidural space: a new hypothesis. *Anaesthesia*, Vol. 39, pp. (1101-1104)



Epidural Analgesia - Current Views and Approaches

Edited by Dr. Sotonye Fyनेface-Ogan

ISBN 978-953-51-0332-5

Hard cover, 174 pages

Publisher InTech

Published online 16, March, 2012

Published in print edition March, 2012

Epidural analgesia is a form of pain relief administered through the space surrounding the dural sheath either by direct injection or via catheter. The agent, when administered, can cause both a loss of sensation (anesthesia) and a loss of pain (analgesia), by reversibly interrupting the transmission of signals through nerves in or near the spinal cord. This form of pain relief has been found useful in many clinical situations. This book intends to provide an in-depth review of the current knowledge on epidural analgesia. The use of this form of analgesia is explored by contributors from different perspectives, including labor and delivery, postoperative analgesia in both pediatric and geriatric patients, and its role during anesthesia and surgery. In order to provide a balanced medical view this book was edited by an obstetric anesthesiologist.

How to reference

In order to correctly reference this scholarly work, feel free to copy and paste the following:

Sotonye Fyनेface-Ogan (2012). Anatomy and Clinical Importance of the Epidural Space, Epidural Analgesia - Current Views and Approaches, Dr. Sotonye Fyनेface-Ogan (Ed.), ISBN: 978-953-51-0332-5, InTech, Available from: <http://www.intechopen.com/books/epidural-analgesia-current-views-and-approaches/anatomy-and-clinical-importance-of-the-epidural-space>

INTech
open science | open minds

InTech Europe

University Campus STeP Ri
Slavka Krautzeka 83/A
51000 Rijeka, Croatia
Phone: +385 (51) 770 447
Fax: +385 (51) 686 166
www.intechopen.com

InTech China

Unit 405, Office Block, Hotel Equatorial Shanghai
No.65, Yan An Road (West), Shanghai, 200040, China
中国上海市延安西路65号上海国际贵都大饭店办公楼405单元
Phone: +86-21-62489820
Fax: +86-21-62489821

© 2012 The Author(s). Licensee IntechOpen. This is an open access article distributed under the terms of the [Creative Commons Attribution 3.0 License](https://creativecommons.org/licenses/by/3.0/), which permits unrestricted use, distribution, and reproduction in any medium, provided the original work is properly cited.

IntechOpen

IntechOpen