

# We are IntechOpen, the world's leading publisher of Open Access books Built by scientists, for scientists

6,900

Open access books available

186,000

International authors and editors

200M

Downloads

Our authors are among the

154

Countries delivered to

TOP 1%

most cited scientists

12.2%

Contributors from top 500 universities



WEB OF SCIENCE™

Selection of our books indexed in the Book Citation Index  
in Web of Science™ Core Collection (BKCI)

Interested in publishing with us?  
Contact [book.department@intechopen.com](mailto:book.department@intechopen.com)

Numbers displayed above are based on latest data collected.  
For more information visit [www.intechopen.com](http://www.intechopen.com)



## Clinical Application of CO<sub>2</sub> Laser

Hyeong-Seok Oh and Jin-Sung Kim  
*Wooridul Spine Hospital, Seoul  
 Korea*

### 1. Introduction

The carbon dioxide (CO<sub>2</sub>) laser was first introduced in 1964 by Patel and has been extensively used in the next two decades as an incision tool in increasingly wide areas, such as neurosurgery, dermatology and plastic surgery, otorhinolaryngology, ophthalmology, gynecology, and general surgery. In 1984, its reliability resulted in its approval by the U.S. Food and Drug Administration, and thus, medical use of lasers became more prevalent. Currently, the CO<sub>2</sub> laser is considered an indispensable piece of diagnostic and therapeutic equipment.

The CO<sub>2</sub> laser produces a beam of infrared light with the principal wavelength bands centering at 10,600 nanometers. Collisional energy transfer between the nitrogen and the carbon dioxide molecule causes vibrational excitation of the carbon dioxide, with sufficient efficiency to lead to the desired population inversion necessary for laser operation. It is easy to actively Q-switch a CO<sub>2</sub> laser by means of a rotating mirror or an electro-optic switch, giving rise to Q-switched peak powers up to gigawatts (GW) of peak power.

CO<sub>2</sub> lasers are attracting attention as cutting tools. They are able to seal lymphatic and blood vessels less than 0.5-mm wide and can reduce intraoperative bleeding and the occurrence of postoperative swelling. CO<sub>2</sub> lasers emit a longer wavelength than those transmitted by other types of lasers. Their penetration depth of 0.03 mm is very safe. Coagulation in small blood vessels, as well as sealing of lymphatic and small peripheral nerves, have been reported in experimental studies using CO<sub>2</sub> lasers; this sealing alleviates postoperative pain.

The CO<sub>2</sub> laser also offers more comfort to patients by reducing intraoperative bleeding and postoperative edema, facilitating the process of wound healing after surgery. The boundaries between the tissues receiving heat damage and the surrounding intact tissue are very well defined. A CO<sub>2</sub> laser can evaporate through the surrounding tissue without physical force, sealing the vessel and minimizing bleeding; thus, it is useful when a bloodless view is required during surgery. Moreover, wounds can be treated in a sterile manner because of high-temperature evaporation of tissue lesions.

Regarding its disadvantages, the equipment is expensive, operators require time to become familiar with it, and the sophisticated operation is technically difficult. Therefore, more repetitions are required to gain the necessary experience and practice. In addition, there is a risk of fire if the laser is used improperly. It can also damage the cornea; thus, eye protection is needed for the surgeon and the patient. Because the gas discharged from the vaporization of tissue contains an excess of CO<sub>2</sub> or virus particles, it can be harmful to the human body.

## 2. Clinical application in neurosurgery

The CO<sub>2</sub> laser is most widely used in the field of neurosurgery for removal and evaporation of tumors located in difficult surgical fields, such as the base of the skull, ventricles, brainstem, and spinal cord.

### 2.1 Brain tumor surgery

The CO<sub>2</sub> laser has been used in brain microsurgery after Steller et al. (Stellar, Polanyi et al. 1970) had first successfully used it in removing a recurrent glioma in 1969. The most ideal treatment of a brain tumor is minimizing damage to the normal brain tissue and removing only the tumor area. To overcome the surgical difficulty of avoiding damage to the brain tissue, a special instrument was developed. Theoretically, lasers have several advantages. First, although the surgical field is narrow, it makes surgery possible. Other small-sized surgical approaches are facilitated to minimize injury to normal brain tissue. Second, brain retraction is minimized, thus causing less damage to normal brain tissue. Third, laser beam minimizes injury to surrounding tissues and enables removal of a tumor with less thermal injury. Fourth, lasers have a coagulating property that lessens bleeding of the surgical field. Fifth, operation time is shortened (Tew and Tobler 1983; Krishnamurthy and Powers 1994).

The CO<sub>2</sub> laser is the main instrument used in brain surgery. It has the advantage of rapidly removing separated tumor cells and exact irradiation of target cells by a microsurgical technique where the CO<sub>2</sub> laser is installed with a microscope. However, as energy cannot pass through an optical fiber, it is inconvenient to use the equipment. It has limited function in bleeding control, as control of bleeding is not possible in a vessel with a diameter 0.5 mm, necessitating the use of the equipment in conjunction with other equipments for severe bleeding management (Heppner 1978; Ascher and Heppner 1984; Deruty, Pelissou-Guyotat et al. 1993).

The CO<sub>2</sub> laser is most widely used in the field of neurosurgery, and it is mainly used in the removal of tumors by evaporation where surgical approach of the tumor site is difficult. It is common opinion that the CO<sub>2</sub> laser is most effective with skull base, ventricular, brainstem, and spinal cord tumors (Powers, Cush et al. 1991; Origitano and Reichman 1993). In particular, it is most effective in removing a meningioma that is relatively hard or has less vascular distribution to be calcified. In addition, it is suitable for removing a low-grade glioma that is relatively rigid (Deruty, Pelissou-Guyotat et al. 1993).

The Nd:YAG laser has the advantage that energy can be passed to thinner fiberoptic cables and excellent clotting function is possible at a 3-mm vessel. Therefore, it has been reported as a valid technique of removing brain tumors having greater vascular distribution and cerebral vascular malformation (Beck 1980). The combolaser has been developed in recent years by Fasano et al. (Glasscock, Jackson et al. 1981) and has been applied in surgery. It is composed of CO<sub>2</sub> and Nd:YAG lasers, combining the advantages of both. It works by first emitting Nd:YAG energy to the tumor for clotting, followed by tumor removal by evaporation using the CO<sub>2</sub> laser (Beck 1980; Glasscock, Jackson et al. 1981).

### 2.2 Spine surgery

Since the first trial of Nd:YAG in a lumbar disk surgery in 1986 (Choy, Case et al. 1987), there have been many reports about the usefulness of different kinds of lasers in disk

surgery (Nerubay, Caspi et al. 1997; Hellinger 1999; Houck 2006). Nerubay et al. reported that 50 patients with low back and radicular pains were successfully treated by percutaneous laser nucleolysis using a CO<sub>2</sub> laser (Nerubay, Caspi et al. 1997), and successful vaporization of the disk was accomplished in animal models (Stein, Sedlacek et al. 1990).

Considering the similarity between the disk and the meniscus (Whipple, Caspari et al. 1984), we cite studies on the effect of the CO<sub>2</sub> laser on the meniscus. According to these research results, there was a considerable proliferation of cells resembling chondrocytes after 2 weeks of the CO<sub>2</sub> laser treatment and there was definitely an increase in the production of ground substance and immature collagen fibers after 4 weeks; the collagen had become well reorganized into a logical orientation, resembling the normal architecture of fibrocartilage, after 10 weeks (Benjamin, Qin et al. 1995).

These animal and clinical studies strongly support the claim that CO<sub>2</sub> lasers can safely and feasibly be used for the removal of protruded disks and discal cysts. Moreover, the CO<sub>2</sub> laser, when attached to an operating microscope, allows for quick and easy removal of the discal cyst and, if needed, easy vaporization of disk material.

### 2.2.1 Disk herniation

Laser removes disk material by vaporization (Stein, Sedlacek et al. 1990) and consequently lowers intradiskal pressure (Gropper, Robertson et al. 1984). In spine surgery, the use of a laser has advantages over scalpel use in terms of precision; the ability to be used on delicate tissues; minimal tissue manipulation; and less bleeding, swelling, and trauma (Jeon, Lee et al. 2007). It is especially useful in the small spaces involved in herniated disks (Kim, Choi et al. 2009). Therefore, a laser is an effective tool for performing a minimally invasive spinal surgery with percutaneous and open spinal procedures (Ahn, Lee et al. 2005; Lee, Ahn et al. 2006; Lee, Ahn et al. 2006; Jeon, Lee et al. 2007; Lee, Ahn et al. 2008; Kim, Choi et al. 2009; Kim and Lee 2009).

In the Wooridul Hospital, CO<sub>2</sub> laser-equipped surgical microscopes have been used for open lumbar microdiscectomy since December 1991 (Fig. 1). These microscopes coaxially align the invisible CO<sub>2</sub> laser beam with a visible helium-neon laser beam and can focus exactly on and evaporate the target disk material by the commonly used 20- to 30-W single-pulse mode laser. Therefore, we aimed to determine whether a CO<sub>2</sub> laser-equipped surgical microscope is a useful tool for microdiscectomy.

Lee et al. (Lee and Lee 2011) reported that the CO<sub>2</sub> laser-assisted microdiscectomy could be an effective alternative to conventional microdiscectomy techniques. Because the CO<sub>2</sub> laser enabled effective removal of extraforaminal lumbar disk herniation (EFLDH) via a narrow extraforaminal operative corridor without excessive loss of the facet joint and/or the par interarticularis, a thorough decompression of the extraforaminal and/or the foraminal zone was achieved while preserving spinal stability (Fig. 2). Thirty-one patients exhibited a marked reduction in leg pain immediately after the surgery. No patient complained of persistent severe leg pain in the perioperative period. In the present study, reherniation occurred in 1 patient (3.6%) at the 1-year follow-up. The CO<sub>2</sub> laser is also believed to decrease reherniation after discectomy owing to laser-induced metaplasia. (Kim, Choi et al. 2009)

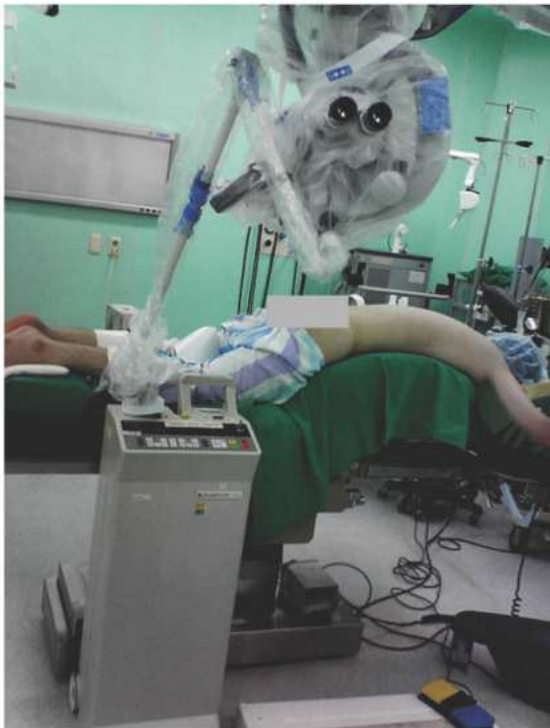

Fig. 1. Photograph of a CO<sub>2</sub> laser-equipped surgical microscope.

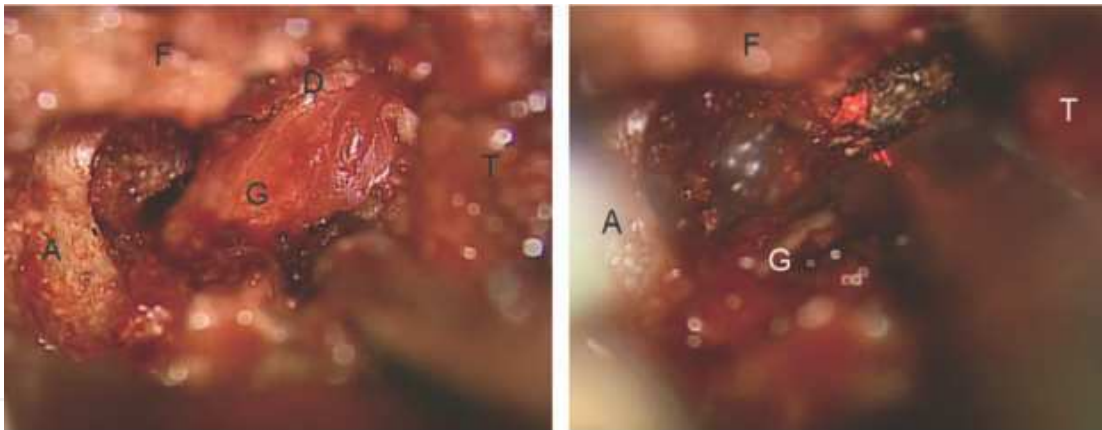


Fig. 2. Intraoperative photomicrographs depicting CO<sub>2</sub> laser-assisted microdissection for EFLDH at the L5/S1 level. Left. Photomicrograph taken after exposure of the L5 dorsal root ganglion (A:upper border of the sacral ala; D:herniated disc; F: the lateral L5-S1 facet joint, G:the L5 dorsal root ganglion; and T:the lower border of the L5 transverse process). Right: EFLDH being removed by CO<sub>2</sub> laser with gentle retraction of L5 dorsal root ganglion. Note the red He-Ne beam in the surgical field.

**2.2.2 Recurrent disk herniation**

There are various surgical treatments for recurrent lumbar disk herniation (rLDH), including revision microdisectomy, lumbar fusion with or without instrumentation (Choi, Lee et al. 2008), and recently, some minimally invasive methods, such as percutaneous endoscopic lumbar discectomy (PELD) (Ahn, Lee et al. 2004), have also been developed. They noted that favorable pain relief was achieved in most patients through this procedure.



Owing to the steep learning curve of PELD (Lee and Lee 2008), the modified microdiscectomy is still more popularity.

In the study by Kims et al (Kim 2010), 21 cases of rLDH, which caused the same symptoms and signs as those of virgin lumbar disk herniations, were excised successfully with modified microdiscectomy using a CO<sub>2</sub> laser.

The author used CO<sub>2</sub> laser during modified lumbar microdiscectomy and reported that using the technique, surgeons can focus the laser beam exactly on the target adhesion scar for adhesiolysis and vaporization and then quickly and easily dissect the adhesion scar tissue. In his results, no approach-related or CO<sub>2</sub> laser-related complications developed. In our opinion, the reason that no incidental durotomy occurred in our series is the precise and gentle dissection using the CO<sub>2</sub> laser (Fig. 3 A,B).

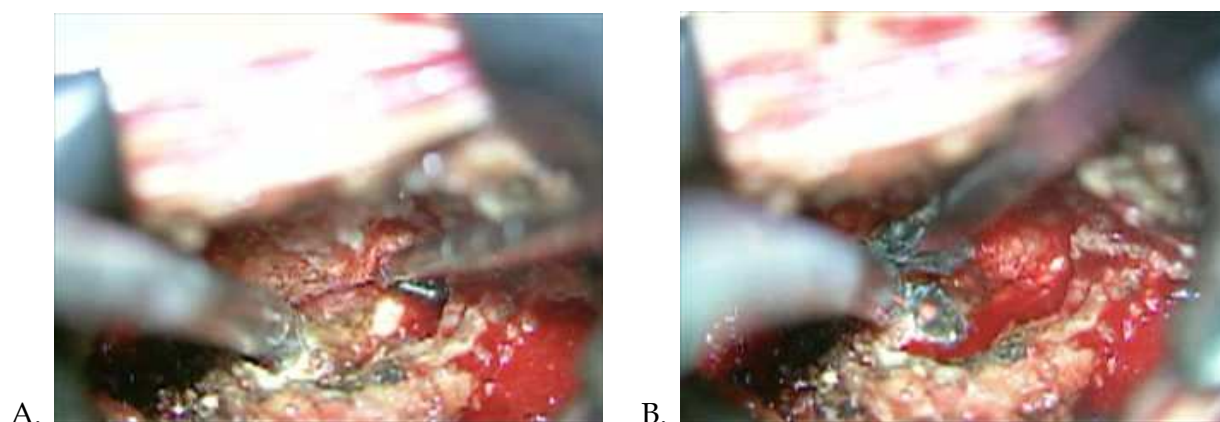


Fig. 3. A. Operative view showing granulation tissue and recurrent lumbar disc herniation located ventromedially to the L5 nerve root (black asterisk) B. The small tip of the CO<sub>2</sub> laser could be seen on the protruded disc (black arrow).

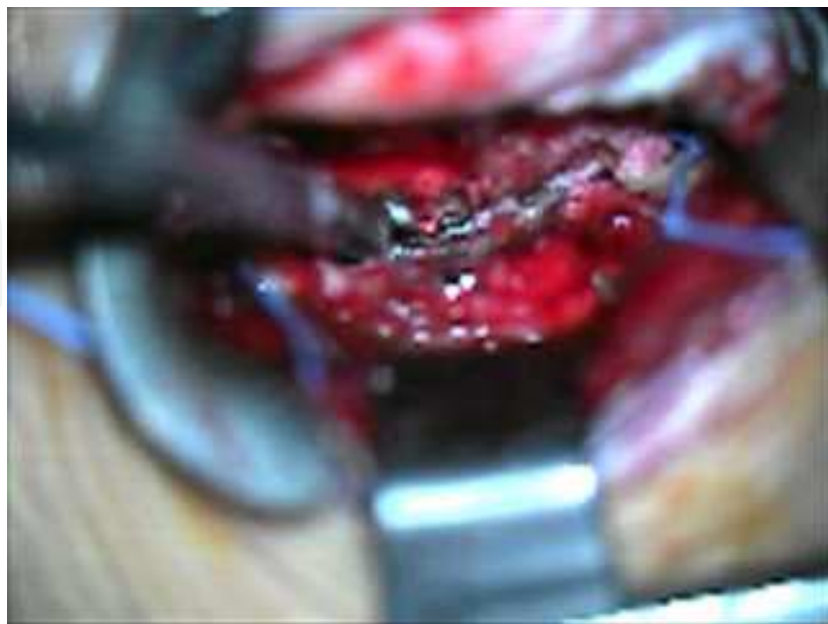

Fig. 4. Operative view presenting easily access narrow ventral part of nerve root using CO<sub>2</sub> laser where blunt scalpel couldn't access, with a slight gentle retraction of nerve root

Because an epidural or perineural scar tissue may hinder the dissection using the modified microdiscectomy, increasing the risk of incidental durotomy or iatrogenic neural injury, the CO<sub>2</sub> laser can help surgeons make more precise and safe dissections of the scar tissue than when using a blunt scalpel. Calcifications around recurrent disk fragments are often seen, which may also hinder surgeons to dissect safely. However, with the aid of the CO<sub>2</sub> laser, surgeons can evaporate the calcified portion of the disk without excessive retraction of the nerve root via a narrow operative corridor (Lee, Ahn et al. 2008). Moreover, with a slight gentle retraction of the nerve root, surgeons can easily access the narrow ventral part of the nerve root using the CO<sub>2</sub> laser, where a blunt scalpel could not (Fig. 4).

### 2.2.3 Discal cyst

Many kinds of surgical methods have been introduced for the treatment of discal cysts. Most discal cysts reported have been treated by open surgical excision (Chiba, Toyama et al. 2001; Lee, Lee et al. 2006) or with some direct intervention, such as computed tomography-guided aspiration and steroid injection (Kang, Liu et al. 2008). Recently, it was reported that a discal cyst was treated with a minimally invasive technique using PELD (Min 2006).

Kim et al. (Kim and Lee 2009) reported that the CO<sub>2</sub> laser, when attached to an operating microscope, allows for quick and easy removal of a discal cyst and, if needed, easy vaporization of disk material. In his study, 14 cases of discal cyst that caused the same symptoms and signs as those of lumbar disk herniations were excised successfully by open surgery using a CO<sub>2</sub> laser.

After the intraoperative removal of the discal cyst, the authors found the communication hole between the cyst and the protruded disk. They then used the heat energy produced by CO<sub>2</sub> lasering and removed the pulled-out disk fragment, if any existed, after pushing into the disk space with a right-angled probe (Fig. 5 A.B).

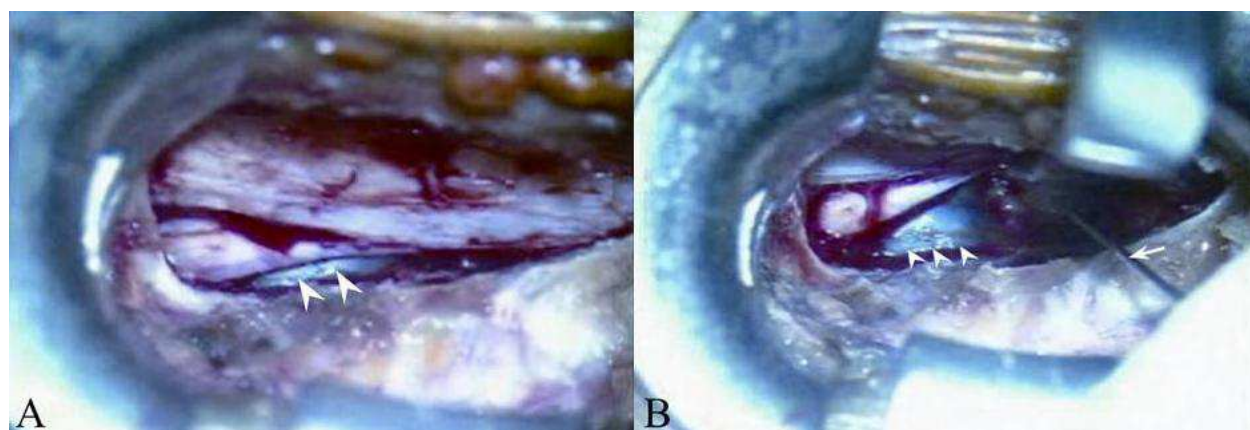


Fig. 5. (A) Distinct communication-like hole between the cyst and intervertebral disc (white arrow) and (B) small tip of laser on the protruded disc (white arrow)

### 2.2.4 Cervical ossification of ligamentum flavum (OPLL)

The choice of a surgical approach for multi-level cervical OPLL is still a controversial issue.

Direct anterior decompression by corpectomy followed by fusion should be the proper choice of surgical treatment of this multi-level OPLL than indirect decompression by posterior laminoplasty.

The rationale of preferring the anterior approach is based on evidence that the compressive elements are located anterior to the spinal cord in 75% of cases, and therapeutic benefit can be obtained by directly approaching these lesions(Cusick 1991). The degree of cervical myelopathy caused by OPLL is also reported to be influenced not only by static compression from the ossification mass, but also by abnormal intervertebral mobility at the responsible level(s)(Onari, Akiyama et al. 2001).

Despite these theoretical advantages, anterior corpectomy has been reported to be fraught with iatrogenic deterioration of the neurological state, and complications such as spinal fluid fistula or graft problem. Naturally, it will be more technically demanding if the OPLL is involved at multiple cervical levels, and treatment success will depend heavily on a less traumatic manipulation.

In Lee et al report, the authors concluded that direct anterior cervical corpectomy using the CO<sub>2</sub> laser resulted in a better recovery of neurological deficit, and adequate decompression of the spinal canal and maintenance of cervical regional lordosis at the operated level for patients with multilevel cervical OPLL. Assuming the surgeon can employ safe anterior microsurgical tools combined CO<sub>2</sub> laser and decompression method, proceeding with direct decompressive corpectomy rather than indirect, inadequate laminoplasty is recommended if the patient's preoperative status is appropriate.

They expected that a focused laser beam could vaporize the OPLL and even produce a positive effect. A 5-W pulse, single-pulse mode laser was sufficient to vaporize a thinned OPLL or an osteophyte, as it is known to penetrate only the outer table of the bone(Neblett 1992).(Fig.6)

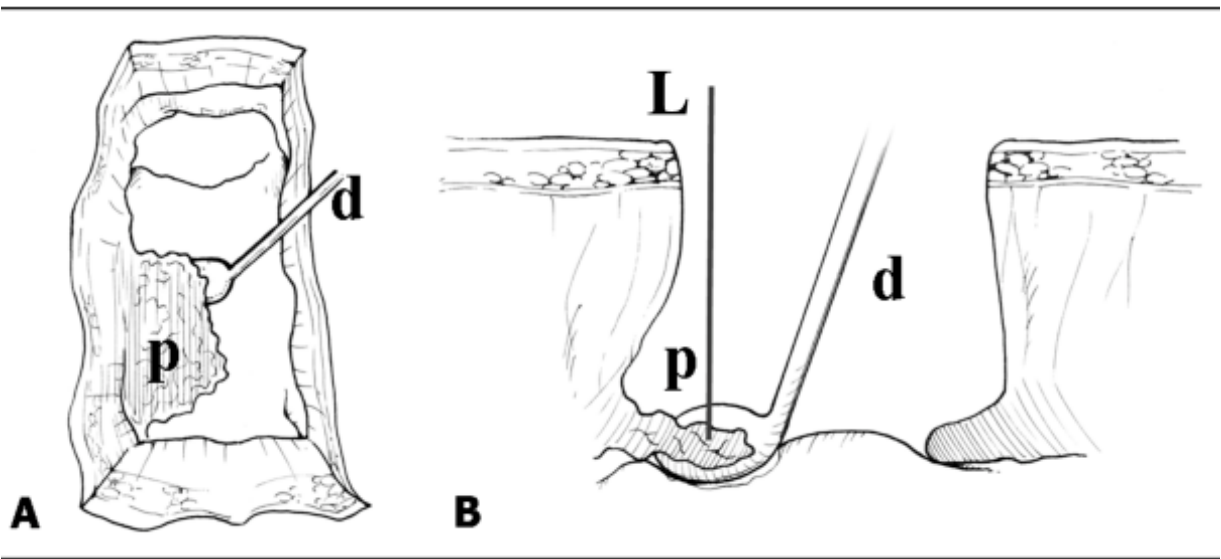


Fig. 6. An illustration showing the top view (A) and side view(B) of the surgical technique used to remove the densely adhered OPLL using the CO<sub>2</sub> laser (L) with the angled microdissector (d), which is held between the OPLL. (p) and the dura to avoid laser-induced damage to the dura.



### 2.2.5 Complication

Previously, a case of major vessel injury involving perforation of the iliac artery during CO<sub>2</sub> laser-assisted lumbar microdiscectomy, caused by prolonged irradiation of the CO<sub>2</sub> laser into the deep anterior disc space, has been reported. (Jeon, Lee et al. 2007) Avoiding point focusing of the CO<sub>2</sub> laser on the surface of the anterior annulus, as well as injecting a small amount of saline at the bottom of the intradiscal space during laser ablation, can prevent the occurrence of such a complication. (Jeon, Lee et al. 2007)

And during this procedure, keeping the surgical field moistened was important to minimize the risk of inadvertent injury, as water can absorb CO<sub>2</sub> laser energy immediately (Choi, Lee et al. 2005). (Fig.7)

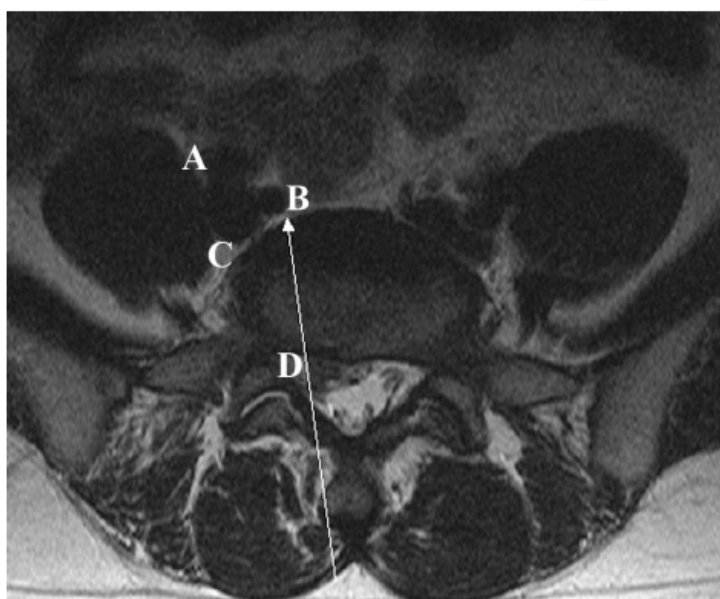


Fig. 7. Preoperative axial MRI at the L5-S1 level. White arrow indicates the direction of the carbon dioxide laser beam. A, External iliac artery. B, Internal iliac artery. C, Common iliac vein. D, Herniated disc fragment.

## 3. Clinical application in dermatology (Jung 2008)

### 3.1 Evolution of rejuvenation using lasers. (Alexiades-Armenakas, Dover et al. 2008; Jih and Kimyai-Asadi 2008)

It is described about the evolution of CO<sub>2</sub> fractional lasers utilized in the treatment of aging on a typical appliance, equipmental characteristics, clinical utilization in the future development direction,

#### 3.1.1 Historical background of fractional photothermolysis(FP)

##### 1. The period of introduction of concept of SPTL

Since Dr Rox Anderson represented the concept of selective photothermolysis(SPTL) In 1983, specific treatment methods of selectively targeting chromophore like melanin and hemoglobin have been developed clinically.

2. The period of CO<sub>2</sub> laser resurfacing

After destructive treatment by CO<sub>2</sub> laser at skin tumor was universal, it was known that aging skin was reformed as causing shrinkage in the recovery process after resurfacing. Laser resurfacing has been used as representative of treatment of aging of the skin in spite of long downtime from early 1990.

3. Introduction of NAR

There was effort to reduce the inconvenience of resurfacing by conventional laser using for rejuvenation and minimized the downtime. In 1991 Dr Shimon Dckhouse developed intense pulsed light(IPL) emitting to single pulse from multiple optical energy and introduced advantage for various clinical effect. So it was introduced the concept of non-ablative rejuvenation(NAR).

3.1.2 The development and change of fractional photothermolysis(FP)

Since introduction of the infrared wavelength range of equipment in 2006, AFR concept of a number of devices are being launched as merging ablation and FP using CO<sub>2</sub> and Er:YAG laser. Recently, laser equipment of IR, CO<sub>2</sub>, and Er:YAG are coexisting. The concept of FP having advantage of being safely usable of high powered energy is proliferated broadly to all territory of laser.

3.2 Treatment principle of CO<sub>2</sub> fractional laser

CO<sub>2</sub> laser is used to treatment of antiaging as removing by ablation of aging tissue and accelerating to regeneration of dermis by transmission of thermal stimulus.

Though resurfacing using existing CO<sub>2</sub> laser has many discomfort as ablation of total skin, CO<sub>2</sub> fractional laser is focus to treat only fine territory partially. So it is enable to treat safely epidermis and dermis though more high energy than existing treatment is transferred. Because the wound can be restored quickly and easily from surrounding normal skin though injured at epidermis and dermis by laser (Fig. 8.9).

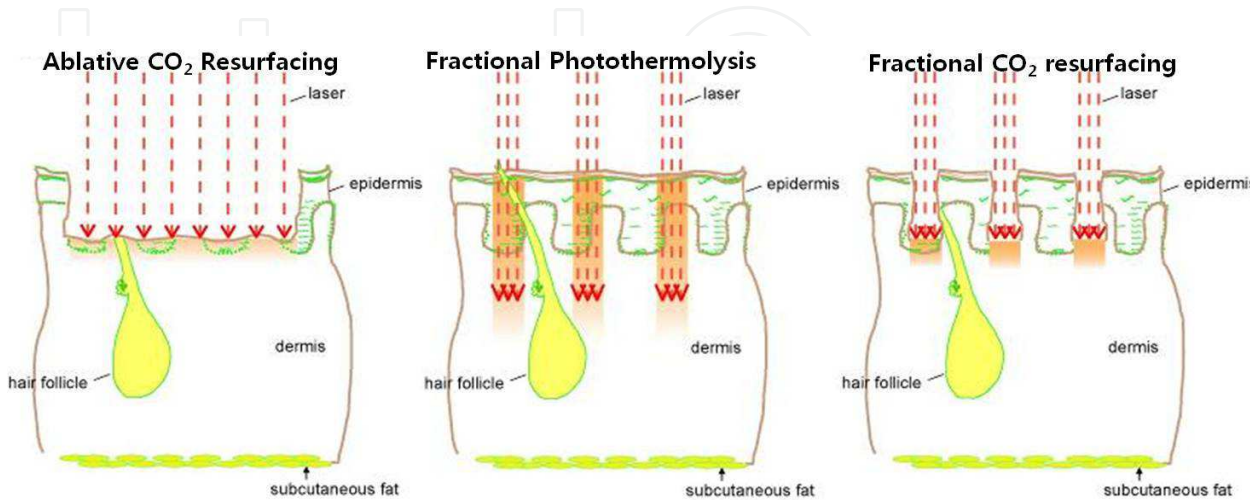


Fig. 8. The basic concept of Fractional Photothermolysis

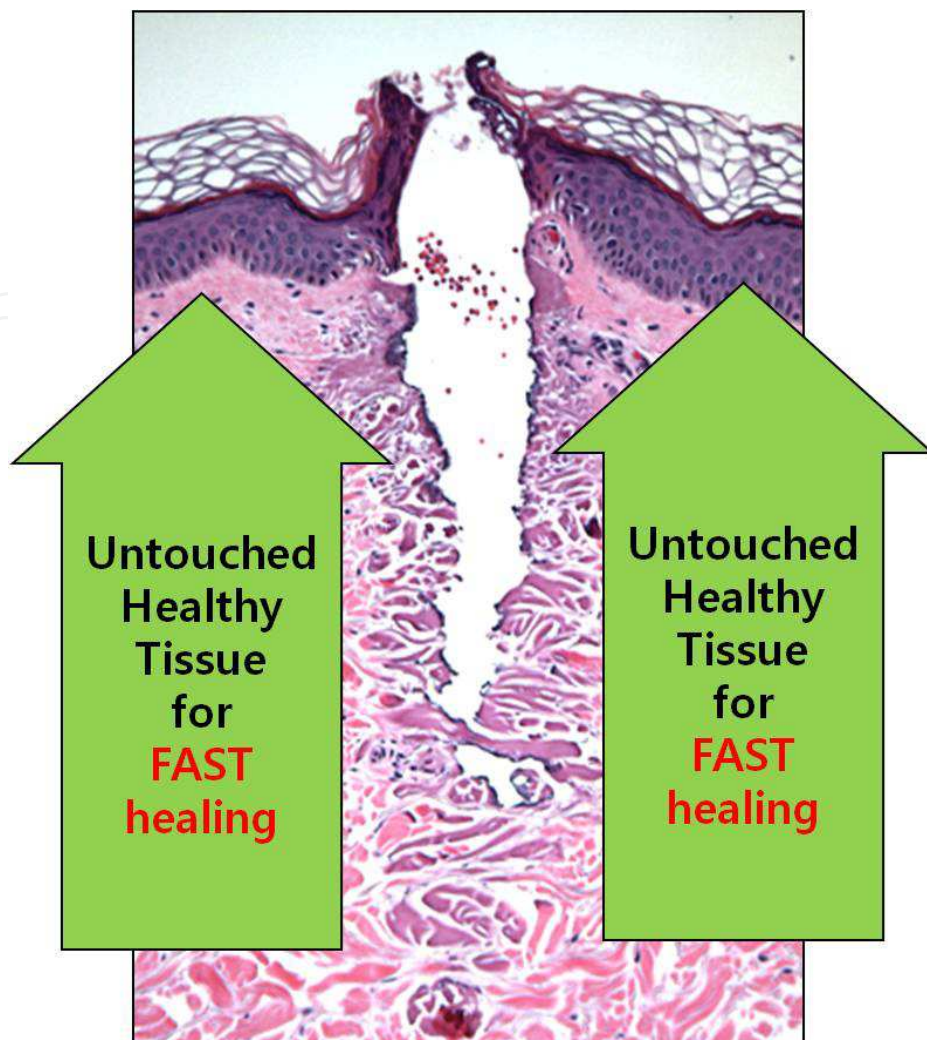


Fig. 9. The basic concept of Fractional CO<sub>2</sub> resurfacing: advantages.

You shall awaken warning to attach a laser cover at an operating room entrance as you use a CO<sub>2</sub> laser if you enforce an operation.

An enough exhaust device shall install because a lot of extensions occur, and you disturb an operation visual field, and you pollute air when you vaporize an organization.

### 3.2.1 Differences between the fractional infrared laser (1064~1600nm) and the CO<sub>2</sub> fractional laser (10,600nm)

CO<sub>2</sub> laser ablates tissue, such as the epidermis and dermis, resulting in tissue damage. This outcome differs completely from the Fraxal tissue reaction, which occurs when a cut is treated by the existing infrared laser (Fig. 10). However, no comparative study has been conducted on the recovery process of infrared rays (IR) and CO<sub>2</sub> laser. We know that CO<sub>2</sub> laser damages the dermo-epidermal junction, causing severe inflammation at the outset, which in turn results in edema and erythema reactions. We also understand that the lesions damaged by CO<sub>2</sub> laser ablation is first filled with keratonocyte within 48 hours and replaced by dermis through the remodeling process, a process that can be continued even after three months(Hantash, Bedi et al. 2007) (Fig. 11).



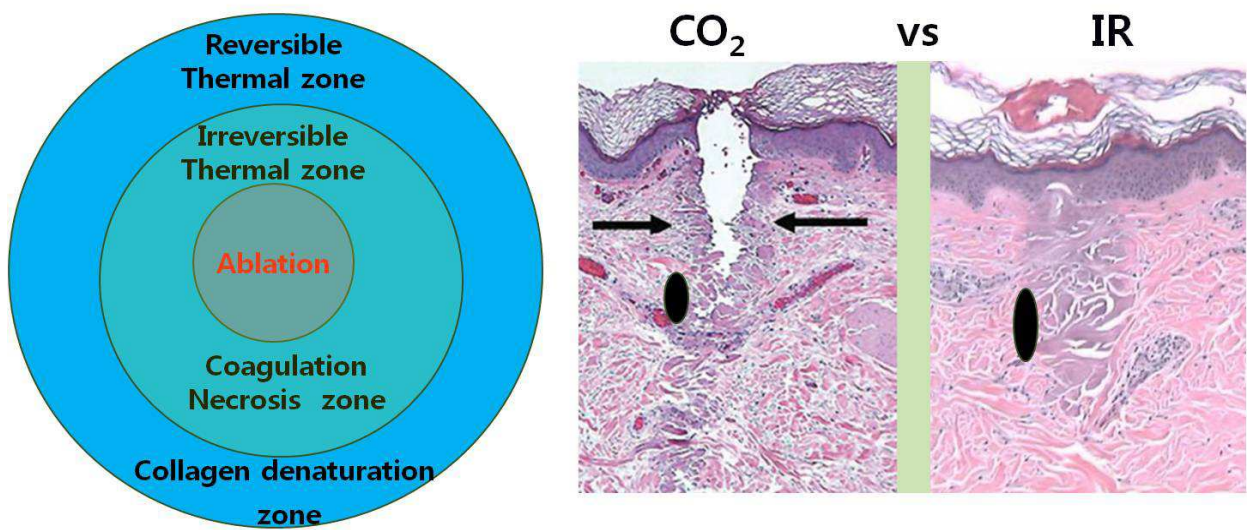


Fig. 10. The main difference between fractional infrared and fractional CO2 laser.

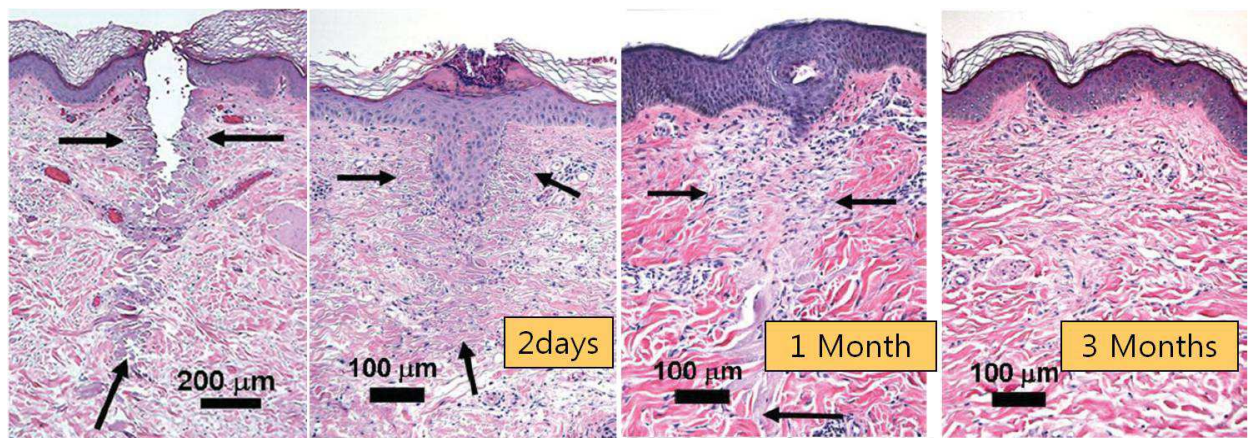


Fig. 11. The wound healing process of fractional CO2 laser treatment

3.2.1.1 Difference in tissue reaction according to wavelength

Infrared (Er:Glass, 1,400-1,600nm)  
CO<sub>2</sub>: 10,640 nm  
Er:YAG: 2,940 nm

1. Water absorption

The water absorption rate is in the order of Er: YAG, CO<sub>2</sub>, and IR (Fig. 12)

2. Lateral Heat Diffusion

CO<sub>2</sub> and Er:YAG lasers have higher water absorption rates compared to IR (1064~1600nm) equipment under the same condition (Fig. 12), and most of the energy disappears during the ablation and vaporization process. Therefore, they have less lateral heat diffusion to surrounding tissues when the laser is irradiated and can minimize heat accumulation inside the dermis. In other words, IR equipment accumulates relatively more heat in dermis tissues.



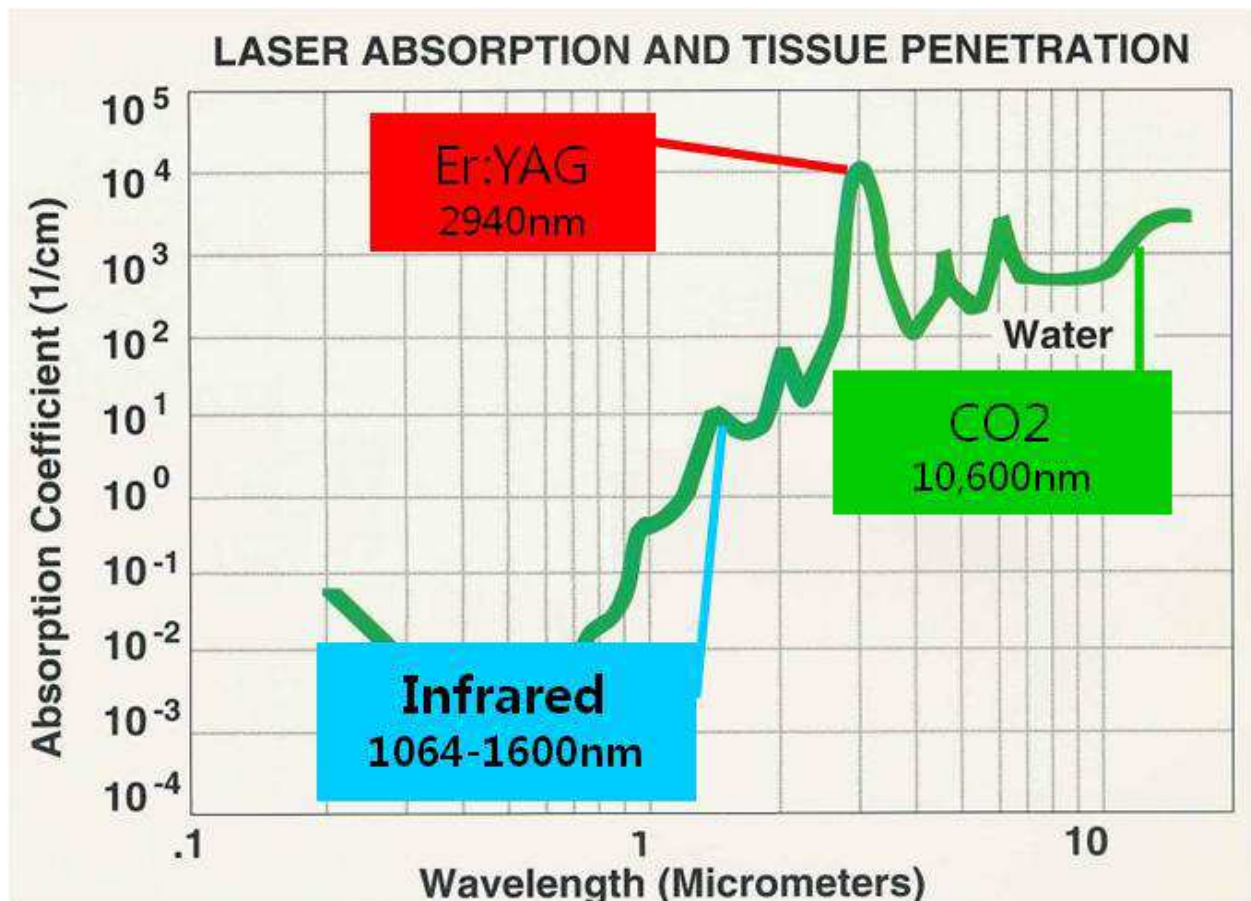


Fig. 12. Water absorption curve.

3. Shrinkage (Rosenberg, Brito et al. 1999; Fitzpatrick, Rostan et al. 2000; Jun, Harris et al. 2003; Zelickson, Kist et al. 2004; Hantash, Bedi et al. 2007)

Shrinkage is a tissue reaction related to the tightening effect that occurs due to tissue shortening after laser irradiation. So far, it is known to progress in the collagen denaturation zone (reversible thermal damage zone) (Fig. 10). Even though no comparative studies have been conducted on this process, IR equipment accumulates more heat inside dermis tissues under the same condition, which is why we think shrinkage will happen more with IR equipment. However, it is hard to estimate if more shrinkage is directly related to the rejuvenation effect, such as tissue tightening or lifting.

#### 4. Penetration Depth

IR can penetrate 1.0~1.5 mm maximum. However, it is believed that the Er:YAG or CO<sub>2</sub> lasers penetrate less than the IR laser since they absorb more water. According to recent studies, the CO<sub>2</sub> laser can penetrate as deeply as the IR laser if the wattage is increased, the size of the beam is reduced, and the quality beam is irradiated vertically on skin. Due to the CO<sub>2</sub> laser's characteristics, if the laser is repeatedly stacked on the same area, tissues can be constantly vaporized so that the laser can penetrate deeply enough. However, repetitive and deep penetration performed several times can cause unwanted excessive heat stimulation, leading to a higher chance of side effects. Therefore, it is right to consider the depth of single beam irradiation as a standard.

### 5. Risk of erythema and pigmentation

The potential of erythema and pigmentation is related to the damage level of the epidermis and dermis-epidermis joint area as well as the inflammatory reaction due to heat stimulation on the dermis. The risk decreases as fractional treatment convergence is decreased, with the proper convergence of fractional treatment being 20%. Since the risk increases in proportion to the level of heat damage, the CO<sub>2</sub> fractional laser can theoretically reduce epidermis damage and dermis heat damage because it has less lateral heat diffusion compared to the IR laser, which in turn will reduce the risk of erythema and pigmentation if it can produce a quality laser beam and be irradiated.

### 6. Level of Pain

Theoretically, the CO<sub>2</sub> fractional laser minimizes pain during procedures. Since most of the heat is lost during the tissue ablation process performed after laser irradiation, it has less lateral heat diffusion, which in turn reduces heat accumulation in tissues compared to IR equipment. Therefore, we expect less pain if we use the CO<sub>2</sub> fractional laser. In addition, short pulse duration, smaller spot size, and shorter irradiation time on the skin can reduce pain. Therefore, it is theoretically possible to actualize the CO<sub>2</sub> fractional laser with very little pain. However, this laser can damage the epidermis and dermis joint, which will cause more severe initial inflammation reaction and edema and burn feeling.

#### 3.2.1.2 Can parameter be independently controlled?

Since the CO<sub>2</sub> laser is a continuous wave laser, output is written in watts. Most CO<sub>2</sub> lasers can control parameters such as watt and pulse duration independently. Therefore, the same amount of energy (J) can be irradiated while the depth is controlled by watt level and the coagulation range (heat damage range) can be controlled by pulse duration (Fig. 13). These are very important strong points of the CO<sub>2</sub> laser, differing from IR equipment, which changes power and pulse duration according to the J (energy) level. That is, IR equipments cannot independently control factors since power and pulse duration is simultaneously increased as J (energy) is increased.

$$J \text{ (Energy)} = W \text{ (Power)} \times \text{Time (Pulse duration)}$$

· CO<sub>2</sub> laser: W, Time (pulse duration)  
independently controlled

· W: depth control

· Pulse duration: coagulation control

$$12W \times 5ms = 60mJ \quad 2W \times 30ms = 60mJ$$



$$J \text{ (Energy)} = \text{Watt (Power)} \times \text{Time (pulse duration)}$$

Fig. 13. Parameter controllability

Due to these characteristics, the CO<sub>2</sub> fractional laser can treat very deep layers and offers a better recovery process after treatment as it allows high power (deep penetration) and short pulse duration (minimal lateral heat diffusion to the surrounding area), creates a very narrow vertical ablation zone, and forms a limited lateral heat diffusion zone (Fig. 14).

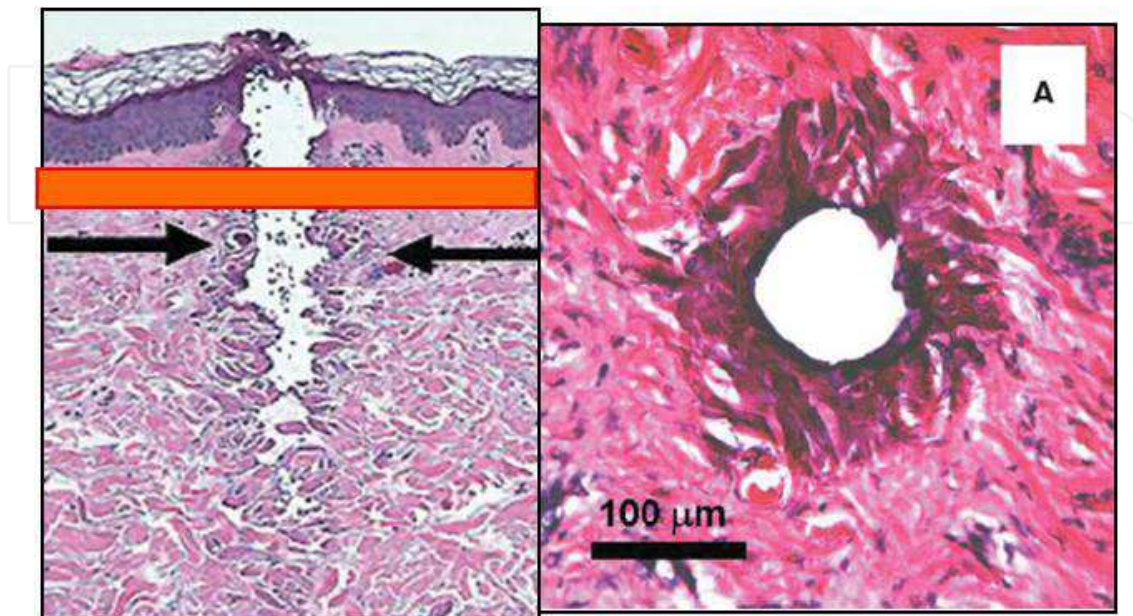


Fig. 14. Vertical and horizontal view of Fractional CO<sub>2</sub> laser.

### 3.2.2 Basic considerations for the fractional laser

#### 3.2.2.1 Spot size

The spot size of the laser refers to the diameter of irradiated beam. As the spot gets bigger, the re-epithelization process takes longer, which in turn cases a longer downtime. In fact, if the spot size is 140μm, re-epithelization of the dermo-epidermal junction takes less than 36 hours. It takes two to four days for 300μm, three to five days for 500μm, and five to ten days for over 1.25mm. Therefore, it is important to make the spot small to facilitate safe treatment and fewer inconveniences. Since there is a limit to the minimum spot size that can be actualized physically, it is impossible to reduce the size below a certain point. If the spot is too small, a lot more lasers should be irradiated on a certain area to get converge that is required for proper treatment. In that case, we cannot exclude excessive heat accumulation, which is why we cannot say a smaller spot size is always advantageous.

#### 3.2.2.2 Laser beam irradiation methods

There are various methods of irradiating several spots on a certain area. They can be classified into the moving method and the stamp method according to the type of equipment being utilized.

##### 1. Moving method

The moving method is used for Fraxal repair that has a function that can realize regular spot converge by controlling beam irradiation speed regardless of moving speed and eCO<sub>2</sub> equipment that has fixed beam irradiation speed by moving the handpiece constantly.



2. Stamp method: micro lens array and scanner type

After Fraxal acquired a patent on moving method irradiation, the equipment produced later on mostly adapted the stamp method. This method can be classified into two divisions. The most common method is micro lens array (the beam goes through the lens and is simultaneously irradiated after being divided into several fine beams, like LUX1540 and Affirm) that treats the parts by stamping microbeams. The other one is also a stamp method, but uses the scanner method rather than lens array and irradiates beams in order. The scanner method can be classified in two manners. The sequential type irradiates beams sequentially adjacently. Alternative type irradiates one line and skips the close line and irradiates the next line. Random type irradiates with no order. Theoretically, the sequential type includes a high possibility of heat accumulation due to adjacent irradiation. The random type can be a safer treatment since it minimizes heat accumulation. However, it is not clear if it has clinical significance.

3.2.2.3 Density

Density is the portion of treated area where the laser beam is irradiated. Density is considered to be low when there are many normal tissues left around the area. If density is too low, it is safe but can be ineffective. However, when density is high, there are less normal tissues, which is meaningless since fractional technology’s strength is safe and fast recovery. Therefore, we need to determine the density within proper range, considering the purpose of the treatment as well as the characteristics of the equipment. If more than two passes of treatment is done right after the first pass, density increases in proportion. However, it can weaken its safety as it causes excessive heat accumulation and repetitive irradiation on the same area. Therefore, it is safer to obtain the intended density from the first pass rather than acquiring it from repetitive passes.

3.2.2.4 Characteristics of the beam

We can observe various equipment characteristics, such as spot size, pitch, pitch control possibility and range, controllable range of irradiation time, watt range, scanning method scanning range, and scanning shape. However, the most important evaluation factor should be: “How superior is each beam’s characteristic?” In fact, the users are not fully aware of CO2 laser equipment’s characteristics. For example, if this equipment includes a scanner with various modes with an inconsistent quality beam, inconsistent irradiation direction or penetration depth, it can be a low-priced CO2 laser with a scanner. It is too much to expect this type of equipment to irradiate the quality beam uniformly on skin with detailed control over lateral heat diffusion and to penetrate into the skin with the depth one wants and obtain satisfactory results safely.

---

<ul style="list-style-type: none"><li>● Type of resonator and beam (<i>Longitudinally excited, Transversely excited, Gas dynamic, Waveguide laser</i>)</li><li>● Durability of resonator</li><li>● Beam window</li><li>● Calibration</li><li>● Auto-detection</li><li>● Individual control of pulse duration</li></ul>
--

---

Table 1. Factors Affecting the Beam Quality of CO<sub>2</sub> Laser



Therefore, when comparing CO<sub>2</sub> fractional laser performance, the most important factor that shows the biggest deviation is quality of beam. The following are the major factors that determine beam quality (Table 1).

3.3 Clinical application of CO<sub>2</sub> fractional laser

Laser induced regeneration by vaporizing aging tissue at the epidermis and dermis. It can effectively lead to regrowth and remodeling in the process, so it can be applied broadly to a variety of issues (scar, pigmentation, texture so on) at epidermis and dermis and it was also effective to improve the aging skin because laser can treated from 0.2mm in depth to 1mm or more at dermis.

However, it is limited to case reflected in the previously mentioned characteristics of the CO<sub>2</sub> when the CO<sub>2</sub> laser beam to penetrate the organization is elaborately controlled.

Because it can not be told that there was less possibility of erythema and pigmentation if not uncontrolled beam.

By such advantage, CO<sub>2</sub> fractional laser can be utilized to various indications of epidermis and dermis. (Table 2)

Since it was initially introduced in 2006, CO<sub>2</sub> fractional laser has been made up a large development and evolution for a short period of time, and future developments are expected as follows. (Table 3)

1. Superficial problem	
● Pigmentary lesions	● Pore
● Texture & aging skin	● Laxity(hand, neck)
● Wrinkles	
2. Surface and deeper structure	
● Scar	● Striae distensa
3. Dermal problem	
● Pigmentary lesions: refractory PIH, cloasma, tattoo	

Table 2. Clinical Indications of CO<sub>2</sub>Fractional Laser Treatment

● Controllable, smaller spot	● Powerful
● Variable parameter	● Surface cooling for epidermal preservation
● Increasing dermal shrinkage	● Deeper penetration
● Pattern of beam	● Quality of beam

Table 3. Future Development of CO<sub>2</sub>Fractional Laser

4. Clinical application in plastic surgery

You decrease a pain after operations by a laser in case of constancy as the way that used a CO<sub>2</sub> laser compares to the way that used a knife as you seal the peripheral nerve edge. And

because CO<sub>2</sub> laser can seal the lymphatics located at cutting plane and directly seal at peripheral vessel small sized less than 0.5mm, you can support patient to more comfort by accelerating wound healing process and by decreasing intraoperative bleeding and postoperative edema, contusion.

This CO<sub>2</sub> laser has definite advantage that it is very clear between the tissue which has thermal injury and no damaged tissue located at surrounding area, and it enable to cut tissue by not putting to physical stress to surrounding tissue. It has profit at the procedure by need of bloodless surgical field because of minimizing bleeding. And it enable to treat antiseptically to wound as vaporize the tissue by high temperature.

In palatoplasty and pharyngeal flap operation, compared to conventional method, complication caused by intra- and postoperative bleeding was decreased and there was no difference between CO<sub>2</sub> using and conventional method in aspect of wound healing. And CO<sub>2</sub> laser has merits to decrease hospitalization (Song IC 1998).

In patients of shortening of frenulum, CO<sub>2</sub> laser is available to frenotomy (Yoon CH 1998)

In blepharoplasty using CO<sub>2</sub> laser, it was first reported by Baker in 1984(Baker, Muenzler et al. 1984). Using CO<sub>2</sub> laser, blepharoplasty was processed safely and more enhanced to decrease bleeding, operation time, edema, time to heal. Mittelman et al (Mittelman and Apfelberg 1990) evaluated as safe method in spite of having risks of eyeball injury, breakaway from its course, fire at operation room, burn injury of skin.

Extramammary Paget's disease is eczema like disease accompanied mainly by itching of anus and genitalia. It was found very much among a middle age or patients of prime of manhood with the past history which a treatment of skin clinic was failed in during long periods. About this disease, invasive method was surgical excision and topical ointment using 5-fluorouracil, radiotherapy. Recently it is the trend that an interest of the treatment using CO<sub>2</sub> laser and Nd:YAG laser is rising (Ewing 1991; Yoon ES 2000)

In wound healing, Low-powered CO<sub>2</sub> laser helps to induce the synthesis of DNA by give effects to permeability of cell membrane, and to activate fibroblast and chondrocyte, and to accelerate to absorb the hematoma and to remove necrotic tissue, and to help to healing process of bone and cartilage (Tsai, Huang et al. 1997).

In atrophic scar, pulsed CO<sub>2</sub> laser having high power was utilized.

In acne scar, dermabrasion using CO<sub>2</sub> laser minimizing the common complication by conventional method and is enable to control the depth of peeling by depth of acne scar. So is enable to avoid to complication of hypertrophic scar and keloid etc.. It is available to process peeling safely and deeply. So recovery toward a daily life is fast as managements after operations is convenient because of decreasing of postoperative edema and pain by disconnecting at nerve terminals (Yoon ES 1998).

## **5. Clinical application in otorhinolaryngology**

### **5.1 Laryngeal microsurgery using CO<sub>2</sub> laser**

CO<sub>2</sub> laser is infrared having 10,600 nm wavelength. It has vibrational energy and enable to control to transfer through the mirror. The diameter of focus is about 1mm by

handpiece and about 200-250 $\mu$ m by micromanipulator from focus distance of 400mm. It was used by controlling the focus distance by using purpose, and it enable to cut like common scalpel. If defocused beam is emitted from more longer distance than focus distance, tissue coagulation was available as decreasing per unit of energy (Ossoff, Coleman et al. 1994).

Laryngeal microsurgery using CO<sub>2</sub> laser has many advantages more than conventional surgical method. CO<sub>2</sub> laser enables the surgeon to remove the exact desired pathology through controlling of power and emission time, which is necessary to preserve normal function. In situations where it is necessary to remove the pathology of a tubed organ, direct contact of the excised area and disturbance of the surgical field can be avoided. A bloodless operation is possible by the unique ability of the CO<sub>2</sub> laser to cauterize even arteries and veins as small as 0.5mm in diameter. Safety margins can be secured more easily when removing a tumor. A local inflammatory response is extremely small after an operation, and there is a little hyperplasia of a granulation tissue and scar formation during healing processes. In case of a huge tumor, CO<sub>2</sub> laser can help reduce the amount of tissue removed, which in turn can assist in maintenance of laryngeal function (Hall 1971; Norris and Mullarky 1982).

Possible anesthesia methods for laser microlaryngosurgery are intubation and non-intubated anesthesia etc. Rarely it is possible by Jet ventilation or tracheostomy. In cases of intubated anesthesia, protective tubes such as laser-Shield, Bivoan, and Malincrodt tubes can be used. The cuff of the intubation tube must be protected with a cottonoid soaked in a solution of normal saline during an operation. Non intubated anesthesia may be used when the visual field during an operation is obstructed by an anesthesia tube. This is achieved by removing the tube during surgery at 100% O<sub>2</sub> saturation, and quickly reinserting the tube after 2-3 minutes when the O<sub>2</sub> saturation begins to fall. Tumors located posterior to the larynx may be removed by inserting a laryngoscope behind the intubation tube (Fried 1984; Shapshay, Beamis et al. 1989).

When using a laser for laryngomicrosurgery, laser power should be set between 1 to 10 watts according the type of tissue to be removed or type of surgery. The most frequently used setting is a microscope magnified 16 to 25 times, laser power of 2 watts, and focus of 250 to 400 $\mu$ m. If the target tissue is too hard and blood vessels are too small, super pulse or ultrapulse methods should be used with a smaller focus (Ossoff, Coleman et al. 1994).

Carbonization of cancer pathology can be visualized more clearly during an operation with a continuous mode laser and can help discriminate between normal and cancer cells. A laryngeal forceps or suction tube should be used to pull the target tissue before using a laser to cut more cleanly while reducing carbonization or thermal injury.

CO<sub>2</sub> laser can be used in a variety of laryngeal diseases. First, benign laryngeal diseases such as laryngeal nodule, Reinke's edema, laryngeal cyst, granuloma, papilloma, angioma, septum and so on. Secondly, pre-cancerous pathology like white keratosis. Thirdly, it is partly applied in a treatment of malignant laryngeal pathology.

CO<sub>2</sub> laser can also be used to prevent asphyxia in various laryngeal diseases causing airway obstruction such as laryngeal and tracheal stenosis.

## 6. Conclusion

CO<sub>2</sub> laser has been developed until nowadays. At present, CO<sub>2</sub> laser is considered as essential instrument in medicine. In future, we think that CO<sub>2</sub> laser may be more developed for achieving the goal and more generalized.

## 7. Acknowledgment

Thank to corresponding Dr. Jun-Sung Kim for helping to support academic basis. And thank to Dr. Sang-Ho Lee for permitting the chance to writing in Wooridul Hospital. Also thank to Dr. Chan-Woo Jung at Leaders dermatologic clinics in South Korea for supporting dermatologic description and figure. Special thank to Mrs. Park Min for supporting dedication of this manuscript.

## 8. References


- Ahn, Y., S. H. Lee, et al. (2004). "Percutaneous endoscopic lumbar discectomy for recurrent disc herniation: surgical technique, outcome, and prognostic factors of 43 consecutive cases." *Spine (Phila Pa 1976)* 29(16): E326-332.
- Ahn, Y., S. H. Lee, et al. (2005). "Percutaneous endoscopic cervical discectomy: clinical outcome and radiographic changes." *Photomed Laser Surg* 23(4): 362-368.
- Alexiades-Armenakas, M. R., J. S. Dover, et al. (2008). "The spectrum of laser skin resurfacing: nonablative, fractional, and ablative laser resurfacing." *J Am Acad Dermatol* 58(5): 719-737; quiz 738-740.
- Ascher, P. W. and F. Heppner (1984). "CO<sub>2</sub>-Laser in neurosurgery." *Neurosurg Rev* 7(2-3): 123-133.
- Baker, S. S., W. S. Muenzler, et al. (1984). "Carbon dioxide laser blepharoplasty." *Ophthalmology* 91(3): 238-244.
- Beck, O. J. (1980). "The use of the Nd-YAG and the CO<sub>2</sub> laser in neurosurgery." *Neurosurg Rev* 3(4): 261-266.
- Benjamin, M., S. Qin, et al. (1995). "Fibrocartilage associated with human tendons and their pulleys." *J Anat* 187 ( Pt 3): 625-633.
- Chiba, K., Y. Toyama, et al. (2001). "Intraspinal cyst communicating with the intervertebral disc in the lumbar spine: discal cyst." *Spine (Phila Pa 1976)* 26(19): 2112-2118.
- Choi, K. B., D. Y. Lee, et al. (2008). "Contralateral reherniation after open lumbar microdiscectomy : a comparison with ipsilateral reherniation." *J Korean Neurosurg Soc* 44(5): 320-326.
- Choi, S., S. H. Lee, et al. (2005). "Factors affecting prognosis of patients who underwent corpectomy and fusion for treatment of cervical ossification of the posterior longitudinal ligament: analysis of 47 patients." *J Spinal Disord Tech* 18(4): 309-314.
- Choy, D. S., R. B. Case, et al. (1987). "Percutaneous laser nucleolysis of lumbar disks." *N Engl J Med* 317(12): 771-772.
- Cusick, J. F. (1991). "Pathophysiology and treatment of cervical spondylotic myelopathy." *Clin Neurosurg* 37: 661-681.
- Deruty, R., I. Pelissou-Guyotat, et al. (1993). "Routine use of the CO<sub>2</sub> laser technique for resection of cerebral tumours." *Acta Neurochir (Wien)* 123(1-2): 43-45.



- Ewing, T. L. (1991). "Paget's disease of the vulva treated by combined surgery and laser." *Gynecol Oncol* 43(2): 137-140.
- Fitzpatrick, R. E., E. F. Rostan, et al. (2000). "Collagen tightening induced by carbon dioxide laser versus erbium: YAG laser." *Lasers Surg Med* 27(5): 395-403.
- Fried, M. P. (1984). "Limitations of laser laryngoscopy." *Otolaryngol Clin North Am* 17(1): 199-207.
- Glasscock, M. E., 3rd, C. G. Jackson, et al. (1981). "The argon laser in acoustic tumor surgery." *Laryngoscope* 91(9 Pt 1): 1405-1416.
- Gropper, G. R., J. H. Robertson, et al. (1984). "Comparative histological and radiographic effects of CO<sub>2</sub> laser versus standard surgical anterior cervical discectomy in the dog." *Neurosurgery* 14(1): 42-47.
- Hall, R. R. (1971). "The healing of tissues incised by a carbon-dioxide laser." *Br J Surg* 58(3): 222-225.
- Hantash, B. M., V. P. Bedi, et al. (2007). "In vivo histological evaluation of a novel ablative fractional resurfacing device." *Lasers Surg Med* 39(2): 96-107.
- Hellinger, J. (1999). "Technical aspects of the percutaneous cervical and lumbar laser-disc-decompression and -nucleotomy." *Neurol Res* 21(1): 99-102.
- Heppner, F. (1978). "[The laser scalpel in the nervous system]." *Wien Med Wochenschr* 128(7): 198-201.
- Houck, P. M. (2006). "Comparison of operating room lasers: uses, hazards, guidelines." *Nurs Clin North Am* 41(2): 193-218, vi.
- Jeon, S. H., S. H. Lee, et al. (2007). "Iliac artery perforation following lumbar discectomy with microsurgical carbon dioxide laser: a report of a rare case and discussion on the treatment." *Spine (Phila Pa 1976)* 32(3): E124-125.
- Jih, M. H. and A. Kimyai-Asadi (2008). "Fractional photothermolysis: a review and update." *Semin Cutan Med Surg* 27(1): 63-71.
- Jun, J. H., J. L. Harris, et al. (2003). "Effect of thermal damage and biaxial loading on the optical properties of a collagenous tissue." *J Biomech Eng* 125(4): 540-548.
- Jung, C. W. (2008). "Understanding of CO<sub>2</sub> laser in dermatology." *Journal of dermatology korean society for laser medicine and surgery* 12(1): 90-99.
- Kang, H., W. C. Liu, et al. (2008). "Midterm results of percutaneous CT-guided aspiration of symptomatic lumbar discal cysts." *AJR Am J Roentgenol* 190(5): W310-314.
- Kim, J. S. (2010). "Facility of the removal of recurrent disc herniation due to use of laser in primary operation." *Journal of the korean society for laser medicine and surgery* 14(1): 83-87.
- Kim, J. S., G. Choi, et al. (2009). "Removal of a discal cyst using a percutaneous endoscopic interlaminar approach: a case report." *Photomed Laser Surg* 27(2): 365-369.
- Kim, J. S. and S. H. Lee (2009). "Carbon dioxide (CO<sub>2</sub>) laser-assisted ablation of lumbar discal cyst." *Photomed Laser Surg* 27(6): 837-842.
- Krishnamurthy, S. and S. K. Powers (1994). "Lasers in neurosurgery." *Lasers Surg Med* 15(2): 126-167.
- Lee, D. Y., Y. Ahn, et al. (2006). "Percutaneous endoscopic lumbar discectomy for adolescent lumbar disc herniation: surgical outcomes in 46 consecutive patients." *Mt Sinai J Med* 73(6): 864-870.
- Lee, D. Y. and S. H. Lee (2008). "Learning curve for percutaneous endoscopic lumbar discectomy." *Neurol Med Chir (Tokyo)* 48(9): 383-388; discussion 388-389.

- Lee, D. Y. and S. H. Lee (2011). "Carbon dioxide (CO<sub>2</sub>) laser-assisted microdiscectomy for extraforaminal lumbar disc herniation at the L5-S1 level." *Photomed Laser Surg* 29(8): 531-535.
- Lee, H. K., D. H. Lee, et al. (2006). "Discal cyst of the lumbar spine: MR imaging features." *Clin Imaging* 30(5): 326-330.
- Lee, S. H., Y. Ahn, et al. (2006). "Immediate pain improvement is a useful predictor of long-term favorable outcome after percutaneous laser disc decompression for cervical disc herniation." *Photomed Laser Surg* 24(4): 508-513.
- Lee, S. H., Y. Ahn, et al. (2008). "Laser-assisted anterior cervical corpectomy versus posterior laminoplasty for cervical myelopathic patients with multilevel ossification of the posterior longitudinal ligament." *Photomed Laser Surg* 26(2): 119-127.
- Min, J., Chung, B.J., and Lee, S.H. (2006). "Endoscopically managed synovial cyst of the lumbar spine." *Korean Journal of Spine* 3: 242-245.
- Mittelman, H. and D. B. Apfelberg (1990). "Carbon dioxide laser blepharoplasty--advantages and disadvantages." *Ann Plast Surg* 24(1): 1-6.
- Neblett, C. R. (1992). *Laser and the cervical spine*. Philadelphia, Lippincott Williams & Wilkins.
- Nerubay, J., I. Caspi, et al. (1997). "Percutaneous laser nucleolysis of the intervertebral lumbar disc. An experimental study." *Clin Orthop Relat Res*(337): 42-44.
- Norris, C. W. and M. B. Mullarky (1982). "Experimental skin incision made with the carbon dioxide laser." *Laryngoscope* 92(4): 416-419.
- Onari, K., N. Akiyama, et al. (2001). "Long-term follow-up results of anterior interbody fusion applied for cervical myelopathy due to ossification of the posterior longitudinal ligament." *Spine (Phila Pa 1976)* 26(5): 488-493.
- Origitano, T. C. and O. H. Reichman (1993). "Photodynamic therapy for intracranial neoplasms: development of an image-based computer-assisted protocol for photodynamic therapy of intracranial neoplasms." *Neurosurgery* 32(4): 587-595; discussion 595-586.
- Ossoff, R. H., J. A. Coleman, et al. (1994). "Clinical applications of lasers in otolaryngology--head and neck surgery." *Lasers Surg Med* 15(3): 217-248.
- Powers, S. K., S. S. Cush, et al. (1991). "Stereotactic intratumoral photodynamic therapy for recurrent malignant brain tumors." *Neurosurgery* 29(5): 688-695; discussion 695-686.
- Rosenberg, G. J., M. A. Brito, Jr., et al. (1999). "Long-term histologic effects of the CO<sub>2</sub> laser." *Plast Reconstr Surg* 104(7): 2239-2244; discussion 2245-2236.
- Shapshay, S. M., J. F. Beamis, Jr., et al. (1989). "Total cervical tracheal stenosis: treatment by laser, dilation, and stenting." *Ann Otol Rhinol Laryngol* 98(11): 890-895.
- Song IC, P. W., Kil MS (1998). "Laser assisted palatoplasty and pharyngeal flap." *J Korean Soc Plast Reconstr Surg* 25: 252.
- Stein, E., T. Sedlacek, et al. (1990). "Acute and chronic effects of bone ablation with a pulsed holmium laser." *Lasers Surg Med* 10(4): 384-388.
- Stellar, S., T. G. Polanyi, et al. (1970). "Experimental studies with the carbon dioxide laser as a neurosurgical instrument." *Med Biol Eng* 8(6): 549-558.
- Tew, J. M., Jr. and W. D. Tobler (1983). "The laser: history, biophysics, and neurosurgical applications." *Clin Neurosurg* 31: 506-549.
- Tsai, C. L., L. L. Huang, et al. (1997). "Effect of CO<sub>2</sub> laser on healing of cultured meniscus." *Lasers Surg Med* 20(2): 172-178.

- Whipple, T. L., R. B. Caspari, et al. (1984). "Laser subtotal meniscectomy in rabbits." *Lasers Surg Med* 3(4): 297-304.
- Yoon CH, R. Y., Park HS, Kim HJ (1998). "Comparative study between using CO<sub>2</sub>-laser and classic method in frenulotomy." *J Korean Soc Plast Reconstr Surg* 25: 1475.
- Yoon ES, C. J., Han SK, Kim WK (2000). "Treatment of extramammary Paget's disease using the CO<sub>2</sub> laser." *J Korean Soc Plast Reconstr Surg* 27: 169.
- Yoon ES, K. S., Ahn DS, Park SH (1998). "CO<sub>2</sub> laser resurfacing of acne scar." *J Korean Soc Aesth Plast Reconstr Surg* 4: 381.
- Zelickson, B. D., D. Kist, et al. (2004). "Histological and ultrastructural evaluation of the effects of a radiofrequency-based nonablative dermal remodeling device: a pilot study." *Arch Dermatol* 140(2): 204-209.



## **CO2 Laser - Optimisation and Application**

Edited by Dr. Dan C. Dumitras

ISBN 978-953-51-0351-6

Hard cover, 436 pages

**Publisher** InTech

**Published online** 21, March, 2012

**Published in print edition** March, 2012

The present book includes several contributions aiming a deeper understanding of the basic processes in the operation of CO<sub>2</sub> lasers (lasing on non-traditional bands, frequency stabilization, photoacoustic spectroscopy) and achievement of new systems (CO<sub>2</sub> lasers generating ultrashort pulses or high average power, lasers based on diffusion cooled V-fold geometry, transmission of IR radiation through hollow core microstructured fibers). The second part of the book is dedicated to applications in material processing (heat treatment, welding, synthesis of new materials, micro fluidics) and in medicine (clinical applications, dentistry, non-ablative therapy, acceleration of protons for cancer treatment).

### **How to reference**

In order to correctly reference this scholarly work, feel free to copy and paste the following:

Hyeong-Seok Oh and Jin-Sung Kim (2012). Clinical Application of CO<sub>2</sub> Laser, CO<sub>2</sub> Laser - Optimisation and Application, Dr. Dan C. Dumitras (Ed.), ISBN: 978-953-51-0351-6, InTech, Available from:  
<http://www.intechopen.com/books/co2-laser-optimisation-and-application/clinical-application-of-co2-laser>

**INTech**  
open science | open minds

### **InTech Europe**

University Campus STeP Ri  
Slavka Krautzeka 83/A  
51000 Rijeka, Croatia  
Phone: +385 (51) 770 447  
Fax: +385 (51) 686 166  
[www.intechopen.com](http://www.intechopen.com)

### **InTech China**

Unit 405, Office Block, Hotel Equatorial Shanghai  
No.65, Yan An Road (West), Shanghai, 200040, China  
中国上海市延安西路65号上海国际贵都大饭店办公楼405单元  
Phone: +86-21-62489820  
Fax: +86-21-62489821



© 2012 The Author(s). Licensee IntechOpen. This is an open access article distributed under the terms of the [Creative Commons Attribution 3.0 License](https://creativecommons.org/licenses/by/3.0/), which permits unrestricted use, distribution, and reproduction in any medium, provided the original work is properly cited.

IntechOpen

IntechOpen