

# We are IntechOpen, the world's leading publisher of Open Access books Built by scientists, for scientists

6,900

Open access books available

185,000

International authors and editors

200M

Downloads

Our authors are among the

154

Countries delivered to

TOP 1%

most cited scientists

12.2%

Contributors from top 500 universities



WEB OF SCIENCE™

Selection of our books indexed in the Book Citation Index  
in Web of Science™ Core Collection (BKCI)

Interested in publishing with us?  
Contact [book.department@intechopen.com](mailto:book.department@intechopen.com)

Numbers displayed above are based on latest data collected.  
For more information visit [www.intechopen.com](http://www.intechopen.com)



# Development and Clinical Evaluation of Bioactive Implant for Interbody Fusion in the Treatment of Degenerative Lumbar Spine Disease

Michal Filip<sup>1</sup>, Petr Linzer<sup>1</sup> and Jakub Strnad<sup>2</sup>

<sup>1</sup>Neurosurgical Dept. KNTB Zlín,

<sup>2</sup>LASAK Ltd., Prague,  
Czech Republic

## 1. Introduction

Due to new information about the pathophysiology and biomechanics of degenerative lumbar spine disease, the surgical treatment of this disease has undergone a significant increase over the past forty years. Novel diagnostic approaches and the development of new materials provided the impetus to produce new types of instrumentation, and these instruments have led to the modernization of interbody fusion including PLIF, TLIF and ALIF methods. These interventions are currently performed in either an open mini-invasive or endoscopic manner. The open interventions are indicated in cases where the spinal canal stenosis is caused by severe degenerative lesions affecting the motion of intervertebral discs, joints, ligaments, or vertebral arch. Despite the development of other surgical techniques (e.g., functional disc substitutes, dynamic stabilization), the posterior interbody fusion represents a powerful approach in the surgical treatment of degenerative stenosis of the spinal canal.

The PLIF method was first applied in the 1940s by Briggs and Milligan who inserted crushed bone grafts into the intervertebral space, and the bone grafts insertion technique was further developed by Cloward (Cloward, 1953). Due to complications associated with autografts (i.e., pain at the sampling site, procedure prolongation, etc.), the PLIF surgical technique was improved in the 1980s, and new implants constructed of various materials were developed (Bienik and Swiecki, 1991; Brantigan et al, 1994; Khoo et al, 2002; Šrámek et al, 2010). Likewise, novel diagnostic tools have been developed including MRI, 3D CT, SPECT-CT (Crock, 1976, Modic et al, 1988; Blumenthal et al, 1988), and new materials (e.g., ceramic, titanium, PEEK) have yielded new types of implants leading to the modernization of the interbody fusion via PLIF techniques (Alexander et al, 2002; Bessho et al, 1997; Brayan et al, 2002; Ciappetta et al, 1997; Kokubo, 1990; Yamamuro, 1995; Hashimoto et al, 2002; Thalgott et al, 2002; Sandhu, 2003). Currently, the majority of implants for PLIF consist of two separate components, including the solid cage shape and osseointegrative material (i.e., TCP, BMP) that ensures osteoblastic activity and the interbody fusion formation. To date, no material with both suitable mechanic properties and high grade bioactivity is currently

available. For instance, solid materials (e.g., medical steel, titanium, PEEK) lack bioactivity that is able to support the osseointegration (Carlson et al, 1988; Williams and McNamara, 1987; Zdeblick and Philips, 2003). Likewise, bioactive or resorbable materials (e.g., glass-ceramic, hydroxyapatite, polysaccharides) do not meet the mechanical requirements for fusion implants of intervertebral discs (Hench et al, 1971; Filip et al, 1996; Sobale et al, 1990; McAfee, 1986).

Currently, the majority of implants consist of cages that form various shapes. The perimeter is constructed from a solid material that ensures the structural strength. The centre of the cage is hollow and is filled by bone grafts or osseointegrative material (e.g. bi- or tri-calcium phosphate) to promote bone fusion in this part of the implant. The optimal implant for an interbody fusion should imitate the properties of the bone tissue by combining sufficient mechanical strength as well as bioactive surface. Therefore, the mechanical strength and the shape of the implant should ensure the primary stability of the segment of the lumbar spine following the operation. Furthermore, the bioactive surface should allow stimulation of osteoblast proliferation at the interface of the implant and bone, and should promote activation of their migration along the implant surface. The bioactive surface should also act as a conductor for osteoblast migration to the fixed vertebral bodies to form the fusion. This quality would prevent the requirement for additional filling of the implant by osseointegrative material. The aim of our work was to create an implant with optimal strength and bioactivity in an attempt to replace the use of autografts and two-compartment implants for PLIF.

## 2. Research

### 2.1 Advantages and disadvantages of PLIF surgical technique using autografts

When the conservative treatment fails, patients from categories LS syndrome and FBS syndrome (Failed Back Surgery syndrome) are often referred to surgical management via posterior interbody fusion (Benzel et al, 2003; Cloward, 1953; Crock, 1976; Daniaux, 1986; Dove, 1990; Gurr et al, 1999; Cho et al, 2002). The indication for this surgery is based on neurological finding. In general, the patient predominantly either suffers from back pain associated with progression of root lesion in a lower extremity or with neurogenic claudications in the lower limbs, and shows no reaction to the full conservative therapy algorithm (Anderson, 2000; Brinckman et al, 1989; Brodke et al, 1997; Cloward, 1953, Hrabálek et al, 2009; Paleček et al, 1994; Fischgrund et al, 1997). Furthermore, the disease is supported by graphic images of compression of the neural structures caused by degenerative lesions (Knudson, 1944; Crock, 1978; Modick et al, 1983; Sonntag and Theodore, 2000). The desired clinical effect can be achieved by the decompression of neural structures together with spondylodesis of the affected spine segment using PLIF (Steffee, 1988; Hashimoto et al, 2002; Dick, 1987; Wang et al, 2005). When surgical treatment is necessary, no acceptable scientific long-term evidence of efficacy exists for any type of surgical treatment of the degenerative lumbar spine disease (Brodke et al, 1997; Benzel, 2003; Sonntag and Theodore, 2000; Paleček et al, 1994).

We performed PLIF using autografts that were developed in the 1980s. An autograft (mostly iliac crest bone grafts) stripped of connective tissue was inserted under compression into the intervertebral space. The best stability was achieved by transpedicular fixation of the

operated segment necessary for osteointegration of the grafts via their remodeling and PLIF formation (Bauer and Muschler, 2000). The advantage of a recently collected autolog bone graft has been the presence of live bone cells with mineralized extracellular matrix. The biological activity, structure and proteins of bone morphogenesis are important prerequisites of the fusion. In addition, clinical experiences from the first half of the 20th century have proved better surgical outcomes with autolog grafts in comparison to simple decompression (Cloward, 1953; Dawson et al, 1981; Dick, 1987; Carlson et al, 1988). Autolog grafts in this form have been the gold standard for PLIF in the majority of spondylosurgical clinics through the end of the 20th century. Despite improving surgical outcomes with a growing number of operated patients, new complications still exist regarding this otherwise successful surgical technique (Kurz et al, 1989).

The most common complications associated with this surgery include problems with bone graft sampling in that limitations are present in bone size and structure that may be safely collected from a live patient in cases of extensive intervention. Furthermore, patients can suffer from unpleasant reactions including debilitating postoperative pain, infection, seroma, cosmetic defects, nerve injury, hip fractures, vessel injury and blood loss. These adverse reactions can occur in 10 to 39% of cases (Arrington et al, 1996; Banwart et al, 1994; Banwart et al, 1995). Therefore, these reactions and other problems have led to search for artificial materials for PLIF. The optimal material for PLIF substituting bone grafts should ideally have the following characteristics. First, the material should show solid structural support (load resistance immediately after implantation). Second, the material should display osseointegration and bioactivity or the ability to bind with a bone, fusion support without any other additional material (e.g., bone, BCP etc.). Third, the material should provide the possibility for a radiographical assessment of the bone fusion process. Finally, the material should show biomechanical properties (elasticity modulus similar to bone).

## 2.2 Development of a new implant for PLIF

As described in chapter 2.1, we considered using an implant made from a synthetic material for PLIF in the early 1990s to eliminate the disadvantages of autografts (Madawi et al, 1996). The most available implants were constructed of medical steel (Bagby, 1988). However, these implants did not meet our notion of sufficient strength accompanied by bioactivity. Spondylosurgeons in Charkov (Professor Gruntovskij) have successfully used corundum implants in combination with hydroxyapatite for PLIF in the surgical treatment of degenerative lumbar spine disease in the 1980s. According to results of this clinic, the success of this implant resulted from its prism shape with projections firmly anchored in the intervertebral space that helped the implant to fixate the segment with or without transpedicular fixation following operation. Due to its bioinertness, hydroxyapatite was added, and this soft material was placed around the corundum (Rowlings, 1993; Gogolewski et al, 1993). Therefore, this implant stimulated formation of osteoblasts, and served as a conductor for their migration between adjacent surfaces of adjoining vertebral bodies. In the early 1990s, another type of prosthesis produced from bioactive glass-ceramic was developed by Electric Nippon Glass, and was used by Japanese orthopedists for PLIF (Yamamuro, 1995, Kokubo, 1990). While transpedicular fixation was added to PLIF due to its fragility, the bioactivity of the implant surface allowed fusion due to migration of bone cells along its surface without addition of any supporting material (e.g., bone,

hydroxyapatite) (Sobale, 1990; Yamamuro, 1995). Based on these experiences, we began searching for a material for PLIF implant that would combine the advantages of both the shape and the strength of corundum and the bioactivity of glass-ceramic used in the early 1990s. Thereby, the combination of these two properties would allow strong anchoring of this material in the intervertebral space, the restoration of anatomy in the operated segment, the stabilization of unstable segment, and the formation of interbody fusion associated with osseoconductive properties without addition of another material and without the risk of migration.

### **2.3 Experimental development of glass-ceramic implant (BAS-O)**

Unlike bioinert or biotolerant materials, bioactive glass-ceramic material BAS-O, forms a strong chemical bond with live bone tissue (Fatley et al, 1979; Urban, 1992). Material BAS-O is prepared by progressive steps, such as sintering, controlled crystallization and others. The controlled crystallization allows control of processes that determine the bioactive ability of the final material including material transformation, the control of chemical structure, and the structure of the glass phase (Strnad, 1992). The ability of this material to form a strong bond with bone tissue results from the formation of an apatite layer on the material surface resulting in the connection of the bioactive material with body fluid. Crystallographic chemical characteristic of apatite released on the material surface is similar to the organic part of the bone tissue. Thereby, the stability of the operated segment without micromovements and the tight contact of the material without microgaps are necessary for perfect chemical bond BAS-O / live tissue. Otherwise, a risk of connective tissue penetration exists that can prevent the chemical bond on the bone / implant interface (Kokubo, 1990; Urban, 1992).

The most important finding for the planned use of the lumbar implant necessitated that the biochemical and mechanical properties of the glass-ceramic BAS-O mimic the cortical bone tissue. According to the Young model, the shape of their implant exceeded twice the strength of the vertical load, and was close to its flexural strength. Therefore, we based our implant shape on our previous experiences and according to the models that we observed during our study visits. Together with size and shape development, we also created application instrumentation used for the intervertebral space as well as the operation procedure. At this time, the fragility of the ceramic in the contact with steel represented our only disadvantage in that this fragility could cause problems with insertion using metal application instrumentation. The application instrumentation was coated by Teflon in order to prevent damage to the implant. A rectangular prism-shaped implant (25 mm long, 8 mm high and 10 mm wide) was progressively developed after repeated experiments with cadavers from 1991 to 1993 (Filip et al, 1995). "Winglets" have been placed on the opposite sides of the prism (Figure 1).

The winglets cut into the adjacent vertebral bodies after its rotation by 90 degrees, and the implant was firmly attached within the space without a risk of migration into the spinal canal. Due to its bioactivity, the implant should stimulate migration of bone cells along its surface to form interbody fusion. The application technique for the glass-ceramic implant was the same as with other implants for PLIF. During experimental application in cadavers, the implants were well-anchored in the vertebral bodies without compression of dural sac in the spinal canal, and this placement was confirmed by imaging techniques (X-ray and CT).



We also planned to apply such PLIF methods alone in both low-grade instabilities and to add transpedicular fixation in high-grade instabilities.

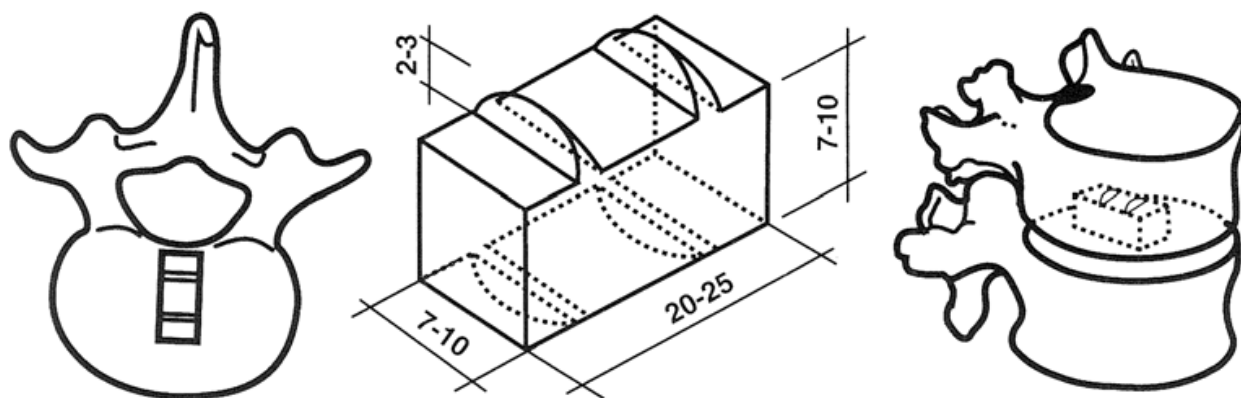


Fig. 1. Outline of the implant and its position in the interbody space (1992).

The implant was inserted using a specially developed instrumentation into the interbody space (Figure 2).




Fig. 2. Glass-ceramic implant plus application fork (1992).

#### 2.4 Implant made of material BAS-0 in clinical practice

Implant BAS-O was registered by the Ministry of Health of the Czech Republic with registration number 89/492/98-IIB in 1992. After registration of the implant and based on experimental results, we introduced the implant into clinical practice in 1994. Based on the advantages from the experimental studies (e.g., stability in the operated space, restoration of anatomy, elimination of the risk of bone grafts sampling, etc.), we expected that these results would be confirmed. From 1994 to 1999, we used this technique in 65 patients observing the indication criteria and the surgical procedure described in the previous chapters. We assessed clinic and graphic postoperative findings in 25 patients out of this population during follow-ups conducted three, six, and twelve months after the intervention. The average age of the patients was 52 years. In 22 patients, the operation represented the first

on the spinal segment affected by degenerative instability of various types. We applied the implant BAS-O according to the experimental study. Additionally, PLIF was performed using a pair of implants by the stand alone technique in ten patients (Figure 3), and PLIF was conducted using one or two implants with additional transpedicular fixation by various companies in fifteen patients (Synthes, Stryker etc.).



Fig. 3. Fixation of L4/5 instability using a pair of glass-ceramic implants by stand alone technique (1995).

We assessed our results three, six and twelve months after the operation using the ODI score (Oswestry Disability Index; see Table 1). The Oswestry Disability Index (ODI) has become one of the principal condition-specific outcome measures used in the management of spinal disorders. We also used imaging techniques that were available at the time (i.e., X-ray, CT, rarely MRI), and we assessed the change of the implant position in the operated space (i.e., damage, dislocation) using the postoperative imaging techniques (X-ray; see Table 2).

ODI score of our population [%]	Mean [n] 25	Primary instability [n] 8	Degenerative listhesis grade I-II [n] 11	Isthmic listhesis up to grade II [n] 6
Before operation	60	55	67	58
3 months after operation	39	36	44	38
6 months after operation	40	39	42	38
12 months after operation	42	40	46	41

Table 1. Clinical assessment according to ODI score.

BAS-O implant position on X-ray	Assessment Month 3	Assessment Month 6	Assessment Month 12
No damage, no migration	25	23	20
Damage, no migration	2	3	5 (20%)

Table 2. Assessment of position change using X-ray.

Our results indicated that we achieved a mean improvement of I grade in the aforementioned population according to ODI assessment during twelve months [60% (severe invalidity) and 42% (moderate invalidity) with mild progression in long-term; 38% at month three and 42% at month twelve]. Using X-ray, we diagnosed implant damage without fragment(s) migration towards the spinal canal or in the prevertebral direction in five patients (20%) after twelve months. Initially, we utilized the sole interbody fixation (stand alone technique) mainly in patients with low grade instability. We found that the clinical condition stabilized in these patients, and the postoperative imaging investigation showed good fixation of the operated segment without prosthetic damage and with adequate postoperative changes around the nerve structures (Figure 4).

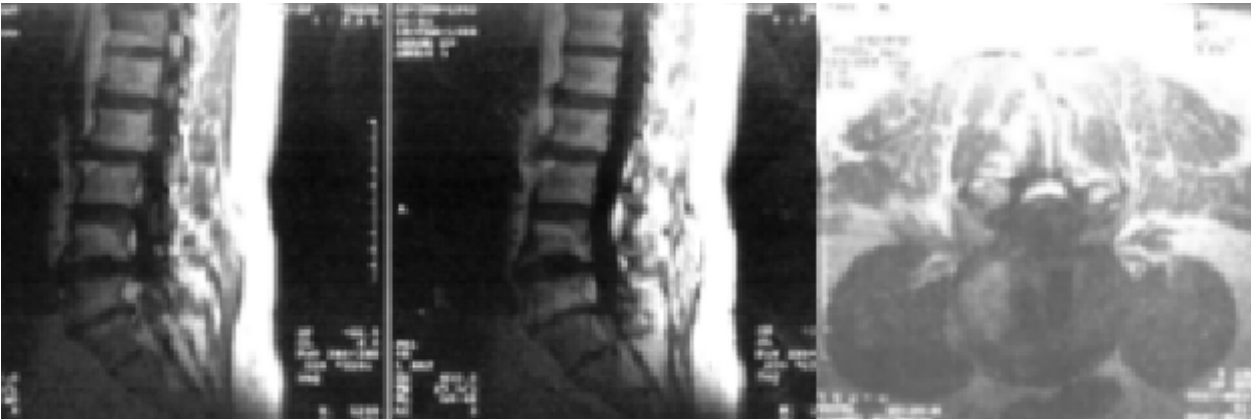

Fig. 4. MRI performed three years after operation of segment L4/5 using a pair of glass-ceramic implants (1998).

In case of 1<sup>st</sup> or 2<sup>nd</sup> grade translation as previously defined by Meyerding, we added posterior transpedicular fixation of the whole segment to the implant application. The assessments of the population showed advantages and disadvantages associated with the glass-ceramic implant. For example, the operation time was shortened, and firm anchoring in the interbody space was confirmed due to the shape and elimination of risk associated with bone graft sampling. However, the limiting factor for the universal use, in particular for application stand alone technique, was the mechanical resistance to bending at the ultimate load as well as the probable discongruence of the implant and the bone bed, especially related to shorter implants (under 10 mm). This finding was reflected by implant damage on X-ray in the clinical practice (see Table 2). Due to the relatively good results previously observed (Filip et al, 1996), we extended the stand alone technique to higher grades of translation. However, the lower mechanical resistance of the glass-ceramic to bending was observed, and damage of the implant was detected several months after the operation. This problem affected five patients following operation using this technique during twelve months. Despite implant damage, no migration towards the spinal canal or



across vertebral bodies occurred resulting from the construction with retention winglets and the chemical bond (Figure 5).

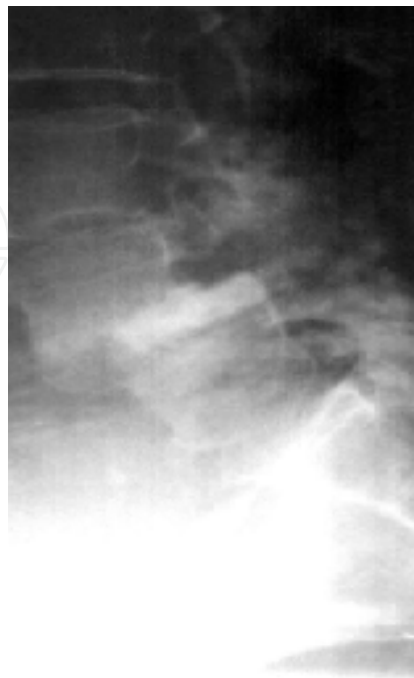

Fig. 5. Slide progression at L4/5 during overload of glass-ceramic implants in 2<sup>nd</sup> grade instability according to Meyerding.

We also added transpedicular fixation of the affected segment in case a patient experienced clinical impairment(s) due to implant damage and instability progression. We did not observe implant damage in the fixed segments in this study; however, we stopped using the stand alone technique with the glass-ceramic implant for PLIF after this experience. Unfortunately, we failed to directly demonstrate osseointegrative properties of the glass-ceramic implant BAS-0 for PLIF that was associated with fusion of the adjacent vertebral bodies by migrating bone tissue along the glass-ceramic body from 1994 to 1999.

## 2.5 Experimental development of bioactive titanium in forms by LASAK

The LASAK Company developed bioactive titanium with original surface modification at the end of the 1990s. Due to the limitations of the glass-ceramic implant mentioned above, we have been developing a new type of implant combining bioactive properties and higher mechanical resistance in cooperation with LASAK Company since 1998. Characteristics of this material (higher strength, bioactivity) have provided optimal implant characteristics for PLIF (Yan, 1997; Strnad, 2010). The material used for this implant is technically pure titanium (grade 3) which is dedicated for surgical implants (Regulation ISO 5832-2:1993(E): Implants for surgery, ISO 5835-2). To ensure bioactivity of this material, the implant surface is chemically modified by LASAK technology (Adjudication on Permission to Use a Medical Device No. 82/125/00-II B by State Institute for Drugs Control of the Ministry of Health of the Czech Republic). Mechanical properties of this material are identical to pure titanium, and its strength and fracture persistence are several times better than characteristics of the bone tissue and the glass-ceramic material (see Table 3).

	Titanium	Bone	Glass-ceramic
Compressive strength (MPa)		100-230	1080
Tensile strength, flexural strength* (MPa)	240-680	200*	170-218*
Elasticity modulus (GPa)	100-120	25	220
Fracture persistence (MPa·m <sup>-1/2</sup> )	~40-100	2-12	2

Table 3. Comparison of mechanical properties of titanium, bone and glass-ceramic BAS-0.

The mechanically and chemically modified surface of the bioactive titanium by LASAK technology is able to induce the production of calcium-phosphate (apatite), and this compound arises from the interaction between the surface of the material and body fluid within hours to days. The chemical and crystallographical properties of this mineral are nearly identical with the bone apatite. Experimental studies with bioactive and bioinert titanium demonstrated that titanium with a bioactive surface better tolerates unfavourable conditions for osseointegration, as gaps between the implant and the bone (Strnad et al, 2003). Bioinert titanium allows penetration of fibrous tissue into the interface implant/bone, and promotes instability or migration of implants towards the spinal canal in conditions requiring spondylosurgery. However, a firm interaction between the calcium-phosphate layer of the implant and the surrounding bone forms immediately after application if bioactive titanium with technological modification according to LASAK is used, which ultimately eliminates this risk.

Strength parameters and bioactivity would be expected to improve conditions for osseointegration in the intervertebral space, as compared to implants generated from bioinert materials and glass-ceramic. Therefore, this type of material appears to be optimal for the development of a new implant for PLIF. Based on our experiences with the glass-ceramic BAS-O, we designed a new implant model constructed from this material. Due to different properties of these two materials (glass-ceramic/biotitanium), we modified the shape of the implant, and we designed new application instrumentation. The basic model was the shape of skewed prism (4°) (20 mm long, 8 mm wide, with graduated high 6, 8 and 10 mm). The implant was equipped with two pairs of projections or winglets (2 mm high) on the opposite sides of the prism. The compression and bending load of our original model for PLIF was virtually mathematically tested using computer technology in cooperation with ČVUT Prague. These tests showed that the shape of the skewed prism with winglets can theoretically ensure the restoration of the anatomy of the operated segment of lumbar spine without a risk of a plunge into the adjacent vertebral bodies both during compression and flexion and without a risk of its damage (Figure 6).

Based on these mathematical analyses, we maintained the basic shape of the implant with the above mentioned parameters. The higher strength of the material allowed us to design simplified application instrumentation. We used a thread in the implant body instead of the Teflon-coated fork used in the implant BAS-O. Due to its strength, no opposite space dilatation was necessary before the application as a result of the bioactive titanium implant, and no risk of damage of the implant shape by metal loaders was detected. Therefore, the handling of the implant during an intervention is easy and safe. The shape of the implant ensured good restoration of the anatomy of the operated area (restoration of the interbody space and its stability) with minimal risk of implant plunge into the adjacent vertebral bodies, as demonstrated by imaging investigations. Other benefits of the new implant included higher strength and shape variability.

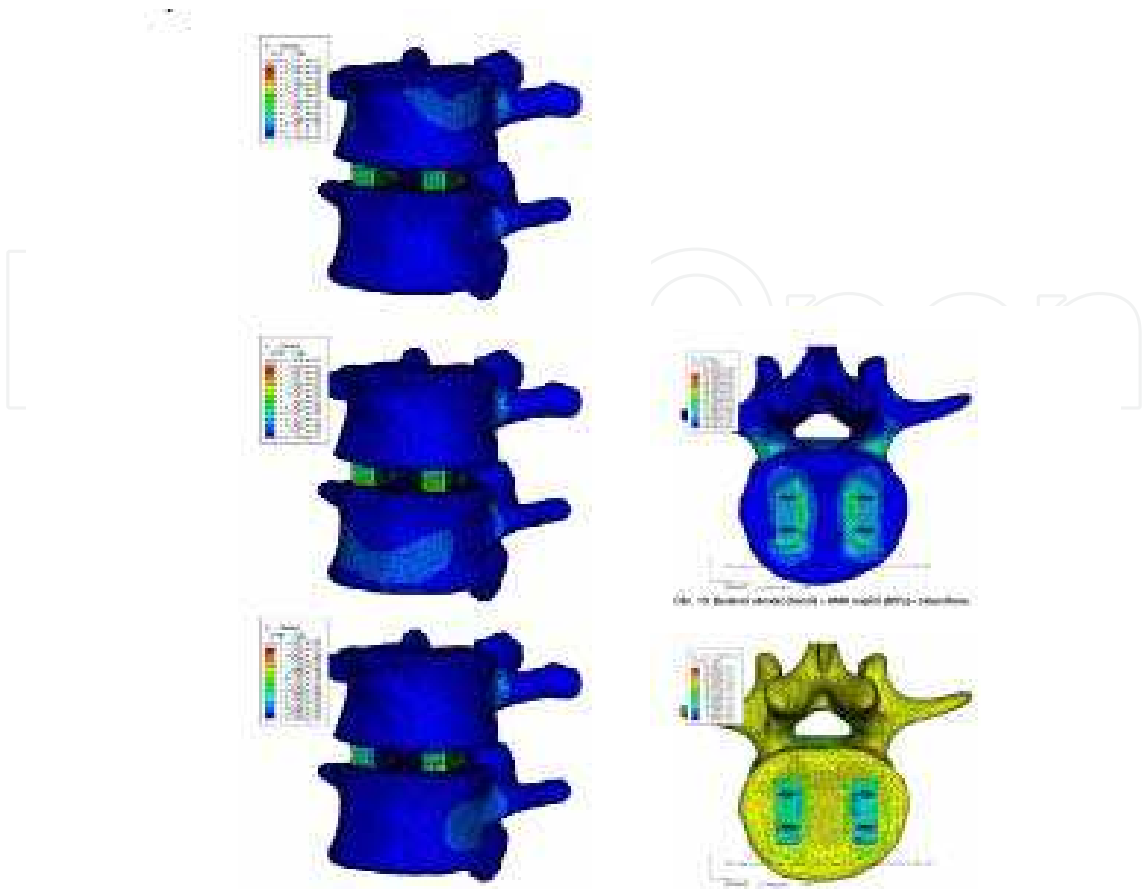


Fig. 6. Illustration of the mathematical testing of the implant model.

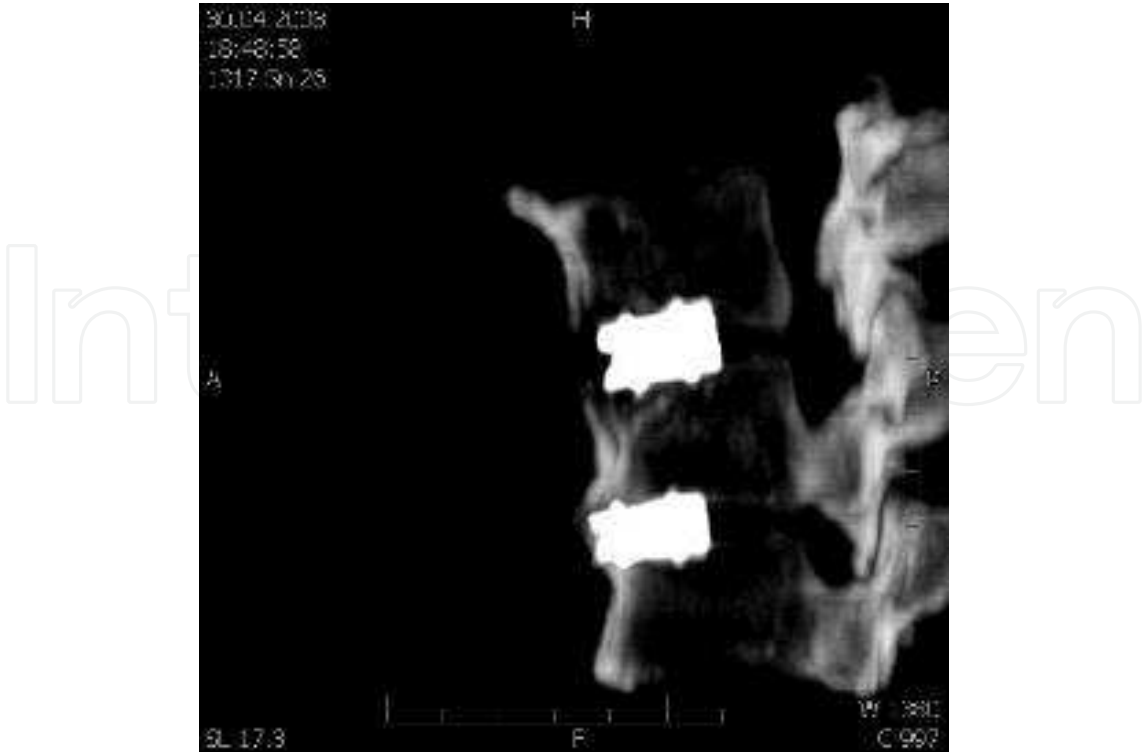

Fig. 7. Implaspin in the intersomatic space of a cadaver by CT (2001).

We removed the whole motion segment with implants from cadavers after experimental operations, and we assessed their localization and the degree of their damage by X-ray and CT scans (Filip et al, 2001). Both investigations showed proper localization of the implants in the intervertebral spaces without any contact with the spinal canal or perforation of the winglets into the adjacent vertebral bodies (figure 7).

Additionally, their shape and surface were not damaged by the new type of instrumentation. Therefore, we assumed that these findings would transfer from experimental studies into clinical practice. However, we were not able to verify the osseoconductive properties of the implant surface in the cadavers. A perfect contact was observed between the surrounding bone tissue resulting from the simple application in cadavers, which was a good precondition for supporting osseointegration in the interbody space via osteoblasts' migration along its surface. Thus, we verified the osseoconductive properties of the BIO surface of the implant in an animal model (Strnad, 2008). The implant surface in the direct contact with newly produced bone tissue yielded the following values [BIC (%) =  $48,5 \pm 2,9$ ,  $66,0 \pm 7,4$  and  $90,6 \pm 7,0$ , respectively, two, five and twelve weeks after implantation].

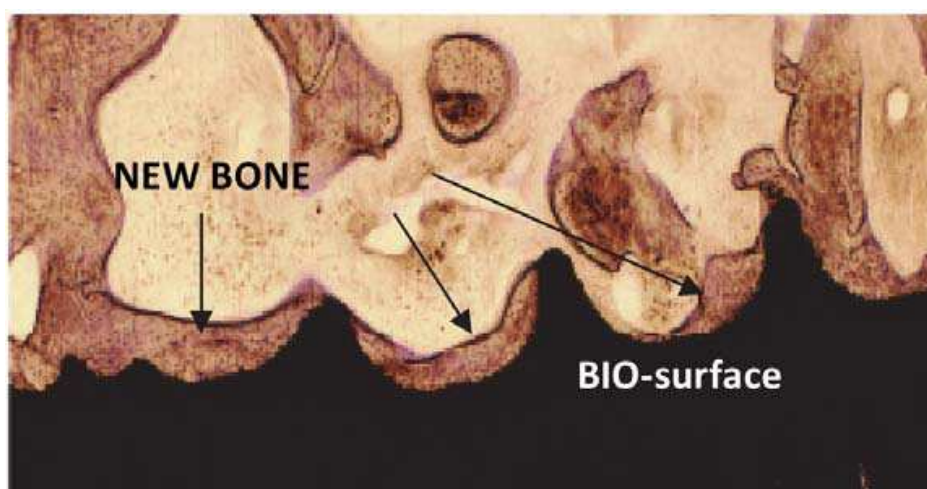


Fig. 8. Histological section of the interface of newly formed bone tissue on the BIO surface of the titanium implant twelve weeks after implantation. This figure illustrates the osseoconductive properties of the surface (optical microscope, toluidine blue staining, original magnification - 200x).

## 2.6 Implaspin in clinical practice

Encouraged by these experimental results, we began to use this type of implant in clinical practice in indications for PLIF instead of the glass-ceramic implant since 2002 (Figure 9).

The operation technique PLIF was identical to the operation technique used in cadavers (Filip et al, 2010). For example, we decompressed the nervous structures through posterior median line approach, and we then radically removed the degenerated intervertebral disc under the control of the operation microscope. Afterwards, we removed the surfaces of the adjacent vertebral bodies, and we then inserted the bioactive titanium implant using the innovated instrumentation (Figure 10). Finally, we added transpedicular fixation of the whole segment (Synthes, Signus, Easy spine, etc.) (Figure 11).




Fig. 9. Implant from bioactive titanium – Implaspin (2002).

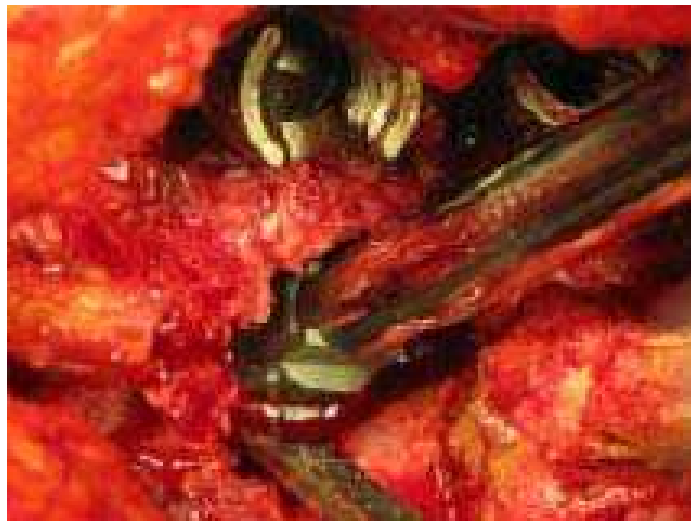

Fig. 10. Insertion of Implaspin into the interbody space.

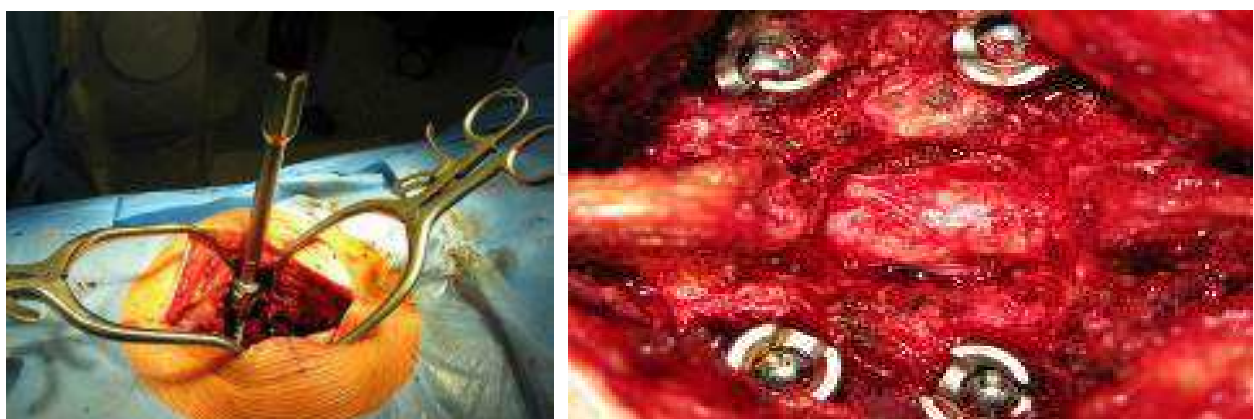

Fig. 11. Transpedicular application of screws (SIGNUS)

To date, we have not observed any complications associated with the implant application into the interbody space. According to the postoperative scans, the implant was always placed in



the correct position with winglet penetration into the spongy tissue of the adjacent vertebral bodies. We have selected the size empirically according to the extent of osteochondrosis of the affected disc and the degenerative lesions of the surrounding tissues on scans (X-ray, CT, MRI) during the intervention. In the majority of cases, we used implants (8 or 10 mm high) with angle 4° to maintain lordosis in the lumbar area (Figure 12).

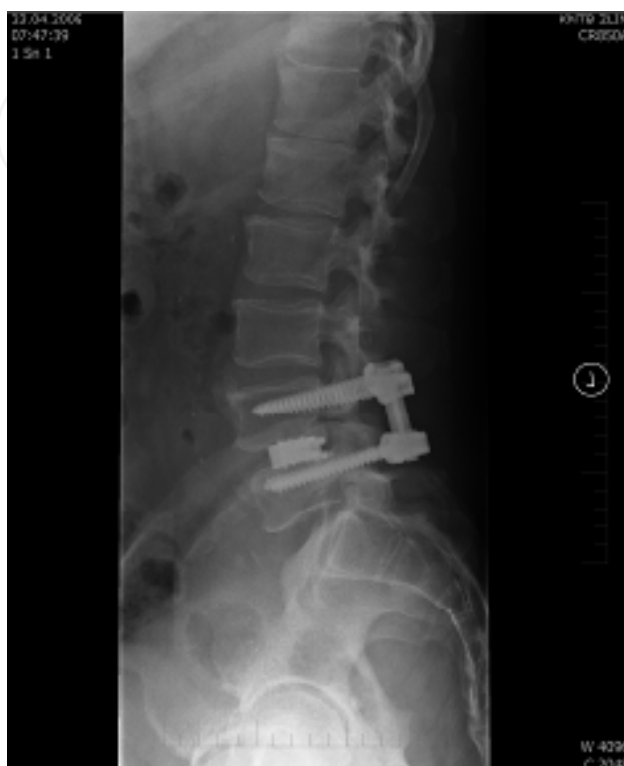

Fig. 12. Fixation L4/5 (Implaspin plus transpedicular screws Signus).

According to the experimental studies, tight contact with the surrounding bone tissue was necessary to activate the bioactivity of the surface. This contact was ensured by the shape of the implant and the winglets that penetrated into the spongy bone tissue of the adjacent vertebral bodies, and was the precondition for migration of the osteoblasts along the implant body resulting in the formation of a junction of the adjacent vertebral bodies by bone tissue without the need to sample bone grafts or to add supporting synthetic materials inside or around the implants.

In 2002 to 2007, operations were performed on 57 patients using the bioactive implant Implaspin in the Neurosurgery Clinic of the Faculty Hospital in Ostrava and in the Neurosurgery Department of Tomáš Baťa's Regional Hospital in Zlín. We assessed a population of 25 patients with follow-up examinations conducted two or more years following surgery, according to the clinical condition. The follow-ups were also based on the generally used score system ODI and imaging methods (X-ray, CT, MRI) that occurred three, six, twelve and 24 months after surgery. During the follow-ups, we examined the patients for signs of implant damage, instability of the operated segment, and signs of supposed osteoblastic activity of the bioactive surface of the implant on the scans. Results of the ODI questionnaire showed that with Implaspin, our success rate improved by 1 degree (59%–40%), or we stabilized the clinical condition of the majority of the patients long-term (2

and more years), which corresponds to results of other clinics using other implant types (Bessho et al, 1997; Brantigan et al 1993; Brayan et al, 2002; Bienik and Swiecki, 1991; Ciappetta et al, 1997; see Table 4).

ODI score in our population [%]	Mean [n] 25	FBSS [n] 9	IS [n] 6	DI [n] 10
Before surgery	59	65	55	57
3 months after surgery	42	46	40	40
6 months after surgery	40	45	37	38
12 months after surgery	41	45	39	39
24 months after surgery	40	47	35	38

Table 4. Mean Oswestry score values before surgery and at regular visits (FBSS – failed back surgery syndrome; IS – isthmic spondylolisthesis; DI – degenerative instability).

The assessment of the implant position on scans (X-ray, CT, MRI) at postoperative visits demonstrated no signs of implant damage or implant migration out of the intersomatic space. These investigations have not yet shown any signs of instability of the operated segment (i.e., formation of new osteophytes, progression of hypertrophy of the articular facets, and migration of the implant at the site of application). We observed one severe complication in the population which was caused by an inaccurate application of the transpedicular screws. The wound healed in this patient, and the neurological findings stabilized after removal of the screws. The stabilization of the condition may be supported by the implant shape and the winglets which prevented instability even after the removal of the transpedicular screws. This finding was confirmed by the imaging investigations. Based on the clinical condition and the absence of instability signs on imaging investigations, we concluded that the formation of bone fusion was due to osteoblasts’ migration along the bioactive of Implaspin surface.

2.7 Assessment of bioactivity of the implant using SPECT-CT

During our investigations, we attempted to demonstrate the migration of bone cells along the surfaces of the glass-ceramic or biotitanium implants using imaging investigations. Unfortunately, standard CT or MRI were not able to provide this precise information. The CT scans were limited by screw artefacts, and the MRI scans were generally unable to detect changes in bone. In an attempt to resolve these problems, we utilized SPECT-CT, a method that provides up-to-date computed tomography (CT) and gamma camera (SPECT), to detect the activity of the osteoblasts on the body of the titanium implant applied into the interbody space. The computed tomography (CT) can precisely display the anatomic structure of the investigated tissue, and the gamma camera investigation (SPECT) can yield a functional view of the metabolic process in the patient’s body, but without its precise localization or other anatomical details. Thereby, the combination of these investigations provided more complete information on the precise place of the metabolic process as well as its dynamics. In our study, the metabolic process included the activity of the osteoblasts on the surface of the bioactive implant, as applied by the PLIF method.

In 2009, we performed this type of investigation in four patients after surgery for the primary instability of the lower lumbar spine segment using the PLIF operation technique

with Implaspin. The study was conducted before the surgery as well as two and six months after the intervention, and we assessed the anatomical changes and metabolic activity at the location where the implants were applied by using the combined scans. The investigation provided preoperative signs of instability localized to the affected space in the area of the disc in all four patients. We detected a hyperintense signal at the operated segment two to three months after the surgery, which was a sign of osteoblast activity on the surface of the implant. We also observed a decrease of this activity (hypointense signal) six months after the surgery as well as a change on the surface of the implant using the combined CT scans.

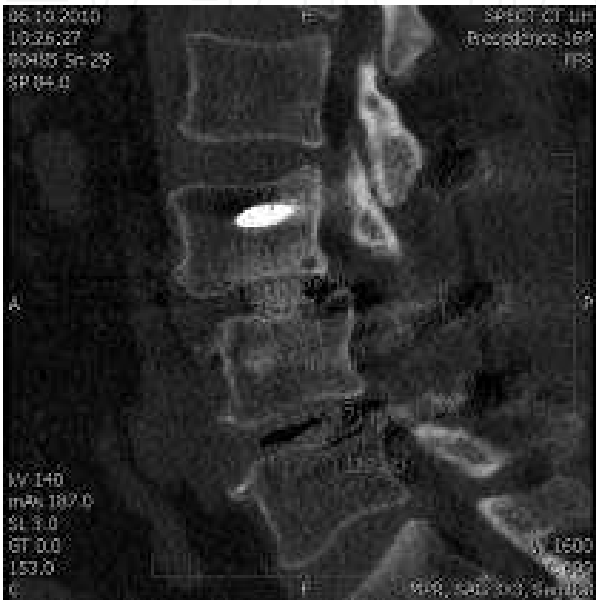

Fig. 13. Implants applied into the spaces L3/4 and L4/5 on SPECT CT. The figure shows the surface of the implant with the bone tissue (grey-black colour) and the titanium screw in the body of the L3 (white colour).

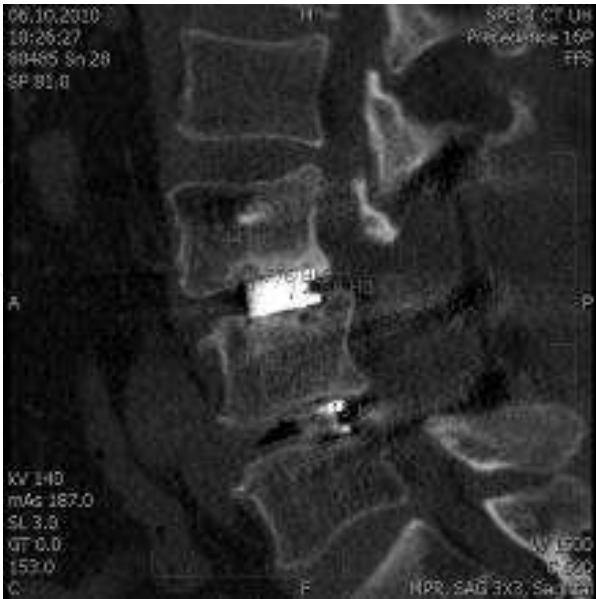


Fig. 14. Implants on a SPECT-CT scan. The bone growth at the border of bone tissue (grey) and Implaspin (white) is visible in the space L4/5.

According to our method, hypointensity signified the completion of the osteoblastic activity. The changes on the CT scans were completed by conducting a measurement using Haunsfield’s units (metal – about 2000 HU; bone tissue 100–300 HU), which provided evidence that the implant was overgrown by bone tissue. This kind of image detects the primary successful binding of the implant via activation of the osteoblasts by its specially adapted bioactive surface (figure 13 and 14). Using this combined imaging technique in all four patients, we demonstrated the migration of bone cells along Implaspin wall and the formation of fusion without the addition of another material, such as autografts or TCP, six months after the surgery. Therefore, the successful fusion was indirectly confirmed using the SPECT-CT improving the postoperative clinical findings.

3. Conclusion

The development of both the material and the shapes of implants continues to progress. Currently, the primary focus of this development is to produce an implant that forms a firm fusion as soon as possible and to ensure the formation of new bone due to its material composition. The current implants for PLIF combine two separate components, including a solid cage shape and osseoconductive material (i.e., TCP, BMP) that ensures the activity of osteoblasts and the formation of the interbody fusion. To date, none of the materials for PLIF available on the market optimally meet both characteristics (see Table 5).

Optimal parameters of the implant	Metal (Titanium, steel)	PEEK or +PEEK carbon fibres	Glass-ceramic	Resorbable implants - polylactides	Bioactive titanium (LASAK Ltd.)
1. Firm structural support (load resistance immediately after implantation)	+	+	+/-	+/-	+
2. Osseoconductivity, bioactivity – ability to bind with a bone, support of fusion without addition of other material (bone, TCP, etc.)	-	-	+	-	+
3. Possibility of radiographic assessment of the bone fusion progression	+	+	+	+	+
4. Biomechanical properties (elasticity modulus similar to bone)	-	+	-	+/-	-

Table 5. Parameters of the implant according to the type of material.

During this investigation, our goal was to develop an implant that would combine both of these components in one unit, ultimately maintaining the strength and bioactive properties present in two-component implants. At the end of the 1990s, we were close to the development

of such material due to the implant BAS-0. However, the resistance of the glass-ceramic at the ultimate load provided a limitation that negatively influenced the shape and the application process, as described in chapters 2.3 and 2.4. However, due to these experiences, we and other technicians successfully designed an implant that meets our original conception. This implant is currently used in clinical practice, and experimental studies have confirmed its supposed properties. The combination of the implant's strength and shape with bioactivity enables the smooth application and restoration of anatomy, thereby providing a perfect fixation of the operated segment and stimulating growth of osteoblasts and their migration along its surface. Our original implant Implaspin combines the osteoconductive and osteoplastic properties of the glass-ceramic with the strength of titanium, which was the aim of our research. Thanks to these properties, this implant represents a quality alternative to implants constructed from other materials dedicated to PLIF (see Table 5).

#### 4. Acknowledgement

This study was supported by the Ministry of Industry and Trade of the Czech Republic under the project number: FR-TI3/587

#### 5. References


- [1] Anderson, V. C.: A rationale for treatment algorithm of failed back surgery syndrome. *Curr Rev Pain* 2000; 4: 395-406
- [2] Alexander, J., Branch, C., Subach, B., et al.: Applications of a resorbable interbody spacer in posterior lumbar interbody fusion. *J Neurosurg (Spine)*. 2002;97:468-472
- [3] Arrington, E., Smith, W., Chambers, H., et al.: Complications of iliac crest bone graft harvesting. *Clin Orthop Rel Res*. 1996;329:300-309
- [4] Bagby, G.: Arthrodesis by the distraction-compression method using a stainless steel implant. *Orthopedics*. 1988;11:931-944
- [5] Banwart, J., Asher, M., Hassanein, R.: Iliac crest bone harvest donor site morbidity; a statistical evaluation. *Spine*. 1994;20:1055-1060
- [6] Banwart, J., Asher, M., Hassanein, R.: Iliac crest bone graft harvest donor site morbidity. *Spine*. 1995; 20:1055-1060. Sandhu H, Hs G, Parvatanemi H. Bone grafting for spinal fusions. *Orthop Clin North Am*. 1999;30:685-698
- [7] Bauer, T., Muschler, G.: Bone graft materials: an overview of the basic science. *Clin Orthop*. 2000;371:10-27
- [8] Benzel, E.: Best indications for DDD: Fusion or Non Fusion. In International symposium- Non Fusion techniques in Spinal Surgery. Bordeaux France 2003, Book of Abstracts: 140-1
- [9] Bessho, K., Iizuka, T., Murakami, K.: A bioabsorbable polt-L-lactide miniplate and screw system for osteosynthesis in oral and maxillofacial surgery. *J Oral Maxillofac Surg*. 1997;55:941-945
- [10] Bienik J, Swiecki Z. Porous and porous-compact ceramics in orthopedics. *Clin Orthop* 1991;27:88-94
- [11] Blumenthal, S.L., Baker, J., Dosset, A., Selby, D.K.: The role of anterior lumbar vision for internal disc disruption. *Spine* 1988; 13: 566-9
- [12] Brantigan, J., McAfee, P., Cunningham, B., et al.: Interbody fusion using a carbon fiber implant versus allograft bone: a investigational study in the Spanish goat. *Spine*. 1994;19:1436-1444



- [13] Brantigan, J., Steffee, A.: A carbon fiber implant to aid interbody lumbar fusion. *Spine*. 1993;18:2106-2117
- [14] Brinckmann, P, Bigemann, M., Hilweg, D.: Prediction of the Compressive Strength of Human Lumbar Vertebrae. *Clin. Biomech.*, 1989, č. 4, s. S1-S27.
- [15] Brodke, D., Dick, J.C., Kunz, D.N., McCabe, R., Zdeblick, T.A.: Posterior Lumbar Interbody Fusion: A Biomechanical comparison, Including a New Threaded Cage. *Spine* 1997; 22(1): 26-31
- [16] Bryan, B., Gerald, E., Regis, W.H., Brian, R.S., Mark, R.M.: Allograft Implants for Posterior Lumbar Interbody Fusion: Results Comparing Cylindrical Dose and Impacted Wedges. *Neurosurgery* 2002; 51(5): 1191
- [17] Carlson, L., Rostland, T., Albrektsson, B.: Implant fixation improved by close fit. *Acta Orthop. Scand.*, 59: 272-275, 1988.
- [18] Cloward R.: Gas-sterilized cadaver bone grafts for spinal fusion operations. *Spine*. 1980;5:4
- [19] Ciappetta, P., Boriani, S., Fava, G.P.: A Carbon Fiber Reinforced Polymer cage for Vertebral Body Replacement: Technical Note. *Neurosurgery*, 41: 1203-1206, 1997
- [20] Clemens, J.A.M., Klein, C.P.A.T., Sackers, R.J.B.: Healing of gaps around calcium phosphate-coated implants in trabecular bone of the goat. *J. Biomed. Mater. Res.*, 36:55-64, 1997
- [21] Cloward, R.: The Treatment of Ruptured Lumbar Intervertebral Disc by Vertebral Body Fusion. 1. *Neurosurg.*, 10, 1953, s. 154-168. Cockin, J.: Autologous bone grafting complications at the donor site. *J Bone Joint Surg Br*. 1971;53:153
- [22] Crock, H. V.: Isolated Lumbar Disc Resorption as a Cause of Nerve Root Canal Stenosis. *Clin. Orthop.*, 115, 1976, s. 109-115.
- [23] Daniaux, H.: Transpedikuläre Reposition und Spongiosplastik bei Wirbelkörperbrüchen der unteren Brust- und Lendenwirbelsäule. *Unfallchirurgie*, 89, 1986, 197-213
- [24] Dick, W.: The Fixator Interne as a Versatile Implant for Spine Surgery. *Spine*, 12, 1987, 882-900
- [25] Dove, J.: Instrumentation postérieure du rachis: Le système de Hartshill. *Rachis*, 2, 1990, s. 487-492.
- [26] Fatley T. J., Lynch, K. L., Bensen, M. D.: Tissue Response to Implants of Calcium Phosphate Ceramic in Rabbit Spine. *Clin. Orthop.*, 1979, 1983, s. 246.
- [27] Filip, M., Veselský, P., STRNAD, Z., LANÍK, P.: Replacement of an Intervertebral Disc, using a ceramic prosthesis in the treatment of degenerative diseases of the spine. *Acta Chirurgiae Orthopaedicae et Traumatologiae Czechoslovakia* 62, 1995, p. 226 - 231.
- [28] Filip, M., Veselský, P.: Treatment of instability of the lumbar spine by Glass-ceramic Prostheses of the intervertebral disc. *Acta Chirurgiae Orthopaedicae et Traumatologiae Czechoslovakia.. Acta Chir Orthop Traum Čech* 1996; 63: 83-7
- [29] Filip, M., Linzer, P., Veselský, P., Paleček, T.: Surgical technique verification by the Help of New bioactive titan cage in treatment of degenerative disease of the lumbar spine-experimental study. *Acta Chir Orthop Traum Čech* 2001; 68: 369-373
- [30] Filip M., Linzer P., Šámal F., Kremr J., Mrůzek M., Paleček T., Strnad J. : Bioactive cage implant in operation treatment of LBP. *Bolest* No.1, 25- 30, r.2010
- [31] Fischgrund, J., Mackay, M., Herkowitz, H., et al.: Degenerative lumbar spondylolisthesis with spinal stenosis: a prospective, randomized study comparing decompressive laminectomy and arthrodesis with and without spinal instrumentation. *Spine*. 1997;22:2807-2812

- [32] Gogolewski, S., Jovanovich, M., Dillon, J., et al.: Tissue response and in vivo degradation of selected polyhydroxyacids: polylactides (PLA), poly(3-hydroxybutyrate) (PHB), and poly(3-hydroxybutyrate-co-3-hydroxyvalerate) (PHB/VA). *J Biomed Mater Res.* 1993;27:1135-1148
- [33] Gurr, K. R., McAfee, P. C., Shih, C.-M.: Biochemical Analysis of Posterior Instrumentation Systems after Decompressive Laminectomy. An Unstable Calf-spine Model. *J. Bone Jt Surg.*, 70-A, June 1988, 680-691. Hamer, A., Stockley, I., Elson, R.: Changes in allograft bone irradiated at different temperatures. *J Bone Joint Surg Br.* 1999;81:342-344
- [34] Hashimoto, T., Shigenobu, K., Kanayama, M., Harada, M., Oha, F., Ohkoshi, Y., et al.: Clinical Results of Single-Level Posterior Lumbar Interbody fusion Using the Brantigan I/F Carbon Cage Filled With a Mixture of local Morselized Bone and Bioactive Ceramic Granules. *Spine* 2002; 27(3): 258-262
- [35] Hench, L.L., Splinter, R.J., Allen, W.C., Greenlee, T.K.: Bonding mechanisms at the interface of ceramic prosthetic materials. *J. Biomed. Mater. Res. Symp.*, 2: 179-149, 1971
- [36] Hrabálek, L., Rešková, I., Bučil, J., Vaverka, M., Houdek, M.: Použití titanových a PEEKových implantátů při ALIF stand-alone u degenerativního onemocnění lumbosakrální páteře - prospektivní studie. *Česká a slovenská neurologie a neurochirurgie*, 72/105 (1), 2009, 38-44
- [37] Chaloupka, R., Krbec, M., Ciencala, J., Tichý, V.: Comparison of Surgical Load in Case of 360-degree Fusion in Lumbar Vertebra Spondylolistheses Treated via Rear Instrumentation and the PLIF or ALIF Technique. *Acta spondylologica* 2003; 2: 69-72
- [38] Cho, D., Liau, W., Lee, W., et al.: Preliminary experience using a polyetheretherketone (PEEK) cage in the treatment of cervical disk disease. *Neurosurgery.* 2002;51:1343-1350
- [39] Khoo, LT., Palmer, S., Laich, DT., Fessler, RG.: Minimally invasive percutaneous posterior lumbar interbody fusion. *Neurosurgery* 2002; 51 (5 Suppl): 166-1
- [40] Knudson, R.: The Instability Associated with Disc Degeneration in the Lumbar Spine. *Acta Radiol.*, 25, 1944, s. 594-609.
- [41] Kokubo, T.: Bonding Mechanism of Bioactive Glass-ceramics A-W to Living Bone. In: *CRC. Handbook of Bioactive Ceramics, Volume I. Bioactive Glasses and Glass-Ceramics*, Yamamuro, T., Hench, L. L., Wilson, J. (eds). Boca Raton, CRC Press, 1990, 41 - 49.
- [42] Kokubo, T., Shigematsu, M., Naghashima, Y.: Apatite wollastonite-containing glass-ceramic for prosthetic application. *Bull. Inst. Chem. Res., Kyoto Univ.*, 60: 260-268, 1982
- [43] Kurz, L., Garfin, S., Booth, R.: Harvesting autogenous iliac bone: a review of complications and techniques. *Spine.* 1989;14:1324-1331
- [44] Madawi. A.A., Powell, M., Crockard, H.A.: Biocompatible osteoconductive polymer versus iliac graft. *Spine.* 21:2123-2130, 1996
- [45] McAfee, P. C.: Biochemical Approach to Instrumentation of Thoracolumbar Spine: A Review Article, *Adv. Orthop. Surg.*, 8, 1985, 313 - 327.
- [46] McAfee, P.C., Bohlmann, H.H., Ducker, T., Elsmont, F.J.: Failure of Stabilization of the Spine with Methylmethal - crylate. A Retrospective Analysis of Twenty-four Cases. *J. Bone Jt Surg.*, 68: 1145-1151, 1986
- [47] Modic, M. T., Wienstein, M. A., Pavlicek, W. et al.: Nuclear Magnetic Resonance Imaging of the Spine. *Radiology*, 148, 1983, s. 757-762.

- [48] Modic, M.T., Masaryk, T.J., Ross, J.S., Carter, J.R.: Imaging degenerative disc disease. *Radiology* 1988; 168(1): 177-186
- [49] Paleček, T., Wolný E., Veselský, P., Filip M., Drábek, P.: Náš současný přístup k chirurgické léčbě degenerativního onemocnění bederní meziobratlové ploténky. *čes. a Slov. Netrol. Neurochic*, 57/90, 1994, č. 5, s. 198-201.
- [50] Rowlings, CH.E.III.: Modern Bone Substitutes with emphasis on calcium Phosphate ceramics and osteoinductors. *Neurosurgery*, 4: 933-936, 1993
- [51] Russell, G., Hu, R., Raso, J.: Bone banking in Canada: a review. *Can J Surg.* 1989;32:231-236
- [52] Sandhu, HS.: Bone Morphogenetic Proteins and Spinal Surgery. *Spine* 2003; 28: 64-73
- [53] Sobale, K., Hansen, E.S., Rasmussen, H.: Hydroxyapatite coating enhance fixation of porous coated implants. *Acta Orthop. Scand.*, 61: 299-306, 1990
- [54] Sonntag, V. K.H., Theodore, N.: Spinal Surgery: The Past Century and the Next. *Neurosurgery*, 46: 767-778, 2000
- [55] Steffee, A.D., Sitkowski, D.J.: Posterior lumbar interbody fusion and plates. *Clin Orthop Relat Res* 1988 ; 227:99-102
- [56] Strnad Z., Role of the glass phase in bioactive glass-ceramics. *Biomaterials* Vol.13, No. 5 1992, p.317-321
- [57] Strnad J., Urban K., Povysil C., Strnad Z.: Secondary Stability Assessment of Titanium Implants with Alkali-Etched Surface: A Resonance Frequency Analysis Study in Beagle Dogs; *The International Journal of Oral & Maxillofacial Implants*, Volume 23, Number 3, 2008
- [58] Strnad J.: Způsob úpravy povrchu titanových implantátů“ Pat.č.291685 (2003)
- [59] Strnad J., Helebrant A.: Kinetics of bone-like apatite formation in simulated body fluid In: *Proc. 5th ESG Conference* (eds. Helebrant A., Kasa S., Maryška M.), pp. B2 9-16, Czech Glass Soc., Praha 1999
- [60] Thalgott, J., Giuffre, J., Klezl, Z., et al.: Anterior lumbar interbody fusion with titanium mesh cages, coralline hydroxyapatite, and demineralized bone matrix as part of a circumferential fusion. *Spine J.* 2002;2:63-69
- [61] Tullberg, T.: Failure of a carbon fiber implant: a case report. *Spine.* 1998;23:1804-1806
- [62] Urban, K., Strnad, J.: Clinical Application of the Bioactive Glass-Ceramics BAS-O in Orthopaedics, *Lékařské zprávy LF UK, Hradec Králové* 37, 1992. Vaccaro, A.R., Madigan, L.: Spinal applications of bioabsorbable implants. *J Neurosurg.* 97[Suppl 4]:407- 412, 2002
- [63] Wang, J.C., Mummaneni, P.V., Haid, R.W.: Current treatment strategies for the painful lumbar motion segment: Posterolateral fusion versus interbody fusion. *Spine* 2005;30:S33-S43
- [64] Williams, A., McNamara, R.: Potential of polyetheretherketone and carbon fiber-reinforced PEEK in medical applications. *J Mater Sci Lett.* 1987;6:188-190
- [65] Yamamuro, T.: AW Glass-Ceramic in Spinal Repair. *Bioceramics*, Vol.8,p.123, Ed.: J. Wilson, L. Henche, D. Greenspan, Ponte Verda, Florida, USA, November 1995
- [66] Yan, W.Q., Nakamura, T., Kobayashi, M., Kim, H.M., Miyaji, F., Kokubo, T.: Bonding of chemically treated titanium implant to bone. *J. Biomed Mater. Res.*, 37: 265-275, 1997
- [67] Zdeblick, T.A., Philips, F.M.: Interbody Cage Device. *Spine* 2003; 28 (15 Suppl ): S2-S7



## **Low Back Pain Pathogenesis and Treatment**

Edited by Dr. Yoshihito Sakai

ISBN 978-953-51-0338-7

Hard cover, 244 pages

**Publisher** InTech

**Published online** 14, March, 2012

**Published in print edition** March, 2012

Low back pain is a common disorder which affects the lumbar spine, and is associated with substantial morbidity for about 80% of the general population at some stages during their lives. Although low back pain usually is a self-limiting disorder that improves spontaneously over time, the etiology of low back pain is generally unknown and the diagnostic label, "non-specific low back pain", is frequently given. This book contains reviews and original articles with emphasis on pathogenesis and treatment of low back pain except for the rehabilitative aspect. Consisting of three sections, the first section of the book has a focus on pathogenesis of low back pain, while the second and third sections are on the treatment including conservative and surgical procedure, respectively.

### **How to reference**

In order to correctly reference this scholarly work, feel free to copy and paste the following:

Michal Filip, Petr Linzer and Jakub Strnad (2012). Development and Clinical Evaluation of Bioactive Implant for Interbody Fusion in the Treatment of Degenerative Lumbar Spine Disease, Low Back Pain Pathogenesis and Treatment, Dr. Yoshihito Sakai (Ed.), ISBN: 978-953-51-0338-7, InTech, Available from: <http://www.intechopen.com/books/low-back-pain-pathogenesis-and-treatment/development-and-clinical-evaluation-of-bioactive-implant-for-interbody-fusion-in-the-treatment-of-de>

**INTECH**  
open science | open minds

### **InTech Europe**

University Campus STeP Ri  
Slavka Krautzeka 83/A  
51000 Rijeka, Croatia  
Phone: +385 (51) 770 447  
Fax: +385 (51) 686 166  
[www.intechopen.com](http://www.intechopen.com)

### **InTech China**

Unit 405, Office Block, Hotel Equatorial Shanghai  
No.65, Yan An Road (West), Shanghai, 200040, China  
中国上海市延安西路65号上海国际贵都大饭店办公楼405单元  
Phone: +86-21-62489820  
Fax: +86-21-62489821

© 2012 The Author(s). Licensee IntechOpen. This is an open access article distributed under the terms of the [Creative Commons Attribution 3.0 License](https://creativecommons.org/licenses/by/3.0/), which permits unrestricted use, distribution, and reproduction in any medium, provided the original work is properly cited.

IntechOpen

IntechOpen