

# We are IntechOpen, the world's leading publisher of Open Access books Built by scientists, for scientists

6,900

Open access books available

186,000

International authors and editors

200M

Downloads

Our authors are among the

154

Countries delivered to

TOP 1%

most cited scientists

12.2%

Contributors from top 500 universities



WEB OF SCIENCE™

Selection of our books indexed in the Book Citation Index  
in Web of Science™ Core Collection (BKCI)

Interested in publishing with us?  
Contact [book.department@intechopen.com](mailto:book.department@intechopen.com)

Numbers displayed above are based on latest data collected.  
For more information visit [www.intechopen.com](http://www.intechopen.com)



# Nonfusion Techniques for Degenerative Lumbar Diseases Treatment

Leonardo Fonseca Rodrigues, Paula Voloch and Flávio Cavallari  
*Hospital São Vicente de Paulo/ Hospital Federal do Andaraí,  
 Brazil*

## 1. Introduction

Conservative treatment is the “gold standard” treatment for low back pain, in spine degenerative conditions. However, in cases where there is a failure in conservative measures, surgical treatment becomes an option (Roh et al, 2005). These procedures traditionally included decompression of spinal elements, correction of deformity and arthrodesis of the diseased spinal segment but, in some conditions, they both may be used in a combined manner (Schwarzenbach et al, 2005).

The technique of fusion with the use of only bone graft was first reported by Hibbs and Albee in 1911 (*apud in* Huang et al, 2005), for prevention of progression of Pott disease. Pioneers in using metallic instrumentation for stabilization, associated with bony fusions, were Harrington (1976) for scoliosis surgery, Roy Camille (1979) and Steffe (1986) with screw-plate system, Magerl (1984) with external fixation for fracture treatment, and Dick (1985), with the internal fixator (*apud in* Schwarzenbach et al, 2005). Since then, lumbar fusion became the “gold standard” surgical treatment for a wide range of painful conditions. The primary goal of lumbar stabilization is to treat pain from disc or facet, in the instable spinal unit. In these cases pain emerges apparently under load (Christiansen et al, 2004).

However, no surgical treatment is perfect. Christiansen and coworkers (2004) obtained positive results in approximately 70% of cases of fusion surgery. An important complication, in the medium-term follow-up, is degeneration of the disc, adjacent to a fusion segment (Rham and Hall, 1996), known as adjacent disc degeneration (ADD). In this study, ADD occurred in 30% of cases, five years after fusion. Articular hypermobility in the segment above fusion segment was reported by Luk and collaborators (1987) in 50% of cases, of which 30% had also stenosis of the spinal canal.

Another post-operative complication, related to fusion, is pseudoarthrosis, compromising the final result of the surgery (Kornblum et al, 2004). In order to achieve good results in fusion, consolidation of the bony fusion is critical (Butterman et al, 1998). However, a study of Muholland and Sengupta (2002) noted that bony consolidation, with achieved fusion segment, does not represent necessarily a clinical success.

Rham and Hall (1996), in their study, also demonstrated that, in pseudoarthrosis, micromovements in the facet joint preserves hypermobility in the adjacent segments, acting

like a “protective factor for the development of the adjacent segment degeneration”. This finding was also described in 2004 by Ghiselli and collaborators.

With all these evidences, nonfusion techniques arise, aiming the prevention of ADD, and the fact that this new technology does not require bone graft, since these techniques don't depend on bony consolidation.

### 1.1 The lumbar stability

In 1990, White and Panjabi defined instability of the spine as “the loss of the spine's ability to maintain its patterns of displacement under physiologic loads so there is no initial or additional neurologic deficit, no major deformity, and no incapacitating pain”.

The importance of lumbar stability was originally established by Kruton (1944). Morgan and King (1957) reported that instability was a primary cause of low back pain. The degenerative process of the lumbar spine was better understood after studies of Kirkaldy-Willis and coworkers (1978), and the development of the disease was described later by Kirkaldy-Willis and Farfan (1982), using a concept of three phases: 1) temporal dysfunction, 2) unstable phase, and 3) restabilization. In the last phases, 2 and 3, patients often have stenosis, or deformities, like degenerative scoliosis, often requiring surgery for stabilization, decompression and/or correction of the deformity. (**Figure 1**)

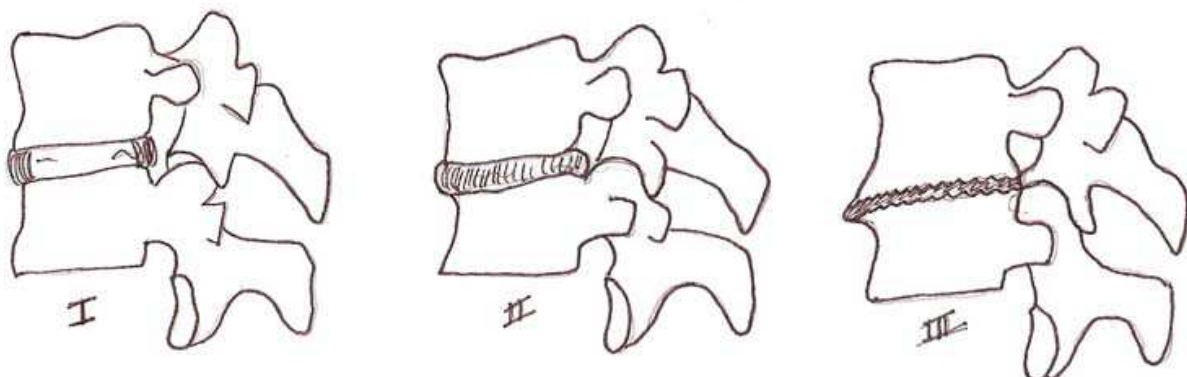


Fig. 1. The degenerative cascade described by Kirkaldy-Willis and Farfan (1982). At the third phase, the disc lost height and facet hypertrophy promotes segment stabilization, but also narrowing the neural foramen and the vertebral canal (stenosis)

The intervertebral disc plays the most important role in spine stabilization (Roh et al, 2005). Disc degeneration is a physiological process with aging. The extracellular matrix structure changes, mainly in proteoglycans concentration at the *nucleus pulposus*, leading to disc dehydration causing, because of that, morphological changes in the disc (Biyany et al, 2004). With these changes, biomechanical function of the disc is altered, and the load in this dysfunctional disc starts to injury other structures, such as the endplates, the facet joints and the fibrous annulus (Bernick et al, 1991). Additionally, these degenerative changes can cause a number of effects in the spine and nerve roots. Protrusion or disc herniation can cause radicular compression, central stenosis and considering that there are nociceptors located there, it will, as well, lead to low back pain (Roh et al, 2005).

The basic functions of the spine are: to provide stability, giving mobility to the body, to protect the spinal cord, and to control neural information in order to move the upper and lower limbs (Harms and Tabasso, 1999). For this reason, this architecture has passive elements (bones, joints and ligaments) and active elements (muscles).

Therefore, the spinal stabilizing system consists of three subsystems: spinal column, muscles surrounding the spine, and motor control unit. The spine carries load, and provides information about position, motion and loads of the spinal column (proprioception). With this information, the control unit turns it into action by the muscles (active elements), which must provide dynamic changes in the spinal column, altering the spinal posture and loads (Panjabi, 1992).

1.2 Biomechanics of the degenerated spine

Biomechanics of the spine is not simple, because it involves complex movements of flexion, lateral inclination and rotation, and the combination of all these movements. As the spine has a huge amount of spinal units, which provide the movements, its center of rotation is not static. As movement changes, the center of rotation changes as well, and so does the loading on the spine structures, having different points of axial load in the same functional unit, with focus in the intervertebral disc and facet joints (Lumsden et al, 1968). This mobility is possible due to the possibility of intervertebral disc deformation, but is limited by the disc architecture, vertebral body, and the structures in the posterior arch (Harms and Tabasso, 1999).

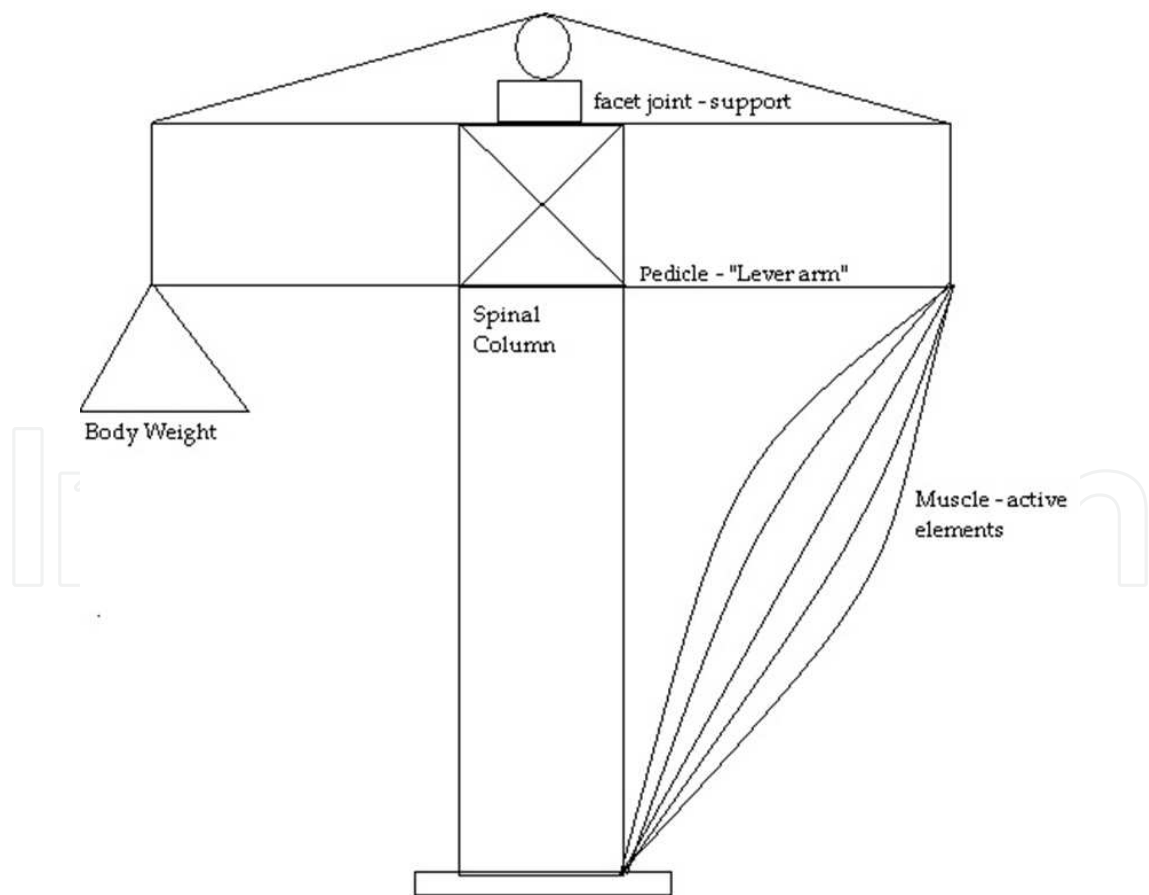


Fig. 2. The "crane", of the lumbar stability. To be stable, all the elements, active and passive, must be intact. (Adapted from Harms and Tabasso, 1999)

For Better understanding, we can imagine the spine as a crane (**Figure 2**). In standing position, the body center of gravity is located anterior to the spine, anterior to the vertebral bodies and intervertebral discs. Thus, an axial load is distributed as an axial compressive load in the anterior column, holding 80% of the axial load, and the remaining 20 % as a shear force in the posterior column (Harms and Tabasso, 1999). So, the anterior column receives loads primarily by compression forces, and the posterior column also resists stretching, torque and tilt. Due to these characteristics, the anterior column acts like a distraction device, and the posterior column as a tension band (Harms and Tabasso, 1999). The tensile forces in the posterior columns are actively made by the muscles, and supported by the facet joints and ligaments. The lever arm of this stabilization system depends on the pedicular sizes, influencing in the effectiveness of the posterior musculature (Harms and Tabasso, 1999).

The function and effectiveness of the posterior elements to provide stability depends on the integrity of the anterior column (Harms and Tabasso, 1999). Kirkaldy-Willis and Farfan described this degenerative cascade (1982), the degeneration of the disc (anterior column) causing an overload in posterior elements, thus inducing a degeneration of muscles and facet joints.

Modic (1984, 1991), using Magnetic Resonance Imaging (MRI) studies, described degenerative changes in the intervertebral disc, with overload to the endplates (**Figure 3**). Biomechanical failure on the facet joints, and muscular failure, with overload to the endplates, leads to a nociceptive pain (Kusslich et al, 1991), and the progression of the disease leads to cyst formation on the facets, hypertrophy, with narrow disc space, that can cause central or *foraminal stenosis* (Dubois et al, 1999).

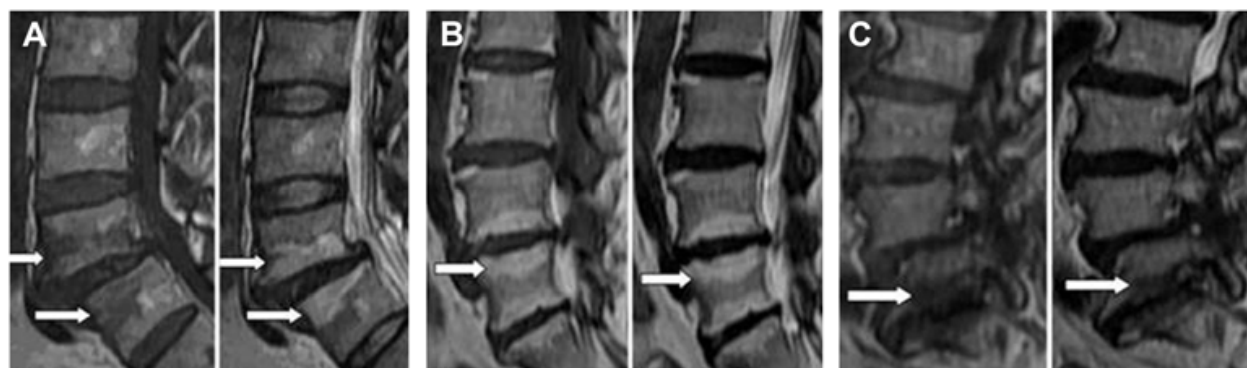

Fig. 3. The overload in the endplates, caused by disc degeneration, induces changes in the MRI. **A)** Modic type 1, the endplates are black in T1 incidence and white in 2 incidence (edema). **B)** The enplates are white in both T1 and T2 incidences (fat). **C)** The endplates are black in both incidences (sclerotic). (Adapted from Zhang et al, 2008)

Albert and Manniche (2007) demonstrated, in a randomized controlled trial with 181 patients, that Modic changes type 1 is more strongly associated with non-specific low back pain than Modic changes type 2. They also suggested in this study, that disc herniation is a strong risk factor for developing Modic changes in the same level, during the following year (Albert and Manniche 2007).



### 1.3 The adjacent segments

Over the years, the “gold standard” technique to treat severe degenerative lumbar spondylosis has been spinal fusion (Lehman et al 1987, Ko et al 2010). However, since the beginning of this use, the damaging effects of creating rigid segments in the spine, with overload to the adjacent levels (transition syndrome) have been discussed (Fymoyer et al, 1979, Stokes et al, 1981, Aota et al, 1995, Rahm et al, 1996, Christensen et al, 2004, Fritz et al, 2003, Cheh et al, 2007, Kumar et al, 2001, Wiltse et al, 1999, Miyakoshi et al, 2000, Lee et al, 1988, Min et al, 2008, Yang et al, 2008, Korovesis et al, 2009).

No surgical technique is perfect, even in this “gold standard” method, patients are subject to a number of short and long-term morbidities. The relative immobility of fused spinal segments transfers stress to adjacent segments, leading to acceleration of adjacent level degeneration, because the sagittal alignment of a fused spinal segment is fixed and cannot adapt to variations in posture (Weinhoffer et al, 1995).

A series of studies have shown, in cadavers and in vitro, that fusion increases intradiscal pressures, end plate stresses, and annular stresses at adjacent segments (Lee et al, 1984, Weinshoffer et al, 1995, Cunningham et al, 1997, Rohlman et al, 2001, Eck et al, 2002, Rao et al, 2005, Sudo et al, 2006). The restricted motion in the fused segments, in a active body, having fixed sagittal alignment, increases motion and stress at adjacent levels, in sitting, supine and erect postures (Huang et al, 2005).

This stress doesn't lead to hypermobility in the adjacent levels after fusion since degeneration progresses. Avoidance of hypermobility at the adjacent levels is frequently attributed to nonfusion technology. A few studies already reported about such an effectiveness of dynamic stabilization techniques (Olsewski et al, 1996, Phillips et al, 2002, Shono et al, 1998, Panjabi et al, 2007).

The incidence of adjacent disc degeneration is not clear. But, it has shown clinical evidence. Sears and coworkers (2011), in a retrospective cohort study, associate the risk of a new surgery for adjacent level degeneration with the number of levels fused. They concluded that, although young patients who underwent single-level fusions are at low risk, patients who underwent fusion of three or four levels had a threefold increased risk of further surgery, compared with single-level fusion, and a predicted 10-year prevalence of 40%.

Szpalski and coworkers (2002) published a comprehensive review of nonfusion implants, which comprises posterior dynamic stabilization, interspinous devices, and total lumbar disc replacement. The potential reduction of the adjacent disc disease is mainly attributed to the avoidance of increased stress at the adjacent segments. Such increased stress is anticipated in instrumented fusion procedures, leading to hypermobility at the adjacent segments. Shono and coworkers (1998) demonstrated that hypermobility at the adjacent levels was proportional to the length and rigidity of the instrumented constructs.

## 2. When is surgery necessary?

Low back pain is the first symptom of disc degeneration. The degenerate intervertebral disc is associated with structural failure, with radial failures, prolapse, endplate damage, annular protrusion, internal disc rupture, and disc space narrowing (Dubois et al, 1999, Schnake et al, 2006). Especially the discs, posterior and capsular ligaments, as well as the vertebral

endplates have been found to be the major sources of nociception leading to pain (Kusslich et al, 1991). With the progression of the disease, hydration of the nucleus pulposus decreases, and this composition alters, leading to loss of disc height and reduction of its intradiscal pressure. As described by Kirkaldy-Willis (1982), this cascade evolves, leading to overload the annulus fibrosus and the facet joints. Loading with inadequate nuclear turgor leads to shearing forces in the transitional zone between the nucleus and annulus (Huang et al, 2005). As a result, we have ruptures and radial tears in the annulus fibrosus, and overload of the facet joints. This change leads to instability. In addition to disc protrusion toward the spinal canal, disc height decreases, and there is spinal canal or neural foramen stenosis, that leads to radicular pain (Yu et al, 1988, Urban et al, 2003).

Pain from degenerative diseases may arise from stenosis, facet overload, the disc itself, and eccentrically loaded vertebral endplate. In patients with radicular pain, secondary to radicular compression, consequence to disc prolapse, surgical procedures have to be carried out, if the conservative therapy fails. However, operative treatment, like discectomy or nucleotomy, leads to progression of the disc degeneration (Dunlop et al, 1984, Gottfried et al, 1986, Brinckmann et al, 1991). In 2004, Jansson and collaborators published that approximately 10% of all operated discs reherniate and approximately 27% of all operated patients have to undergo a second operation within 10 years.

Nonsurgical management must be considered, in low back pain, especially in patients without radicular compression signs.

Stabilization devices leave the pain-generating disc tissues in situ, but restrict certain types of motion and alter load transfer through the functional spinal unit (Huang et al, 2005). Fusion implants are designed to unload the disc and facets by load sharing.

In 1954, Verbiest described the so called neurogenic intermittent claudication secondary to lumbar spine stenosis. Recent studies show that clinical or nonsurgical treatment have poor results comparing to surgical procedures (Weinstein et al, 2008). Surgical treatment based on decompression alone presented poor results, related to progression of symptoms and deformity (Hanley et al, 1995). At the same time, adding an arthrodesis to the decompression procedure increases the operative time and blood loss, and consequently the complication rate (Di Silvestre et al, 2010).

### **3. Nonfusion techniques: Advantages and disadvantages**

For many years arthrodesis has been acknowledged as the gold standard treatment for a wide variety of spinal pathologies such as deformities, unstable and painful conditions of the lumbar motion segment (Mayer et al, 2002).

Nevertheless, spinal fusion in degenerative disc disease when there is no instability or disturbed curvature, though often performed, is not a consensus among the spinal community (Greenough et al, 1994, 1998, Kozak et al, 1994, Mayer et al, 1998). In most cases, there is indication of arthrodesis when all kinds of conservative therapies fail.

However, the results seem to not always justify these decisions (Mayer et al, 2002). Fritzell and coworkers (2003) observed a 12% 2-year incidence rate of major complications following lumbar arthrodesis, with a reoperation rate of 14.6%. Complications include pseudarthrosis,

bone graft donor site pain, instrumentation failure, infection and simple failure to relieve pain (Frelinghuysen et al, 2005, Tropiano et al, 2005). Not to mention the possibility of an adjacent segment degeneration, which have made spinal surgeons think of an alternative method that could avoid such complications (Rham et al, 1996).

It's important to mention that there are increasing numbers of patients who have undergone spinal fusion for degenerative disc disease with images showing adjacent level degenerative changes, but not necessarily with a strong clinical impact. In a long term follow-up of 30 years, there was a significantly higher incidence of radiographic changes at adjacent levels after lumbar fusion, but this was not accompanied by a significant change in the functional outcomes (Kumar et al, 2001).

Non fusion technologies in spine surgery are being developed to address the arthrodesis' disadvantages (Jansen and Marchesi, 2008).

Non fusion implant types include total disc replacements, prosthetic nuclear implants, and posterior stabilization devices.

Potential advantages of nonfusion implants (Mayer et al, 2002, Huang et al, 2005):

1. Elimination of the need for bone graft.
2. Reduction in surgical morbidity
3. Elimination of pseudarthrosis
4. Reduction of adjacent level degeneration

Pseudarthrosis and the need for bone graft are truly eliminated, as well as the above mentioned reduction in surgical morbidity. Nevertheless, it is questionable whether nonfusion technologies significantly decrease the incidence of adjacent level disease, especially if segmental motion is not well maintained. Furthermore, if bone graft substitutes prove to be efficacious and economically viable alternatives to autogenous bone grafting, avoidance of autograft harvest will no longer be a significant advantage of nonfusion implants.

Potential disadvantages of nonfusion implants (Mayer et al, 2002):

1. Mechanical failure and device migration
2. Implant subsidence
3. Same level degeneration

Considering the fact that nonfusion implants are characterized by motion, therefore they are subject to mechanical failure or migration.

It is believed that subsidence is a significant contributor to poor outcomes after total disc replacements and this is probably the most significant challenge to long-term outcomes with these implants. Optimized implant design and end plate coverage may diminish the chances of subsidence happening.

The preservation of segmental motion obtained in nonfusion technology created the concept of symptomatic same level degeneration, as opposed to what is seen in a solid fusion. The possible sources of same level degeneration are the intervertebral disc, the facet joints, and the ligamentum flavum.



In conclusion, the potential pitfalls and benefits of nonfusion implants have to be carefully considered before the selection of this technology. Long-term randomized prospective studies are necessary and are currently unavailable, so non fusion procedures should be reserved for use in a small population of highly selected patients.

## 4. Total disc arthroplasty

### 4.1 Overview

Lumbar fusion has been developed for several decades and became the standard surgical treatment for symptomatic lumbar degenerative disc disease (DDD). Disc arthroplasty devices have been designed in an attempt to replace functionally the intervertebral discs, as opposed to the gold standard method (fusion) which could not achieve that (Fekete et al, 2010). Hence, a method of motion preservation would be the best alternative to spinal arthrodesis, considering that it could theoretically prevent adjacent level degeneration. However, the long-term stability, endurance and strength of the prosthesis are unknown for the majority of implants (Freeman et al, 2006).

The most important functions of the intervertebral discs are the transmission of load and the maintenance of motion and disc height. Nevertheless, none of the implants currently available can reproduce totally the kinematics of a healthy intervertebral disc (Fekete et al, 2010).

There are basically two types of disc arthroplasty devices: nucleus or total disc replacement (TDR) devices, the latter being the most frequently used.

The first total disc arthroplasty implant to be widely used was the three component SB-Charité prosthesis, a metal-polyethylene-metal construct, devised by Schellnack and Buttner-Janz in 1984. Since then, three different prototypes of the SB-Charité prosthesis have been developed. Of all the other types of total disc arthroplasty, the Pro-disc prosthesis, devised by Marnay, also in the 1980s, has been widely used (Zigler et al, 2004) (**Figure 4**).




Fig. 4. Total disc replacement in lumbar Spine: **A)** Sb-Charité, **B)** ProDisc prosthesis

Each artificial disc comprehends two or three components including two endplates and an articulating mechanism with either a metal-on-metal or metal-on-polymer surface. In order to keep the disc in place and providing stability within the host vertebral body, devices

feature different designs, such as teeth-like components called spikes or fins that are driven into the vertebral bone, a porous coated surface on the endplates, promoting bony in-growth around these structures, or are secured into the recipient vertebral body with screws (Mayer et al, 2005, Jansen and Marchesi, 2008).

Arthroplasty devices can be classified based on their biomechanical properties, as (Errico et al, 2005):

1. Constrained implant: Have mechanical restrictions in motion within the physiological range, providing a fixed center of rotation.
2. Semi-constrained implant: allows motion in the physiological range
3. Non-constrained implant: allows hypermobility in comparison to the physiological range

The healthy tri-joint complex (intervertebral disc and the two facet joints) represents a semi-constrained system that allows physiological motion and prevents abnormal (excessive) motion. This motion unit in its healthy state allows for six potential motion directions: compression, distraction, flexion, extension, lateral bending, and axial rotation (McCullen et al, 2003).

Unlike spinal fusion, artificial disc replacement (ADR) is designed to preserve motion at the target spinal level. As well as possibly providing greater pain relief, this motion preservation may potentially decrease stress on and mobility of the adjacent segment structures, factors that are thought to contribute to adjacent segment disease. ADR can also restore pre-degenerative disc height and spinal

Alignment and the benefit of not depending upon a bone graft. Other theoretical advantages include maintenance of mechanical characteristics, decreased perioperative morbidity compared with fusion, and early return to function (Fritzell et al, 2001).

## 4.2 Indications

The leading indication for total disc arthroplasty is symptomatic, degenerative, monosegmental instability of the lumbar spine between L2 and S1. The patient must be refractory to all kinds of conservative treatment, having persistent pain (intensity greater than 5 on the visual analog scale) for at least six months. Age should range preferably between 30 and 50 years old. Furthermore, there must be a correlation between imaging studies and symptoms. MRI shows degeneration of the disc, with only mild loss of height of intervertebral space. Provocative discography reproduces the patient's typical pain (Kraemer et al, 2009).

Contraindications to the implantation of disc prosthesis include: osteoporosis, infection, deformities, tumors, malformations, multisegmental degeneration and psychosocial disturbances (Kraemer et al, 2009).

## 4.3 Surgical method

Insertion of the prosthesis involves an anterior approach and is usually performed by a general surgeon and a spine surgeon. Potential problems associated with ADR may include injury to other structures (vascular, neurologic, intestinal, or urogenital), infection,

loosening, polyethylene or metal wear, loss of motion over time, impact on adjacent discs and facet joints, subsidence, implant failure, heterotopic ossification, and device related endplate fracture (Geisler et al, 2004, 2008).

#### **4.4 Clinical results**

It is still uncertain, though, whether TDR is really more effective and safer than the gold standard treatment, lumbar fusion. To systematically compare the effectiveness and safety of TDR to that of arthrodesis treating lumbar DDD, Yajun and collaborators performed a meta-analysis, which has been published in 2010. The authors observed that the group of patients submitted to TDR had slightly better functioning and less back or leg pain without clinical significance, and significantly higher satisfaction status in TDR group compared with lumbar fusion group at the 2-year follow-up. Later on, at five years follow-up, these outcomes have not shown significant differences between comparing groups. The complication and reoperation rate of two groups are similar both at two and at five years.

The authors concluded that TDR does not show significant superiority for the treatment of lumbar DDD compared with fusion. The benefits of motion preservation and the long-term complications are still unable to be concluded. More high-quality RCTs with long-term follow-up are imperative to come to new conclusions.

In a systematic review of the literature, Freeman and coworkers (2006) stated that significant facet joint osteoarthritis is a contraindication to TDR, but that could be a difficult situation to identify in its early stages.

Moreover, the future of facet joints following a total disc replacement is obscure and facet joint hypertrophy, which accelerates spinal stenosis, may be a potent long-term complication that kind of implant. Not to mention that revision procedures will unquestionably be technically difficult with a great risk of vascular injury, particularly at the L4/5 level.

Therefore, that review of the literature concluded that the use of TDR may be limited to the treatment of degenerative disc disease in its early stages, with preservation of disc height. That would limit its indications, eliminating its uses in the majority of patients.

Up until now, only few studies have examined the direct effects of disc arthroplasty on adjacent levels. These studies show contradictory conclusions. While some of them support the idea of decreased adjacent-level degeneration, although lacking a clinical significance (Huang et al, 2006) others raise concerns about the high rates of index-level facet joint arthrosis and adjacent-level degeneration, despite motion preservation (van Ooij et al, 2003, Shim et al, 2007, Siepe et al, 2007) A trustworthy analysis of these results is difficult, considering the limitations in study design as well as the differences in the kinematics of the various implants examined.

### **5. Interspinous implants**

#### **5.1 Overview**

With population aging, degenerative spine disorders became more common. The degenerative cascade, described by Kirkaldy-Willis and Farfan (1982) leads to disc and

articular changes, with disc bulging and facet hypertrophy, causing effects in the spine, such as central and/or foraminal stenosis. Verbiest (1954) described neurogenic intermittent claudication secondary to degenerative lumbar stenosis. Thus, some kind of management has to be proposed, either conservative or surgical, in order to relieve symptoms. Weinstein (2008) suggests, in his study, that surgical procedures achieve better results, compared to conservative management.

Symptoms of spinal stenosis most often occur in patients 50 to 70 years old. These symptoms include low back pain, buttock pain, and/or trochanteric and posterior thigh pain (Trautwein et al, 2010). Neurogenic claudication occurs when these symptoms exacerbate with walk, in extend position, and relieves when sitting or flexion of the spine.

A surgical treatment, for decompression and fusion of the segments, has increased operative time and blood loss, increasing complication rate in elderly patients (Carreon, et al, 2003, Deyo et al, 1993, Benz et al, 2001). To prevent complications and relief symptoms, with minimally intervention, new techniques have been developed to manage this condition.

Interspinous devices were first described in 1950, by Dr Fred L Knowles (Bono et al, 2007). But, the results are poor, with high number of devices dislodged, needing to be removed. S  n  gas (1988) described an interspinous spacer, made of titanium, with Dacron tapes to fix the devices to spinous process. He had success in the treatment of more than 300 patients. After that, other implants have been developed (Coflex, Wallis, X-stop, Diam), with another material types (Titanium, peek) (Sengupta, 2004), but follow-up studies are still running to access its efficiency, and precise its indications (**Figure 5**).




Fig. 5. Interspinous distraction devices: A) Coflex, B) Diam, C) X-stop and D) Wallis.

## 5.2 Indications

The interspinous distraction devices, keep the segment in flexion. In this condition, the device reduces loading to the intervertebral disc, and also reduces spinal and foraminal stenosis (Sengupta et al, 2004). For this reason, this procedure is indicated in patients in whom the symptoms are increased in extension (Gunzburg et al, 2003). For better results, it is indicated for patients aged 50 years or older, with moderately impaired physical function related to neurogenic intermittent claudication, and may be implanted at one or two lumbar levels (Yi et al, 2010). Better results are related to pain relief in lumbar flexion, with or without low back pain, and failure of nonsurgical care (Laurysen et al, 2007). The Wallis mechanism to treat low back pain, caused by degenerative instability, is indicated for: Massive disc herniation, with substantial loss of disc material, reherniated disc with second

discectomy, disc herniation in traditional level, like sacralization of L5, adjacent segment degeneration, to previous fusion, and isolated Modic I lesion, that leads to chronic low back pain. (Sengupta et al, 2004). Contraindications include: Disc degeneration grade V of Pfirrmann classification, spondilolisthesis, severe osteoporosis, spinal anatomy that would prevent implantation or cause instability, cauda equine syndrome and active systemic infection or localized infection at the site of implantation (Yi et al, 2010).

### 5.3 Surgical method

The X-stop device was developed to a minimally invasive approach, with short time surgery, to prevent complications in the elderly patients (Sengupta et al, 2004). For the procedure, patient must be placed in prone or lateral decubitus. They are positioned in flexed position, to keep distraction between the spinous process of the vertebral segment that will be treated. With a 4-5cm midline incision, the spinous processes are approached at the appropriate disc level, which is confirmed radiographically (Zucherman et al, 2004). The supraspinous ligament has to be maintained, to prevent kyphosis and stabilize the implant (Yi, et al, 2010, Zucherman et al, 2007). The distractor is placed through the interspinous ligament, after distraction, to maintain flexion of the segment. The spinal canal is not violated, with no need of laminectomy, laminotomy or foraminotomy.

The Wallis device must be placed with local or general anesthesia. Patient is placed in a prone position, in neutral. A neutral position of physiological lumbar lordosis is best to optimize the effect of the implant. All efforts should be made to avoid subsequent lumbar kyphosis (Sénégas et al, 1988). The supraspinous ligament must be retained, to prevent kyphosis, and stabilize the segment. The procedure itself takes less than 15 minutes (Sénégas et al, 2008).

### 5.4 Clinical results

Some studies have shown that surgical procedure, using X-stop device for chronic low back pain, substantially superior to conservative treatment, when is related to 1 or 2 level spinal stenosis, in cases where pain is relieved with flexion. These clinical results are based in a 2 years follow-up with claudication Questionnaire criteria (Zucherman, et al, 2004, 2005, Hsu et al, 2006, Anderson et al, 2006).

Comparing patients who received X-stop implants, with patients who underwent laminectomy without fusion (decompression surgery), Kondrashov et al (2007) have shown, in their study, an improvement of 15 points in the Oswestry Disability Index, defining patient success (78% of the X STOP group, versus only 33% of the laminectomy group, had successful outcomes at 4 years follow-up).

Biomechanical studies have shown beneficial effects of X-stop in kinematics of the spine (Kabir et al, 2010), with limitation in flexion/extension movement in the instrumentated level, increase in spinal canal and neural foramen, decrease in intradiscal pressure, decrease facet overload, no degenerative affection in adjacent levels, and no significant changes in biomechanics of the segment. Kutcha et al (2009) indicated, after Oswestry scores and Visual analogic scale evaluation, that X-stop implantation provides short and long term satisfactory clinical outcomes. However, some cases with severe stenosis and claudication have insatisfactory results with these implants.



Barbagallo and coworkers (2009) looked into the complications of X-STOP. Of a total of 69 patients, 8 had complications (1 intraoperative and 7 postoperative). These included 4 device dislocations and 4 spinous process fractures, one of this peroperative, in a double-level implant. Of these, 7 patients (10.14%) required revision surgery. Korovessis and coworkers (2009), in a prospective controlled study, concluded that Wallis interspinous implant changed the natural history of adjacent disc degeneration incidence until up to 5 years after surgery. S  n  gas and coworkers (2009), in a 13 year follow up study with 107 patients, with canal stenosis or herniated disc, who underwent dynamic stabilization with Wallis, reported that the implants had to be removed in 20 patients, leading to fusion. The other 87 with Wallis had better clinical results in a retrospective evaluation, compared to fusion group. Floman and coworkers (2007), in a retrospective study with 37 patients who underwent primary lumbar disc excision and stabilization with Wallis, have shown 13% of recurrent herniations, suggesting that this implant does not reduce the incidence of recurrent herniations.

Trautwein and coworkers (2010), evaluated Coflex device (interspinous U shaped titanium alloy process), and concluded that fatigue failure of the spinal process and lamina is extremely rare. Kong and coworkers (2007), in a retrospective study, compared clinical results of patients who underwent lumbar decompression surgery, with Coflex placement, with patient who underwent posterior lumbar interbody fusion (PLIF). They assumed that Coflex leads to a lower stress in adjacent levels than PLIF.

## 6. Pedicular stabilization

### 6.1 Overview

To reduce pain and disability, spine surgical procedures have three main components: decompression, stabilization and correction of deformity (Schwarzenbach et al, 2005). For many years, spine fusion of the affected segments has been the gold standard procedure for this treatment. However, patients undergoing arthrodesis are subjected to a large number of short and long-term morbidities (Huang et al, 2005).

Considering the concepts of spinal instability, defined by Junghanns (1968), Kirkaldy-Willis and Farfan (1982), and White and Panjabi (1990), and the history of instrumentation in the spine, stabilization methods must diminish pathologic motion, prevent deformity, reduce deformity and compensate iatrogenic destabilization (Schwarzenbach et al, 2005).

Dynamic stabilization with pedicular screws has been developed, as an alternative to fusion, to achieve segmental stabilization, without complications seen in fusion (Di Silvestre et al, 2010).

Henry Graf (1992) first described the system of pedicular screws, surrounded by nonelastic polyester ligament with tension to lock the motion segment in extension. This concept was to lock the facet joints, stopping rotation (Sengupta et al, 2004). This system presented some problems, because the lordosis that the Graf produces results in stenosis of lateral recess, especially if there was any preexisting facet arthropathy or in-folding of the *ligamentum flavum*, and increases load in posterior annulus, which is a feature of painful degeneration of the disc (Grevitt et al, 1995).

In 1994, Dubois proposed the Dynesys system, a pedicular screw-based system, with flexible rods as a dynamic stabilization. Based on Kirkaldy-Willis concept of degeneration, Dynesys attempts to alter the first and second phases, reducing segmental motion to a physiologic level, neutralizing bending, torsional, and shear forces, thus reducing load on disc (Schwarzenbach et al, 2005)(Figure 6).

Stremmel and coworkers (2000) introduced a pedicular based stabilization system, with rigid rods and hinged head screws. With this architecture, a division of the load between implant and anterior column is achieved. Screws are made of titanium alloy and, since 2002, are covered by hydroxyapatite for better bone ingrowths (Figure 6).

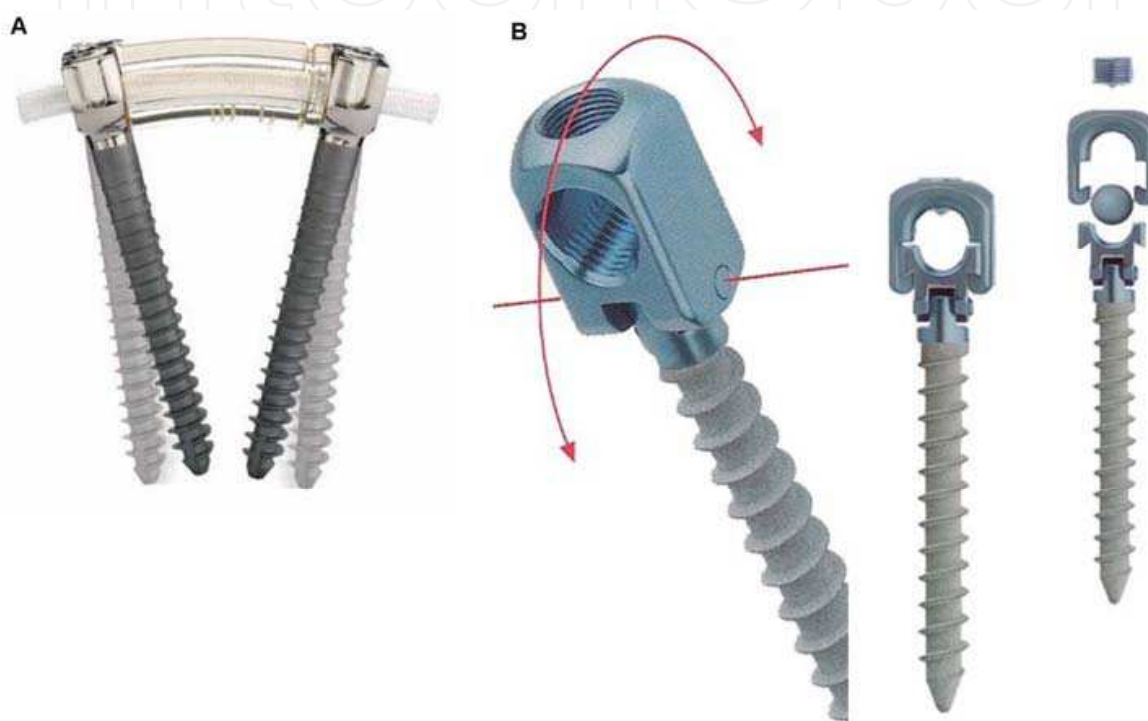


Fig. 6. Pedicular stabilization devices: **A)** Dynesys – dynamic in the flexible rod, **B)** cosmic: Hinged head screws

## 6.2 Indications

In instability, dynamic devices are indicated in some conditions, based on their design and biomechanical effects (Schwarzenbach et al, 2005). The main goal of Dynesys is to stabilize the degenerated segments in early stages of degeneration, defined by Kirkaldy-Willis (1982). Ko and coworkers (2010) presented a study with patients who underwent dynamic stabilization with Dynesys. These patients had symptomatic low back pain, as result of degenerative spondylolisthesis, radiculopathy, or neurogenic claudication and they failed to respond to conservative treatment.

Stremmel and coworkers (2000) said that cosmic system may possibly relieve pain as well as restore the neurologic function without correction. Fusion is necessary when corrections (mostly in the sagittal plane) are necessary to treat pain. With limitation, this system won't be used when there's a need to treat more than three segments of the spine. Indications for cosmic are: Symptomatic lumbar stenosis, chronically recurring low back pain in the case of

discogenic pain and facet syndrome, recurrent disc herniation, combination with a spondylodesis, and extension of an existing spondylodesis in the case of a painful adjacent level degeneration (the last 2 indications are hybrid constructions).

Di Silvestre (2010) consider to use dynamic stabilization system with Dynesys to treat lumbar degenerative scoliosis in the elderly, as an alternative to fusion methods, in order to decrease blood loss (there is no need to decortications of the facets and transverse processes), eliminate need of bone graft, and thus decreasing operative time.

### 6.3 Surgical method

Patients were treated under general anesthesia, in prone position (Di Silvestre et al, 2010, Ko et al. 2010, Maleci et al, 2011). Medial unique incision must be made, but Wiltse intermuscular plane approach is an option in stabilization procedures without wide decompression (Wiltse et al, 1988, von Strempel, 2000). In cases of stenosis, using Dynesys stabilization, and needing wide laminectomy, patients are positioned with hips flexed in 90 degrees and, after decompression, patients are repositioned to maximum lordosis (Di Silvestre et al 2010).

Pedicular screws are placed, by fluoroscopic control, in a lateral point entry, at the basis of transverse process with convergence angle between 13 and 18° in Dynesys (Di Silvestre et al, 2010), and between 20 and 25° in cosmic (Strempel et al, 2000) horizontal to the sagittal plane. The screws must be as long as possible to prevent shear forces. Removing and reinserting of the screws must be avoided, to prevent screw loosening (Di Silvestre et al, 2010, Strempel et al, 2000).

After screw placement, distraction must be taken up to 4mm in cosmic system (Maleci et al, 2011), and 2mm in Dynesys system, to expand the neural foramina. In cosmic system, when decompression is necessary, a transverse stabilizer must be placed (Maleci et al, 2011).

### 6.4 Clinical results

Nonfusion techniques have been developed to prevent complications seen in spinal fusion, as adjacent segment disease (Cakir et al, 2009). Additionally, fusion involves longer operative time and blood loss, increasing the complication rate, mainly in elderly (Di Silvestre et al, 2010). Not to mention the need of bone graft, with potencial effects on donor site (Huang et al, 2005).

Graf ligamentoplasty has been often unsatisfactory, not preventing postoperative instability, with high percentage of destabilization of the affected segment (Guigui et al, 1994). This system presented some problems, because the lordosis that the Graf produces results in stenosis of lateral recess, especially if there was any preexisting facet arthropathy or infolding of the ligamentum flavum, and increases load in posterior annulus, which is a feature of painful degeneration of the disc (Grevitt et al, 1995). Kanayama and coworkers (2005) showed poor clinical outcomes with Graf.

Di Silvestre (2010) evaluated clinical results after dynamic stabilization with Dynesys in elderly patients with lumbar degenerative scoliosis, with questionnaires (oswestry disability index, Roland Morris, and visual analog scale), and radiologic imaging. In this study,

clinical results have shown nonfusion stabilization as a safe procedure in elderly patients, with low complication rate, and statistically significant improvement in clinical outcomes.

Cakir and coworkers (2009), compared patients who underwent surgical treatment with decompression and Dynesys or decompression and fusion, having concluded that, in monosegmental instrumentation, no differences in adjacent level have been found, in a minimum follow-up of 24 months.

In 2006, Schanke and coworkers found signs of degeneration in disc adjacent to Dynesys stabilization in 29% of discs after 2 years. In the same follow-up period, the authors reported complications in 17% of patients, with 4 loosen screws and 1 broken screw out of 96 screws. This proportion was maintained in a continuous follow up, after 2 years, and no progression of instability has been shown (Schaeren et al, 2008). Screw loosening was assessed by Ko and coworkers (2010). Seventy one patients, who underwent decompression and stabilization with Dynesys were evaluated. Loosening of the screws occurred in 19,7% of patients, but this did not affect their clinical improvement. It is interesting to note that such findings had never occurred in the middle vertebrae in intermediary level. It's more likely to occur on marginal segments.

Treatment of the dysfunctional segmental motion was assessed by Cansever and coworkers (2011), using radiologic parameters in postoperative time, in one year follow-up. Their results suggest that decompression with dynamic stabilization were effective for radiologic stability over time.

A recent article described nonfusion method in lumbar spinal fractures (Kim et al, 2011). In a 4 year follow-up (2002 - 2006), their results suggests that this method is one of the most effective to manage thoracolumbar fractures, especially in younger people.

Clinical results published with cosmic system, shows improvement in quality of life after dynamic stabilization, with decrease in visual analog scale of pain (Rodrigues et al. 2010, Strempel et al, 2006, Strempel et al, 2008). As complications, screw loosening was found in 5,2% and 5,03% cases, and just 1 case of adjacent disc degeneration was related. Screw breakage occurred in a low rate, but not all of them were symptomatic.

Rodrigues and coworkers (2010), in a retrospective evaluation of patients submitted to a pedicular dynamic stabilization with cosmic, showed an improvement in quality of life of these patients during the 29,5 months follow-up period. The SF-36 score ranging from 33.15% preoperatively, to 75.99% in the postoperative, was statistically significant using the *student t test* ( $p < 0,0001$ ). Maleci and coworkers (2011), using cosmic system, in a 2 year follow up period, showed good results, with a low complication rate. In this article, they emphasized advantages, such as reduction in surgical trauma, avoidance of complication in graft donor site, and preservation of intervertebral cartilage. No spontaneous fusion has been observed in the follow-up, but a fibrous rigidity has been present.

## 7. Conclusion

Nonfusion techniques are new, compared to fusion, as an option in the surgical treatment for low back pain. As new techniques, long-term prospective studies must be designed to achieve their effectiveness.



The effects of fusion are well known in a long term analysis, with a large number of complications. Adjacent disc degeneration, donor site pain, pseudoarthrosis and high blood loss are aspects that must be avoided with nonfusion technologies.

The right indication is the most important key to the success of the surgical treatment. Up to now, good results have been shown with nonfusion surgeries, and these technologies are improving, to avoid complications, and preserve the physiological motion of the spine.

Long-term Follow-up studies must be taken, to a better understanding of these procedures, and indications in a large scale. But, the results obtained up to now are encouraging and hopeful.

## 8. Acknowledgment

The authors thank Tania Spohr, PhD, for her suggestions regarding the chapter.

*In memoriam* to Jorge Luiz Santana Rodrigues.

## 9. References

- Albert H B, Manniche C. (2007). Modic changes following lumbar disc herniation. *Eur Spine J*, vol 16, No7 (mar 2007), pp.(977-982), ISSN: 0940-6719
- Anderson PA, Tribus CB, Kitchel SH. (2006). Treatment of neurogenic claudication by interspinous decompression: application of the X STOP device in patients with lumbar degenerative spondylolisthesis. *J Neurosurg Spine*, vol 4, No 6 (Jun 2006), pp. (463–471), ISSN 1547-5654
- Aota Y, Kumano K, Hirabayashi S. (1995). Postfusion instability at the adjacent segments after rigid pedicle screw fixation for degenerative lumbar spinal disorders. *J Spinal Disord*, vol 8, No 6 (Dec 1995), pp. (464–473), ISSN: 1536-0652
- Barbagallo GM, Olindo G, Corbino L, et al. (2009). Analysis of complications in patients treated with the X-Stop Interspinous Process Decompression System: proposal for a novel anatomic scoring system for patient selection and review of the literature. *Neurosurgery*, vol 65, No 1 (Jul 2009), pp. (111–119), ISSN: 0148-396X
- Benz RJ, Ibrahim ZG, Afshar P, et al. (2001). Predicting complications in elderly patients undergoing lumbar decompression. *Clin Orthop Relat Res*, vol 384 (Mar 2001), pp. (116-121), ISSN 0009-921X
- Bernick S, Walker JM, Paule WJ. (1991). Age changes to the anulus fibrosus in human intervertebral discs. *Spine*, vol 16, No 5 (May 1991), pp. (520-524) ISSN: 0362-2436
- Biyani A, Amendersoon GB. (2004). Low Back Pain: Pathophysiology and management. *J Am Acad Orthop Surg*. vol 12, (2004), pp. (106-115). ISSN: 1067-151X
- Bonno CM, Vaccaro AR. (2007). Interspinous Process devices in the lumbar spine. *J Spine Disord Tech*, vol 20, No 3 (May 2007), pp. (255-261), ISSN: 15360652
- Brinckmann P, Grootenboer H (1991) Change of disc height radial, disc bulge, and intradiscal pressure from discectomy. An in vitro investigation on human lumbar discs. *Spine*, vol 16, No 6 (Jun 1991), pp. (641-646), ISSN 0362-2436
- Buttermann GR, Garvey TA, Hunt AF, et al. (1998) Lumbar fusion results related to diagnosis. *Spine*, vol 23, No 1 (Jan 1998), pp. (116-127), ISSN: 0362-2436



- Buttner-Janz K, Schellnack K, Zippel H (1987). An alternative treatment strategy in lumbar intervertebral disk damage using an SB Charite modular type intervertebral disk endoprosthesis. *Z Orthop Ihre Grenzgeb* vol 125, No 1 (jan-feb 1987), pp. (1-6), ISSN: 0044-3220
- Cakir B, Carazzo C, Schmidt R et al. (2009) Adjacent segment mobility after rigid and semirigid instrumentation of the lumbar spine. *Spine*, vol. 34, No 12 (May 2009), pp.(1287-1291), ISSN 0362-2436
- Cansever T, Civelek E, Kabatas S, et al. (2011) Dysfunctional segmental motion treated with dynamic stabilization in the lumbar spine. *World Neurosurg*, vol. 75, No 5 (May-Jun 2011), pp. (743-749), ISSN 1878-8750
- Carreon LY, Puno RM, Dimar JR, et al. (2003). Perioperative complications of posterior lumbar decompression and arthrodesis in older adults. *J Bone Joint Surg Am*, vol .85A, No11 (Nov 2003), pp. (2089-2092), ISSN 0021-9355
- Cheh G, Bridwell K, Lenke L, et al. (2007). Adjacent segment disease following lumbar/thoracolumbar fusion with pedicle screw instrumentation: a minimum 5-year follow-up. *Spine*, vol32, No 20 (Sep 2007), pp. (2253-2257), ISSN: 0362-2436
- Christensen FB. (2004). Lumbar spinal fusion. Outcome in relation to surgical methods, choice of implants and postoperative rehabilitation. *Acta Orthop Scand*, vol 75, No 313 (Oct 2004), pp. (2-43), ISSN:0001-6470
- Cunningham B, Kotani Y, McNulty P, et al. (1997). The effect of spinal destabilization and instrumentation on lumbar intradiscal pressure: an in vitro biomechanical analysis. *Spine*, vol22, No 22 (Nov 1997), pp. (2655-2663), ISSN: 0362-2436
- Deyo RA, Ciol MA, Cherkin DC, et al. (1993). Lumbar spinal fusion. A cohort study of complications, reoperations, and resource use in the Medicare population. *Spine*, vol 18, No 11 (Sep 1993), pp.(1463-1470), ISSN 0362-2436
- Di Silvestre M, Lolli F, Bakaloudis G, Parisini P. (2010). Dynamic stabilization for degenerative lumbar scoliosis in elderly patients. *Spine*, vol 35, No 2 (Jan 2010), pp. (227-234), ISSN: 0362-2436
- Dubois G, de Gernay B, Schaerer N S & Fennema P (1999). Dynamic Neutralization: A New Concept for Restabilization of the Spine. *Lumbar Segmental instability*. Lippincott Marek Szpalski, Robert Gunzbrug and Malcolm H Pope. (23) pp (233-240), Lippincott Williams & Wilkins Healthcare, ISBN 0-7817-1906-2, Philadelphia, USA
- Dunlop RB, Adams MA, Hutton WC. (1984). Disc space narrowing and the lumbar facet joints. *J Bone Joint Surg Br*, vol 66, No 5 (Nov 1984), pp.(706-710), ISSN 0301-620X
- Eck JC, Humphreys SC, Lim TH, et al. (2002). Biomechanical study on the effect of cervical spine fusion on adjacent level intradiscal pressure and segmental motion. *Spine*, vol 27, No 22 (Nov 2002), pp. (2431-2434), ISSN: 0362-2436
- Errico TJ. (2005) Lumbar disc arthroplasty. *Clin Orthop Relat Res*, vol 435 (Jun 2005), pp. (106-117), ISSN 0009-921X
- Fekete TF & Porchet F (2010). Overview of disc arthroplasty – past, present and future. *Acta Neurochir*, vol 152, No 3 (Mar 2010), pp.(393-404), ISSN: 0942-0940
- Floman Y, Millgram MA, Smorgick Y, et al. (2007). Failure of the Wallis interspinous implant to lower the incidence of recurrent lumbar disc herniations in patients

- undergoing primary disc excision. *J Spinal Disord Tech*, vol 20, No 5 (Jul 2007), pp. (337–341), ISSN: 1536-0652
- France JC, Yaszemski MJ, Lauerma WC, et al. (1999). A randomized prospective study of posterolateral lumbar fusion. Outcomes with and without pedicle screw instrumentation. *Spine*, vol 24, No 6 (Mar 1999), pp. 553-560, ISSN 0362-2436
- Freeman BJC & Davenport J (2006). Total disc replacement in the lumbar spine: a systematic review of the literature. *Eur Spine J*, vol 15 (Aug 2006) Suppl 3: (S439-447), ISSN 0940-6719
- Frelinghuysen P, Huang RC, Girardi FP, et al (2005) Lumbar total disc replacement part I: rationale, biomechanics, and implant types. *Orthop Clin North Am*, vol 36, No 3 (Jul 2005), pp. (293–299), ISSN 0030-5898
- Fritzell P, Hägg O, Nordwall A. (2003). Complications in lumbar fusion surgery for chronic low back pain: comparison of three surgical techniques used in a prospective randomized study. A report from the Swedish Lumbar Spine Study Group. *Eur Spine J*, vol 12, No 2 (Apr 2003), pp. (178–189), ISSN 0940-6719
- Fritzell P, Hagg O, Wessberg P, Nordwall A (2001) Volvo Award Winner in Clinical Studies: lumbar fusion versus nonsurgical treatment for chronic low back pain: a multicenter randomized controlled trial from the Swedish Lumbar Spine Study Group. *Spine*, vol 26, No 23 (Dec 2001), pp(2521–2532), ISSN: 0362-2436
- Frymoyer J, Hanley E, Howe J, et al. (1979). A comparison of radiographic findings in fusion and nonfusion patients ten or more years following lumbar disc surgery. *Spine*, vol 4, No 5 (Sep-Oct 1979), pp. (435–440), ISSN: 0362-2436
- Geisler FH, Blumenthal SL, Guyer RD, et al. (2004) Neurological complications of lumbar artificial disc replacement and comparison of clinical results with those related to lumbar arthrodesis in the literature: results of a multicenter, prospective, randomized investigational device exemption study of Charite intervertebral disc. Invited submission from the Joint Section Meeting on Disorders of the Spine and Peripheral Nerves. *J Neurosurg Spine*, vol 1, No 2 (Sep 2004), pp. (143–154), ISSN 1547-5654
- Geisler FH, Guyer RD, Blumenthal SL, et al. (2008) Effect of previous surgery on clinical outcome following 1-level lumbar arthroplasty. *J Neurosurg Spine*, vol 8, No 2 (Feb 2008), pp(108–114), ISSN 1547-5654
- Ghiselli G, Wang JC, Bhatia NN, et al. (2004). Adjacent segment degeneration in the lumbar spine. *J Bone Joint Surg Am*, vol 86, No 7 (Jul 2004), pp.(1497-1503), ISSN: 1535-1386
- Gottfried Y, Bradford DS, Oegema TR. (1986). Facet joint changes after chemonucleolysis-induced disc space narrowing. *Spine*, vol 11, No 9 (Nov 1986), pp.(944-950), ISSN 0362-2436
- Graf H. (1992). Lumbar instability: surgical treatment without fusion. *Rachis*, vol 412, pp.(123–137)
- Greenough CG, Peterson MD, Hadlow S, et al. (1998) Instrumented posterolateral lumbar fusion. Results and comparison with anterior interbody fusion. *Spine*, vol 23, No 4 (Feb 1998), pp.(479–486), ISSN: 0362-2436

- Greenough CG, Taylor LJ, Fraser RD (1994) Anterior lumbar fusion: results, assessment techniques and prognostic factors. *Eur Spine J*, vol 3, No 4 (1994), pp. (225-223), ISSN 0940-6719
- Grevitt MP, Gardner AD, Spilsbury J, et al. (1995) The Graf stabilisation system: early results in 50 patients. *Eur Spine J*, vol 4, no 3 (1995), pp.(169-175), ISSN: 0940-6719
- Guigui P, Chopin D. (1994). Assessment of the use of the Graf ligamentoplasty in the surgical treatment of lumbar spinal stenosis: a propos of a series of 26 patients. *Rev Chir Orthop Reparatrice Appar Mot*, vol 80, No 8 (1994), pp.(681-688), ISSN 0035-1040
- Gunzburg R, Szpalski M. (2003). The conservative surgical treatment of lumbar spinal stenosis in the elderly. *Eur Spine J*, vol 12, No 2 (Oct 2003), pp. (S176-180), ISSN0940-6719
- Hanley EN Jr. (1995). The indications for lumbar spinal fusion with and without instrumentation. *Spine*, vol 20, No 24 (Dec 1995), pp. (143S-153S), ISSN 0362-2436
- Harms, J. and Tabasso, G (1999) *Instrumented Spinal Surgery*. by Georg Thieme Verlag, ISBN 85-86703-05-2. Germany
- Hsu KY, Zucherman JF, Hartjen CA, et al. (2006). Quality of life of lumbar stenosis- treated patients in whom the X STOP interspinous device was implanted. *J Neurosurg Spine*, vol 5, No 6 (Dec 2006), pp. (500-507), ISSN 1547-5654
- Huang RC, Girardi FP, Lim MR, et al. (2005). Advantages and disadvantages of Nonfusion Technology in Spine Surgery. *Orthop Clin North Am*, vol 36, No 3 (Jul 2005), pp. (263-269), ISSN 0030-5898
- Huang RC, Tropiano P, Marnay T, et al. (2006) Range of motion and adjacent level degeneration after lumbar total disc replacement. *Spine J*, vol 6, No 3 (May-Jun 2006), pp. (242-247) ISSN: 1529-9430
- Jansen ME, Marchesi DG. AO (2008) Evidence-based spine surgery. Special edition total disc replacement. *Lumbar spine*.vol.4 No .3.pp (6-12)
- Jansson KA, Nemeth G, Granath F, et al. (2004). Surgery for herniation of a lumbar disc in Sweden between 1987 and 1999 an analysis of 27,576 operations. *J Bone Joint Surg Br*, vol 86, No 6 (Aug 2004), pp. (841-847),ISSN 0301-620X
- Junghanns H, Schmoral G. (1968). Die gesunde und die kranke Wirbelsäule in Röntgenbild und Klinik. Thieme, 556 pages
- Kabir SM, Gupta SR, Casey AT. (2010). Lumbar interspinous spacers: a systematic review of clinical and biomechanical evidence. *Spine*, vol 35, No 25 (Dec 2010), pp. (E1499-506), ISSN 0362-2436
- Kanayama M, Hashimoto T, Shigenobu K, et al. (2005). Non-fusion surgery for degenerative spondylolisthesis using artificial ligament stabilization: surgical indication and clinical results. *Spine*, vol 30, No 5 (Mar 2005), pp. (588-592), ISSN 0362-2436
- Kim YM, Kim DS, Choi ES, et al. (2011). Nonfusion method in thoracolumbar and lumbar spinal fractures. *Spine*, vol 36, No 2 (Jan 2011), pp. (170-176), ISSN 0362-2436
- Kirkaldy-Willis WH, Farfan HF (1982). Instability of the lumbar spine. *Clin Orthop Relat Res*, vol 165, pp(110-123), ISSN 0009-921X
- Kirkaldy-Willis WH, Wedge JH, Yong-Hing K, et al. (1978). Pathology and pathogenesis of lumbar spondylosis and stenosis. *Spine*, vol 3, No 4 (Dec 1978), pp.(319-328), ISSN: 0362-2436

- Ko C. C. Tsai HW, Huang WC, et al. (2010) Screw loosening in the Dynesys stabilization system: radiographic evidence and effect on outcomes. *Neurosurg Focus*, vol 28, No 6 (June 2010), pp. (E10), ISSN 1092-0684
- Kondrashov DG, Hannibal M, Hsu KY, et al (2007). X STOP versus decompression for neurogenic claudication: Economic and clinical analysis. *The Internet J Minimally Invasive Spinal Technology* . Vol 1. No 2. (2007) ISSN: 1937-8254
- Kong DS, Kim ES, Eoh W. (2007). One-year outcome evaluation after interspinous implantation for degenerative spinal stenosis with segmental instability. *J Korean Med Sci*, vol 22 No 2 (Apr 2007), pp. (330-335), ISSN 1011-8934
- Kornblum MB, Fischgrund JS, Herkowitz HN, et al. (2004) Degenerative lumbar spondylolisthesis with spinal stenosis: a prospective long-term study comparing fusion and pseudarthrosis. *Spine*, vol 29, No 7 (Apr 2004), pp. (726-733), ISSN: 0362-2436
- Korovessis P, Repantis T, Zacharatos S, et al.(2009). Does Wallis implant reduce adjacent segment degeneration above lumbosacral instrumented fusion? *Eur Spine J*, vol 18, No 6 (Jun 2009), pp. (830-840), ISSN 0940-6719
- Kozak JA, Heilman AE, O'Brien JP (1994) Anterior lumbar fusion options. *Clin Orthop Relat Res*, vol 300, (Mar 1994), p. (45-51), ISSN: 0009-921X
- Kraemer J (2009). Intervertebral Disk Prostheses. In: Intervertebral disk diseases: causes, diagnosis, treatment and prophylaxis 3<sup>rd</sup> edition. Thieme, Stuttgart, New York, pp 297-303.
- Kruton F (1944) The instability associated with disc degeneration in the lumbar spine. *Acta-Radio*, vol 25 (1944), pp. (593-609)
- Kuchta J, Sobottke R, Eysel P, Simons P. (2009). Two-year results of interspinous spacer (X-Stop) implantation in 175 patients with neurologic intermittent claudication due to lumbar spinal stenosis. *Eur Spine J*, vol 18, No 6 (Jun 2009), pp. (823-829), ISSN 0940-6719
- Kumar M, Jacquot F, Hall H. (2001). Long-term follow-up of functional outcomes and radiographic changes at adjacent levels following lumbar spine fusion for degenerative disc disease. *Eur Spine J*, vol 10, No 4 (Aug 2001), pp. (309-313), ISSN 0940-6719
- Kusslich D, Ulstrom C, Michael C. (1991). The tissue origin of low back pain and sciatica: a report of pain response to tissue etimulation during operations on the lumbar spine using local anesthesia. *Orthop Clin North Am*, vol 22, No 2 (Apr 1991), pp. (283-301), ISSN: 0030-5898
- Lauryssen C. Appropriate selection of patients with lumbar spinal stenosis for interspinous process decompression with the X STOP device. *Neurosurg Focus*. 2007 Dec 15;22(1):E5. ISSN 1092-0684
- Lee C, Langrana N. (1984). Lumbosacral spinal fusion. A biomechanical study. *Spine*, vol 9, No 6 (Sep 1984), pp. (574-581), ISSN 0362-2436
- Lee CK. (1988). Accelerated degeneration of the segment adjacent to a lumbar fusion. *Spine*, vol 13, No 3 (Mar 1988), pp. (375-377), ISSN: 0362-2436
- Lehmann TR, Spratt KF, Tozzi JE, et al. (1987) Long-term follow-up of lower lumbar fusion patients. *Spine*, vol 12, No 2 (Mar 1987), p. (97-104), ISSN: 0362-2436



- Luk KD, Lee FB, Leong JC, Hsu LC. (1987) The effect on the lumbosacral spine of long spinal fusion for idiopathic scoliosis. A minimum 10-year follow-up. *Spine*, vol 12, No 10 (Dec 1987), pp.(996-1000), ISSN: 0362-2436
- Lumsden RM, Morris JM. (1968) An in vivo study of axial rotation and immobilization at lumbosacral joint. *J Bone Joint Surg*, vol 50, No 8 (Dec 1968), pp. (1591-1602), ISSN: 1535-1386
- Maleci A, Sambale RD, Schiavone M, et al. (2011). Nonfusion stabilization of the degenerative lumbar spine. *J Neurosurg Spine*, vol 15, No 2 (Aug 2011), pp. (151-158) ISSN 1547-5654
- Mayer HM (1998) Microsurgical anterior approaches for anterior interbody fusion of the lumbar spine. In: McCulloch JA, Young PH (eds) *Essentials of spinal microsurgery*. Lippincott-Raven, Philadelphia, pp 633-649
- Mayer HM (2005) Total lumbar disc replacement. *J Bone Joint SurgBr*, vol 87, No 8 (Aug 2005), pp. (1029-1037), ISSN 0301-620X
- Mayer HM , Korge A; (2002) Non-fusion technology in degenerative lumbar spinal disorders: facts, questions, challenges. *Eur Spine J*, vol 11, No.2 (Oct 2002), pp. (S85-S91), ISSN 0940-6719
- McCullen GM, Yuan HA (2003) Artificial disc: current developments in artificial disc replacement. *Curr Opin Orthop*; vol 14, no 3 (Jun 2003), pp. (138-1430), ISSN: 10419918
- Min J, Jang J, Jung B, et al. (2008). The clinical characteristics and risk factors for the adjacent segment degeneration in instrumented lumbar fusion. *J Spinal Disord Tech*, vol 21, No 5 (Jul 2008), pp. (305-309), ISSN 1536-0652
- Minns RJ, Walsh WK. (1997). Preliminary design and experimental studies of a novel soft implant for correcting sagittal plane instability in the lumbar spine. *Spine*, vol 22, No 16 (Aug 1997), pp. (1819-1825), ISSN 0362-2436
- Miyakoshi N, Abe E, Shimada Y, et al. (2000). Outcome of one-level posterior lumbar interbody fusion for spondylolisthesis and postoperative intervertebral disc degeneration adjacent to the fusion. *Spine*, vol 25, No 14 (Jul 2000), pp.(1837-1842). ISSN 0362-2436
- Modic M, Pavlicek W, Weinstein M, et al. (1984). Magnetic resonance imaging of the intervertebral disc disease. Clinical and pulse sequence considerations. *Radiology*, vol 152, No 1 (Jul 1984), p(103-111), ISSN 0033-8419
- Modic M, Ross J. (1991). Magnetic resonance imaging in the evaluation of low back pain. *Orthop Clin North Am*, vol 22, No 2 (Apr 1991), pp. (283-301), ISSN 0030-5898
- Morgan FP, King T. (1957) Primary instability of lumbar vertebrae as common cause of low back pain. *J Bone Joint Surg*, vol 39, No 1 (1957), pp. (6-22), ISSN: 0301-620X
- Mulholand RC, Sengupta DK. (2002). Rationale, principles and experimental evaluation of the concept of soft stabilization. *Eur Spine J*, vol 11, No 2 (Oct 2002), pp. (S198-205), ISSN 0940-6719
- Olsewski JM, Schendel MJ, Wallace LJ, et al. (1996). Magnetic resonance imaging and biological changes in injured intervertebral discs under normal and increased mechanical demands. *Spine*, vol 21, No 17 (Sep 1996), pp.(1945-1951), ISSN: 0362-2436




- Panjabi M, Henderson G, Abjornson C, et al. (2007). Multidirectional testing of one and two-level ProDisc-L versus simulated fusions. *Spine*, vol 32, No 12 (May 2007), pp. (1311-1319), ISSN: 0362-2436
- Panjabi M, Malcolmson G, Teng E, et al. (2007). Hybrid testing of lumbar CHARITE discs versus fusions. *Spine*, vol 32, No 9 (Apr 2007), pp. (959-966), ISSN: 0362-2436
- Panjabi MM. (1992). The stabilizing system of the spine. Part II. Neutral zone and instability hypothesis. *J Spinal Disord*, vol 5, No 4 (Dec 1992), pp. (390-396), ISSN 0895-0385
- Phillips FM, Reuben J, Wetzel FT. (2002). Intervertebral disc degeneration adjacent to a lumbar fusion. An experimental rabbit model. *J Bone Joint Surg Br.*, vol 84, No 2 (Mar 2002), pp.(289-294), ISSN 0301-620X
- Putzier M, Schneider SV, Funk JF, et al. (2005). The surgical treatment of the lumbar disc prolapse: nucleotomy with additional transpedicular dynamic stabilization versus nucleotomy alone. *Spine*, vol 30, No 5 (Mar 2005), pp. (E109-114), ISSN 0362-2436
- Rahm MD, Hall BB. (1996). Adjacent segment degeneration after lumbar fusion with instrumentation: a retrospective study. *J Spinal Dis*, vol 9, No 5 (Oct 1996), pp. (392-400), ISSN: 0895-0385
- Rao R, David K, Wang M. (2005). Biomechanical changes at adjacent segments following anterior lumbar interbody fusion using tapered cages. *Spine*, vol 30, No 24 (Dec 2005), pp. (2772-2776), ISSN: 0362-2436
- Rodrigues LF, Voloch P, Gurgel S, Cavallari F. (2010). Retrospective evaluation by SF-36 questionnaires of patients submitted to pedicular dynamic stabilization for treatment of degenerative lumbar diseases. *Coluna/Columna*, Vol.9. No2. (Abr/jun 2010), pp.(104-112), ISSN: 1808-1851
- Roh JS, Teng AL, Yoo JU, Davis J, Furey C & Bohlman HH (2005). Degenerative Disorders of the Lumbar and Cervical Spine. *Orthop Clin N Am*, vol 36, No 3 (Jul 2005), pp. (255-262), ISSN: 0030-5898
- Rohlmann A, Neller S, Bergmann G, et al. (2001). Effect of an internal fixator and a bone graft on intersegmental spinal motion and intradiscal pressure in the adjacent regions. *Eur Spine J.*, vol10, No 4 (Aug 2001), pp. (301-308), ISSN 0940-6719
- Schaeren S, Broger I, Jeanneret B. (2008). Minimum four-year follow-up of spinal stenosis with degenerative spondylolisthesis treated with decompression and dynamic stabilization. *Spine*. Aug 15;33(18):E636-42. ISSN 0362-2436
- Schnake KJ, Schaeren S, Jeanneret B. (2006). Dynamic stabilization in addition to decompression for lumbar spinal stenosis with degenerative spondylolisthesis. *Spine*, vol 31, No 4 (Feb 2006), pp. (442-449), ISSN 0362-2436
- Schwarzenbach O, Berlemann U, Stoll T M, et al (2005). Posterior Dynamic Stabilization System: DYNESYS. *Orthop Clin N Am*, vol 36, No 3 (Jul 2005), pp. (363-372), ISSN 0030-5898
- Sears W R, Sergides IG, Kazemi N, et al (2011). Incidence and prevalence of surgery at segments adjacent to a previous posterior lumbar arthrodesis. *Spine J*, vol 11, No 1 (Jan 2011), pp.(11-20), ISSN 1529-9430
- Sénégas J, Etchevers JP, Baulny D, et al (1988) Widening of the lumbar vertebral canal as an alternative to laminectomy, in the treatment of lumbar stenosis. *Fr J Orthop Surg* No 2. pp. (93-99). ISSN: 1749-799X

- Sénégas J, Vital JM, Pointillart V, et al. (2009). Clinical evaluation of a lumbar interspinous dynamic stabilization device (the Wallis system) with a 13-year mean follow-up. *Neurosurg Rev*, vol 32, No 3 (Jul 2009), pp. (335–341), ISSN 0344-5607
- Sénégas J. (2002). Mechanical supplementation by non-rigid fixation in degenerative intervertebral lumbar segments: the Wallis system. *Eur Spine J*, vol 11, No 2 (Oct 2002), pp.(S164-169), ISSN 0940-6719
- Sénégas J. (2008). Dynamic lumbar stabilization with the Wallis interspinous implant. *Interactive Surgery*. vol 3, No 4 (2008), pp. (221-228), ISSN 1778-3968
- Sengupta DK. (2004). Dynamic stabilization devices in the treatment of low back pain. *Orthop Clin North Am*, vol 35, No 1 (Jan 2004), pp. (43-56), ISSN: 0030-5898
- Shim CS, Lee SH, Shin HD, et al (2007) CHARITE versus ProDisc: a comparative study of a minimum 3-year follow-up. *Spine*, vol 32, No 9 (Apr 2007), pp. (1012-1018), ISSN 0362-2436
- Shono Y, Kaneda K, Abumi K, et al. (1998). Stability of posterior spinal instrumentation and its effects on adjacent motion segments in the lumbosacral spine. *Spine*, vol 23, No 14 (Jul 1998), pp. (1550–1558), ISSN 0362-2436
- Siepe CJ, Mayer HM, Heinz-Leisenheimer M, et al (2007) Total lumbar disc replacement: different results for different levels. *Spine*, vol 32, No 7 (Apr 2007), pp. (782–790), ISSN 0362-2436
- Stokes I, Wilder D, Frymoyer J, Pope M. (1981). 1980 Volvo award in clinical sciences. Assessment of patients with low-back pain by biplanar radiographic measurement of intervertebral motion. *Spine*, vol 6, No 3 (May-Jun 1981), pp. (233-240), ISSN 0362-2436
- Strempele A, Moosmann D, Stoos C, Martin A. (2007). Posterior nonfusion stabilization of the degenerated lumbar spine with cosmic. In: Szpalski M, Gunzburg R, Le Huec JC, Brayada-Bruno M, eds. Nonfusion techniques in spine surgery. Philadelphia: Lippincott Williams & Wilkins; 2000:410-430 ISBN: 0781769728.
- Strempele, A., Moosmann, D., Stoss, C., et al. (2006). Stabilization of the degenerated lumbar spine in the non fusion technique with Cosmic posterior dynamic system *World Spine J*, vol. 1, No 1 (2006), pp.(40-47)
- Strempele, A. (2008). Dynamic stabilisation: cosmic system. *Interact Surg*, Vol 3, No 4(2008),pp.( 229–236). ISSN: 1778-3968
- Sudo H, Oda I, Abumi K, et al. (2006). Biomechanical study on the effect of five different lumbar reconstruction techniques on adjacent-level intradiscal pressure and lamina strain. *J Neurosurg Spine*, vol 5, No 2 (Aug 2006) pp. (150–155), ISSN 1547-5654
- Szpalski M, Gunzburg R, Mayer M. (2002). Spine arthroplasty: a historical review. *Eur Spine J*, vol 11, No 2 (Oct 2002), pp.(S65-84), ISSN 0940-6719
- Trautwein FT, Lowery GL, Wharton ND, et al. (2010). Determination of the in vivo posterior loading environment of the Coflex interlaminar-interspinous implant. *Spine J*, vol 10, No 3 (Mar 2010) pp. (244–251), ISSN 1529-9430
- Tropiano P, Huang RC, Girardi FP, et al (2005) Lumbar total disc replacement. Seven to eleven-year follow-up. *J Bone Joint Surg Am*, vol 87, No 3 (Mar 2005), pp. (490–496), ISSN 0021-9355

- Turner JA, Ersek M, Herron L, et al. (1992). Surgery for lumbar spinal stenosis: attempted meta-analysis of the literature. *Spine*, vol 17, No 1 (Jan 1992), pp. (1-8), ISSN 0362-2436
- Urban JPG, Roberts S. (2003). Degeneration of the intervertebral disc. *Arthritis Res Ther*, vol 5, No 3 (2003), pp. (120-130), ISSN 1478-6354
- van Ooij A, Oner FC, Verbout AJ (2003) Complications of artificial disc replacement: a report of 27 patients with the SB Charite disc. *J Spinal Disord Tech*, vol 16, No 4 (Aug 2003), pp.(369-383), ISSN 1536-0652
- Verbiest H (1954). A radicular syndrome from developmental narrowing of the lumbar vertebral canal. *J Bone Joint Surg Br*, vol 36-B, No 2 (May 1954), pp. (230-237), ISSN: 0301-620X
- Weinhoffer S, Guyer R, Herbert M, et al. (1995). Intradiscal pressure measurements above an instrumented fusion. A cadaveric study. *Spine*, vol 20, No 5 (Mar 1995), pp.(526-531), ISSN 0362-2436
- Weinhoffer SL, Guyer RD, Herbert M, et al. (1995) Intradiscal pressure measurements above an instrumented fusion. A cadaveric study. *Spine*, vol 20, No 5 (Mar 1995), pp.(526-531), ISSN 0362-2436
- Weinstein JN, Tosteson TD, Lurie JD, et al. (2008). SPORT Investigators: Surgical versus nonsurgical therapy for lumbar spinal stenosis. *N Engl J Med*, vol 358, No 8 (Feb 2008), pp.(794-810), ISSN: 0028-4793
- White A.A., Panjabi M.M (Eds.), *Clinical biomechanics of the spine*, 2nd ed, JB Lippincott, Philadelphia, PA, 1990
- Wiltse L, Radecki S, Biel H, et al.(1999) Comparative study of the incidence and severity of degenerative change in the transition zones after instrumented versus noninstrumented fusions of the lumbar spine. *J Spinal Disord*, vol 12, No 1 (Feb 1999), pp.(27-33), ISSN 0895-0385
- Wiltse LL, Spencer CW. (1988). New uses and refinements of the paraspinal approach to the lumbar spine. *Spine*, vol 13, No 6 (Jun 1988), pp. (696-706) ISSN 0362-2436
- Wippermann BW, Schrott HE, Steeg S, et al. (1997). Complications of spongiosa harvesting of the ilial crest. A retrospective analysis of 1,191 cases. *Chirurg*, vol 68, No 12 (Dec 1997), pp. (1286-1291), ISSN 0009-4722
- Yajun W, Yue Z, Xiuxin H, Cui C. A meta-analysis of artificial total disc replacement versus fusion for lumbar degenerative disc disease. *Eur Spine J*, vol 19, No 8 (Aug 2010), pp. (1250-1261), ISSN 0940-6719
- Yang J, Lee J, Song H. (2008). The impact of adjacent segment degeneration on the clinical outcome after lumbar spinal fusion. *Spine*, vol 33, No 5 (Mar 2008) pp. (503-507), ISSN 0362-2436
- Yi X, McPherson B. (2010). Application of X Stop device in the treatment of lumbar spinal stenosis. *Pain Physician*, vol 13, No 5 (Sep-Oct 2010), pp.(E327-326), ISSN 1533-3159
- Yu S, Haughton VM, Ho PS, Sether LA, Wagner M, Ho KC.(1988). Progressive and regressive changes in the nucleus pulposus II. The adult. *Radiology*, vol 169, No 1 (Oct 1988), pp. (93-97) ISSN 0033-8419
- Zhang YH, Zhao CQ, Jiang LS, et al (2008). Modic changes: a systematic review of the literature. *Eur Spine J*, vol 17, No 10 (Oct 2008), pp. (1289-1299), ISSN 0940-6719

- Zigler JE. (2004) Spinal Jn Lumbar spine arthroplasty using the ProDisc II. *Spine J*, vol 4, No 6 (Nov-Dec 2004), pp.(260S-267S), ISSN 1529-9430
- Zucherman J, Hsu K, Hartjen C, et al. (2004). A prospective randomized multicenter study for the treatment of lumbar spinal stenosis with the X STOP interspinous implant: 1-year results. *Eur Spine J*, vol 13, No 1 (Feb 2004), pp.(22-31), ISSN 0940-6719
- Zucherman JF, Hsu KY, Hartjen CA, et al. (2005). A multicenter, prospective, randomized trial evaluating the X STOP interspinous process decompression system for the treatment of neurogenic intermittent claudication. Two year follow-up results. *Spine*, vol30, No 12 (Jun 2005), pp.(1351-1358), ISSN 0362-2436



## **Low Back Pain Pathogenesis and Treatment**

Edited by Dr. Yoshihito Sakai

ISBN 978-953-51-0338-7

Hard cover, 244 pages

**Publisher** InTech

**Published online** 14, March, 2012

**Published in print edition** March, 2012

Low back pain is a common disorder which affects the lumbar spine, and is associated with substantial morbidity for about 80% of the general population at some stages during their lives. Although low back pain usually is a self-limiting disorder that improves spontaneously over time, the etiology of low back pain is generally unknown and the diagnostic label, "non-specific low back pain", is frequently given. This book contains reviews and original articles with emphasis on pathogenesis and treatment of low back pain except for the rehabilitative aspect. Consisting of three sections, the first section of the book has a focus on pathogenesis of low back pain, while the second and third sections are on the treatment including conservative and surgical procedure, respectively.

### **How to reference**

In order to correctly reference this scholarly work, feel free to copy and paste the following:

Leonardo Fonseca Rodrigues, Paula Voloch and Flávio Cavallari (2012). Nonfusion Techniques for Degenerative Lumbar Diseases Treatment, Low Back Pain Pathogenesis and Treatment, Dr. Yoshihito Sakai (Ed.), ISBN: 978-953-51-0338-7, InTech, Available from: <http://www.intechopen.com/books/low-back-pain-pathogenesis-and-treatment/nonfusion-techniques-for-degenerative-lumbar-diseases-treatment>

**INTECH**  
open science | open minds

### **InTech Europe**

University Campus STeP Ri  
Slavka Krautzeka 83/A  
51000 Rijeka, Croatia  
Phone: +385 (51) 770 447  
Fax: +385 (51) 686 166  
[www.intechopen.com](http://www.intechopen.com)

### **InTech China**

Unit 405, Office Block, Hotel Equatorial Shanghai  
No.65, Yan An Road (West), Shanghai, 200040, China  
中国上海市延安西路65号上海国际贵都大饭店办公楼405单元  
Phone: +86-21-62489820  
Fax: +86-21-62489821



© 2012 The Author(s). Licensee IntechOpen. This is an open access article distributed under the terms of the [Creative Commons Attribution 3.0 License](https://creativecommons.org/licenses/by/3.0/), which permits unrestricted use, distribution, and reproduction in any medium, provided the original work is properly cited.

IntechOpen

IntechOpen