

We are IntechOpen, the world's leading publisher of Open Access books Built by scientists, for scientists

6,900

Open access books available

186,000

International authors and editors

200M

Downloads

Our authors are among the

154

Countries delivered to

TOP 1%

most cited scientists

12.2%

Contributors from top 500 universities



WEB OF SCIENCE™

Selection of our books indexed in the Book Citation Index
in Web of Science™ Core Collection (BKCI)

Interested in publishing with us?
Contact book.department@intechopen.com

Numbers displayed above are based on latest data collected.
For more information visit www.intechopen.com



The Dental Volumetric Tomography, RVG, and Conventional Radiography in Determination the Depth of Approximal Caries

Cafer Türkmen, Gökhan Yamaner and Bülent Topbaş

*Department of Operative Dentistry,
Faculty of Dentistry, University of Marmara, Istanbul,
Turkey*

1. Introduction

Detection of carious lesions is prerequisite to an optimal preventive and minimal surgical intervention strategy. Radiographs are the most accurate diagnostic aid available for the detection of alveolar osseous abnormalities and dental disease progression (Russel & Pitts, 1993; Rothman, 1998). The development of digital radiography (radiovisiographs-RVG) has created new options in dentistry (Hedrick et al., 1994; Svanæs et al., 2000; Van der Stelt, 2005). However, imaging systems used in dentistry are largely limited to 2 dimensional (2-D) systems in including conventional-based radiography and digital radiography. The problem inherent to 2-D system is that 3 dimensional anatomy is collapsed into 2-D space, resulting in the superimposition of structures that potentially obscure features of interest and decrease diagnostic sensitivity. There are a number of 3-D systems available, like computed tomography (CT), tuned aperture computed tomography (TACT), and cone beam computed tomography (CBCT) (Hedrick et al., 1998; Mozzo et al., 1998; Sukovic, 2003; Aranyarachkul et al., 2005; Walker et al., 2005).

The CBCT technique presents an innovation of tomographic imaging systems and subsequent volumetric image reconstruction for dentistry. When compared with other methods of tomographic imaging, CBCT is characterized by rapid volumetric image acquisition from a single low radiation dose scan of the patient. CBCT, also known as true volumetric computed tomography (TVCT) designed for use in dental imaging of osseous structures has been introduced (Rothman, 1998; Mozzo et al., 1998; Schulze et al., 2005). The first available and now well-established CBCT system, the NewTom is an example of such a CBCT machine dedicated to dental and maxillofacial imaging, particularly for surgical and/or prosthetics implant planning in the field of dentistry. The NewTom differs from a traditional dental CT scan in the way it captures an image; it does so by cone beam volumetric tomography. The W-ray tube revolves around the patient's head in a single spiral, capturing a volume with each of the 360 degrees it rotates. Added together, the volumetric cone images are reformatted without any discernible error. In fact, the NewTom is accurate to 0.1 mm. While a dental CT scan takes ten minutes of working time and exposes the patient to two minutes of radiation, the NewTom scan takes 70 seconds and exposes the patient to 17 seconds of low-dose radiation. The radiation from a NewTom scan

is comparable to the radiation from a single Panorex, while a dental CT scan is roughly equivalent to 6-8 times that amount, depending on bone density.

It is also possible to detect the relationship of the caries lesions with pulp chamber as 3-D. Therefore, the superpositions were eliminated with this system. The aim of this study was to compare the new dental volumetric tomography, RVG and conventional radiography in determination of the depth of approximal carious lesions.

2. Materials & methods

Randomly chosen 44 extracted and unrestored premolars and molars teeth with approximal carious lesions were embedded in silicone (Optosil- Bayer Dental, Leverkusen, FRG) blocks in sets of 4 (2 premolars and 2 molars in contact), simulating as far as possible their presumed anatomical relationships. Extra 3 posterior teeth (One of them with a 1 cm metal wire fixed on occlusal, the others drilled in depth of 3 mm round hole in proximal contacts) were mounted for the calibration and control.

D (Agfa Dentus M 2D, Germany) and E (Cea Dent, Ced D, Sweden) – speed radiographic films were used to take x-ray. Exposures were standardized at 18 impulses (0.3 s) from a model Kodak C6 320 FFD (70 kVp, 8 mA) radiation source (Kodak-Trophy ETX, France) that is also then integrated with the imaging system (*Kodak RVG 5000*) with distance of 20 cm holder device (short cone) (Dentsply Gendex Rinn, Milano, Italy). Films were processed immediately after exposure in fresh Kodak Readymatic processing solutions by means of a Velopex automatic temperature controlled processor (Extra-x, London, England). Processed radiographs were scanned to the computer for the measurement of carious lesions depths linearly in software. For the digital imaging, the sensor was fixed with the holder and Trophy dental unit was exposed for the 0.18 s.

The NewTom (NewTom 9000; Quantitative Radiology, Verona, Italy) CBCT machine was used for the volumetric CT imaging. The teeth blocks were inserted to the centre of a water filled glass model have a volume to simulate a human head. Exposure was; 110 kVp, 5,2 mA for 36 s.

The depth of carious lesions was measured linearly in software (NewTom 3G, generation 2).

For the validation criteria, the roots of teeth were discarded and the crowns were sectioned as mesiodistally by a low speed diamond saw (Isomet 100 precision saw, Buchler, Germany) for histological measurements under the stereomicroscopy (Leica MZ 75, Heerbrugg, Germany).

Bland-Altman plot test was used to describe agreement between software and histologic measurements of approximal carious lesion depths.

3. Results

Table 1 lists the measured the average carious lesion depths of 44 teeth on digital images (radiographs, RVG, and tomographic) and histologic observation.

The Bland-Altman plot test revealed that the percentage agreement between radiographic and histologic measurements was 93.2% while 6.8% of the points were beyond the ± 2 (Std. Dev.) of the mean difference. On the other hand, 90.9% agreement were observed between both RVG and histologic measurement and volumetric CT and histologic measurement. 9.1% of the points were beyond the ± 2 (SD) of the mean difference for both comparisons.

Tooth No	Radiographic	RVG	Volumetric CT	Histologic
1	2.3	2.5	2.6	2.4
2	3.3	3.3	3.5	3.2
3	4.8	4.9	5.0	4.7
4	4.4	4.5	4.7	4.3
5	2.6	2.6	2.5	2.3
6	3.0	3.1	3.3	3.0
7	4.4	4.5	4.4	4.2
8	4.8	4.9	5.1	4.7
9	3.5	3.5	3.6	3.3
10	2.0	2.1	2.2	2.0
11	4.1	4.0	4.2	3.8
12	4.3	4.4	4.6	4.2
13	3.2	3.1	3.3	3.0
14	3.0	3.1	3.2	2.8
15	4.0	4.1	4.1	3.8
16	3.6	3.7	3.8	3.5
17	3.8	3.8	3.9	3.6
18	4.3	4.2	4.4	4.1
19	4.7	4.8	4.7	4.2
20	4.6	4.8	4.9	4.6
21	2.3	2.4	2.6	2.3
22	2.5	2.5	2.7	2.4
23	2.7	2.9	2.9	2.8
24	3.6	3.8	3.7	3.5
25	4.4	4.6	4.8	4.1
26	3.6	3.7	3.9	3.8
27	2.1	2.3	2.3	2.0
28	4.3	4.0	4.4	4.1
29	3.0	3.3	3.5	3.2
30	2.7	2.9	3.0	2.5
31	3.1	3.2	3.4	3.0
32	4.0	4.1	4.3	3.8
33	3.5	3.5	3.7	3.3
34	2.6	2.7	2.7	2.7
35	2.8	2.6	2.9	2.5
36	4.2	4.3	4.4	4.0
37	3.3	3.4	3.6	3.2
38	3.5	3.7	3.9	3.4
39	4.0	4.2	4.4	3.9
40	3.8	3.3	3.5	4.0
41	2.7	2.6	2.7	4.1
42	1.8	2.0	2.1	4.2
43	1.4	1.7	1.5	4.3
44	2.3	2.3	2.5	4.4

*(Bland-Altman analysis: Radiographic-histologic: 93.2%, RVG-histologic and Volumetric-histologic: 90.9%)

Table 1. Carious lesion depths (mm) measured linearly in software and histologically.

The stereomicroscopy measurements revealed that the real caries depth was determined with the new volumetric tomography (fig.1) while RVG (fig.2) and similarly conventional radiography (fig.3) imaged less depth than it.

Histologic examination of the teeth confirmed that the dental volumetric CT also appears to be very promising in caries lesion imaging.

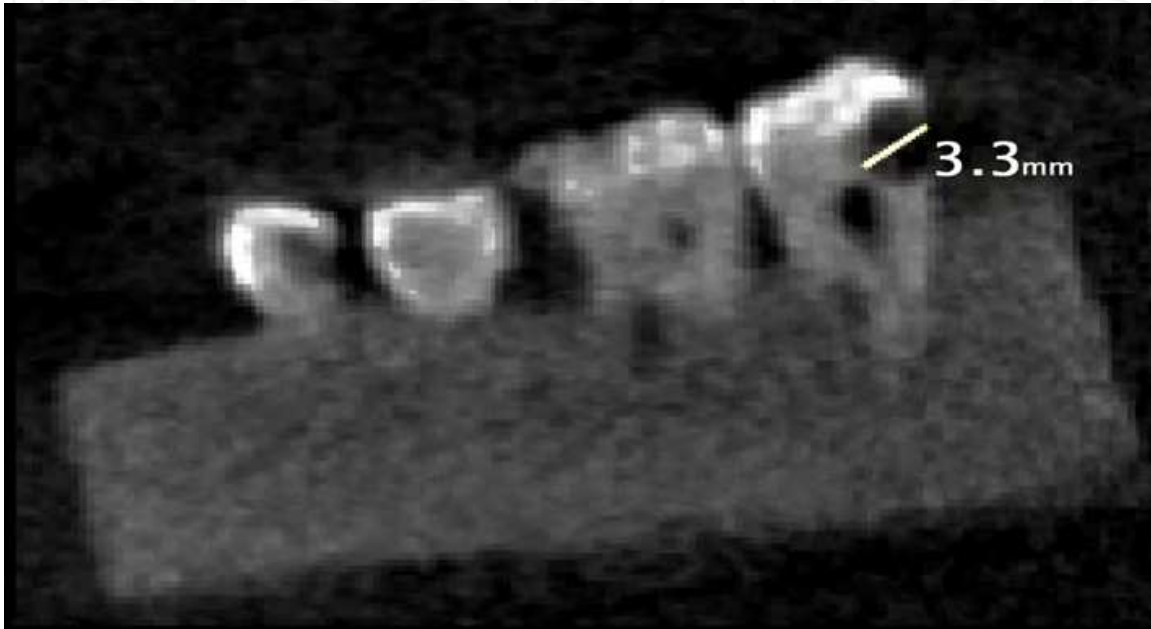


Fig. 1. Digital image of Volumetric CT.

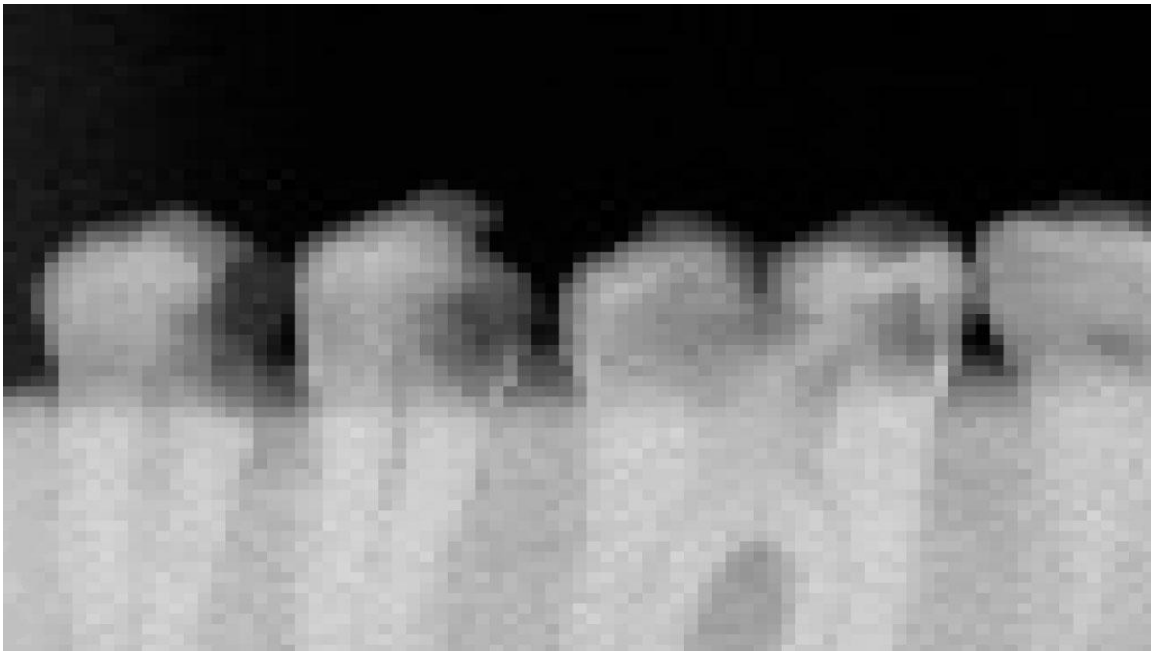
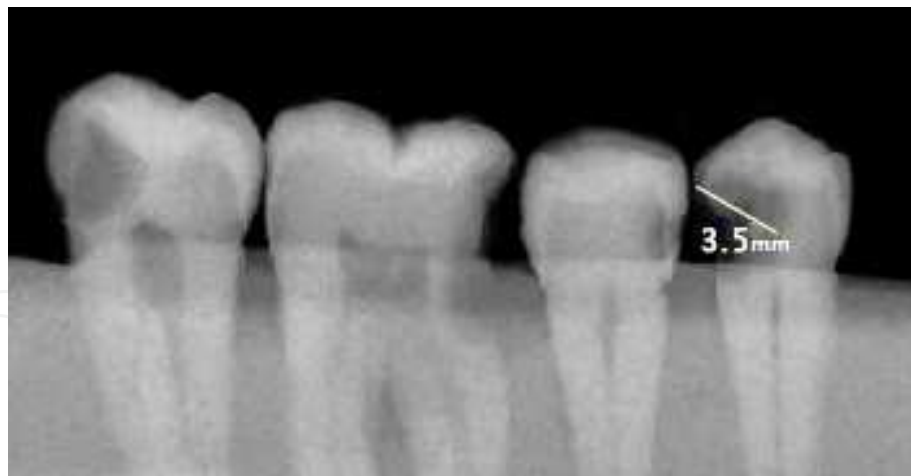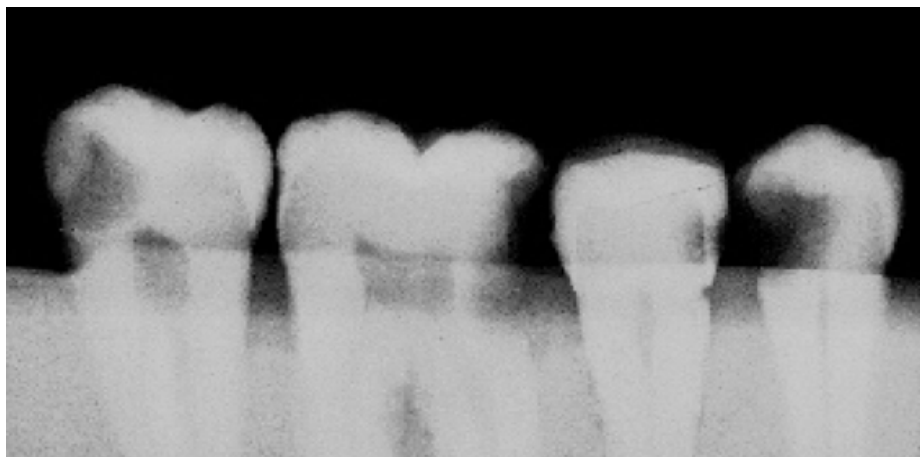


Fig. 2. Digital image of RVG.



(a)



(b)

Fig. 3. Photographs of conventional radiographs, D (a) and E (b) speed films.

4. Discussion

The present study has demonstrated that the volumetric tomography images have the potential to be the practical extraoral imaging modality for proximal caries detection.

In the most of studies (Velders et al., 1996; Svanæs et al., 2000; Wenzel, 2001; Khan et al., 2004; Young & Featherstone, 2005), the proximal carious lesion was evaluated by using the visual criterion. Although the visual criterion used was somewhat subjective, it represented the best clinical representation of a proximal carious lesion. In previous similar in vitro studies (Jesse, 1999; Kooistra et al., 2005), the gold standard for comparisons was histological section of the extracted teeth. Caries depth was evaluated in these sections based solely on the microscopic evaluation of a color change between involved and uninvolved dentin.

The singular purpose of the radiographic capture device (DDR sensor or conventional film) is to capture the X-ray photon density pattern as it emerges from the subject tissues. The photon dispersion pattern that emerges from the tissues is a function of the tissues and the radiation source. An image would be sharper if the beam originated from a point source

rather than a source area. Clinical radiation generators emit X-rays from a source area and not from a singular point. This means that radiographic images are subject to loss of image detail and geometric unsharpness. The loss of image detail and sharpness is a function of the dimensions of the focal spot. The greater the focal spot size, the greater the loss of detail. Since X-ray photons cannot be focused into a sharp image as light can be focused through a camera lens, the image captured by conventional film or DDR sensors will never have a crisp, in focus appearance like a photograph focused through a lens. Radiographic images will always be subject to a certain degree of geometric unsharpness that will limit the resolution of the image that can be captured. The photon dispersion pattern cannot be improved by the sensor and will continue to limit image quality and sharpness for both conventional and DDR systems (Langland & Sippy, 1973; Hedrick et al., 1994).

The CBCT scanners utilize a two-dimensional, or panel, detector, which allows for a single rotation of the gantry to generate a scan of the entire head, as compared with conventional CT scanners whose multiple "slices" must be stacked to obtain a complete image. Cone beam technology utilizes X-rays much more efficiently, requires far less electrical energy, and allows for the use of smaller and less expensive X-ray components than fan-beam technology. In addition, the fan-beam technology used in conventional CT scanners does not lend itself to miniaturization because it requires significant space to spiral around the entire body (Sukovic, 2003; Marmulla et al., 2005).

Jaffray & Siewerdsen (2000) noted that the CBCT approach offers two important features that dramatically reduce its cost in comparison to a conventional scanner. First, the cone beam nature of the acquisition does not require an additional mechanism to move the patient during the acquisition. Second, the use of a cone beam, as opposed to a fan beam, significantly increases the X-ray utilization, lowering the X-ray tube heat capacity required for volumetric scanning. For the same source and detector geometry, the efficiency roughly scales with slice thickness. For example, the X-ray utilization increases by a factor of 30 in going from a 3 mm slice in a conventional scanner to a cone angle corresponding to a 100 mm slice with a cone beam system. This would reduce heat load capacity dramatically.

In summary, cone beam CT is a versatile emerging technology whose high and isotropic spatial resolution, undistorted images, compact size and relatively low cost, make it a perfect candidate for a dedicated dentomaxillofacial imaging modality. When combined with dedicated software packages, it can provide practitioners with a complete solution for demanding tasks (Mozzo et al., 1998; Sukovic, 2003; Schulze et al., 2005).

For approximal caries detection, the sensitivity of the volumetric dental tomography images was found to be slightly less than conventional radiographs and digital images in this study. Overall, the three methods were not statistically significantly different for the determination depth of the approximal carious lesions in vitro.

5. Conclusion

The results from the initial study suggest that although the sensitivities determined for all techniques were low, the volumetric dental tomography images showed that this device had a potential for detection approximal caries depths, root canal filling lengths, and left emptiness in the root in 3-D views.

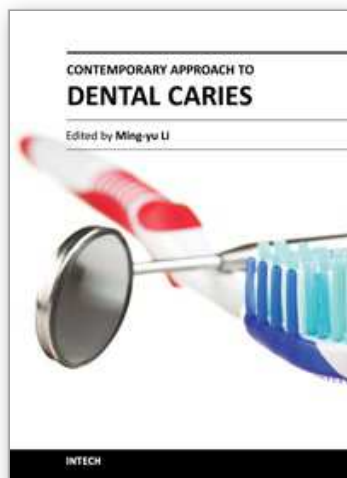
6. References

- Aranyarachkul, P.; Caruso, J., Gantes, B., Riggs, M., Dus, I. & Yamada, J. M. (2005). Bone density assessments of dental implant sites: 2. quantitative cone-beam computerized tomography. *International Journal of Oral & Maxillofacial Implants*, Vol. 20, pp. 416-424.
- Hedrick, R.T.; Dove, B., Peters, D.D. & McDavid, W.D. (1994). Radiographic determination of canal length: Direct digital radiography versus conventional radiography. *Journal of Endodontics*, Vol. 20, pp. 320-326.
- Jaffray, D.A. & Siewerdsen, J.H. (2000). Cone-beam computed tomography with a flat-panel imager: Initial performance characterization. *Medical Physics*, Vol. 27, pp. 1311-1323.
- Jesse, S.A.; Makins, S.R. & Bretz, W.A. (1999). Accuracy of proximal caries depth determination using two intraoral film speeds. *General Dentistry*, Vol. 47, pp. 88-93.
- Khan, E.A.; Tyndall, D.A. & Caplan, D. (2004). Extraoral imaging for proximal caries detection: Bitewings vs scanogram. *Oral Surgery Oral Medicine Oral Pathology Oral Radiology & Endodontics*, Vol. 98, pp. 730-737.
- Kooistra, S.; Dennison, J.B., Yaman, P., Burt, B.A. & Taylor, G.W. (2005). Radiographic versus clinical extension of class II carious lesions using an F-speed film. *Operative Dentistry*, Vol. 30, pp. 719-726.
- Langland, O.E. & Sippy, F.H. (2005). Textbook of dental radiography. 1st edn. Springfield: Charles C Thomas, 1973.
- Marmulla, R.; Wörtche, R., Mühling, J. & Hassfeld, S. (2005). Geometric accuracy of the NewTom 9000 Cone Beam CT. *Dentomaxillofacial Radiology*, Vol. 34, pp. 28-31.
- Mozzo, P.; Procacci, C., Tacconi, A., Tinazzi Martini, P. & Bergamo Andtreis, I.A. (1998). A new volumetric CT machine for dental imaging based on the cone-beam technique: preliminary results. *European Radiology*, Vol. 8, pp. 1558-1564.
- Rothman, S.L.G. (1998). *Dental applications of computerized tomography*. 1st Edn. Quintessence Publishing Co, Inc., Illionis, pp. 5-57.
- Russell, M. & Pitts, N.B. (1993). Radiovisiographic diagnosis of dental caries: Initial comparison of basic mode videoprints with bitewing radiography. *Caries Research*, Vol. 27, pp. 65-70.
- Schulze, D.; Heiland, M., Blake, F., Rother, U. & Schmelzle, R. (2005). Evaluation of quality of reformatted images from two cone-beam computed tomographic systems. *Journal of Cranio-Maxillofacial Surgery*, Vol. 33, pp. 19-23.
- Sukovic, P. (2003). Cone beam computed tomography in craniofacial imaging. *Orthodontics of Craniofacial Restorations*, Vol. 6, pp. 31-36.
- Svanæs, D.B.; Møystad, A. & Larheim, T.A. (2000). Approximal caries depth assessment with storage phosphor versus film radiography. *Caries Research*, Vol. 34, pp. 448-453.
- Van der Stelt, P.F. (2005). Filmless imaging: The uses of digital radiography in dental practice. *Journal of American Dental Association*, Vol. 136, pp. 1379-1387.
- Velders, X.L.; Sanderink, G.C.H. & Van der Stelt, P.F. (1996). Dose reduction of two digital sensor systems measuring file lengths. *Oral Surgery, Oral Medicine Oral Pathology Oral Radiology & Endodontics*, Vol. 81, pp. 607-612.
- Walker, L.; Enciso, R. & Mah, J. (2005). Three-dimensional localization of maxillary canines with cone-beam computed tomography. *American Journal of Orthodontic & Dentofacial Orthopedics*, Vol. 128, pp. 418-423.

- Wenzel, A. (2001). Computer-automated caries detection in digital bitewings: Consistency of a program and its influence on observer agreement. *Caries Research*, Vol. 35, pp. 12-20.
- Young, D.A. & Featherstone, J.D.B. (2005). Digital imaging fiber-optic trans-illumination, F-speed radiographic film and depth of approximal lesions. *Journal of American Dental Association*, Vol. 136, pp. 1682-1687.

IntechOpen

IntechOpen



Contemporary Approach to Dental Caries

Edited by Dr. Ming-Yu Li

ISBN 978-953-51-0305-9

Hard cover, 488 pages

Publisher InTech

Published online 14, March, 2012

Published in print edition March, 2012

With an update of the recent progress in etiology, pathogenesis, diagnosis, and treatment of caries, it may be said that the final defeat of dental caries is becoming possible soon. Based on the research in this area in recent decades, "Contemporary Approach to Dental Caries" contained the caries in general, the diagnosis of caries, caries control and prevention, the medical treatment of caries, dental caries in children and others such as secondary caries. This book provides the reader with a guide of progress on the study of dental caries. The book will appeal to dental students, educators, hygienists, therapists and dentists who wish to update their knowledge. It will make you feel reading is profitable and useful for your practice.

How to reference

In order to correctly reference this scholarly work, feel free to copy and paste the following:

Cafer Türkmen, Gökhan Yamaner and Bülent Topbaşı (2012). The Dental Volumetric Tomography, RVG, and Conventional Radiography in Determination the Depth of Approximal Caries, Contemporary Approach to Dental Caries, Dr. Ming-Yu Li (Ed.), ISBN: 978-953-51-0305-9, InTech, Available from:
<http://www.intechopen.com/books/contemporary-approach-to-dental-caries/the-dental-volumetric-tomography-rvg-and-conventional-radiography-in-determination-the-depth-of-appr>

INTech
open science | open minds

InTech Europe

University Campus STeP Ri
Slavka Krautzeka 83/A
51000 Rijeka, Croatia
Phone: +385 (51) 770 447
Fax: +385 (51) 686 166
www.intechopen.com

InTech China

Unit 405, Office Block, Hotel Equatorial Shanghai
No.65, Yan An Road (West), Shanghai, 200040, China
中国上海市延安西路65号上海国际贵都大饭店办公楼405单元
Phone: +86-21-62489820
Fax: +86-21-62489821

© 2012 The Author(s). Licensee IntechOpen. This is an open access article distributed under the terms of the [Creative Commons Attribution 3.0 License](https://creativecommons.org/licenses/by/3.0/), which permits unrestricted use, distribution, and reproduction in any medium, provided the original work is properly cited.

IntechOpen

IntechOpen