

# We are IntechOpen, the world's leading publisher of Open Access books Built by scientists, for scientists

6,900

Open access books available

185,000

International authors and editors

200M

Downloads

Our authors are among the

154

Countries delivered to

TOP 1%

most cited scientists

12.2%

Contributors from top 500 universities



WEB OF SCIENCE™

Selection of our books indexed in the Book Citation Index  
in Web of Science™ Core Collection (BKCI)

Interested in publishing with us?  
Contact [book.department@intechopen.com](mailto:book.department@intechopen.com)

Numbers displayed above are based on latest data collected.  
For more information visit [www.intechopen.com](http://www.intechopen.com)



# Noninsertional Achilles Tendinopathy – Treatment with Platelet Rich Plasma (PRP)

Marta Tarczyńska and Krzysztof Gawęda  
 NZOZ Arthros, Nałęczów  
 Orthopaedic Surgery and Traumatology Department,  
 Medical University of Lublin  
 Poland

## 1. Introduction

### 1.1 Tendinopathy pathology

Various forms of overload pathology of the Achilles tendon constitutes the usual source of pain within the posterior surface of the peripheral part of the calf, occurring without particular traumatic cause.

This condition affects patients across ages groups (1,2). Both the location of the pathological lesions and their nature are different from each other (3). Pain is usually reported approximately 2 - 6 cm above the junction of the tendon and calcaneal tubercle. This condition has been called **noninsertional tendinopathy** (4).

As opposed to the above, the pathological processes that develop at the Achilles tendon attachment site on the calcaneus have been called **insertional tendinopathy**, and are less frequent. Initially, both conditions were jointly referred to as **Achilles tendinitis**, supposedly to explain the inflammatory origin of lesions in the calcaneal tendon and its insertion point.

According to Schepsis this was an incorrect approach, resulting from insufficient knowledge and understanding of the variable nature of pathological lesions in the course of these processes (5). **Clinical, imaging or histological features of inflammation were rarely observed (6,7). These were only seen in the peritendineum (7). They were often symptomless, did not cause any complaints and were only found by accident (5).** However, considering the results of other studies, lesions in the Achilles tendon were found to involve neurogenic inflammation (8,9).

The usual cause of pain is related to an increase in the number of cells in the tendon, and an increase of their activity, thus resulting in an increased volume of extracellular substance. The collagen fibre pattern and neovascularisation process are thus corrupted (10). **There is no evidence indicating the development of prostaglandin-mediated inflammation.** Sometimes, fatty degeneration or mucin deposits are observed in the Achilles tendon (5).

Such incomplete knowledge of the aetiopathogenesis has led to many misunderstandings regarding nomenclature, and even treatment methods (5,11). **The term tendinitis,**

indicating an inflammatory aetiology, is therefore correct only for the neurogenic origin that is not a frequent feature of the pathomorphological picture. It has been replaced in the literature by terms such as tendinosis or tendinopathy, used interchangeably (5).

## 1.2 Tendinopathy aetiology

Tendinopathy may develop as a result of a single cause, or result from the overlapping effects of multiple causative factors. These always lead to an overload of the Achilles tendon. It is believed that a sudden, short-term increase of loads may be one of the causes of the developing lesions. In a similar manner, an overload may also result from an increased duration or frequency of physical training loads.

As a result of an increased frequency of training sessions, the rest intervals become shorter, thus reducing the chances for regeneration and self-repair of any micro-injuries that may have occurred.

An undoubted increase of the risk of Achilles tendinopathy occurs when the training shoes are replaced with new, often uncomfortable or even improper ones that force a pronation position of the foot. Subjecting the foot to loads in forced tarsal overpronation causes an increase of the forces transmitted through the calcaneal tendon.

Own observations in ultrasonography studies show that lesions usually occur within the section of the calcaneal tendon formed by the medial head of the gastrocnemius muscle. Running on a hard and uneven surface forces substantial and suddenly changing tensions within the Achilles tendon that lead to the formation of lesions within its internal structure.

Seasonal changes of the surface on which the patient walks or trains on an everyday basis also play an important role. Excessively tense or weakened muscles of the calf, subjected to regular loads, also sometimes cause the development of calcaneal tendon overload lesions.

A limited range of motion in the ankle joint is a similar risk factor. Inappropriate motor training methods, especially insufficient muscular warm-up prior to training, improper stretching of calf muscles or their abrupt cooling after effort increase the risk of Achilles tendinopathy.

## 1.3 Tendinopathy symptoms

### 1.3.1 Clinical

Patients' complaints and physical symptoms of noninsertional Achilles tendinopathy are variable, depending on the severity and extent of the lesions. It has also been found that the duration of the pathological processes has an impact on the severity and features of the complaints.

The most frequent and unspecific symptom is moderate to severe pain in the area of the calcaneal tendon, located proximally from its attachment to the calcaneus. The painful section of the tendon usually shows evidence of a nodule- or spindle-like thickening.

The thickened areas are very painful at palpation. Pressure sensitivity can be increased following a period of rest, especially at night. Patients report stiffness of the ankle joint during its first movements. A reduction of strength and range of plantar flexion of the foot is observed. A sensations of heaviness of the affected limb is a common complaint.

Considering the pain incidence and intensity, noninsertional Achilles tendinopathy is classified into 4 stages. Stage I features pain that occurs only following effort, especially running. Patients with stage II report pain both before and after running. Complaints slightly decrease while running. Stage III includes pain during any activity, significantly reducing the duration and levels of achievable loads. In stage IV, pain occurs during normal everyday activity that increases the pain intensity or extends its duration.

### 1.3.2 Imaging

Standard radiological imaging are not useful in supporting the diagnostics and imaging of tendinopathy lesions of the calcaneal tendon. Only imaging techniques that are capable of showing the differences in soft tissue structure may be helpful in diagnosing and monitoring the course of tendinopathy of the Achilles tendon.

Ultrasonography (US) and magnetic resonance imaging (MRI) are the golden standard in tendinopathy imaging. Due to its availability, ultrasonography is the most frequently used method. Various ultrasonography options and variants are useful.

The most frequent ultrasonographic symptoms of tendinopathy are focal thickening of the tendon, hypoechogenic intratendinous foci and evidence of rupture of the fibrillar structure of tendons. A thickening of the peritendon and tendon sliding restriction during active movements of the foot are less frequent. Ultrasonography with the Power Doppler (PDUS) and Color Doppler (CDUS) options usually shows no substantial abnormalities while clinical symptoms last. Healing symptoms are clearly visible in the form of increased number of vascular pulses within the tendon, and in the immediate vicinity of the tendon (12). Fig. 1, 2.

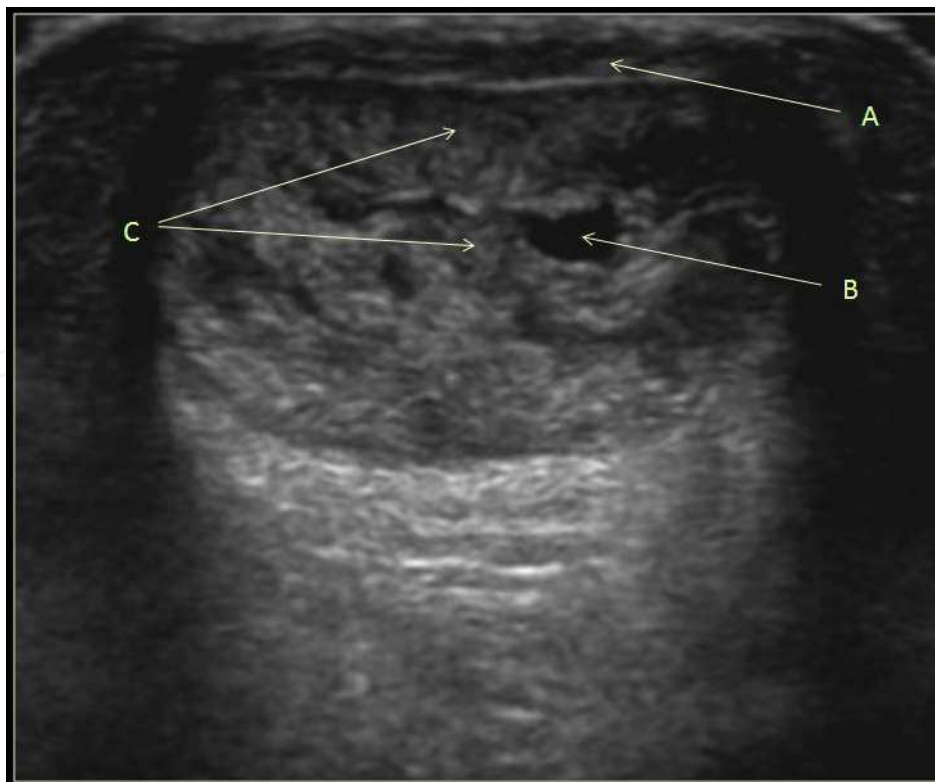

Fig. 1. Transverse US view of Achilles tendinopathy: A – peritendon thickening, B – area of fibrillar rupture, C – hypoechogenic foci.

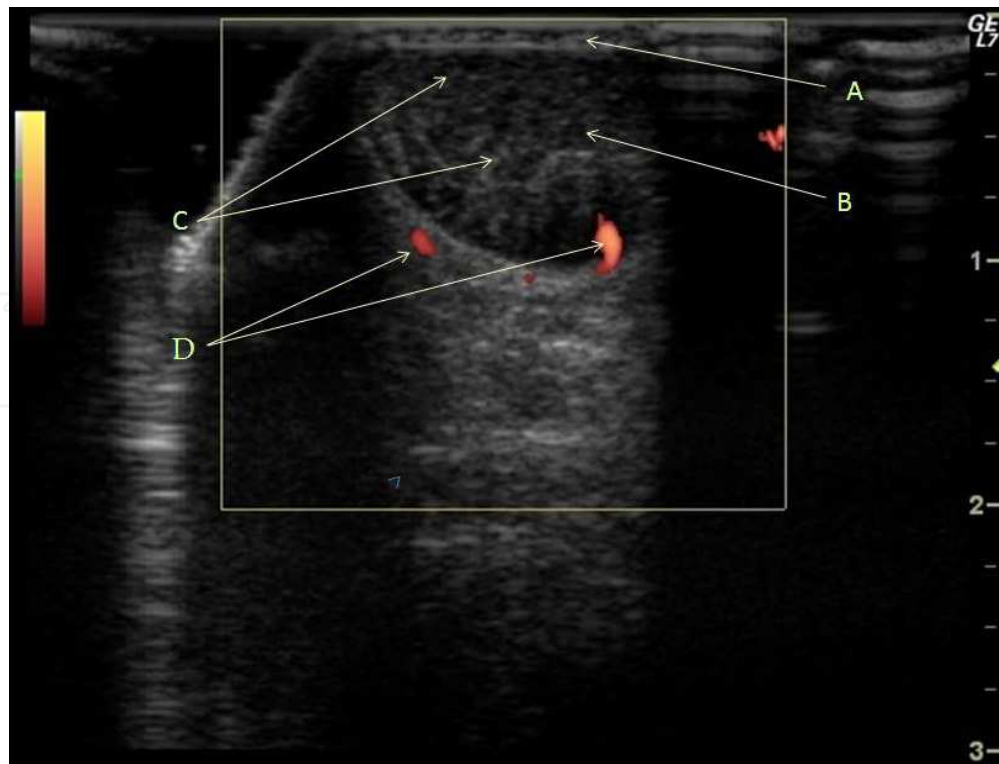


Fig. 2. Transverse PDUS view of Achilles tendinopathy: A – peritendon thickening, B – area of fibrillar rupture, C – hypoechogenic foci, D – vascular pulses.

Comparing with US studies, MRI scans are more sensitive in differentiating adjacent healthy and affected tissues. MRI scans allow the imaging of a selected area in various planes and a more detailed evaluation of the internal structure of the investigated organ. Its costs and limited availability make MRI scans useful only for the evaluation of cases that are doubtful in terms of diagnostics, or following various invasive treatments that may blur the ultrasonographic image (13).

#### 1.4 Treatment methods

Many authors stress the necessity to properly match the management method with the cause of tendinopathy, its severity and previously used therapies (14,15). Conservative management should be used for initial stages of progression of the disease, and mainly in the younger patients. The need to resort to surgery increases with the duration of the complaints, their intensity and the age of the patient (16,17). A complete management algorithm depending on the above mentioned criteria has been presented by Alfredson (18).

The management principle for every Achilles tendon tendinopathy is to discontinue previous motor activity at the origin of tendinopathy lesions, and resting of the patient.

Initial management should include stretching and eccentric training exercises. Appropriate footwear with heel elevation should be used, and the easiest way to achieve this is to insert a cork wedge into one's own shoe. With pain complaints resolved, the programme of returning to training should be modified. If such management proves ineffective, unloading with elbow crutches becomes necessary.

At the same time, various forms of physiotherapy are used, such as ultrasounds, magnetic fields, laser or ultrasonic shock wave (19). Some centres sometimes recommend massage and immobilisation in carefully selected orthoses. Cast immobilisation is rarely used.

In the event of a failure of the physiotherapy management methods, many patients undergo steroid injections into the affected areas in the vicinity of the calcaneal tendon. The alleviation of complaints reported following such management is temporary. As the nature of the lesions within the tendon has usually no inflammatory origin, it is difficult to expect the improvement to be long-lasting, as it only translates into reduced pain.

It is also sometimes recommended to proceed with injections of products causing obliteration of the vessels formed in the neovascularisation processes that are seen in the course of tendinopathy.

The inefficacy of subsequent treatment modalities, especially in middle and older age patients, leads to the performance of various surgical interventions. The value of surgical management is generally positively perceived by the patients, especially in subjects who had previously been treated without effect using other management methods (20,21).

We have implemented a different management method at our Centre. It consists in a local administration of autologous leukocyte- and platelet-rich plasma (L-PRP) under direct ultrasonographic imaging control into evidenced lesions within the calcaneal tendons (22).

## 2. Objective

The objective of this paper is to evaluate the efficacy of noninsertional Achilles tendinopathy treatment using local injections of autologous leukocyte- and platelet-rich plasma.

## 3. Material

Evaluation involved the treatment of 29 patients aged 24 through 53 years, 42 years on average. Patients included 11 women and 18 men. In 5 subjects, lesions involved bilateral calcaneal tendons. Therefore, 34 tendons were subjected to this treatment. Sport or motor activities exceeding the average loading level for a given age group were seen in 7 subjects. Metabolic abnormalities in the form of diabetes were noted in one patient.

The period of complaints preceding treatment with autologous leukocyte- and platelet-rich plasma ranged from 5 to 21 months, on average 14 months. L-PRP injections were used following failure of other forms of treatment in all subjects. Initially, immobilisation was used in 11 patients, and all subjects underwent various physiotherapy procedures. One-time steroid injections were given in 9 cases. The above patient characteristics indicate that some patients underwent various therapies at subsequent phases of the course of the disease. None of the previously used therapies proved effective in eliminating the tendinopathy symptoms. There were no periods of substantial reduction of complaints. The follow-up period for patients treated with L-PRP until their last follow-up visit exceeded 1 year in all subjects.

## 4. Method

Evaluation involved randomly selected patients among those reporting for treatment at the outpatient clinic of the hospital, presenting with pain of the posterior surface of calf



circumference. Based on an initial interview and physical examination, subjects with clinical features of noninsertional tendinopathy were selected. The main inclusion criteria were symptoms lasting time longer than 5 months and fail of previously employed non-invasive treatment modalities. Patients with insertional tendinopathy symptoms and those without previous courses of physiotherapy, rest, heel elevation and limb unload were excluded from the study and referred to these treatment forms.

All patients presented painful thickening of the Achilles tendon, at a level at least 2 cm above its insertion point into the calcaneal tubercle. There was evidence of painful restriction of plantar and dorsal flexion movements. Conserved ankle pronation and supination movements also caused pain in the peripheral section of the Achilles tendon. An objective functional evaluation was performed using the AOFAS scale for the posterior section of the foot, and using VISA-A score (23,24).

All the selected patients had radiograms of the ankle joint performed that also included the distal  $\frac{1}{2}$  of the calf, using standard radiographic projections. If radiograms were not showing lesions within the skeletal system, ultrasonographic evaluation was performed within the painful area of the calcaneal tendon, using a linear probe with frequencies of 12-15 MHz. Continuity of the entire tendon and its internal structure were verified using ultrasonography. The evaluation focused on seeking out focal continuity ruptures of the fibrillar tendon structure, determining the filling of empty inter-fibrillar spaces, and confirming the presence or absence of tendon oedema and its sheath. The freedom of tendon movement was assessed in a dynamic study. The intensity of vascular flow was evaluated using Power-Doppler within the tendon, its sheath and in its direct vicinity, including the para-insertional area on the calcaneal tubercle and the Kager's triangle.

Peripheral blood morphology and biochemistry tests were performed in subjects to exclude generalised inflammatory symptoms. Fulfilment of all diagnostic criteria allowed the patient to be included in the therapeutic group, upon receipt of the patient's informed consent.

Peripheral blood was taken from subjects selected for treatment, and a thrombocyte preparation was prepared according to the recommendations of the separator manufacturer. The suspension thus obtained was injected under ultrasonographic control into hypoechogenic foci within the area of affected tendon. Fig. 3, 4.

For 3 days following the injection, subjects were recommended to unload the limb, use elbow crutches, and elevate the limb. Within the next 2 weeks, patients used walking sticks, walking with partial loading of the anterior section of the foot, performed passive motor exercises of the ankle joint. During the following 2 weeks, the loading of the foot was gradually increased with concomitant elevation of the heel in the subject's own footwear, with continued passive and active exercises with limb unloading. At 6 weeks following the injection, patients started full loading of the limb without walking sticks. Heel elevation was maintained.

6 weeks after injection, all patients underwent another evaluation of the foot performance based on the AOFAS criteria and with the VISA-A performance scales. A follow-up ultrasonographic evaluation was also performed at that time. The same features were evaluated as during the baseline evaluation. Normal daily activity was recommended if fibrillar regeneration symptoms were seen. Periodic heel elevation was still maintained. Patients were advised against motor activity, even at recreational levels.

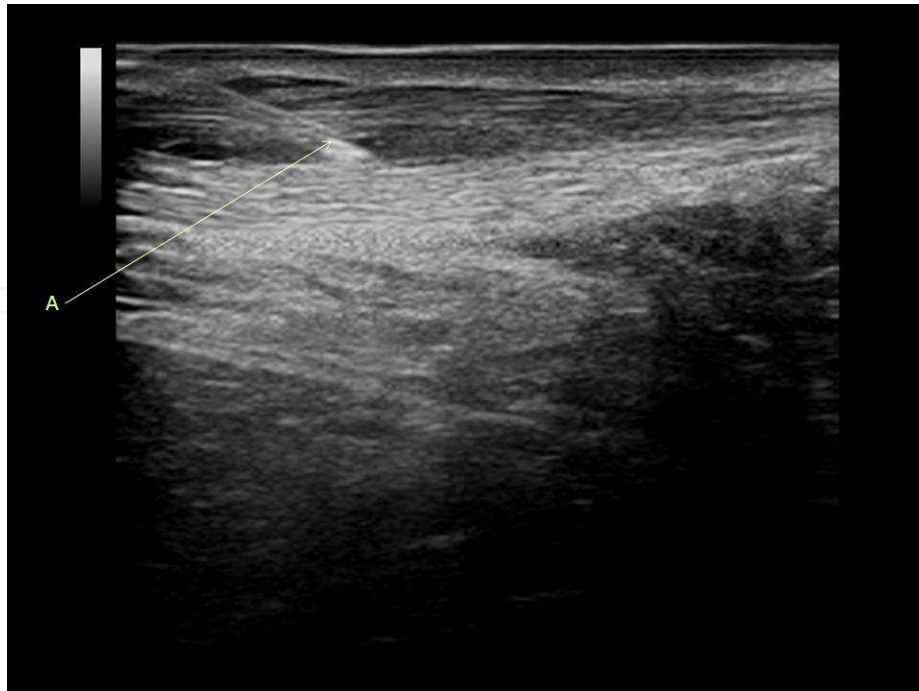


Fig. 3. US longitudinal view demonstrating the needle insertion into the tendon: A – needle.

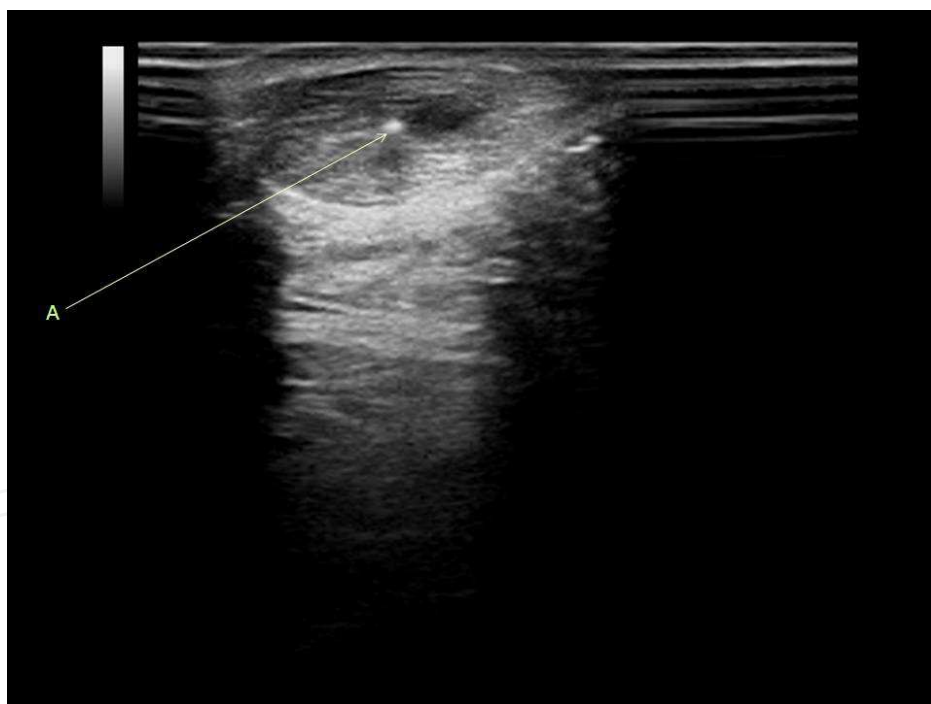


Fig. 4. US transverse view demonstrating the needle insertion into the tendon: A – needle.

Injections were repeated in patients with limited progression of healing reactions seen at ultrasonography evaluations. In the case of 15 treated patients it proved necessary to repeat the injections. Subject who did not require repeat administrations of the preparation between 6 and 12 weeks after the procedure returned to their normal activities, as conducted prior to the onset of the symptoms. Patients who received repeat injections underwent rehabilitation in the same manner as following the first injection.



Subsequent clinical evaluations using functional performance scales and ultrasonographic examinations were conducted in all treated patients 6 and 12 weeks after treatment, as well as 6 and 12 months after treatment. Follow-up continuity is ensured through follow-up visits scheduled once a year.

## 5. Results

Before starting the therapy, the values for functional assessment using the AOFAS scale for the posterior section of the foot ranged from 28 to 69 points, with 47 points on average. Using the VISA-A scale, patients achieved scores ranging from 6 to 34, with an average of 21 points. Ultrasonographic evaluations in all subjects showed spindle-like thickening of the tendon, also involving the peritendon in 17 cases. Numerous intratendinous ruptures were seen in 8 patients. Isolated fibrillar rupture lesions were observed in 14 other subjects. All evaluated subjects showed hypoechogenic areas within these lesions, 7 of them showed only small hypoechogenic foci. 5 subjects presented a significant restriction of tendon mobility at dynamic evaluation. Four subjects had evidence of foci with significantly reduced echogenicity, potentially consistent with intratendinous hyalinisation. These were patients who had previously received steroid injections into the affected area. There were no patients with inflammatory reaction within the Achilles bursa. Studies with the Power Doppler option showed no evidence of an increased blood supply within the lesions area.

After 6 weeks, AOFAS scores ranged from 64 to 84 points, with an average of 76. VISA-A scores were in the range between 27 and 58 points, 44 on average. Ultrasonographic evaluation in 21 patients showed persistent thickening of the tendon at the location of intratendinous ruptures. The thickness of the peritendon remained increased in 14 subjects. In most patients a discreet reduction of the size of hypoechogenic foci was seen. No alteration of the tendon movement range was seen in 3 patients. In 23 subjects, a substantial increase of the number of vascular flow signals was seen, as compared with baseline.

Evaluations at 12 weeks showed AOFAS scores in the range between 68 and 100 points, 90 on average, and VISA-A scores ranging from 48 to 98, with an average of 87 points. Regression of the spindle-like tendon thickening was seen in ultrasonographic evaluations, observed in 11 subjects. In 6 subjects, a decreased thickness of the peritendon was noted, as compared to the evaluation at 6 weeks. In 13 subjects, the areas of fibrillar continuity rupture faded out. In 11 subjects, small hypoechogenic areas were seen, reduced in size as compared with previous evaluations. Four tendons showed evidence of residual presence of fibrillar rupture areas. Power Doppler evaluation showed an increased number of vessels within the tendinopathy area.

After 6 months, AOFAS scores ranged from 72 to 100 points, with an average of 91. VISA-A scores ranged from 64 to 100 points, with an average of 90 points. 25 subjects were freed from local pain and thickening of the Achilles tendon. These tendons showed reduced thickness at ultrasonographic evaluation. A reduction of the peritendon thickness was also noted. Its previous abnormal thickening was only seen in 3 subjects. These subjects also had isolated intratendinous hypoechogenic foci. Two subjects still showed discreet evidence of rupture of the tendon fibres. All treated patients showed normal, symmetrical mobility of the Achilles tendon. The number of vascular signals within the tendon itself was reduced,

but remained unchanged within the vicinity of the tendon, as compared with the previous evaluation.

After a year, AOFAS scores ranged from 80 to 100 points, with an average of 94 points. Patients achieved VISA-A scores in the range of 78-100 points, and an average of 93 points. Ultrasonographic evaluations showed thickening of the tendons in 3 subjects. Peritendon thickening also persisted in 3 subjects. There were no intratendinous fibrillar ruptures, however small, focal reduced echogenicity areas were still seen in 3 evaluations. PDUS studies showed a further decrease of the number of vascular signals within the tendons and their vicinity.

Further annual evaluations for up to 4 years showed neither a recurrence of the complaints nor a deterioration of clinical assessment scores in any of the evaluated patients. All treated patients achieved pain resolution and full motor function in everyday activities. Periodic pain following sports was seen in 7 patients, however at reduced levels, as compared with the pretreatment period.

## 6. Discussion

Eccentric exercises recommended by Woodley and Fahlstrom did not lead to a cure in our patients in their management prior to L-PRP injections (25,26). Based on a review of 697 bibliographic items, Rompe assessed the value of NSAIDs administration, steroid injections, heel supports and various forms of physical therapy in the treatment of Achilles tendinopathy (27). He concluded that their efficacy is similar to that of the placebo effect, while the results are comparable to those achieved in groups of subjects receiving no treatment at all.

Surgical management methods proposed by Schepisis have not been verified in our material, as we have not used surgical management (5). Similarly, we are unable to evaluate the efficacy of endoscopic management proposed by Steenstra (28).

Treatment of chronic tendinopathy of the calcaneal tendon using L-PRP injections provided alleviation or withdrawal of disease symptoms in all our patients. Observations made by other authors are thus confirmed; other authors noticed an improvement of tendon repair capacities following local administration of growth factors.

Kurtz reported anti-inflammatory effects of IGF-1 in the healing of sectioned tendons, while Sanchez reported a similar effect following the application of PRGF (29,30). Anitua reported in studies conducted in sheep that blood platelet concentrates administered onto fibrin matrices accelerate and shape the proliferation of active tendon cells and stimulate neovascularisation (31).

Schnabel et al. have shown in experimental studies on a model of equine tendons that an increased concentration of blood platelets and growth factors they release causes an increased expression of genes responsible for tendon repair (32). Mishra presented promising experiences in the treatment of tendinopathy of wrist and hand extensor tendon insertion points in the area of the lateral epicondyle of humerus using buffered platelet-rich plasma (33).

On the other hand, the observation made in Power Doppler ultrasonographic evaluations is puzzling. Baseline evaluations have shown no differences in the number of vascular flow

signals as compared to the healthy side. In subsequent follow-up evaluations after 6 and 12 weeks, the number of vascular flow signals gradually increased, and the process did not stop in evaluations performed after 24 weeks within tissues surrounding the tendons. However, at that time, the number of vascular impulses within the tendons themselves was significantly inferior. Knoblach reports that micro-circulation anomalies may be a cause for developing tendinopathy (34). He considers that extra-capillary venous hyperaemia is one feature of this process, without impact, however, on the tissue oxygenation levels.

Resolving clinical symptoms, increasing tendon thickness at rupture sites, and a decreased thickening of the tendon and peritendon, with fading out of hypoechogenic foci, as observed in ultrasonography evaluations, show substantial repair efficacy following local injection of autologous thrombocyte gel into the affected area of calcaneal tendon. The lack of appropriate number of the randomised controls is the week point of the study. Good and very good results after L-PRP injections were gained in the group of patients with affected Achilles tendons who had previously employed heel elevation, rest, limb unloading or physiotherapy and didn't improved. In this term, the role of these treatment modalities in the course post L-PRP injections presumably is small and were advised for pain and mechanical protection or patient's comfort soon after needle manipulation around the heal. The statistically significant increase in functional assessment scores, with simultaneous complete absence of complications, show the high therapeutic value of this method.

## 7. Conclusions

1. In author's opinion local administration of autologous platelet-rich plasma in chronic noninsertional tendinopathy of the Achilles tendon provides substantial reduction and in most cases a complete withdrawal of the disease symptoms.
2. The treatment results of noninsertional Achilles tendinopathy with direct L-PRP injection into affected area are higher then other non-invasive treatment modalities.
3. Positive early and medium term treatment results require further follow-up and well controlled, randomised studies.

## 8. References

- [1] Mahieu NN, Witvrouw E, Stevens V et al. *Intrinsic Risk Factors for the Development of Achilles Tendon Overuse Injury: A Prospective Study*. Am J Sports Med. 2006; 34:226-35
- [2] Clement DB, Taunton JE, Smart GW, McNicol KL. *A survey of overuse running injuries*. Physician Sportsmed. 1981; 9:47-58
- [3] Astrom M, Rausing A. *Chronic achilles tendinopathy: a survey of surgical and histopathic findings*. Clin Orthop Rel Res. 1995; 316:151-64
- [4] Puddu G, Ippolito E, Postucchini F. *Classification of Achilles Tendon Disease*. Am J Sports Med. 1976; 4:145-50
- [5] Schepsis AA, Jones H, Haas AL. *Achilles Tendon Disorders in Athletes*. Am J Sports Med. 2002; 30:287-305
- [6] Clancy WG Jr. *Tendon Trauma and Overuse Injuries in Sports-Induced Inflammation: Clinical and Basic Science Concepts*. Chicago, AAOS, 1989
- [7] Leach RE, Jones S, Wasilewski S. *Achilles Tedinitis*. Am J Sports Med. 1981; 9:93-8

- [8] Hart DA, Frank CB, Bray RC. *Inflammatory processes in repetitive motion and overuse syndromes: potential role of neurogenic mechanisms in tendons and ligaments*. In: Gordon SL, Blair SJ, Fine LJ, eds. *Repetitive motion disorders of the upper extremity*. Rosemont, IL: American Academy of Orthopaedic Surgeons. 1995, 247-62
- [9] Scott A, Khan KM, Cook JL et al. *What do we mean by the term "inflammation"? A contemporary basic science update for sports medicine*. *Br J Sports Med*. 2004; 38:372-80
- [10] Alfredson H, Thorsen K, Lorentzon R. *In situ microdialysis in tendon tissue: high levels of glutamate, but not protoglandin E2 in chronic Achilles tendon pain*. *Knee Surg Sports Traumatol Arthrosc*. 1999; 7:378-81
- [11] Fox JM, Blazina ME, Jobe FW et al. *Degeneration and rupture of the Achilles Tendon*. *Clin Orthop*. 1975; 107:221-4
- [12] Gawęda K, Tarczyńska M, Krzyżanowski W. *Treatment of Achilles Tendinopathy with Platelet-Rich Plasma*. *Int J Sports Med*. 2010; 31:577-83
- [13] Shalabi A, Kristoffersen-Wilberg M, Svensson L et al. *Eccentric Training of the Gastrocnemius-Soleus Complex in Chronic Achilles Tendinopathy Results in Decreased Tendon Volume and Intratendinous Signal as Evaluated by MRI*. *Am J Sports Med*. 2004; 32:1285-96
- [14] Kannus P. *Tendon pathology: basic science and clinical applications*. *Sports Exerc Inj*. 1997; 3:62-75
- [15] Kader D, Saxena A, Movin T et al. *Achilles tendinopathy: some aspects of basic science and clinical management*. *Br J Sports Med*. 2002; 36:239-49
- [16] Paavola M, Kannus P, Paakkala T et al. *Long-term prognosis of patients with Achilles tendinopathy. An observational 8-year follow-up study*. *Am J Sports Med*. 2000; 28:634-42
- [17] Kvist M. *Achilles tendon injuries in athletes*. *Sports Med*. 1994; 18:173-201
- [18] Alfredson H, Cook J. *A treatment algorithm for managing Achilles tendinopathy: new treatment options*. *Br J Sports Med*. 2007; 41:211-6
- [19] Luscombe KL, Sharma P, Maffulli N. *Achilles Tendinopathy*. *Trauma*. 2003; 5:215-25
- [20] Vulpiani MC, Guzzini M, Ferretti A. *Operative Treatment of Chronic Achilles Tendinopathy*. *Int Orthop*. 2003; 27:307-10
- [21] Maffulli N, Testa V, Capasso G et al. *Results of Percutaneous Longitudinal Tenotomy for Achilles Tendinopathy in Middle- and Long-distance Runners*. *Am J Sports Med*. 1997; 25:835-40
- [22] Ehrenfest DM, Rasmusson L, Albrektsson T. *Classification of platelet concentrates: from pure platelet-rich plasma (P-PRP) to leucocyte- and platelet-rich fibrin (L-PRF)*. *Trends Biotechnol*. 2009 Mar; 27(3):158-67
- [23] Kitaoka HB, Alexander JJ, Adelaar RS et al. *Clinical Rating System for the Ankle-Hindfoot, Midfoot, Hallux and Lesser Toes*. *Foot and Ankle International*. 1994; 15:7
- [24] Robinson JM, Cook JL, Purdam C et al. *The VISA-A Questionnaire: A valid and reliable index of the clinical severity of Achilles tendinopathy*. *Br J Sports Med*. 2001; 35:335-41
- [25] Woodley BL, Newsham-West RJ, Baxter GD et al. *Chronic Tendinopathy: Effectiveness of Eccentric Exercise*. *Br J Sports Med*. 2007; 41:188-98
- [26] Fahlstrom M, Jonsson P, Lorentzon R, Alfredson H. *Chronic Achilles Tendon Treated with Eccentric Calf-Muscle Training*. *Knee Surg Sports Traumatol Arthrosc*. 2003; 11:327-33

- [27] Rompe JD, Nafe B, Furia JP, Maffulli N. *Eccentric Loading, Shock-Wave Treatment or a Wait-and-See Policy for Tendinopathy of the Main Body of Tendon Achilles: A Randomized Controlled Trial*. Am J Sports Med. 2007; 35:374-83
- [28] Steenstra E, van Dijk CN. *Achilles Tendoscopy*. Foot Ankle Clin. 2006; 11:429-38
- [29] Kurtz CA, Loebig TG, Anderson DD et al. *Insulin-Like Growth Factor I Accelerates Functional Recovery from Achilles Tendon Injury in a Rat Model*. Am J Sports Med. 1999; 27:363-9
- [30] Sanchez M, Anitua E, Azofra J et al. *Comparison of Surgical Repaired Achilles Tendon Tears Using Platelet-Rich Fibrin Matrices*. Am J Sports Med. 2007; 35:245-51
- [31] Anitua E, Sanchez M, Zaldueño M et al. *Autologous Fibrin Matrices: a Potential Source of Biological Mediators that Modulate Tendon Cell Activities*. J Biomed Mater Res A. 2006; 77:285-93
- [32] Schnabel LV, Mohammed HO, Miller BJ et al. *Platelet Rich Plasma (PRP) Enhances Anabolic Gene Expression Patterns in Flexor Digitorum Superficialis Tendons*. J Orthop Res. 2007; 25:230-40
- [33] Mishra A, Pavelko T. *Treatment of Chronic Elbow Tendinosis With Buffered Platelet-Rich Plasma*. Am J Sports Med. 2006; 10:1-5
- [34] Knobloch K, Kraemer R, Lichtenberg A et al. *Achilles Tendon and Paratendon Microcirculation in Midportion and Insertional Tendinopathy in Athletes*. Am J Sports Med. 2006; 34:92-7.

IntechOpen





## **Achilles Tendon**

Edited by Prof. Andrej Cretnik

ISBN 978-953-51-0264-9

Hard cover, 144 pages

**Publisher** InTech

**Published online** 08, January, 2012

**Published in print edition** January, 2012

Achilles tendon has always attracted a great attention. Its disorders include various problems from pain and swelling with bumps to functional impairment or even ruptures. Debates concerning aetiology and optimal treatment are still going on. A lot of efforts and research have already been put on to find the answers to unsolved problems and this book is an attempt to share (some of) these findings to the readers. If only one of the papers helps the therapists or patients in understanding and solving their problems, we will consider that the mission of the book was accomplished.

### **How to reference**

In order to correctly reference this scholarly work, feel free to copy and paste the following:

Marta Tarczyńska and Krzysztof Gawęda (2012). Noninsertional Achilles Tendinopathy - Treatment with Platelet Rich Plasma (PRP), Achilles Tendon, Prof. Andrej Cretnik (Ed.), ISBN: 978-953-51-0264-9, InTech, Available from: <http://www.intechopen.com/books/achilles-tendon/noninsertional-achilles-tendinopathy-treatment-with-platelet-rich-plasma-prp->

**INTECH**  
open science | open minds

### **InTech Europe**

University Campus STeP Ri  
Slavka Krautzeka 83/A  
51000 Rijeka, Croatia  
Phone: +385 (51) 770 447  
Fax: +385 (51) 686 166  
[www.intechopen.com](http://www.intechopen.com)

### **InTech China**

Unit 405, Office Block, Hotel Equatorial Shanghai  
No.65, Yan An Road (West), Shanghai, 200040, China  
中国上海市延安西路65号上海国际贵都大饭店办公楼405单元  
Phone: +86-21-62489820  
Fax: +86-21-62489821

© 2012 The Author(s). Licensee IntechOpen. This is an open access article distributed under the terms of the [Creative Commons Attribution 3.0 License](https://creativecommons.org/licenses/by/3.0/), which permits unrestricted use, distribution, and reproduction in any medium, provided the original work is properly cited.

IntechOpen

IntechOpen