

We are IntechOpen, the world's leading publisher of Open Access books Built by scientists, for scientists

6,900

Open access books available

186,000

International authors and editors

200M

Downloads

Our authors are among the

154

Countries delivered to

TOP 1%

most cited scientists

12.2%

Contributors from top 500 universities



WEB OF SCIENCE™

Selection of our books indexed in the Book Citation Index
in Web of Science™ Core Collection (BKCI)

Interested in publishing with us?
Contact book.department@intechopen.com

Numbers displayed above are based on latest data collected.
For more information visit www.intechopen.com



Total Hip Arthroplasty After Previous Acetabulum Fracture Surgery

Babak Siavashi

*Tehran University of Medical Sciences, Sina Hospital
Iran*

1. Introduction

In recent years because of more car accidents and high energy traumas, acetabulum and pelvic fractures are happened more.

Because acetabulum is a part of hip joint, its fracture is important. At first, it is a weight bearing joint and it is involved in approximately all movements of body. In daily living, it must tolerate about 5-7 times body weight. For example, in the position of one leg stance about 3.5 times body weight is transmitted to hip joint. Even in sitting position and also in supine position and straight leg rising, hip joint is under pressure. Because it is a weight bearing joint, it should be smooth without step in articular surface to be harmonic and congruent with the head of femur. Hip joint is a ball and socket joint with wide range of motion. Lower limb is attached by it to body and because of long lever arm of femur and tibia, transmitted force to joint is extremely high.

In the past, acetabulum surgery and fixation of it was not as common as today. Many patients were treated with long time skeletal traction (for about 3 months). This type of treatment has some complications. The joint is not reduced anatomically and articular surface is not smooth and a step remains in joint surface which lead to destructive joint disease (DJD) and arthrosis after union of fracture. It means that it is united in malreduced position ,therefore malunion occurs. In some instances ,joint particles do not come near each other even with heavy skeletal traction so there may be nonunion in some regions of acetabulum and a defect may remain in a wall or column of acetabulum. If in the future this patient need total joint replacement, there may be wide range of acetabular deficiencies from cavitary and segmental deficiencies to the most sever one named pelvic discontinuity which should be repaired before implantation of acetabular cup. This is a complicated and difficult surgery to reconstruct acetabulum and prepare it for total hip arthroplasty. Long term skeletal traction has some other complications. Bed rest for a long period of time may lead to bed sore on buttocks and sacrum and discomfort. Muscle atrophy and weakness around hip and knee joint appears after complete bed rest for a long time. Kidney stones and gastrointestinal malfunction are other complications of long term skeletal traction.

Because of social deprivation, psychological problems may be seen in an active patient who should rest for about 3 months in bed for skeletal traction. But, with open reduction and internal fixation of acetabulum fracture, patient can be out of bed with crutches and be present in community .Also ,he or she can move his or her joints and prevent muscle atrophy.

For these reasons, open reduction and internal fixation of acetabulum fracture is advised in recent years. The philosophy of this procedure is not only restoration of smooth articular surface and cartilage of hip joint, but also it brings different parts of acetabulum near each other for union with each other. If in future because of joint destruction and arthrosis total joint replacement is necessary, there will be a good and stable bone stock for implantation of acetabular cup and there will be no missed segment or pelvic discontinuity.

But unfortunately, acetabulum surgery and internal fixation of columns and walls of it is not free of complications. Infection, sciatic nerve injury, avascular necrosis (AVN) of head of femur and late destructive joint disease (DJD) of hip and leg length discrepancy (LLD) are some examples. Some of these complications have no definitive treatment (like sciatic nerve injury) but other complications as DJD and AVN of head of femur can be managed in the best way with total joint replacement.

But hip joint replacement after previous operation for internal fixation of fractured acetabulum is not a simple and straight forward operation and needs special attentions. The aim of this chapter is to discuss about indications of total hip arthroplasty after acetabulum fracture surgery, pre operative planning, approaches and needed equipments and post operative rehabilitation after this kind of total joint replacement.

2. Indications of total hip arthroplasty after acetabulum fracture fixation

In post operative period, acutely or chronically, there may be some complications which may be solved by total hip replacement. One of them is avascular necrosis of head of femur. Some acetabular fractures are truly fracture dislocations and even after reduction and rigid fixation, because of injury to vascular supply of head of femur, necrosis and collapse of head of femur develop in early period or as a late complication. Specially with posterior approach to hip joint (Kocher langen beck approach), there may be injury to main vascular supply of head of femur (medial femoral circumflex artery). With disruption of blood input to the head of femur, signs and symptoms of necrosis will be appeared. Because of rapid progression of collapse and joint destruction in these cases, minor surgeries like core decompression and osteotomies are ineffective and finally total joint replacement is inevitable.

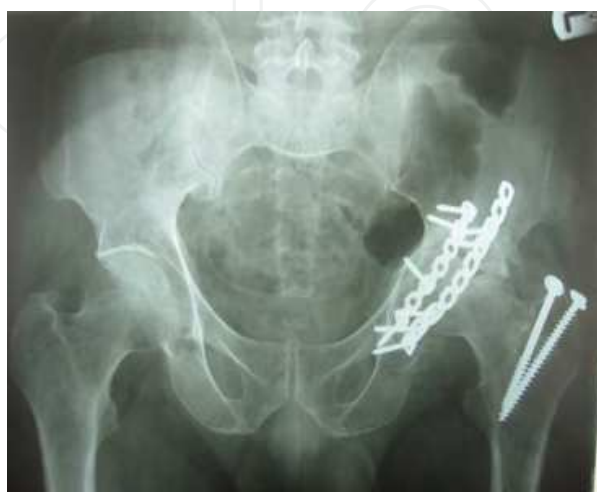

Fig. 1. Avascular necrosis of head of femur.

One of the most common complications of acetabular fractures are destructive joint disease. Because even with surgery and open reduction of acetabulum, anatomic reduction may not be possible(after some days because of contracture of soft tissues, joint particles may not come near each other and perfect reduction may not be achieved) and remaining steps in joint surface may lead to destructive joint disease after union of fracture and weight bearing on lower extremity.

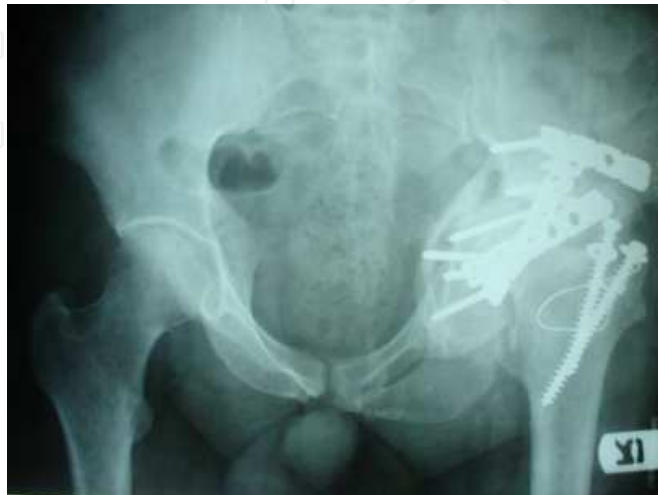

Fig. 2. Destructive joint disease after acetabulum fracture.

Painful joint after acetabulum fracture may be due to chondrolysis of articular cartilage and may be severe enough to be treated with total joint replacement.

These are main indications for total hip replacement after fixation of acetabulum fracture but there are some other indications for total hip replacement .

Infection and resorption of head of femur after acetabulum surgery can be treated with debridement and irrigation and intravenous antibiotic therapy. After complete eradication of infection, total hip replacement can be done.

In some situations, internal fixation may be failed. It may be treated with refixation of fracture but sometimes with fixation failure there may be injury to the head of femur or acetabular walls and reconstruction of them may be impossible and joint replacement may be the best treatment .

Leg length discrepancy may appear after collapse of femoral head after avascular necrosis. So, leg length discrepancy itself is not the indication of joint replacement .But in parallel with treatment of avascular necrosis of femoral head, length of lower extremity can be increased and leg length discrepancy can be corrected.

3. Preoperative planning

Total hip arthroplasty after surgical fixation of acetabular fracture is a technical demanding operation. So, it should be done after complete assessment of both patient and bony pelvis.

At first, infection as a cause of hip destruction and resorption of head of femur should be ruled out. Complete blood cell count (CBC), Erythrocyte sedimentation rate (ESR) and C

4. Approaches

Factors that guide the surgeon to choose the best approach for total hip arthroplasty after acetabulum surgery are : 1- previous approach to hip joint for acetabulum fixation 2- deficiencies in anterior or posterior wall or column of acetabulum and need to reconstruct them 3- surgeon experience 4- condition of soft tissue and skin

Because of previous surgery, there is fibrosis in the tract of incision and around hip joint. This fibrotic tissue in one hand, limits soft tissue mobility and make the operation more difficult and on the other hand, increases bleeding in the field of operation. Because of tightness in the soft tissue and limited exposure, sometimes it is better to do osteotomy of greater trochanter. This osteotomy not only makes exposure better and wider, but also helps the surgeon to save abductors. Also, sometimes for better exposure of the acetabulum for preparation of it for implantation of acetabular cup, there may need to forcefully retract the muscles. This violence to muscles can damage them and predispose infection. Forceful exposure may transmit the energy to shaft or proximal femur and break them.

In my opinion, exploration of sciatic nerve is not always necessary. Because of fibrotic tissue around sciatic nerve from previous operation and exploration of it, dissection of sciatic nerve is very difficult and dangerous, it may itself damage the fibers of nerve. For this reason, after exposure of hip joint and identification of remaining capsule, by staying close to bone and retraction of sciatic nerve with the fibrotic tissue around it, acetabulum can be identified and can be prepared for implantation of acetabular cup.

If it is not necessary for preparation of acetabulum for implantation of cup, it is not wise to search for all of hardwares (plate and screws) for fixation of acetabulum fracture and their removal. Because this not only damage more soft tissue and weaken posterior support of hip joint and predisposes the prosthesis to dislocation, but also, it may destroy bony support and bone stock of acetabulum and make implantation of cup weaker than usual.

Because of difference in the composition of metal back of acetabular cup and the plate and screws for fixation of acetabulum fracture, there may be galvanic wear of implants and cup of acetabulum. This is a cause of sooner than normal loosening of prosthesis.

Some times, before reaming acetabulum, no hardware or screws are visible behind cartilage of hip joint. After first or second ream, screws come in the field and appear and make more reaming impossible. In this manner, screw or plate removal is necessary.

After exposure of hip joint and acetabulum, union and competency of posterior column and wall should be checked with a probe so the surgeon should be sure about the stability of peripheral ring of acetabulum and its boundaries before implantation of acetabular cup. If the fixation is imperfect, so re fixation and plating and bone grafting may be necessary.

5. Equipments

If it is possible, because of lower age of patients in this category, it is better to use cementless cup and cementless stem for total hip arthroplasty. But in some situations, it may be better to use cemented cup. For example, in deficient posterior wall or column and reconstructions

of them with structural bone (allograft or autograft), if it is large and bone contact between host bone and cup is minimal (less than 30%), it may compromise osteointegration and also the cup can not be inserted with press fit technique, so cemented cup is preferred. It is accepted that if more than 1/3 of cup is in contact with graft, it is better to use cemented prosthesis. About femoral stem, because of younger age of these patients, nearly always it is better to use cementless stems.

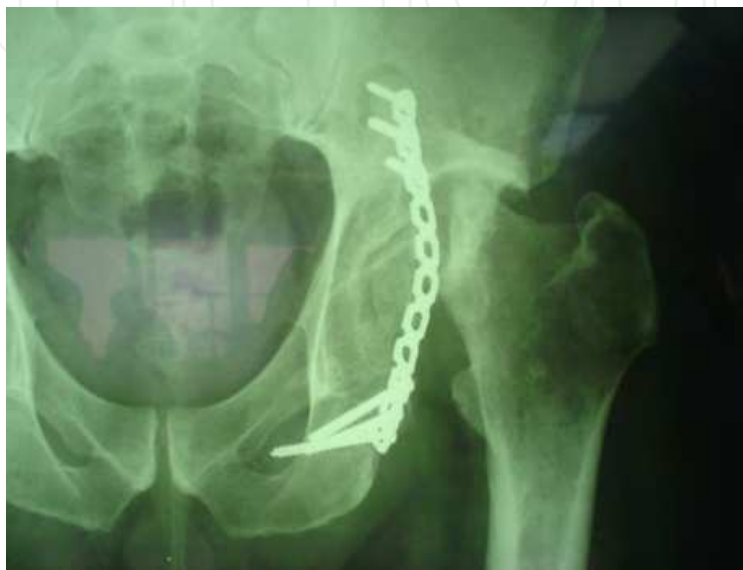

Fig. 4. bone defect of acetabulum.

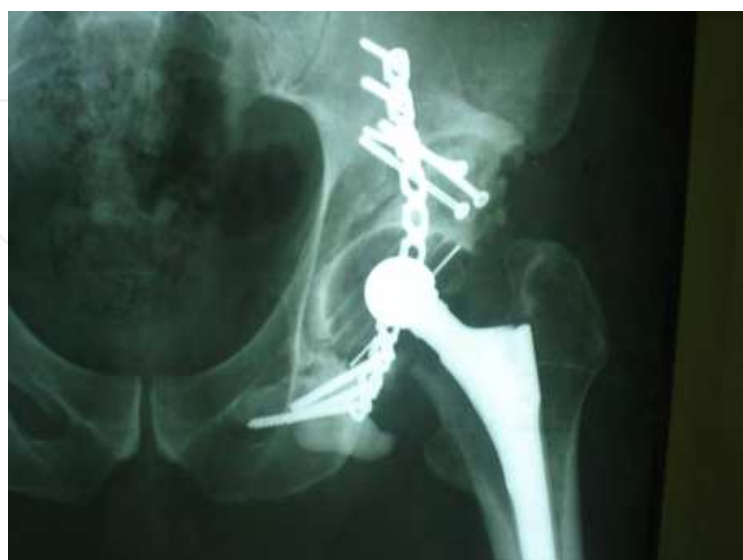

Fig. 5. reconstruction of defect with bone graft and cemented cup.

If trochanteric osteotomy has been done for previous acetabulum surgery, screw removal is not necessary always for insertion of femoral stem. Surgeon can start preparation of femur for insertion of femoral stem, if the screws are found in the way of broaches, then removal of screws should be done.

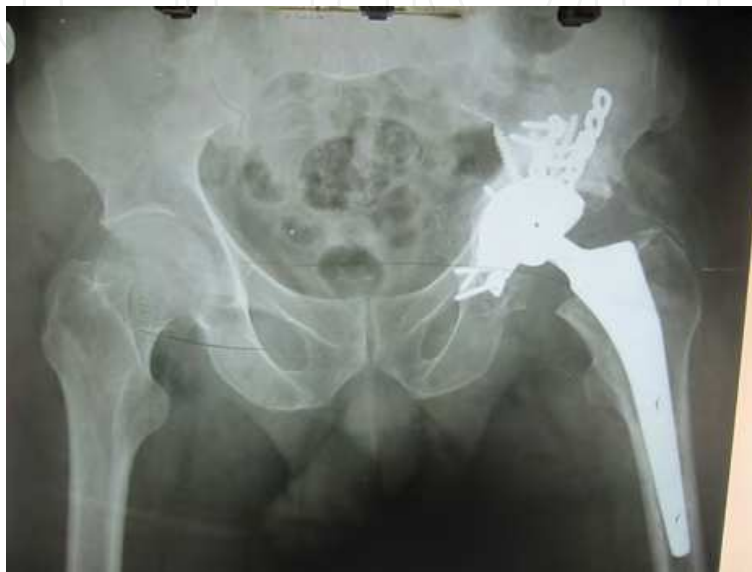

Fig. 6. Cement less cup and cementless stem.

Because removing screws which are inserted for fixation of greater trochanter may damage some fibers of abductor muscles, so, it is better to leave screws in place unless they are located in the tract of insertion of femoral stem.

In rare situations, if even largest cup cannot cover the whole periphery of acetabulum, it may be necessary to use reinforcement acetabular rings or cages. If it should be done, after implantation of cages and fixation of it to iliac bone, behind it, particles of bone grafts (mostly allograft), should be inserted and then cemented cup should be used inside the ring.

If medial wall is deficient, it should be covered with mesh and over it particulated chips bone (allograft or autograft) should be inserted and then acetabular cup or reinforcement ring should be used.

In some cases, hip arthroplasty may be necessary because of absorption of head of femur after avascular necrosis of head. In these cases, even acetabular cartilage seems normal, it is better to do total hip replacement instead of bipolar prosthesis. Because of younger age of these patients and higher demand of them, wear of acetabulum progresses rapidly and another surgery to change bipolar to total hip arthroplasty may be necessary soon.

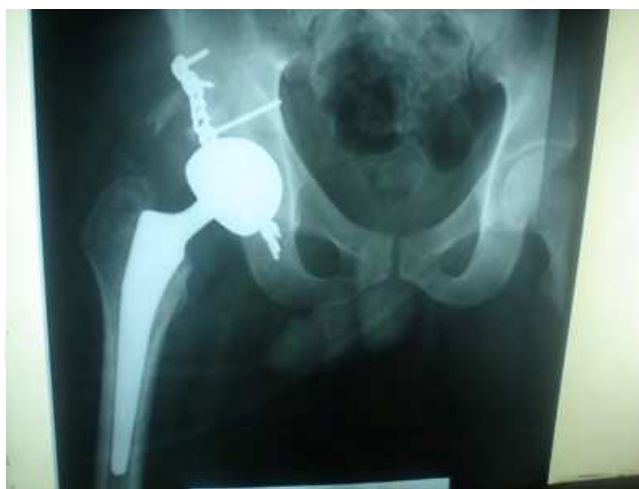

Fig. 7. Bipolar prosthesis for avascular necrosis of head of femur after acetabulum fracture fixation.

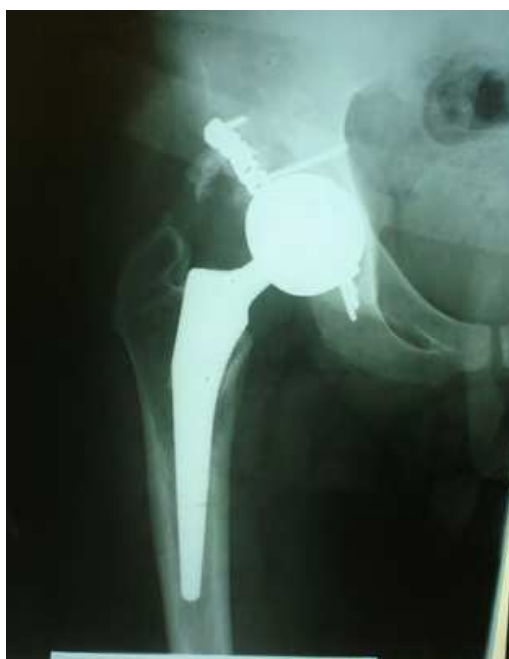

Fig. 8. Rapid wear of acetabulum with bipolar prosthesis (after 5 months).

6. A kind of revision surgery

As it shows, total hip arthroplasty after previous acetabulum surgery is a kind of revision surgery. Because there is a large amount of fibrotic tissues remaining from previous surgery and previous approaches, exposure is limited. Also, there are various defects of walls or columns of acetabulum. Some of these defects are created from resorption of bone and some are created during new exposure and device removal.

Rate of dislocation of prosthesis is higher than primary arthroplasties in these cases as in revision total hip arthroplasties. Also, there is higher risk of infection and sciatic nerve palsy.

These similarities should alert both the surgeon and the patient to be realistic about this operation and preoperative discussion is mandatory for reaching the best results.

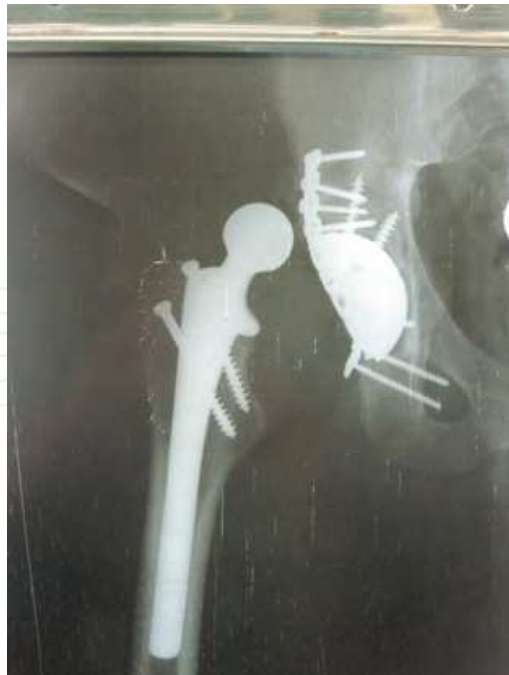

Fig. 9. Dislocation of total hip prosthesis.

7. Post operation period

As other total hip arthroplasties, after operation and before full clearance of anesthesia and sedation, it is wise to use abduction pillows between two legs. If trochanteric osteotomy has been done or if there is weakness of abductor muscles, then for a period of time (approximately 3 months) abduction brace is useful. It not only prevents adduction of lower extremities, but also can limit flexion. With limitation of adduction and flexion, the position of dislocation can be prevented. Because there is no capsule of hip joint and there is deficient and damaged posterior soft tissues after several approaches and operations, hip may be unstable in some degrees of flexion so limitation of flexion while posterior soft tissues are repaired and strong fibrosis develop in the field, is useful.

Because of using cementless prosthesis or using bone grafts for reconstruction of acetabulum, nearly always it is not possible to permit patient to have full weight bearing on his leg. Therefore, we advise touch weight bearing postoperatively.

8. Attention

Risk factors of acetabulum fracture which after fixation may end to total hip replacement seems to be the following items:

1. Posterosuperior wall fracture
2. Posterior wall and column fracture
3. Trochanteric osteotomy
4. Nonanatomic reduction
5. Sever primary displacement of fragments
6. Delayed surgical fixation of acetabulum fracture
7. Comminuted fractures with several particles
8. Intraarticular placement of screws

Fractures of posterosuperior wall of acetabulum may lead to total hip replacement more than fracture of direct posterior wall fracture.

The underlying reasons for this are :

- a. Posterosuperior fragment is involved more than posterior wall with weight bearing, so the quality of its reduction is more critical for future destructive joint disease than pure posterior wall segment
- b. Reduction and fixation of posterosuperior segment needs more dissection of soft tissue and release of surrounding tissues and may compromise blood supply to the head of femur (may incidentally damage articular supply of head of femur)
- c. For better exposure of posterosuperior wall of acetabulum, trochanteric osteotomy is more needed. This osteotomy potentially may injure vascular supply of femoral head from arteries around and beneath short external rotators and finally lead to avascular necrosis of head of femur.
- d. Fractures of posterosuperior segment are more high energy traumas and the initial impact to the acetabulum is more severe than pure posterior wall fractures. This high energy mechanism of fracture may itself be the cause of cartilage damage and destructive joint disease in the future.

In acetabular fractures which in early phase (usually around 3 months) avascular necrosis of femoral head appears, direct vascular injury to the head of femur is the main cause of head necrosis. But in late necrosis, other factors influence too.

Delayed open reduction and fixation of acetabular fracture is a cause of hip destructive joint disease. Because after 2-3 weeks soft tissue contracture develop and reduction and fixation of segments of joint needs more soft tissue dissection, with this soft tissue dissection, vascular injury to the head of femur is highly possible. Also, after 2-3 weeks, joint particles can not be anatomically reduced and even small steps and gaps in articular surface of acetabulum may remain. In this way, severe displacement of acetabular segments also lead to poor reduction.

Some times, non intentional placement of screws in joint are the cause of joint damage. So, if there is doubt about position of screws, intraoperative x ray imagings (C-arm or radiography) or postoperative CT scan (specially axial and coronal cuts) are very helpful. If there is a screw in the joint, do not hesitate to remove it and insert another one in correct direction. The best position of screws are toward ischial tuberosity (inferior screws) and toward ilium and iliac bone (superior screws). The most dangerous screws are those that are inserted in the field of acetabular cavity. Even intraoperative C-arm, cannot guaranty safe positioning of screws so special attention to direction of hand during screw insertion is more important.


In few cases, necrosis may develop in acetabular fragments not in the head of femur. So, dissection of all soft tissues from the acetabular segments specially detachment of capsule of hip joint and the periosteum from the wall fragments is forbidden because it can damage the remaining nutrients to the segment.

9. References

- [1] Márcio KatzI; Marcos Antônio Akira OkumaI; Alexandre Leme Godoy dos SantosII; Cesar Luiz Betoni GuglielmettiIII; Marcos Hideyo SakakiIV; Arnaldo Valdir Zumioti. Epidemiology of high-energy trauma injuries among the elderly. *Acta ortop. bras.* vol.16 no.5 São Paulo 2008

- [2] Souza RB, Powers CM. Differences in hip kinematics, muscle strength, and muscle activation between subjects with and without patellofemoral pain. *J Orthop Sports Phys Ther.* 2009 Jan;39(1):12-9.
- [3] B Noehren¹, J Scholz², I Davis The effect of real-time gait retraining on hip kinematics, pain and function in subjects with patellofemoral pain syndrome *Br J Sports Med* doi:10.1136/bjsm.2009.069112
- [4] Thomas Trumble, *Christopher H. Allan, *John Miyano, *John M. Clark, Susan Ott, D. E. Casey Jones, ‡Patrick Fernicola, *Marteinn Magnusson, and *Allan Tencer A Preliminary Study of Joint Surface Changes After an Intraarticular Fracture: A Sheep Model of a Tibia Fracture With Weight Bearing After Internal Fixation. *Journal of Orthopaedic Trauma* Vol. 15, No. 5, pp. 326-332 © 2001 Lippincott Williams & Wilkins, Inc., Philadelphia
- [5] Letournel E. Diagnosis and treatment of nonunions and malunions of acetabular fractures. *Orthop Clin North Am.* 1990 Oct;21(4):769-88.
- [6] Joel M. Matta, MD; Tania A. Ferguson, MD. Total Hip Replacement After Acetabular Fracture *Orthopedics* September 2005;28(9):959.
- [7] Mears DC, Velyvis JH. Primary total hip arthroplasty after acetabular fracture. *Instr Course Lect.* 2001;50:335-54.
- [8] D Murphy, M Kaliszer, J Rice. Outcomes after acetabulum fracture:: prognostic factors and their inter relationships *Injury*, Volume 34, Issue 7, Pages 512-517 (July 2003)
- [9] al-Qahtani S., O'Connor G.: Acetabular fractures before and after the introduction of seatbelt legislation. *Can J Surg* 1996; 39:317-320.
- [10] Alexander R.D., Grimm L., Vrahas M.S.: The effect of knee immobilization on degree of hip flexion: A clinical correlation with posterior wall acetabular fractures. *Am J Orthop* 1997; 26:345-347.
- [11] Allen T.L., Carter J.L., Morris B.J., et al: Retrievable vena cava filters in trauma patients for high-risk prophylaxis and prevention of pulmonary embolism. *Am J Surg* 2005; 189:656-661.
- [12] Alonso J.E., Davila R., Bradley E.: Extended iliofemoral versus triradiate approaches in management of associated acetabular fractures. *Clin Orthop Relat Res* 1994; 305:81-87.
- [13] Alonso J.E., Volgas D.A., Giordano V., et al: A review of the treatment of hip dislocations associated with acetabular fractures. *Clin Orthop Relat Res* 2000; 377:32-43.
- [14] Anglen J.O., Bagby C., George R.: A randomized comparison of sequential-gradient calf compression with intermittent plantar compression for prevention of venous thrombosis in orthopedic trauma patients: Preliminary results. *Am J Orthop* 1998; 27:53-58.
- [15] Anglen J.O., Burd T.A., Hendricks K.J., et al: The "Gull Sign": A harbinger of failure for internal fixation of geriatric acetabular fractures. *J Orthop Trauma* 2003; 17:625-634.
- [16] Anglen J.O., Hughes M.: Trochanteric osteotomy for incarcerated hip dislocation due to interposed posterior wall fragments. *Orthopedics* 2004; 27:213-216.
- [17] Anglen J.O., Moore K.D.: Prevention of heterotopic bone formation after acetabular fracture fixation by single-dose radiation therapy: A preliminary report. *J Orthop Trauma* 1996; 10:258-263.
- [18] Arrington E.D., Hochschild D.P., Steinagle T.J., et al: Monitoring of somatosensory and motor evoked potentials during open reduction and internal fixation of pelvis and acetabular fractures. *Orthopedics* 2000; 23:1081-1083.

- [19] Attias N., Lindsey R.W., Starr A.J., et al: The use of a virtual three-dimensional model to evaluate the intraosseous space available for percutaneous screw fixation of acetabular fractures. *J Bone Joint Surg [Br]* 2005; 87:1520-1523.
- [20] Bacarese-Hamilton I.A., Bhamra M.: Small bowel entrapment following acetabular fracture. *Injury* 1991; 22:242-244.
- [21] Bartlett C.S., DiFelice G.S., Buly R.L., et al: Cardiac arrest as a result of intraabdominal extravasation of fluid during arthroscopic removal of a loose body from the hip joint of a patient with an acetabular fracture. *J Orthop Trauma* 1998; 12:294-299.
- [22] Baumgaertner M.R.: Fractures of the posterior wall of the acetabulum. *J Am Acad Orthop Surg* 1999; 7:54-65.
- [23] Beaulé P.E., Dorey F.J., Matta J.M.: Letournel classification for acetabular fractures. Assessment of interobserver and intraobserver reliability. *J Bone Joint Surg [Am]* 2003; 85:1704-1709.
- [24] Beaulé P.E., Griffin D.B., Matta J.M.: The Levine anterior approach for total hip replacement as the treatment for an acute acetabular fracture. *J Orthop Trauma* 2004; 18:623-629.
- [25] Berg E.E.: Charcot arthropathy after acetabular fracture. *J Bone Joint Surg [Br]* 1997; 79:742-745.
- [26] Berton C., Bachour F., Migaud H., et al: [A new type of acetabular fracture: "True" posteriosuperior fracture, a case report]. *Rev Chir Orthop Reparatrice Appar Mot* 2007; 93:93-97.
- [27] Bhandari M., Matta J., Ferguson T., et al: Predictors of clinical and radiological outcome in patients with fractures of the acetabulum and concomitant posterior dislocation of the hip. *J Bone Joint Surg [Br]* 2006; 88:1618-1624.
- [28] Borer D.S., Starr A.J., Reinert C.M., et al: The effect of screening for deep vein thrombosis on the prevalence of pulmonary embolism in patients with fractures of the pelvis or acetabulum: A review of 973 patients. *J Orthop Trauma* 2005; 19:92-95.
- [29] Borrelli Jr. J., Goldfarb C., Catalano L., et al: Assessment of articular fragment displacement in acetabular fractures: A comparison of computerized tomography and plain radiographs. *J Orthop Trauma* 2002; 16:449-456.discussion 456-457
- [30] Borrelli Jr. J., Goldfarb C., Ricci W., et al: Functional outcome after isolated acetabular fractures. *J Orthop Trauma* 2002; 16:73-81.
- [31] Borrelli Jr. J., Ricci W.M., Anglen J.O., et al: Muscle strength recovery and its effects on outcome after open reduction and internal fixation of acetabular fractures. *J Orthop Trauma* 2006; 20:388-395.
- [32] Bosse M.J.: Posterior acetabular wall fractures: A technique for screw placement. *J Orthop Trauma* 1991; 5:167-172.
- [33] Bosse M.J., Poka A., Reinert C.M., et al: Preoperative angiographic assessment of the superior gluteal artery in acetabular fractures requiring extensile surgical exposures. *J Orthop Trauma* 1988; 2:303-307.
- [34] Bosse M.J., Poka A., Reinert C.M., et al: Heterotopic ossification as a complication of acetabular fracture. Prophylaxis with low-dose irradiation. *J Bone Joint Surg [Am]* 1988; 70:1231-1237.
- [35] Bray T.J., Esser M., Fulkerson L.: Osteotomy of the trochanter in open reduction and internal fixation of acetabular fractures. *J Bone Joint Surg [Am]* 1987; 69:711-717.



Orthopedic Surgery

Edited by Dr Zaid Al-Aubaidi

ISBN 978-953-51-0231-1

Hard cover, 220 pages

Publisher InTech

Published online 09, March, 2012

Published in print edition March, 2012

Orthopaedic surgery is the widest and the strongest growing surgical specialty. It is clear, that the process of improving treatments and patients care, requires knowledge, and this requires access to studies, expert opinion and books. Unfortunately, the access to this knowledge is being materialized. As we believe that access to the medical knowledge should be reachable to everyone free of charge, this book was generated to cover the orthopaedic aspect. It will provide the reader with a mix of basic, but as well highly specialized knowledge. In the process of editing this book, my wife Jurgita has been, as usual, the most supportive person. I would like to thank her for being in my life. I would like to thank Mr. Greblo, the Publishing Process Manager, for all his help and last but not least thanks to our readers, as without them this book would have no meaning.

How to reference

In order to correctly reference this scholarly work, feel free to copy and paste the following:

Babak Siavashi (2012). Total Hip Arthroplasty After Previous Acetabulum Fracture Surgery, Orthopedic Surgery, Dr Zaid Al-Aubaidi (Ed.), ISBN: 978-953-51-0231-1, InTech, Available from:
<http://www.intechopen.com/books/orthopedic-surgery/total-hip-replacement-after-acetabulum-fracture-surgery->

INTECH
open science | open minds

InTech Europe

University Campus STeP Ri
Slavka Krautzeka 83/A
51000 Rijeka, Croatia
Phone: +385 (51) 770 447
Fax: +385 (51) 686 166
www.intechopen.com

InTech China

Unit 405, Office Block, Hotel Equatorial Shanghai
No.65, Yan An Road (West), Shanghai, 200040, China
中国上海市延安西路65号上海国际贵都大饭店办公楼405单元
Phone: +86-21-62489820
Fax: +86-21-62489821

© 2012 The Author(s). Licensee IntechOpen. This is an open access article distributed under the terms of the [Creative Commons Attribution 3.0 License](https://creativecommons.org/licenses/by/3.0/), which permits unrestricted use, distribution, and reproduction in any medium, provided the original work is properly cited.

IntechOpen

IntechOpen