

We are IntechOpen, the world's leading publisher of Open Access books Built by scientists, for scientists

6,900

Open access books available

186,000

International authors and editors

200M

Downloads

Our authors are among the

154

Countries delivered to

TOP 1%

most cited scientists

12.2%

Contributors from top 500 universities



WEB OF SCIENCE™

Selection of our books indexed in the Book Citation Index
in Web of Science™ Core Collection (BKCI)

Interested in publishing with us?
Contact book.department@intechopen.com

Numbers displayed above are based on latest data collected.
For more information visit www.intechopen.com



Management of Dental Impaction

Farid Bourzgui, Mourad Sebbar, Zouhair Abidine and Zakaria Bentahar
*Faculty of Dentistry, University of Hassan II Ain Chok
 Morocco*

1. Introduction

Practitioners are frequently faced with tooth eruption anomalies during the gradual emergence of complete adult dentition, and notably disorders related to tooth impaction (Hurme et al. 1949). This process, which affects deciduous, permanent and supernumerary teeth, is thought, apart from more general causes, to stem from a breakdown in the dynamics of eruption as a result of numerous different factors (Rajic et al. 1996) among which we can cite the following:

- Malformation of the germ;
- Local obstacles (tumors or cysts, supernumerary teeth and odontomas);
- Inadequate available volume on the arch which can have either a primary etiology of skeletal (brachygnathism) or dental origin (macrodontia) or secondary etiology due to spontaneous mesial drift (premature loss of milk teeth due to resorption) or iatrogenic mesial drift (premature avulsions).

Agenesis of proximal teeth sometimes gives rise to tooth impaction as a result of loss of the eruption guidance function. In particular, this can affect the upper lateral incisors. And, lastly, the poorly-documented phenomenon of ankylosis occurs following the more or less total disappearance of the dental ligament associated with hypercementosis and root resorption which obstruct all physiological or provoked dental development at various stages (Chambas, 1997).

The unerupted or impacted tooth will trigger some major esthetic and/or functional disorders (Le Breton, 1997) depending on which tooth is affected; hence, the need to reposition in the arch, particularly if the impaction is located in the anterior region. With this in mind, and to achieve maximum results, treatment of tooth retention requires collaboration between surgeons and orthodontists. Consequently, the introduction of surgical-orthodontic techniques in our clinical practice has made it easier to manage dental impaction.

This chapter aims to review the current state of knowledge on management of impacted teeth in order to establish a standard protocol and thus codify the treatment of this anomaly.

2. Definition

Impacted teeth are classically defined as retained in the jaw beyond their normal date of eruption, surrounded by their coronary bag and without communication with the oral cavity (Favre, 2003).

For Izard (Izard, 1950), there is total retention tooth when the tooth is kept inside the jaw beyond the normal period of its eruption, and no tendency to make its vertical migration.

According to Lacoste (1988): a tooth that remains within bone or submucosa after the normal date of its rash is most often referred to as tooth retention.

According Bordais (1980), a tooth is said to be retained when its evolutionary potential is preserved, while a tooth is said to be included when its evolutionary potential is lost.

Vigneul (1974) speaks of a tooth completely embedded in the bone and whose coronary bag remains unscathed. He maintains that there are two types of inclusions:

- Aphysiologicaltype, which refers to any tooth that has not erupted, and
- A pathological type, which is the topic of our study, in which the tooth can be intraosseous or submucosa.

A new classification of Dentistry Teeth (Favre, 2003) integrates data from major international reference classifications. The clinicopathological and pathophysiological classification distinguishes:

- tooth included in the way of normal eruption;
- tooth retention;
- impacted teeth, proper, or retained tooth included;
- enclosed tooth retention;
- tooth disimpaction, in its proper sense;
- tooth disimpaction at large.

3. Epidemiology

The results of different studies show variable numbers, which are not necessarily contradictory. These discrepancies come from the non-homogeneity of the samples studied. All are unanimous on the fact that the mandibular third molars are most frequently included, followed by their counterparts of maxillary and maxillary canines.

The classic distribution in order of frequency of impaction of permanent teeth can be summarized as follows : lower third molars, upper third molars, upper canines, upper and lower premolars, upper incisors, lower canines, lower incisors, upper and lower first molars and upper and lower second molars [Ericsson, 2000; Quirynen, 2000).

The position of the canines is palatal in 50% of the cases, buccal in 30% of the cases, while it occupies an intermediate position in 20% of the cases (Chambas, 1997). Its frequency is 10 times higher in Caucasians than in Chinese, while the variability in gender shows a slight prevalence in girls.

4. Etiology

Primary reasons: genetics (Vichi, 1996), endocrinologic deficiency, irradiation, palatal clefts, developmental abnormalities of germs, supernumerary tooth or tooth fragments , dento-maxillary disharmony (mostly for buccal impactions), late or missing root development, growth disharmony between pre-maxilla and maxilla (concerns maxillary

canines only), maxillary brachygnathia, transversal growth deficiency of the anterior maxilla (Mc Connelt, 1996).

Secondary reasons: loss of guidance of the lateral incisor (microdontia or tooth absence) (Sasakura, 1984; Ericsson, 1987; Peck, 1996), trauma, premature extraction causing space problems by mesialisation of the anterior sector (second mandibular premolar moving mesially after extraction of the second deciduous molar), root malformation, pericorony pathology, ectopic germ position, thick fibrous tissue (Goho, 1987), mesio-distal dimension of the nasal fossae, unerupted canine at the borderline of a palatal cleft (Benoit, 1989).

5. Diagnosis

The diagnosis of any tooth impaction should be established as early as possible in order to monitor its development and implementation of appropriate therapy in time. In the absence of a maxillary central incisor, the parents consult early for the appearance of the lateral incisor reducing the median space, thus creating an asymmetric and unsightly situation. For canines, as a rule, no functional sign would lead the patient to consult early; the discovery is almost always casual in a screening or radiological examination (presence of a late primary cuspid).

The diagnosis is based on clinical and radiographic examination. Three positions of impaction are generally possible: buccal, intermediary and palatal (in the maxilla) or lingual (in the mandible). But a very strict attitude in this subject can lead to errors in the appreciation of the precise position. Thus we know that canines whose crowns are positioned buccally often have their root reaching out palatally behind the root-tips of the neighbouring teeth (Korbendeau, 2005).

5.1 Clinical diagnosis

5.1.1 Anamnesis

The interview will allow collecting any family predisposition to inclusions or other hereditary factors such as agenesis. The medical history should identify pathological antecedents and any counter-indications for surgical-orthodontic treatment. The patient's motivation is also an important point to consider, facing a long and difficult treatment.

5.1.2 Clinical examination

The clinical examination often allows establishing a presumption of inclusion. Two methods are used:

Inspection

- The persistence of a deciduous tooth in the arch beyond its normal replacement date;
- The absence of a permanent tooth when its normal time of eruption is exceeded;
- Reduction of the space of tooth eruption by underlying mesialization adjacent teeth;
- The malposition or malformation of the teeth adjacent to the missing tooth (versions and rotations);
- Lack of synchronization between left and right exfoliation and eruption of teeth two counterparts, are all elements for a strong presumption of inclusion or retention tooth.

Palpation

- Palpation of the buccal and lingual mucosa simultaneously using the indexes of the two hands is recommended to estimate the position of the teeth changing.
- The lack of hump canine on the arch at 10 or 11 years, coinciding with the absence of the permanent canine is also a presumption in favor of inclusion or agenesis. But only X-ray examination can establish with certainty the diagnosis of inclusion.

5.1.3 Radiological examination

In addition to clinical assessment, the protocol begins with a dental panoramic X-ray around which the complementary techniques revolve. Emphasis should be placed on simple conventional sophisticated methods and keep modern imagery to circumstances where simple tests are insufficient.

The dental panoramic X-ray or orthopantomogram (OPT)

The OPT allows practionners to:

- Give an overview of the dental arch and skeletal structures;
- Distinguish between a missing tooth in the arch, agenesis, inclusion or locoregional ectopic;
- Learn about the depth of inclusion, the general axis of the tooth, and its teeth relationship, but it cannot locate buccal or palate position.
- Identify an obstacle that blocks the development of the tooth;
- Identify possible complications;
- Discover other anomalies of the dental system.

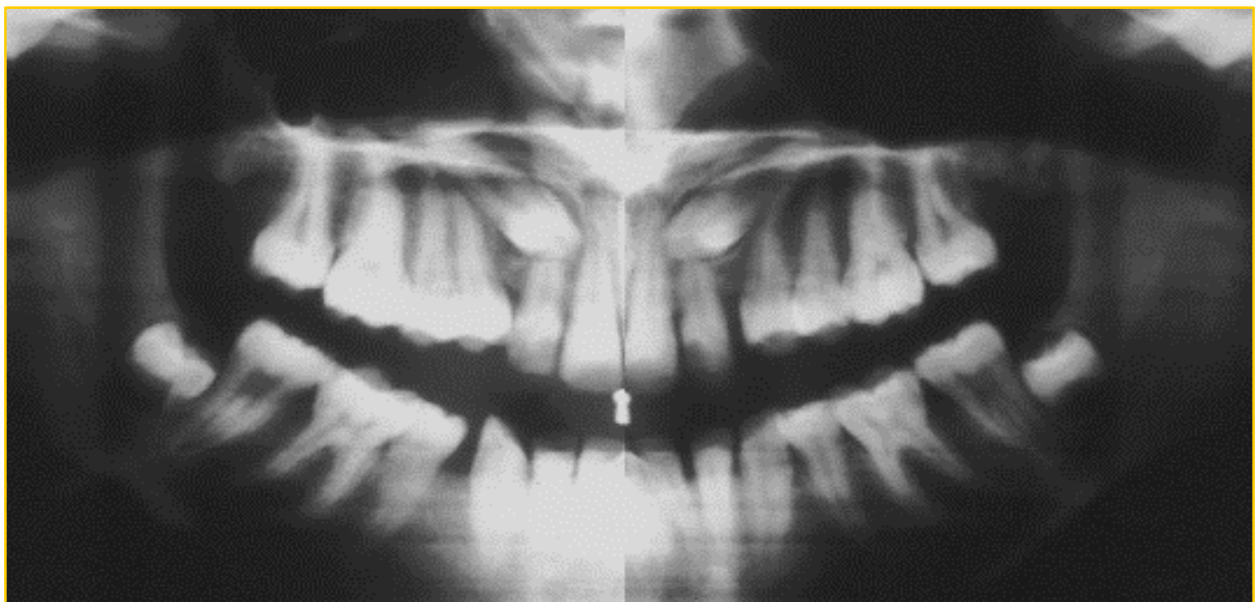


Fig. 1. The panoramic screening to determine the dental formula, which must be performed at the age of 8-9 years.

Periapical radiograph

Any x-ray is a two-dimensional representation of structures that are actually three dimensional. Therefore, it is essential to achieve at least two shots as different impacts to be able to determine the position of the canine, both mesiodistally and vestibulo-buccally. Thus, the technique of "tubeshift" or as the "rule of Clark" is based on achieving two to three shots. The first shot is made as mesial eccentric projection, for the second shot, the central beam is positioned perpendicular to the alveolar process, the effect corresponding to the ideal axis of the canine and the third shot is made as eccentric projection distal. When the dog moves in the same direction as the source of X-rays, it is included in palatal position. It moves in the opposite direction, it is in position buccal (Crisman, 2000).

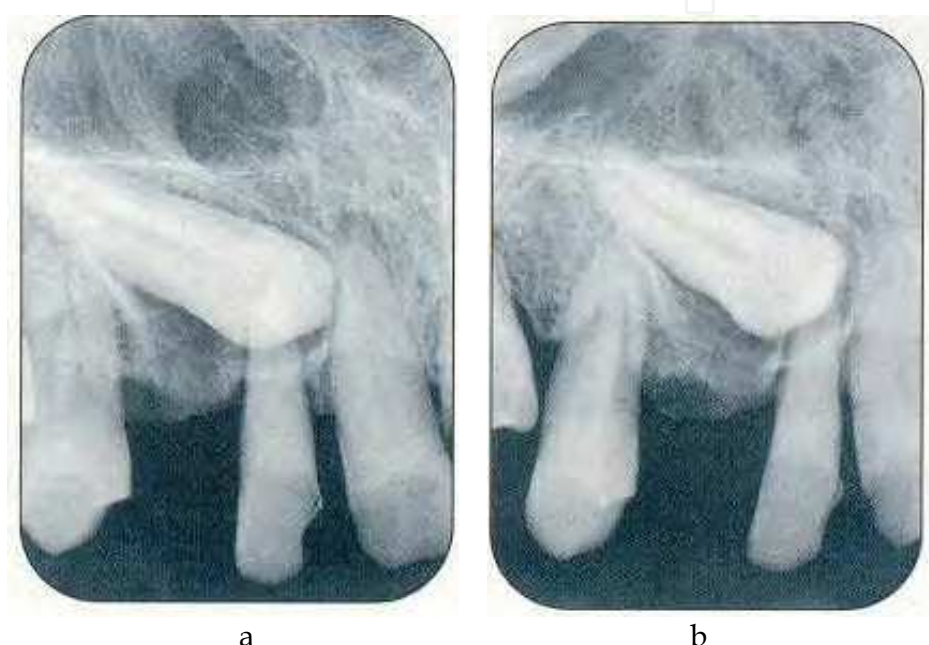


Fig. 2. a) Periapical radiograph: with an orthocenter incidence. b) Periapical radiograph with a distocentric incidence. These two shots are needed to determine if the crown of the tooth is in position vestibular or buccal compared to others teeth.

Occlusal check-bit

The occlusal radiograph is very easy to use in young children because of the narrowness of the palate. Three types of effects can be used:

- The impact dysocclusale upper middle: it gives a topographic image of the hard palate and therefore precise morphology of the tooth retention,
- The impact ortho occlusion at 90 °: theory reveals the relationship of the crown of the impacted tooth with the roots of the incisors,
- The impact dysocclusale side at 60 °: this effect can view an entire canine included anteroposterior and its relationship with the incisors.

This exploration technique differentiates the position of the buccal or palatine impacted teeth by providing essential data on the transverse plane, the location of the tooth compared to the apex. It is full of orthopantomography (Korbendeau, 2005).

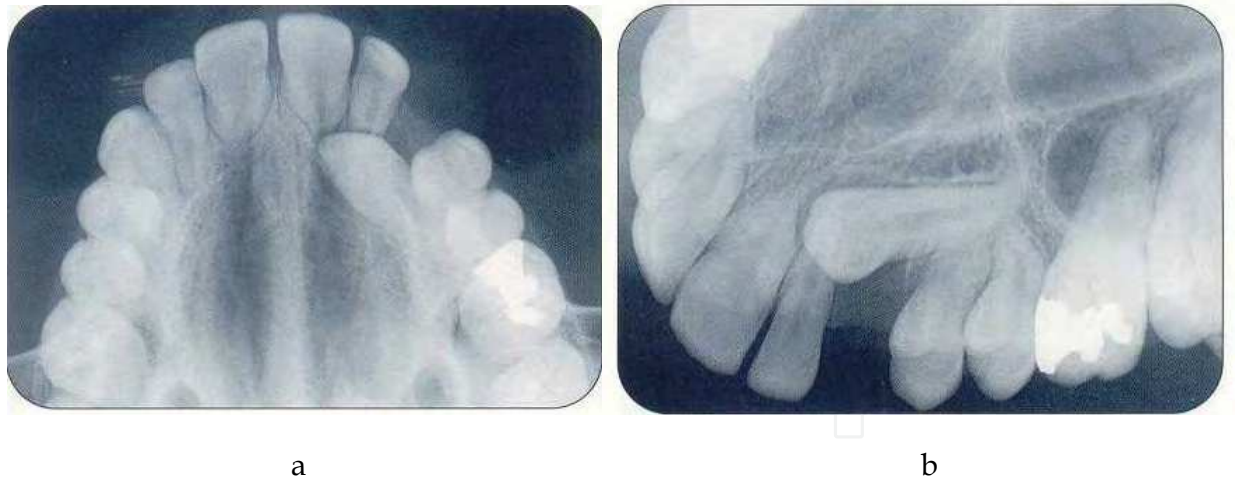


Fig. 3. a) The orthoocclusal incidence reveals the palatal dystopia of 23. It allows visualizing the orientation of the impacted tooth, but it does not show the apical third of the root. The relationship with the roots of the incisors cannot be interpreted. b) The dysocclusal side to 60 ° can view the impacted tooth as a whole, and its relation with the anteroposterior incisor.

Lateral cephalometric radiographs

Orthodontic part of the record, this examination provides information in the vertical and sagittal - position - direction - height of inclusion. The superimposition of teeth from left and right arch limits the accuracy of the images (Korbendeau, 2005).

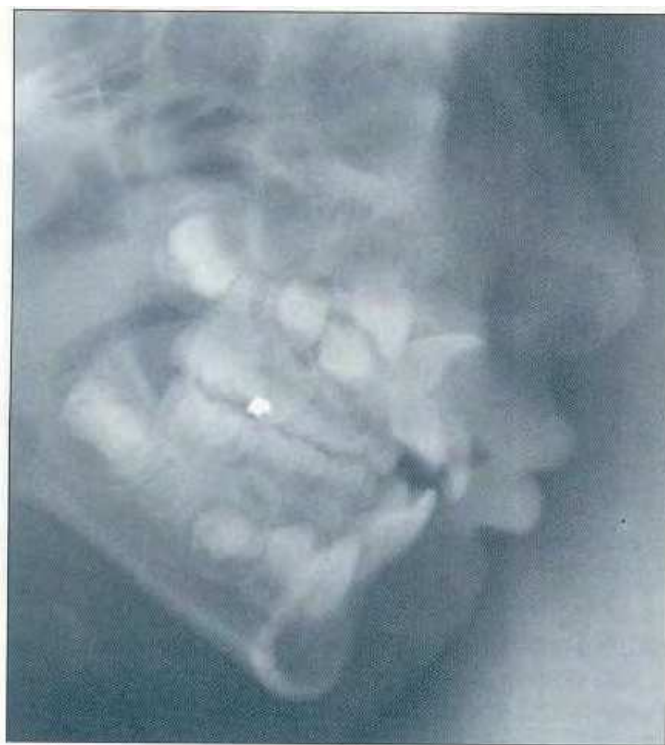

Fig. 4. the direction of the crown and the angle of the root are well highlighted in this lateral cephalometric radiograph.

CT or scanner

We realize, in the maxillary, a fine axial parallel to the palate bone; documents are provided full-scale, enabling a study and direct measurements on the photographs:

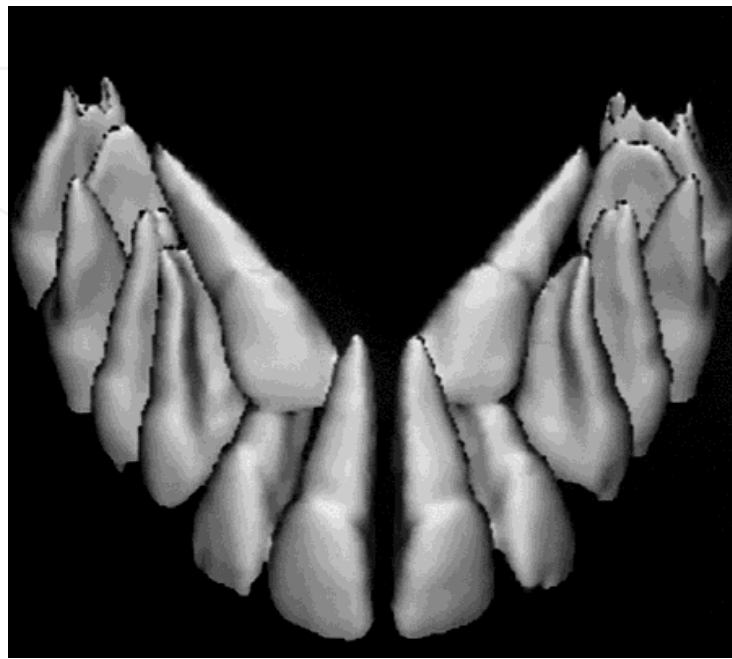
- Very precise localization of impacted teeth;
- Visualization of anatomic relationships of structures
- Neighborhood
- Location of an obstacle (odontoma, supernumerary tooth ...);
- Suspected effects on adjacent teeth (root resorption);
- Morphology of the impacted tooth (apical hooks or bends);
- Balance sheet bone abnormalities associated (cyst).

With modern software reconstruction from cuts made in all three planes of space, we will obtain three-dimensional reconstructions. These images will allow to study the position of the teeth and their relationship to adjacent anatomical structures from any angle desired and to perform distance measurements between the various structures (Nabbout, 2004; Treil, 1997).

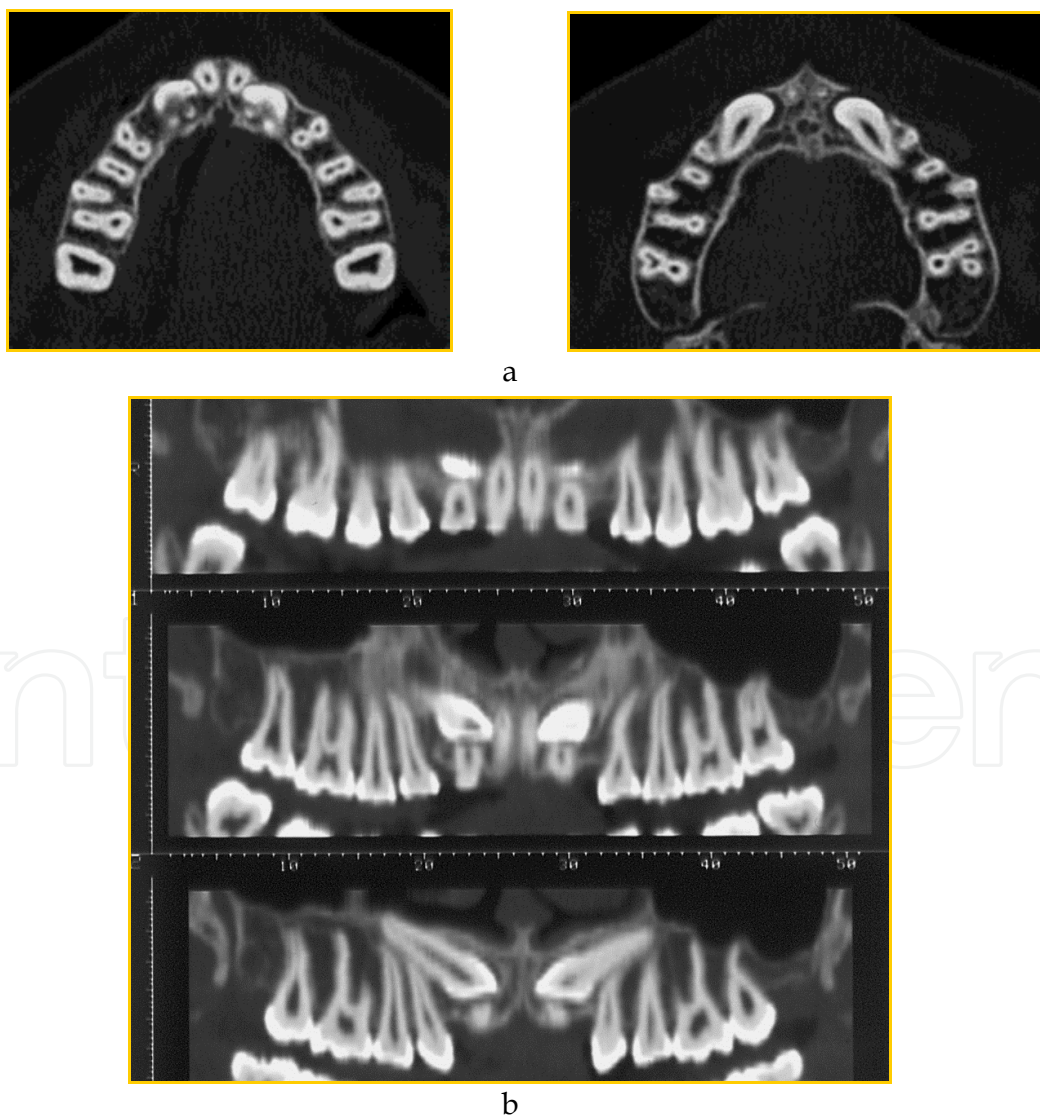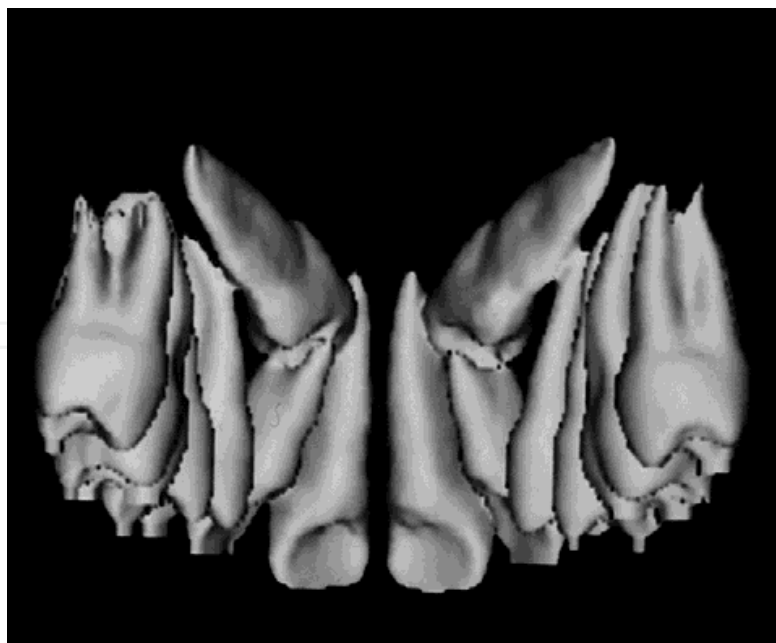


Fig. 5. a) Native axial b) The panoramic curve reconstruction.

CT allows a precise localization of the germ of the impacted tooth and guide the surgical approach safely. In addition, it allows the examination of the anatomical structures of neighborhood (nasal cavity, adjacent tooth), the ability to view dental resorptions, the location of a potential barrier (supernumerary teeth, follicular cyst)



a



b

Fig. 6. a) b) 3D reconstruction provides a relief image of the orientation and position of teeth, and their relationship with the roots of permanent teeth. These images are very useful in the choice of operating procedures when clearing of impacted teeth deep.

6. Surgical-orthodontic management of dental impaction

After diagnosis, four types of attitudes are possible, facing impaction or missing eruption of teeth: abstention (mandibular canines close to the alveolar nerve); extraction; etiologic therapy if a deciduous tooth blocks the evolution; surgical exposure.

6.1 Abstention

The grounds for abstention may come from the patient who refuses orthodontic treatment when the impacted tooth does, by its position, represent no threat to the environment. This decision may also be related to the inability to establish the impacted tooth, because of its position or its ankylosis and the desire to avoid a too avulsion decaying in bone or adjacent teeth. In all cases, regular monitoring will be necessary to intercept any active disease of the teeth left in place.

6.2 Etiological treatment

The age of the patient is decisive when setting up preventive measures against risks of inclusion. Suspicion of impacted teeth will lead the practitioner to implement early treatment.

- Avulsion of the temporary tooth: in order to change the trajectory of eruption of the permanent tooth for a tooth-changing moves "in the path of least resistance" (Korbendeau, 2000).
- Maintenance of the space for the impacted tooth: the premature loss of deciduous tooth requires the possible establishment of a space maintainer.
- Avulsion of supernumerary teeth: the supernumerary germs and odontoma should be diagnosed early and avulsed to prevent the risk of inclusions.
- Expansion of the maxillary cross: the increase of available space by orthopedic device (palatal expander or Quad helix) (Dupont, 2001).
- Closure of a diastema therapeutic interincisal: frenotomy upper lip in front of a brake inserted deeply or avulsion of a mesiodens.

6.3 Technologies to promote spontaneous eruption of impacted teeth

6.3.1 Preventive guidance

It includes all actions necessary for the removal of barriers, but it also serves to create space for a normal development of tooth retention (Al Hussain, 1988). The goal is to awaken the potential eruption as soon as possible by lifting these barriers to have a spontaneous eruption. The avulsion of permanent or temporary teeth may be indicated to allow eruption of the impacted tooth physiological (Altounian, 1997, Langlade, 1986) but only if three conditions are met: inclusion bit old, apex not closed and canine well oriented.

6.3.2 Conductive alveolectomy

This technique, also called alveolectomy induction was established by Chatellier in 1957 (Chatellier, 1962). It creates a path of surgical eruption by releasing obstacles bone and removing the fibrous tissue periodontal (pericoronal bag). For the potential of eruption to be maximized, the conductive alveolectomy must be completed before the construction of the

apical third and the apex overhangs the desired axis of extrusion (Durival, 1979). This technique has the advantage of enjoying the natural and physiological potential eruption of the tooth, however, the risk of ankylosis and / or bone resorption due to trauma of the periodontal ligament in the bone resection is not insignificant.

6.3.3 Directional osteotomy

It corrects the position of the tooth without moving its apex. It is indicated when the canine is raised, with an apex close to its normal place. A flap of the lateral incisor to first molar can expose the portal up to two thirds and a root mobilization syndesmotome is performed with a minimal apical displacement and thus a decreased risk of secondary mortification. But the risk of ankylosis still exists and the position of the canine often limits the indication of this process (Baron, 2001).

6.3.4 Autotransplantation

It is a resettlement in a newly formed alveolar at the level of the physiological eruption site of the extracted tooth. This technique is indicated when surgical-orthodontic treatment is impossible or when the impacted tooth threatens the roots of adjacent teeth. It requires sufficient space in the arch as well as mesiodistal vestibulopalatine and should be reserved for immature teeth. The major risk of this intervention is the process of ankylosis-root resorption resulting in the total resorption of the root variable within 7 to 10 years. To inhibit this process, it is necessary to follow a very strict operating procedure preserving the integrity of the periodontal ligament, and there is a differentiation of a functional periodontal ligament stable over time, putting the root transplanted immune to ankylosis phenomena (Garcia 1990).

6.4 Treatment of selected central incisors

In the absence of a maxillary central incisor, the parents consult most often after the emergence of the lateral incisor. The reduction of space further underscores the absence of the plant, because the asymmetry created is unattractive. Sometimes an early screening radiographic examination reveals the existence of inclusion.

6.4.1 Extraction of the permanent central incisor

This decision is based on therapeutic and complementary clinical examinations. The lack of a permanent central incisor is revealed after the fall of the deciduous tooth, a more or less pronounced collapse of the alveolar process in its vestibular part. Surgical-orthodontic treatment usually ensures the building of the thickness and height of the alveolar bone. Avulsion is reserved for cases of ankylosis and cases of laceration of interest to the crown or the top third root (Wong-Lee, 1985).

6.4.2 Implementation surgical-orthodontic

This is the technique of choice for positioning function of impacted teeth; it offers the best results and longevity of the tooth over time. A space to recreate the arcade is almost always necessary and this often lengthy treatment is possible at any age but requires motivation and impeccable cleanliness on the part of the patient. Several phases of treatment will succeed.

6.4.2.1 Presurgical orthodontic preparation

It aims to provide an anchor to pull the impacted tooth from its release position and to develop a surgical site on receiving the arch with an excess of up to 2 mm. This action may be obtained either by a removable appliance with resin base plate equipped with an active device (cylinder, spring ...) but it is more often preferred as a fixed multi-attachments with various accessories (coil spring, intermaxillary traction ...). This anchoring is most often offered by the entire arcade, but it can also be provided by implants or mini implants.

6.4.2.2 Surgical phase: Principle of surgical release

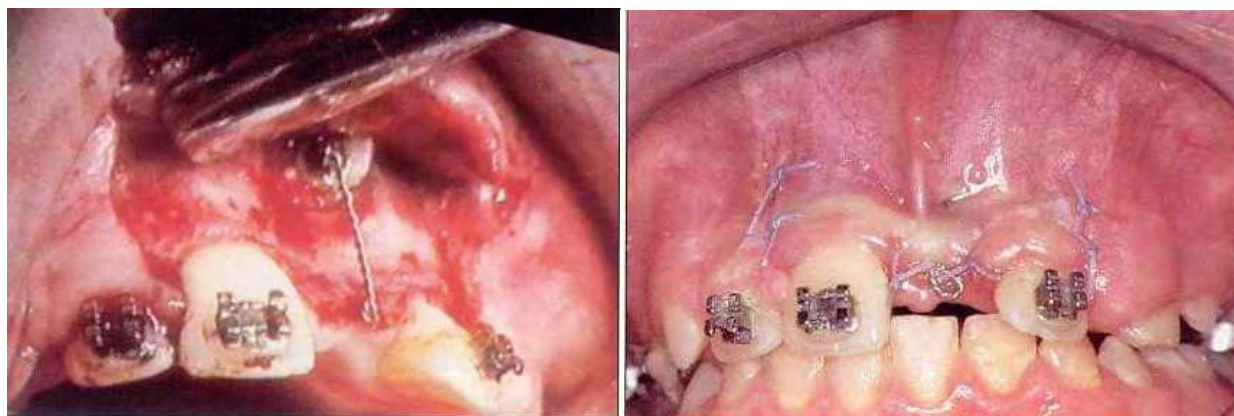More than two decades ago, the surgeon used to perform a "comprehensive exhibition of the crown" of the tooth retained by making a buttonhole opening through the alveolar mucosa or attached gingiva (Archer, 1996). Other authors (Eiholtz, 1979) prepared a wider path by raising a mucoperiosteal flap to remove the bony wall, and the entire follicle to relate the crown to the anatomical neck. The mucous membrane covering the crown was then removed and the flap sutured in its original position.

Mucoperiosteal flap replaced

When the inclusion is deep, bonding intraoperatively is often difficult, so a rectangular flap provides extended release, conducive to good hemostasis. This flap is delimited by two vertical incisions, away from the impacted tooth, and a horizontal incision.

The two vertical incisions - discharge - leave the bottom of the vestibule, through the alveolar mucosa and reach the gum interdental papilla. The horizontal incision placed in the gingival sulcus, the lateral incisor, crosses the top of the edentulous ridge and follows the gingival sulcus of the contralateral central incisor to the line of the vertical incision.

This is a flap that provides a comprehensive surgery, with good visibility, and allows access to large vestibular ectopic teeth, the cystic lesions, the odontoma, ect. When the incisions are removed, hemostasis is ensured. The flap returned to its original position and ensures a rapid closure of the wound sealed. The post-operative care is reduced (Korbendeau, 1998).



a

b

Fig. 7. a) Preparation of a rectangular mucoperiosteal flap. The horizontal incision is placed at the top of the ridge, so that the pull wire reaches the axis of the arcade. b) The tissue flap is replaced in its original position. (Korbendeau, 1998).

Apically positioned flap

The apical fragment of translation is to place the gingival tissue on the labial crown of the impacted tooth to achieve a surgical emergence. The flap is delimited by two vertical incisions and a horizontal incision.

- The first vertical incision (mesial) is located along the labial frenum on the side of the tooth.
- The situation of the second vertical incision (distal) is determined so as to define an area of attached gingiva with a width at least equal to the mesiodistal crown dimension of the central incisor.
- The horizontal incision defines the height and thickness of the gum tissue to be positioned on the crown.

Apical displacement of the bottom edge of the flap provides a surgical emergence of the crown. This protocol has the advantage of seeing the crown, of picking a clip, of moving an anchor point in the weeks after surgery, and finally of leading the tooth, from the start of the pull toward eruption. Finally, the migration of the tooth, following emergent surgical trajectory occurs spontaneously and is usually faster than if the flap is replaced (Korbendeau, 1998).

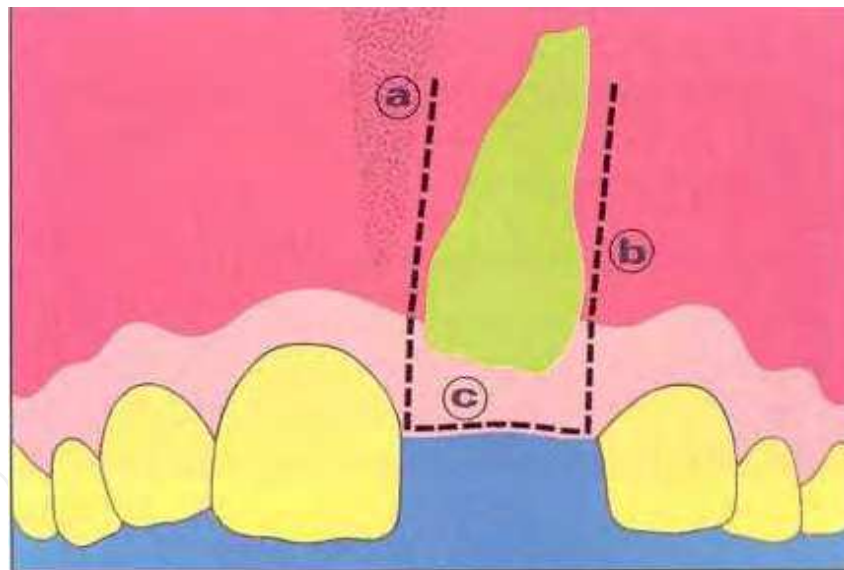


Fig. 8. The apically positioned flap is defined by three incisions: a, b and c. (Korbendeau, 1998).

6.5 Treatment of retained canines

6.5.1 Surgical techniques

Surgical exposure is undertaken only after orthodontic pre-treatment. Orthodontic preparation concerns mostly space management for the final position of the tooth. The extraction of the deciduous canine or of the premolar should only be planned after the impacted tooth has been mobilised without any sign of ankylosis (particularly in adults).

The preservation of the deciduous canine is usually not only an important question for the patients' aesthetics, but also for biomechanics and space maintenance. Nevertheless, to permit spontaneous eruption or orthodontic repositioning, disposing of sufficient keratinized tissue, extraction of the deciduous tooth may sometimes be necessary (Monnet-Corti, 2003).

Premolar extraction for space management has to be delayed until the probability of success is evaluated, and the duration of treatment and patient's motivation established (Thomine, 1995). The extraction has to be conducted to maintain the integrity of the osseous structures and particularly the bucal cortical plate, often being lost and thus reducing the buco-palatal dimension of the residual bone.

The access flaps are derived from the papers of Korbendau and Guyomard 1980 and 1998. The following techniques of surgical exposure are described: on the bucal side, gingivectomy, repositioned bucal flap, apically positioned flap and the laterally and apically repositioned flap, and the palatal side, the palatably repositioned flap in its fenestrated or not fenestrated version.

6.5.2 Gingivectomy

Gingivectomy is indicated when a big amount of keratinised tissue is found at the level of the impacted tooth. Between one third and one half of the tooth can be uncovered with a simple excision, leaving imperatively at least 3 mm of keratinised tissue on the apical side. From a periodontal point of view the application of such an excision is not indicated if only the oral mucosa is present (Archer, 1996).

6.5.3 Repositioned buccal flap

This flap is indicated when the tooth is positioned centrally to the alveolar crest or very high into the vestibulum (under the nasal spine) (Hunter, 1983; Magnusson 1990). In these very special situations apical and/or lateral translation of the keratinised tissue is impossible. It allows bone exposure and the bonding of the orthodontic device. For Boyd et al. it represents the technique of choice for any type of impaction.

6.5.4 Apically repositioned flap

This type of flap is the treatment of choice in many situations (Borghetti, 2000). It aims to create or to maintain keratinised tissue around the tooth by displacing the pre-existent keratinised tissue into the apical direction. The technique of the apically positioned flap (APF) is based on a mucosal flap (or partial thickness flap), the preservation of the existing keratinised tissue, its displacement into an apical position and its immobilisation by periosteal sutures which remain in place. Access to the impacted tooth is obtained by a full thickness flap.

The dimension of the tissue to be displaced is decided according to the quality and quantity of periodontal tissue of the adjacent teeth (39). The horizontal width of the flap depends on the width of the crown of the impacted tooth (~ 7, 5-8 mm for an impacted maxillary canine) to which 1-2 mm are added if possible.

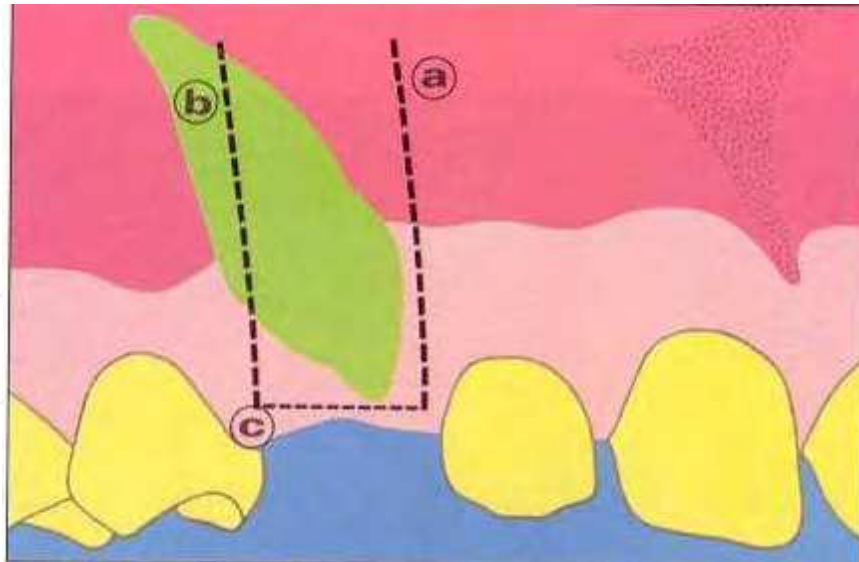


Fig. 9. The apically positioned flap is defined by three incisions a, b and c.

6.5.5 Laterally and apically positioned flap

The indications for this flap are the same as for the APF but the position of the tooth is more lateral in relation to the keratinised tissue on the crest or at the level of the adjacent teeth (Kokich, 1993).

The donor site can be the edentulous ridge (the simplest case) or the bucal tissue of the adjacent teeth. If the donor site is above a lateral or a central incisor, at least 2-3 mm of keratinised tissue have to remain over the teeth. At least 3 mm of tissue have to be displaced. Thus the donor site has to present with at least 6 mm of keratinized tissue to make sure that no dehiscence or recessions are created above the donor tooth (Kokich, 1993). The incisions permit to access the crown and to recreate a healthy periodontal environment).

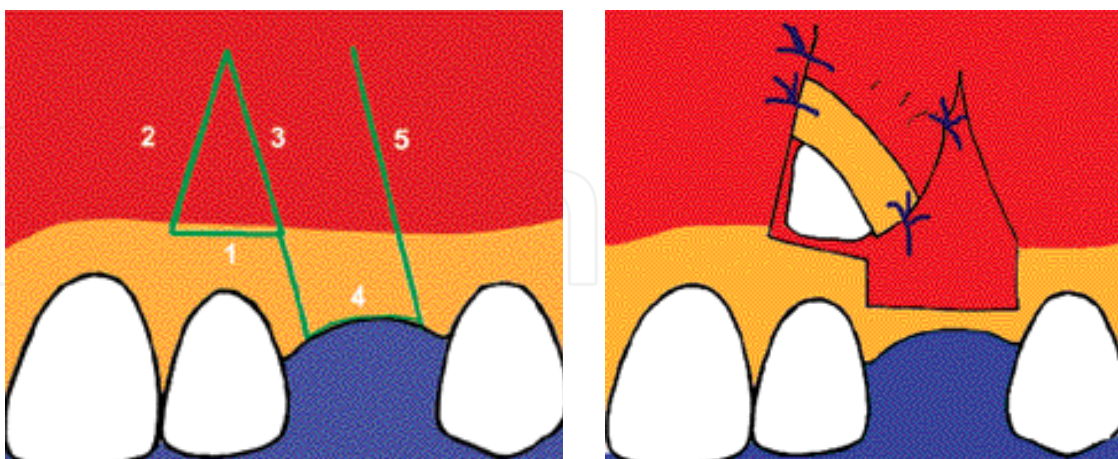


Fig. 10. Schematic drawing of laterally and apically positioned flap (from Borghetti and Monet Corti, 2000).

(a) Incision design 1: horizontal incision; 2-3: vertical incisions connecting to the first incision to remove the alveolar mucosa over the canine; 4: crestal horizontal incision and 5: vertical incision delimiting the distal part of the flap, dissected in partial thickness.

(b) Discontinuous flap sutures

6.5.6 Palatably repositioned flap

This technique is recommended for palatal inclusions. Because of the difficulties in determining the precise dimension and position of the tooth, direct access to the impacted tooth by cutting a little window into the soft tissue cannot be recommended.

Eliminating the bone, managing the bleeding and bonding the orthodontic device may present further difficulties. The intra-sulcular incisions are extending from the first premolar to the central incisor when the tooth is not deeply impacted. In cases of deep impaction near the palatal median line, the incisors can reach down to the contra-lateral premolar. No vertical incisions are made.

A full thickness flap is raised. The position of the tooth can mostly be determined by a typical convexity of the cortical bone, allowing the crown to expose. After the flap is replaced, a little window is prepared (using a new blade N° 15). The window has to be big enough to contain the rapid connective tissue proliferation, tending to close the wound (Monnet-Corti, 2003).

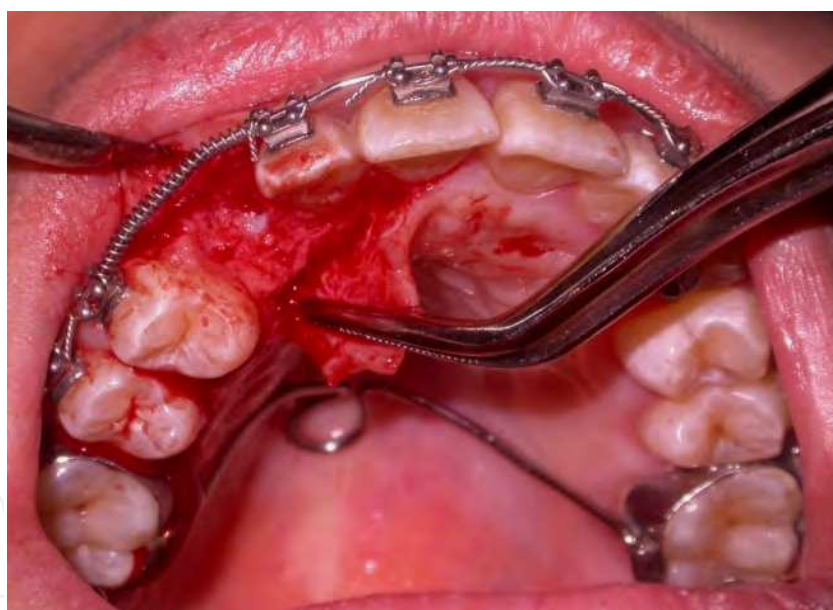

Fig. 11. Osteotomie and peri-coronary curettage disengaging the clinical crown.

7. Study conducted at the faculty of dentistry, Casablanca

The Department of Dentofacial Orthopaedics of the Faculty of Dentistry at Casablanca conducted an internal survey to review the current state of knowledge on management of impacted teeth in order to establish a standard protocol and thus codify the treatment of this anomaly (Bourzgui et al. 2009).

Our sample comprised 30 patients (24 females, 6 males) aged between 9 and 40 years. Mean age was 17 with a standard deviation of 8.141. These patients were all treated for impacted teeth by both the Surgical Dentistry Department and the Dentofacial Orthopaedics Department in Casablanca (Morocco). The clinical files included in the study comprised a clinical examination, X-rays and an iconography.

In our sample, the main reason for consultation was esthetics (54%). The discovery was made for esthetic reasons in 56.7% of the cases, for clinical examination in 16.7% of the cases, for X-ray examination and totally fortuitously in 23.3% of the cases, and delayed eruption unsuspected by the patient, but revealed by the practitioner in 3.3% of the cases.

The clinical examination was followed by X-ray examinations comprising not only a panoramic and slide-view headfilm but also a periapical radiograph and an occlusal check-bite in 36.7% of the cases, a periapical image combined with a CT scan in 16.7% of the cases and a check-bite combined with a CT scan in 6.7% of the cases.

The number of impacted teeth varied from 1 to 6. Most often, however, only one tooth was involved (56.7%). In 66% of cases, canines were implicated, of which 9% were mandibular, 22% were incisal (all maxillary) and 12% were premolars. The impacted tooth was vestibular in 43.3% of cases, palatal in 33.3%, and in an intermediary position in 20% with 1 case with 2 impacted teeth; one vestibular, the other palatal. Level wise, distribution of dental impaction was divided into two groups: high impaction 63.3% and low impaction 36.7%.

Twenty-four patients (80%) were treated orthodontically prior to surgery. This stage aimed to prepare traction anchorage in 29.2% of cases or to open up space in 70.8%, occasionally with the assistance of extractions (41.2%). It should be noted that in 1 patient out of 30, the impacted tooth erupted spontaneously after 6 months of orthodontic preparation without course to surgery as the orthodontist had direct access to the tooth and was able to bond a bracket to it.

The surgical approach was vestibular in 17 cases, palatal in 9 cases and both vestibular and palatal in 3 cases. A replaced flap was used in 27 cases, a displaced flap in 1 case. In 1 case, a replaced flap was used on one side and a displaced flap on the other. Osteotomy was also performed to free the impacted tooth in 75.9% of cases.

An obstacle was found in 5 cases. Surgical elimination was performed in only 4 cases and the fifth case, involving a cyst, was marsupialized. Bonding was done during surgery in 27 cases and later in 2 cases. In 8 cases, a second procedure was needed following complications occurring during orthodontic traction. Treatment duration ranged from 3 to 24 months, with a mean of 11.4 months.

Twenty-one of 30 impacted teeth were correctly positioned in the arch, representing 70% success rate. Among the teeth which were not positioned, 66.6% were upper canines, 22.2% were upper central incisors and 11.1 were upper first premolars.

8. Discussion

The diagnosis of tooth impaction is made at different stages in the clinical examination and is then confirmed by radiological documents. In the course of our study, we looked most

specifically into the reason for consulting which, in some cases, can lead the orthodontist to suspect the presence of an impacted tooth.

Dental impaction can be associated with various accidents, whether infectious, mechanical, or other, or with clinical silence. In the latter case, the practitioner should look carefully for revelatory clinical signs such as diastemas, swelling, teeth loss, etc. which can confirm any suspicion the patient may have had during the pretreatment history-taking (Roberts-Harry et al. 2004). Apart from the fairly uncommon cases of impaction which are easily detected from symptoms, the orthodontist should also use X-ray in order to localize unerupted teeth. According to the British body which deals with the use of radiographic imagery for orthodontic diagnosis, any tooth which has not yet erupted and which has not been felt on palpation should necessarily be X-rayed (Isaacson and Thom 2001)

A number of potential complications can occur and disrupt treatment leading inevitably to failure. Some of these complications may require a second surgical procedure. This is the case, for instance, when soft tissue covers the site which is deliberately left open and thus prevents clinical access to the impacted tooth (Burden et al. 1999) or when the orthodontic attachment detaches during traction mechanics (Pearson et al. 1997).

Other complications can occur in which no second procedure can be of assistance, notably resorption (Blair et al. 1998), necrosis and ankylosis (Roberts-Harry et al. 2004). This last instance presents the worst scenario. Encountered in one of our patients, it was treated by extraction.

Enhanced management of impacted teeth can be achieved in daily practice by implementing the dental impaction charter which we submit in conclusion to our study. The charter comprises three items:

- Prevention: by means of awareness campaigns, early screening and interceptive treatment (extraction of the temporary tooth at the site of impaction);
- A scale of difficulty: this would allow practitioner to take the appropriate treatment decision according to the level of difficulty presented by each clinical situation as determined by a number of factors;
- A global treatment protocol: information is gathered during the initial history-taking and the clinical examination and complemented by radiological examinations including a panoramic, an occlusal check-bite, and even a CT-scan, depending on the case.

If surgical-orthodontic treatment is scheduled, it is essential to coordinate the appointments with both the orthodontist and the surgeon. The following considerations should be taken into account:

- space opening if space is inadequate;
- preferably a closed eruption technique with the least aggressive osteotomy possible;
- orthodontic traction with alignment of the tooth in the arch;
- gingivoplasty if the periodontal tissue is of unsatisfactory quality.

Furthermore, the practitioner should consider the benefit/risk ratio as well. In some instances, it is advisable to refrain from treatment.

9. Clinical cases

Clinical case 1

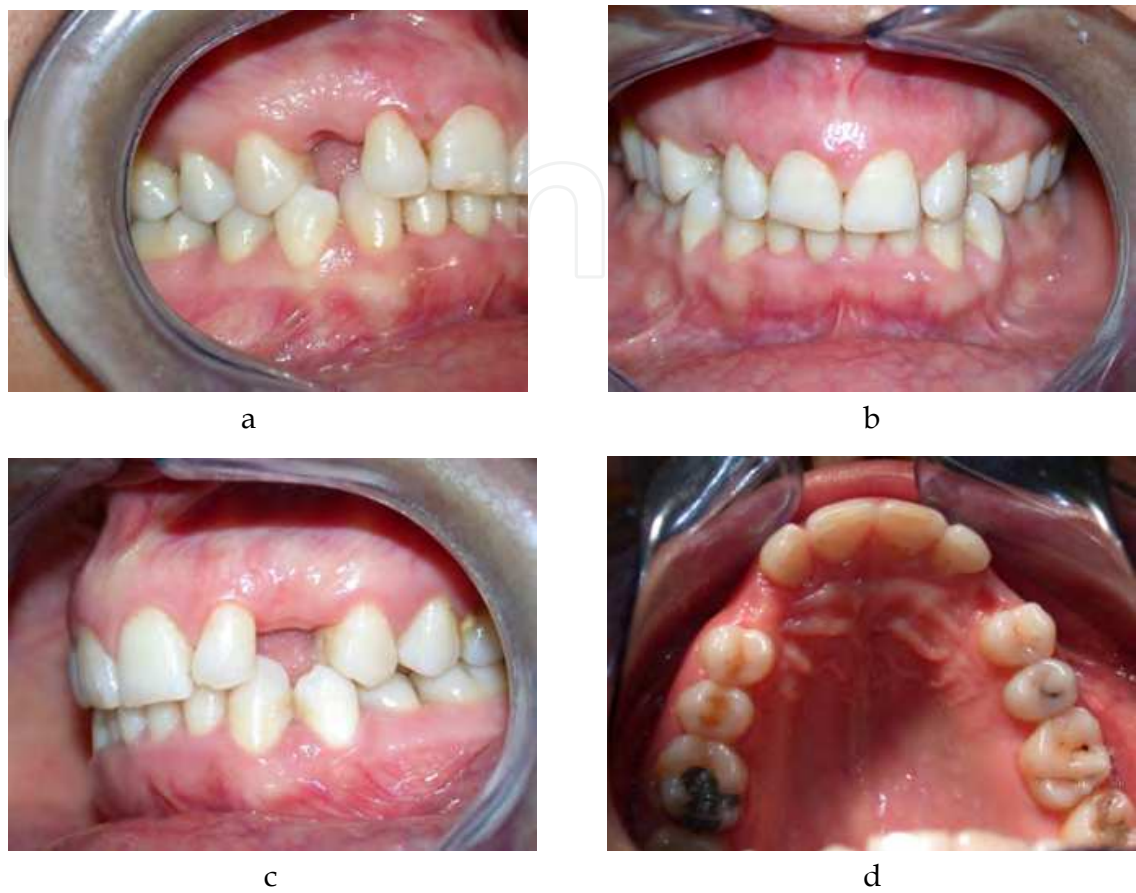

Fig. 12. a, b, c, d: Views buccal, right, front and left at the start of treatment. We note the absence of 13 and 23 with persistence of their spaces on the arcade. On palpation, we note the presence of palatal voussoirs.

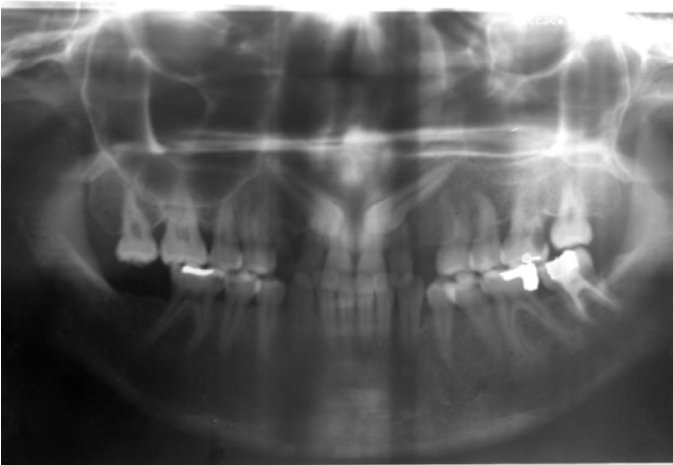

Fig. 13. The panoramic photograph shows the presence of 13 and 23 which have an inclination mesially and whose images are superimposed with those of the roots of the maxillary incisors.

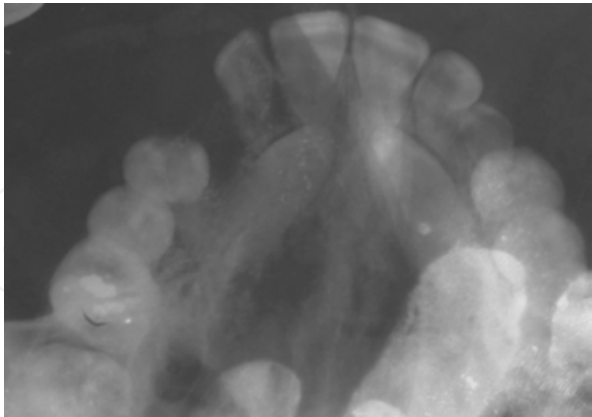


Fig. 14. The Occlusal check-bit shows the palatal position of 13 and 23.

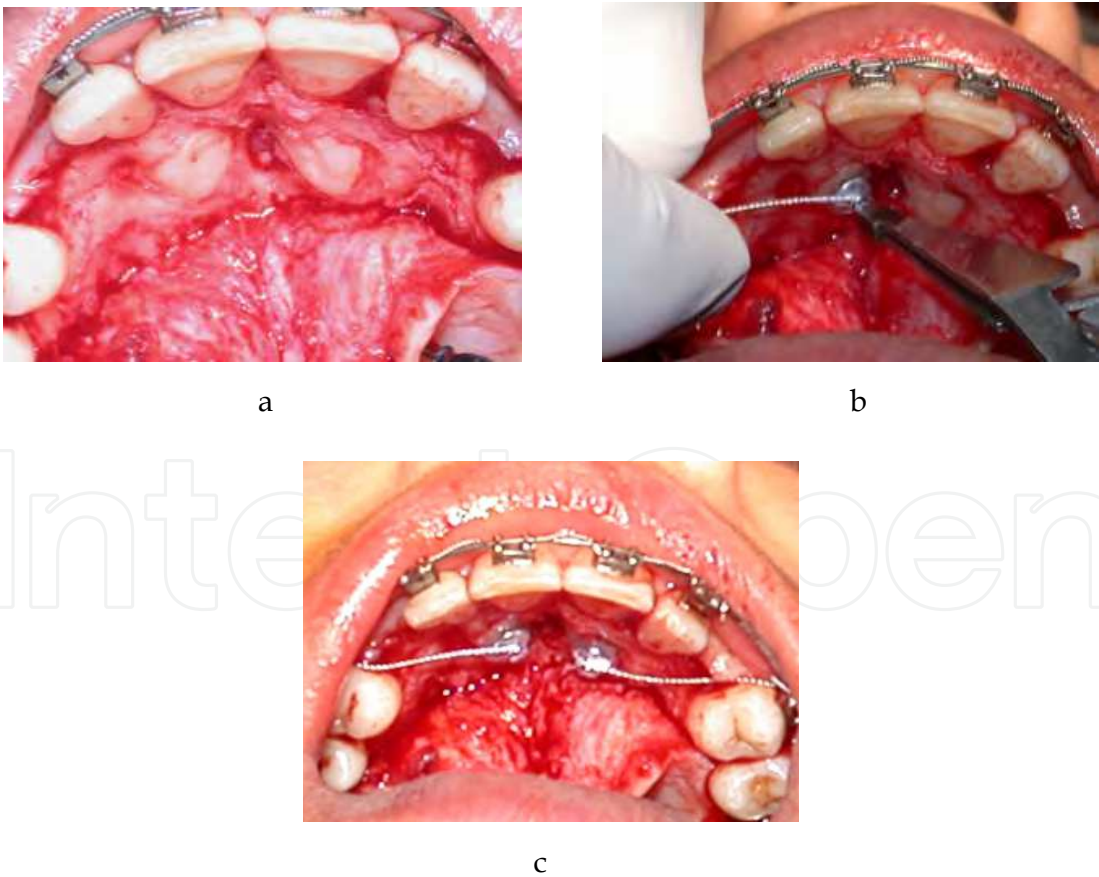


Fig. 15. a, b, c: a palatal flap ranging from 14 to 24 is off. After the release bone, the palatal surfaces of 13 and 23 are exposed. The clip provided with a tie wire is attached during surgery.

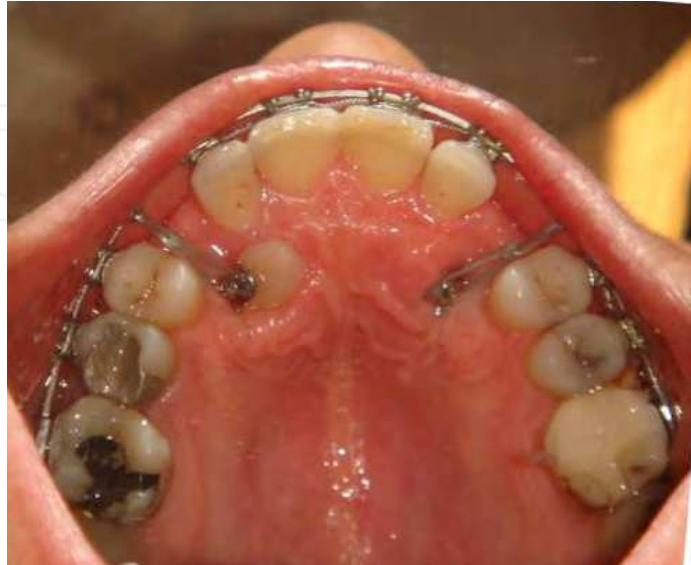

Fig. 16. The traction of 13 and 23 is made using elastic. A window gum can be achieved to facilitate the orthodontic traction.

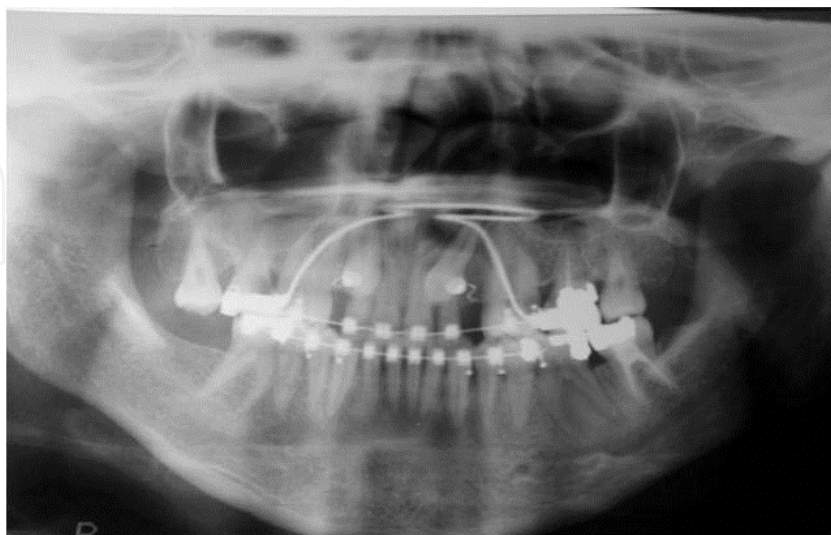
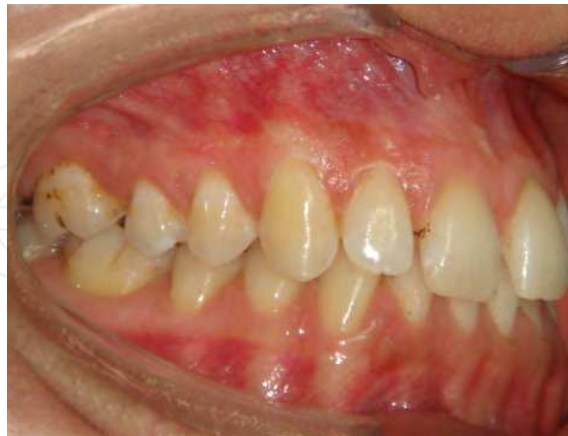
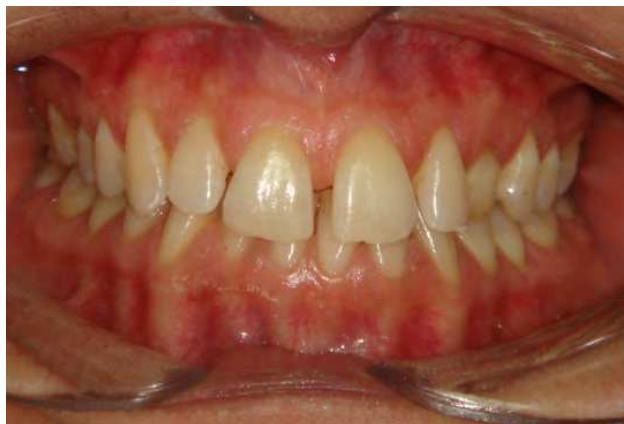
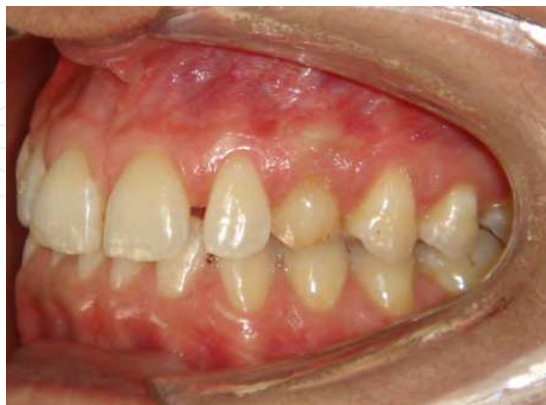Fig. 17. The panoramic photograph shows the favorable axis of 13 and 23.

Clinical case 2

a



b



c

Fig. 18. a; b ;c : Views of buccal, right, front and left at the start of treatment. We note the absence of the 23 with persistence of 63 on the arcade.

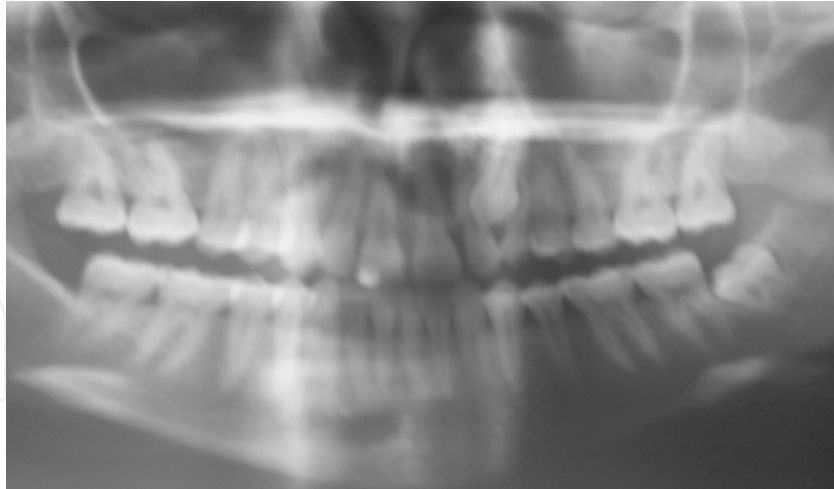


Fig. 19. The panoramic photograph shows the presence of 23 which is inclined mesially and whose axis is favorable for an attempt to orthodontic traction.

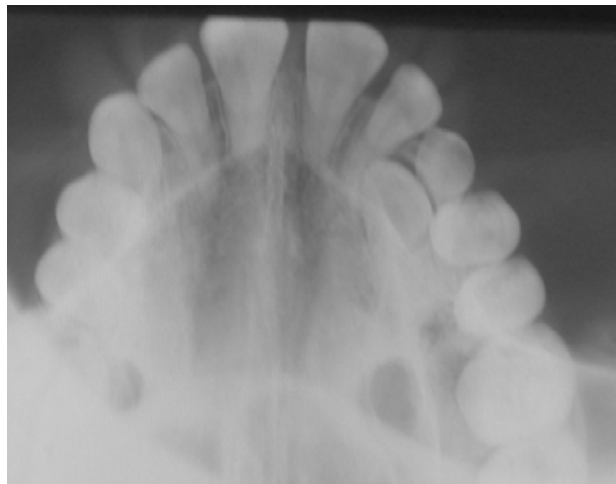


Fig. 20. The Occlusal check-bit shows an intermediate position of 23, the crown appears in buccal position and the root in palatal position.

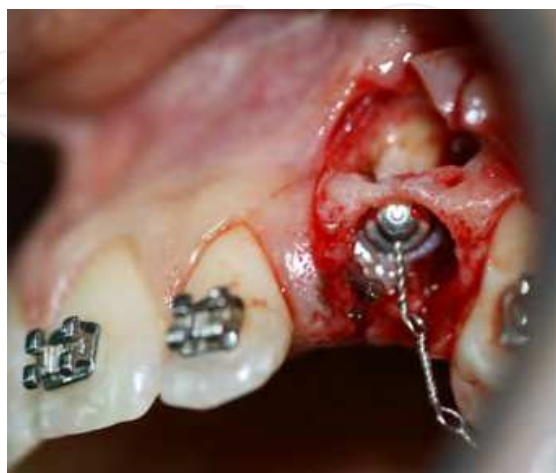
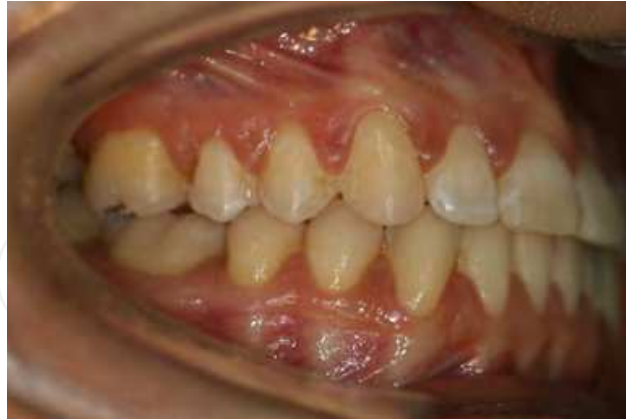
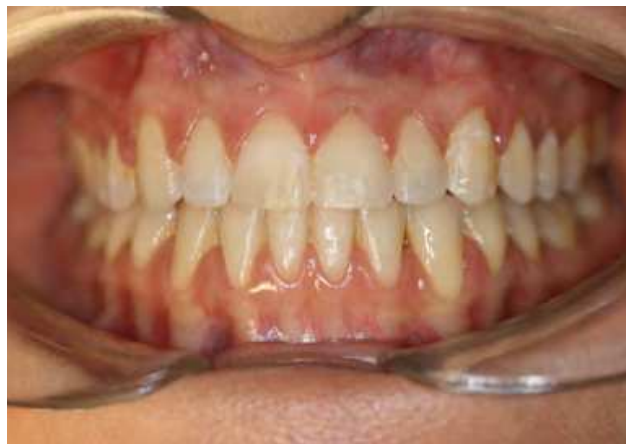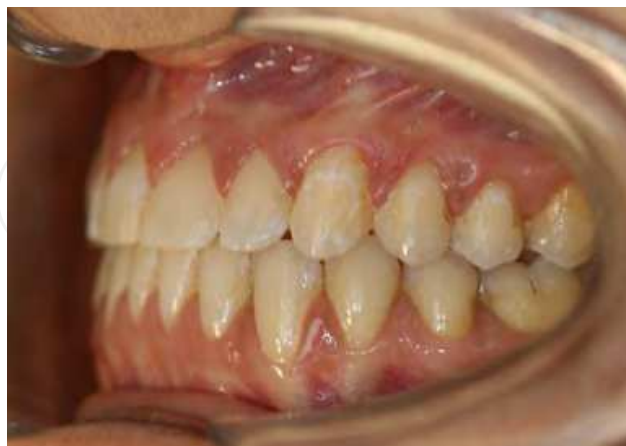Fig. 21. Apically positioned flap was performed. The clip was bonded to the buccal surface of 23.



a



b



c

Fig. 22. a; b ;c : Views of buccal, right front and left at the end of treatment. We note the establishment of 23 that seems built on both the aesthetic and functional.

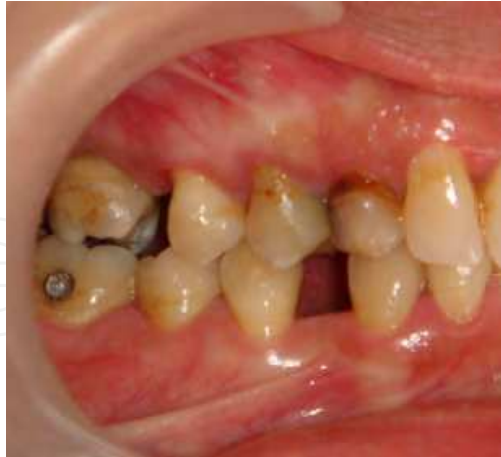Clinical case 3

Fig. 23. Intraoral labial view of right at the start of treatment. We note the absence of the 13 with persistence of 53 on the arcade.

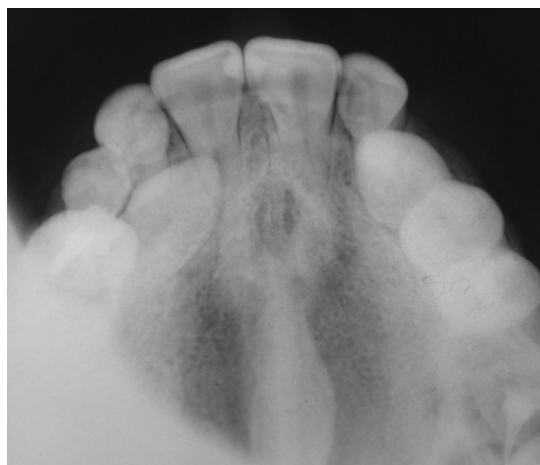

Fig. 24. The Occlusal check-bit shows palatal position of the 13.

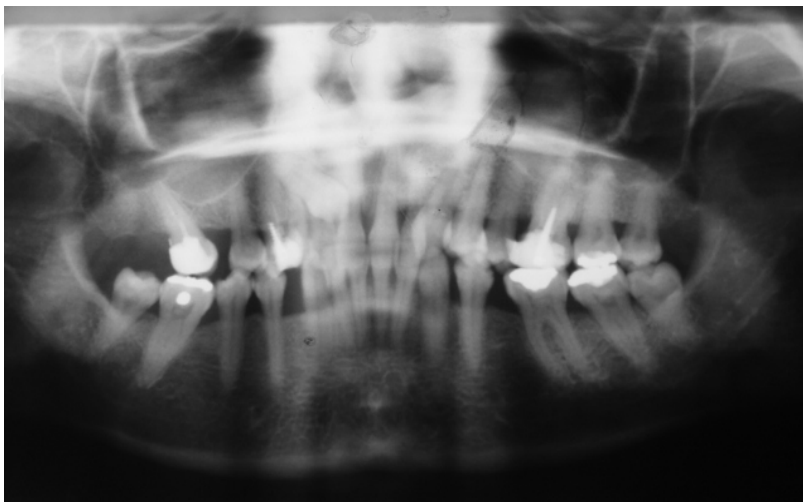


Fig. 25. The panoramic photograph shows the presence of 23 which is inclined mesially and whose axis is favorable for an attempt to orthodontic traction.

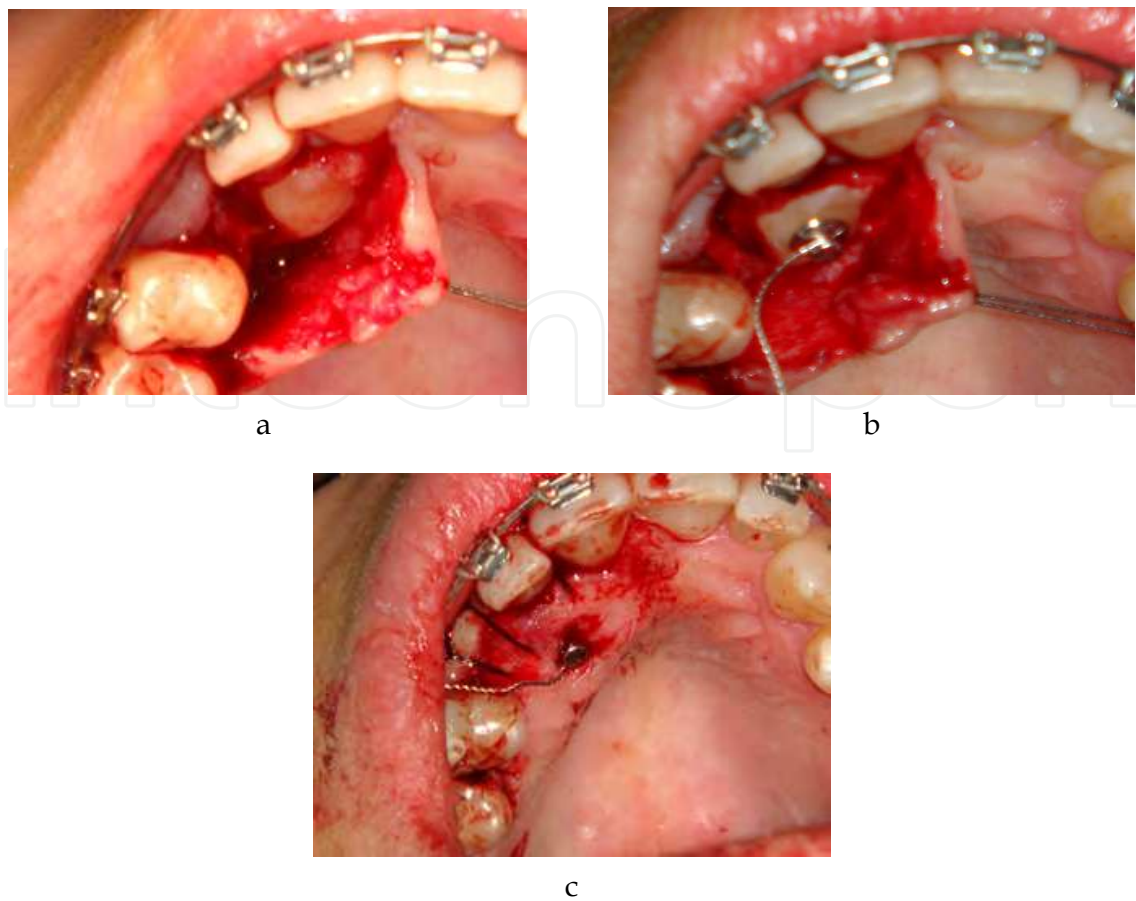


Fig. 26. a, b, c: a palatal flap is lifted off. The palatal surface of 13 is exposed. The clip provided with a tie wire is attached during surgery.

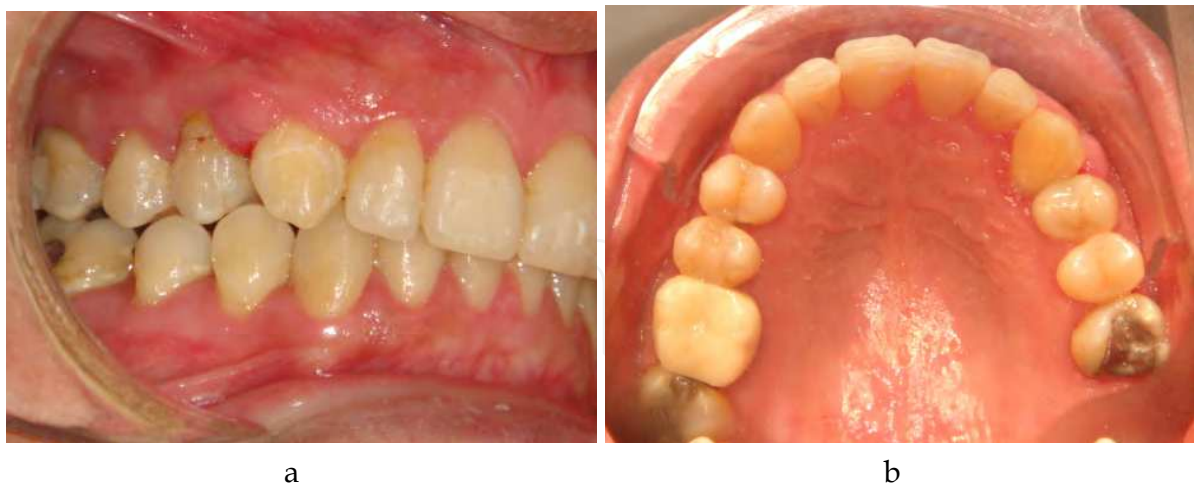

Fig. 27. a; b: View vestibular intraoral right, and view of occlusal jaw at the end of treatment. We note the establishment of 13.

10. Conclusion

Dental impaction confronts the practitioner with a serious challenge. Failure of the various approaches can be highly frustrating.

Treatment for dental impaction is a complex procedure on account of the wide range of cases encountered and the difficulty involved in making a precise and, most importantly, an early diagnosis and adequate treatment plan. Nevertheless, the treatment of choice for the placement of the unerupted tooth in the arch will involve close collaboration between orthodontists and surgeons.

The 70% success rate achieved on the 30 cases treated in our study is the result of a close partnership between the two specialties. Nevertheless, this figure can be improved still further by following the threefold strategy described above for the management of impacted teeth.

11. Acknowledgment

I would like to express my gratitude to my colleague Pr. Samir Diouny for his big help with the translations.

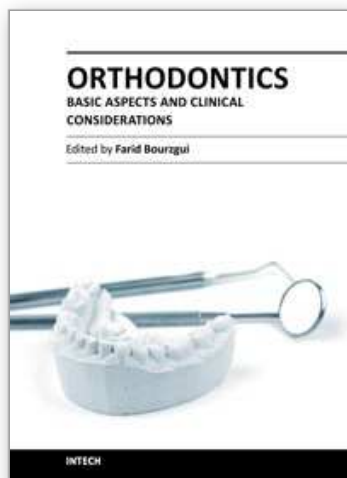
12. References

- Al Hussain I. Contribution à l'étude de la canine maxillaire incluse. [these 3e cycle], Strasbourg, 1988. 128p.
- Altounian G. Mise en place de la canine maxillaire en ectopie palatine. *Orthod Fr* 1997; Vol 68:291-6.
- Archer WH. Oral surgery. 4th ed. Philadelphia: WB Saunders Co, 1996.
- Baron P. Désinclusion orthodontico-magnétique des canines. *J Edge* 2001; Vol 43:59-71.
- Benoit R., Leduc J.P., Genon P. Considérations orthodontiques et parodontales pour la mise en place des canines en bordure des fentes labio-alvéolaires. *J Parodont* 1989; Vol 8:139-154.
- Blair GS, Hobson RS, Leggat TG. Posttreatment assessment of surgically exposed and orthodontically aligned impacted maxillary canines. *Am J Orthod Dentofacial Orthop.* 1998; Vol 113:329-32.
- Bordais P. ET AL. Les dents incluses. *Encycl. Med. Chir. Paris, Odontologie ; 22032 G10*, 10-1980.
- Borghetti A., Monnet-Corti V. Chirurgie Plastique Parodontale. Ed: CdP Paris, 2000.
- Bourzgui F, Belhaj S, Tazi H, Hamza M, Khazana MM. *Int Orthod.* 2009 Sep;7(3):257-67
- Burden DJ, Mullally BH, Robinson SN. Palatally ectopic canines: closed eruption versus open eruption. *Am J Orthod Dentofacial Orthop.* 1999;Vol 115:640-4.
- Chambas C. Désinclusion et mise en place des dents retenues. *Encycl Méd Chir (Elsevier SAS, Paris), Odontologie*, 23-492-A-10,1997.
- Chatellier J, Chateau M, Kolf J, Landart L. Notes sur le traitement chirurgico-orthodontique des dents retenues et incluses. *Actual Odontostomatol (Paris)* 1962; Vol 59:293-318.
- Crismani AG, Freudenthaler JW, Weber, Bantleon RH. Canines supérieures incluses – méthodes conventionnelles de diagnostic radiologique et de traitement. *Rev Mens Suisse Odontostomatol* 2000,Vol 110:1264-1268.
- Dupont S, Durand B. Approche préventive et orthopédique des canines maxillaires incluses dans les cas de brachygraphie maxillaire. *J Edge* 2001;Vol 43:85-99.
- Durivaux S, Viennet D, Demetz P. Alvéolectomie conductrice de la canine supérieure permanente. *Rev Odontostomatol (Paris)* 1979; Vol 8:91-3.

- Eiholtz B, Salaun R, Brethaux J, Allain P, Huard JL. Conduite à tenir devant la rétention de l'incisive centrale supérieure. *Actual Odonto Stomatol* 1979;Vol 128:751-65.
- Ericson S, Kurolj. Radiographic examination of ectopically erupting maxillary canines. *Am J Orthod Dentofac Orthop* 1987, Vol 91:483-492.
- Ericsson S, Kurol J. Resorption of incisors after ectopic eruption of maxillary canines: a CT study. *Angle Orthod* 2000; Vol 70:415-23.
- Favre de Thierrens C, Cantaloube D, Delestan C, Goudot P, Predine- Hug F, Torres JH. Nouvelle classification médicochirurgicale odontostomatologique des dents incluses. *Encycl Méd Chir (Elsevier SAS,Paris), Odontologie*, 23-400-A-19, 2003.
- Favre de Thierrens C, Moulis C, Bigorre M et De la Chaise S. Inclusion dentaire (I). Aspects biologiques, odontogéniques, physiologiques et pathologiques. *Encycl Méd Chir (Elsevier SAS), Stomatologie*, 22-032-A-15, *Odontologie*, 23-400-A-16, 2003.
- Garcia R. Canine quand tu nous tiens! *Rev Orthop Dentofac* 1990; Vol 24: 359-66.
- Goho C. Delayed eruption due to overlying fibrous connective tissue: case reports. *J Dent Child* 1987; Vol 54:359-360.
- Hunter S. Treatment of the unerupted maxillary canine. *Brit dent J* 1983; Vol 154:294-296.
- Hurme VO. Ranges of normalcy in the eruption of permanent teeth. *J Dent Child*. 1949; Vol 16:11-5.
- Isaacson K G, Thom A R. Guidelines for the use of radiographs in clinical orthodontics. British Orthodontic Society, London 2001.
- Izard G. *Orthodontie* Masson et Cie ;édit. ;Paris,1950
- Korbendau JM, Guyomard F. Apport de la chirurgie parodontale à la mise en place des canines en dystopie vestibulaire. *Rev Ortho Dent Fac* 1980; Vol 14:459-477.
- Korbendau JM, Guyomard F. *Chirurgie parodontale orthodontique*. Editions CdP 1998.
- Korbendau JM, Pajoni D. Canines maxillaires, inclusions profondes, diagnostic : choix du protocole opératoire. *J Parodontol Implantol Orale* 2000; Vol 19:279-89.
- Korbendeau JM., Patti A. *Le traitement orthodontique et chirurgical des dents incluses* Quintessence Internationale, Paris, 2005.
- Lacoste J.L. Désinclusion et mise en place des dents retenues. *Encycl. Med .Chir. , Paris, odontologie* 23492 A10, 1-1988,9.
- Langlade M. *Thérapeutique orthodontique*. Paris: Maloine; 1986 (863p).
- Le Breton G. *Traité de sémiologie et clinique odonto-stomatologique*. Paris CdP 1997:100-109.
- Magnusson H. Saving impacted teeth. *J Clin Ortho* 1990;24:246-249.
- Mc Connelt. L., Hoffman D.L., Forbes D.P., Janzen E.K., Weintraub N.H. Maxillary canine impaction in patients with transverse maxillary deficiency. *J dent Child* 1996;63:190-195.
- Monnet-Corti V, Borghetti A. Canines incluses et chirurgie plastique parodontale. *Rev Odont Stomat* 2003;32:259-277.
- Nabbout F, Faure J, Baron P, Braga J, Treil J. L'ancrage dentaire en orthodontie : les données du scanner. *Int Orthod* 2004; Vol 2:241-56.
- Pearson MH, Robinson SN, Reed R, Birnie DJ, Zaki GA. Management of palatally impacted canines: the findings of a collaborative study. *Eur J Orthod*. 1997; Vol 19, N°5:511-5.
- Peck S., Peck L., Katajam. Site specificity to tooth agenesis in subjects with maxillary canine malpositions. *Angle Orthodontist* 1996; Vol 66:473-476.

- Quirynen M, Opheij DG, Andriasens A, Opdebeek HM, Van Steenberghe D. Periodontal health of orthodontically extruded impacted teeth. Asplit mouth, long-term clinical evaluation. *J Periodontol* 2000; Vol 71:1708-14.
- Rajic S, Muretic Z, Percac S. Impacted canine in a prehistoric skull. *Angle Orthod.* 1996;66:477 -80.
- Roberts-Harry D, Sandy J. Orthodontics. Part 10: Impacted teeth. *Br Dent J.* 2004; Vol 196:319-27; quiz 362.
- Sasakura H., Xoshida T., Murxama S., Hamadak., Makajima T. Root resorption of upper permanent incisor caused by impacted canine. An analysis of 23 cases. *Int J Oral Surg* 1984; Vol 13:299-306.
- Thomine F., Korbendau J.M., Martineau C. - Mise en place chirurgico-orthodontique des dents retenues. *Réalités Clin* 1995;6:351-369.
- Treil J, Casteigt J, Madrid C, Borianne P. Une nouvelle construction céphalométrique tridimensionnelle. Un nouveau paramétrage d'analyse tridimensionnelle : les axes d'inertie. Un nouveau concept de l'équilibre maxillo-facial. *Orthod Fr* 1997; Vol 68:171-81.
- Vichi M., Franchi L. Eruption anomalies of the maxillary permanent cuspids in children with cleft lip and or palate. *J Clin Pedia Dent* 1996; Vol 20:149-53.
- Vigneul J.C. Extraction chirurgicale des canines incluses *Act. Odonto-Stomatol.* 1974; Vol 105 :53-78
- Wong-Lee TK, Wong FC. Maintaining an ideal tooth-gingiva relationship when exposing and aligning an impacted tooth. *Br J Orthod.* 1985; Vol 12:189-92.

IntechOpen



Orthodontics - Basic Aspects and Clinical Considerations

Edited by Prof. Farid Bourzgui

ISBN 978-953-51-0143-7

Hard cover, 446 pages

Publisher InTech

Published online 09, March, 2012

Published in print edition March, 2012

The book reflects the ideas of nineteen academic and research experts from different countries. The different sections of this book deal with epidemiological and preventive concepts, a demystification of cranio-mandibular dysfunction, clinical considerations and risk assessment of orthodontic treatment. It provides an overview of the state-of-the-art, outlines the experts' knowledge and their efforts to provide readers with quality content explaining new directions and emerging trends in Orthodontics. The book should be of great value to both orthodontic practitioners and to students in orthodontics, who will find learning resources in connection with their fields of study. This will help them acquire valid knowledge and excellent clinical skills.

How to reference

In order to correctly reference this scholarly work, feel free to copy and paste the following:

Farid Bourzgui, Mourad Sebbar, Zouhair Abidine and Zakaria Bentahar (2012). Management of Dental Impaction, Orthodontics - Basic Aspects and Clinical Considerations, Prof. Farid Bourzgui (Ed.), ISBN: 978-953-51-0143-7, InTech, Available from: <http://www.intechopen.com/books/orthodontics-basic-aspects-and-clinical-considerations/management-of-dental-impaction>

INTECH
open science | open minds

InTech Europe

University Campus STeP Ri
Slavka Krautzeka 83/A
51000 Rijeka, Croatia
Phone: +385 (51) 770 447
Fax: +385 (51) 686 166
www.intechopen.com

InTech China

Unit 405, Office Block, Hotel Equatorial Shanghai
No.65, Yan An Road (West), Shanghai, 200040, China
中国上海市延安西路65号上海国际贵都大饭店办公楼405单元
Phone: +86-21-62489820
Fax: +86-21-62489821

© 2012 The Author(s). Licensee IntechOpen. This is an open access article distributed under the terms of the [Creative Commons Attribution 3.0 License](https://creativecommons.org/licenses/by/3.0/), which permits unrestricted use, distribution, and reproduction in any medium, provided the original work is properly cited.

IntechOpen

IntechOpen