

We are IntechOpen, the world's leading publisher of Open Access books Built by scientists, for scientists

6,900

Open access books available

186,000

International authors and editors

200M

Downloads

Our authors are among the

154

Countries delivered to

TOP 1%

most cited scientists

12.2%

Contributors from top 500 universities



WEB OF SCIENCE™

Selection of our books indexed in the Book Citation Index
in Web of Science™ Core Collection (BKCI)

Interested in publishing with us?
Contact book.department@intechopen.com

Numbers displayed above are based on latest data collected.
For more information visit www.intechopen.com



The Use of Mini-Implants (Temporary Anchorage Devices) in Resolving Orthodontic Problems

P. Salehi, S. Torkan and S.M.M. Roeinpeikar

*Orthodontic Research Center, Shiraz University of Medical Sciences, Shiraz
Iran*

1. Introduction

In orthodontic treatment, the final goal is to achieve the desired tooth movement and to reduce the number of unwanted side effects and eventually to improve patient's esthetics.[1] Therefore, different methods for anchorage control has been suggested, such as using the opposing arch, extraoral anchorage, increasing the number of teeth in the anchorage unit or circum-oral musculature.

Nowadays, with the advent of mini-implants, maximum anchorage has become possible and unwanted side effects have been reduced to a minimum. Mini-implants which are also known as Temporary Anchorage Devices (TADs) are small titanium bone screw or stainless steel bone screws which are placed either in buccal alveolar bone or the palatal side. These bone screws can be placed on the paramedian areas of the palate in growing children. [2, 3] The use of TADs can ensure a rigid intra-oral anchorage through which different tooth movements in all three planes of space can be provided. This might as well serve as an alternative to orthognathic surgery, especially in those instances where changes in the vertical dimension are required.[4] They can vary in size form 5-12 mm in length and from 1.2-20 mm in diameter. [5]

Among the pioneers in this field, Linkow was one of the first to use blade implants as an anchorage method for cl II elastics, [6] Later, in 1983, Creekmore and Eklund used vitallium screws placed in the anterior nasal spine region to intrude maxillary incisors as much as 6 mm. [7] it was until later in 1997, that Kanomi described the intrusion of mandibular anterior teeth using mini-implants. [8] Gelgor et al. reported as much as 88% success in molar distalization when the first and second molars were present following immediate loading. [9]

It has been reported that mini-implants can be further divided into two group: 1) those that provide mechanical retention and 2) those that osseointegrate. [10] The process of osseointegration is a histological phenomenon through which the bony tissue is formed around the implant without the presence of fibrous tissue at the interface of implant-bone, [11-13] however, in mechanical retention, those areas which are in direct contact with the bone are in charge of providing the primary stability; while there might be gaps in other areas between the mini-implant and the bone. [10] Osseointegrated devices need a healing period during

which they should not be loaded. Anyhow, it has been reported that immediate loading up to 5 N does not affect the stability of miniscrew or loss of anchorage. [14, 15]

The decision making based on which the site for mini-implant placement is determined depends on the quality and quantity of bone in a particular region as well as interdental root space and the type of malocclusion. [5] The recommended anatomic sites for placement of mini-implant in maxilla include the interdental alveolar process, maxillary tuberosity, palate or anterior nasal spine.[16] As for mandible, the proper anatomic places are symphysis and parasymphysial area, interdental alveolar process and retromolar area. [16]

Correction of vertical problems has become easier with the advent of mini-implants. The envelope of orthodontic tooth movement has well increased and less emphasis needs to be placed upon patient's compliance. Treatment of different patients addressing their orthodontic problems (specially vertical problems) are presented in this chapter.

2. Patients and methods

2.1 Case 1: T.P.

The patient is a 15 year old male who was suffering from crowding both in the upper and lower arches. In order to alleviate the crowding, the patient had extracted the four first premolars based on an old myth that this will resolve the crowding. The spaces did not obviously close following extraction and the patient was referred to the orthodontist due to deep bite and the presence of spacing both in the upper and lower arches. (Figure 1-a to 1-c and 2-a to 2-f) The patient's chief complaint was the presence of spaces in both the maxillary and mandibular arches.

Clinical examination of patient show a slightly retrusive mandible and a nice posed smile. The intraoral photographs exhibit increased overbite, mild maxillary anterior crowding and a class II canine and molar relationship on both sides.



Fig. 1. Figure 1-a to 1-c, patient T.P, pretreatment facial photographs. The patient exhibits a nice social or posed smile, but a convex profile. An analysis of the E-line and S-line of the patient shows that the lips are retruded and therefore, the teeth cannot be further retracted.

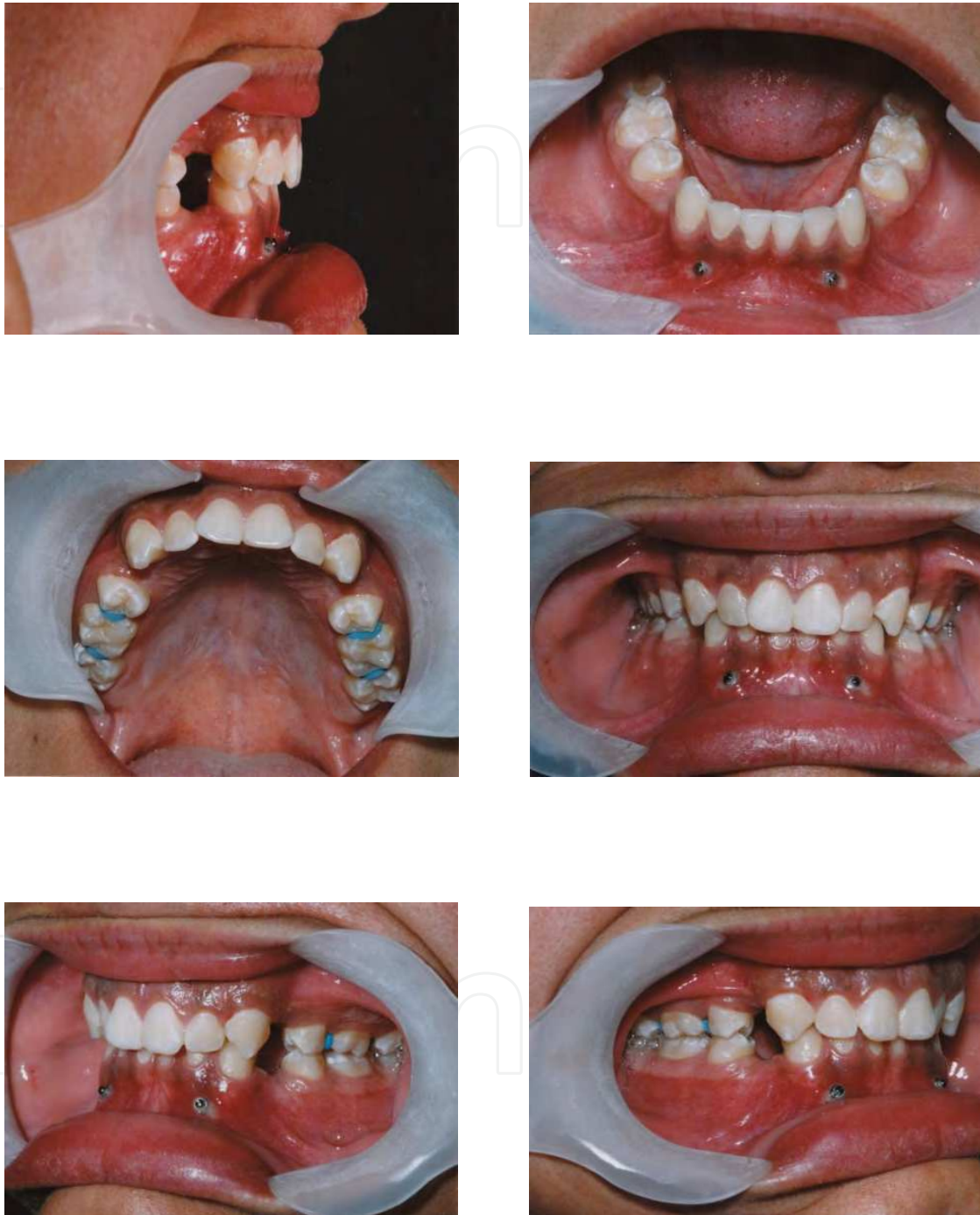


Fig. 2. Figs 2-a to 2-f, the patient had already extracted his four first premolars hoping that this would alleviate the mild crowding present. This had only led to a deep bite and four extraction spaces which looked unaesthetic.

x

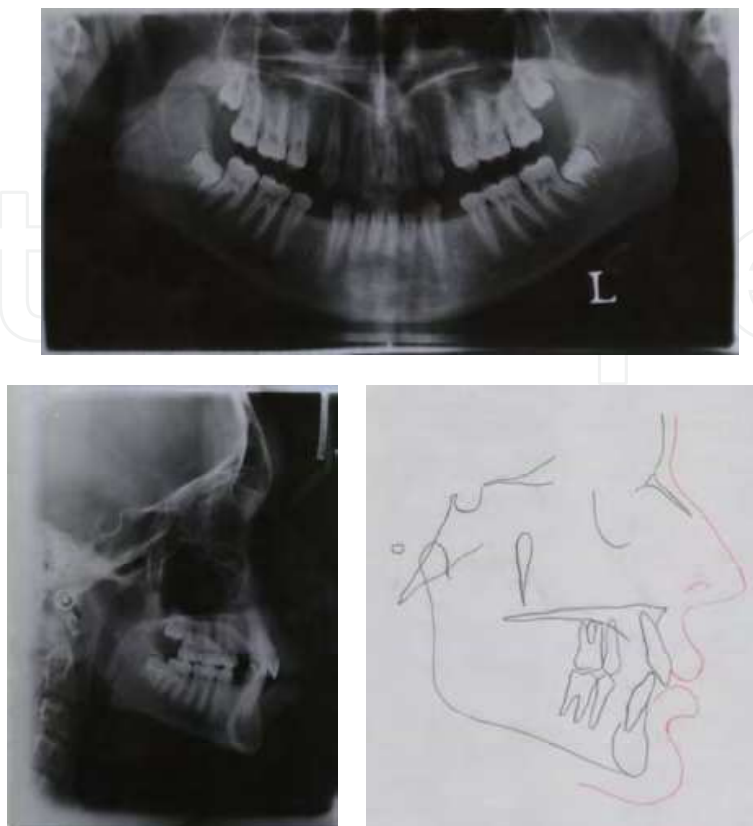


Fig. 3. Figs 3-a to 3-c, pretreatment lateral cephalograms, cephalometric tracing and panoramic radiograph.

Correction of deep bite can be achieved through different methods: extrusion of posterior teeth, upper incisors flaring, upper or lower incisors intrusion. Factors such as lower face height and upper incisor display dictate the technique through which deep bite can be addressed.[17]

Intrusion of anterior teeth has always been challenging and more difficult to attain than extrusion. [18] For intrusion to be successful and efficient, light, continuous forces are desired. [17, 19] This method can be successfully carried out in patients with an increased interlabial gap, increased vertical dimension and excessive gingival display.[20]

Case T.P exhibits acceptable posed smile at rest and upon smiling, therefore, intrusion of the upper incisors would not be a wise choice. Extrusion of posterior teeth, even though easier to achieve has a higher tendency for relapse but it tends to rotate the mandible backward and downward and thus aggravate the convex profile.[21] Based on the aforementioned factors, intrusion of lower incisors is the logical treatment approach.

Lower and upper arch were set up with 0.018-in slot standard edgewise braces. In the lower arch, segmented technique was used to intrude anterior teeth. Two mini-implants, 1.6 mm in diameter and 8.0 mm in length were placed between the roots of mandibular lateral incisors and canines for en masse intrusion of lower incisors by chain elastics. In the rest of treatment the lower anterior teeth were tied to the miniscrews in order to prevent them from

relapse after their intrusion and to prepare anchorage for upper and lower posterior teeth to protract.

After intrusion the lower arch was replaced by a continuous arch wire. The mini-implants were used in this stage of treatment for upper and lower posterior segment protraction. Lower posterior teeth were protracted one by one. Protraction of upper posterior teeth was done by class III elastics. So, the miniscrews were used as an indirect anchorage to close the spaces in the upper arch. In addition, As the upper anterior teeth were not retracted and the canine relationship was class II it was necessary for the lower anterior teeth to be protracted by increased lower arch wire and use of miniscrews. (Figures 4-a to 4-c)

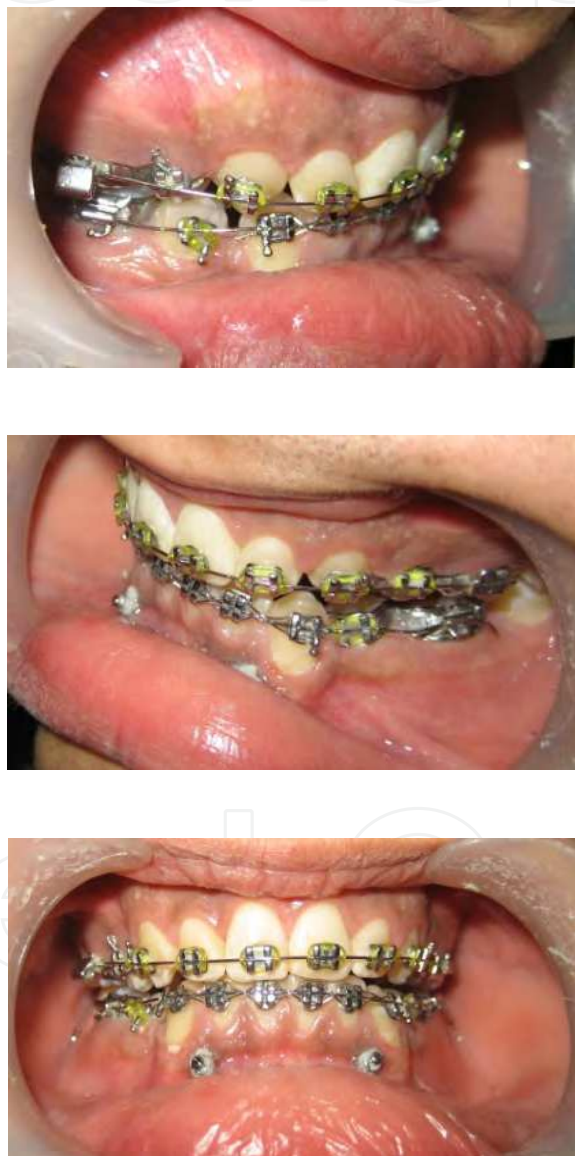

Fig. 4. Figs 4-a to 4-c, progress intraoral photographs, Protrusion of upper and lower anterior teeth along with intrusion of lower incisors was needed to achieve the optimal overbite.

At 12 months, treatment was completed (figure 5-a to 5-h and figures 6-a to 6-c). Fixed retainers extending from premolar to premolar were bonded in maxilla and mandible.

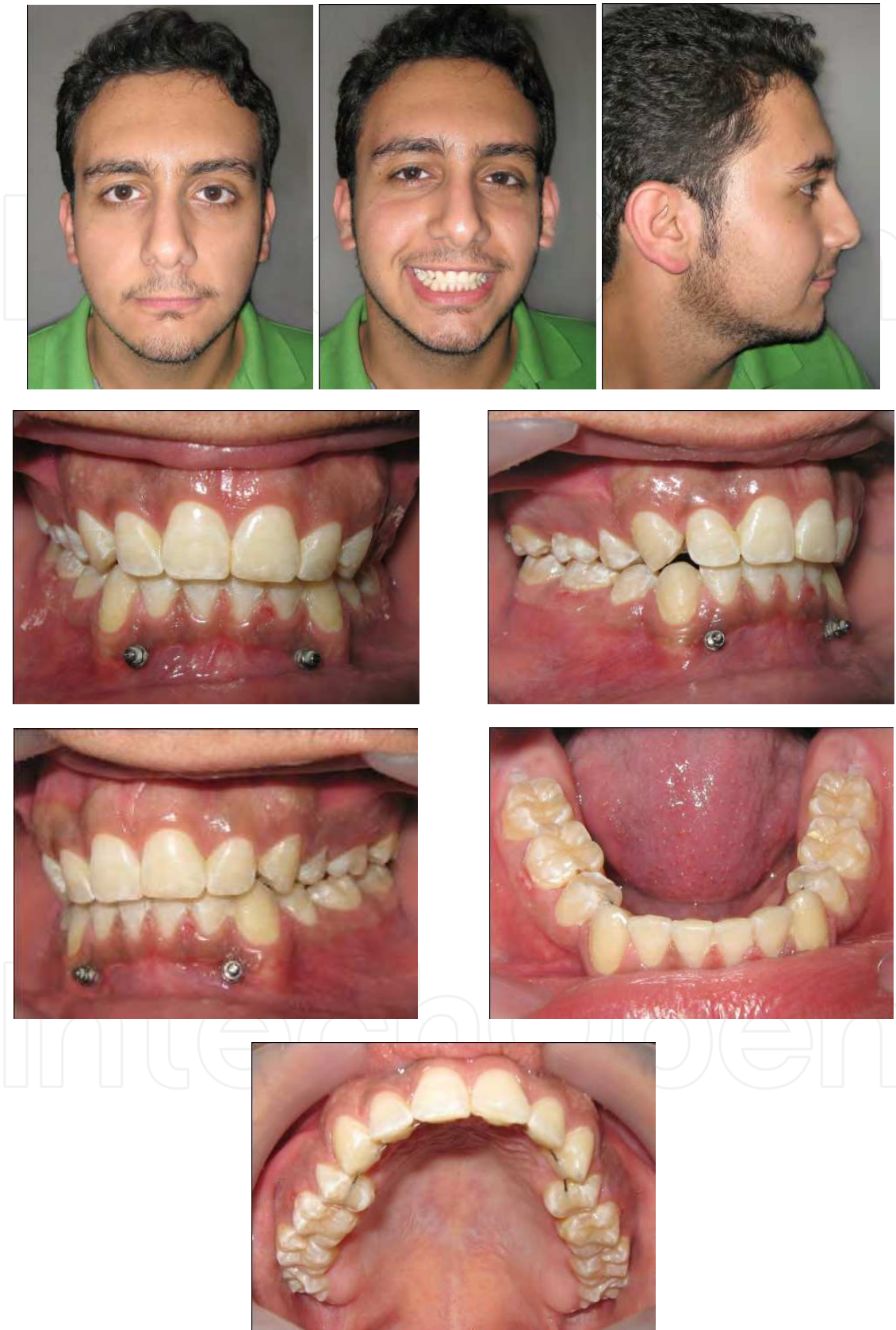


Fig. 5. Figs 5-a to 5-h at 11 months, treatment is completed. Notice the marked improvement in the facial profile and overbite.

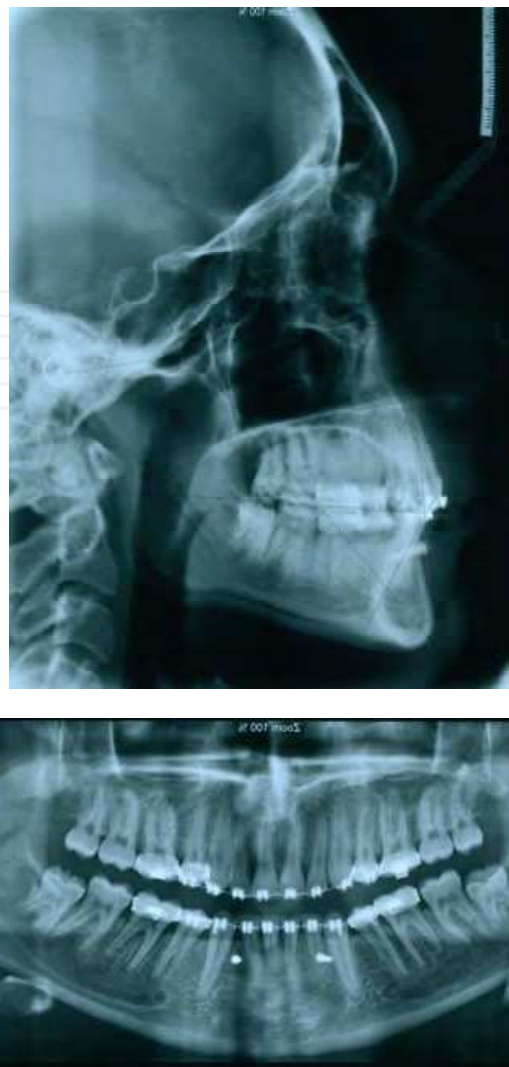

Fig. 6. Figs 6-a to 6-c, posttreatment cephalogram and panoramic radiograph.

2.2 Case 2: J.V.

The patient is a 16-year-old girl with a class II canine relationship on both sides and a very deep overbite. Her chief complaint was irregular teeth.

The pretreatment facial photographs show a retrusive mandible and moderate crowding of the maxillary anterior teeth. The pretreatment intraoral photographs exhibited full class II molar and canine relationship on both sides, severe deep bite along with retroinclination of maxillary central incisors (fig 7-a to 7-I)

Cephalometric analysis showed a class II skeletal relationship due to mandibular deficiency (SNB angle, 71°), A-point was also retruded (SNA angle, 75°). The FMA was within the normal range (26°). Maxillary incisor to SN plane was 87° which is much smaller than the normal range. IMPA was 94° which is within the normal range. In other words, the maxillary incisors were linguoversion and mandible is slightly retruded.

The ideal treatment was to create a normal overbite and overjet relationship, reduce the anteroposterior skeletal discrepancy and obtain a class I canine and molar relationship.

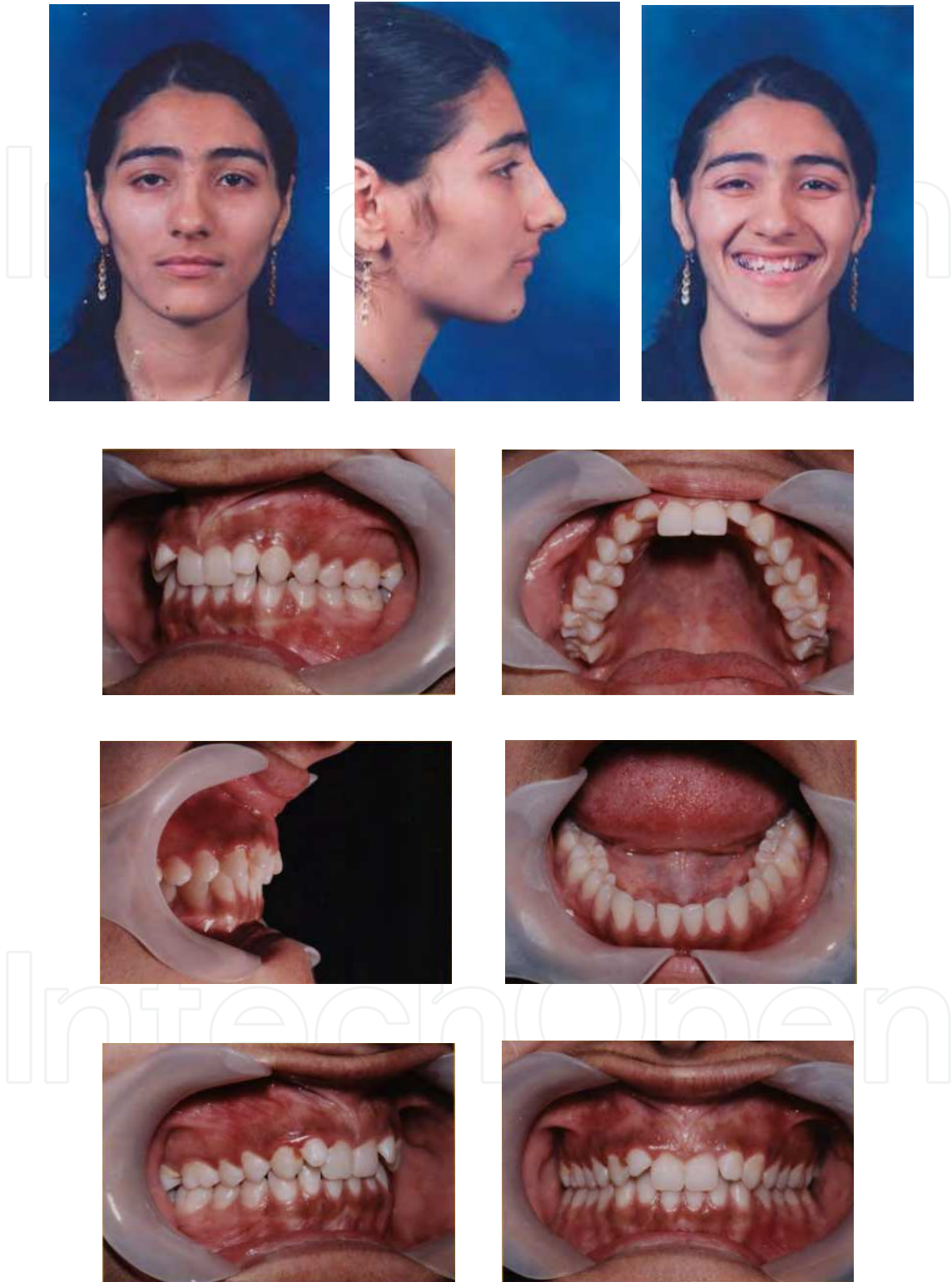


Fig. 7. Fig 7-a to 7-i, pretreatment facial and intraoral photographs. Notice the retruded mandible and marked retroinclination of maxillary central incisors.

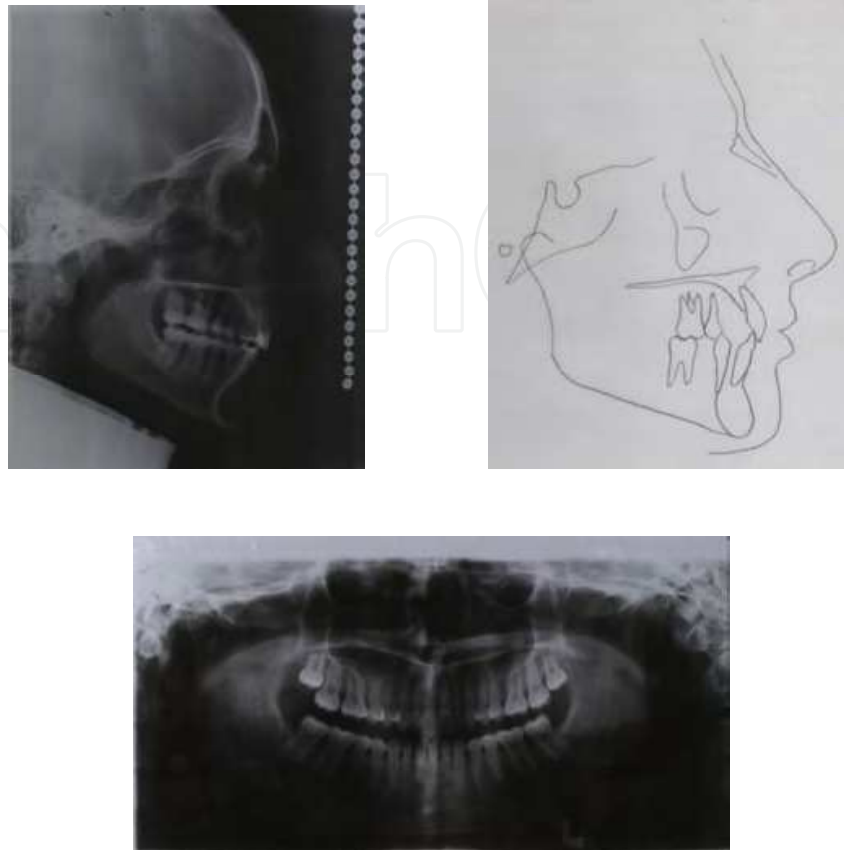


Fig. 8. Figs 8-a to 8-c, pretreatment cephalogram, cephalometric tracing and panoramic radiograph.

The ideal treatment approach would be orthognathic surgery during which maxillary anterior teeth are proclined forward to obtain some overjet and move the mandible forward. However, the patient is past the age of growth modification and is not willing to undertake surgery as well. The treatment alternative would be distalization of maxillary dentition to provide space for leveling and aligning of maxillary incisors. However, distalizing the teeth tends to extrude them which makes the mandible to rotate backward and downward and thus worsen the facial profile. Therefore, it is essential that distalization of maxillary molars be carried out without extrusion.

Missing of mandibular third molars permitted the second upper molars to be extracted. Therefore, Initially maxillary second molars were extracted and it was decided that the maxillary third molars would eventually replace the extracted teeth . Then, a segmented arch technique (0.018-in slot) was fabricated in the maxillary arch to prevent protrusion of the maxillary incisors while distalization of maxillary molars was being carried out. Two mini-implants 2mm in diameter and 10 mm in length were placed in paramedian midsagittal raphe. A transpalatal bar (0.38-in) was fabricated which was soldered to the bands cemented on maxillary molars. Anchorage was provided from the mini-implants to distalize the maxillary molars and at the same time prevent extrusion of maxillary molars. (figure 9-a to 9-f)

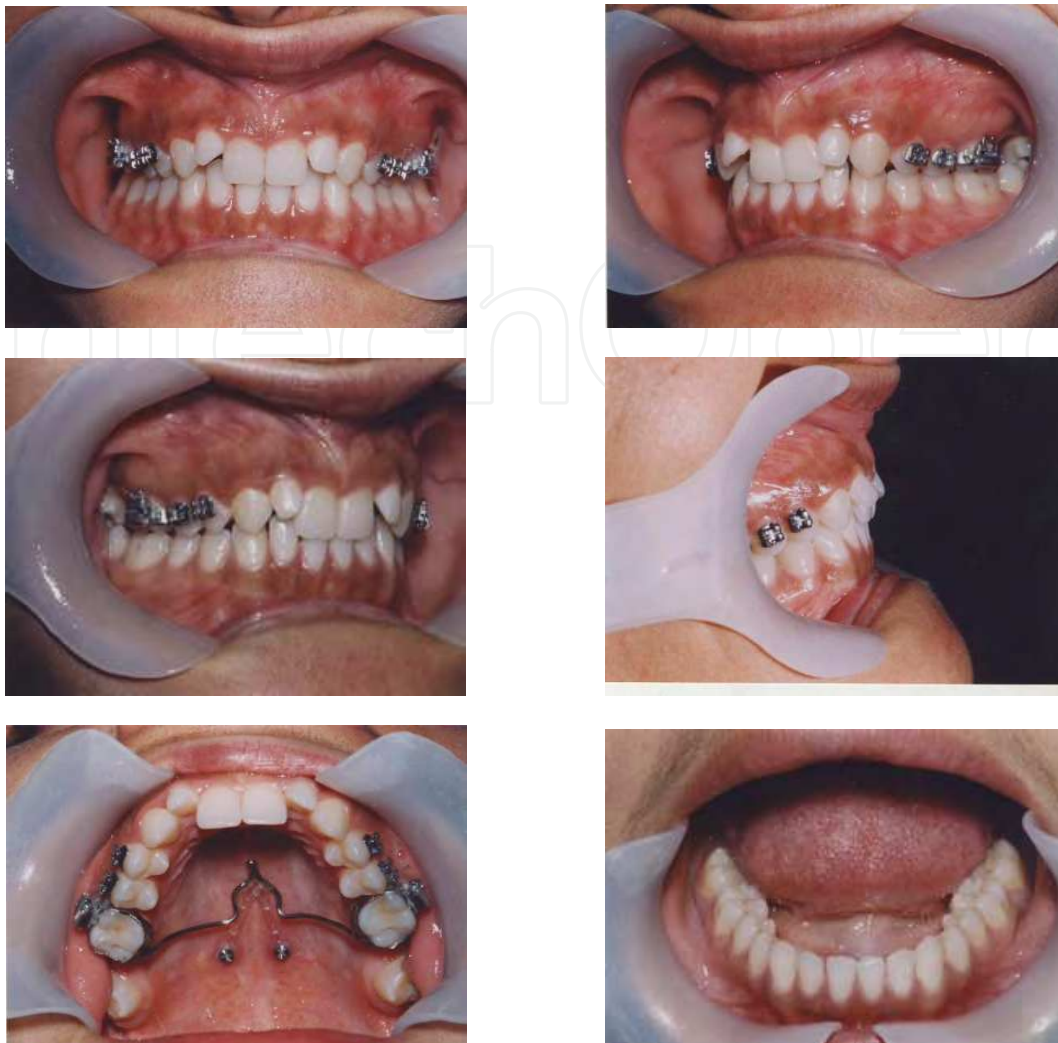


Fig. 9. Figs 9-a to 9-f, A modified version of transpalatal bar is fabricated in the maxillary arch to help distalize maxillary molars. As you see first upper molars have started to rotate.

Retraction of all posterior maxillary teeth were intended during the course of distalization, maxillary first molars started to rotate (mesial in and distal out) due to the location of mini-implants and the resultant untoward moment on them, therefore two other miniscrews were inserted in the buccal vestibule in the position of extraction of the second upper molars. The position where the miniscrews were to be inserted was critical in this case because if they were inserted too far mesially, distal root of the first molar could be cut off while they were being retracted. On the other hand, if they were inserted too far distally the third molars could not be repositioned mesially to replace the extracted second molars.

While retracting upper posterior teeth lower teeth and upper anterior teeth were not set up since it was not necessary and also the patient was sensitive on her appearance And wanted to reduce the time during which she had to bear braces in the anterior area to a minimum. Therefore, for the major part of her treatment process which included the retraction of upper posterior teeth she was free of braces in the esthetic zone. Once a class I canine and molar relationship was attained, the transpalatal bar was removed to minimize the irritation in the palatal mucosa (figures 10-a to 10-f).

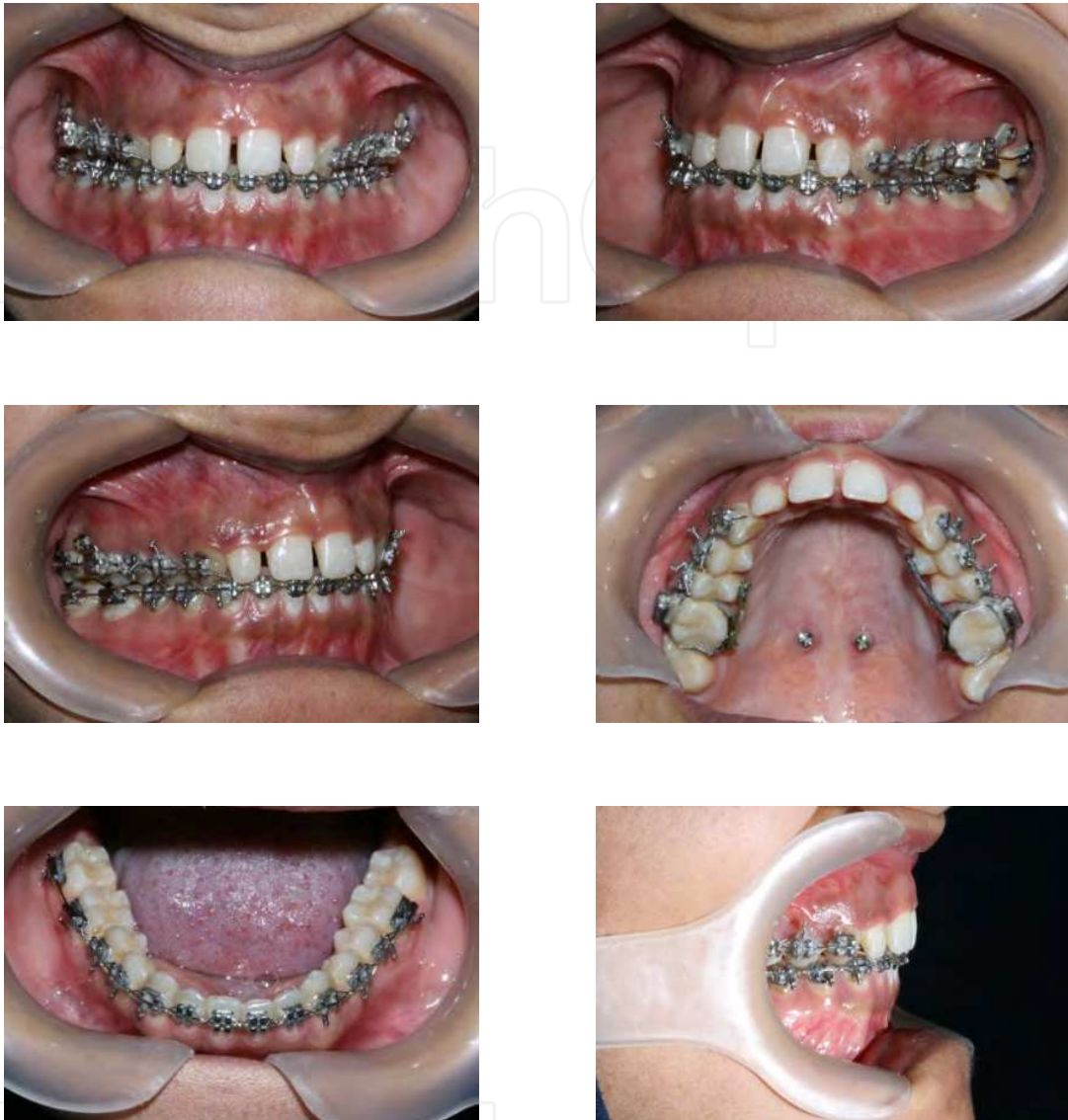


Fig. 10. Figs 10-a to 10-f, progress intraoral photographs at 6 months. A class I molar and canine relationship is maintained. Notice the miniscrews in the buccal vestibule. The transpalatal bar is removed to eliminate the irritation of soft tissue.

Upper lateral incisors were small-sized and had thus resulted in anterior Bolton discrepancy. The patient was referred for composite build up of lateral incisors to gain normal tooth size. Total treatment time was 15 months. The mini-implant and the transpalatal bar were well tolerated by the patient. The post treatment intraoral photographs show a class I canine and molar relationship. Overbite is corrected. Facial harmony is very good. The pretreatment and posttreatment superimposition of lateral cephalograms shows no backward or downward rotation of mandible. Fixed canine to canine retainers were bonded in the maxilla and mandible (figures 11-a to 11-I and figures 12-a to 12-c)

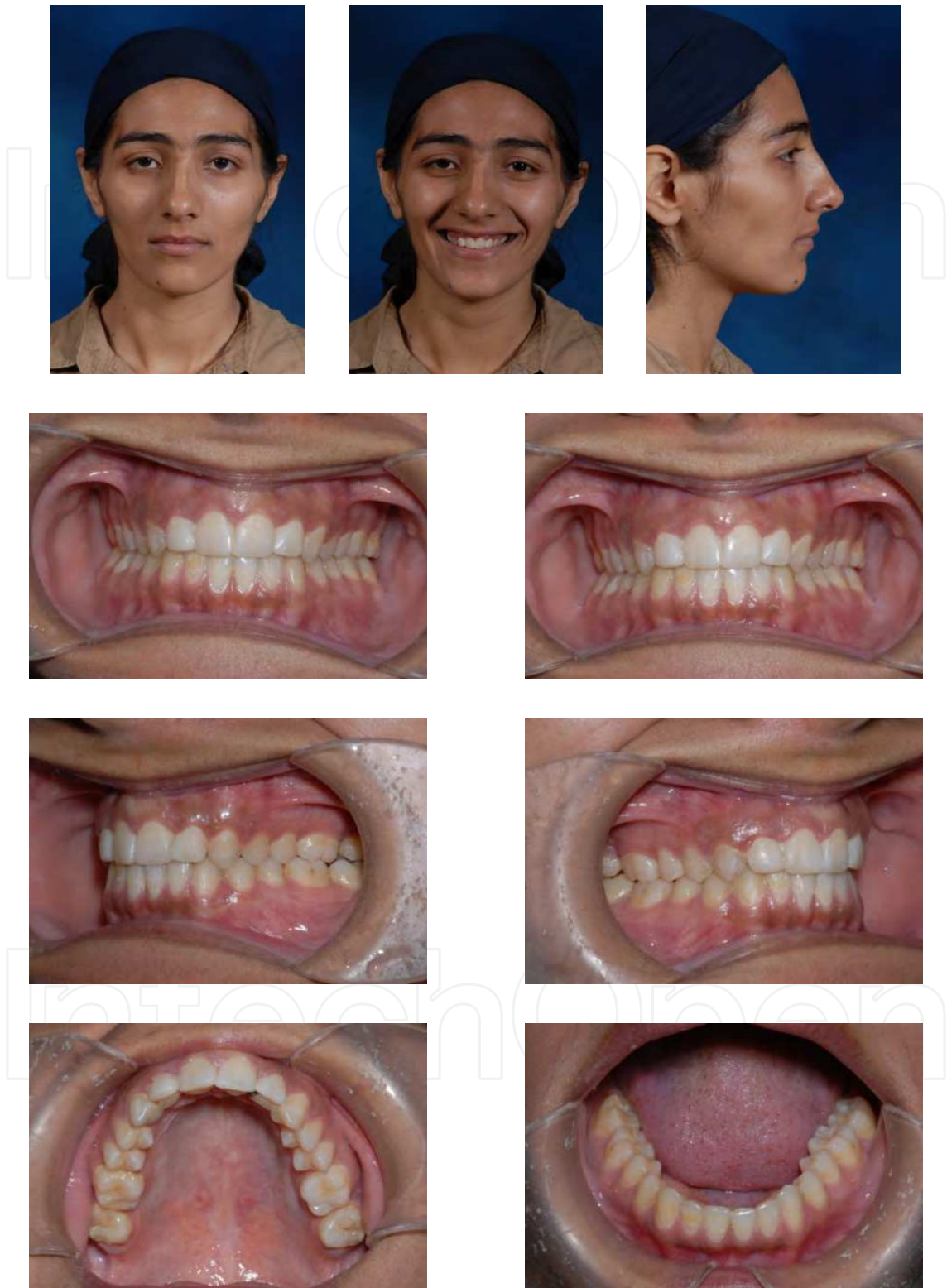

Fig. 11. Figs 11-a to 11-I, posttreatment facial and intraoral photographs. Correction of increased overbite and class II molar and canine relationship.

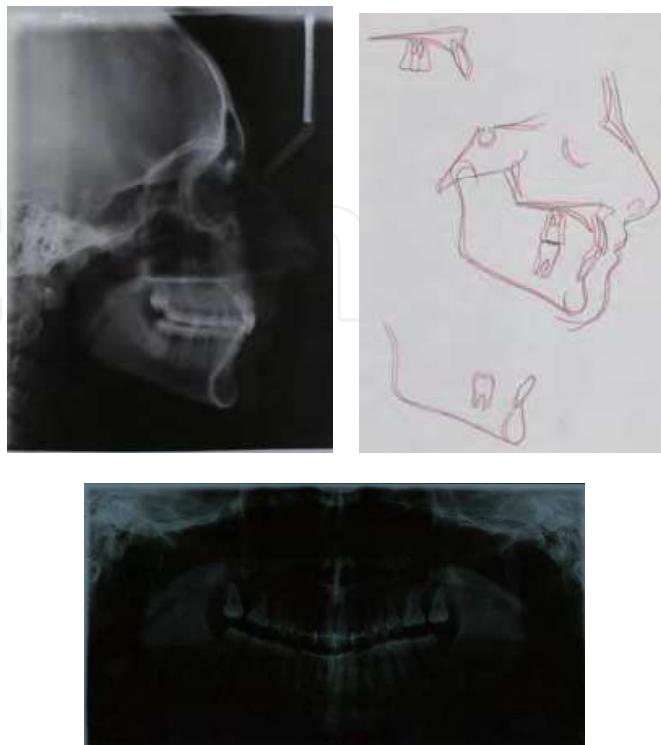


Fig. 12. figs 12-a to 12-c, post treatment cephalogram, superimposition of pretreatment (red) and post treatment (black) cephalometric tracings, and panoramic radiograph.

2.3 Case R.R.

The next patient is a 31-year-old female who was once referred to a maxillofacial surgeon with a chief complaint of gummy smile. The surgeon had performed a maxillary impaction and an advancement genioplasty on the patient without presurgical orthodontic treatment. The patient eventually was not satisfied with the results and was therefore, referred to the orthodontist. Her chief complaints were gummy smile and the present spacing.

The pretreatment facial photographs exhibit facial asymmetry along with a cant of maxillary occlusal plane. Clinical examination revealed a deviated midline (2mm). Spacing could be noticed at different areas both in maxillary and mandibular dentition. The four first premolars had already been extracted in earlier years to help alleviate crowding, but no further orthodontic treatment was carried out on the patient to consolidate the arches (figures 13-a to 13-j)

Cephalometric analysis revealed a retrusive mandible (ANB angle 7°) and an increased IMPA angle (94°). The SNA angle was within the normal limits (82°); however, SNB angle was decreased (75°). In other words, patient had a skeletal class II profile accompanied with mandibular dental compensation (figures 14-a to 14-c). The patient was not willing to undergo another orthognathic surgery to correct the existing problems and since the four first premolars had already been extracted, extracting yet another tooth was out of question.

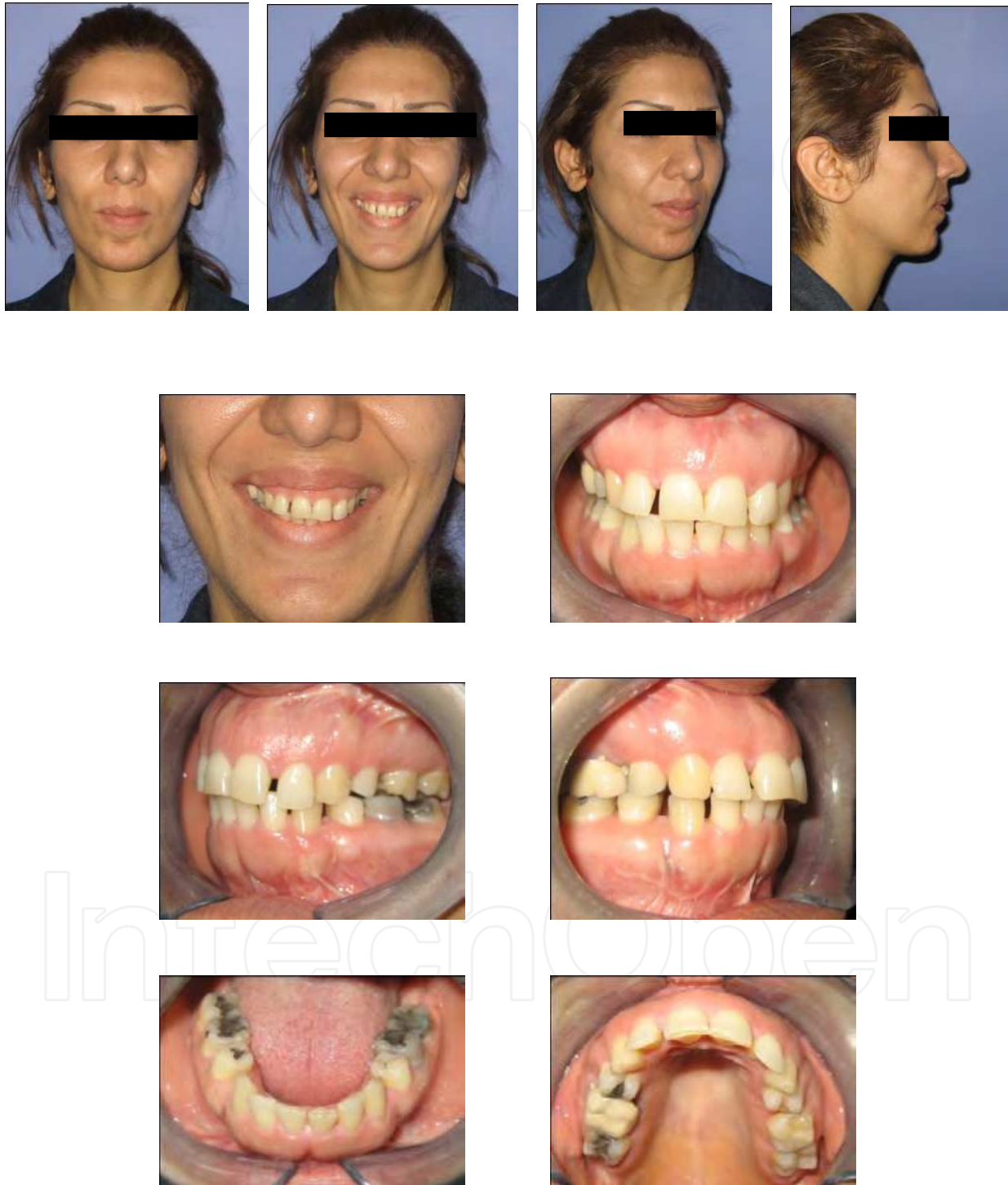

Fig. 13. Figs 13-a to 13-j pretreatment facial and intraoral photographs, the four first premolars had already been extracted; notice the canted maxillary occlusal plane and excessive gingival display.

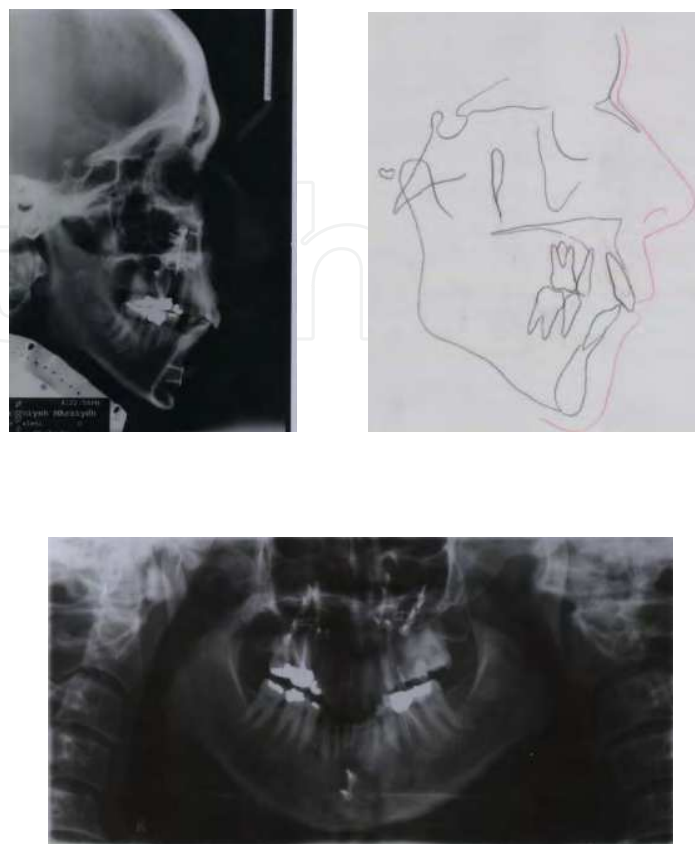


Fig. 14. figs 14-a to 14-c, pretreatment cephalogram, cephalometric tracing and panoramic radiographs.

The treatment goals were to address the patient's chief complaints, i.e correct the canted occlusal plane and close the spaces. Two mini-implants of 1.4 in diameter and 6.0 mm in length were placed between the roots of maxillary lateral incisors and canines. Initially a continuous 0.016 NiTi arch wire was placed as the initial arch wire. With the progress in the size of the arch wire, after 2 months, a 0.016×0.022-in stainless steel segmented arch wire was placed extending from left to right maxillary lateral incisors. In order to decrease the gummy smile, the patient was asked to wear $\frac{3}{16}$ - in latex elastics from the anterior segment to the mini-implants. Since, the equal use of both mini-implants would not correct the canted occlusal plane, the patient was asked to wear the latex elastic to the left mini-implant two days in a row and to the right mini-implant once every three days (figure 15-a to 15- f)

Consecutive use of latex elastics in the anterior region has the disadvantage of irritating the labial frenum, thus, decreasing the patient cooperation. After 1 month, in lieu of latex elastics, elastomeric chains were used. After intrusion of the upper anterior teeth and correction of its cant, continuous 0.016 SS arch wire was inserted in the upper and lower arches. Midline correction and space closure was carried out in both arches at this stage. Meanwhile, the upper anterior teeth were tied to the miniscrews to prevent their relapse after intrusion.

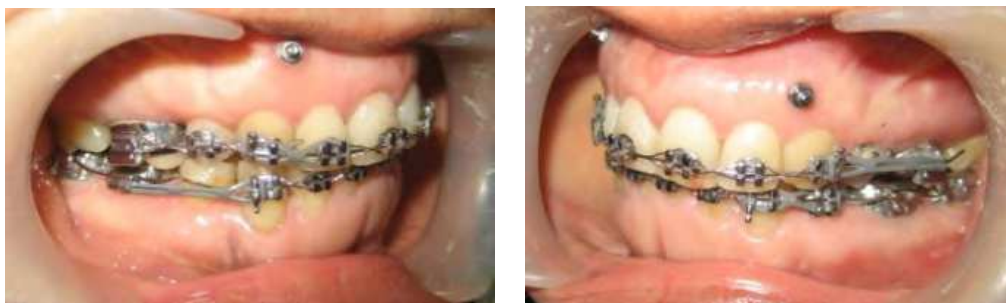
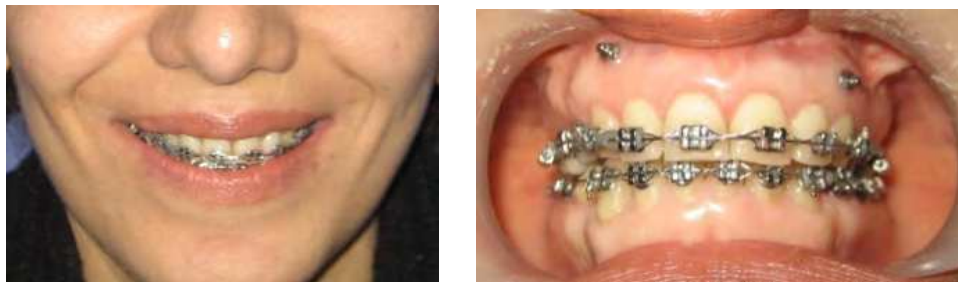
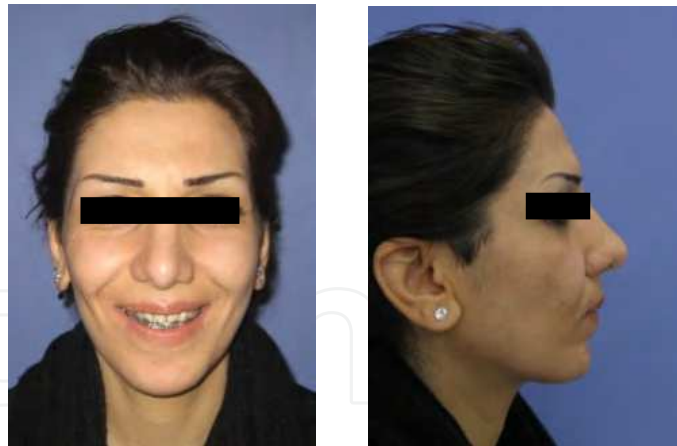Fig. 15. Figs 15-a to 15-f, progress facial and intraoral photographs, mini-implants are placed between the roots of lateral incisor and canine to address gummy smile and canted occlusal plane.

After 13 months, the treatment was completed. The patient was very well satisfied with the changes in her appearance. The gummy smile and canted occlusal plane had resolved significantly. Fixed retainers extending from second premolar to second premolar were bonded in the maxilla and mandible (figures 16-a to 16-h). Post treatment cephalometric tracing revealed 6 mm intrusion of maxillary incisors without a significant difference in the inclination of upper incisors (upper incisors to SN angle, pretreatment : 106° , post treatment: 105°) (figures 17-a to 17-d).

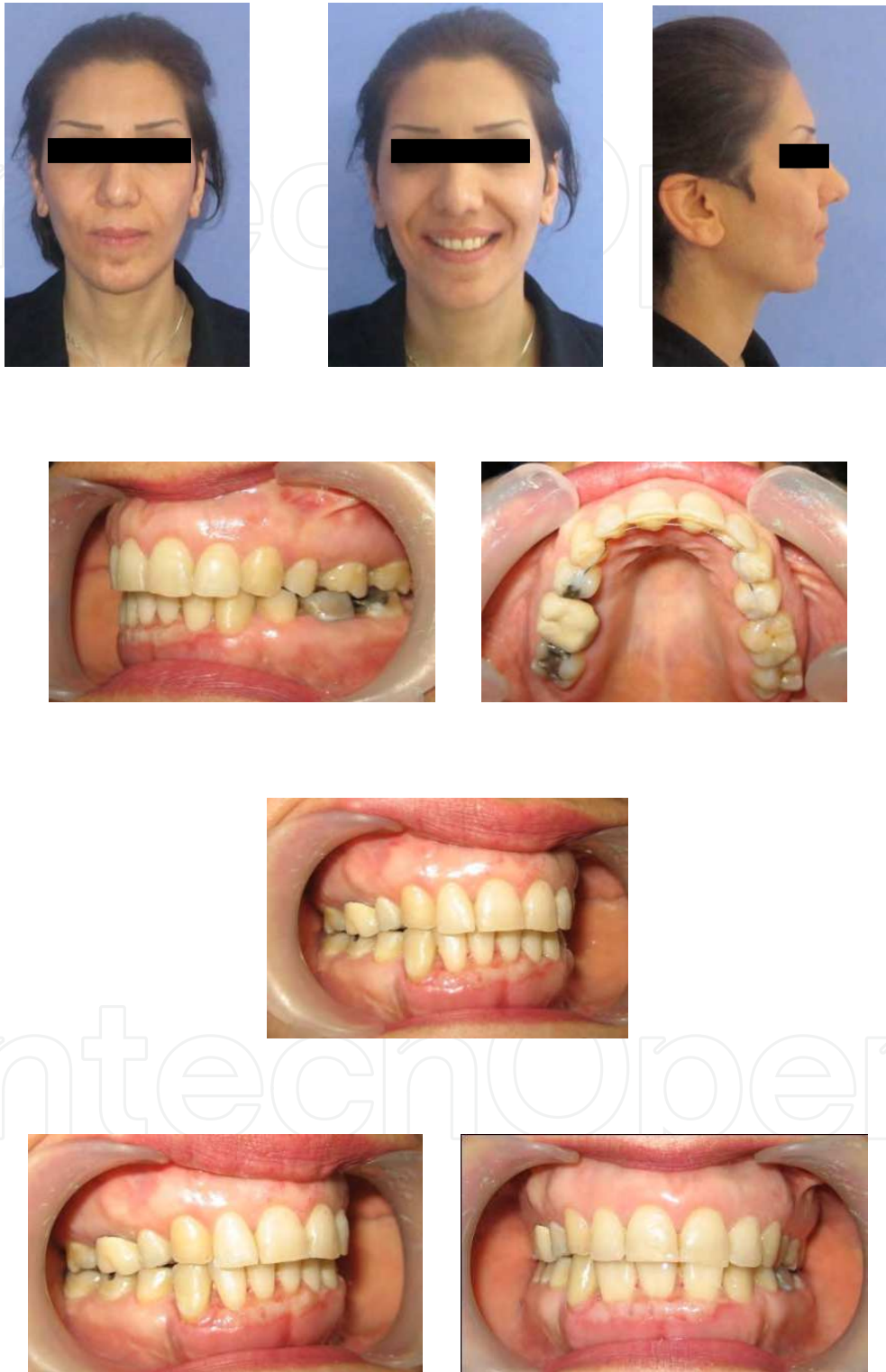


Fig. 16. Figs 16-a to 16-h, post treatment facial and intraoral photographs, notice the correction of the canted occlusal plane and gummy smile.

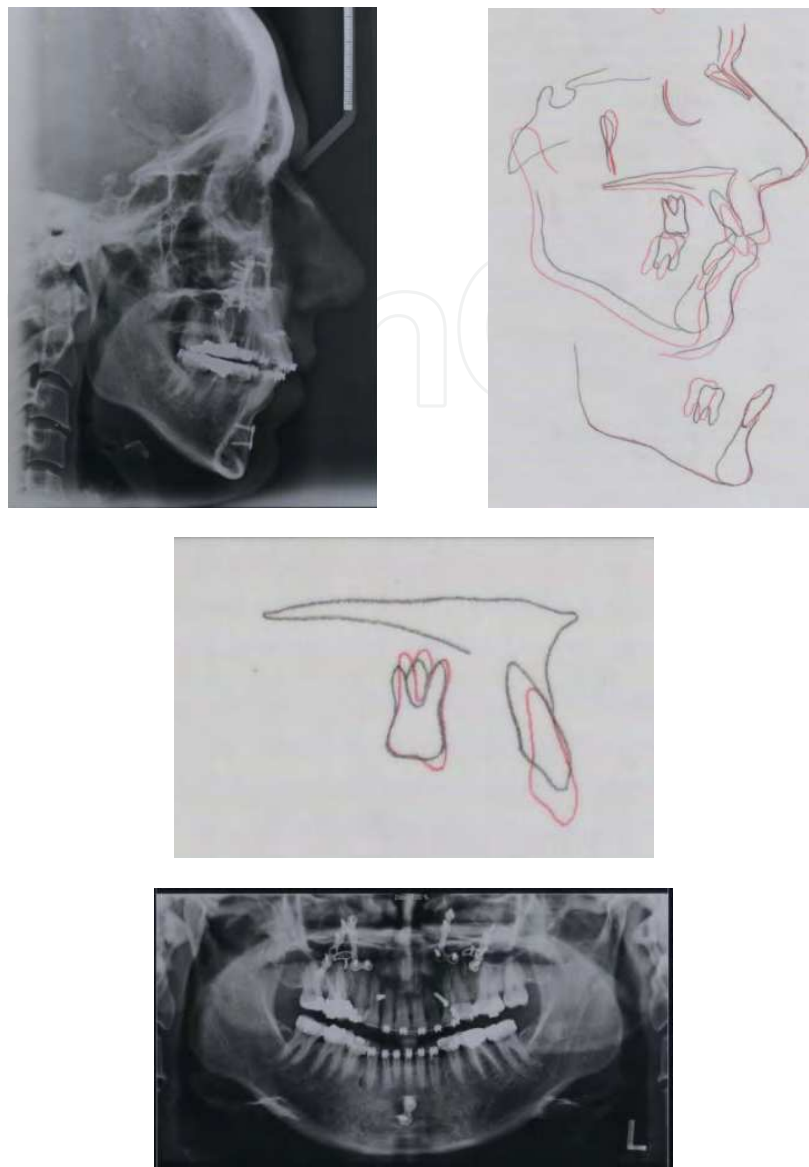


Fig. 17. Figs 17-a to 17-d. post treatment cephalogram, superimposition of pretreatment (red) and post treatment (black) cephalometric tracings and panoramic radiograph.

2.4 Case R.T.

This patient was a 31-year-old female with a class I molar and canine relationship. Her chief complaints were protrusion of her teeth and inability to bring her lips together.

Clinical examination revealed bimaxillary dentoalveolar protrusion with excessive gingival display upon rest and lip incompetence. She exhibited slight facial asymmetry with her chin deviated to the left and also a class I molar and canine relationship and spacing distal to both maxillary lateral incisors (figures 18-a to 18-h)

Cephalometric analysis showed the A-point and B-point to be protruded (SNA angle 89° and SNB angle 85°). The upper incisor angle was increased (126°) and IMPA was also much larger than normal (105°). The interincisal angle was 97° . The ANB angle was 4° . In other words, the patient showed bimaxillary dentoalveolar protrusion (figures 19-a to 19-c).

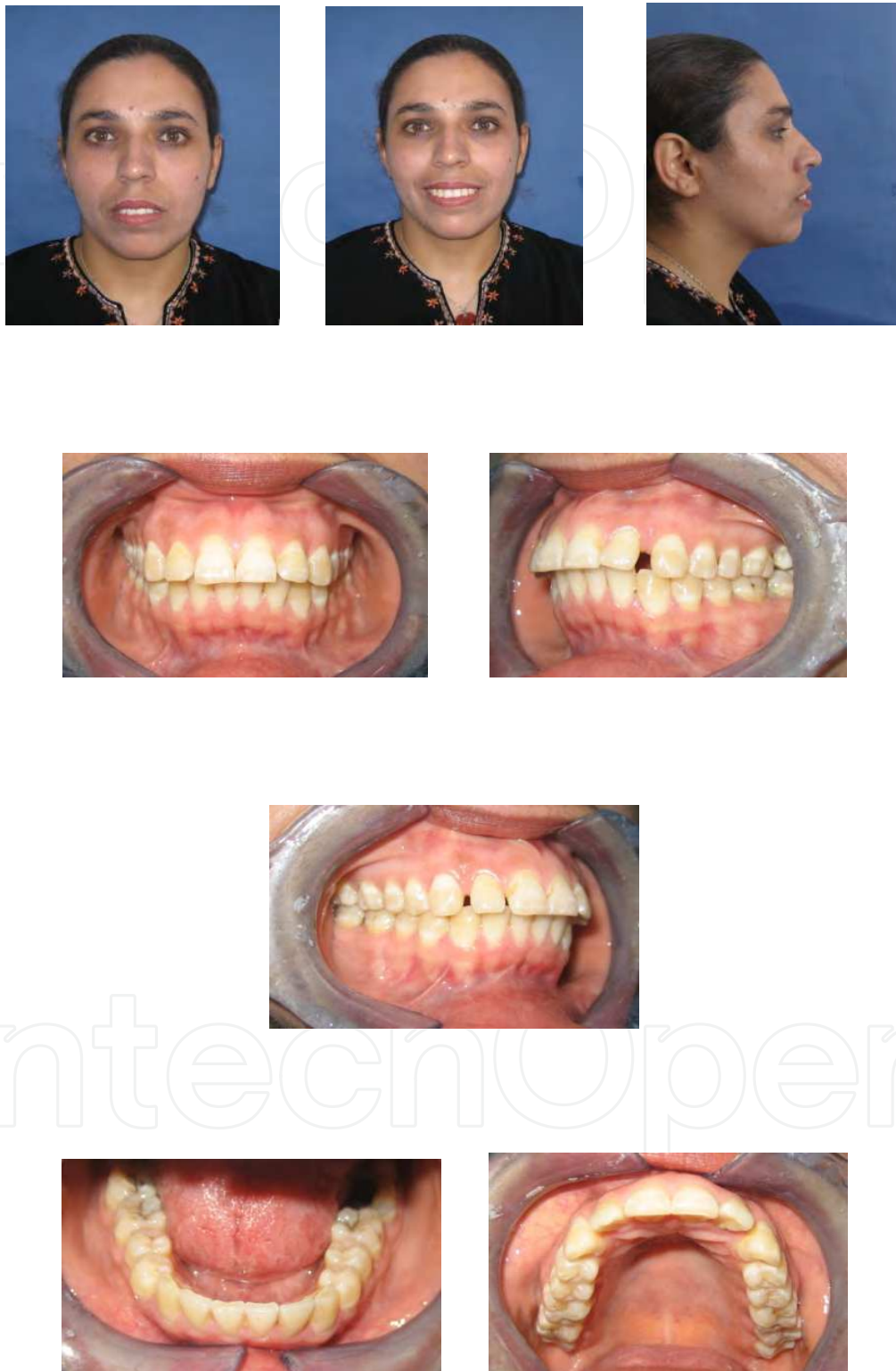

Fig. 18. Figs 18-a to 18-h, Pretreatment facial and intraoral photographs of the patient R.T.

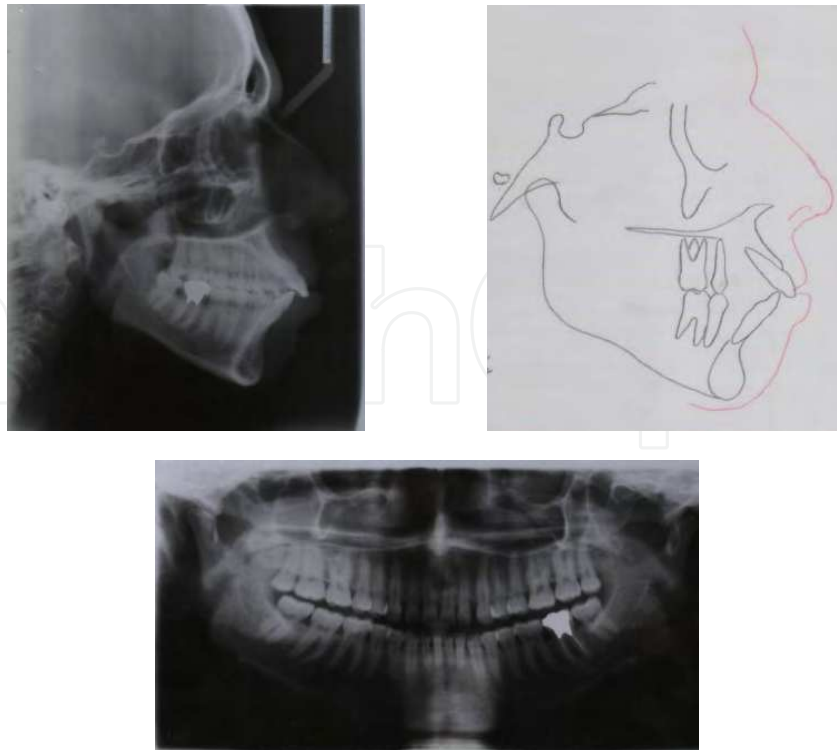


Fig. 19. Figs 19-a to 19-c, pretreatment cephalogram, cephalometric tracing and panoramic radiographic.

The best treatment approach in bimaxillary dentoalveolar protrusion is extraction of four first premolars. However, since the patient is suffering from excessive upper incisor display upon rest, extraction of premolars and retraction of anterior teeth would only exacerbate the gummy smile. In this case, the best treatment approach would probably be orthognathic surgery. The patient, however, was reluctant to undertake any type of surgery due to financial issues. The treatment alternative was to intrude the teeth and reduce the excessive gingival display with the use of mini-implants.

Two mini-implants of 1.6 in diameter and 8.0 in length were placed between the roots of maxillary lateral incisors and canines. 0.018-in slot standard edgewise brackets were bonded on the patients teeth. The four first premolars were extracted. Anchorage preparation was extremely important in this case and therefore, maxillary and mandibular second molars were added to the anchorage unit. Anterior teeth retraction was carried out in two separate stages. Initially, maxillary and mandibular canines were retracted using pull coil spring and then T-loop on 0.016×0.022-in stainless steel was used to retract the incisors during the second phase of anterior teeth retraction. Elastic chain was applied to the upper anterior teeth from miniscrews to intrude them during retraction. 0.016-in and 0.016×0.022-in stainless steel wires were inserted after space closure as ideal arch wires. Interdigitation of the teeth was achieved by a short duration of interarch elastics. [22]

After 17 months, treatment is completed. Even though the bimaxillary dentoalveolar protrusion is resolved, excessive tooth display was also corrected. Fixed retainers were bonded from the left to the right second premolars in both maxilla and mandible (figure 20-a to 20-f). cephalometric tracing revealed significant improvement in the inclination of the

maxillary and mandibular incisors (upper incisors to SN angle; pretreatment: 126° and post treatment: 91° , IMPA; pretreatment: 105° and post treatment 94° , Figures 21-a to 21-e).

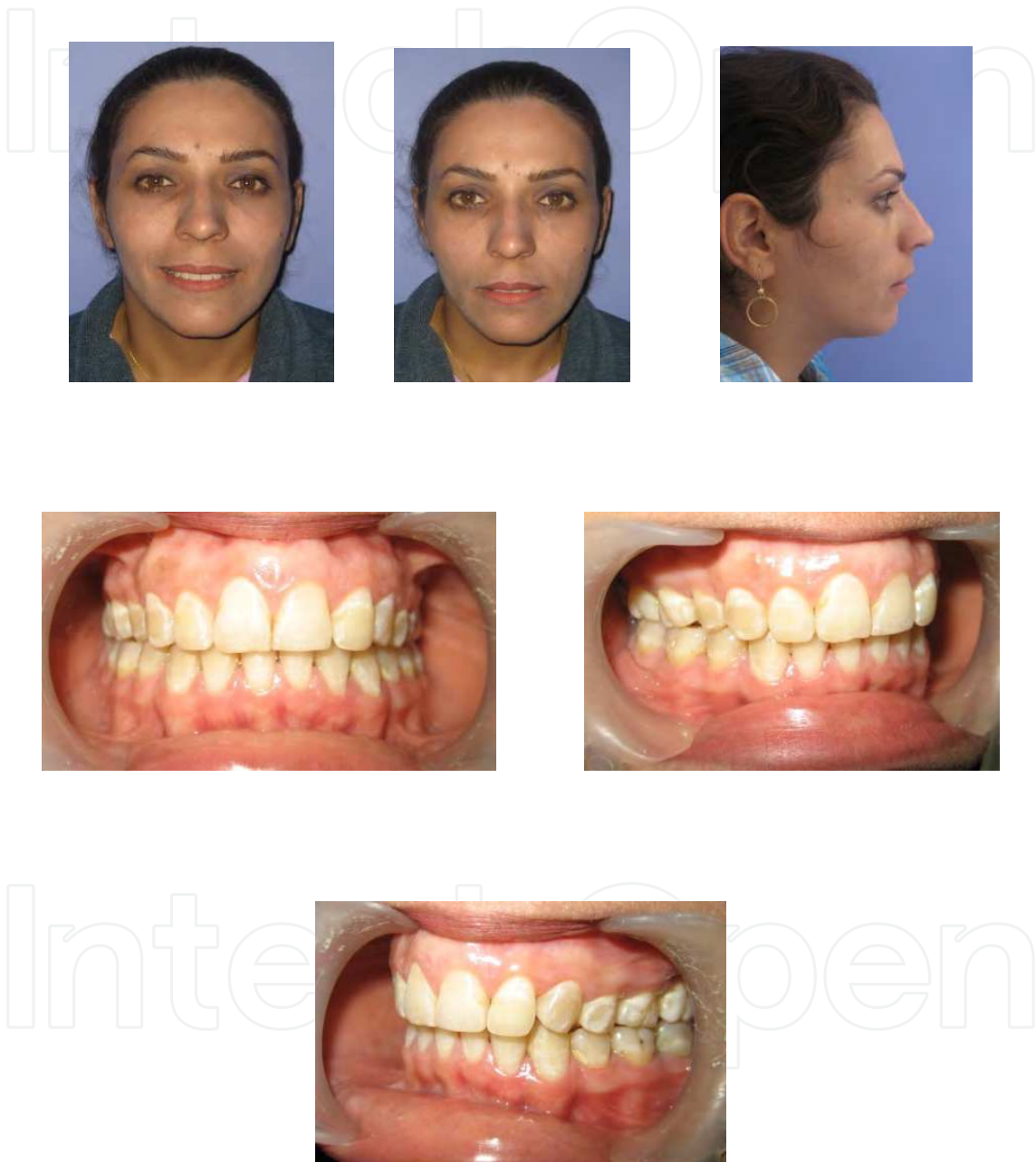

Fig. 20. Figs 20-a to 20-f, post treatment facial and intraoral photographs, notice the marked improvement in the patient's profile. Lip incompetence is resolved with no increase in upper incisor display upon rest or posed smile.

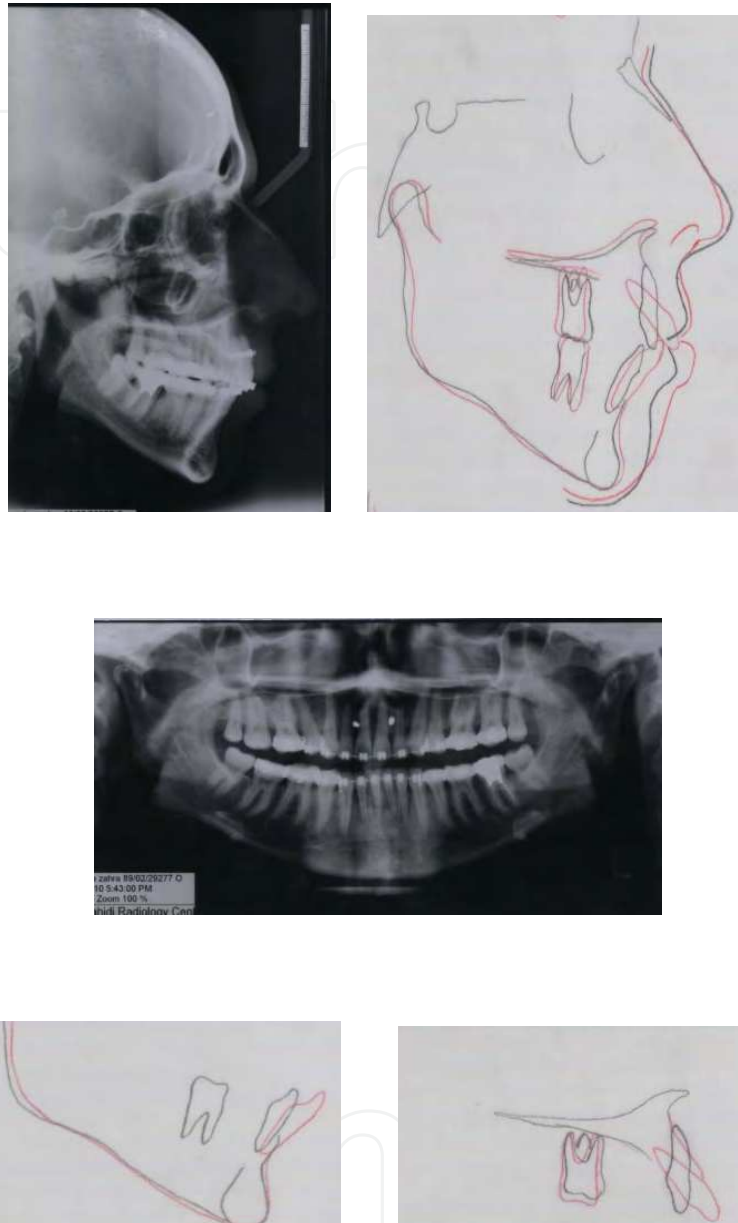


Fig. 21. Figs 21-a to 21-e, post treatment cephalogram, superimposition of pretreatment (red) and post treatment cephalometric tracings and panoramic radiograph. Notice the miniscrews in the upper arch that are not explanted yet.

3. Conclusion

The introduction of mini-implants has improved the practice of orthodontics. Treatment approaches have become available that can be an alternative to orthognathic surgery and

provide acceptable results. Duration of treatment becomes shorter significantly and simpler. The envelope of tooth movement has increased to an extent that more versatile movements in three planes of space can be carried out with more success.


4. References

- [1] Proffit, W.R. and J.L. Ackerman, *Orthodontic diagnosis: the development of a problem list*. 2nd ed. Contemporary orthodontics, ed. W.R. Proffit and H.W. Fields. 1993, St Louis: Mosby.
- [2] Kinzinger, G., et al., *Innovative anchorage alternatives for molar distalization- An overview*. J Orofac Orthop, 2005. 66: p. 397-413.
- [3] Gedrange, T., K. Boening, and W. Harzer, *Orthodontic implants as anchorage appliances for unilateral mesialization: a case report*. Quintessence International, 2006. 37: p. 485-91.
- [4] Lee, J.S., et al., *Application of orthodontic mini-implants*, ed. L.C. Bywaters. 2007, Hanover park, IL: Quintessence.
- [5] Mizrahi, E. and B. Mizrahi, *Mini-screw implants (temporary anchorage devices) : orthodontic and pre-orthodontic applications*. Journal of Orthodontics, 2007. 34: p. 80-94.
- [6] Linkow, L.I., *Implant orthodontics*. J Clin Orthod, 1970. 4: p. 685-690.
- [7] Creekmore, T.D. and M.K. Eklund, *The possibility of skeletal anchorage*. J Clin Orthod, 1983. 17: p. 266-269.
- [8] Kanomi, R., *Mini-implants for orthodontic anchorage*. J Clin Orthod, 1997. 31: p. 763-67.
- [9] Gelgor, I.E., et al., *Intraosseous screw-supported upper molar distalization*. Angle Orthod, 2004. 74: p. 838-850.
- [10] Nanda, R.S. and F.A. Uribe, *Temporary anchorage devices in orthodontics*. Biological response to orthodontic temporary anchorage devices, ed. J.J. DOlan. 2009, St. Louis, Missouri: Mosby.
- [11] Branemark, P.I., *Osseointegration and its experimental background*. Journal of Prosthetic Dentistry, 1983. 50(3): p. 399-410.
- [12] Albrektsson, T. and M. Jacobsson, *Bone-metal interface in osseointegration*. Journal of Prosthetic Dentistry, 1987. 57(5): p. 597-607.
- [13] Cooper, L.F., *Biologic determinants of bone formation for osseointegration: clues for future clinical improvements*. Journal of Prosthetic Dentistry, 1998. 80(4): p. 439-49.
- [14] Crismani, A.G., et al., *Miniscrews in orthodontic treatment: review and analysis of published clinical trials*. Am J Orthod Dentofacial Orthop, 2010. 137(1): p. 108-13.
- [15] Chen, F., et al., *Anchorage effect of osseointegrated vs nonosseointegrated palatal implants*. Angle Orthod, 2006. 76(4): p. 660-5.
- [16] Papadopoulos, M.A. and F. Tarawneh, *The use of miniscrew implants for temporary skeletal anchorage in orthodontics: a comprehensive review*. Oral Surgery, Oral Medicine, Oral Pathology, Oral Radiology and Endodontics, 2007. 103(5): p. e6-15.
- [17] Nanda, R., *Correction of deep overbite in adults*. Dent Clin North Am, 1997. 41(1): p. 67-87.
- [18] Burstone, C.R., *Deep overbite correction by intrusion*. Am J Orthod, 1977. 72(1): p. 1-22.
- [19] Shroff, B., et al., *Simultaneous intrusion and retraction using a three-piece base arch*. Angle Orthod, 1997. 67(6): p. 455-61; discussion 462.
- [20] Nanda, R., R. Marzban, and A. Kuhlberg, *The Connecticut Intrusion Arch*. J Clin Orthod, 1998. 32(12): p. 708-15.

- [21] Levin, R.I., *Deep bite treatment in relation to mandibular growth rotation*. Eur J Orthod, 1991. 13(2): p. 86-94.
- [22] Burstone, C.J., *The segmented arch approach to space closure*. Am J Orthod, 1982. 82(5): p. 361-78.

IntechOpen

IntechOpen



Orthodontics - Basic Aspects and Clinical Considerations

Edited by Prof. Farid Bourzgui

ISBN 978-953-51-0143-7

Hard cover, 446 pages

Publisher InTech

Published online 09, March, 2012

Published in print edition March, 2012

The book reflects the ideas of nineteen academic and research experts from different countries. The different sections of this book deal with epidemiological and preventive concepts, a demystification of cranio-mandibular dysfunction, clinical considerations and risk assessment of orthodontic treatment. It provides an overview of the state-of-the-art, outlines the experts' knowledge and their efforts to provide readers with quality content explaining new directions and emerging trends in Orthodontics. The book should be of great value to both orthodontic practitioners and to students in orthodontics, who will find learning resources in connection with their fields of study. This will help them acquire valid knowledge and excellent clinical skills.

How to reference

In order to correctly reference this scholarly work, feel free to copy and paste the following:

P. Salehi, S. Torkan and S.M.M. Roeinpeikar (2012). The Use of Mini-Implants (Temporary Anchorage Devices) in Resolving Orthodontic Problems, *Orthodontics - Basic Aspects and Clinical Considerations*, Prof. Farid Bourzgui (Ed.), ISBN: 978-953-51-0143-7, InTech, Available from:
<http://www.intechopen.com/books/orthodontics-basic-aspects-and-clinical-considerations/the-use-of-mini-implants-temporary-anchorage-devices-in-resolving-orthodontic-problems-a-case-serie>

INTeCH
open science | open minds

InTech Europe

University Campus STeP Ri
Slavka Krautzeka 83/A
51000 Rijeka, Croatia
Phone: +385 (51) 770 447
Fax: +385 (51) 686 166
www.intechopen.com

InTech China

Unit 405, Office Block, Hotel Equatorial Shanghai
No.65, Yan An Road (West), Shanghai, 200040, China
中国上海市延安西路65号上海国际贵都大饭店办公楼405单元
Phone: +86-21-62489820
Fax: +86-21-62489821

© 2012 The Author(s). Licensee IntechOpen. This is an open access article distributed under the terms of the [Creative Commons Attribution 3.0 License](https://creativecommons.org/licenses/by/3.0/), which permits unrestricted use, distribution, and reproduction in any medium, provided the original work is properly cited.

IntechOpen

IntechOpen