14

Management of Primary Hyperparathyroidism

Jessica Rose and Marlon A. Guerrero
Department of Surgery, University of Arizona, Tucson, Arizona USA

1. Introduction

Primary hyperparathyroidism (PHPT) is caused by overproduction of parathyroid hormone (PTH) by at least 1 autonomously functioning parathyroid gland. Such overproduction results in increased blood calcium levels because of increased renal absorption, increased vitamin D synthesis (and calcium absorption in the gastrointestinal tract), and increased bone resorption. (Felger, Johnson) PHPT is caused by a single parathyroid adenoma 80% to 85% of the time. (Pyrah) Less frequently, it is caused by multiple adenomas or multigland hyperplasia (MGH). Intraoperatively, MGH may be difficult to differentiate from an adenoma, because hyperplasia may occasionally be asymmetric. (Kaplan) PHPT is generally a benign disease, but parathyroid carcinoma accounts for 0.5% of cases. The majority of PHPT cases are sporadic, but PHPT may also be associated with familial syndromes, including familial PHPT and multiple endocrine neoplasia type I and IIA. (Johnson)

2. Embryology

Most normal parathyroid glands (parathyroids for short) weigh between 35 and 50 mg, are under 5 mm in diameter, and are yellowish-brown. (Pyrah, Johnson) The upper parathyroids develop embryologically from the fourth branchial pouches. They descend with the thyroid into the neck and tend to have a fairly consistent location in the posterior portion of the middle third of the thyroid, just above the intersection of the inferior thyroid artery and recurrent laryngeal nerve. (Pyrah) Ectopic superior parathyroids may be found in the tracheoesophageal groove; in the retropharyngeal or retroesophageal space; posterior mediastinum; in the carotid sheath; or within the thyroid itself (intrathyroidal). (Johnson) Inferior parathyroids derive from the third branchial pouch, descend with the thymus, and are typically found on the posterior portion of the lower pole of the thyroid. However, *ectopic* inferior parathyroids may be submandibular, intrathymic, or intrathyroidal, or may be found in the thyrothymic ligament or anterior mediastinum. (Pyrah) Supernumerary parathyroids are found in 13% of cases; fewer than 4 of them are found in about 3% of cases. (Johnson)

3. Diagnosis

PHPT commonly affects individuals between the ages of 30 and 60 years—and women by a 3-to-1 ratio. (Kaplan) In outpatients, it is the most frequent cause of hypercalcemia. It is typically identified as hypercalcemia on routine laboratory evaluation in a seemingly asymptomatic individual. Symptoms may include weakness, easy fatigability, muscle aches, weight loss,

irritability, depression, constipation, epigastric pain, nausea, vomiting, polyuria, renal colic, arthralgias, bony aches, pruritus, and paresthesias. Less common are the supposedly classic symptoms known by this rhyming mnemonic: stones, bones, groans, and psychic overtones (for renal calculi, osteoporosis, abdominal pain, and neuropsychiatric symptoms). If left untreated, patients with PHPT are at risk for hypertension, peptic ulcers, pancreatitis, nephrolithiasis, gout, and pathologic fractures. Patients typically present in one of three groups: those with osteitis fibrosa, those with nephrolithiasis, and those who are asymptomatic and whose disease is incidentally found. Those with osteitis fibrosa tend to have more symptoms and higher concentrations of PTH. (Mallette)

Most cases of PHPT are diagnosed incidentally, when hypercalcemia is identified on routine blood work. Hypercalcemia with an elevated PTH level confirms the diagnosis of PHPT. Some patients have a PTH level within the normal range, but the level is inappropriately high relative to the serum calcium level. (Mallette) In patients with symptoms suggestive of PHPT, the serum calcium level (corrected for albumin) should be checked and compared with the specific laboratory reference range. (Chan, Kaplan, Glendenning) The ionized calcium level may also be obtained, because that level is not affected by binding globulins, transfusions, venous stasis, or gadolinium. (Glendenning)

If the serum or ionized calcium level is elevated, other causes must be considered, such as milk-alkali syndrome, malignancy, sarcoidosis, hyperthyroidism, hypervitaminosis D, and many primary bone disorders. (Keating) In addition, the PTH level (via second- or third-generation assays) should be measured. (Chan AK, Bilezikian) In young patients and in patients of any age who have family members with hypercalcemia, the urinary calcium level should also be obtained, in order to evaluate for familial hypocalciuric hypercalcemia (FHH). (Kaplan) A Ca/Cr ratio of less than 0.01 is diagnostic of FHH; a ratio of more than 0.02 confirms PHPT. (Glendenning) Other laboratory abnormalities associated with PHPT include hypophosphatemia, hyperchloremic acidosis, hypomagnesemia, elevated alkaline phosphatase levels, and increased urinary calcium excretion. Moreover, 25-hydroxy vitamin D levels should be checked, in order to identify coexisting vitamin D deficiency. (Mallette)

Classic symptoms	Associated symptoms	Associated conditions
Renal calculi Osteoporosis Abdominal pain Neuropsychiatric symptoms	Weakness Easy fatigability Muscle aches Weight loss Irritability Depression Constipation Epigastric pain Nausea Vomiting Polyuria Renal colic Arthralgias Bony aches Pruritus Paresthesias	Hypertension Peptic ulcers Pancreatitis Nephrolithiasis Gout Pathologic fractures Osteitis fibrosa

Table 1. Symptoms of PHPT

4. Surgical indications

An operation can be helpful in patients with PHPT in order to restore their calcium balance and euparathyroid state. Postoperatively, most symptoms resolve, especially osteitis fibrosa. (Kaplan)

Preoperatively, all patients should begin, or continue, treatment for any concomitant diseases, such as angina, hypertension, and diabetes. They should be adequately hydrated, especially if they have significant hypercalcemia. In addition, their calcium level and renal function should be evaluated. It is also a good idea to assess bone mineral density, which gives an idea of the chronicity of a given patient's PHPT and the potential need for antiresorptive therapy postoperatively. (Davies)

4.1 Symptomatic PHPT

In patients with confirmed PHPT who can tolerate surgery, symptoms are one of the main indications. (Kaplan, Bilezikian) Those with renal involvement benefit from a parathyroidectomy, in order to reduce the risk of nephrolithiasis and to help improve renal function. Those with pancreatitis should be offered a parathyroidectomy; without one, the risk of disease recurrence and of significant complications is significant. Those with osteitis fibrosa and osteoporosis also benefit from a parathyroidectomy, which improves cortical and trabecular bone symptoms, though not always bone mineral density. A parathyroidectomy also decreases the risk of a pathologic fracture and lessens muscle weakness and fatigue. In addition, it helps avoid a hypercalcemic crisis. (Davies)

Reviewing the records of their own patients and other studies, Kaplan et al. found that 100% of patients with osteitis and pancreatitis saw improvement after a parathyroidectomy. And about 90% of patients with nephrolithiasis saw improvement, although renal function improved only variably (in 0% to 43% of patients). Other symptoms of PHPT also improved only variably, specifically peptic ulcers, hypertension, neuropsychiatric symptoms, and constipation. (Kaplan)

Renal involvement
Pancreatitis
Osteitis fibrosa
Osteoporosis
Bone Fracture
Muscle weakness
Fatigue
Hypercalcemic crisis

Table 2. Indications for surgery: *symptomatic* PHPT

4.2 Asymptomatic PHPT

In most asymptomatic patients, if they are not treated surgically, PHPT will eventually progress; in many of them, bone mineral density (BMD) will decrease. Such patients are also potentially at risk for cardiovascular and neurocognitive problems, and they have lower quality of life scores and more psychological symptoms. (Bilezikian)

Asymptomatic PHPT should be treated surgically if the patient meets the criteria set by the Task Force on Primary Hyperparathyroidism of the American Association of Clinical Endocrinologists and the American Association of Endocrine Surgeons (AACE/AAES). The criteria are as follows: patient age under 50 years, serum calcium level more than 1 mg/dL above the upper limit of normal, creatinine clearance less than 30% below age-matched norms, decreased BMD (T or Z score under -2.5), and difficulty with medical follow-up. (Felger, Bilezikian, Kukora)

In the past, hypercalciuria (excretion of more than 400 mg/day of calcium) was an indication for surgery--even in the absence of renal stones; it is no longer an indication, according to a summary statement from the Third International Workshop on Asymptomatic PHPT. (Bilezikian)

Most asymptomatic patients have improved symptoms postoperatively. (Felger) The reason is probably that many patients with hyperparathyroidism suffer preoperatively from weakness, easy fatigability, depression, neurocognitive dysfunction, and increased sleep requirements; still, it is impossible to predict which patients will benefit from surgery. (Bilezikian) Surgeons adhering to the National Institutes of Health (NIH) surgical indications criteria have noticed a cure rate of 95% to 98%, with a risk of complications of only 1% to 2%. (Sosa, Kukora) Some groups feel that the criteria for a parathyroidectomy are too limited, and that more patients would benefit from it. (Sywak)

Patient age < 50 years
Serum calcium level > 1 mg/dL above the upper limit of normal
Creatinine clearance < 30% below age-matched norms
Decreased BMD (T or Z score under -2.5)
Difficulty with medical follow-up

Table 3. Indications for surgery: *asymptomatic* PHPT

5. Preoperative imaging

The choice of preoperative imaging for patients with PHPT is often controversial. Without imaging, in the hands of an experienced surgeon, a patient undergoing a bilateral neck exploration for PHPT typically has a cure rate of 95% to 98%. (Shaha) But given the ability to perform minimally invasive surgery, preoperative imaging is gaining importance. (Shaha, Johnson) Such imaging can lead to the discovery of ectopic parathyroids and other pathology (such as other cervical masses). (Lumachi)

Imaging is most valuable for patients who require a reoperation for persistent or recurrent PHPT. Other populations who particularly benefit from preoperative localization via imaging include asymptomatic patients who previously underwent related neck surgery (such as a thyroidectomy or neck dissection); patients with difficult anatomic issues (such as those who are obese with a short neck); and patients at high operative risk. (Shaha)

Currently, sestamibi and ultrasound studies are the most common preoperative imaging modalities, but other imaging modalities are being more readily utilized.

5.1 Sestamibi scans

A sestamibi scan is a scintigraphic study; sestamibi was first noted to be taken up by the parathyroids when the study was used to evaluate cardiac perfusion. Since then, it has been thought to be a valuable tool for preoperative evaluation of the parathyroids. It uses technetium-99m hexakis-methoxyisobutyl isonitrile as the radionucleotide. The technetium is taken up by both the thyroid and parathyroids, so iodine (I^{123}) is used for thyroid subtraction. Initially, the study was performed with thallium technetium; however, sestamibi has a higher affinity for abnormal parathyroids. A sestamibi scan result is deemed positive if it pinpoints a "hot focus" on the initial and/or the delayed image of the parathyroids (but not on the thyroid scan). (Shaha)

One group noted that the accuracy of the sestamibi scan is 80% and the positive predictive value is 89%. (Shaha) Its sensitivity for identifying solitary adenomas ranges from 68% to 95%. (Johnson) However, it is able to identify only 30% of patients with double adenomas. As a single modality, it has a higher sensitivity than other imaging modalities for identifying solitary adenomas. However, false-positives may be due to thyroid nodules, lymph nodes, and brown adipose. (Mihai)

Using the sestamibi scan to preoperatively locate abnormal parathyroids is thought to improve the cure rate of PHPT, decrease operative time, and allow the possibility of a minimally invasive parathyroidectomy; however, such speculation is not always supported in the literature. Patients with negative sestamibi scan results are more likely to have lower operative cure rates (92%) than those whose scans showed a distinct adenoma (99%). (Allendorf) The scan result is more likely to be positive for adenomas in the face of higher calcium and PTH levels, higher oxyphil concentration, and vitamin D deficiency. Patients who are taking a calcium channel blocker are more likely to have a negative sestamibi scan result. Radiotracer retention is necessary in order for the sestamibi scan result to be positive; therefore, patients with high levels of P-glycoprotein (a multidrug resistance protein) are likely to have a negative result. (Mihai)

Pros	Cons
Highest sensitivity as single modality Positive results suggestive of higher cure Visualization of one focus allows facilitates minimally invasive parathyroidectomy	False-positives due to thyroid nodules, lymph nodes, and brown adipose False-negatives in patients on calcium channel blockers, high P-glycoprotein, and drug resistance genes

Table 4. Pros and Cons of Sestamibi Scans

5.2 Ultrasound (US) scans

An US study performed with a high-frequency transducer is used to comprehensively evaluate the neck from the hyoid bone to the thoracic inlet. The thyroid is imaged as well, looking for nodules or intrathyroidal parathyroids. Doppler is added to image the vascular structures and to visualize vessels supplying adenomas. In obese patients, graded compression can be used to assist in visualization. (Johnson)

US has a sensitivity for finding solitary adenomas of 72% to 89%. On US, adenomas appear homogenous and hypoechoic. They are most frequently seen if they are at least 10 mm.

Sometimes the blood supply of the adenoma can be visualized with Doppler: frequently a rim of vascularity at the periphery of the gland is seen. Normal parathyroids are small (about 5 mm) and are rarely seen on ultrasound. It can be difficult to diagnose hyperplasia with US, since the parathyroids are not markedly enlarged. Retrotracheal and mediastinal ectopic parathyroids are not well visualized on US. (Johnson)

Another difficulty is differentiating cervical lymph nodes from parathyroids; the two can be mistaken for each other. Nodes typically have a fatty hilum and are supplied by small hilar vessels. Thyroid nodules, especially those posteriorly located, can also be difficult to differentiate from parathyroids. Thyroid nodules do not typically display a vascular pattern. Intrathyroid parathyroids are also difficult to discern from thyroid nodules. (Johnson) Diagnostic fine-needle aspiration of thyroid nodules helps differentiate parathyroids from other cervical nodules. (Dimashkieh)

Individually, sestamibi and US studies have limited accuracy, but the use of both imaging modalities increases the ability to successfully identify a single adenoma: the reported combined sensitivity is 95%. (Lumachi, 2000) When the results of both the sestamibi and US studies are concordant, the accuracy for identifying a single adenoma can be as high as 98%. (Haciyanli)

Pros	Cons
Anatomic study Identifies concomitant thyroid disease Intraoperative use	Difficulty visualizing normal glands Mistaking of thyroid nodules and lymph nodes for adenomas Difficulty in identifying multigland disease

Table 5. Pros and Cons of US Scans

5.3 Computed tomography (CT)

CT of the neck and mediastinum is very good for recognizing enlarged glands, with sensitivity from 76% to 83%. Despite its accuracy, CT is infrequently used because of the associated radiation exposure and the need to give intravenous (IV) contrast. However, it can help predict four-gland hyperplasia (necessitating bilateral neck exploration) more frequently than other imaging modalities. It has also been shown to pick up some parathyroid adenomas previously missed on ultrasound scans. (Lumachi, 2004)

CT is efficacious when combined with sestamibi scans: their combined sensitivity nears 100%. (Lumachi, 2004)

SPECT/CT is an emerging technology that allows better definition of scintigraphic images; its sensitivity for defining parathyroid lesions preoperatively is close to 88%. (Neumann) (SPECT stands for single-photon- emission CT.) It is most beneficial when patients have had a prior operation and when anatomic details matched with functional information from sestamibi scans are required. It is also very useful for identifying ectopic parathyroids. (Krauz)

A new method, called 4D-CT, uses CT anatomic images combined with functional images. Its purported sensitivity is 88%, higher than the individual sensitivities of sestamibi and US scans. 4D-CT is very beneficial for identifying multigland disease. (Mihai)

5.4 Positron emission tomography (PET)

A newer form of PET called [18F]-2-fluorodeoxyglucose (FDG)-PET can be helpful with parathyroid imaging. FDG-PET uses a methionine-labeled radiotracer that has good specificity for hyperfunctioning parathyroid tissue. It is helpful in patients who have had a negative result on localization imaging studies or who need a reoperation. Its sensitivity is 86%, but increases to 92% when coupled with CT. (Mihai)

5.5 Magnetic resonance imaging (MRI)

MRI can be used in a similar manner to CT to diagnose the cause of PHPT. (Johnson) It has not been used frequently or studied extensively in patients with PHPT, but its sensitivity ranges from 71% to 100%. MRI may be especially useful if paired with a sestamibi scan or with a methoxyisobutylisonitrile (MIBI) scan for enhanced accuracy, though no protocols have yet been developed for such combinations. (Mihai)

Image Modality	Sensitivity
Sestamibi	68-95%
US	72-89%
CT	76-83%
PET	86%
MRI	70-100%
Combined Sestamibi and US	95%
Combined CT and Sestamibi	100%
Combined PET and CT	92%

Table 6. Sensitivities of Imaging Modalities

6. Adjuncts in parathyroid surgery

As minimally invasive procedures become more popular, the need becomes greater to provide minimally invasive parathyroidectomies. With a minimally invasive parathyroidectomy, as previously mentioned, preoperative imaging is necessary in order to determine which gland needs to be removed. Additionally, intraoperative adjuncts (described below) are frequently used in order to decrease operative time and increase operative success.

6.1 Intraoperative PTH monitoring

Intraoperative PTH (IOPTH) monitoring was developed to help guide the extent of surgical exploration and parathyroid resection. The most common reason for a failed initial operation is missed multigland disease. (Irvin, 1994) IOPTH monitoring is based on the assumption that removing the hyperfunctioning gland will cause the PTH level to fall appropriately. (Vignali) The half-life of PTH ranges from 3 to 4 minutes and can be measured easily with a quick immunoradiometric assay or with a two-site antibody immunochemiluminometric assay. (Irvin, 1994)

The Miami group was the first to describe IOPTH monitoring in conjunction with a minimally invasive parathyroidectomy. The PTH is measured twice before the parathyroid is resected (preincision and preexcision). The higher value of the two is used. Once the parathyroid is removed, the PTH is measured again at 5 and 10 minutes. PTH levels are drawn either from a peripheral vein or from an internal jugular vein. Additional intervals are also measured if deemed necessary by the operating surgeon. (Boggs) A successful resection is defined as a ≥ 50% drop in PTH from baseline at 10 minutes after parathyroid removal. (Boggs, Vignali, Irvin, 1994) A fall in PTH < 50% indicates inadequate resection and necessitates further exploration. (Boggs) The success of minimally invasive parathyroidectomies and IOPTH monitoring is now reported as 98%, a rate equivalent to the standard bilateral neck exploration. (Vignali) However, IOPTH also results in a false-positive rate of 3% to 24% (the rate is lower with adenomas and higher with multigland disease), leading to failed operations. (Yang)

IOPTH monitoring is an important adjunct to surgery, especially with negative or discordant results of preoperative imaging studies. (Gawande) It can guide the operation and minimize unnecessary bilateral neck dissections. It is also beneficial in reoperative parathyroidectomies, when it is necessary to find the source of disease. Higher success rates (from 76% to 94%) have been noted for reoperative parathyroidectomies that incorporate IOPTH monitoring. (Irvin, 1999)

6.2 Gamma probes

Minimally invasive radio-guided surgery is now performed for patients with PHPT. The technique involves preoperative IV injection of 37MBq of MIBI). (Rubello) Then the 11-mm gamma probe is used to scan the patient's neck, near the site of the presumed adenoma, in order to obtain a preoperative background gamma count. After the surgical field is exposed, the radioactivity of the parathyroid adenoma, thyroid, and surrounding area are all re-measured. An adenoma is defined as an ex-vivo parathyroid with at least 20% of the background radioactivity. The empty parathyroid bed is also checked for radioactivity, and any remaining tissue should only have up to 3% of the radioactivity of the adenoma. (Rubello, Howe) Some clinicians opt to perform *intraoperative* PTH measurements as well, to enhance their accuracy. (Rubello)

One of the benefits of using the gamma probe is that it assists in localizing ectopic adenomas and those located deep in the neck. It allows re-checking not only of the operative field for radioactivity after removal of the presumed source but also of the removed tissue, in order to be certain that the hyperactive adenoma has been removed. (Rubello) Technically, the gamma probe is also helpful with a very small incision, which makes visualization of glands much more difficult than in a traditional bilateral neck exploration. It is also helpful for reoperations, because scar tissue makes finding the adenoma of interest much more difficult. (Jaskowiak) Some clinicians find that the gamma probe is also more cost-effective in that it decreases the number of frozen sections. (Jaskowiak) However, most agree that it is possible to miss multigland disease with this technique. (Rubello) About 2% to 3% of patients require conversion to a bilateral neck exploration, most frequently because intraoperative PTH levels failed to decrease. (Rubello, Jaskowiak)

6.3 Intraoperative assessment

6.3.1 Frozen section analysis

Intraoperative frozen sections for PHPT are helpful in many situations. Parathyroids can be difficult to grossly differentiate from other tissues, such as fat, thymus, thyroid, and lymph nodes. Despite advances in preoperative imaging studies, their accuracy remains limited; sampling parathyroids intraoperatively, before excision, may be necessary to look for hypercellularity. (Osamura) Frozen section analysis allows for rapid confirmation of the tissue, and especially for differentiation between parathyroid and non-parathyroid tissue. Like any other test, frozen sections have limitations. During the freezing process, the tissue can be damaged and distorted, leading to a delay in diagnosis (while awaiting final pathology results) or to an error in diagnosis. In small glands, the sample may not be large enough for an adequate diagnosis (although this is not an issue with enlarged, abnormal glands). It can be very difficult to differentiate thyroid nodules from intrathyroidal parathyroids. (Westra) With the advent of minimally invasive parathyroidectomies, frozen sections are no longer used to assess non-affected glands. (Osamura)

At some institutions, instead of frozen section analysis, scrape cytology is performed to assess the parathyroids intraoperatively. Scrape cytology requires few instruments and little equipment, which makes it a more economical test. One study reported its sensitivity to be 86%. Its main drawback is that, in very small glands, obtaining an adequate sample may be more difficult. Occasionally, the sample is misinterpreted as thyroid tissue. Still, if frozen sections are not available, scrape cytology can be very helpful. (Rohaizak)

6.3.2 Needle aspiration and PTH analysis

An alternative to frozen section analysis for intraoperative identification of parathyroids is needle aspiration with rapid PTH analysis. This method is more cost-effective than frozen section analysis because it allows for intraoperative identification without the need for pathologic evaluation. It uses the same technique as IOPTH monitoring, but requires much less tissue for diagnosis. Some groups advocate this method for intraoperative confirmation of PHPT, while others use it to confirm that the removed tissue is parathyroid tissue. Some have raised the concern that this method can damage normal parathyroids, yet no evidence of this effect exists. Needle aspiration for PTH can also be used preoperatively by percutaneously aspirating a presumed parathyroid under imaging guidance, in order to confirm that a visualized neck nodule is a parathyroid. (Chan RK)

The technique for needle aspiration involves a 25-gauge needle on a 3-cc syringe filled with 1.0 mL normal saline solution. The PTH level is determined by the dual-antibody immunoassay for intact PTH. The PTH value of the thyroid is used as a control. Aspiration of parathyroids have reportedly produced a value greater than 1600 pg/mL; the average PTH of the thyroid is 87 pg/mL. (Chan RK) Some clinicians, while advocating similar methods of obtaining tissue, have shown that more needle passes (20 instead of 10) and a larger biopsy size (1.0-mm^3) increase accuracy. The method can be performed in vivo or ex vivo. Its sensitivity for identifying parathyroid tissue is 99%, using 1,000 pg/mL as the cutoff. (Conrad)

When this method is performed preoperatively, either a CT or ultrasound scan is obtained to identify cervical masses in patients with PHPT or in patients who have recurrent PHPT

after an initial operation. Any level of PTH is considered a positive result, because no other tissue should contain PTH. Percutaneous aspiration can be performed safely with minimal associated complications. Although this method allows for accurate identification of parathyroid tissue, the false-negative rate is 13% (likely depending on the needle aspiration technique). (Sacks)

7. Operative techniques

7.1 Minimally invasive parathyroidectomy (MIP)

With technical advances in imaging and surgical adjuncts, PHPT is now commonly treated with a minimally invasive parathyroidectomy. Most clinicians agree that candidates for a minimally invasive parathyroidectomy need to have two concordant preoperative imaging studies (typically, sestamibi and ultrasound scans). The operation is usually performed with one of the aforementioned surgical adjuncts, which allow for a more focused operation, a smaller and more cosmetic incision, less operative risk, and outpatient surgery or the use of local anesthesia. Most patients have single-gland disease, so a minimally invasive approach seems preferable. (Lorenz)

7.1.1 Focused parathyroidectomy

A focused parathyroidectomy entails a targeted exploration, directed by the results of preoperative imaging, at the site of the suspected adenoma. All patients undergoing a focused parathyroidectomy were thought to possibly have single-gland disease, per preoperative imaging. The operation can be performed with IOPTH monitoring or the gamma probe. A 2-cm transverse incision is made over the site of the suspected adenoma, at the medial border of the ipsilateral sternocleidomastoid muscle. The sternocleidomastoid muscle and carotid artery are retracted laterally, and the thyroid is retracted anteromedially. If the adenoma is identified, it is circumferentially dissected. If the adenoma is not identified, the ipsilateral neck should be explored; conversion to a traditional bilateral exploration may be necessary. Although focused parathyroidectomy allows for a smaller cosmetic incision, the downside is that conversion to a bilateral neck exploration may require a second incision. (Lorenz)

7.1.2 Unilateral neck exploration

In a unilateral neck exploration, the incision is half the length of the traditional Kocher incision. The skin and subcutaneous layers are divided down through the platysma, and the subplatysmal flaps are raised. The median raphe of the strap muscles is divided; the ipsilateral strap muscles are retracted laterally; and the thyroid lobe is rotated anteromedially. Once the adenoma is identified, it is circumferentially dissected and resected. Both parathyroids on the ipsilateral side should be visualized: one normal and one abnormal gland should be visualized. However, if both those glands appear normal, or if an abnormal adenoma is not localized, the contralateral side must be explored. (Lorenz)

A unilateral exploration may be performed under local anesthesia. Frequently, this operation is coupled with intraoperative adjuncts to help guide the extent of resection. (Lorenz) Most groups report similar rates of disease recurrence after unilateral and bilateral

neck explorations. The Michigan group reported no incidence of recurrent disease after unilateral neck explorations and a follow-up of 4 years. (Lucas)

7.1.3 Endoscopic parathyroidectomy

This type of neck exploration uses multiple small incisions to insert endoscopic instruments and a camera.(Lorenz) It has several advantages. First, it is a minimally invasive method that can treat multigland disease. Second, it magnifies all of the anatomy, making a nerve injury less likely. Third, it allows exploration of the mediastinum, if needed, for ectopic glands. (Gagner) Its downsides are that the surgeon is unable to use tactile sensation and that the patient is prone to hypercarbia and subcutaneous emphysema. (Naitoh)

An endoscopic parathyroidectomy can be performed in several different ways. Gagner et al. devised a method with CO_2 insufflation. They use a 2-cm suprasternal incision for a 5-mm trocar, and then place 2 to 3 needle trocars and one more 5-mm trocar on the medial aspect of the ipsilateral sternocleidomastoid muscle. The camera goes in the 5-mm trocars; the rest are working trocars. The area is insufflated to 15 mm Hg. Endoscopic scissors and dissectors are used to dissect out the borders of the thyroid and trachea. Clips are used to ligate vessels. The specimen is retrieved through an incision of 2 to 3 cm at the maxillary angle. Single adenomas as well as multigland disease can be effectively treated with this method.

Yeung et al. place an 11-mm trocar above the suprasternal notch. The platysma is incised, and CO_2 is insufflated to 6 to 8 mm Hg. Then a 5-mm trocar is placed near the lower edge of the sternocleidomastoid muscle, 2 cm above the incision on the opposite side of the lesion. A second 5-mm trocar is placed 2 to 3 cm lateral to the midline incision. One additional trocar, if needed, is occasionally placed. Endoscopic scissors are used to create a plane between the sternocleidomastoid and the strap muscles. The carotid sheath and thyroid lobe are exposed, and the fascia of the thyroid is incised, to mobilize the thyroid anteromedially after dividing the middle thyroid vein. Any abnormal parathyroids are identified and resected, then removed through the 11-mm port.

An endoscopic video-assisted parathyroidectomy is also possible. Miccoli et al. described a procedure using only CO_2 during the initial dissection, in order to avoid hypercarbia and subcutaneous emphysema. They make a 1.5-cm incision 1 cm above the sternal notch and incise the linea alba to insert a 12-mm trocar toward the side of the adenoma. The area is insufflated to 12 mm Hg, in order to dissect the strap muscles away. Then the CO_2 is turned off, and the space is maintained with retraction. A 5-mm camera is inserted in the same incision, as are skin retractors (one lifting the thyroid up and the other retracting laterally). The thyrotracheal groove is exposed, and the 2-mm instruments are inserted through a small lateral incision. The parathyroid of interest is identified and resected.

7.1.4 DaVinci-assisted parathyroidectomy

Robot-assisted parathyroidectomy was first used to assist with removing mediastinal parathyroids. (Harvey) The daVinci system has now been used for robotic transaxillary parathyroid surgery. A daVinci-assisted parathyroidectomy and an open operation have equivalent cure and complication rates. However, the advantages of a daVinci-assisted parathyroidectomy include cosmesis (it avoids neck scars), reduced operating times, shorter hospital stays, and decreased analgesia requirement. The robotic endoscope has

magnification, enabling better visualization than traditional endoscopic procedures. Though robotic instrumentation allows more flexible motion than traditional endoscopic instruments, it is still more restricted than open surgery. Other limitations include difficulties with depth perception, less tactile feedback, and dependence on multiple assistants. (Tolley)

For a daVinci-assisted parathyroidectomy, the patient is positioned supine, with the neck extended and the shoulder bolstere. The initial incision is made below the ipsilateral clavicle to expose the sternoclavicular junction, long enough for a 12-mm trocar. Dissection continues cranially until exposure of the internal jugular vein, carotid artery, and omohyoid and sternohyoid muscles. A retractor is used to retract the strap muscles. At this point, the posterolateral border of the thyroid is exposed. The other three trocars are then inserted at the anterior axillary line. The camera is placed through the infraclavicular trocar. The daVinci instruments are placed through the axillary incisions (5-mm trocars). Then, the inferior thyroid pole, recurrent laryngeal nerve (RLN), and vascular pedicle of the parathyroid gland are exposed. A nerve stimulator may be used to continually identify the RLN. A harmonic scalpel is used to dissect the pathologic parathyroid free. Hemostasis is obtained, the trocars are removed, and the wounds are closed. (Tolley)

7.2 Conventional bilateral neck exploration

7.2.1 Surgical approach

A traditional bilateral neck exploration is performed through a transverse cervical incision (Kocher), about 2 cm above the sternal notch and just below the cricoid cartilage. The dissection is carried through the subcutaneous tissue and platysma down to the strap muscles, which are opened in the midline and retracted laterally. A self-retaining retractor is placed to assist with exposure. The strap muscles are separated from the thyroid. The right lobe of the thyroid is dissected bluntly and retracted medially, enabling the surgeon to look for the course of the recurrent laryngeal nerve. The middle thyroid vein is identified and ligated. The thyroid gland is rotated anteromedially, and the recurrent laryngeal nerve is identified near the middle thyroid artery. The superior parathyroid is found by slowly dissecting the loose tissue attaching the superior pole of the thyroid. The inferior gland is found in the same manner near the inferior thyroid artery. The procedure is repeated on the left side. All four glands are accessible through this incision and all four glands are viewed. (Johnson)

Once all four glands are identified, the extent of resection must be decided. If a single adenoma is found, it is removed. Two glands are removed if a double adenoma is visually confirmed. If all four glands are enlarged, indicating multigland hyperplasia, then a 3.5-gland resection is performed. All four glands can be biopsied to accurately distinguish single-gland from multigland disease. (Lorenz)

If the parathyroids are not found in their usual location, it is necessary to explore the common locations of ectopic glands. Ectopic *superior* glands may be found in the tracheoesophageal groove; in the retropharyngeal or retroesophageal space; posterior mediastinum; in the carotid sheath; or within the thyroid itself (intrathyroidal). (Johnson) Ectopic *inferior* parathyroids are typically on the posterior portion of the lower pole of the thyroid, but may be submandibular, intrathymic, or intrathyroidal, or may be found in the thyrothymic ligament or anterior

mediastinum. (Pyrah) At this point, if the adenoma is still not localized, an ipsilateral thyroidectomy is performed. The success rate of a bilateral neck exploration is 95% when performed by an experienced endocrine surgeon. (Low)

7.2.2 Indications

A bilateral neck exploration should be performed when the results of preoperative localizing imaging studies are equivocal or discordant. (Lumachi, 2000) It is also recommended for patients with familial PHPT; patients with multiple endocrine neoplasia syndrome type I and IIA; and patients who may have a carcinoma. In addition, it should be performed when a thyroid resection is planned concomitantly. Obese patients may be more likely to require a bilateral neck exploration, because their body habitus may preclude a minimally invasive procedure. (Grant)

7.2.3 Indications for conversion from a minimally invasive parathyroidectomy

A minimally invasive parathyroidectomy is becoming more common in patients with single-gland disease. However, in some patients, it may be necessary to convert from a minimally invasive parathyroidectomy to a bilateral neck exploration. The most common reason for conversion is failure to appropriately identify a single abnormal gland. Conversion is also recommended when surgical adjuncts fail to indicate success (for example, the operation is unsuccessful when IOPTH monitoring shows a drop of < 50% in the PTH). Note that, if a unilateral neck exploration finds two normal or two abnormal glands, it, too, should be converted to a bilateral neck exploration. (Moalem)

For Initial Surgery
Equivocal or discordant preoperative imaging results
Familial PHPT
Multiple endocrine neoplasia syndrome type I and IIA
Carcinoma
Concomitant thyroid resection
Obesity
For Conversion from Minimally Invasive Surgery
Failure to identify a single abnormal gland
Multiple abnormal glands
Failure of adjuncts to indicate success

Table 7. Indications for Bilateral Neck Exploration

8. Complications

All operations on the parathyroids have potential complications, regardless of the surgical approach. Of most concern to patients is the risk of RLN injury leading to vocal cord paralysis on the side of the injury. The risk of RLN injury is about 1% in the hands of experienced surgeons. Rarely, both RLNs may be injured, resulting in airway obstruction, stridor, and the need for a tracheostomy. The superior laryngeal nerve can also be injured, which leaves patients hoarse and unable to change the pitch of their voice. (Fewins)

Another common risk is postoperative hypocalcemia, which occurs temporarily in 5% of patients (because of bone hunger or inadequate PTH secretion from the remaining parathyroids as a result of prolonged suppression). In 1% of patients, hypocalcemia is permanent, as a consequence of inadvertent injury to the remaining parathyroid(s). (Inabnet) Hypocalcemia typically involves perioral numbness or digit tingling and paresthesias, but can progress to tetany or stridor. Treatment requires calcium, and often vitamin D, supplementation. (Fewins)

Other, more rare complications include cervical hematomas, injury to the carotid artery, dysphagia, deep vein thrombosis, wound infection, and pneumothorax. (Low, Fewins) Hematomas are usually secondary to inadequate hemostasis. (Fewins) Symptoms can include pain, dysphagia, and respiratory distress. Such patients need to emergently undergo reexploration; however, the hematoma needs to be evacuated at the bedside if the patient is in respiratory distress. (Fewins) Complications specific to endoscopic parathyroidectomies include hypercarbia and extended subcutaneous emphysema. (Lorenz)

If the patient has significant comorbidities before surgery, the risks of anesthesia can also cause complications, including aspiration pneumonia, respiratory failure, cardiac events, and even death. (Low) It is important to note that, in the hands of experienced endocrine surgeons at high-volume parathyroidectomy centers, postoperative complication rates decrease. (Stavrakis)

Common
Hypocalcemia
Injury to the recurrent or superior laryngeal nerve
Rare
Cervical hematomas
Injury to the carotid artery
Dysphagia
Deep vein thrombosis
Wound infection
Pneumothorax

Table 8. Surgical Complications

9. Summary

PHPT is a common disease that is effectively treated by surgery. The many surgical options range from a minimally invasive parathyroidectomy to a bilateral neck exploration. Regardless of the surgical approach, the likelihood of success is highest with an experienced endocrine surgeon at a high-volume center. To reduce the chance of operative failure, knowledge of the anatomy and embryology of the parathyroids is paramount.

10. Acknowledgement

We would like to acknowledge and thank Mary Knatterud for her assistance in editing this chapter.

11. References

Allendorf J, Kim L, Chabot J, DiGiorgi M, Spanknebel K, Logerfo P. The impact of Sestamibi scanning on the outcome of parathyroid surgery. J Clin Endocrinol Metab, 2003; 88: 3015-3018.

Bergenfelz A, Kannigiesser V, Zielke A, Neis C, Rothmund M. Conventional bilateral cervical exploration versus open minimally invasive parathyroidectomy under local anesthesia for primary hyperparathyroidism. BJS, 2005; 92: 190-197.

Bilezikian JP, Khan AA, Potts JT. Guidelines for the management of asymptomatic primary hyperparathyroidism: Summary statement from the third international workshop. J Clin Endocrinol Metab, 2009; 94: 335-339.

Boggs JE, Irvin GL, Molinari AS, Deriso GT. Intraoperative parathyroid hormone monitoring as an adjunct to parathyroidectomy. Surgery, 1996; 120: 954-958..

Chan AK, Duh QY, Katz, MH, Siperstein AE, Clark OH. Clinical manifestations of primary hyperparathyroidism before and after parathyroidectomy: A case-control study. Ann. Surg., 1995; 222: 402-414.

Chan RK, Ibrahim SI, Pil P, Tanasijevic M. Validation of a method to replace frozen section during parathyroid exploration by using the rapid parathyroid hormone assay on parathyroid aspirates. Arch Surg. 2005; 140: 371-373.

Conrad DN, Olson JE, Hartwig HM, Mack E, Chen H. A prospective evaluation of novel methods to intraoperatively distinguish parathyroid tissue using a parathyroid hormone assay. Journal of Surgical Research, 2006; 133: 38-41.

Davies M, Fraser WD, Hosking DJ. Management of primary hyperparathyroidism. Clinical Endocrinology, 2002; 57: 145-155.

Dimashkieh H, Krishnamurthy S. Ultrasound guided fine needle aspiration biopsy of parathyroid glands and lesions. Cytojournal. 2006; 3: 6.

Felger EA, Kandil E. Primary hyperparathyroidism. Otolaryngol Clin N Am 43 (2010) 417–432.

Fewins J, Simpson CB, Miller FR. Complications of thyroid and parathyroid surgery. Otolaryngol Clin N Am., 2003; 36: 189-206.

Gagner M. Endoscopic subtotal parathyroidectomy in patients with primary hyperparathyroidism. Br J Surg., 1996; 83: 875.

Gawande AA, Monchik JM, Abbruzzese TA, Iannuccilli JD, Ibrahim SI, Moore FD. Reassessment of parathyroid hormone monitoring during parathyroidectomy for primary hyperparathyroidism after 2 preoperative studies. Arch Surg. 2006; 141: 381-384.

Glendenning P. Diagnosis of primary hyperparathyroidism: controversies, practical issues and the need for Australian guidelines. Intern Med J 2003; 33: 598–603.

Grant CS, Thompson G, Farley D, van Heerden J. Primary hyperparathyroidism surgical management since the introduction of minimally invasive parathyroidectomy. Arch Surg. 2005; 140: 472-479.

Haber RS, Kim CK, and Inabnet WB. Ultrasonography for preoperative localization of enlarged parathyroid glands in primary hyperparathyroidism: comparison with 99m technetium sestamibi scintigraphy. Clinical Endocrinology, 2002; 57: 241-249.

Haciyanli M, Lal G, Morita E, Duh QY, Kebebew E, Clark OH. Accuracy of preoperative localization studies and intraoperative parathyroid hormone assay in patients with

primary hyperparathyroidism and double adenoma. J Am Coll Surg. 2003; 197: 739-46.

Inabnet WB, Fulla Y, Richard B, Bonnichon P, Icard P, Chapuis Y. Unilateral neck exploration under local anesthesia: the approach of choice for asymptomatic primary hyperparathyroidism. Surgery, 1999; 126: 1004-10.

Irvin GL, Deriso GT. A new, practical intraoperative parathyroid hormone assay. Am J Surg., 1994; 168: 466-468.

Irvin GL. Molinari AS, Figuroa C, Carniero DM. Improved success rate in reoperative parathyroidectomy with intraoperative PTH assay. Ann Surg. 1999; 229: 874-879.

Jaskowiak NT, Sugg SL, Helke J, Koka MR, Kaplan EL. Pitfalls of intraoperative quick parathyroid hormone monitoring and gamma probe localization in surgery for primary hyperparathyroidism. Arch Surg. 2002; 137: 659-669.

Johnson, NA. Tublin ME, Ogilvie JB. Parathyroid imaging: Technique and role in the preoperative evaluation of primary hyperparathyroidism. AJR, 2007; 188: 1706-1715.

Kaplan EL, Yahiro T, Salti G. Primary Hyperparathyroidism in the 1990s: Choice of surgical procedures for this disease. Ann. Surg., 1992; 300-317.

Keating FR. Diagnosis of primary hyperparathyroidism: Clinical and laboratory diagnosis. JAMA, 1961; 178: 547-555.

Kern KA, Shawker TH, Doppman JL, Miller DL, Marx SJ, Spiegel AM, Aurbach GD, Norton JA. The use of high-resolution ultrasound to locate parathyroid tumors during reoperations for primary hyperparathyroidism. World J. Surg., 1987; 11: 579-585.

Krausz Y, Bettman L, Guralnik L, Yosilevsky G, Keidar Z, Bar-Shalom R, Even-Sapir E, Chisin R, Isreal O. Technetium-99m-MIBI SPECT/CT in primary hyperparathyroidism. World J Surg, 2006; 30: 76–83.

Kukora JS, Zeiger MA. The American Association of Clinical Endocrinologists and The American Association of Endocrine Surgeons position statement on the diagnosis and management of primary hyperparathyroidism: AACE/AAES task force on primary hyperparathyroidism. Endocrine Practice, 2005; 11: 49-54.

Lorenz K, Nguyen-Thanh P, Dralle H. Unilateral open and minimally invasive procedures for primary hyperparathyroidism: a review of selective approaches. Langenbeck's Arch Surg, 2000; 385:106–117.

Low RA, Katz AD. Parathyroidectomy via bilateral cervical exploration: a retrospective review of 866 cases. Head Neck, 1998; 20: 583-587.

Lucas RJ, Welsh RJ, Glocer JL. Unilateral neck exploration for primary hyperparathyroidism. Arch Surg., 1990; 125: 982-985.

Lumachi F, Zucchetta P, Marzola MC, Boccagni P, Angelini F, Bui F, D'Amico DF, Favia G. Advantages of combined techneticum-99m-sestamibi scintigraphy and high-resolution ultrasonography in parathyroid localization: comparative study in 91 patients with primary hyperparathyroidism. European Journal of Endocrinology, 2000; 143: 755-760.

Lumachi F, Tregnaghi A, Zucchetta P, Marzola MC, Cecchin D, Marchesi P, Fallo F, Bui F. Technetium-99m sestamibi scintigraphy and helical CT together in patients with primary hyperparathyroidism: a prospective clinical study. BJR, 2004; 77: 100-103.

Mallette LE, Bilezikian JP, Heath DA, Aurbach GD. Primary hyperparathyroidism: Clinical and biochemical features. Medicine, 1974; 53: 127-146.

Miccoli P, Bendinelli C, Conte C, Pinchera A, Marcocci C. Endoscopic parathyroidectomy by a gasless approach. J Laparoendosc Adv Surg Tech A., 1998; 8: 189-194.

Mihai R, Simon D, Hellman P. Imaging for primary hyperparathyroidism—an evidence-based analysis. Langenbeck's Arch Surg, 2009; 394:765–784.

Moalem J, Guerrero M, Kebebew E. Bilateral exploration in primary hyperparathyroidism—When is it selected and how is it performed? World J Surg, 2009; 33:2282–2291.

Naitoh T, Gagner M, Garcia-Ruiz A, Heniford BT. Endoscopic endocrine surgery in the neck: An initial report of endoscopic subtotal parathyroidectomy. Surg Endosc, 1998; 12: 202–205.

Neumann, DR. Obuchowski NA. DiFilippo FP. Pre-operative ^{123}I/^{99m}Tc-Sestamibi subtraction SPECT and SPECT/CT in primary hyperparathyroidism. Nucl Med 2008; 49:2012–2017.

Osamura RY, Hunt JL. Current practices in performing frozen sections for thyroid and parathyroid surgery. Virchow Arch, 2008; 453: 443-440.

Pyrah LN, Hodgkinson A, Anderson CK. Critical Review: Primary hyperparathyroidism. Brit J Surg, 1966; 53: 245-316.

Rohaizak M, Munchar MJJ, Meah FA, Jasmi AY. Prospective study comparing scrape cytology and frozen section in the intraoperative identification of parathyroid tissue. Asian J Surg, 2005; 28: 82–5.

Rubello D, Piotto A, Muzzio PC, Shapiro B, Pelizzo MR. Role of gamma probes in performing minimally invasive parathyroidectomy in patients with primary hyperparathyroidism: optimization of preoperative and intraoperative procedures. European Journal of Endocrinology, 2003; 149: 7-15.

Saaristo RA, Salmi JJO, Koobi T, Turjanmaa V, Sand JA, Nordback IH. Intraoperative localization of parathyroid glands with gamma counter probe in primary hyperparathyroidism: A prospective study. J Am Coll Surg, 2002; 195: 19–22.

Sacks BA, Pallotta JA, Cole A, Hurwitz J. Diagnosis of parathyroid adenomas: efficacy of measuring parathormone levels in needle aspirates of cervical masses. AJR, 1994; 163: 1223-1226.

Shaha AR, Sarkar S, Strashun A, Yeh S. Sestamibi scan for preoperative localization in primary hyperparathyroidism. Head Neck , 1997; 19: 87–91.

Smit PC, Rinkes IHMB, van Dalen A, van Vroonhoven TJVMV. Direct, minimally invasive adenomectomy for primary hyperparathyroidism: An alternative to conventional neck exploration? Ann. Surg., 2000; 231: 559-565.

Sosa JA, Powe NR, Levine MA, Udelsman R, Zeiger MA. Profile of a clinical practice: Thresholds for surgery and surgical outcomes for patients with primary hyperparathyroidism: A National survey of endocrine surgeons. J Clin Endocrinol Metab, 1998; 83: 2658-2665.

Stavrakis AI, Ituarte PHG, Ko CY, Yeh MW. Surgeon volume as a predictor of outcomes in inpatient and outpatient endocrine surgery. Surgery 2007; 142: 887-99.

Sywak MS, Knowlton ST, Pasieka JL, Parsons LL, Jones J. Do the National Institutes of Health consensus guidelines for parathyroidectomy predict symptom severity and

surgical outcome in patients with primary hyperparathyroidism? Surgery, 2002; 132: 1013-1020.

Vignali E, Picone A, Materazzi G, Steffe S, Berti P, Cianferotti L, Ambrogini E, Miccoli P, Pinchera A, Marcocci A. A quick intraoperative parathyroid hormone assay in the surgical management of patients with primary hyperparathyroidism: a study of 206 consecutive cases. European Journal of Endocrinology, 2002; 146: 783-788.

Westra WH, Pritchett DD, Udelsman R. Intraoperative confirmation of parathyroid tissue during Parathyroid Exploration: A Retrospective Evaluation of the Frozen Section. The American Journal of Surgical Pathology, 1998; 22: 538-544.

Yang GP, Levine S, Weigel RJ. A spike in parathyroid hormone during neck exploration may cause a false-negative intraoperative assay result. Arch Surg. 2001; 136: 945-949.

Yeung GHC, Ng JWT. The technique of endoscopic exploration for parathyroid adenoma of the neck. Aust. N.Z. J. Surg., 1998; 68: 147-150.

Zollinger RM, Zollinger RM. Parathyroidectomy. In Zollinger RM, Zollinger RM. Zollinger's Atlas of Surgical Operations. 8th ed. Colombia: McGraw-Hill; 2003.

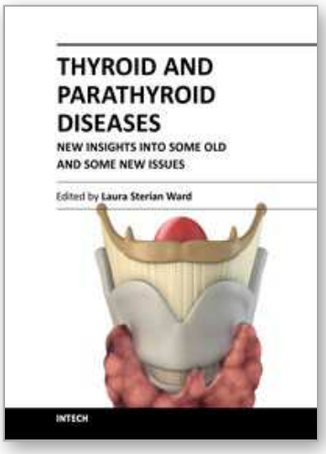

Thyroid and Parathyroid Diseases - New Insights into Some Old and Some New Issues

Edited by Dr. Laura Ward

ISBN 978-953-51-0221-2
Hard cover, 318 pages
Publisher InTech
Published online 07, March, 2012
Published in print edition March, 2012

This book was designed to meet the requirements of all who wish to acquire profound knowledge of basic, clinical, psychiatric and laboratory concepts as well as surgical techniques regarding thyroid and parathyroid glands. It was divided into three main sections: 1. Evaluating the Thyroid Gland and its Diseases includes basic and clinical information on the most novel and quivering issues in the area. 2. Psychiatric Disturbances Associated to Thyroid Diseases addresses common psychiatric disturbances commonly encountered in the clinical practice. 3. Treatment of Thyroid and Parathyroid Diseases discusses the management of thyroid and parathyroid diseases including new technologies.

How to reference

In order to correctly reference this scholarly work, feel free to copy and paste the following:

Jessica Rose and Marlon A. Guerrero (2012). Management of Primary Hyperparathyroidism, Thyroid and Parathyroid Diseases - New Insights into Some Old and Some New Issues, Dr. Laura Ward (Ed.), ISBN: 978-953-51-0221-2, InTech, Available from: http://www.intechopen.com/books/thyroid-and-parathyroid-diseases-new-insights-into-some-old-and-some-new-issues/surgical-management-of-primary-hyperparathyroidism

INTECH
open science | open minds

InTech Europe
University Campus STeP Ri
Slavka Krautzeka 83/A
51000 Rijeka, Croatia
Phone: +385 (51) 770 447
Fax: +385 (51) 686 166
www.intechopen.com

InTech China
Unit 405, Office Block, Hotel Equatorial Shanghai
No.65, Yan An Road (West), Shanghai, 200040, China
中国上海市延安西路65号上海国际贵都大饭店办公楼405单元
Phone: +86-21-62489820
Fax: +86-21-62489821