

We are IntechOpen, the world's leading publisher of Open Access books Built by scientists, for scientists

6,900

Open access books available

186,000

International authors and editors

200M

Downloads

Our authors are among the

154

Countries delivered to

TOP 1%

most cited scientists

12.2%

Contributors from top 500 universities



WEB OF SCIENCE™

Selection of our books indexed in the Book Citation Index
in Web of Science™ Core Collection (BKCI)

Interested in publishing with us?
Contact book.department@intechopen.com

Numbers displayed above are based on latest data collected.
For more information visit www.intechopen.com



Revascularization of Tibial and Foot Arteries: Below the Knee Angioplasty for Limb Salvage

Marco Manzi, Luis Mariano Palena and Giacomo Cester
*Interventional Radiology Unit -Policlinico Abano Terme, Padua
 Italy*

1. Introduction

Advanced atherosclerosis with extended tibial arteries lesions is a common concern, especially in diabetic patients having critical-limb ischemia (CLI) and skin wounds. Chronic critical limb ischemia is a major worldwide cause of morbidity and, especially when threatening the limb, mortality (Faglia E. et al. 2006). Certainly, major and minor amputations are associated with significant increases in mortality risk, and every efforts should be pursued to minimize amputations and ensure limb salvage (Norgen L. et al. 2007).

Infragenicular atherosclerotic is the most common cause of CLI, usually due to multilevel and diffuse arterial disease with compromised foot arteries run-off. Vascular disease is very often associated with arterial wall calcifications, that are usually severe and diffuse. The combination of severe peripheral arterial occlusion with the increased blood flow requirement necessary to achieve the healing of the skin wounds or surgical incisions, makes this population very challenging. Additionally, diabetics and CLI population have a high rate of comorbidities (Bargelini I, et al. 2008).

Clinical manifestations range from Intermittent claudication to limb-threatening ischemia, with rest pain, non healing ulcers and gangrene.

Despite the benefits of pharmacologic therapy (e.g. Angiotensin-converting enzyme inhibitors, antidiabetic drugs, antiplatelet agents and statins), arterial revascularization remains a mainstay in the management of CLI, with restoration of arterial blood flow to the foot, achieving a relief of rest pain and improving wound healing.

In the last decade surgical revascularization has been adopted as the elective treatment option in patients with suitable anatomical conditions, however surgical by-pass is not always feasible due to the involvement of the foot arteries by the atherosclerotic disease, or recommended because of high surgical risk or contraindications in several cases, lack of venous conduits or poor vessels run-off, that compromise surgical by-pass patency (HerstenNR, et al. 2007; Norgen L, et al. 2007; Walsh Db, et al. 1991).

In recent years, related to good technical and clinical results, endovascular treatment options growing acceptance as the primary therapeutic strategy, especially in subjects with significant risk factors for surgical by-pass. In fact, since its initial applications, endovascular recanalization of tibial vessels and foot arteries has proven to be feasible and safe. Actually it is an established treatment option for limb salvage, avoiding amputations in lot of cases and improving wound healing (Adam DJ, et al. 2005; Balmer H, et al. 2002; Dorros G, et al. 2001; Faglia E, et al. 2005, 2006; Ferraresi R, et al. 2009; Romiti M, et al. 2008; Soder HR, et al 2000; Wack C, et al. 1994).

The development of new technologies, such as dedicated guide-wire or low profile catheter balloons helps the interventionists to achieve technical and clinical results. Nevertheless, the knowledge of the most important techniques should be indispensable to obtain the procedural success and clinical outcome. In fact, the advances in distal lower extremity revascularization have revolutionized salvage of the ischemic limb.

2. Epidemiology of peripheral arterial disease

The management of the patient with peripheral arterial disease (PAD) has to be planned in the context of the epidemiology of the disease, its natural history and, in particular, the modifiable risk factors for the systemic disease as well as those that predict deterioration of the circulation to the limb (Norgen L, et al. 2007).

2.1 Incidence of peripheral arterial disease

Total disease prevalence based on objective testing has been evaluated in several epidemiologic studies and is in the range of 3-10%, increasing to 15% to 20% in persons over 70 years (Criqui MH et al. 1985; Hiatt WR, et al. 1995; Norgen et al. 2007; Selvin E, et al. 2004).

Intermittent claudication (IC) is usually diagnosed by a history of muscular leg pain on exercise that is relieved by a short rest. This symptom does not always predict the presence or absence of PAD. A patient with quite severe PAD may not have the symptom of IC because some other condition limits exercise or they are sedentary. In contrast, some patients with what seems to be IC may not have PAD. Likewise, patients with very mild PAD may develop symptoms of IC only when they become very physically active.

Black ethnicity increases the risk of PAD by over two-fold, and this risk is not explained by higher levels of other risk factors such as diabetes, hypertension or obesity (Criqui MH, et al. 2005). A high prevalence of arteritis affecting the distal arteries of young black South Africans has also been described.

3. Risk factors of peripheral arterial disease

Although the various factors described in this section are usually referred to as risk factors, in most cases the evidence is only for an association. The criteria used to support a risk factor require a prospective, controlled study showing that altering the factor alters the development or course of the PAD, such as has been shown for smoking cessation or treatment of dyslipidemia. Risk may be conferred by other metabolic or circulatory abnormalities associated with diabetes (Norgen L, et al. 2007).

3.1 Race, gender and age

The National Health and Nutrition Examination Survey in the United States found that an ABI ≤ 0.90 was more common in non-Hispanic Blacks (7.8%) than in Whites (4.4%). Such a difference in the prevalence of PAD was confirmed by the recent GENOA (Genetic Epidemiology Network of Arteriopathy) study (Kullo IJ, et al. 2003), which also showed that the difference was not explained by a difference in classical risk factors for atherosclerosis.

The prevalence of PAD, symptomatic or asymptomatic, is slightly greater in men than women, particularly in the younger age groups. In patients with IC, the ratio of men to women is between 1:1 and 2:1. This ratio increases in some studies to at least 3:1 in more

severe stages of the disease, such as chronic CLI. Other studies have, however, shown a more equal distribution of PAD between genders and even a predominance of women with CLI.

The striking increase in both the incidence and prevalence of PAD with increasing age is apparent from the earlier discussion of epidemiology (Norgen L, et al. 2007).

3.2 Smoking

The relationship between smoking and PAD has been recognized since 1911, when Erb reported that IC was three-times more common among smokers than among non-smokers. It has been suggested that the association between smoking and PAD may be even stronger than that between smoking and coronary artery disease (CAD). Furthermore, a diagnosis of PAD is made approximately a decade earlier in smokers than in non-smokers. The severity of PAD tends to increase with the number of cigarettes smoked. Heavy smokers have a four-fold higher risk of developing IC compared with non-smokers. Smoking cessation is associated with a decline in the incidence of IC (Norgen L, et al. 2007).

Results from the Edinburgh Artery Study found that the relative risk of IC was 3.7 in 7 smokers compared with 3.0 in ex-smokers (who had discontinued smoking for less than 5 years).

3.3 Diabetes mellitus

Many studies have shown an association between diabetes mellitus and the development of PAD. Overall, IC is about twice as common among diabetic patients than among non-diabetic patients. In patients with diabetes, for every 1% increase in hemoglobin A1c there is a corresponding 26% increased risk of PAD (Selvin E, et al. 2004).

Over the last decade, mounting evidence has suggested that insulin resistance plays a key role in a clustering of cardiometabolic risk factors which include hyperglycemia, dyslipidemia, hypertension and obesity. Insulin resistance is a risk factor for PAD even in subjects without diabetes, raising the risk approximately 40% to 50%. PAD in patients with diabetes is more aggressive compared to non-diabetics, with early large vessel involvement coupled with distal symmetrical neuropathy. The need for a major amputation is five- to ten-times higher in diabetics than non-diabetics. This is contributed to by sensory neuropathy and decreased resistance to infection. Based on these observations, a consensus statement from the American Diabetes Association recommends PAD screening with an ABI every 5 years in patients with diabetes (Norgen L, et al. 2007).

3.4 Hypertension

Hypertension is associated with all forms of cardiovascular disease, including PAD. However, the relative risk for developing PAD is less for hypertension than diabetes or smoking (Norgen L, et al. 2007).

3.5 Dyslipidemia

In the Framingham study, a fasting cholesterol level greater than 7 mmol/L (270 mg/dL) was associated with a doubling of the incidence of IC but the ratio of total to high-density lipoprotein (HDL) cholesterol was the best predictor of occurrence of PAD. In another study, patients with PAD had significantly higher levels of serum triglycerides, very low-density lipoprotein (VLDL) cholesterol, VLDL triglycerides, VLDL proteins, intermediate

density lipoprotein (IDL) cholesterol, and IDL triglycerides and lower levels of HDL than controls (Attinder CE, et al. 2001; Criqui MH, et al. 1985; Fowkes FG, et al. 2004; Norgen L, et al. 2007; Selvin E, et al. 2004; Senti M, et al. 1992).

Although some studies have also shown that total cholesterol is a powerful independent risk factor for PAD, others have failed to confirm this association. It has been suggested that cigarette smoking may enhance the effect of hypercholesterolemia. There is evidence that treatment of hyperlipidemia reduces both the progression of PAD and the incidence of IC. An association between PAD and hypertriglyceridemia has also been reported and has been shown to be associated with the progression and systemic complications of PAD. Lipoprotein(a) is a significant independent risk factor for PAD.

3.6 Hyperviscosity and hypercoagulable states

Raised hematocrit levels and hyperviscosity have been reported in patients with PAD, possibly as a consequence of smoking. Increased plasma levels of fibrinogen, which is also a risk factor for thrombosis, have been associated with PAD in several studies. Both hyperviscosity and hypercoagulability have also been shown to be markers or risk factors for a poor prognosis (Norgen L, et al. 2007).

3.7 Hyperhomocysteinemia

The prevalence of hyperhomocysteinemia is as high in the vascular disease population, compared with 1% in the general population. It is reported that hyperhomocysteinemia is detected in about 30% of young patients with PAD. The suggestion that hyperhomocysteinemia may be an independent risk factor for atherosclerosis has now been substantiated by several studies. It may be a stronger risk factor for PAD than for CAD (Norgen L, et al. 2007).

3.8 Chronic renal insufficiency

There is an association of renal insufficiency with PAD, with some recent evidence suggesting it may be causal. In the HERS study (Heart and Estrogen/Progestin Replacement Study), renal insufficiency was independently associated with future PAD events in postmenopausal women (O'Hare AM, et al. 2004; Norgen L, et al. 2007).

4. Vascular anatomy and angiosome concept - The first step toward pedal recanalization

Knowledge of vascular anatomy of the leg, ankle and foot, and an understanding of the dynamic nature of that vasculature are essential for limb salvage (Taylor G, et al. 1992).

The concept that divides the body into three-dimensional vascular territories supplied by specific source arteries, known as the angiosome principle, was introduced by Taylor and expanded for the clinical treatment of ischemic lesions at the foot and ankle level by Attinger (Attinger CE, et al. 2001). The foot and the ankle can be divided into six distinct angiosomes; each fed by a specific arterial branch. Recent data suggest a different clinical outcome of successful revascularization procedures based on the possibility of providing inline vascular supply to the specific angiosome of the ischemic wound.

By combining the anatomic and functional aspects of foot circulation, the angiosome theory can be useful in planning the endovascular revascularization strategy in cases of ischemic

wounds at foot and ankle level. In particular, the angiosome concept can help to select the target vessel for revascularization, that is, the artery which will yield the best local results.

4.1 Normal vascular anatomy and main variations

By definition the popliteal artery ends at the origin of the first tibial artery, which typically is the Anterior Tibial Artery. In about 4% of cases we find a so-called high origin of the Anterior tibial Artery at the level of the knee joint or even some centimetres more proximal. Similarly, in a small proportion of the population (1-2%) a high origin of the posterior tibial artery has been described. Normally, the direct continuation of the popliteal artery, after the branch of the anterior tibial artery, is the tibioperoneal trunk. This vascular segment splits into the posterior tibial artery and the peroneal artery (Fig. 1).

As a variation, a trifurcation of the popliteal artery into all three lower leg arteries at the same point has been observed in 0.4% of patients. The posterior tibial artery may be missing completely in 1-5% of a normal adult population.

The vascular anatomy of the foot is composed of the anterior and posterior circulation, connected through the pedal arches. The anterior tibial artery continues into the dorsal pedal artery. The posterior tibial artery continues into the common plantar artery and then in the lateral and medial plantar arteries. The peroneal artery splits above the ankle joint into an anterior and posterior branch, the ramus perforans that anastomoses with the dorsal pedal artery, and the ramus communicans that anastomoses with the plantar arteries. The dorsalis pedis artery and the lateral plantar artery communicate via the plantar arch (Fig. 2 and Fig. 3).

The digital branches originate from the plantar arch and there are a dorsal and plantar branches for each toe. The plantar digital branch for the first toe usually originates from the medial plantar artery.

Both tibial arteries, together with the peroneal artery, supply different portions of the foot and ankle. The plantar foot and the medial ankle are fed by the posterior tibial artery, the anterior ankle and the dorsum of the foot by the anterior tibial artery, and the antero-lateral ankle and rear foot by the peroneal artery.

As an anatomic variation of the foot dorsalis pedis artery may be absent in 6-12% of cases; in this patient the lateral tarsal artery often became predominant and developed anastomosis through the plantar arch to the plantar circulation.

In some cases the lateral plantar artery, through the plantar arch, is the predominant artery for the I toe. In a few cases has been described the absence of the plantar arch, in this situation the dorsalis pedis is the predominant artery for the I and II toe and the lateral plantar artery, is the predominant artery supplying the III, IV and V toe.

4.2 Angiosome and wound related artery concept

The angiosome principle was defined by Ian Taylor's landmark anatomic study and divides the body into individual angiosomes: three-dimensional blocks of tissue fed by "source" arteries. He defined an angiosome as a three-dimensional anatomic unit of tissue fed by a source artery and defined at least 40 angiosomes in the body, including six in the foot and ankle region. Adjacent angiosomes are bordered by choke vessels, which link neighboring angiosomes to one another and demarcate the border of each angiosome. In addition, these choke vessels are important safety conduits that allow a given angiosome to provide blood flow to an adjacent angiosome if the latter's source artery is damaged (Calligaris PR, et al. 1992; Taylor GI, et al. 1992a, 1992b).

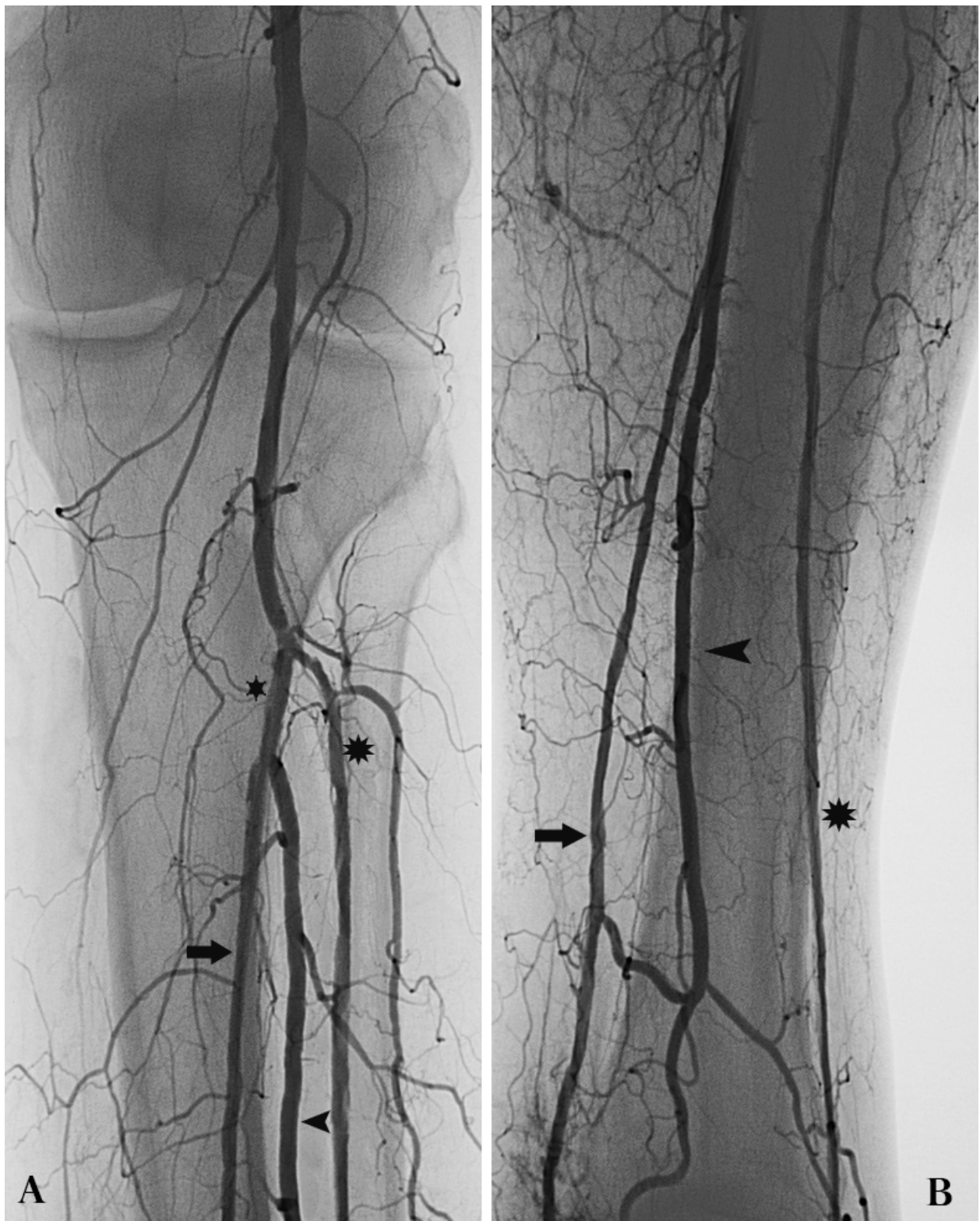


Fig. 1. A. Anteroposterior view of the tibial trifurcation show anterior tibial artery (*), tibio-peroneal trunk (*), peroneal artery (▶) and posterior tibial artery (⇒). B. Lateral view at the distal leg and ankle level show the anterior (*) and posterior (⇒)tibial arteries and the peroneal artery (▶) with the collateral branches.

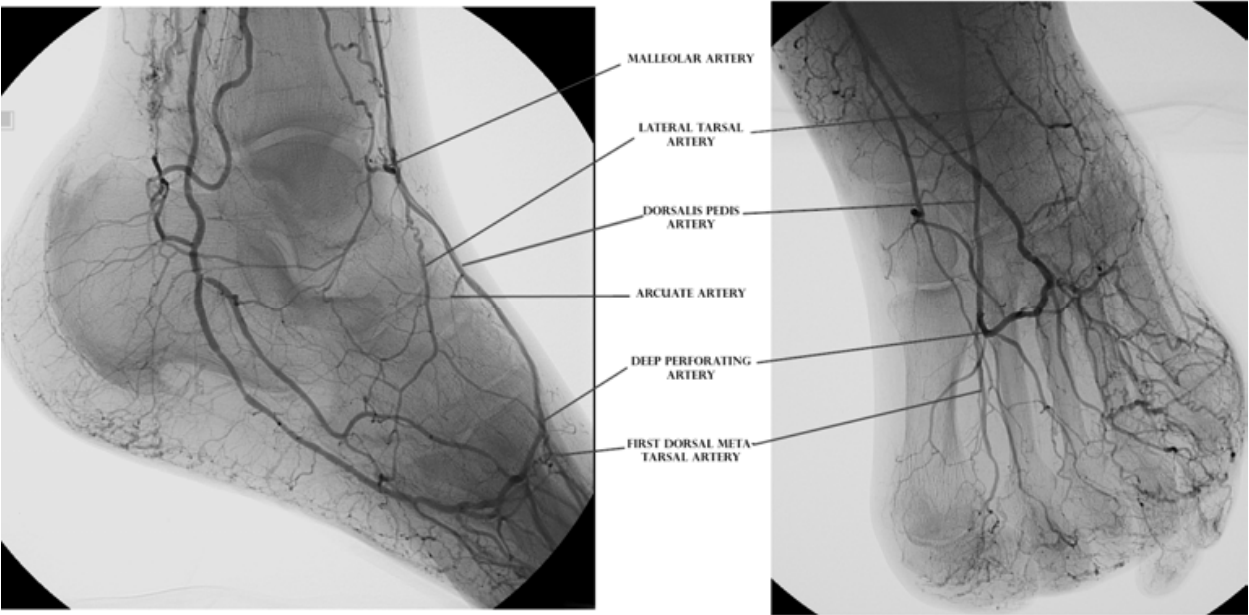


Fig. 2. Anterior and dorsal circulation. The major arteries are visualized in the lateral-oblique view (left side) and in the antero-posterior view (right side) angiographic projections.

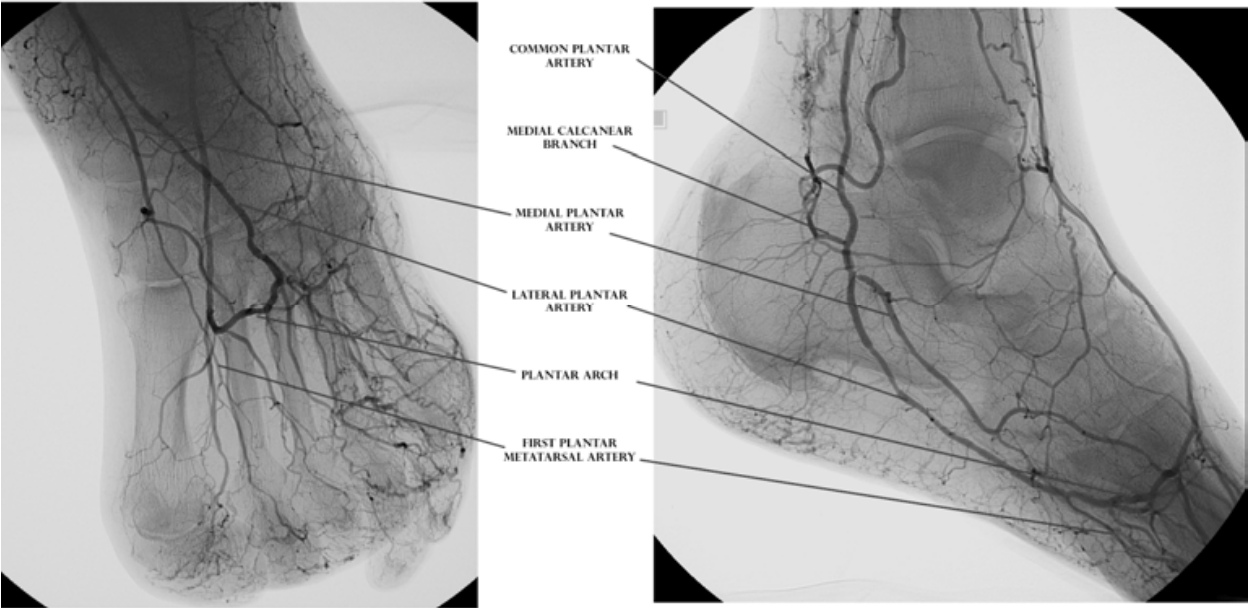


Fig. 3. Posterior and plantar circulation. The major arteries are visualized in antero-posterior view (left side) and in the lateral-oblique view (right side) angiographic projections.

The choke vessel system links the angiosomes to one another. A unified network is created so that one source artery can provide blood flow to multiple angiosomes beyond its immediate border.

While the choke vessels provide an indirect connection among angiosomes, there are also direct arterial-arterial connections that allow blood flow to immediately bypass local obstructions in the vascular tree.

The six angiosomes of the foot and ankle originate from the three main arteries to the foot and ankle. The posterior tibial artery supplies the medial ankle and the plantar foot, the anterior tibial artery supplies the dorsum of the foot, and the peroneal artery supplies the anterolateral ankle and the lateral rear foot. The large angiosomes of the foot can be further broken into angiosomes of the major branches of the above arteries. The three main branches of the posterior tibial artery each supply distinct portions of the plantar foot: the calcaneal branch (heel), the medial plantar artery (instep), and the lateral plantar artery (lateral midfoot and forefoot). The two branches of the peroneal artery supply the anterolateral portion of the ankle and rear foot, the anterior perforating branch (lateral anterior upper ankle) and the calcaneal branch (plantar heel). The anterior tibial artery supplies the anterior ankle and then becomes the dorsalis pedis artery that supplies the dorsum of the foot (Attinger CE, et al. 1997; Attinger CE, et al. 2001; Sarrafain SK. 1993; Taylor GI, et al. 1998).

The dorsalis pedis artery follows a curved pathway on the forefoot to join the first plantar space, where meets the posterior circulation through the perforating deep artery.

In according with angiosome concept, the foot lesion location is related to an specific angiosome and the revascularization of this specific angiosome is our target vessel or wound related artery.

5. Endovascular intervention

Endovascular recanalization of tibial vessels and foot arteries should be the first line treatment in patients with CLI, because of its good technical and clinical outcomes.

Endovascular treatment is possible in most cases, with the known low complication rate of PTA. In cases in which endovascular revascularization failed, all surgical options remain open.

The primary indications for tibial and foot arteries intervention is limb salvage, to avoid amputations. Patients with chronic leg ischemia face a gloomy future, in fact, long-term survival rate with CLI is significantly lower than that of a matched population.

Limb salvage is of more importance to these patients. The most plausible explanation for this is that healing the wounds and/or infection will reduce the oxygenation demand.

5.1 Vessel features

Calcified vessels are the most difficult situation in endovascular treatment, especially when calcifications are very dark and thick, in a visual evaluation. We propose intraluminal approach in very heavy calcified vessels, using dedicated 0.014" guide wire and short, low-profile OTW dedicated catheter balloons, like coronary balloons. OTW catheter balloon are necessary in order to be able to inject contrast material and check the position and to change the wire, when necessary.

Non calcified vessel allows different recanalization alternative, as endoluminal or subintimal approach. If the occluded tract is short, may be endoluminal approach could be the first alternative. In long occlusions, especially when there is a good distal re-entry, subintimal approach could be a good alternative.

In calcified vessel, when is imposible to cross the lesion trough the true lumen and vascular situation are dramatic and the indications to revascularization, related to wounds on the foot are present, a more aggressive strategy could be adopted. A subintimal attempt is justified in these cases and could bring to good result.

5.2 Technical strategies

Antegrade access in the common femoral artery is, in our experience, the best approach to perform tibial and foot arteries revascularization, with excellent guide-ability of the guide-wire and good push-ability of the catheter balloons due to this access is closer to the lesions. Contra-lateral approach is indicated in cases in which iliac treatment is required or is possible to treat contra-lateral common femoral artery or Superficial femoral artery. In cases of BTK interventions makes the procedure more difficult, require long shafts catheter balloons, limits some technical strategies and makes complications management considerably more complex.

In some selected cases antegrade access in the popliteal artery could be useful, because it is closer to the lesions and ensure more push-ability of the devices, but the prone position of the patient is required.

Previously to begging the procedure are injected, systematically, a intra-arterial bolus of 5.000 I.U of heparin. The patients are undergo to double anti-platelets therapy with ticlopidine, 250 mg daily and acetylsalicylic acid 100 mg daily, 3 days before the procedure. The double antiaggregation is continued for 6 weeks after the procedure and acetylsalicylic acid is prescribed quoad vitam.

5.2.1 Transluminal recanalization

Transluminal recanalization is the preferred techniques to treat stenotic lesions, very short occlusions (<1 cm) (Hauser H, et al. 1996) or lesions that involve the bifurcations. In our experience, is the best technical strategy to recanalize calcified vessels and it could be the first choice in CTO lesions with very heavy calcified arteries.

The classic approach to intraluminal recanalization use a guide-wire in conjunction with a support catheter to cross the lesion (Patel PJ, et al. 2010).

In our experience we prefer to use a 0.014"-in. guide-wire (Pilot@200 - Abbott) with an angulated tip (45° angle), that allows to guide the guide-wire, avoiding subintimal progression or vessel spills. A straight CTO dedicated guide-wire can also be used, with good results, in calcified and insuperable lesions.

The first step is to penetrate the proximal occlusion followed by negotiation the full extent of the occlusion, until the distal patent lumen. A drilling motion of the guide-wire is performed to properly penetrate and cross the lesion. Often times, a short and low profile coaxial catheter balloon can be used as a support catheter (Patel PJ, et al. 2010). Coaxial catheter balloon system is preferred to monorail system, because monorail system work well when the sheath tip can be placed close to the lesion. Coaxial system allows to remove the guide-wire, inject contrast media and check the position of the catheter and, if necessary, change the guide-wire. When the recanalization is completed, we perform a pre-dilatation with the support catheter balloon. A definitive dilatation is performed with a long catheter balloon, and based in the authors experience, in a heavy calcified vessels we prefer to avoid dissections during PTA dilating the crural vessels to 2.5 mm and the foot arteries to 2 mm in diameter (Fig 4 and 5).

Diagnostic angiography. (A-B) Obstruction of the anterior and posterior arteries, patency of the tibio-peroneal trunk and peroneal artery. (C-D) patency of common plantar artery, dorsalis pedis artery and plantar arch, in a heavy calcified vessels.

(E-H) Intraluminal recanalization of the posterior tibial artery, lateral plantar artery, plantar arch and the digital branch for the first toe and angioplasty of the digital branch (1.5 x 20 mm catheter balloon). (I-J) Intraluminal PTA of the posterior and anterior tibial arteries (2.5 x 220 mm catheter balloon).

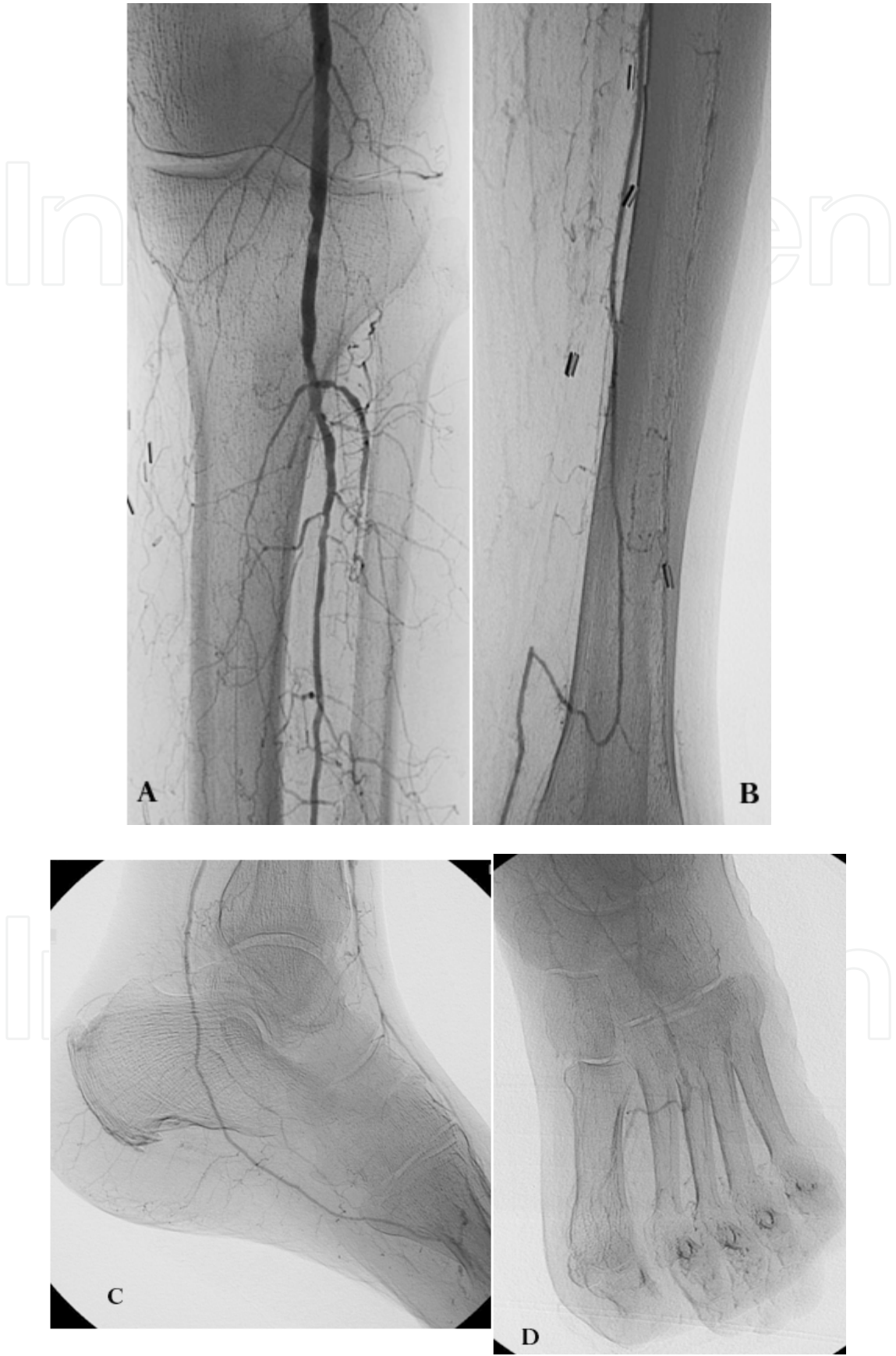

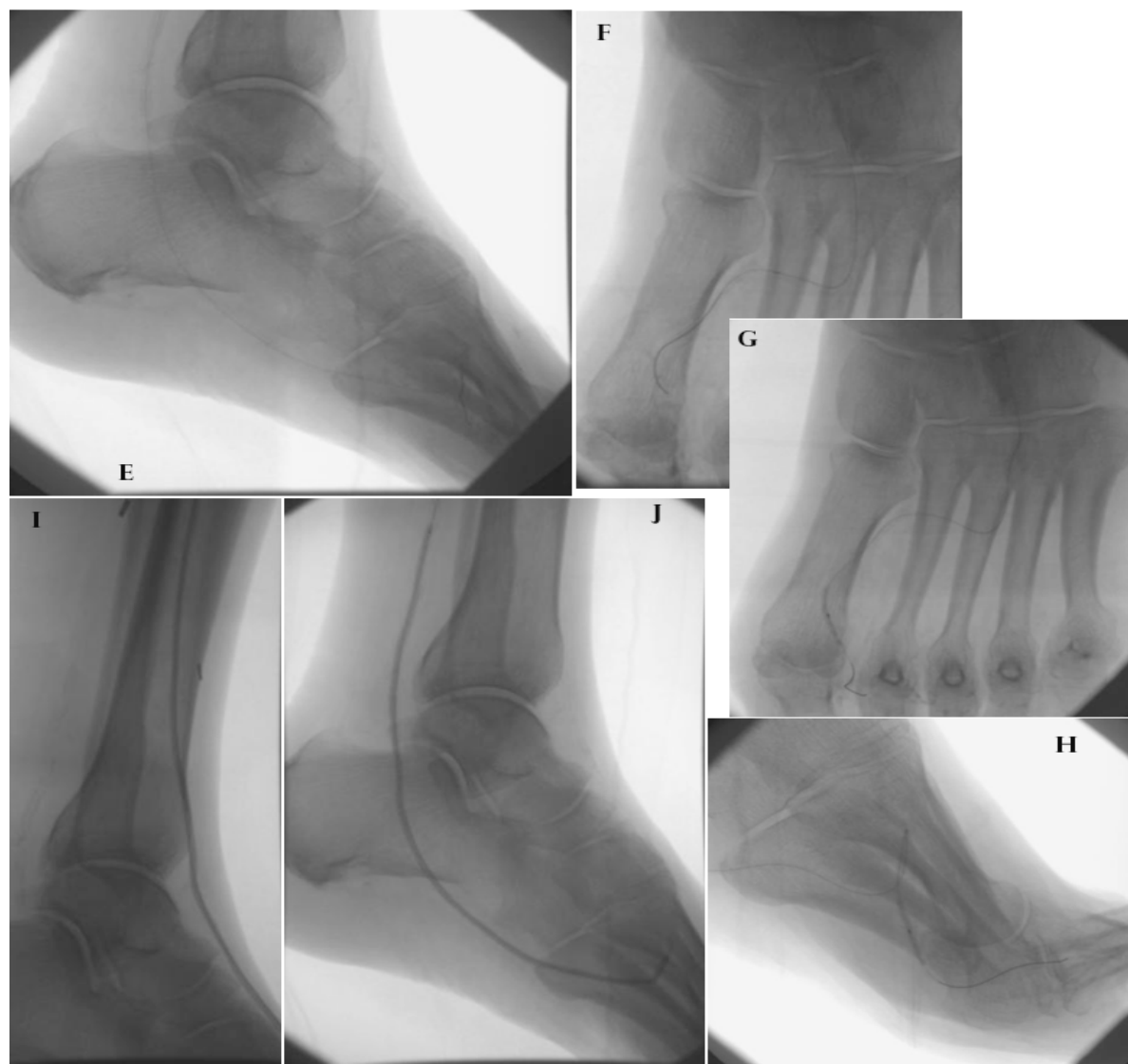


Fig. 4. Case 1. Diabetic patient with apical ulcer on the first toe, TcPO₂: 13 mmHg. Diagnostic angiography. (A-B) Obstruction of the anterior and posterior arteries, patency of the tibio-peroneal trunk and peroneal artery. (C-D) patency of common plantar artery, dorsalis pedis artery and plantar arch, in a heavy calcified vessels. (E-H) Intraluminal recanalization of the posterior tibial artery, lateral plantar artery, plantar arch and the digital branch for the first toe and angioplasty of the digital branch (1.5 x 20 mm catheter balloon / FlexeCTO – Clearstream). (I-J) Intraluminal PTA of the posterior and anterior tibial arteries (2.5 x 220 mm catheter balloon / Bantamα – Clearstream).

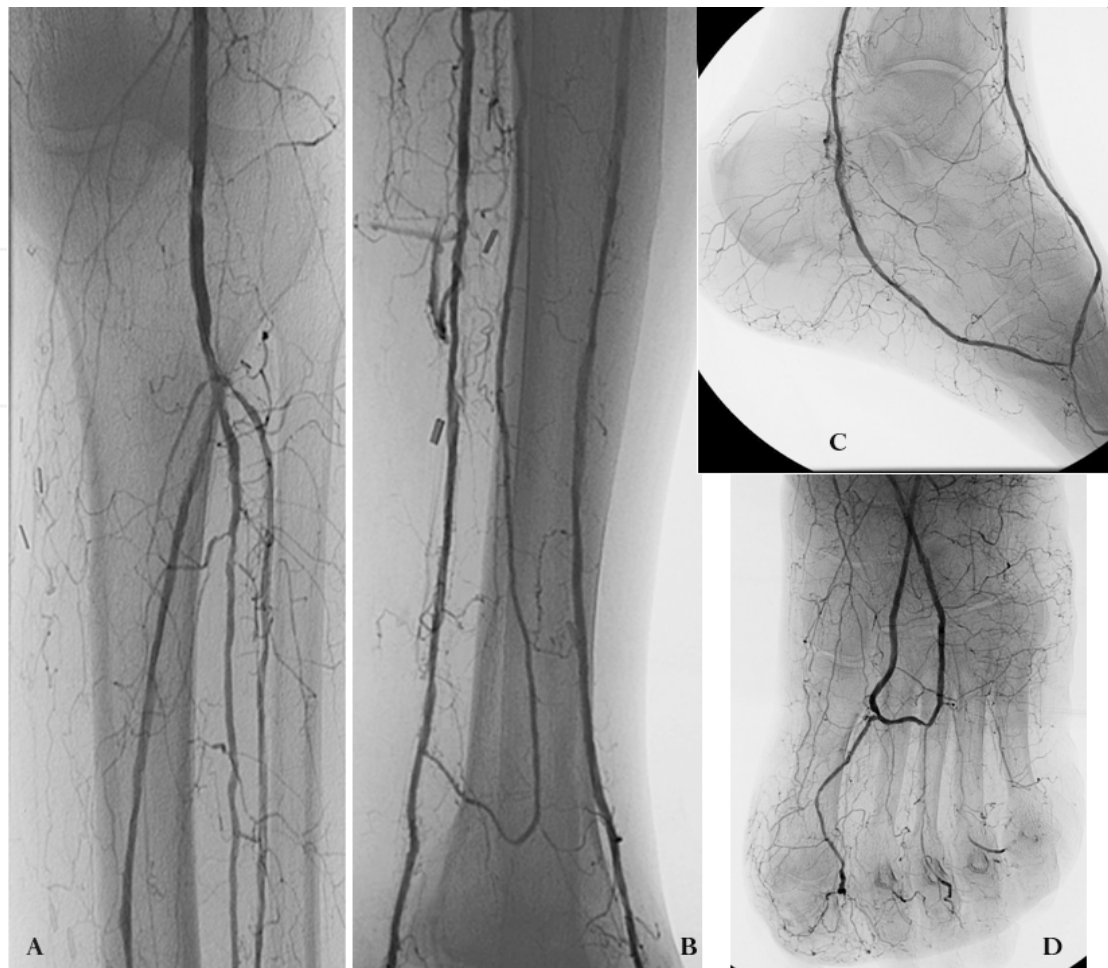


Fig. 5. Case 1. Technical and clinical results.

(A-D) Angiographic results of the intraluminal recanalization of the anterior and posterior tibial arteries; lateral plantar and dorsalis pedis arteries, plantar arch and the first digital branch, with excellent blood flow in the target vessel.

Clinical follow up at 4 months show increased of the TcPO₂ to 42 mmHg and ulcer healing, avoiding amputation.

5.2.2 Subintimal recanalization

On the other hand, when the arteries are not calcified or low and incomplete calcifications are observed, a subintimal recanalization is proposed as the first technical strategy. Subintimal angioplasty was first described by Bolia (Bolia A et al. 1990) and since then there have been a lot of publications confirming the value and assess the clinical results of this technique to treat tibial vessels (Alexandrescu V, et al. 2009; Bolia A, et al. 1994, Bown MJ, et al. 2009; Chun JY, et al. 2010; Ingle H, et al. 2002; Met R, et al. 2008; Reekers J, et al. 1994, Spinoso DJ, et al. 2004).

A subintimal recanalization in a heavy calcified crural vessels can also be considered, after failure of intraluminal attempts, with the impossibility to cross the lesion (Bolia A. 1998.)

This technical strategy could also be used in Pedal arteries and a published paper described this technical option to recanalize the Pedal arch (Fusaro M, et al. 2007).

The principal advantages of this technique are the ability to cross long chronic occlusions and the option of recanalization of more than one crural vessel. In our experience, the failure of this technical strategy is related to heavy calcified vessels, with fissuring the arterial wall

during the subintimal progression of the guide-wire, rupture of the arterial wall and failure of the recanalization.

We perform a subintimal recanalization in crural arteries with a 0.018"-in guide-wire (V18® - Boston Scientific) or, less frequent, with 0.014"-in guide-wire (Pilot®200 - Abbott).

The 0.014"-in guide-wire should be preferred to perform a subintimal recanalization in the Pedal arteries.

Is also possible to perform a subintimal dissection using a 0.035"-in hydrophilic guide-wire, but in our opinion this more aggressive approach is reserved for cases with heavy calcified vessel and is not indicated for Pedal arteries recanalization. A diagnostic catheter (Berenstein II® - Cordis) or a balloon catheter, is used to support the guide-wire during subintimal progression.

We prefer to avoid a pre-dilatations of the subintimal dissection before to reach the distal patent lumen and check the re-entry. This is just a modification of Bolia technique, in order to avoid the risk of potential bleeding secondary to vessel perforation or to prevent the dilatation of the subintimal dissection that could not re-entry and could need to change the subintimal way to obtain technical success. When the re-entry is achieved, we change a guide-wire with a new one, usually 0.014"-in to avoid spasm in the foot arteries and Pedal arch.

After pedal distal patent lumen recanalization, we deploy a low profile catheter balloon and perform a pre-dilatations of the crural vessel. After short balloon pre-dilatation, a longer one can be placed and a final dilatation performed. We usually dilate crural vessels with a 3 mm diameter balloon and Pedal arteries, including Pedal arch with 2.5 mm diameter balloon. When the result is still not satisfactory, dilatation can be repeated.

In a recent published study (Met R, et al. 2005) a systematic review showed that subintimal recanalization can be a useful option in the treatment of patients with CLI, with primary success rate of 80-90% and 1 year limb salvage rate as high as 90% and conclude that despite the moderate long-term patency rates of the revascularized segments, subintimal angioplasty may serve as a "temporary by-pass", providing wound healing and limb salvage.

5.3 Antegrade and retrograde recanalization

In our experience antegrade approach should be the first choice to treat tibial vessels and foot arteries and a retrograde recanalization should be seen as a support or problem solving strategy, in cases of antegrade failure, such as the inability to re-enter in the true patent distal lumen after subintimal recanalization.

In this context, the retrograde recanalization can be performed and there are different technical options, such as trans-collateral navigation and retrograde recanalization, Pedal-Plantar Loop technique or, retrograde distal access and recanalization.

In our opinion, perform a distal retrograde access is the last technical strategy in order to create a re-entry or resolve problems.

5.3.1 Trans-collateral recanalization

In many cases of extreme vascular intervention, it is not possible to perform regular antegrade recanalization of occluded tibial arteries, which makes even the most expert interventionist resort to unusual techniques (Bolia A, 2005; Fusaro M, et al. 2008; Graziani L, et al. 2008, 2011) to restore direct blood flow to the foot. Combined retrograde-antegrade arterial recanalization through collateral vessels, essentially combined retrograde and antegrade arterial recanalization using a single entry site.

This technical strategy, largely tested by the authors, has been described in published papers (Fusaro M, et al 2008, Graziani L, et al. 2011) and is intended as option to recanalize tibial arteries.

In our experience it could also be used to recanalize foot arteries, using a natural anastomoses in the foot, such as the so-called “Deep arch” of the foot, that communicate medial plantar artery with lateral tarsal branch and can be tracking in each other sense, to recanalize anterior or posterior tibial artery or in order to arrive to the Pedal arch, through the tarsal branch. In the same way, there is a natural anastomoses between peroneal artery and the “Deep arch” of the foot (Palena LM, et al. 2011), through a perforating deep branch and tracking this way is possible to retrogradely racanalize the other tibial arteries, via peroneal artery, using a “Deep arch” of the foot.

The vessels are finally recanalized by antegrade PTA (Fig. 6 and 7).

There are another collateral ways or natural anastomoses between tibial and foot arteries that allows to perform retrograde-antegrade recanalization of the tibial and the foot arteries, and its represent an alternative option to recanalize the target vessel.

However, the use of this technique may be considered selectively, even in last-attempt efforts, when other options are not possible or are contraindicated. This technique may be of value specifically when a proximal occlusion stump is not evident, when a dissection flap or a perforation in the proximal tract of the target vessel impairs guide-wire advancement. This technique may represent a feasible endovascular option to avoid more invasive, time-consuming or riskier procedures.

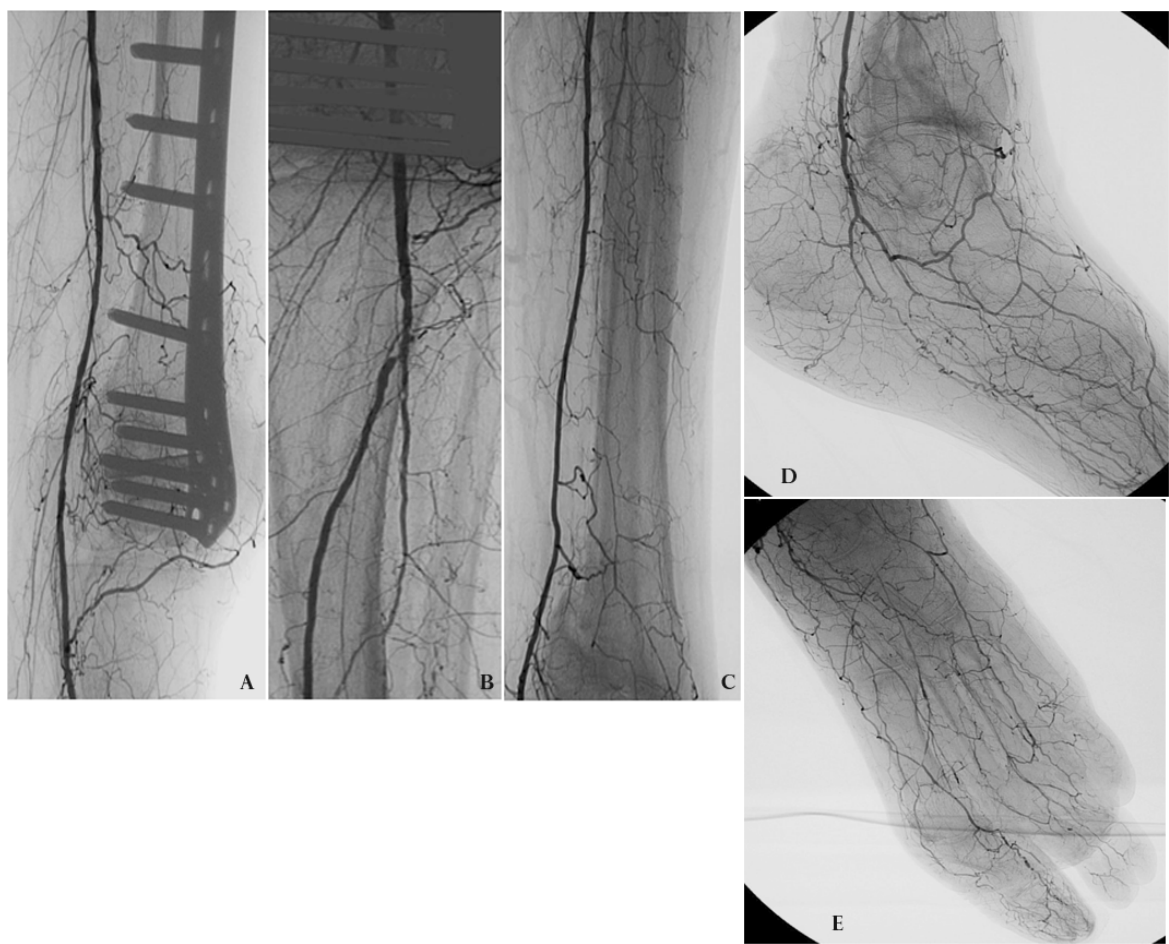


Fig. 6. Case 2. Diabetic patient with amputation of the II and V toes, previously undergone to endovascular treatment with poor outcome and guide-wire fracture at the origin of the dorsalis pedis artery with loss the rest of the wire in a subintimal lumen. TcPO2: 6 mmHg.

(A-D) Diagnostic angiography shown patency of the posterior tibial artery and obstruction of the peroneal and anterior tibial arteries. On the foot patency of the first tract of the medial plantar artery and tarsal branch, obstruction of the lateral plantar and dorsalis pedis arteries.

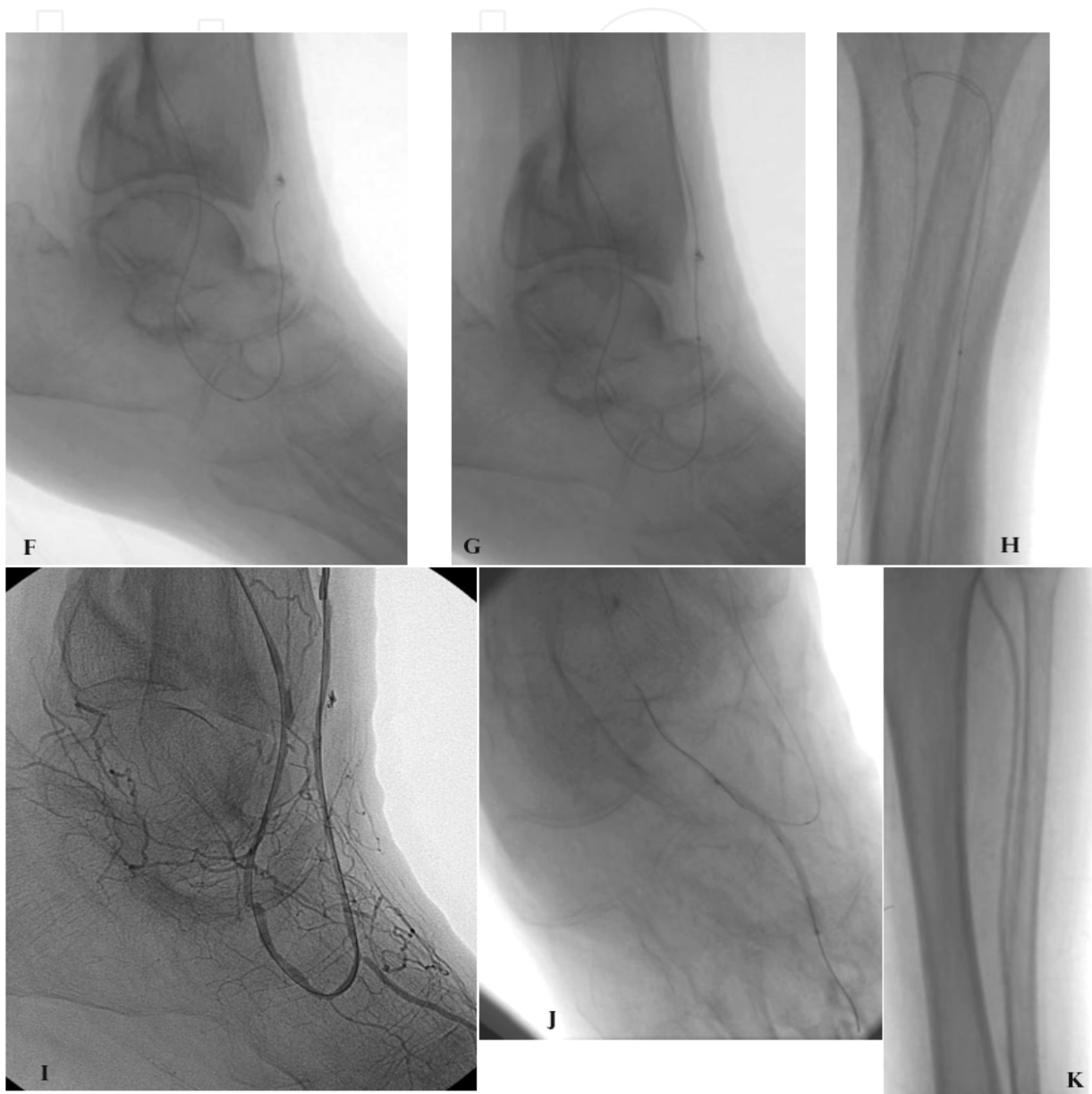


Fig. 6. (cont). (F-H) recanalization of the peroneal artery and, through the “deep arch”, retrogradely recanalization of the anterior tibial artery. After antegrade catheterization of the anterior tibial artery, (I) injection of the contrast material shown patency of the lateral tarsal branch. (J-K) PTA of the lateral tarsal branch (2 x 40 mm / FlexeCTO – Clearstream) and PTA of the anterior tibial artery (2.5 x 220 mm catheter balloon / Bantamα – Clearstream).

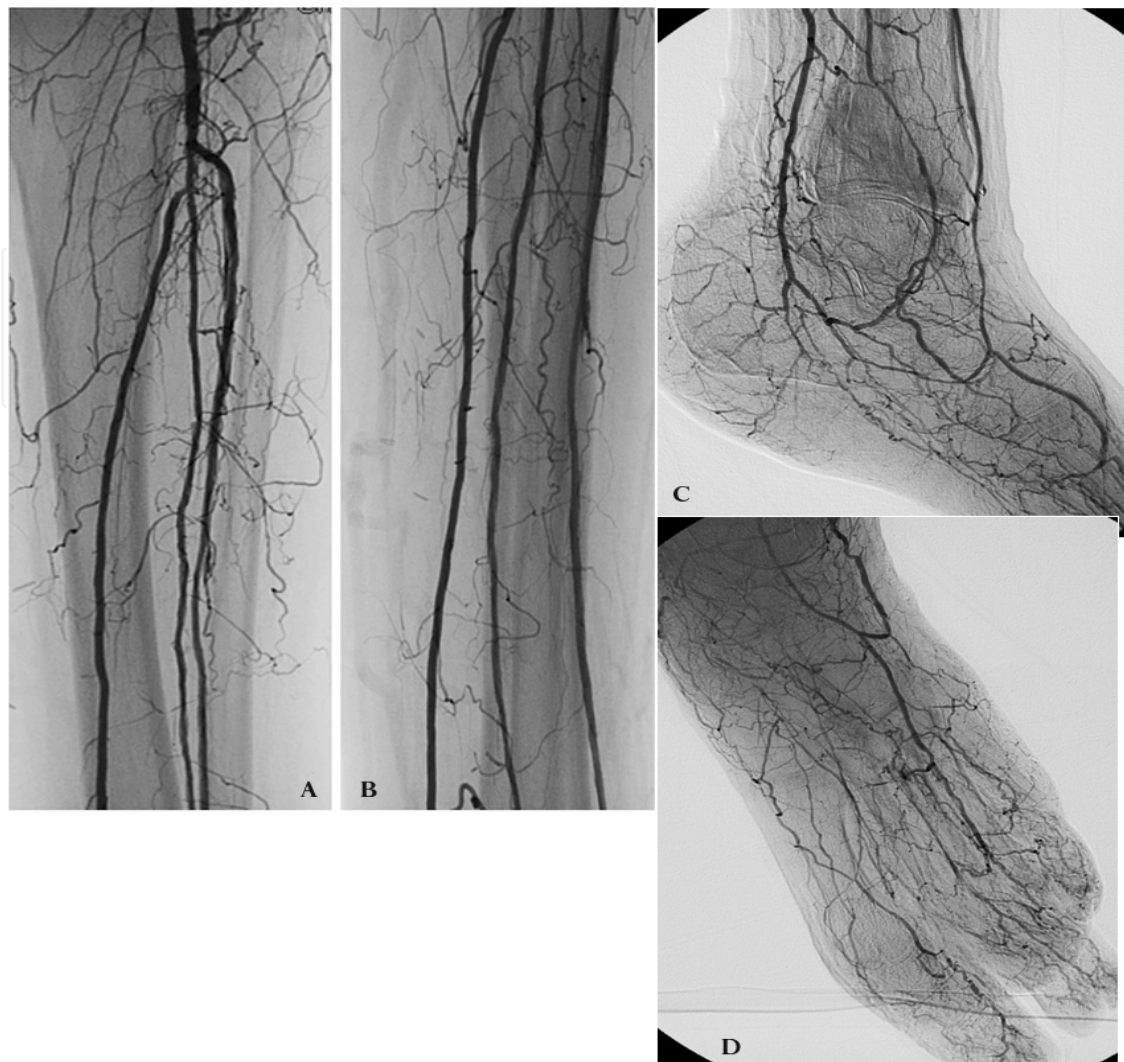


Fig. 7. Angiographic results. (A-B) Recanalization of the anterior and peroneal arteries, patency of the posterior tibial artery. (C-D) Recanalization of the lateral tarsal branch and plantar arch, with good blood flow for the foot and the toes.

Clinical follow up. TcPO₂ increased to 37 mmHg with healing the surgical treatment.

5.3.2 Pedal-Plantar LOOP technique

In a high percentage of cases the success rate of PTA remains suboptimal, particularly when the atherosclerotic disease involving also the distal run-off. In these cases the support of Pedal-Plantar LOOP technique could be necessary.

This technical approach, intended for the recanalization of challenging below-the-knee and below-the-ankle lesions, has been already described (Fusaro M, et al 2007) and the clinical results of its application in revascularization of tibial and foot vessels has thoroughly been described in a recent paper (Manzi M, et al. 2009).

Specifically, this technique consist in either one or both the following two approaches: antegrade recanalization of the anterior tibial artery and the pedal artery, including the pedal arch, followed by retrograde recanalization of the lateral plantar artery and then of the posterior tibial artery; or antegrade recanalization of the posterior tibial artery and the lateral plantar artery, including pedal arch, followed by retrograde recanalization of the

pedal artery and then of the anterior tibial artery. After successfully crossing the target lesion with the guide-wire, usually 0.014"-in (Pilot® 200 - Abbott), a dedicated low-profile over-the-wire catheter balloon should be deployed for PTA and the check to confirm the position of the tip of the catheter in the distal true lumen should be done, injecting contrast media through the catheter.

Pedal-Plantar LOOP technique is based on the creation of a loop with the guide-wire from the anterior tibial to the posterior tibial arteries (or vice versa) by means of guide-wire tracking through the pedal arch of the foot.

Clearly, this strategy can be adapted case by case and a combination of other technical possibilities, such as subintimal recanalization of the tibial vessel recanalized antegradely, followed by a re-entry on the foot artery or a subintimal recanalization of the foot and tibial artery recanalized retrogradely, followed by a re-entry at the origin of the tibial vessel, could help to reach both, technical and clinical success.

This technique may be of particular value whenever a proximal occlusion stump is unavailable, when dissection flap or a perforation in the proximal tract of the target vessel impairs the guide-wire advancement, as well as when distal disease makes retrograde percutaneous puncture impossible.

5.3.3 Retrograde percutaneous revascularization

In our opinion this should be the last technical strategy, considered when the possible solutions before described failed.

It is intended as a direct percutaneous retrograde puncture of the distal tract of the tibial vessel or foot arteries, in order to retrogradely recanalization of the target vessel (Fig. 8 and 9).

This approach has been described as a solution for the re-entry in a subintimal recanalization (Gandini R, et al. 2007; Spinoso DJ, et al 2003, 2005), that in a small percentage of patients in whom antegrade subintimal recanalization is unsuccessful or there is a limited distal target vessel "landing" zone, a retrograde distal puncture can be performed and a retrograde recanalization, following by antegrade PTA and haemostasis may be a solution.

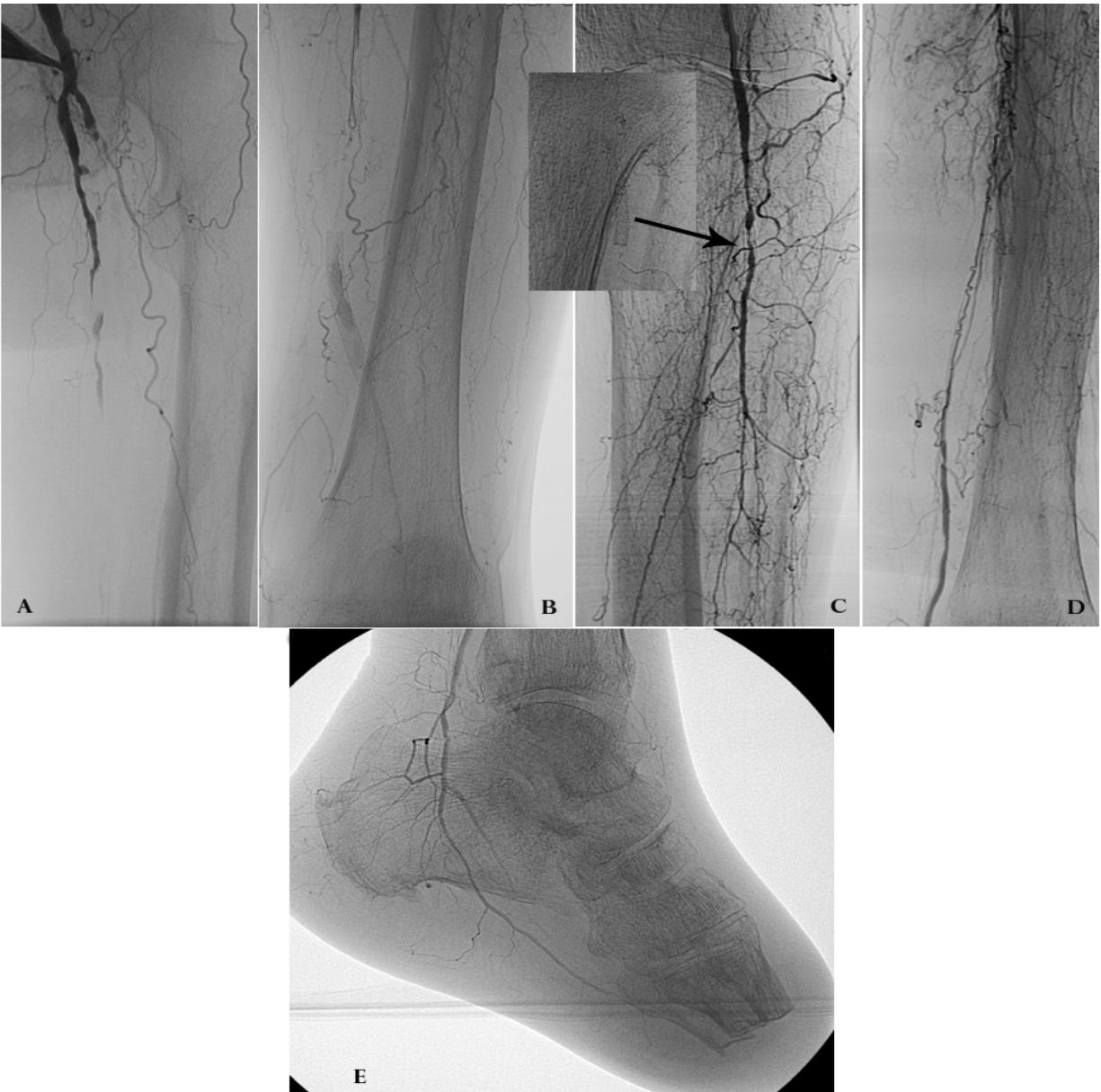The possible retrograde access site may be different, such as distal tract of the posterior tibial artery, pedal artery (Fusaro M, et al. 2006, 2007) or peroneal artery, but the difficulties to perform the puncture increase from each other site and the risk to damage the distal patent vessel, compromising the possibility to perform a distal by-pass, should be considered.

In our experience, in selected and very challenging cases in whom a distal by pass is contraindicated, antegrade revascularization attempts failed and retrograde percutaneous distal access on the target vessel is not possible or failed too, an antegrade percutaneous distal access on the Pedal artery or in the common plantar artery, followed by antegrade recanalization of the foot artery, pedal arch and retrograde recanalization of the target vessel, is possible, but should be considered as indication in cases in whom every other endovascular or surgical strategy failed or are contraindicated.

Endovascular recanalization of the tibial vessels and foot arteries, especially in diabetics with CLI is actually an excellent treatment option and, in our experience, should be considered as the first treatment option for revascularization. Different clinical studies and registries show that technical success rate is between 80% and 90% and clinical

success rate, intended as limb salvage, is about 70% at 12 months. These technical and clinical outcomes are obtained in a dedicated centers, combining all technical strategies described before.

Stent deployment in the below-the-knee district, in our opinion, should be considered as the last treatment option, because in-stent re-stenosis and occlusion related to neo-intimal hyperplasia or struts fractures, is a frequent complication and the presence of occluded stent represent a foreign body that makes new endovascular treatment very difficult.



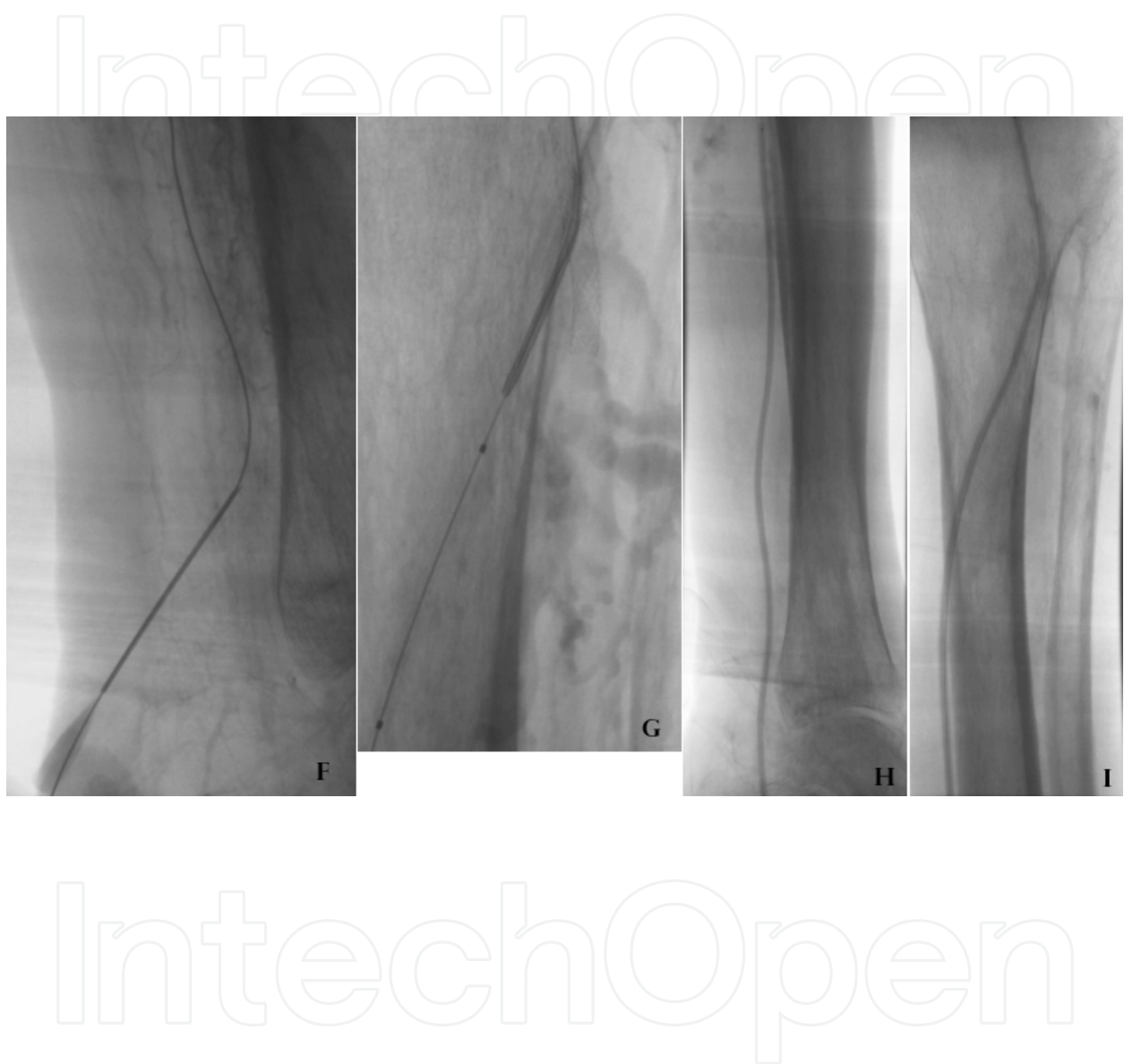


Fig. 8. Case 3. Diabetics patient, previously underwent to TMA, with apical ischemic wound. The patient was underwent to endovascular treatment and stenting in the tibio-peroneal trunk, without any stump of the posterior tibial artery origin. TcPO₂: 4 mmHg. (A-E) Occlusion of the SFA with stent, occluded in the distal tract. Patency of the popliteal artery and the tibio-peroneal trunk, with in-stent re-stenosis and patency of the peroneal artery and the distal tract of the posterior tibial artery. On the foot patency of the plantar arteries. (F-I) Retrograde puncture of the distal tract of the posterior tibial artery and retrograde recanalization. Antegrade long balloon PTA (2.5 x 220 mm catheter balloon / Bantam - Clearstream).

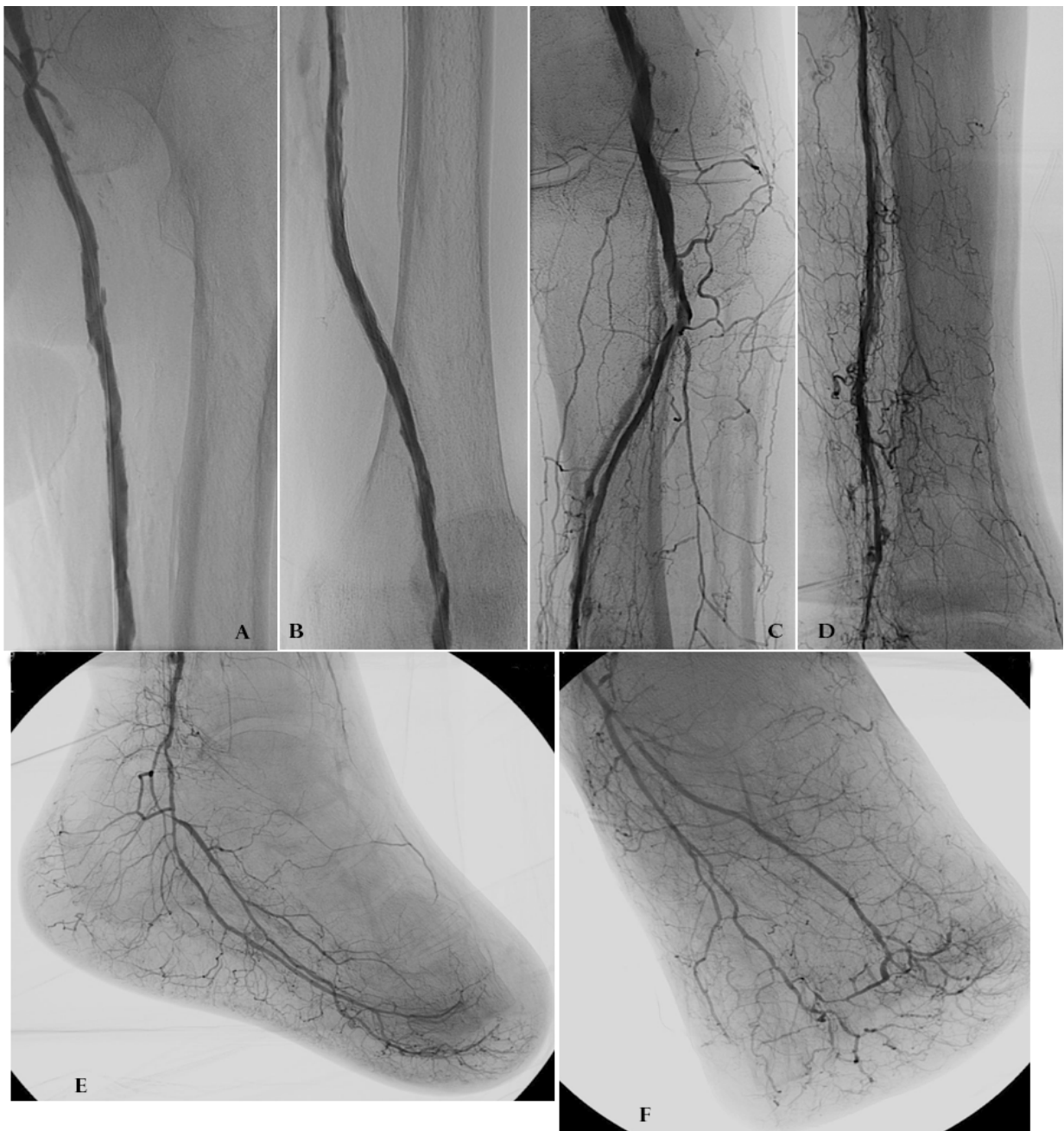

Fig. 9. (A-F) After PTA of the SFA and Popliteal arteries, the angiographic study show patency of the femoro-popliteal tract, patency of the tibio-peroneal trunk and posterior tibial artery with excellent flow for the plantar arteries and for the apical lesion on the foot. Clinical follow up. TcPO2 increased to 33 mmHg with wound healing.

6. Materials

During the last years the development of the BTK techniques and the increasing rate of BTK interventionists have led a continuous expansion of the dedicated materials.

Actually, there are a huge different type of dedicated guide-wire, from 0.014"-in and 0,018"-in to the 0,035"-in or CTO guide-wire, from different manufacturers, all usefully and necessary in the interventional suite.

In the same context, a lot of dedicated catheter balloons are actually available, from long balloons such as 22 cm or longer, to short and coronary-like such as 2 cm; and from 1.25 mm in diameter to 3 mm.

The selection of the guide-wire and the catheter balloons should be done on the personal preferences and experience, but the availability of different materials, from different manufacturer would be useful and necessary to perform very challenging cases.

7. New frontiers and devices

Current results of minimally invasive endovascular techniques, with 2-years patency rate between 40 and 60%, low primary patency and increased repeat intervention rates, has oriented toward new alternative techniques.

7.1 Atherectomy

Percutaneous angioplasty of below-the-knee arteries is an accepted therapy for patients with critical limb ischemia (Buckenham TM, et al. 1993; Hanna GP, et al. 1997; Saab MH, et al. 1992; Soder HK, et al. 2000).

However, below-the-knee interventions are limited by a considerable number of re-stenosis, especially in lesions with heavy calcified plaque. Directional atherectomy may be an alternative option to improve the procedural success and reduce the re-stenosis rate and the re-intervention rate (McKinsey JF, et al. 2008; Zeller T, et al. 2004, 2007).

In our opinion this debulking device is indicated especially in cases of re-stenosis, but also is an excellent option to treat bifurcations and could be used to treat in-stent re-stenosis, despite this indication (in-stent treatment) is contraindicated by the manufacturer.

Atherectomy should be prefer to traditional PTA in the popliteal artery, because of excellent technical results, avoiding dissection and stenting (Fig. 10).

New dedicated BTK devices, with range from 2 to 4 mm in diameter, very small caliber design and excellent push-ability allow the recanalization of long occlusion, involving tibial vessels and/or foot arteries.

The atherectomy cutter catheter usually need a 6F sheath and is designed to track over a 0.014"-in guide-wire. Is recommended to use atherectomy crossing the lesion intraluminally, because of the potential risk of perforation during subintimal debulking. Cases of stenosis can be treated with primary atherectomy whereas occlusions should be pre-dilated with an undersized catheter balloon, to be sure that the guide-wire crosses the occlusion intraluminally and to guaranty the progression of the cutter catheter through the occlusion.

Rotational atherectomy is also a useful technical strategy for calcified vessels. The limits of this technique is the push-ability of the device, that usually require long sheath deployment into the tibial vessel.

After atherectomy, usually, is not necessary perform catheter balloon dilatation, because the atherectomy results are satisfactory when the debulking procedure is performed correctly, cutting in the four faces of the artery wall.

This technique present low rate of complications and could be the option to avoid stent deployment with significant advantage in cases of re-stenosis, allowing the endovascular re-intervention.

Promising acute and long-term clinical results, with a high rate of limb salvage and high rate of primary and secondary patency (McKinsey, et al. 2008), makes this technical strategy an excellent option for endovascular treatment in the below-the-knee district.

7.2 DEB's

The other possible solution to fight re-stenosis in the BTK district could be Drug eluting balloons. This new technology, Paclitaxel-coated balloons should be a potential role in the peripheral district (Manzi M, et al. 2010; Sharma S, et al. 2010; Waksman P, et al. 2009) to avoid re-stenosis due to the antiproliferative effect. The use of DEB is not technically complex and there are, actually, a wide range of different devices. Despite the encouraging data on coronary arteries where drug eluting devices have shown promising antirestenotic effects in experimental and clinical trials, a clinical results in BTK district, early experimental and clinical data are promising but a randomized controlled trials, comparing DEB and traditional angioplasty or DEB and atherectomy must be produced.

The limits of DEB's, in our experience, is the use of this device in a subintimal recanalization. DEB's are preferred to be used in intraluminal recanalization, due to the risk of pseudo-aneurism formation during subintimal recanalization.

7.3 Cryoplasty

The rational to use this technology is based in the presumed more uniform and less traumatic immediate performance of cryoplasty, in synergy with the induction of the apoptotic effect, that would result in less neo-intimal hyperplasia and, as consequence, better immediate and long-term angiographic and clinical results (Sipiliopoulos S, et al. 2010).

The data about 12-months follow-up from the BTK Chill trial (Das TS, et al. 2009), which evaluated cryoplasty in the infra-popliteal district of CLI patients, reported high rates of acute technical success and major amputation-free interval (97.3% and 78.5%, respectively) followed by a low percentage of repeated procedure due to clinically deterioration (21% at 12 months).

We simply report the data published in the actual literature, because we do not have experience with this technical strategy, but the technical and clinical result are encouraging. It seem to avoids stent deployment, with the mentioned benefits in the BTK district. However, more experience are expected and could be useful more data about bigger cohort of patients.

7.4 Laser

The excimer laser technology is based on a cold-tipped laser that delivers intense bursts of energy in the ultraviolet range (308 nm) carried out in ultra-short pulse duration (0.05 nm per pulse vs 0.3-2.0 mm per pulse in the hot-tip laser). The energy delivered elicits photochemical, photothermal and photomechanical actions, which break molecular bonds, and produce vapor bubbles that generate kinetic energy (Serino F, et al. 2010).

This technology has been studied in below-the-knee lesions, with improved results over standard PTA alone and exhibited excellent limb salvage rate (Bosier M, et al 2005; Laird JR, et al.2006). The use of the excimer laser represents a great opportunity to pursue a true endoluminal recanalization with potential long-term efficacy and decreased need for stenting. The LACI and LACI Belgium study have both proven that laser-assisted angioplasty is a low risk, successful treatment strategy in CLI patients. Primary patency rate range from 83% at 6-months to 97.6% at 12-months and the limb salvage rate range from 92.5% at 6-months to 94% at 12-months. However, the reported rate of stent deployment in the mentioned study was in a range from 21% to 52.9%, and this seem to be a contradiction between the opportunity to pursue the reduction of stent deployment that is at the bases of the use of this device and the real data reported about stent placement.

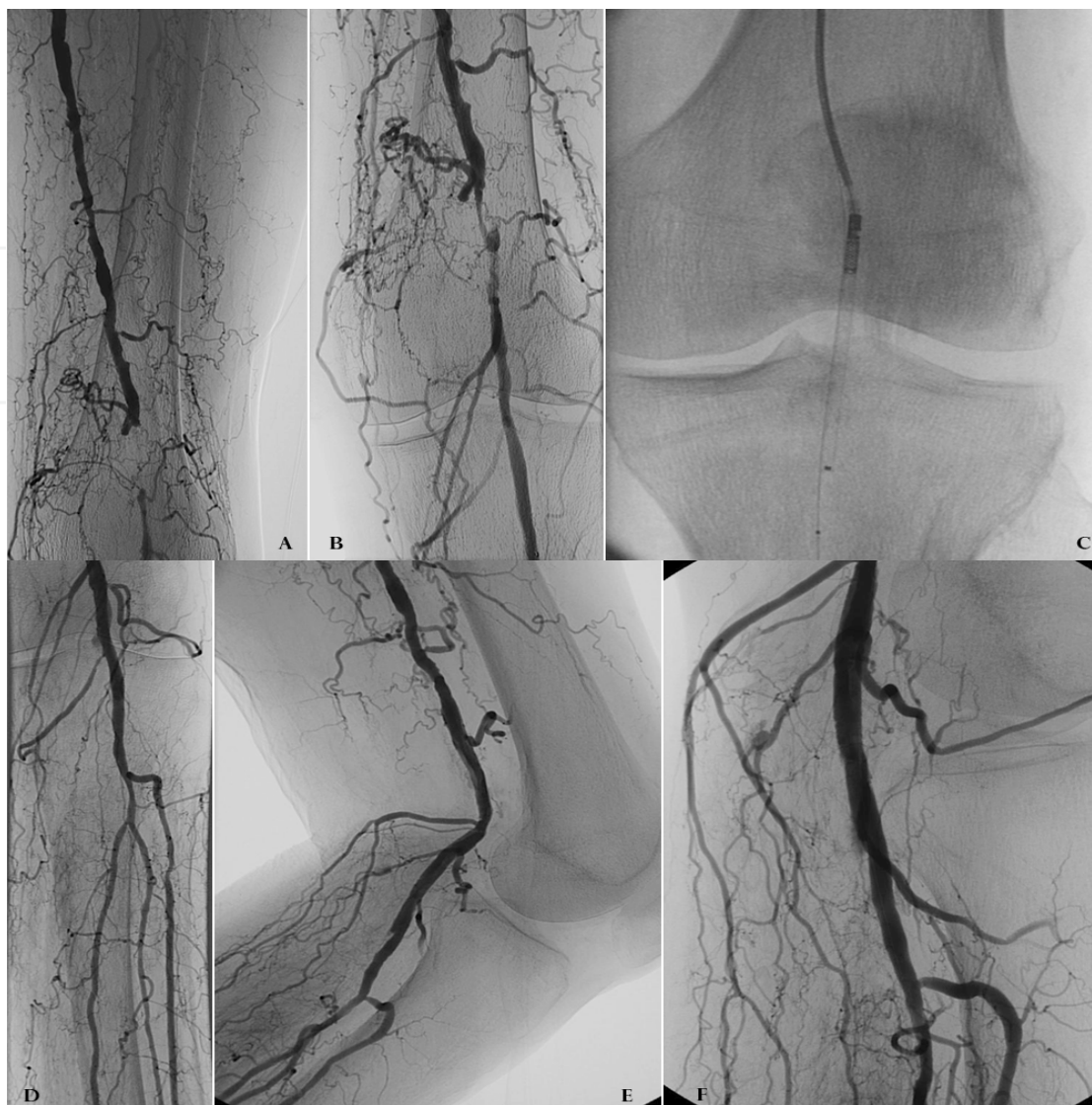


Fig. 10. Case 4. Diabetic patient with claudication intermittens (50 m). (A-B) Diagnostic angiography shows occlusion in the popliteal artery. (C) shows directional atherectomy of the occluded tract. (D-F) angiographic result shows excellent recanalization of the popliteal artery, without dissection, avoiding stenting and patency in flexion position.

8. Stent deployment

Finally, we want to express our opinion about stent deployment in the BTK district. In literature is reported the use of stent for various indications such as dissections, calcified restenosis, recoiling and thrombus formation (Tepe G, et al. 2007), with good clinical results. We are in accord with the concept that stent use translates in acute high technical success and good short-term patency rate, but the re-stenosis rate related to neo-intimal hyperplasia is very high and the presence of stent appear as a foreign body in the true or in a subintimal lumen, that makes re-intervention more complex or, sometimes, impossible. Our stent deployment rate in the BTK district in the last year, was less than 3% and it was related to very flow limiting dissection, especially in the bifurcations, thrombus formation with unsuccessful attempts to perform thrombus-aspiration and in 1 case the stent deployment was related to artery perforation with acute bleeding.

The fear that early thrombosis and late luminal loss due to intimal hyperplasia formation potentially leads to insufficient long-term patency rates can explain the reluctance on implanting stents in small diameter below-the-knee (BTK) arteries. Drug-eluting stent (DES) technology was developed to prevent early thrombosis and late luminal loss to potentially improve long-term patency rates (Bosier M, et al. 2011).

Currently, the first level 1 evidence from prospective, randomized, controlled DESTINY and ACHILLES studies indicate that the implantation of DES in short lesion in the infrapopliteal arteries leads to favorable outcomes with high primary patency rates and a published paper (Rosales OR, et al. 2008.) conclude that DES is a safe and effective long-term option for CLI due to severe infrapopliteal arterial disease. Long-term vascular patency led to a high rate of limb preservation and low amputation rate.

May be in the future, a resorbable dedicated stent conceived for the BTK district will change the indications for stent deployment in tibial arteries.

9. Conclusions

Endovascular treatment of critical limb ischemia in diabetics with crural and pedal disease can be an exceedingly challenging and complex problem. Technical success rate and clinical outcomes, with a high rate of limb salvage and amputation-free survival are encouraging, support the endovascular revascularization as the first treatment option and demonstrate that is a reasonable and effective approach. The rapid pace of development of various endovascular devices and techniques often allow the interventionalist to treat increasingly complex and diffuse patterns of disease.

Is essential for endovascular specialist, in order to reach these technical and clinical success, a thorough knowledge of the wide range of endovascular techniques and options.

Usually only one technical strategy is not enough to treat crural and foot arteries and a combination of the previously described techniques improve the results of the procedures and allow to achieve excellent clinical outcomes.

10. References

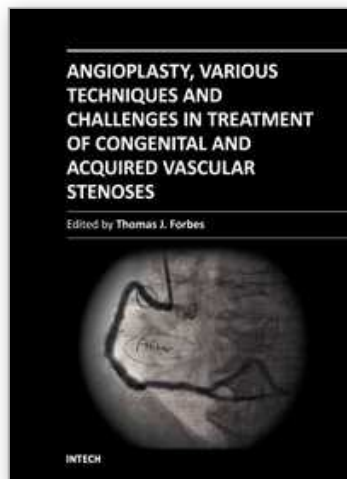
- Adam DJ, Beard JD, Cleveland T, Bell J, Bradbury AW, Forbes JF, et al. (2005). Bypass versus angioplasty in severe ischaemia of the leg (BASIL): multicentre, randomised controlled trial. *Lancet*. 3;366(9501):1925-34.
- Alexandrescu V, Hubermont G, Philips Y, Guillaumie B, Ngongang Ch, Coessens V, et al. (2009). Combined primary subintimal and endoluminal angioplasty for ischaemic inferior-limb ulcers in diabetic patients: 5-year practice in a multidisciplinary 'diabetic-foot' service. *Eur J Vasc Endovasc Surg*. 37(4):448-56.
- Athyros VG, Mikhailidis DP, Papageorgiou AA, Didangelos TP, Ganotakis ES, Symeonidis AN, et al. (2004). METS-GREECE Collaborative Group. Prevalence of atherosclerotic vascular disease among subject with the metabolic syndrome with or without diabetes mellitus: the METS-GREECE Multicentre study. *Curr Med Res Opin*. 20:1691-701.
- Attinger, C. E., Cooper, P. & Blume, P. (1997). Vascular anatomy of the foot and ankle. *Oper. Tech. Plast. Reconstr. Surg*. 4: 183.
- Attinger, C. E., Cooper, P., Blume, P. & Bulan, E. (2001). The safest surgical incision and amputations applying the angiosomes principle and using the Doppler to assess the arterialarterial connections of the foot and ankle. *Foot Ankle Clin. North Am*. 6: 745.

- Balmer H, Mahler F, Do DD, Triller J & Baumgartner I. (2002). Balloon angioplasty in chronic critical limb ischemia: factors affecting clinical and angiographic outcome. *J Endovasc Ther.* 9(4):403-10.
- Bargellini I, Petruzzi P, Scatena A, Cioni R, Cicorelli A, Vignali C, et al. (2008). Primary infrainguinal subintimal angioplasty in diabetic patients. *Cardiovasc Intervent radiol.* 31:713-22.
- Beckman JA, Creager MA & Libby P. (2002). Diabetes and atherosclerosis. *Epidemiology, pathophysiology and management.* *JAMA* 287:2570-81.
- Boiser M, Deloose K, Callaert J, Keirse K, Verbist J & Peeters P. (2011). Drug-eluting stents below the knee. *J Cardiovasc Surg (Torino)* 52(2):231-4.
- Boiser M, Peeters P, Elst FV, Vermassen F, Maleux G, Fourneau I, et al. (2005). Excimer laser assisted angioplasty for critical limb ischemia: results of the LACI Belgium study. *Eur J Vasc Endovasc Surg* 29:613-9.
- Bolia A, Miles KA, Brennan J & Bell PR. (1990). Percutaneous transluminal angioplasty of occlusions of the femoral and popliteal arteries by subintimal dissection. *Cardiovasc Intervent Radiol.* 13(6):357-63.
- Bolia A, Sayers RD, Thompson MM & Bell PR. (1994). Subintimal and intraluminal recanalisation of occluded crural arteries by percutaneous balloon angioplasty. *Eur J Vasc Surg.* 8(2):214-9.
- Bolia A. (1998). Percutaneous intentional extraluminal (subintimal) recanalization of crural vessels in lower limb ischemia: long-term results. *J Endovasc Ther* 9:411-16.
- Bolia A. (2005). Subintimal angioplasty in lower limb ischaemia. *J Cardiovasc Surg (Torino)* 46:385-394.
- Bown MJ, Bolia A & Sutton AJ. (2009). Subintimal angioplasty: meta-analytical evidence of clinical utility. *Eur J Vasc Endovasc Surg.* 38(3):323-37.
- Buckenham TM, Loh A, Dormandy JA & Taylor RS. (1993). Infrapopliteal angioplasty for limb salvage. *Eur J Vasc Surg* 7:21-5.
- Calligari, P.R., Taylor, G. I., Caddy, C. M. & Minabe, T. (1992). An anatomic review of the delay phenomenon: I. Experimental studies. *Plast. Reconstr. Surg.* 89: 397.
- Chun JY, Markose G & Bolia A. (2010). Developments in subintimal angioplasty in the infrainguinal segment. *J Cardiovasc Surg (Torino)* 51(2):213-21.
- Criqui MH, Fronek A, Barrett-Connor E, Klauber MR, Gabriel S & Goodman D. (1985). The prevalence of peripheral arterial disease in a defined population. *Circulation* 71(3):510-551.
- Criqui MH, Vargas V, Denenberg JO, Ho E, Allison M, Langer RD, et al. (2005). Ethnicity and peripheral arterial disease: the San Diego Population Study. *Circulation* 112(17):2703-2707.
- Das TS, McNamara T, Gray B, Sedillo GJ, Turley BR, Kollmeyer K, et al. (2009). Primary cryoplasty therapy provides durable support for limb salvage in critical limb ischemia patients with infrapopliteal lesions: 12-months follow-up results from chill trial. *J Endovasc Ther* 16(suppl 2):I119-I130.
- Dorros G, Jaff MR, Dorros AM, Mathiak LM & He T. (2001). Tibioperoneal (outflow lesion) angioplasty can be used as primary treatment in 235 patients with critical limb ischemia: five-year follow-up. *Circulation* 104(17):2057-62.
- Faglia E, Dalla Paola L, Clerici G, Clerissi J, Graziani L, Fusaro M. et al. (2005). Peripheral angioplasty as the first-choice revascularization procedure in diabetic patients with critical limb ischemia: prospective study of 993 consecutive patients hospitalized and followed between 1999 and 2003. *Eur J Vasc Endovasc Surg.* 29(6):620-7.

- Faglia E, Clerici G, Clerissi J, Gabrielli L, Losa S, Mantero M, et al. (2006). Early and five-year amputation and survival rate of diabetic patients with critical limb ischemia: data of a cohort study of 564 patients. *Eur J Vasc Endovasc Surg.* 32(5):484-90.
- Ferraresi R, Centola M, Ferlini M, Da Ros R, Caravaggi C, Assaloni R, et al. (2009). Long-term outcomes after angioplasty of isolated, below-the-knee arteries in diabetic patients with critical limb ischaemia. *Eur J Vasc Endovasc Surg.* 37(3):336-42.
- Fowkes FG, Housley E, Cawood EH, Macintyre CC, Ruckley CV & Prescott RJ. (1991). Edinburgh Artery Study: prevalence of asymptomatic and symptomatic peripheral arterial disease in the general population. *Int J Epidemiol* 20(2):384-392
- Fusaro M, Agostoni P & Biondi-Zoccai G. (2008). "Trans-Collateral" Angioplasty for a Challenging Chronic Total Occlusion of the Tibial Vessels: A Novel Approach to Percutaneous Revascularization in Critical Lower Limb Ischemia. *Catheterization and Cardiovascular Interventions* 71:268-72
- Fusaro M, Dalla Paola L & Biondi-Zoccai G. (2007). Pedal-Plantar LOOP Technique for a challenging below-the-knee chronic total occlusion: a novel approach to percutaneous revascularization in critical lower limb ischemia. *J Invasive Cardiol* 19:E34-7.
- Fusaro M, Dalla Paola L & Biondi-Zoccai G. (2006). Retrograde posterior tibial artery access for below-the-knee percutaneous revascularization by means of sheathless approach and double wire technique. *Minerva Cardioangiol.* 54:773-7.
- Fusaro M, Dalla Paola L, Brigato C, Marangotto M, Nicolini S, Ripay R, et al. (2007). Plantar to dorsalis pedis artery subintimal angioplasty in a patient with critical foot ischemia: a novel technique in the armamentarium of the peripheral interventionist. *J Cardiovasc Med (Hagerstown)* 8(11):977-80.
- Fusaro M, Tashani A, Molliceli N, Medda M, Inglese L & Biondi-Zoccai G. (2007). Retrograde pedal artery access for below-the-knee percutaneous revascularisation. *J Cardiovasc Med (Hagerstown)* 8:216-8.
- Gandini R, Pipitone V, Stefanini M, Maresca L, Spinelli A, Colangelo V, et al. (2007). The "Safari" Technique to Perform Difficult Subintimal Infragenicular Vessels. *Cardiovasc Intervent Radiol* 30:469-73.
- Graziani L, Silvestro A, Monge L, Boffano GM, Kokaly F, Casadidio I, et al. (2008). Transluminal angioplasty of peroneal artery branches in diabetics: initial technical experience. *Cardiovasc Interv Radiol* 31:49-55
- Graziani L & Morelli LG. (2011). Combined Retrograde-Antegrade Arterial Recanalization Through Collateral Vessels: Redefinition of the Technique for Below-the-Knee Arteries. *Cardiovasc Intervent Radiol* 34:S78-S82
- Hanna GP, Fujise K, Kjellgren O, GP, Feld S, Fife C, Schroth G, et al. (1997). Infrapopliteal transcatheter interventions for limb salvage in diabetic patients: importance of aggressive interventional approach and role of transcutaneous oximetry. *J Am Coll Cardiol* 30:664-9.
- Häuser H, Bohndorf K, Wack C, Tietze W, Wölfle KD & Loeprecht H. Percutaneous transluminal angioplasty (PTA) of isolated crural arterial stenoses in critical arterial occlusive disease. *Rofo.* 164(3):238-43.
- Hiatt WR, Hoag S & Hamman RF. (1995). Effect of diagnostic criteria on the prevalence of peripheral arterial disease. The San Luis Valley Diabetes Study. *Circulation* 91(5):1472-1479.
- Ingle H, Nasim A, Bolia A, Fishwick G, Naylor R, Bell PR, et al. (2002). Subintimal angioplasty of isolated infragenicular vessels in lower limb ischemia: long-term results. *J Endovasc Ther.* 9(4):411-6. Erratum in: *J Endovasc Ther* 9(5):A-6.

- Kullo IJ, Bailey KR, Kardia SL, Mosley TH, Jr., Boerwinkle E & Turner ST. (2003). Ethnic differences in peripheral arterial disease in the NHLBI Genetic Epidemiology Network of Arteriopathy (GENOA) study. *Vasc Med* 8(4):237-242.
- Laird JR, Zeller T, Gray BH, Scheinert D, Vranic M, Reiser C, et al. (2006). LACI investigators. Limb salvage following laser-assisted angioplasty for critical limb ischemia: results of the LACI multicenter trial. *J Endovasc Ther*. 13:1-11.
- Manzi M, Cester G & Palena LM. (2010). Paclitaxel-coated balloon angioplasty for lower extremity revascularization: a new way to fight in-stent restenosis. *J Cardiovasc Surg* 51:567-71.
- Manzi M, Fusaro M, Ceccacci T, Erente G, Dalla Paola L & Brocco E. (2009). Clinical results of below-the-knee intervention using pedal-plantar loop technique for the revascularization of foot arteries. *J Cardiovasc Surg* 50:331-7.
- McKinsey JF, Goldstein L, Khan HU, Graham A, Rezayat C, Morrissey NJ, et al. (2008). Novel Treatment of Patients With Lower Extremity Ischemia: Use of Percutaneous Atherectomy in 579 Lesions. *Ann Surg* 248:519-28.
- Met R, Van Lienden KP, Koelemay MJ, Bipat S, Legemate DA & Reekers JA. (2008). Subintimal angioplasty for peripheral arterial occlusive disease: a systematic review. *Cardiovasc Intervent Radiol*. 31(4):687-97
- Norgren L, Hiatt WR, Dormandy JA, Nehler MR, Harris KA, Fowkes FG, TASC II Working Group et al. (2007). Inter-society consensus for the management of peripheral arterial disease (TASC II). *J Vasc Surg* 45(Suppl.S):S5-S67.
- O'Hare AM, Vittinghoff E, Hsia J & Shlipak MG. (2004). Renal insufficiency and the risk of lower extremity peripheral arterial disease: results from the Heart and Estrogen/Progestin Replacement Study (HERS). *J Am Soc Nephrol* 15(4):1046- 1051.
- Palena LM, Cester G & Manzi M. (2011). Revascularización endovascular del pie y de las arterias tibiales a través de caminos alternativos, utilizando la arcada profunda del pie. Presented at IX SITE- Simposio Internacional sobre Terapéuticas Endovasculares. Barcelona 4-7 May 2011. Published at *Técnicas Endovasculares*. 14(1): 3739.
- Patel PJ, Hieb RA & Bhat AP. (2010). Percutaneous revascularization of chronic total occlusions. *Tech Vasc Interv Radiol*. 13(1):23-36.
- Reekers JA, Kromhout JG & Jacobs MJ. (1994). Percutaneous intentional extraluminal recanalisation of the femoropopliteal artery. *Eur J Vasc Surg*. 8(6):723-8.
- Romiti M, Albers M, Brochado-Neto FC, Durazzo AE, Pereira CA & De Luccia N. (2008). Meta-analysis of infrapopliteal angioplasty for chronic critical limb ischemia. *J Vasc Surg*. 47(5):975-81.
- Rosales OR, Mathewkutty S & Gnaim C. (2008). Drug eluting stents for below the knee lesions in patients with critical limb ischemia : long-term follow-up. *Catheter Cardiovasc Interv*. 72(1):112-5.
- Saab MH, Smith DC, Aka PK, Browlee RW & Killeen JD. (1992). Percutaneous transluminal angioplasty of tibial arteries for limb salvage. *Cardiovasc Intervent Radiol*. 15:211-6.
- Sarrafian, S. K. (1993). *Anatomy of the Foot and Ankle*. Philadelphia: Lippincott.. Pp. 294-355.
- Selvin E & Erlinger TP. (2004). Prevalence of and risk factors for peripheral arterial disease in the United States: results from the National Health and Nutrition Examination Survey, 1999-2000. *Circulation* 110(6):738-743.
- Selvin E, Marinopoulos S, Berkenblit G, Rami T, Brancati FL, Powe NR, et al. (2004). Meta-analysis: glycosylated hemoglobin and cardiovascular disease in diabetes mellitus. *Ann Intern Med*. 141(6):421-431.

- Senti M, Nogues X, Pedro-Botet J, Rubies-Prat J & Vidal-Barraquer F. (1992). Lipoprotein profile in men with peripheral vascular disease. Role of intermediate density lipoproteins and apoprotein E phenotypes. *Circulation*. 85(1):30-36.
- Serino F, Cao Y, Renzi C, Mascellari L, Toscanella F, Raskovic D, et al. (2010). Excimer laser ablation in the treatment of total chronic obstructions in critical limb ischaemia in diabetic patients. Sustained efficacy of plaque recanalisation in mid-term results. *Eur J Vasc Endovasc Surg*. 39:234-8.
- Sharma S, Kukreja N, Christopoulos C & Gorog DA. (2010). Drug-eluting balloon: new tool in the box. *Expert Rev Med Devices*. 7:381-8.
- Söder HK, Manninen HI, Jaakkola P, Matsi PJ, Räsänen HT, Kaukanen E, et al. (2000). Prospective trial of infrapopliteal artery balloon angioplasty for critical limb ischemia: angiographic and clinical results. *J Vasc Interv Radiol*. 11(8):1021-31.
- Spiliopoulos S, Katsanos K, Karanabatidis D, Diamantopoulos A, Kagadis G, Christeas N, et al. (2010). Cryoplasty versus conventional balloon angioplasty of the femoropopliteal artery in diabetic patients: long-term results from a prospective randomized single-center controlled trial. *Cardiovasc Intervent Radiol*. 33:929-38.
- Spinosa DJ, Leung DA, Hathun NL, Cage DL, Angle JF, Hagspiel KD, et al. (2003). Simultaneous Antegrade and Retrograde access for subintimal recanalization of peripheral arterial occlusion. *J Vasc Interv Radiol*. 14:1449-54.
- Spinosa DJ, Leung DA, Matsumoto AH, Bissonette EA, Cage D, Harthun NL, et al. (2004). Percutaneous intentional extraluminal recanalization in patients with chronic critical limb ischemia. *Radiology*. 232(2):499-507.
- Spinosa DJ, Hathun NL, Bissonette EA, Cage DL, Leung DA, Angle JF, Hagspiel KD, et al. (2005). Subintimal Arterial flossing with Antegrade-Retrograde Intervention (SAFARI) for Subintimal Recanalization to Treat Chronic Critical Limb Ischemia. *J Vasc Interv Radiol*. 16:37-44.
- Taylor, G. I. & Minabe, T. (1992). The angiosomes of the mammals and other vertebrates. *Plast. Reconstr. Surg*. 89: 181.
- Taylor, G. I., Corlett, R. J., Caddy, C. M & Zelt, R. G. (1992). An anatomic review of the delay phenomenon: II. Clinical applications. *Plast. Reconstr. Surg*. 89: 408.
- Taylor, G. I. & Pan, W. R. (1998). Angiosomes of the leg: Anatomic study and clinical implications. *Plast. Reconstr. Surg*. 102: 599.
- Tepe G, Zeller T, Heller S, Wiskirchen J, Fischmann A, Coerper S, et al. (2007). Self-expanding nitinol stents for treatment of infragenicular arteries following unsuccessful balloon angioplasty. *Eur Radiol*. 17:2088-95.
- Wack C, Wölfle KD, Loeprecht H, Tietze W & Bohndorf K. (1994). Percutaneous balloon dilatation of isolated lesions of the calf arteries in critical ischemia of the leg. *Vasa*. 23(1):30-4.
- Waksman R & Pakala R. (2009). Drug-eluting balloon: the comeback kid?. *Circulation: Cardiovascular Intervention* 2:352-8.
- Walsh DB, Gilberstone JJ, Zwolajk RM, Besso S, Edelman GC, Schneider JR, et al. (1991). The natural history of superficial femoral artery stenosis. *J Vasc Surg*. 14:299:304.
- Zeller T, Rastan A, Schwarzwälder U, Frank U, Bürgelin K, Amantea P, et al. (2004). Midterm Results after Atherectomy-assisted Angioplasty of Below-Knee Arteries with Use of the Silverhawk Device. *J Vasc Interv Radiol*. 15:1391-7.
- Zeller T, Sixt S, Schwarzwälder U, Schwarz T, Frank U, Bürgelin K, et al. (2007). Two-Year Results After Directional Atherectomy of Infrapopliteal Arteries With the SilverHawk Device. *J Endovasc Ther*. 14:232-40.



Angioplasty, Various Techniques and Challenges in Treatment of Congenital and Acquired Vascular Stenoses

Edited by Dr. Thomas Forbes

ISBN 978-953-51-0084-3

Hard cover, 236 pages

Publisher InTech

Published online 14, March, 2012

Published in print edition March, 2012

The field of performing transcatheter interventions to treat vascular lesions has exploded over the past 20 years. Not only has the technology changed, especially in the arena of balloon/stent devices, but the techniques of approaching complex lesions has evolved over the past decade. Lesions that no one would have imagined treating back in the 1990's are now being done routinely in the catheterization suite. This book provides an update on the current techniques and devices used to treat a wide variety of lesions. Though, at first, the outward appearance of the topics appears to be varied, they are all related by the common thread of treating vascular lesions. We hope, by publishing this book, to accomplish two things: First, to offer insight from experts in their field to treat, both medically and procedurally, complex vascular lesions that we frequently encounter. Secondly, we hope to promote increased communication between areas of medicine that frequently don't communicate, between adult interventional cardiologists, pediatric interventional cardiologists, interventional radiologists, and neurosurgeons. Much can be learned from our respective colleagues in these areas which can further our own world of interventions.

How to reference

In order to correctly reference this scholarly work, feel free to copy and paste the following:

Marco Manzi, Luis Mariano Palena and Giacomo Cester (2012). Revascularization of Tibial and Foot Arteries: Below the Knee Angioplasty for Limb Salvage, Angioplasty, Various Techniques and Challenges in Treatment of Congenital and Acquired Vascular Stenoses, Dr. Thomas Forbes (Ed.), ISBN: 978-953-51-0084-3, InTech, Available from: <http://www.intechopen.com/books/angioplasty-various-techniques-and-challenges-in-treatment-of-congenital-and-acquired-vascular-stenoses/revascularization-of-tibial-and-foot-arteries-below-the-knee-angioplasty-for-limb-salvage>

INTECH
open science | open minds

InTech Europe

University Campus STeP Ri
Slavka Krautzeka 83/A
51000 Rijeka, Croatia
Phone: +385 (51) 770 447
Fax: +385 (51) 686 166
www.intechopen.com

InTech China

Unit 405, Office Block, Hotel Equatorial Shanghai
No.65, Yan An Road (West), Shanghai, 200040, China
中国上海市延安西路65号上海国际贵都大饭店办公楼405单元
Phone: +86-21-62489820
Fax: +86-21-62489821

© 2012 The Author(s). Licensee IntechOpen. This is an open access article distributed under the terms of the [Creative Commons Attribution 3.0 License](https://creativecommons.org/licenses/by/3.0/), which permits unrestricted use, distribution, and reproduction in any medium, provided the original work is properly cited.

IntechOpen

IntechOpen