

We are IntechOpen, the world's leading publisher of Open Access books Built by scientists, for scientists

6,900

Open access books available

186,000

International authors and editors

200M

Downloads

Our authors are among the

154

Countries delivered to

TOP 1%

most cited scientists

12.2%

Contributors from top 500 universities



WEB OF SCIENCE™

Selection of our books indexed in the Book Citation Index
in Web of Science™ Core Collection (BKCI)

Interested in publishing with us?
Contact book.department@intechopen.com

Numbers displayed above are based on latest data collected.
For more information visit www.intechopen.com



Extended Applications of Endoscopic Sinus Surgery to the Orbit and Pituitary Fossa

Balwant Singh Gendeh

*Department of Otorhinolaryngology – Head and Neck Surgery
UKM Medical Center, Jalan Yaacob Latif, Bandar Tun Razak, Kuala Lumpur
Malaysia*

1. Introduction

There has been significant evolution over time from external headlight sinus surgery to endoscopic sinus surgery (ESS). ESS was pioneered by Messerklinger, who discovered that the sinuses had a predetermined mucociliary clearance pattern towards the natural ostium irrespective of additional openings into the sinuses. This philosophy of opening the natural ostium of the diseased sinus was then popularized by Stammberger and Kennedy. ESS is now accepted as the surgical management of choice for chronic sinusitis. Furthermore, as our knowledge of the anatomy of the sinuses has improved, other ancillary surgeries such as endoscopic lacrimal surgery, orbital decompression, applications to the pterygopalatine and infratemporal fossa, approaches from the sphenoid/sella extending to the cribriform, parasellar and clival region have evolved. Moreover, innovation in instrumentation has led to the acceptance of endoscopic management of benign endonasal tumors and more recently, on endoscopic management of malignant tumors of the nose and sinuses.

The current interest in ESS stems from several developments. The first is the advent of compact, multi-angled telescopes that allow excellent visualization of the nasal cavity for examination and of the sinuses during procedures, including such areas as the maxillary ostia and the frontal recess. Secondly, is the acceptance and appreciation of the great work of Messerklinger (1967) demonstrating that the anterior ethmoids are usually the key to persistent sinusitis. Thirdly, is the advent in radiological imaging. Endoscopic diagnostic examinations in conjunction with modern imaging methods, particularly CT scan, have proven to be an ideal combination and have been accepted as the ‘Standard of Care’ for sinus disease. The CT scan can clearly identify anterior ethmoid disease which can easily be missed on a plain paranasal sinus X-ray. These developments make it possible to diagnose more accurately and treat sinusitis refractory to non-invasive therapy.

The technique of ESS was developed in Europe by Messerklinger and Wigand, who had two different goals designed for extremes of disease. The Messerklinger technique advocated in 1985 is an anterior to posterior approach which involves only the anterior ethmoids and the maxillary sinus ostium and can be extended into the posterior ethmoids, sphenoid and the frontal sinus anteriorly if necessary. Thus, the Messerklinger technique is ideal for patient with anterior ethmoid disease with or without maxillary or frontal sinus disease. On the contrary, the Wigand approach advocated in 1978 is posterior-to-anterior and routinely involves all the sinuses on the ipsilateral side and is ideal for patient with pan-sinusitis who

has or is apt to fail the more limited Messerklinger approach. Both techniques are based on the assumption that the sinus mucosa is most likely reversibly diseased and will return to normal once ventilation has been established. No attempt is made to eradicate the sinus mucous membrane, as in the Caldwell-Luc procedure, but rather to reestablish drainage so the mucosa can return to normal and restore its proper function.

Although telescopes give the surgeon a clearer and magnified view of the nose and sinuses, the picture on the video monitor is not three-dimensional and depth perception and orientation can be difficult. Consequently there is a risk of getting lost and this may result in an injury to the orbit, its contents, the optic nerve and the intracranial cavity. To reduce this risk, surgeons should ensure that they are thoroughly familiar with the anatomy and the anatomical variations that can occur in the nose and sinuses. Therefore, radiological imaging is essential prior to surgical intervention.

A significant development for soft-tissue removal was the development of “through-cutting” instrumentation. Powered instrumentation using soft tissue shavers (Metronic, Xomed, USA) offer another significant advancement to the endoscopic sinus surgeon but with some risk to the orbit and cranium in inexperienced hands (Fig 1). Setliff and Parsons were the first to report the use of soft-tissue shavers in endoscopic sinus surgery (Setliff , 1994). ESS with its minimally invasive technique often reduces pain, bleeding and length of hospital stay and avoids external incision and thus reduces surgical cost compared to conventional techniques. Endoscopic surgery cannot replace every conventional external approach and we should never be embarrassed to employ or convert to these conventional approaches when necessary (Gendeh et al, 2007). However, not all cases are suitable for an endoscopic approach and the surgeon must be experienced in the full range of surgical options, the patho-physiology and natural history of disease processes, if optimum results are to be achieved. This is particularly true in the controversial area of sinonasal neoplasia.

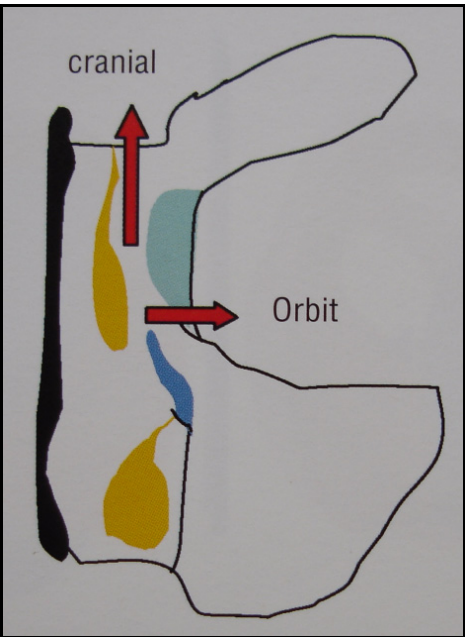


Fig. 1. Diagrammatic coronal section of paranasal sinuses showing the anatomical proximity of orbit and cranium to the nasal cavity in utilization of powered instrumentation and the risk involved.

This chapter will briefly outline the future trends in endoscopic skull base surgery. The Expanded Endonasal Approach(EEA) is a an extended endoscopic transnasal approach, providing access to the entire skull base from the epicenter, the sphenoid sinus.

It is important to define the word “endoneurosurgery” (Kassam et al, 2007). This is a new and emerging field and represents the use of the endoscope as the sole and only tool used to visualize the entire neural axis. In the case of EEA, only the endoscope is used to access the ventral skull via a completely transnasal route. As a joint team effort, this extended applications beyond the sphenoid sinus/sella needs a lot of surgical skills, planning and coordination for proper patient selection and optimal care. The EEA provides surgical access to the ventral skull base to resect a wide variety of intra-dural and extra-dural pathologies and allows the reconstruction of the resulting defect using a naso-septal flap. The evolution of these techniques has been enabled by technological advances including the design of specific endonasal instrumentation, surgical navigation technology and the development of new biomaterials for reconstruction. The incidence of tumor recurrence will be very much reduced with this minimally invasive ventral skull base technique. The use of powered instruments with navigational fusion imaging is most beneficial especially in revision cases.

2. Endoscopic dacryocystorhinostomy

Dacryocystorhinostomy(DCR) involves the formation of a bypass from the lacrimal sac into the nose. It is essential that with proper history and examination including syringing and probing, a correct diagnosis is made. Syringing and probing is performed only in congenital and acquired nasolacrimal duct obstruction (NLDO) and are indications for the procedure. They are not performed in acute and chronic dacryocystitis.

2.1 Indications (Table 1)

The main indication is when there is distal outflow obstruction to the nasolacrimal system which can clearly be demonstrated on a dacrocystogram. Endoscopic surgery is not indicated for obstruction of a punctum or a canaliculus for which there are other procedures. Often distal obstruction is mixed with varying degree of proximal obstruction and this need to be explained when counseling the patient. Syringing and probing is helpful in defining the site of obstruction. It is expected that in congenital and acquired NLDO, the epiphora would resolve and in acute and chronic dacryocystitis, the infection would be resolved without recurrences.

1.	Primary acquired NLDO
2.	Secondary acquired NLDO
	a. Infectious causes of secondary acquired lacrimal duct obstruction
	b. Inflammatory causes of secondary lacrimal obstruction
	c. Neoplastic causes of lacrimal obstruction
	d. Traumatic causes of lacrimal obstruction
	e. Mechanical causes of lacrimal obstruction

Table 1. Indications for Endonasal DCR(EDCR)

A dacrocystogram (Fig 2) is indicated if there is any mass within the sac and scintigraphy helps to define a functional problem. A functional problem is one issue for which a dacryocystogram is helpful. Lacrimal sac mass is another indication for dacryocystogram. A bloody discharge from the punctum is a symptom that needs investigating to exclude malignancy in the sac. The common symptoms are epiphora, recurrent dacryocystitis or swelling from a mucocele. It is unusual for intranasal pathology like Wegener granulomatosis and sarcoidosis to be the causative factor. Nasolacrimal duct obstruction can occur following a middle-third facial fracture. Distal nasolacrimal obstruction can be secondary to endoscopic sinus surgery if the Stammberger Rhinoforce Antrum Punch (Stortz, Germany) used to remove the uncinate process is placed too far forward.

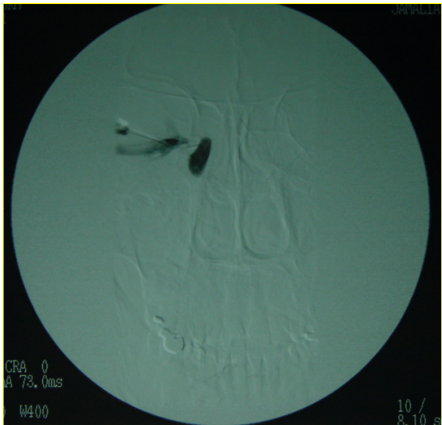

Fig. 2. A dacrocystogram showing distal obstruction of right nasolacrimal system on failure of penetration of dye into the inferior meatus in a patient with unilateral unresolving tearing.

2.2 Contraindications (Table 2)

A contraindication to DCR is the presence of a benign or malignant lesion in the lacrimal system or the surrounding tissues and active Wegener granulomatosis. Other causes are lacrimal sac diverticulum,, canalicular stenosis, lacrimal calculi and extensive midfacial trauma.

1.	Known or suspected lacrimal system neoplasm
2.	Large lateral lacrimal sac diverticulum
3.	Common canalicular stenosis
4.	Lacrimal system stones
5.	Extensive midfacial trauma

Table 2. Contraindications for Endonasal DCR(EDCR)

2.3 Anatomy and pre-operative assessment

The lacrimal system comprises the lacrimal gland and its drainage system which commences with a punctum in each eyelid for 1mm at right angles to the lid margin. It continues as the upper and lower canaliculus which run parallel to the lid margin and then join to form a common canaliculus that drains into the lacrimal sac (Fig 3). Inferiorly the sac forms the nasolacrimal duct, which drains into the inferior meatus about 1cm posterior to

the anterior end of the inferior turbinate (Fig 4). The lacrimal sac sits in the lacrimal fossa which is a very thin bone. Unlike its anterior margin, the anterior lacrimal crest, is made of very dense bone. In about 8% of patients, an anterior ethmoidal air cell lies medial to the lacrimal fossa which needs to be transverse before a rhinostomy can be created.

Topical anesthetic drops such as amethocaine are placed in the eye followed by dilatation of the upper and lower puncta performed with punctual dilator. The puncta are initially dilated with the instrument perpendicular to the lid margin, rotating it for the first 1 mm with the lid margin taut, before turning it medially parallel to the lid. Upon dilatation of the punctum, a “0” Bowman probe is passed through the dilated punctum and angled medially. As the probe enters the common canaliculus, a slight resistance may be felt as a “soft stop” and as it touches the medial wall of the sac, there is a “hard stop”. The probe is then angled vertically down to feel whether there is any sac pathology or distal obstruction. This is a description for probing in children, which is preferably performed under general anaesthesia. It is avoided in adults because of the intolerable pain. Rigid 0.7 mm dacryocystoscopes can be used to inspect the fine obstructing membranes that can be found at the medial aspect of the upper and lower canaliculi (Wormald, 2002). These proximal membranes are the main cause of proximal obstruction, and a DCR is not indicated if this is the site of the obstruction. For surgeons becoming familiar with intranasal anatomy or a history of previous sinonasal surgery, it may be helpful to introduce a 20-gauge fiberoptic endoilluminator(Stortz, Germany) through the superior or inferior canaliculus after punctual dilator. The endoilluminator is then advanced gently until a hard stop signifying the lacrimal bone is identified (Woog, 2004). The location of the lacrimal sac may then be visualized endoscopically by transillumination (Fig 5 a, b).

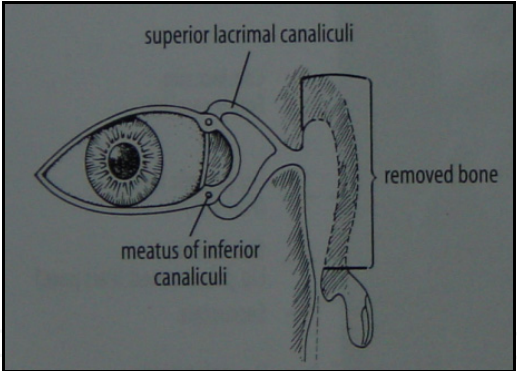


Fig. 3. Diagrammatic anatomical picture of nasolacrimal drainage system

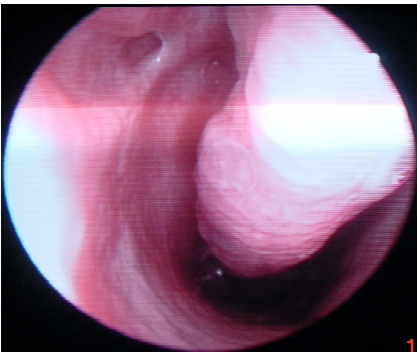


Fig. 4. Endoscopic view of a right nasolacrimal duct opening into an inferior meatus

Distal obstruction is diagnosed by probing and then syringing to see whether the fluid can initially pass through the canaliculi into the nose. If it refluxes through the other punctum, it indicates that there is distal obstruction. On the contrary, if there is reflux through the same punctum, then there is canalicular or common canalicular stenosis and this can be confirmed by gentle probing. There are many causes of dysfunction that requires a different treatment than DCR. The most common site of distal obstruction is where the sac becomes the duct. Some surgeons will offer a DCR to patients with a functional blockage where there is free flow on syringing but on scintigraphy the pump system does not work. Only 70-75% of the tears are drained through the inferior canaliculus. Lester-Jones Pyrex tube is required only in bi-canalicular extensive obstruction that cannot be managed by other procedures such as forced probing and silicone intubation.

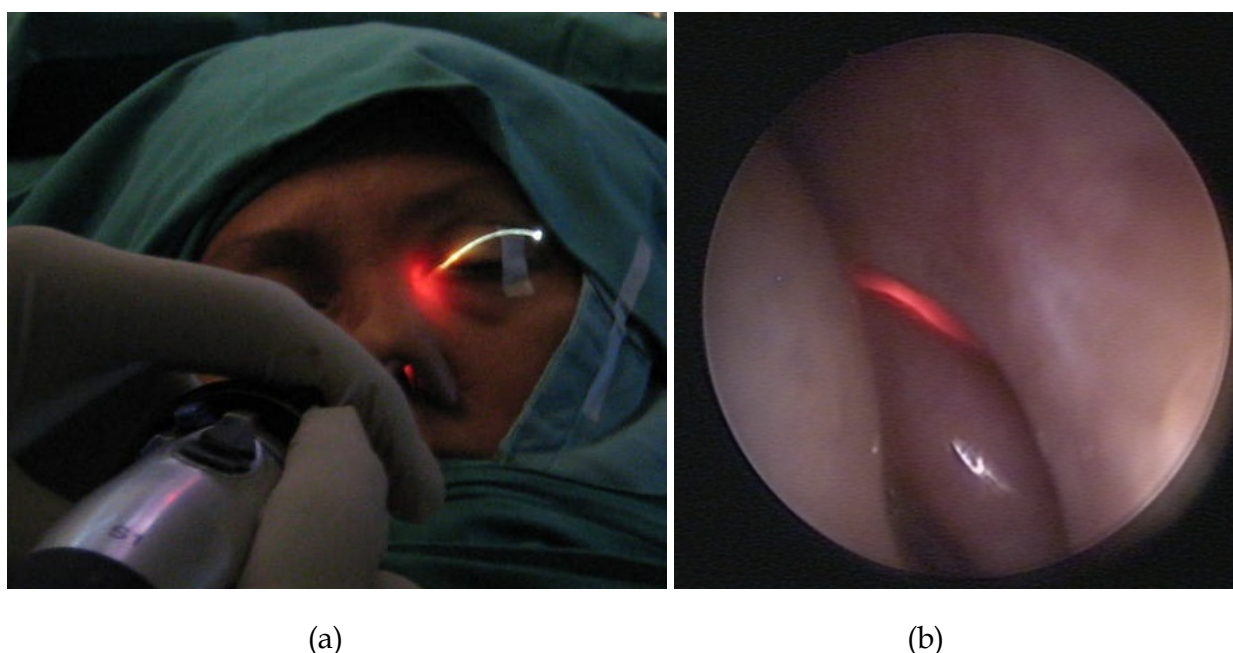


Fig. 5. A picture showing a fiber-optic endoilluminator being introduced via the left inferior cannaliculus to illuminate the nasolacrimal sac(a) and a zero degree endoscopic view identifying the location of the illuminated lacrimal sac(b) in the same patient.

2.4 Surgical technique

Upon nasal decongestion with neopatties and infiltration with lidocaine and adrenaline, a 15 scalpel blade is used for initial mucosal incisions. The first incision is made horizontally 1 cm above the axilla of the middle turbinate, commencing 3 mm posterior to the axilla and coming forward 1 cm onto the frontal process of the maxilla. The blade is then turned vertically and incision made about two thirds of the vertical height of middle turbinate, stopping just above the insertion of the inferior turbinate into the lateral nasal wall. The blade is then turned horizontally and the inferior insertion commenced at the insertion of the uncinat process and brought forward to meet the vertical incision.

A suction Freer's dissector (Stortz, Germany) is used to elevate the mucosal flap, ensuring that the tip of the sucker always maintains contact with the bone. Meanwhile the bone should be palpable so that the junction of the soft lacrimal bone and hard bone of the frontal process can

be identified. The thin lacrimal bone is 2 to 5 mm wide before the insertion of the uncinate process is reached. The dissection stops at the uncinate. A round knife (Stortz, Germany) is used to flake the soft lacrimal bone away from the postero-inferior region of the sac.

A forward-biting Hajek Koeffler punch (Stortz, Germany) is used to remove the lower portion of the frontal process of the maxilla (Fig 6). The tip of the punch is used to push the lacrimal sac away where the lacrimal bone has to be removed. The punch is engaged in the hard bone of the frontal process and this bone is removed. Care should be taken not to grasp the sac as the punch is closed during bone removal. Removal of the frontal process of the maxilla uncovers the antero-inferior portion of the lacrimal sac. Bony removal with punch is continued as far superiorly as possible until the bone becomes too thick for the punch to engage. At this juncture the 15 degree curved 2.9 mm rough diamond burr (Medtronic Xomed, Jacksonville, Florida, USA) is attached to the micro-debrider and used to remove the rest of the bone up to the superior mucosal incision (Jones, 1998). Often, an agger nasi cell is present and the mucosa of this cell will be exposed as the sac is followed superiorly above the axilla of the middle turbinate thus exposing the frontal recess (Fig 7). The diamond burr can be brought into light contact with the lacrimal sac lining without damaging the sac. A cutting burr will remove the bone faster but may cause significant damage to the sac wall with development of hole in the sac wall.

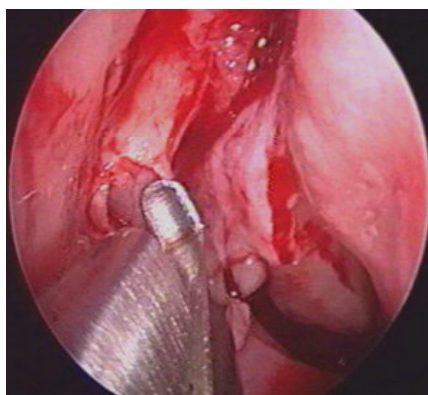


Fig. 6. Intraoperative endoscope view showing right dacryocystorhinostomy with initial removal of the thin lacrimal bone with Hajek Koeffler sphenoid punch and subsequently the hard frontal process of maxilla with a microdrill

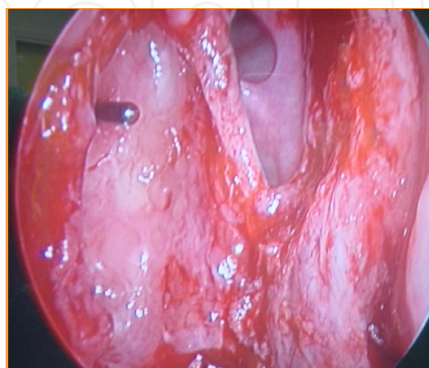


Fig. 7. Intraoperative endoscopic view showing a right dacryocystorhinostomy with wide exposure of the nasolacrimal sac with visible end of eye probe and removal of agger nasi cell exposing the frontal recess

Next, the inferior punctum is dilated with a punctum dilator and a Bowman's canalicular probe is passed into the sac. If the tip of the probe is not seen to move behind the thin sac wall, the probe is not in the lumen. The exposed sac is incised vertically with a DCR minisickle knife (Metronic Xomed, USA). Belucci scissors (Storz, Germany) are used to make upper and lower releasing incisions in the posterior flap which is rolled out on the lateral nasal wall. The sac should now be completely marsupialized and lie flat on the lateral nasal wall. Approximating the lacrimal and nasal mucosa should result in a first intention healing rather than a secondary intention healing and should reduce the formation of granulation tissue and scarring. The puncta are dilated and Silastic lacrimal intubation tubes (O'Donoghue tubes) are placed through the upper and lower puncta and retrieved endonasally. Ligar clips are placed to secure the tubes in place (Fig 8). Before placing the clips ensure a loop of tubing is pulled in the medial canthus of the eye so that the tubes are not tight. If the loop is tight the tubes can cheese-wire through the punctum (Khairullah and Gendeh, 2011). A square of Gelfoam (Pharmacia NSW, Sydney, Australia) or Merogel (Metronic Xomed) is slid up the tubing and placed over the flaps to hold them in position.

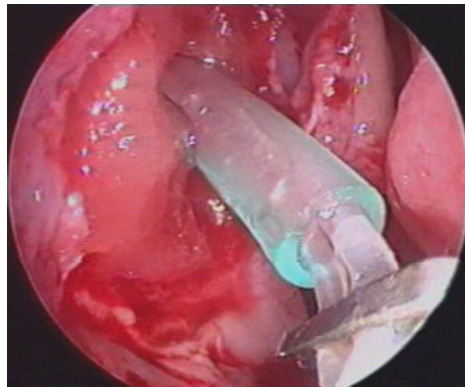


Fig. 8. Intraoperative endoscope view showing right dacryocystorhinostomy with stent in situ an adult patient presenting with unresolving right tearing.

Saline irrigation is started within 3 to 4 hours of surgery. The patient is commenced on broad spectrum antibiotics for 5 days and eye drops are used for 3 weeks. The O'Donoghue tubes are removed in the clinic after 4 weeks. It is rare to see any granulation tissue but if they are present they should be removed. The patient is reviewed for a further 18 months before discharge.

2.5 Laser assisted DCR

For osteotomy, laser was used exclusively in the early part of the series in 1992 and 1993. The preferred site for osteotomy was the thinnest bone located in the infero-posterior parts of the lacrimal fossa, which corresponds to the brightest area in the nasal cavity as demonstrated by the transilluminator. The authors concluded that the success rate of laser-assisted DCR was around 78%, which was much lower than that of conventional DCR. Beginning in 1999 and 2000, osteotomy was performed with either a drill, a punch, or both, which enabled removal of thicker bone. The site of the osteotomy was moved to the level of medial canthus, which was anterior and superior to that of previous surgeries. When the osteotomy was completed, the common internal punctum was visible on endoscopy. With this approach, the success rate improved to 92% (Lee et al, 2004).

In another interesting study in 65 patients with a mean follow-up of 74 months, the authors found the success rate of endoscopic laser assisted DCR has gradually declined over the years to 56%. The authors do not advocate the use of laser in endonasal DCR with epiphora (Umapathy et al, 2006).

3. Endoscopic applications in orbital surgery

3.1 Endoscopic blow out fracture repair

Fractures of the roof of the maxillary sinus with herniation of the orbital content (blow-out fracture), often produce strangulation of the inferior rectus or inferior oblique muscles and thereby impairing movement of eyeball (Fig 9). They can present with periorbital ecchymosis and subconjunctival hemorrhage. Those with fracture of medial wall of orbit without prior surgical intervention can present with enophthalmos.

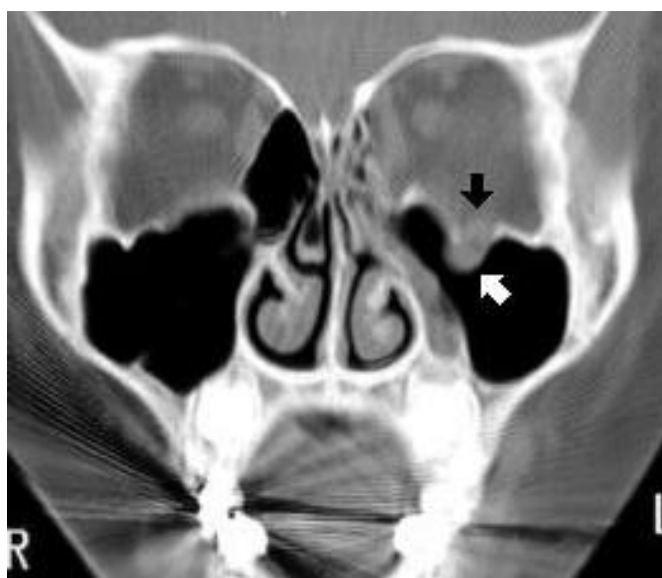

Fig. 9. Coronal CT scan of the paranasal sinuses showing a 'tear drop' sign resulting from a blunt trauma to the left eye in a patient presenting with diplopia

Passage of the endoscope through the intranasal maxillary antrostomy may provide superb visualization of the posterior orbital floor which is the most difficult area to view by transconjunctival or subciliary approach. Anatomically, this area of the orbital floor commonly lies behind the middle half of the globe on axial view. This posterior view may furthermore be obscured because the orbital floor angulates 15 degrees superiorly as one proceeds from the orbital rim toward the orbital apex. Therefore, the endoscope is an extremely useful means of safely and definitely identifying the posterior edge of the defect and ensuring that the posterior edge of the orbital implant do not compromise the optic nerve or other structures at the orbital apex (Hartstein et al, 2004). In many small fractures for which an implant is not required, endoscopic examination and reduction may be sufficient, thus avoiding an external incisional approach.

It is doubtful that endoscopy alone will replace standard CT scanning in the evaluation of orbital fractures. Thus, combining forced duction testing with endoscopic visualization of a fracture may prove to be useful diagnostic tool.

3.1.1 Indications

This include fractures with extension to the middle and posterior portions of the orbital floor, in delayed or secondary fracture repair.

3.1.2 Surgical technique

Orbital fracture repair is normally performed using general anaesthesia. Some author's have reported the use of purely endoscopic approach for the repair of orbital floor fracture (Ikeda et al, 1999). The procedure is commenced by enlarging the maxillary ostium and then introducing an angled endoscope. Bony fragmenst in the fracture site are removed endoscopically until an improvement in forced duction testing is noted. Subsequently, a urethral balloon catheter is introduced through the ostium into the maxillary sinus. In some patients with trap-door-type fractures, successful fracture repair may be possible with endoscopic approach alone, with removal of the displaced bony fragment and relieve of the entrapment. Saline is used to inflate the balloon which elevates the contents out of the fracture site. The balloon is removed approximately two weeks after surgery.

Tips for successful surgery

Endoscopic visualization of fractures of the posterior aspect of the orbital floor and medial orbit may facilitate safe and secure implant placement and ensures that no residual orbital soft tissue is entrapped within the fracture site or beneath the implant. The endoscopic technique minimizers the uncertainty of implant placement posteriorly in both primary and secondary repairs. It may help to minimize the number of additional incisions required in the medial orbit, maxillary sinus and even the eyelid. The increased accuracy of implant placement may help to reduce the risks of residual exophthalmos postoperatively. This technique is useful in the more complex fractures involving the posterior orbital floor and medial wall.

3.2 Endoscopic orbital decompression of complications of thyroid-related orbitopathy

Graves' disease is an autoimmune disorder affecting the thyroid, orbit and skin. Approximately 50% of patients with this disorder develop orbital manifestation of dysthyroid orbitopathy. Fewer than 5% of such patients have disease that is severe enough to require surgical decompression of the orbit (Metson and Samaha, 2004). The extensive muscle enlargement limits globe movement in extremes of gaze which will cause diplopia. Visual loss in Grave's disease is uncommon, occurring in only 2 to 7% of patients (Kountantakis et al, 2000; Kuppersmith et al, 1997). Exophthalmos in Grave's disease is thought to result from the deposition of immune complexes in the intraocular mucle and fat which in turn leads to edema and fibrosis (Tandon et al, 1994). The resultant increase in intraorbital pressure pushes the globe forward causing proptosis. If this proptosis become severe enough, the eyelids cannot close properly and chemosis with or without exposure keratitis of the cornea may occur. Furthermore, the crowding of the orbital apex by the obviously enlarged extraocular muscles places pressure on the optic nerve. Stretching of the optic nerve by increasing proptosis may result in the development of optic neuropathy and visual loss. If medical treatment fails (high dose steroids with or without low-dose radiotherapy) , surgical decompression of eyelid is indicated(Cook et al, 1996).

Removing one or more of the bony walls can decompress the contents of the orbit. The least amount of decompression would be achieved with medial wall removal, but the most physiologic and least to cause complications like globe displacement and diplopia. Endoscopic orbital decompression affords maximal orbital decompression at the orbital apex, an area that is not fully accessible via the external or transantral routes (Metson et al, 1994). Many techniques have been described for decompressing the orbit but the order of the procedures is that orbital decompression first, then strabismus and lastly the eyelid.

3.2.1 Indications and contraindications

The primary indication for the surgery is exophthalmos, either for cosmetic reasons or when vision is deteriorating and steroids and radiotherapy treatment has failed. The most common indications for such surgery are exposure keratopathy and optic neuropathy that have been refractory to conservative measures. Patients with diplopia from dysthyroid orbitopathy may require decompression before strabismus surgery to reaccess the globe and improve the predictability of muscle adjustments. Some surgeons who consider aesthetically undesirable proptosis to be an indication for orbital decompression have performed such surgery for its cosmetic benefits.

Contraindications to endoscopic orbital decompression include acute sinusitis and anatomic abnormalities of the maxillary bone. Endoscopic decompression may be technically difficult in patients with very small maxillary sinuses or thick orbital walls. These features are easily identified on computed tomography(CT) scan of the orbit and sinuses, which should be obtained on all patients before surgery.

3.2.2 Useful instruments

- A long-shanked drill with a coarse diamond burr (Medtronic Xomed, Jacksonville, Florida, USA) and good irrigation system to keep the bone cool.
- Image guided surgery

3.2.3 Endoscopic technique

The patient is placed in a supine position with head slightly elevated. Packing that has been soaked in a 4% cocaine solution is placed in the nasal cavity to initiate mucosal vasoconstriction. Both eyes are exposed in the surgical field. If general anaesthesia is used, the corneas are covered with protective shells. Under endoscopic visualization, submucosal injections of 1% lidocaine with epinephrine are administered along the lateral nasal wall and middle turbinate. If a septal deviation precludes endoscopic access to the middle meatus region, a septoplasty is performed before orbital decompression.

The bones removed in endoscopic decompression include the medial wall of the orbit and the portion of the floor that is medial to the infraorbital canal. The procedure is initiated with an incision through the uncinate process. This incision is made just posterior to the maxillary line, a bony eminence that extends from the anterior attachment of the middle turbinate to the root of the inferior turbinate(Fig 10). The maxillary sinus ostium is then generously enlarged to provide optimal exposure of the orbital floor to prevent obstruction of the maxillary sinus by the decompressed globe. Bone is removed in the posterior

direction to the level of the back wall of the sinus. Anterior removal is terminated at the thick bone of the frontal process of the maxilla, which protects the nasolacrimal duct. The ostium is enlarged superiorly to the level of the orbital floor and inferiorly to the root of the inferior turbinate. A 30-degree endoscope is used to identify the infraorbital nerve along the roof of the sinus (Fig 11).

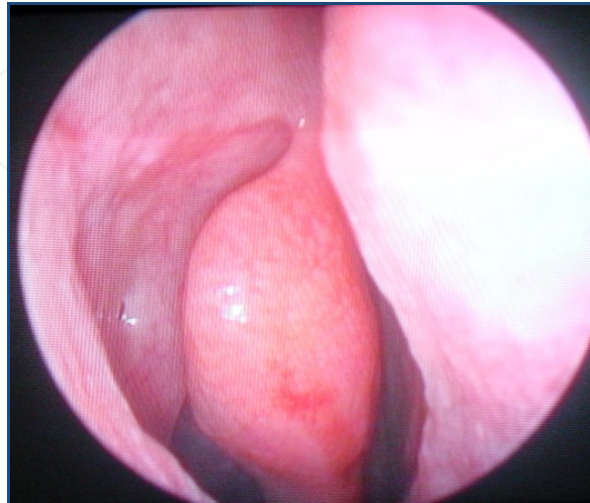


Fig. 10. A zero degree endoscopic view of left lateral nasal wall showing the maxillary line and uncinate process

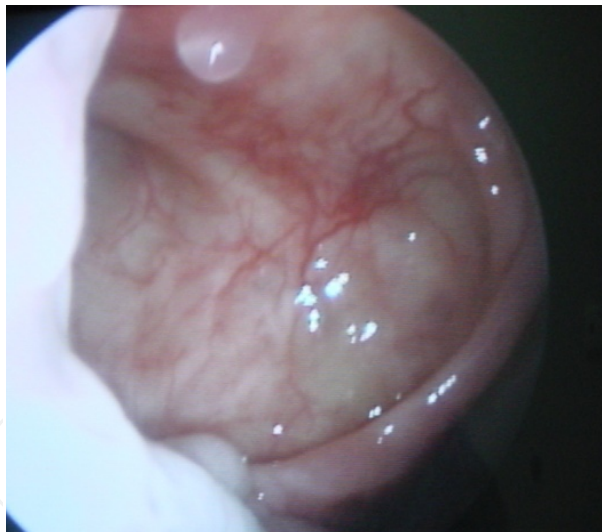

Fig. 11. A 30 degree endoscopic view showing evidence of wide right middle meatal antrostomy with infraorbital indentation in the roof of the maxillary sinus

An endoscopic sphenoidectomy is then completed as described by Stammberger (1991) and Kennedy (1985). The degree of pneumatization of the sphenoid determines whether the optic nerve indents or even dehiscent in its lateral wall. Similarly, if the posterior ethmoid sinuses envelop the optic nerve before it reaches the sphenoid sinus, an Onodi cell may be present (Fig 12). The anterior and posterior ethmoid arteries are identified along the ethmoid roof. The middle turbinate that serves as a landmark during the sphenoidectomy is removed before opening the lamina papyracea to optimize

exposure to the medial orbital wall and facilitate postoperative cleaning. The skeletonized lamina papyracea is gently penetrated with a small spoon curette. Bony fragments of lamina papyracea is lifted in a medial direction to avoid perforation of the underlying periorbita. This elevation may also be performed with a periosteal elevator or delicate Blakesley forceps(Stortz, Germany). If surgery is performed using local anaesthesia, additional injections may be necessary to desensitize the medial orbital wall. Anaesthetic agent is injected just deep to the periorbita through the bony opening in the lamina.

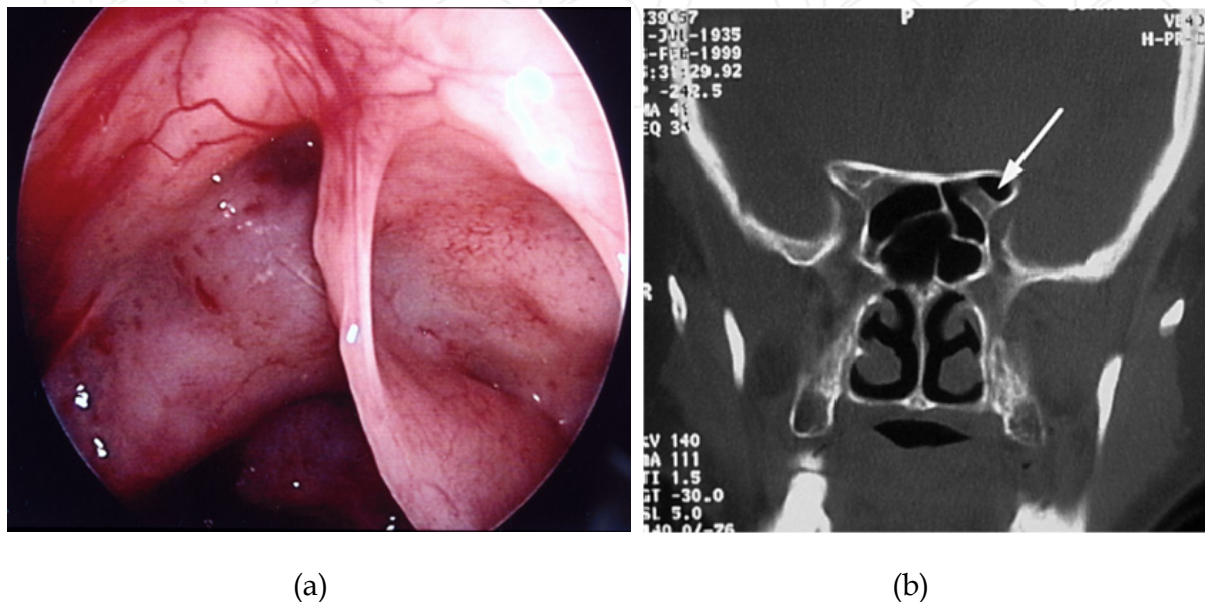


Fig. 12. An intra-operative endoscopic view (a) and coronal CT scan view (b) showing an Onodi cell

Bone of the lamina papyracea is removed in a superior direction toward the level of the ethmoid roof. The frontal recess is the most anterior superior portion of the ethmoid sinus, which communicates with the frontal sinus. Removal of the lamina papyracea in this region can cause postoperative obstruction of the frontal sinus by herniated fat. As dissection continues in a posterior direction toward orbital apex, thicker bone and underlying periorbita are generally encountered within 2 mm of the sphenoid face. This thickening represents the annulus of Zinn, from which the extra ocular muscles(EOMs) originate and through which the optic nerve passes (Fig 13). This landmark represents the posterior limit of dissection and does not need to be removed. In cases of neuropathy, bone removal proceeds more posteriorly and may extend to the lateral wall of the sphenoid sinus.

Fragments of bone are cleared from the anterior end of lamina papyracea where it joins the lacrimal bone. Dissection in this region may be facilitated by use of an angled spoon curette and 30-degree endoscope (Stortz, Germany). The thick white fascia of the lacrimal sac may be uncovered but should not be opened. Firm bone anterior to the maxillary line protects most of the sac, so it should not be removed. Removal of the bone along the medial orbital floor can be most technically challenging aspect of this surgery. A spoon curette is used to fracture the bone in a downward direction. This bone may break apart in several small fragments with a natural cleavage plane along the infraorbital canal. Use of a 30-degree endoscope may facilitate visualization within the maxillary sinus and aid in the identification of the infraorbital nerve which serves as the lateral limit of bone removal.

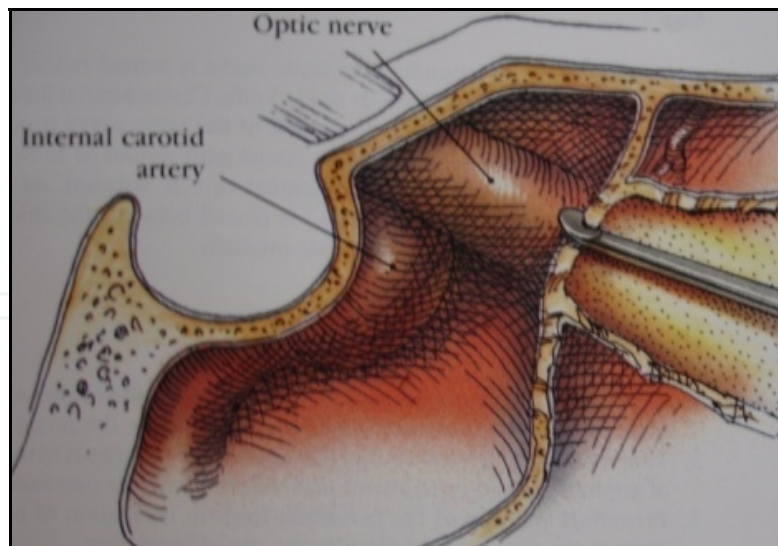


Fig. 13. A diagrammatic sagittal section of left sphenoid and posterior ethmoids showing the thick bone at the annulus of Zinn at the junction of the orbital apex and sphenoid sinus

After the periorbital has been fully exposed and cleared of bony fragments, it is opened with a sickle knife (Storz, Germany). The incision is usually commenced in front of the sphenoid sinus. Care is taken to keep the tip of the blade superficial to avoid injury of the underlying orbital contents especially the medial rectus muscle, which may be enlarged secondary to dysthyroid orbitopathy. Incision of the periorbital is extended along the ethmoid roof and the orbital floor. A horizontal strip of periorbital overlying the medial rectus muscle is preserved (Fig 14). This fascial sling serves to decrease prolapsed of the muscle and is thought to reduce the incidence of postoperative diplopia (Metson and Samaha, 2002). However, in patients with optic neuropathy, maximal decompression is needed and the fascial sling is sacrificed to allow for wider excision of the periorbital which is removed eventually with angled Blakesley forceps. At the completion of the procedure, the generous prolapsed of the orbital fat into the opened ethmoid and maxillary sinuses should be observed (Fig 15)

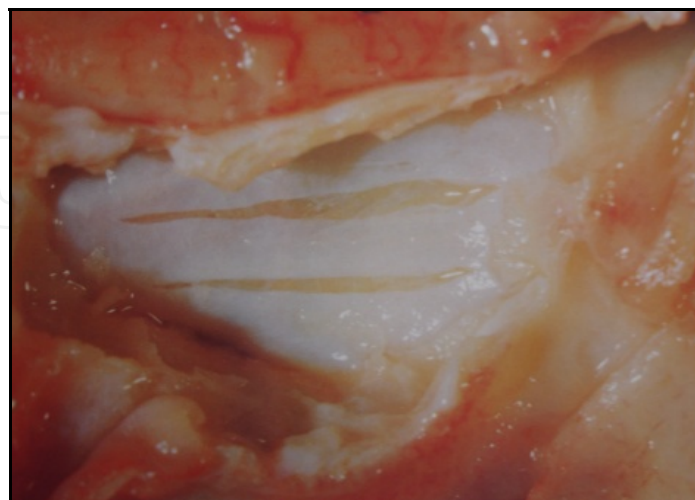


Fig. 14. A 70 degree endoscopic view showing an emergency horizontal orbital decompression incisions of the periorbital extending from the ethmoidal roof to the orbital floor for thyroid related orbitopathy

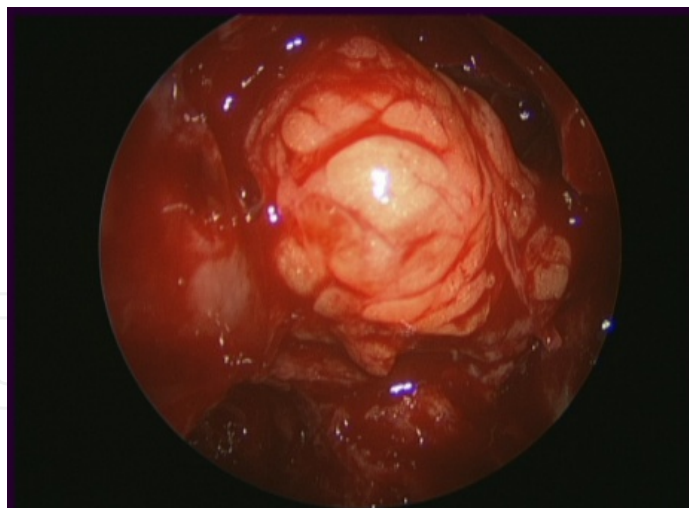


Fig. 15. A 30 degree endoscopic view showing prolapsed of orbital fat into the nasal cavity on balloting the right eye

A lateral orbital decompression may be performed at this time, depending on the extent of patient's disease and the degree of additional decompression desired. Due to the prior medial decompression, the orbital contents are easily retracted in a medial direction to provide excellent exposure of the lateral bony wall, which is removed or contoured. Concurrent excision of excess intraconal fat may also be performed if necessary. Bilateral orbital decompressions may be performed concurrently or as a staged procedure.

Nasal packing is avoided in order to prevent compression of the optic nerve, which is rendered increasingly vulnerable by the decompression. The patient is discharged the morning after surgery with a prescription for oral antibiotics and instructions to begin twice-daily nasal saline irrigations with a bulb syringe. During postoperative visit a week later, residual debris is cleared from the nasal cavity under endoscopic guidance.

In some cases, local anaesthesia may be preferred to general anaesthesia. These situations include patients who have an only-seeing eye, significant medical comorbidity, or a strong preference for local anaesthesia.

The use of local anesthetic enables the surgeon to monitor the patient's vision on a continuous basis during the surgery and reduces the likelihood of occult injury to the optic nerve (Metson et al, 1994). Ideal sedation is achieved with intravenous bolus of propofol, 0.4 to 0.8mg/kg, administered before local injection, followed by maintenance infusion of 95 to 75 ug/kg during the procedure. Submucosal infiltration of 1% lidocaine with epinephrine 1:100,000 is performed exactly as described for the procedure utilizing general anaesthesia. Patients may report discomfort during removal of the lamina papyracea, and this may require a small additional infiltration of anaesthetic solution into the periorbita.

3.2.4 Complications

Diplopia is a relatively common sequela of endoscopic orbital decompression reported in 15 to 30 % of postoperative patients. This complication can be the result of change in the vector of pull of the EOMs. Diplopia that is present preoperatively is usually not improved by this surgery. Patients with preexisting or new-onset post-operative diplopia frequently require

strabismus surgery. It is essential that all patients be informed of the possibility of postoperative double vision before undergoing orbital decompression.

Techniques to decrease the incidence of new-onset postoperative diplopia, including the preservation of the fascial sling of periorbita to prevent prolapsed of the medial rectus muscle, have been mentioned (Metson and Samaha, 2002). To decrease the incidence of postoperative diplopia, the use of balanced decompression technique is advocated. This technique involves performing external lateral wall decompression at the time of endoscopic medial wall decompression to reduce pressure on the medial rectus muscle while simultaneously increasing the degree of ocular recession.

Postoperative bleeding after endoscopic orbital decompression is managed by direct cauterization of the bleeding site. Nasal packing is avoided in these patients to avoid pressure in the region of the optic nerve. The incidence of sinonasal infection post-surgery is minimized with the routine use of postoperative antistaphylococcal antibiotics.

Postoperative epiphora may occur if the nasolacrimal duct is transected during the maxillary antrostomy. This complication is readily treated with an endoscopic DCR. Blindness and cerebrospinal fluid rhinorrhea are also potentially serious complications of orbital decompression but rare.

Endoscopic orbital decompression should be performed only by surgeons with extensive experience in endoscopic intranasal techniques. A team approach, which uses the skills of both an Otolaryngologist and an Ophthalmologist during the performance of this procedure is highly recommended.

Tips for successful surgery

Orbital decompression for thyroid-related orbitopathy is an effective method for reduction of proptosis for cosmetic proptosis, eye complications from exposure of the cornea and visual loss. The amount of regression of proptosis is related to the number of walls removed during surgery. It is believed that three-walled decompression may give a more balanced decompression with less likelihood of postoperative diplopia.

3.3 Endoscopic orbital decompression for acute orbital hemorrhage

The procedure of choice is lateral canthotomy and inferior cantholysis with of course cold dry compresses as tolerable. This is performed for 'orbital compartment syndrome' due to orbital bleeding, emphysema or tumor. For orbital decompression, lateral canthotomy alone is not sufficient and the inferior eyelid should be completely free to allow anterior displacement of the globe. Drainage of any kind is only indicated if this is not helpful. The problem with drainage is that the bleeding is diffuse and not confined to one compartment. Endoscopic drainage is actually performed to remove adjacent orbital wall and open the periosteum to allow decompression of orbital soft tissues. It is important to note that the same can be achieved with the faster canthotomy and inferior cantholysis.

Invariably the anterior ethmoidal artery(AEA) can be located one cell behind the frontal recess(Fig 16 a, b). The size of the so called supra-orbital cell (Bolger & Mann, 2001) varies: it can be small or large. The AEA can often be seen on CT scan, (Fig 10) particularly as it enters

the orbit where it produces a fluted defect in the lamina papyracea(LP). The more pneumatized the supra-orbital recess, the more vulnerable it is to damage. Often the ethmoidal bulla (EB) attaches to the skull base and the AEA lies within the roof and is 1-2 mm behind the attachment of the anterior wall of the EB to skull base. If the frontal recess (FR) does require opening, it is best approached anteriorly, away from AEA if the landmarks are poor owing to previous surgery or bleeding. As the AEA is sometimes dehiscent, it is advisable not to grasp polyps in this area if one is unable to identify the anatomy clearly. Often the FR can be found by following the intact anterior wall of the ethmoidal bulla superiorly.

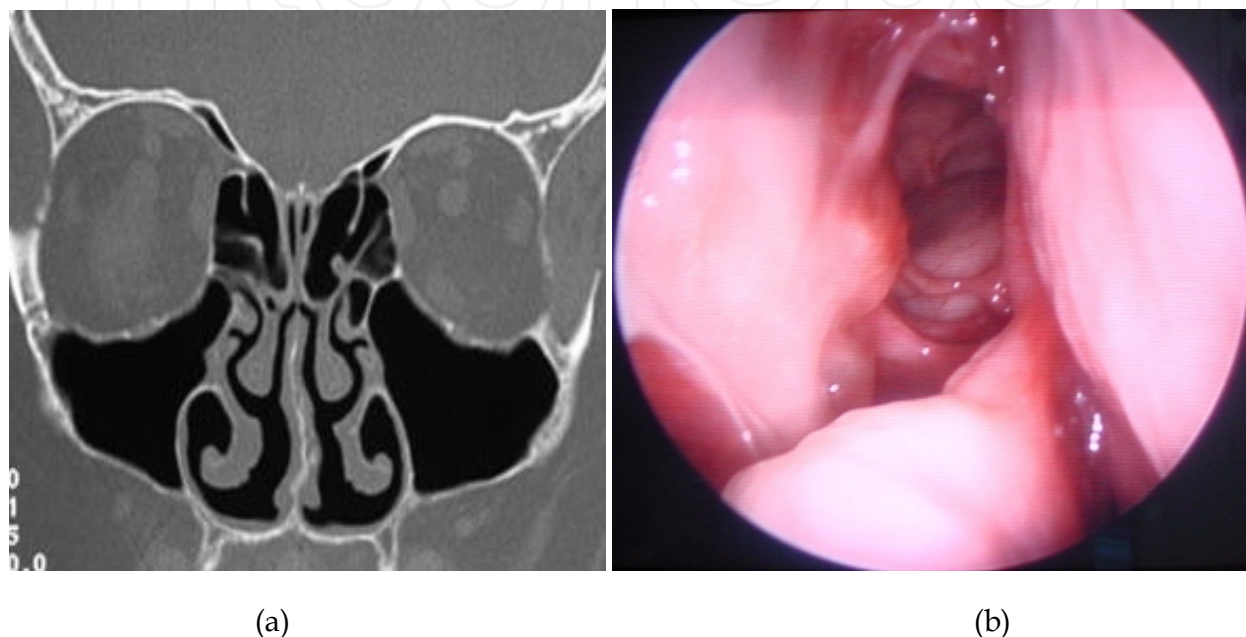


Fig. 16. A coronal CT imaging showing an indentation of right anterior ethmoidal artery at the region of frontal recess (a) and a 70 degree endoscopic view showing indentation of the artery in the same patient(b).

The AEA is dehiscent at some point in the majority of patients (Lang, 1989). It is essential to avoid tearing it for it can cause marked bleeding. If it is transected and retracts into the orbit, a marked increase in pressure in the posterior compartment of the eye can occur and place the retinal artery and its supply to the retina at risk. If it is torn, gentle bipolar diathermy will arrest the bleeding but this should be performed with great care to avoid transecting the remaining segment of the artery.

3.3.1 Bleeding

If there is obvious bleeding into the posterior compartment of the eye, the eye will prop out, the orbit will become very firm and within a few minutes the swinging flash light test will reveal an afferent defect. An awake patient will complaint of discomfort and loss of vision. An orbital tourniquet should be tried on immediate recognition. This involves placing a cotton wool over the closed eyelid and applying an orbital tourniquet over the cotton wool and around the head and then inflating it to systolic pressure. This is performed for one minute and then it should be removed and the pupil reflexes and/or the vision checked. If

the vision or pupil reflex has improved, the orbital tourniquet should be reapplied and the process repeated every minute for up to 5 minutes. If this is performed soon after injury, it may be sufficient to stop bleeding into the orbit and it can arrest the process.

It is advisable to monitor vision for 6 hours postsurgery to ensure that no further bleeding occurs into the posterior compartment. If this maneuver fails then the orbit must be decompressed. A lateral canthotomy and inferior cantholysis is quick and efficient technique for up to one hour and it is best to decompress the orbit as early as possible (Jones, 1997). Moreover, one should not wait for an ophthalmological colleague to arrive unless they do so within an hour. Assessing the vascular supply of the retinal vessels with an ophthalmoscope is inadequate.

3.3.2 Lateral canthotomy and inferior cantholysis

Local anesthetic is placed around the lateral canthus of eye and it is divided using small straight scissors down to the bone of the orbital rim and to the depth of the lateral sulcus of the conjunctiva. A corneal abrasion or conjunctival damage can be avoided by protecting the globe. The lower lid is then retracted downward for good expose. The scissors is angled at 45 degree to the horizontal axis and the lateral ligament and septum is divided and the globe and contents of the orbit will then prolapse forward (Fig 17). The pupil reflexes, the pressure of the orbit and vision should all be checked. The orbit will retract to its normal position over the next 2-3 days. Suturing is usually performed a week or so after the procedure.

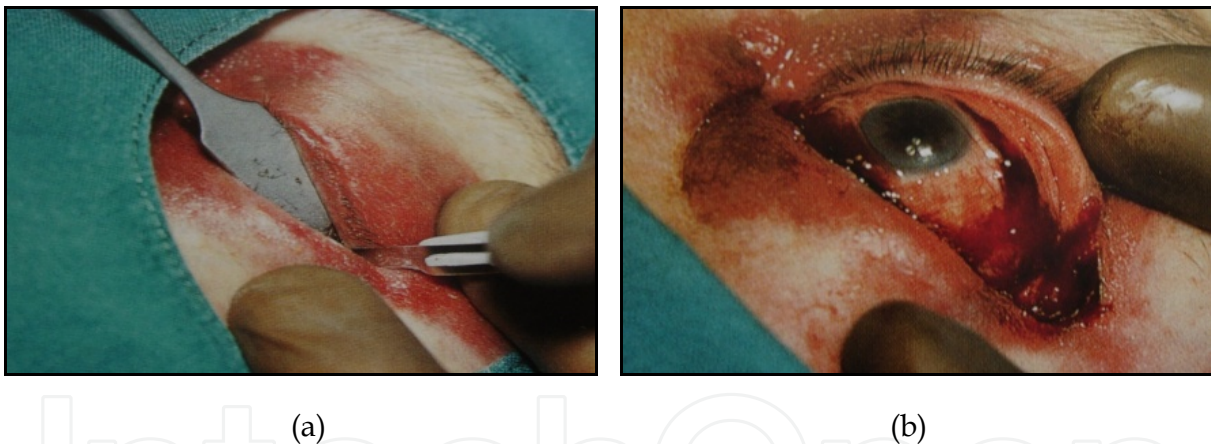

Fig. 17. Picture showing an emergency left lateral canthotomy (a) and subsequent cantholysis (b) being performed in the same patient for iatrogenic orbital hemorrhage

This procedure is normally sufficient to decompress the posterior compartment of the eye. If inadequate a surgical decompression should be undertaken. It can be done either endoscopically by removing the LP widely and incising the orbital periosteum or externally via a Lynch-Howarth incision. Preserving vision takes priority over producing an external scar. If the orbit is decompressed by an external approach, the AEA will not be found as it will have retracted into substance of the orbit.

3.3.3 Medial rectus damage

Medial rectus damage occurs when there is disinsertion of the muscle, damage to the muscle nerve or intramuscular bleeding. In damage encountered during endoscopic sinus

surgery, a vigilant assistant should look out for movement of the globe which occurs unintentionally. As a precautionary measure, the assistant should repeatedly ballot the eye when the surgeon is operating on the lateral nasal wall. Anatomically the medial rectus muscle is located closer to LP posteriorly than anteriorly (Fig 18). The suction port of the powered shaver should preferably be directed medially away from the LP to minimize the risk of damaging the structures in the lateral nasal wall. Damage to medial rectus occurs through deeper penetration into the orbit. Unfortunately, it is very difficult to prevent the scarring and diplopia that are likely to occur if recognized then. Moreover, expert strabismus surgeons have difficulty in correcting the problems caused by damage to the medial rectus. It is a medical negligence and should preferably be settled out of court.

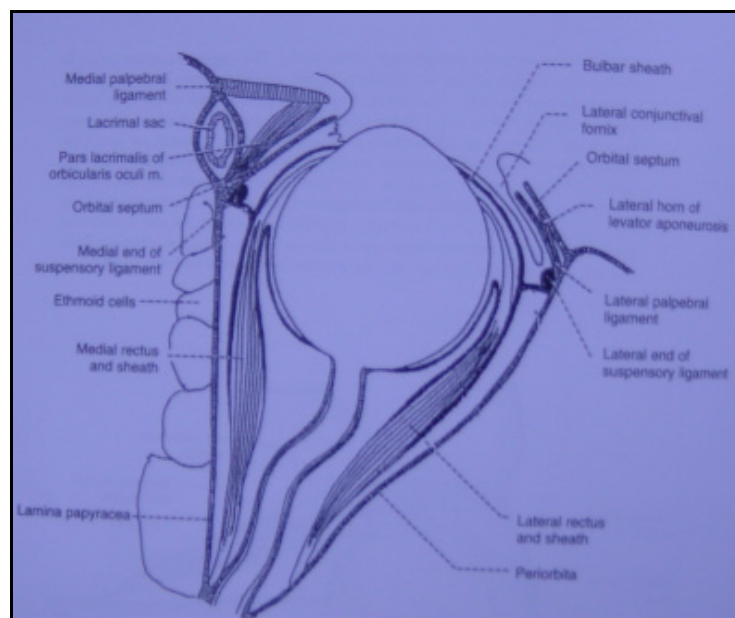


Fig. 18. Axial section of the relationship of right medial rectus and optic nerve to the lamina papyracea

3.3.4 Optic nerve damage

The optic nerve can be damaged by penetration of the orbit through the lamina papyracea. Therefore, it is important for the assistant to look for eye movements when the surgeon is operating on the lateral nasal wall. Moreover, the optic nerve can be damaged if it is exposed in a sphenoethmoid air cell (Onodi cell) (Fig 19). An Onodi cell should be identified on routine pre-operative imaging and care taken in removing polyps lateral to the sagittal plane of the medial wall of the maxillary sinus. It is advisable to identify the sphenoid sinus ostia medially and then work forward. The optic nerve indentation can be prominent in 20% of patients in the upper half of lateral wall of sphenoid sinus but is rarely dehiscent (Fig 20). The carotid artery lies in the lateral and inferior aspect of the sphenoid sinus. Therefore, it is advisable to avoid the lateral wall of sphenoid sinus by directing the suction port of the powered shaver medially away from the lateral wall of sphenoid sinus to minimize the risk of damaging the structures present there.

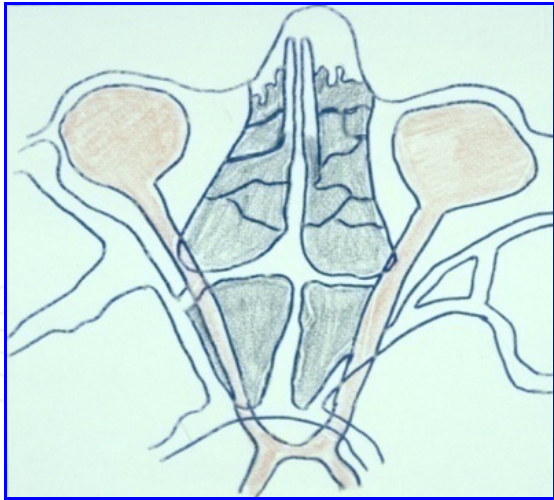


Fig. 19. A diagrammatic axial view of the paranasal sinuses showing a rare bilateral Onodi cell

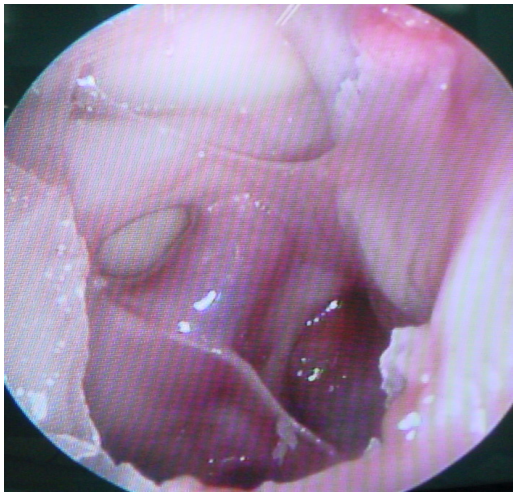
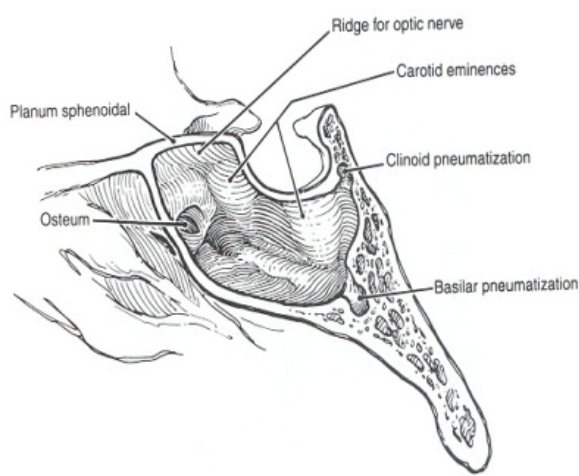


Fig. 20. Diagrammatic sagittal section and endoscopic view of the sphenoid sinus showing indentations of the lateral wall by internal carotid artery inferiorly and optic nerve superiorly

3.3.5 Post-operative complications

3.3.5.1 Bleeding

Sitting the patient 30% head up at end of procedure is often adequate for minor general ooze. Coughing during extubation will result in temporarily more bleeding due to increase in venous pressure. A nasal pack soaked in 1:10,000 epinephrine is helpful for more than minor ooze and removed in the recovery or left in position for 12 hours if oozing continues. Prophylactic antibiotics are advocated for nasal packs left in position for more than 24 hours. Rarely, torrential reactionary bleeding can occur in the first 12 hours due to these vessels initially going into spasm intra-operatively when the platelet plug and clotting factors block them but with due time either due to relaxation of artery or fibrinolysis reverses this process and bleeding commences. Usually it is impossible to locate the bleeding site. If a local nasal pack with vasoconstrictor and local anesthetic is not helpful to

control the bleeding, then bipolar cautery of the offending vessel may be helpful. If this too fails, then reinserting a nasal pack and/or balloon may be necessary to tamponade the bleeding until the sphenopalatine artery (SPA) can be ligated under general anesthesia. If a large sphenoidotomy has been performed, the bleeding could be due to the damaged septal branch as it crosses the anterior wall of the sphenoid (Fig 21).

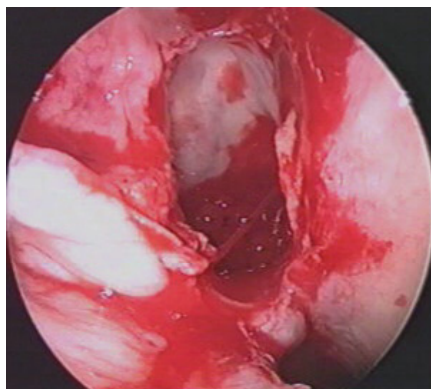


Fig. 21. Intraoperative Endoscopic view showing a right low sphenoidotomy with evidence of sphenopalatine bleed

3.3.5.2 Adhesions

Mucosal damage to adjacent surfaces can result in adhesions (Fig 22). Adhesions can be minimized by topical and local corticosteroids application. If adhesions are present pre-operatively, they need removal with a through-cutting punch followed by douching and debridement at one week.

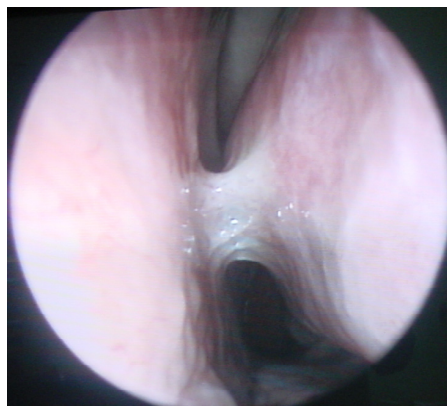


Fig. 22. Endoscopic view showing adhesions between left septum and inferior turbinate after nasal surgery

3.3.5.3 Epiphora

The lacrimal sac or naso-lacrimal duct can be damaged if the middle meatal antrostomy (MMA) is extended too far anteriorly. If middle meatus needs to be enlarged anteriorly to allow improved access or drainage, then the uncinate process (UP) is removed retrograde with Stammberger Rhinoforce antrum punch (Storz, Germany). If patient complaints of watery eyes post surgery, it is best not to intervene as it will often resolve on its own. If the epiphora is persistent, an endo-nasal DCR will be helpful.

3.3.5.4 Periorbital emphysema

Peri-orbital emphysema or air in the soft tissues around the eye is due to intra-operative breach of the LP and the patient unknowingly blown their nose (Fig 23). The anesthetist should be advised to take care on extubating the patient and not to use too much force if patient needs to be ventilated with face mask. The emphysema will resolve in due time provided the patient does not blow any more air into the area. Prophylactic antibiotics are administered for active sinusitis or history of sinusitis.

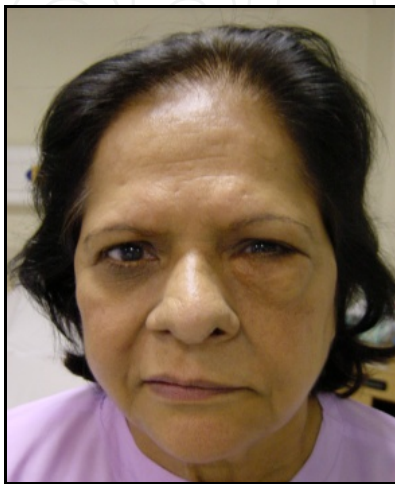

Fig. 23. Left periorbital emphysema post powered endoscopic sinus surgery which resolved spontaneously

3.3.5.5 Anosmia

Smell is a precious sense and every effort should be made to preserve or improve it. The olfactory mucosa extends from the cribriform plate to cover almost all the medial side of middle turbinate and the same area on the septum with a little inferior extension.

Pre-operative oral steroids are helpful in preventing damage to the mucosa, especially if polyps are medial to the middle turbinate (MT) when assessed as an outpatient. If the polyps remain medial to middle turbinate at surgery, perform an ethmoidectomy and then gently lateralize the MT to open the olfactory cleft which allows better access to topical steroid spray. If the patient has hyposmia or anosmia post-surgery and the MT is adherent to the septum, it is worth resecting and lateralizing the MT as an elective procedure when mucosal edema has settled down.

3.3.5.6 Frontal recess stenosis

The frontal sinus is often opaque on CT scan in nasal polyposis and it is normally due to retained secretions. It is rare to find polyps within the frontal sinus. Often opening the middle meatus and de-bulking polyps in region below the frontal recess with a shaver or through-cutting forceps (Stortz, Germany) followed by washing and topical nasal steroids may be adequate to allow the patient's disease to be controlled.

It is essential not to denude the frontal recess of its mucosa since this may predispose to stenosis. If there is purulent disease within the frontal sinus causing symptoms, then it is advisable to open the recess, preserving as much mucosa as possible. This is ideally

performed by dissecting the mucosa off the agger nasi cells with a ball probe and pulling it down on the shell of the cell and removing the fragments of bone and carefully preserving the mucosa. Any loose fragments of mucosa are best left alone. Large fragments of redundant mucosa around the frontal recess can be trimmed using a shaver or through-cutting forceps (Storz, Germany). If there is a bony partition between the supra-orbital cell and frontal recess or a high frontal cell, the partition between them should be removed sub-mucosally.

3.3.5.7 Crusting

Crust results from mucosal damage. If there is full thickness mucosal damage, the mucus produced stagnates because there is no functioning cilia to clear it and it may take up to a year for the cilia to start to function synchronously again. Therefore, mucosal damage should be minimized and a full thickness defect should be avoided at all cost.

3.3.5.8 Infection

Superficial infection of stagnant mucus is common and usually resolves with douching. Sometimes, staphylococci multiply in a sump of mucus that collects in the maxillary sinus and may be slow to clear with douching alone. Topical nasal mupirocin ointment sniffed liberally after douching 6 times a day for 3 weeks can be very helpful.

3.3.5.9 Osteitis

Local osteitis due to exposure of bone is a rare complication resulting in severe pain. It produces a very dull, severe crippling nagging ache that causes tears to the patient. This condition is very distressing to the patient and worrying for the surgeon. Major analgesics are required and local treatment appears to provide little relief. Patients undergoing surgery for inverted papilloma where mucosal preservation is not practiced are at risk.

Tips for successful surgery

Intraorbital hemorrhage should be managed with lateral canthotomy and cantholysis followed by orbital decompression with removal of the medial orbital wall. Orbital decompression can be performed without canthotomy and cantholysis if the complication is noticed intraoperatively.

3.4 Endoscopic orbital decompression for orbital sub-periosteal abscess

Rhinosinusitis in children is not a surgical disease, and therefore the treatment is medical with systemic antibiotics such as clavulanic acid and ampicillin (Augmentin). The priority should be safety in any treatment as the problem usually resolves with time without intervention. Growth and maturation of the immunological response to pathogens play a major role in resolution of the disease (Jones, 1999; Howe & Jones, 2004).

Patients presenting with orbital complications of sinusitis commonly have a degree of cellulitis and edema (chemosis) around the eye with associated proptosis (Fig 24). This may be associated with some restriction of eye movement. Patients typically present with history of nasal obstruction, purulent rhinorrhea and facial pressure or pain. Nasal endoscopy reveals an inflamed and oedematous nasal mucosa with usually presence of pus in the middle meatus.

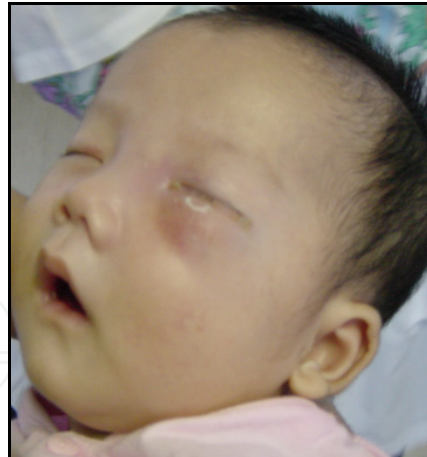

Fig. 24. Picture of a child with a left orbital cellulitis

If a subperiosteal abscess is suspected, a CT scan of the paranasal sinuses with contrast will present a mass located on the lamina papyracea or in relation to the frontal sinus. The rim of the mass will enhance with the contrast. Moreover, the proptosis will be visible on the axial scans.

The external approach is quick and easy and the abscess can usually be rapidly and safely drained. If the surgeon is a skilled and experienced endoscopic sinus surgeon, endoscopic drainage of the subperiosteal abscess can be performed. The problem with this procedure is the significant vascularity that is associated with acute sinusitis. If the mucosal surface is touched with an instrument or endoscope, it will usually bleed and an inexperienced surgeon may lose orientation and complications may occur as a result of poor visibility during the surgery. Frequent packing with decongested soaked neurospunges throughout the procedure helps to minimize the bleeding but will not control it entirely. In a patient with acute sinusitis, the anaesthetist needs to optimize the patient's hemodynamic parameters to create an optimal surgical field.

The surgical approach is to perform an uncinectomy and enlarge the maxillary ostium to a moderate degree. Uncinectomy alone without antrostomy carries the risk of postoperative closure of the maxillary sinus because the inflammation and edema predisposes to scarring and adhesion formation. Clearance of the frontal sinus depends on whether the frontal sinus is thought to be the origin of the subperiosteal abscess. If the abscess is located adjacent to the ethmoidal sinuses, clearance of the bulla ethmoidalis and posterior ethmoids is performed with identification of the lamina papyracea. The lamina papyracea over the subperiosteal abscess is widely exposed and removed. If the abscess is related to the floor of the frontal sinus, it can still be drained endoscopically. A minitrephine is usually placed in the frontal sinus before dissection of the frontal recess. This aids in identification of the frontal outflow tract. The frontal recess is cleared and the frontal ostium identified. The lamina papyracea directly behind the lacrimal sac is removed and using a curette, the orbital periosteum is kept intact and gently pushed laterally while the curette advances into the subperiosteal abscess and the abscess drained (Wormald PJ, 2005).

A malleable suction (Medtronic Xomed, Jacksonville, Florida, USA) is introduced into the cavity and any fibrin within the cavity is removed. A corrugated Penrose drain is slid into the abscess cavity and left in place, draining the abscess cavity into the ethmoid sinuses for 1

to 2 days before being endoscopically removed. Endoscopic removal of the subperiosteal abscess remains highly effective but it must be emphasized that the surgeon should be very experienced.

Although endoscopic drainage of subperiosteal and other orbital abscesses is becoming more common, the efficiency of narrow surgical drainage via an endoscopic approach has not been thoroughly evaluated (Page and Wiatrak, 1996). Similarly, although endoscopic treatment of frontal sinus is less invasive than open frontal surgery, it also has a lower reported success rate (Metson and Gliklich, 1998).

Indications for CT scan

- Unable to accurately assess vision, gross proptosis, ophthalmoplegia, deteriorating visual acuity or colour vision, bilateral edema, no improvement or deterioration at 24 hours or a swinging pyrexia that does not resolve within 36 hours

Tips for successful surgery

Endoscopic decompression of a subperiosteal abscess should only be performed by very experienced endoscopic sinus surgeons because the surgical field can be very bloody, which can significantly increase the degree of difficulty and the likelihood of complications. If the surgeon is not experienced, then the abscess should be drained via an external incision.

3.5 Endoscopic optic canal decompression

The most common indication for endoscopic optic canal decompression is traumatic optic nerve neuropathy (TON). Currently it is thought that 5% of severe head injuries will have concomitant injury to the optic nerve, optic tract or optic cortex (Tandon et al, 1994; Kountantakis et al, 2000; Kuppersmith et al, 1997). Since major brain injury takes precedence over traumatic optic neuropathy, it may result in the optic nerve injury being diagnosed somewhat later than the brain injury. Some authors feel that early diagnosis and treatment of traumatic optic neuropathy may be of greater benefit to the patient (Lubben et al, 2001, Sofferman, 1995) and advocate diagnosis of optic nerve deficit by the presence of an absolute or relative afferent pupillary defect supported by disc edema and congestion of the vessel walls. These findings in addition to CT scan and possibly MRI scan and visual evoked potentials are sufficient to undertake optic canal decompression. Currently there is no properly conducted randomized controlled trials comparing high-dose steroid therapy, surgical decompression and observation (Steinsapir et al, 2002).

Traumatic optic neuropathy is believed to result from two distinct injuries to the nerve. The primary injury is the result of either a direct contusive force on the optic canal and nerve or elastic deformation of the sphenoid, with transfer of the force on the intra-canalicular optic nerve disrupting the axons and blood vessels (Steinsapir & Goldberg, 1994). This primary injury may result in compression of the nerve by bony fragments or in hemorrhage into the nerve sheath. A secondary injury may occur if the primary injury is not treated in due time. Compression of the blood vessels occur if there is bleeding into the dura resulting in ischaemia and continued axon loss (Sofferman, 1995; Steinsapir & Goldberg, 1994).

We have adopted a conservative approach to traumatic neuropathy with all patients undergoing high-dose steroid treatment before being offered surgical intervention. The exception is when bony fragments are found to impinge on the optic nerve.

A randomized clinical trial demonstrated no benefit of either high-dose corticosteroids nor optic nerve decompression. Both are still employed because the alternative may be irreversible blindness. However, at the initial presentation, the visual performance of visual fields is correlated to the final outcome.

3.5.1 Medical therapy for traumatic optic neuropathy

Presently megadose intravenous methylprednisolone is helpful. Methylprednisolone 30mg/kg IV loading dose is given followed by 5.4 mg/kg/hr thereafter (Cook et al, 1996). The patient's visual acuity is monitored hourly and surgical intervention is considered if the patient shows or fails any of the criteria below:

- A dilated optic nerve on CT scan
- Fracture of optic canal on CT scan with vision less than 6/60
- Fracture of optic canal with vision more than 6/60 but the patient's vision deteriorates on steroids
- Vision is less than 6/60 after 48 hours of steroids with likely canal injury (indicated by the presence of fluid levels in the posterior ethmoids and sphenoids and/or the presence of fractures of the ethmoids, orbital apex and sphenoid).

3.5.2 Surgical therapy for traumatic optic neuropathy

Optic nerve decompression (OND) is an extension of orbital decompression when the optic nerve in the lateral wall of the sphenoid is decompressed.

3.5.3 Indications

Optic nerve injury is usually and should be recognized immediately by the existence of relative afferent papillary defect (RAPD) or inverse RAPD. It always appears in optic nerve injury even if visual acuity is relatively preserved initially. If it occurs in traumatic setting, the visual acuity will always deteriorate to no light perception. One should suspect this injury whether the ocular media are clear or opaque. It may be inappropriate for the patient to undergo surgery if they have a Glasgow coma scale of less than eight (Jones et al, 1997). Several studies suggest that with retro-orbital hemorrhage, decompression of the orbit needs to be done in less than one hour (Mason et al, 1998). However, where there is no hemorrhage, it is less understood under what circumstances it is beneficial to decompress the nerve pathway. If there is an anatomical constriction on CT scans affecting the course of the optic nerve and the patient is fit for anesthesia, then it seems reasonable to remove bone pressing on the nerve.

3.5.4 Useful instruments

- A long-shank drill with a coarse diamond burr and good irrigation system (Medtronic Xomed) to keep the bone cool.
- Image guided surgery

3.5.5 Surgical technique

The standard preparation of the nose is performed with decongestants and infiltration. An uncinectomy with exposure of the maxillary ostium is performed (Fig 25). An axillary flap is

performed and the agger nasi cell removed for access to skull base. The fovea ethmoidalis is exposed in the region above the bulla ethmoidalis. If there is disruption of the cells of the frontal recess, then this will be cleared. In some patients with severe sinus fracture, the entire skull base may be mobile.

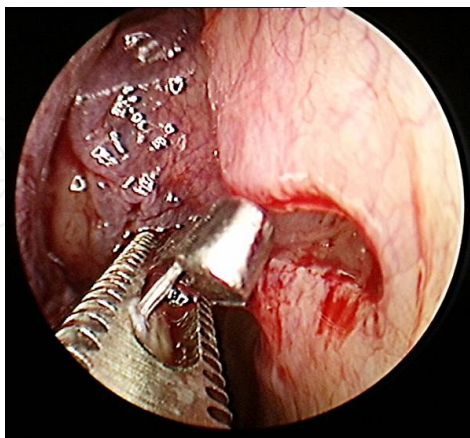


Fig. 25. A zero degree endoscopic view showing a left uncinectomy being performed

In majority of patients, the posterior ethmoid cells will be full of blood and when combined with mobility of lamina papyracea, the skull base surgeon can become disorientated. Thus, this surgery should be undertaken only by highly experienced endoscopic sinus surgeons. A posterior ethmoidectomy and sphenoidotomy should be performed. In the posterior ethmoids, the posterior lamina papyracea and fovea ethmoidalis should be identified. If significant disruption of the posterior ethmoids and lamina papyracea has occurred, then a large middle meatus antrostomy provides an extra reference point and lessens the likelihood of the surgeon becoming disorientated. The natural ostium of the sphenoid sinus should be identified and anterior face of the sphenoid widely opened.

The anterior face of the sphenoid needs to be taken as high as possible so that the roof of the sphenoid and the posterior ethmoids is continuous (Kuppersmith et al, 1997; Luxenberger et al, 1998; Chow and Stankiewicz, 1997). The sphenoid should be inspected and the optic nerve, carotid artery and pituitary fossa identified (Luxenberger et al, 1998; Chow and Stankiewicz, 1997). If there is significant disruption of the orbital apex or the lateral wall of the sphenoid, the identification of these basic structures can be difficult and image guidance may be helpful here.

The thick bone overlying the junction of the orbital apex and sphenoid sinus is known as the optic tubercle. This bone is normally too thick to flake off and an irrigated 15 degree angled diamond burr (Medtronic Xomed, Jacksonville, Florida, USA) is used to thin this bone down until it is almost transparent (Luxenberger et al, 1998; Chow and Stankiewicz, 1997). A blunt Free's elevator is pushed through the lamina papyracea 1.5 cm anterior to the junction of the posterior ethmoids air cell(s) and the sphenoid. While performing, care should be taken to keep the orbital periosteum intact, otherwise prolapsed of the orbital fat can severely obstruct the dissection of the optic nerve. The bone of the posterior orbital apex is flaxed off the underlying orbital periosteum (Luxenberger et al, 1998; Chow and Stankiewicz, 1997).

The bone over the optic canal is approached once the bone over the orbital apex is removed. This bone is usually quite thin and in majority of the cases can simply be flaked off the

underlying nerve (Fig 26). Sometimes, the bone over the nerve can be too thick and will need to be thinned with diamond burr prior to removal. When the bone is thin enough to be flaked off the underlying nerve, suitable instruments like the Beale’s elevator and the House curette, both from the ear tray should be used.

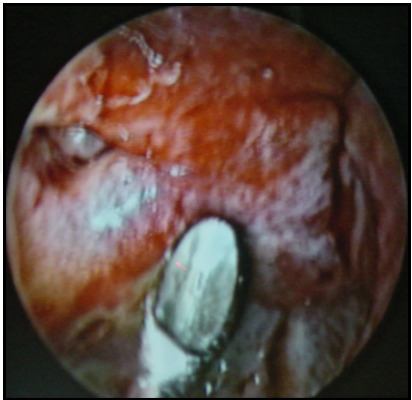


Fig. 26. A 45 degree endoscopic view showing bone being cleared off the optic canal with underlying optic nerve sheath clearly visible in a patient with traumatic optic neuropathy

When all the bone has been cleared off the optic canal and underlying optic nerve sheath is clearly visible, the sheath should be incised (Luxenberger et al, 1998; Chow and Stankiewicz, 1997). The location of the ophthalmic artery should be noted for it usually runs in the posteriorinferior quadrant of the nerve. Occassionally, this artery can migrate around the lower edge of the nerve and potentially into the surgical field (Steinsapir et al, 2002). However, if the nerve is incised in the upper medial quadrant, the risk to this artery should be minimal(Luxenberger et al, 1998; Chow et al, 1995). A sharp sickle knife is used to incise the sheath of the optic nerve. Usually the swollen nerve is under pressure and the sheath splits as it is incised and nerve will protrude through the incision.. The incision is continued onto the orbital periosteum of the posterior orbital apex with resultant protrusion of orbital fat. The orbital fat covering this area of the medial rectus muscle is thin and care should be taken to avoid injuring this muscle (Fig 27). No packs are placed on the nerve or in the sinuses.

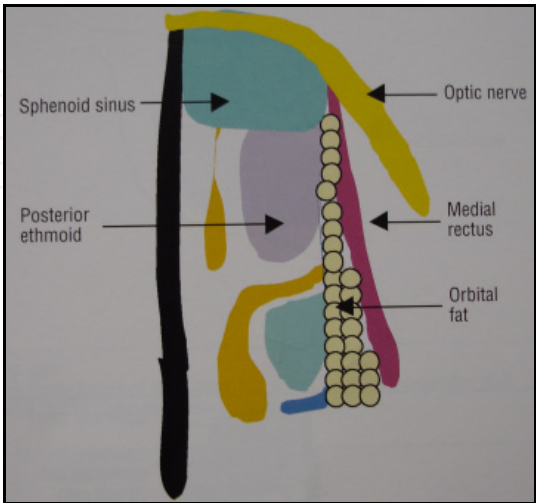


Fig. 27. A diagrammatic axial section of the paranasal sinuses and the orbit showing the anatomical relationship of the medial rectus muscle to fat and periorbita

It is vital to monitor the vision post-operatively quarter-hourly for one hour and then hourly for 4 hours. The immediate or early results of decompression are frequently extremely gratifying. The patient should be instructed not to blow their nose or sniffle sneezes for 4 days to avoid surgical emphysema.

Tips for successful surgery

Optic nerve decompression is a highly complex procedure and should be undertaken by endoscopic sinus surgeon with significant experience and skill. Potential injury to the skull base with a resultant CSF leak may occur and in addition an associated injury to the internal carotid artery may be present. Injudicious manipulation of bony fragments may have catastrophic consequences for the patient. A trial of medical therapy should be advocated before surgery is contemplated unless there is an obvious bony fragment impinging on the optic nerve. Literature review suggests that patients should be operated upon if medical therapy fails to improve the vision within 24 to 48 hours. Significant delays would seem to lessen the potential for success of the surgery. Great care should be considered in exposing the optic nerve especially when flaking the bone from the nerve. Injudicious use of inappropriate instruments has the potential to worsen the vision. In the hands of an experienced endoscopic sinus surgeon, this procedure is relatively safe with low morbidity and has the potential to improve and in some cases restore lost vision, especially after blunt trauma.

4. Endoscopic applications to the pterygopalatine and infratemporal fossa for resection of benign pathological lesions

The most common benign tumor involving the pterygo-palatine and infra-temporal fossa is the juvenile angiofibroma(Fig 28). These tumors originate in the region of spheno-palatine foramen and expand into pterygo-palatine fossa. Large tumors may extend into infra-temporal fossa and usually have a large intranasal component that may extend into nearby sinuses especially the sphenoid sinus. Other benign tumors in this region are inverting papilloma extending from the nasal cavity or rare tumors arising from the nerve sheath (schwannomas)(Fig 29), cartilage or muscle. Meningoceles extending into this area from the middle cranial fossa are rare.

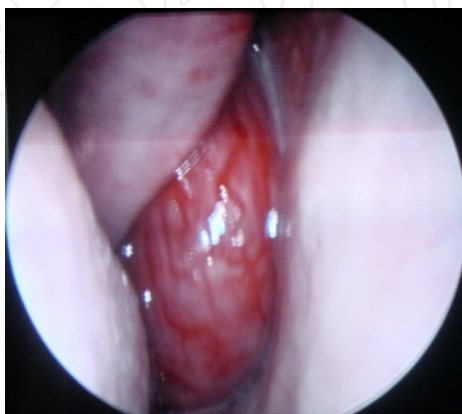

Fig. 28. Endoscopic view of a right juvenile angiofibroma in a teenage male presenting with recurrent epistaxis.

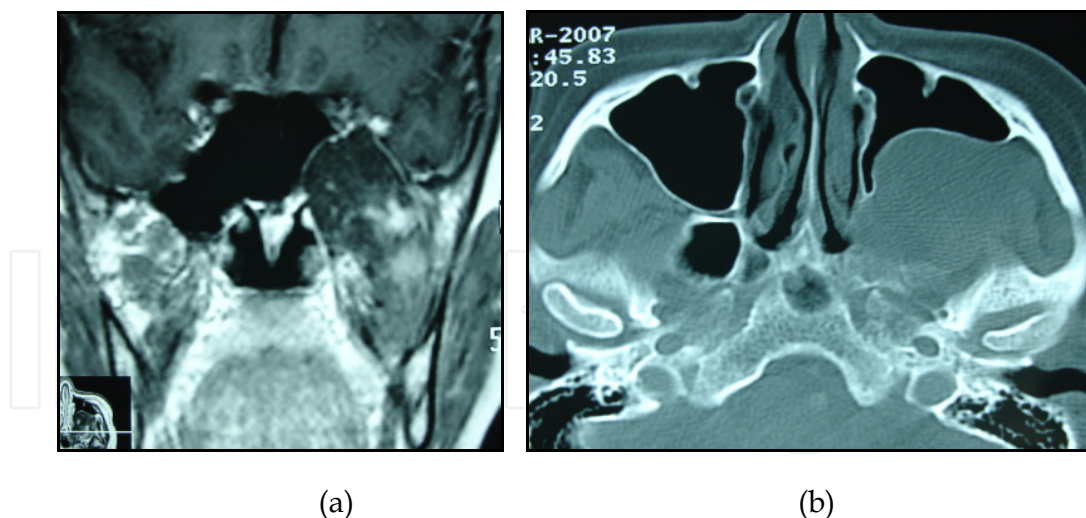


Fig. 29. A coronal(a) and axial(b) MRI view of the paranasal sinuses showing a left maxillary nerve schwannoma

4.1 Surgical technique for endoscopic modified medial maxillectomy

The nasal cavity is prepared by placing cocaine and adrenaline-soaked neuropatties in the nasal cavity. The lateral nasal wall and septum are infiltrated with 2% lidocaine and 1:80,000 adrenaline. Using 2 ml of lidocaine and adrenaline, a pterygo-palatine fossa block is placed via the greater palatine canal which greatly helps to reduce vascularity during dissection of medial wall of the maxilla and pterygo-palatine fossa.

The initial step in endoscopic modified medial maxillectomy is to remove the uncinate process and perform a large middle meatal antrostomy. Moreover, the maxillary antrum is enlarged posteriorly up to posterior wall of maxillary sinus. This provides visualization of the medial orbital wall and aids in removal of residual medial maxilla without endangering the orbit. Majority of tumors of maxillary sinus and pterygo-palatine fossa will involve the posterior ethmoids and sphenoid. The bulla ethmoidalis is removed and a posterior ethmoidectomy and sphenoidotomy are performed. The inferior turbinate is medialized and its posterior two-thirds removed. A right angled phako-knife is used to make mucosal incisions from just below the orbit, through the anterior one third of the inferior turbinate onto the floor of the nasal cavity. The incision is continued along the floor of the nose to the posterior region of the inferior turbinate and on to the maxillary sinus. A sharp chisel is used to cut the bone under the mucosal incisions.

If the bone forming the medial maxillary wall is mobilized, the naso-lacrimal duct will tether the bone anteriorly and the duct will be visualized which can be transected with a scalpel (Fig 30). Subsequently, a DCR spear knife (Metronic Xomed) is used to open the lower half of the sac, creating an anterior and posterior flaps and rolling these out (Wormald et al, 2003; Wormald & van Hasselt, 2003; Vrabac, 1994). This prevents stenosis of the sac postoperatively (Wormald et al, 2003; Wormald & van Hasselt, 2003). The edges of the resected maxilla are cleaned with micro-debrider (Metronic Xomed). Using a 70 degree endoscope the entire maxillary sinus can be visualized including the anterior wall and floor. The tumor can now be removed from the maxillary sinus under direct vision. A canine fossa puncture can be performed, if additional access is required which can be useful to access areas within the sinus.

that may otherwise be difficult to access. Malleable suction dissector's are useful because these instruments can be bent to the required angle for dissection in difficult areas like the anterior wall or antero-lateral region of the lateral wall of maxillary sinus.

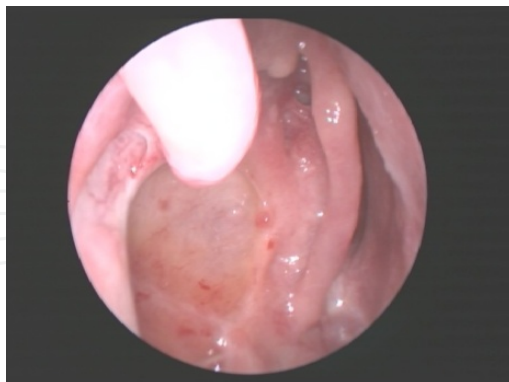


Fig. 30. A 30- degree endoscopic view showing evidence of right modified medial maxillectomy performed for an inverted papilloma.

4.2 Exposure of the pterygo-palatine fossa

Exposure of the pterygo-palatine fossa via a wide medial maxillary antrostomy is necessary for tumors that occupy the pterygo-palatine fossa and extending into the infra-temporal fossa. The mucosa from the posterior wall of the maxillary sinus is elevated and preserved and the exposed bone removed to access the pterygo-palatine fossa. A 45 degree through-biting Blakesley forceps is used to remove the bone anterior to the sphenopalatine artery and continued to the posterior wall of the maxillary sinus exposing the contents of the pterygo-palatine fossa. Traction is vital for tumors that extend into the infra-temporal fossa because it allows the surgeon to identify the areas of attachment of the tumor to the surrounding tissues and to dissect these free with suction dissector. Thus the entire tumor can be mobilized and its pedicle identified.

Tumors that extend into the infra-temporal fossa will usually be closely associated with the maxillary nerve in the pterygo-palatine fossa. This nerve should be identified both distally and proximally early in the dissection and preserved. Suction dissection instruments are used to separate the nerve from the tumor. Fibrous tissue is easily divided with endoscopic soft tissue scissors.

Feeding blood vessels can either be cauterized with suction bipolar diathermy forceps or clipped and cut. Once the tumor is removed, the tumor bed can be closely inspected to ensure no tumor remnant remains. Once hemostasis is achieved with suction bipolar forceps, the preserved mucosa from the posterior wall of the maxillary sinus is replaced. Surgicel can be placed in the cavity if required. Finally, ensure that the lacrimal sac is adequately exposed to prevent postoperative stenosis and epiphora. The incidence of postoperative epiphora has been described as high as 30% (Bolger et al, 1992).

Endoscopic two-surgeon technique for tumors of the pterygo-palatine and infra-temporal fossa

The key to successful endoscopic removal of large tumors in this region is having two surgeons operating at the same time. This can be achieved by providing access to the tumor

bed for the second surgeon through the septum from the opposite nasal cavity. A hemitransfixation(Freer's) incision is made on the opposite site of tumor. Using standard septoplasty techniques, the mucosa is elevated off the cartilage of the septum which is preserved but most of posterior bony septum is resected. A horizontal incision is made in the opposite septal mucosa to allow instruments placed through the opposite nostril and into the Freer's incision to cross the septum and access the tumor on the contra-lateral side of the nose.

During tumor removal, the second surgeon can provide significant traction on the tumor and when the feeding vessel from the maxillary artery is cut, large volume suction in the field can allow the suction bipolar cautery to be used to identify and cauterize the large bleeding vessel.

4.3 Juvenile angiofibroma with pterygo-palatine and infra-temporal fossa extension

Angiofibromas that significantly extend into pterygopalatine fossa can be removed after endonasal endoscopic medial maxillectomy (Kennedy et al, 1990) and embolization within the preceding 24 hours. This reduces the vascularity of the tumor and allows dissection around the tumor without major hemorrhage. The second surgeon can keep the surgical field clear using a large suction in the area of dissection while the other surgeon holds the telescope and suction dissection instrument.

4.4 Schwannoma involving the pterygo-palatine and infra-temporal fossa

Endoscopic medial maxillectomy also provides access to other tumors that may involve the pterygo-palatine and infra-temporal fossa. Schwannoma of the maxillary nerve involves the entire pterygo-palatine fossa and extends significantly into the infra-temporal fossa. Endoscopic medial maxillectomy allows access to the entire posterior wall of the maxillary sinus and after its removal, to the tumor.

4.5 Post-operative care

Douching of the nose with saline is started immediately postoperatively. Local and systemic antibiotics and corticosteroids are usually helpful. Crusting will usually continue for a few weeks until the cavity epithelializes but has not proved to be problematic in the long run. Benign tumors do not usually need any adjuvant treatment but malignant tumors may require postoperative radiotherapy.

5. Endoscopic resection of benign pathological lesions of paranasal sinuses

5.1 Mucocoeles

Mucocele is a chronic, expansile, benign cystic lesion limited by the mucosa of the paranasal sinus, with thick, translucent mucous secretions (Fig 31). The most common are the frontoethmoidal mucocoeles which presents with headaches and orbital symptoms. The expansile character of the mucocele promotes slow erosion of the adjacent bone via compression and consequent bone absorption. This disease is usually secondary to obstruction to sinus drainage, leading to stagnation of the secretion within the cavity. The predisposing factors can be fractures, mucosal edema, polyps, tumors, surgical trauma and

chronic sinusitis. Mucocèles are classified according to the sinus of origin. The frontal sinus being the most common site, followed by the ethmoid, maxillary and sphenoid sinuses.

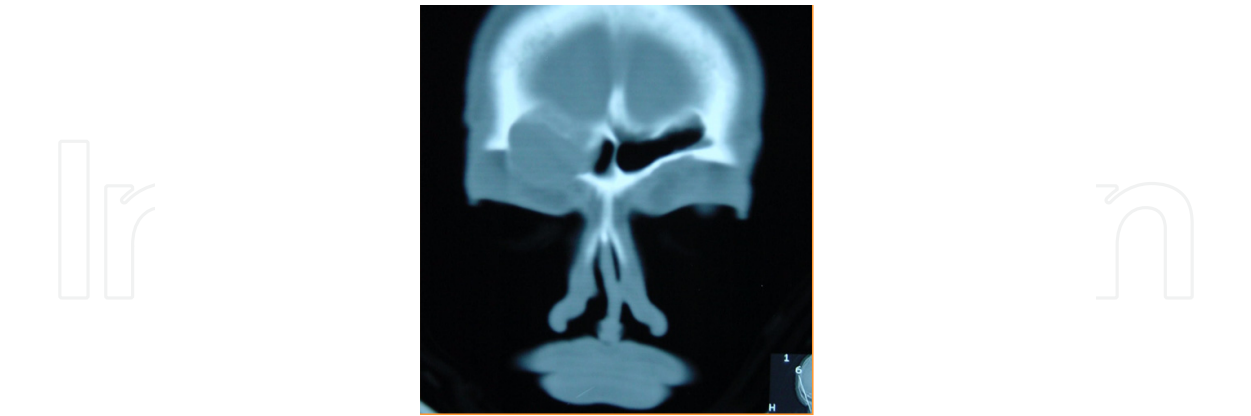


Fig. 31. Coronal CT imaging of the right frontal sinus with evidence of a right mucocèle showing expansile erosion of right orbital floor with lateral extension

Fronto-ethmoidal sphenoidal and the rare maxillary sinus mucocèles are ideal cases for endoscopic approach provided wide marsupialization can be achieved (Hehar & Jones, 1997). Mucocèles accessible with the endoscope should be opened as widely as possible using through-cutting forceps in order to minimize the amount of scar tissue that forms around the edges and which might lead to recurrence. Coronal CT scan is helpful to show whether the lesion can be approached via the nasal cavity and whether it is unilocular or multilocular. In the frontal sinus, a small mucocèle may be drained via the endoscopic approach (Fig 32) but mucocèles with lateral extension may be difficult to access via the nose. Therefore, an external and endoscopic approach can be usefully combined, preserving lateral support of the frontal recess and avoiding a stent.

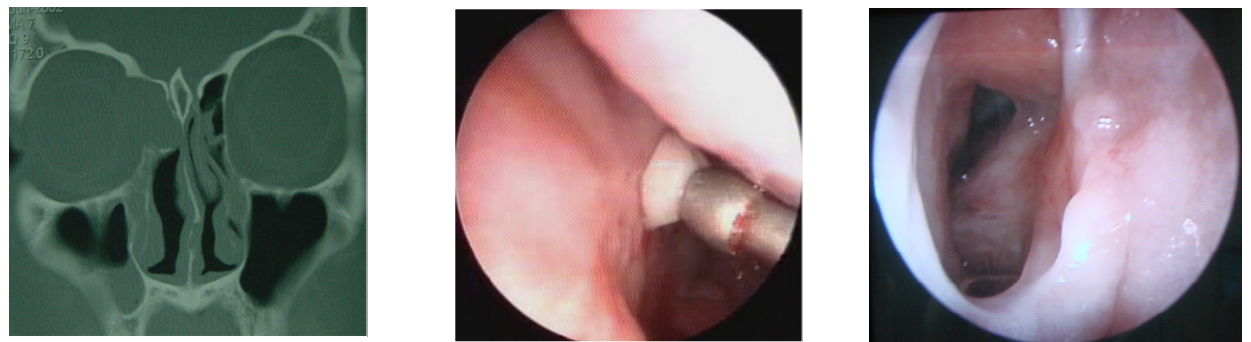

Fig. 32. Coronal CT imaging showing a right iatrogenic frontoethmoid mucocèle and intraoperative endoscopic drainage and follow up a 3 months post surgery showing a patent frontal sinustomy in an adult presenting with frequent right headaches and heavy eyes

Preoperative evaluation of patients with frontal mucocèles should include careful evaluation of the lesion relative to the skull base. Endoscopic decompression is probably the best initial therapy for these lesions. It is particularly true of mucocèles that have eroded the posterior table of the frontal sinus and become adherent to the dura. An uncinectomy is performed with an axillary flap as advocated by Wormald PJ(2005). Often in surgery of these lesions, the skull base is identified within the posterior ethmoids and then followed anteriorly until

the bone of the lesion is identified. The mucosal covered mass at the frontal recess area is opened with Blackesley's straight forceps (Stortz, Germany). As the lesion is approached or entered, mucoïd or mucopurulent material is sucked out. The frontal sinustomy is enlarged upto about 2cm and the edges of exposed mucosa marsupilized. It is essential to remove all osteitic intersinus septa if recurrence of disease is to be avoided. If the bony margins are not flushed with the surrounding wall, narrowing of the opening, due to scarring and closure may occur (Kennedy et al, 1989). Once a frontal and/or ethmoid mucocoele has been marsupilized, the expanded "shell" of bone that remains can be pushed manually to correct any bony swelling that may cause a cosmetic defect or displacement of the orbit intraoperatively. Sometimes a posteriorly placed mucocoele may leave the orbit displaced even after marsupilization and then the orbit may need to be decompressed by removing its lateral wall (Conboy & Jones, 2003).

The majority of mucocels can be marsupilized endoscopically with minimal morbidity and long-term results as compared to other techniques. The wider the mucocoele is marsupilized, the better the result. Majority of mucocoeles can be marsupilized well with the endoscope except those lying in the lateral aspect of the frontal sinus, those that are secondary to malignancy (require an en-bloc and a craniofacial resection) and those secondary to pathology like Paget disease of fibrous dysplasia (Kennedy et al, 1989; Beasley & Jones, 1995).

In the postoperative period, the mucosal lining the mucocoele cavity may undergo significant hypertrophy and secretions may accumulate, necessitating suction from time to time. However, mucociliary clearance becomes reestablished, typically in a few weeks and the mucosal hypertrophy resolves over time (Kennedy et al, 1989). Hospitalization usually is less than 24 hours. As with other endoscopic sinus surgery, meticulous postoperative care is essential.

Relative contraindications for endoscopic marsupilization

- Abnormally thick bone (Paget's disease (Fig 33), fibrous dysplasia (Fig 34)).
- Revision surgery where an external fronto-ethmoidectomy was performed and if the recurrence is located lateral to area accessible via a median drainage procedure
- A laterally placed frontal mucocoele
- Malignancy associated with a mucocoele

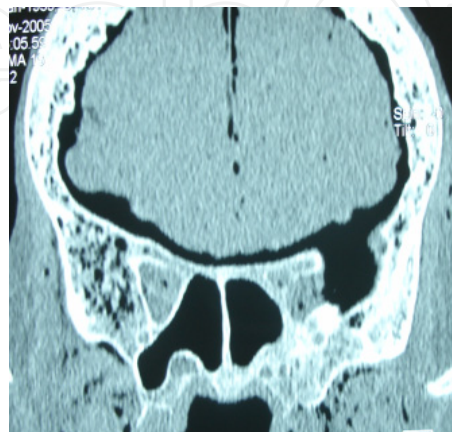

Fig. 33. A coronal CT scan view of paranasal sinuses and skull showing evidence of Paget's disease

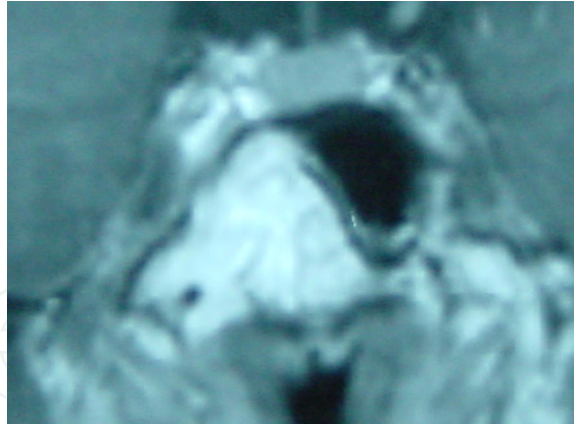


Fig. 34. A coronal CT scan of the paranasal sinuses showing evidence of fibrous dysplasia involving the sphenoid sinus

6. Endoscopic applications to the sellar, parasellar and clival for resection of benign pathological lesions

6.1 Endoscopic pituitary micro-adenoma and macro-adenoma surgery

6.1.1 The various approaches to the pituitary include

- Trans-septal, trans-sphenoidal
- Trans-nasal
- Transcolumellar approach(Fig 35)
- Via an external ethmoidectomy approach
- Through the upper buccal sulcus of the mouth and then trans-septal, trans-sphenoidal
- Via a craniotomy eg an anterolateral or a frontal approach

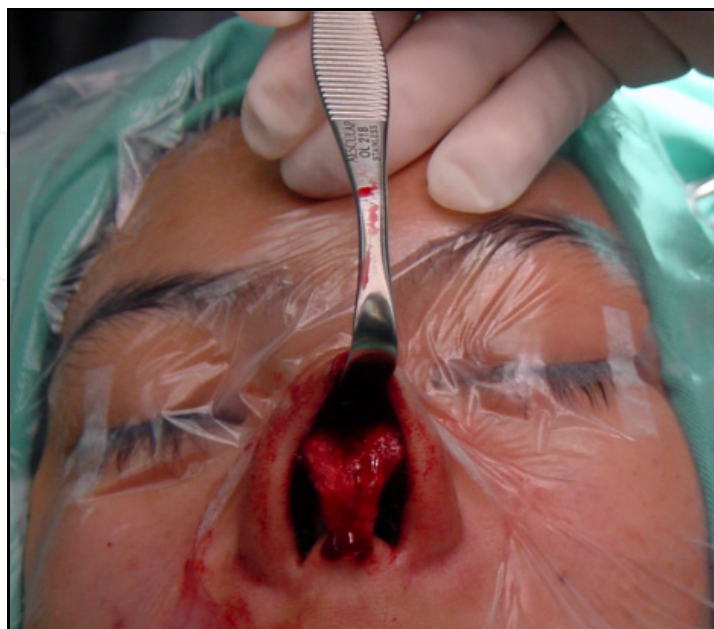

Fig. 35. A picture of transcolumella approach as an access route to the pituitary

6.1.2 Indications

Pituitary tumors occur in 9 in 10,000 population and comprise 10% of intracranial tumors. The commonest pituitary tumors in patients under 35 years secrete prolactin and adrenocorticotropin whereas after 35 to 50 years they generally secrete growth hormone. In the latter, non-secreting tumors are more common. Symptoms can be caused by pressure on the anterior pituitary and hypo-pituitarism or by extra-sellar growth that can produce headaches, pressure on the optic chiasma or brain (Fig 36). Surgery is usually the treatment of choice. Surgery is the first-line treatment in acromegaly, where up to 90% of microadenomas are cured but the outcome is not as good as in large tumors.

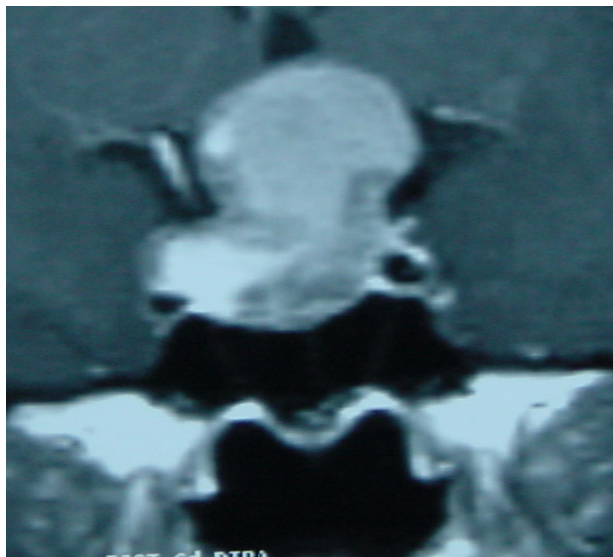


Fig. 36. A coronal MRI of the paranasal sinuses showing a suprasellar extension of a pituitary adenoma presenting with headaches and visual symptoms

Surgery for pituitary disease must be based on an assessment of the patient by a multidisciplinary team (Gendeh, 2006). The medical management of many pituitary tumors has reduced the frequency of the need for surgery in many patients. Medical management is rarely indicated in tumors that extend into the supra-sellar region and extending above the diaphragma sellae.

The endoscope gives excellent visibility within the sphenoid sinus and with a 45 degree endoscope it is possible to see more detail within the pituitary fossa than with the microscope. The advantages of the trans-nasal, trans-septal or lower buccal approach is that it avoids an external scar and by removing the posterior part of the septum, vomer and anterior wall of sphenoid, this approach allows wide access. In the endoscopic trans-nasal technique, mucosal preservation is an added advantage and allows the surgeon to work bimanually if necessary. The advantage of the two nostril technique is when there is moderate or severe bleeding, it can be controlled more readily. An external ethmoidectomy approach produces a scar and has the potential to cause stenosis of the frontal recess. Pituitary surgery has been routinely performed with endoscopic endonasal approach at our referral center since 1990. (Gendeh, 2010)

6.1.3 Surgical anatomy

The vomer consistently joins the sphenoid in the mid-line and this is a very reliable landmark. The sphenoid inter-sinus septum is often asymmetric (more than 75%) and its essential to review the CT scans pre-operatively. The degree of pneumatization of the sphenoid sinus also varies greatly (Lang, 1989). A conchal sinus is small and confined to the anterior aspect of the sphenoid in 5% of cases. A pre-sellar sinus extends to the coronal plane level with the anterior wall of the sphenoid in 28% of cases. In 67% of cases it is sellar type (Fig 37). Agensis of the sphenoid sinus occurs in 0.7% of patients. The carotid artery bulges into its lateral wall and it can be dehiscent in up to 30% of patients. Axillary imaging cuts complement coronal sections and sagittal reconstruction helps. The natural sphenoid sinus is relatively high in the posterior wall of the sphenoid and is often placed at the level of the superior turbinate which may be readily visible after gentle lateralization of the middle turbinate. The bony anterior wall of the sphenoid sinus is often thin or deficient 1 to 1.5 cm above the posterior choana. The lateral wall of the sphenoid sinus has indentations from various structures (Fig 38):

- The optic nerve can indent its surface in the upper third
- The maxillary nerve can form an almost horizontal semicircular intrusion that may be mistaken for optic nerve in its medial third
- The degree of pneumatization of the sinus varies and influences how prominent structures are in its lateral wall. Pneumatization can extend to the clivus, the lesser wing and the root of the pterygoid process).
- The vidian nerve can bulge into its floor

1. Conchal (5%)
 - Common in children below 12 years
 - Area below sella is complete block of bone
2. Presellar (28%)
 - Posterior limit of air cavity is perpendicular to sella
3. Sellar (67%)
 - Commonest,
 - Air cavity extended into body of sphenoid below sella and may extend as posterior as clivus

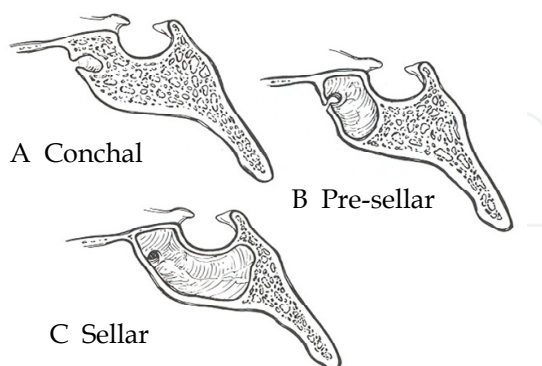


Fig. 37. Types of sphenoid sinus pneumatization

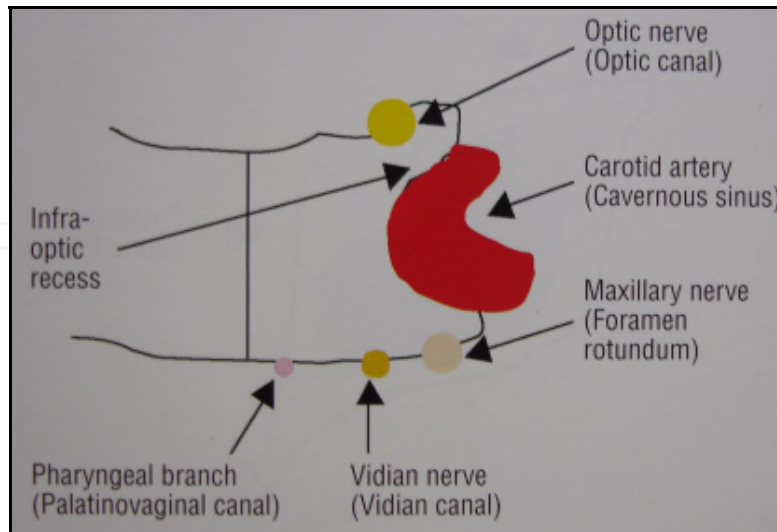


Fig. 38. A diagrammatic coronal section of the sphenoid sinus showing the anatomical indentations of vital structures in its roof, lateral wall and floor.

6.1.4 Useful instruments

- Hajek-Koffler punch (Stortz, Germany) to remove thick bone. The rotating sleeve allows its jaws to be pointed in any direction and for the handle to be in a comfortable position for the operator
- A Kerrison punch (Stortz, Germany) allows fine controlled removal of small segments of bone and the slight reversed angle of its jaws help to remove the back of the vomer
- A long-shanked drill with a coarse diamond (Metronic Xomed) to remove any bone in the roof of the sphenoid bone in a controlled way
- A computer guided systems

6.1.5 Surgical technique

The trans-nasal endoscopic approach commences by making a sphenoidotomy on the side of the tumor or when it is in the midline opening, the side where the sinus is larger. The sphenoidotomy is opened up to the level of the skull base using a sphenoid punch. Suction diathermy will be needed to stop the bleeding from the posterior branch of spheno-palatine artery when opening the sphenoidotomy inferiorly. Any vomerine spur should be removed. After careful CT examination and endoscopically inspecting the sphenoid sinus to check on the proximity of the lateral structures, the lateral aspect of the anterior wall can be removed if necessary. A Kerrison antrum punch (Stortz, Germany) is useful for performing this as its small diameter means that the bone can be removed in small pieces with good visibility. If more space is required across the midline, the vomer can be fractured across or it can be incised 1cm in front of the sphenoid and removed. The vomer can be very thick where it joins the sphenoid but it rarely needs drilling (Fig 39). The pituitary often bulges into the roof of the sphenoid and the bone may be very thin (Fig 40). If the bone is thick, a coarse diamond burr (Metronic Xomed) should be used to thin it. A diathermy point is useful to open the dura by making a cross-shaped incision through it. A 45 degree endoscope gives

excellent visibility and helps to avoid going through the diaphragm sellae. A Hajek punch (Storz, Germany) helps to remove the bone over the pituitary. The tumor is often grey in colour, but occasional it can be vascular and ooze moderately. The pituitary fossa can be closed at the end of the procedure with raised naso-septal flap placed onto the bony defect. If there is a CSF leak, in addition an underlay duragen(collagen matrix graft) is placed before a naso-septal flap is placed as overlay flap and secured in position by Tisseel and gel-foam over it.

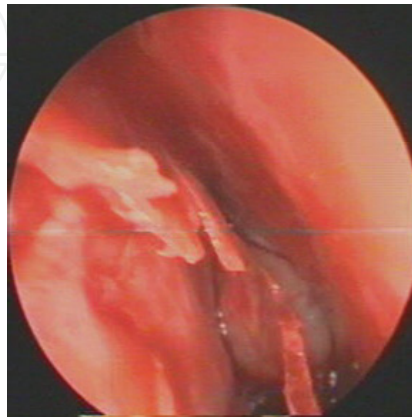


Fig. 39. Intraoperative endoscopic view showing a transseptal transsphenoidal approach to pituitary adenoma exposing the sphenoid rostrum

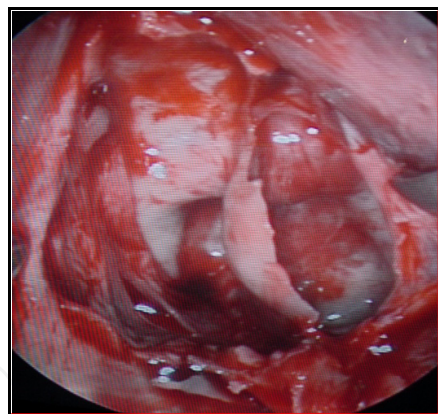


Fig. 40. A 45 degree endoscopic view of exposed sphenoid sinus showing a intersinus septum and an enlarged sella

It is possible to approach the pituitary via a limited sphenoidotomy, although it reduces access and visibility. It may be useful to trim the middle turbinate on one side for better access and visibility utilizing a four hand technique.

7. Endoscopic repair of skull base CSF fistula

CSF leak results from a breach in the dura, which may be spontaneous, secondary to a fracture, related to a surgical trauma or associated with pathology of the skull base and/or secondary to a high-pressure system (Fig 41).

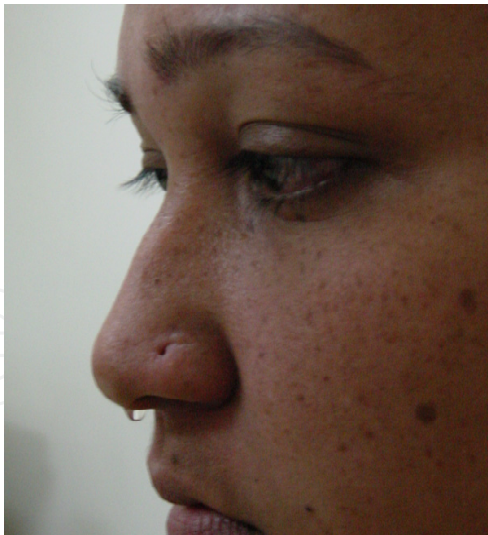

Fig. 41. Picture of an adult obese female presenting with unilateral clear watery spontaneous CSF rhinorrhoea on exertion

7.1 Indications

The main indications for repairing a CSF leak is its association with a 10% risk per year of developing meningitis (Gendeh et al, 1998). Those who have a leak from a fracture of the anterior skull base repaired still have a slightly increased risk of developing meningitis in the future but this is less than those whose leak stops spontaneously. Therefore, active leaks should probably be repaired at any stage.

7.2 Surgical anatomy

The skull base is made up anteriorly of the posterior wall of the frontal sinus, which is a thick frontal bone that extends posteriorly to form roof of ethmoid sinuses(fovea ethmoidalis) on either side of the cribriform plate. The cribriform plate joins the fovea through the lateral lamella and can be almost non-existent when the cribriform plate and fovea ethmoidalis are on the same plane or it can form the thin vertical bone connecting them, depending on how far the cribriform plate dips into the nose (Fig 42). Posteriorly, the sphenoid sinus and posterior ethmoidal air cells form the inferior relationship of the skull base.

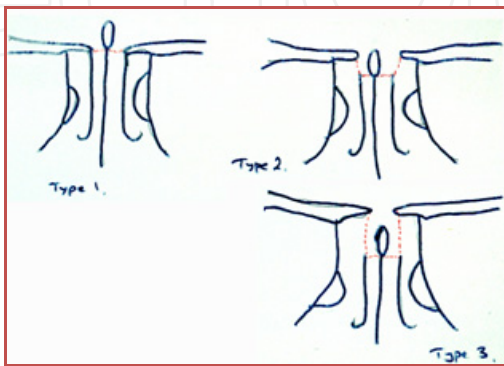


Fig. 42. Keros classification of the anatomy of the cribriform plate which may lie at different level in relation to the anterior skull base

The commonest site of a spontaneous CSF leak is the area of the cribriform plate where dura around the olfactory nerves appears to have extended through the cribriform plate and ruptured (Fig 43). The next most commonest leak is from a very well-pneumatized sphenoid sinus (Fig 44). A high-pressure system may be a contributing factor in these cases and a shunt or ventriculostomy may be required.

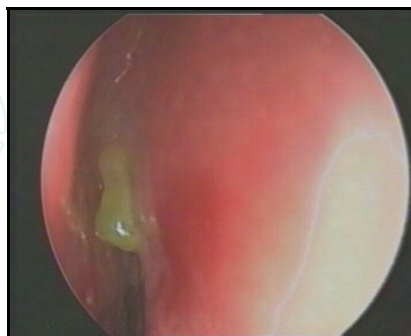


Fig. 43. Intraoperative endoscopic view showing arachnoid granulations arising from the left cribriform area in an obese female presenting with spontaneous cerebro-spinal fluid rhinorrhea

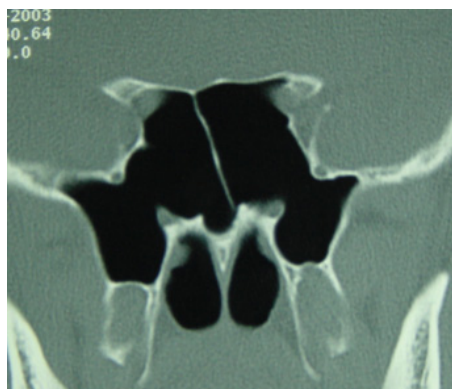

Fig. 44. A coronal CT scan showing a well pneumatized sphenoid sinus

Iatrogenic CSF leaks are often found around the lamina lateralis (the vertical thin bone joining the cribriform plate to the fovea ethmoidalis) near the anterior ethmoidal artery. Post neurosurgical procedure leaks most commonly follow pituitary surgery, come from the posterior wall of frontal sinus when it has not been cranialized and more likely if a pericranial flap has not been used to repair any dural defect.

7.3 Diagnosis

- It is vital to localize the site of a leak (Marshall et al, 2001)
- Fluid collected should be tested for immune-fixation of beta-2-transferrin
- Rule out any high- pressure system leak
- Successful closure depends on localizing the exact site of the fistula

It is essential to confirm the diagnosis with immune-fixation of beta-2-transferrin which is extremely specific and sensitive test (Eljamel, 1993). Unilateral autonomic rhinitis is unusual but can mimic CSF rhinorrhea.

Site of any defect should be defined using high-resolution coronal CT (Lloyd et al, 1994). If CT fails to define the site of the defect, T2-weighted MRI may help which has superseded CT cisternography (Stafford et al, 1996). In a few post-trauma patients the site of leak is uncertain or it could be that there is more than one leak. In dural defects less than 15mm, the 'bath plug' technique is encouraged which consists of introducing a fat plug with vicryl suture into the intra-dural space (Wormald & McDonough, 1997). It is believed that this technique would prevent high pressure from pushing the graft away from the defect (Gendeh et al, 2002). The fat pug can be harvested from the ear lobule. A 4/0 vicryl suture is knotted through one end of the fat plug and the suture is passed down the length of the fat plug. A free mucosal graft about 3 x 3 cm is harvested anterior to the middle turbinate from the contralateral lateral nasal wall. The fat plug is placed below the defect and the malleable frontal sinus probe (Metronic Xomed, Jacksonville, Florida, USA) is used gently to introduce the fat plug through the defect (Wormald and McDonough, 1997). Once the fat plug has been safely introduced through the defect, the plug is stabilized with the probe and the vicryl suture is gently pulled. The seal is tested by placing the patient head down and asking the anaesthetist to perform a forced-inspiration maneuver. No Fluorescein-stained CSF should be seen. The patient is placed head-up (15 degrees) and the free mucosal graft is slid up the vicryl suture until it covers the defect (Fig 45). Ensure that the graft is correctly orientated with the mucosal surface facing the nasal cavity. Fibrin glue is applied and the vicryl suture cut. Gelfoam is placed over the free mucosal graft and fibrin glue is reapplied. No other nasal packing is used.

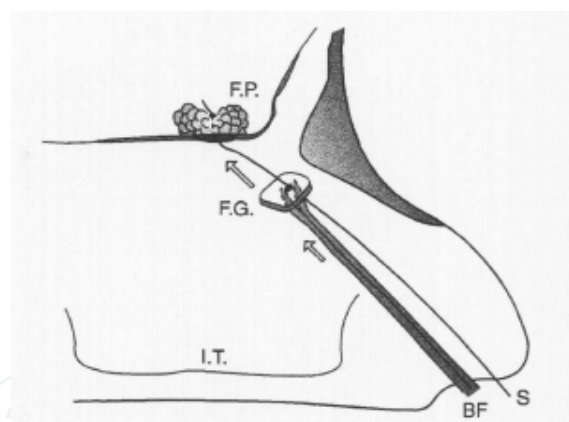


Fig. 45. A diagrammatic sagittal section of the nose showing the a free mucosal graft being slid up the vicry suture to cover the protruding fat plug and skull base defect. Adapted with permission from Wormald and McDonough. *American J Rhinol* 2003; 17:299-305

A diagnostic or pre-operative sodium fluorescein lumbar puncture will help define the source of leak (Fig 46 a). It is vital to ensure that there is a free flow of CSF before proceeding to inject any sodium fluorescein. The patient was skin tested with 2% sodium fluorescein eye drops one day before surgery. A lumbar drain was inserted on the day of surgery and intrathecal sodium fluorescein 10% (0.1% of sodium fluorescein is diluted with 10ml of withdrawn CSF) was given in a slow bolus over 10 minutes to identify site of fistula (Gendeh et al, 2005). The ideal time for the sodium fluorescein to be injected is one hour beforehand. It is a great help to place the patient in a 10 degree head-down position. The

fluid will appear bright yellow, unless a blue filter is used when it appears fluorescent green (Fig 46 b). The systemic clearance of fluorescein is essentially complete by 48 to 72 hours from the patient's body.

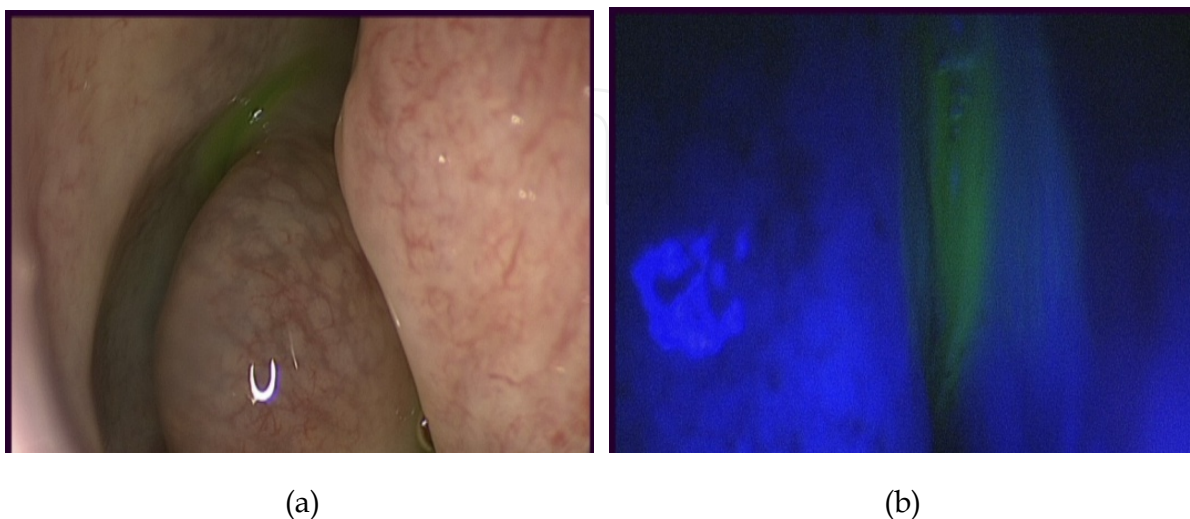


Fig. 46. A 30 degrees endoscopic view showing a spontaneous CSF leak from the anterior cribriform plate using intrathecal sodium fluorescein(a) and highlighted using blue filter(b) in the same patient

The adverse reactions of intrathecal fluorescein administration are nausea, vomiting, gastrointestinal distress, headache, syncope and hypotension. Cardiac arrest, basilar artery ischaemia, severe shock, convulsions, thrombophlebitis at the injection site and rare cases of death have been reported.

7.4 Surgical technique

Initially the repair of CSF fistula involved the use of multi-layered barrier comprised of free tissue grafts harvested from the nasal perichondrium or temporalis fascia. On top of the on lay graft, an abdominal fat graft was used as a bolster and a biological dressing. A fibrin sealant was applied to help fixate the fat graft. Sponge packing (Merocel tampons) were placed intra-nasally to support the fat graft and provide some compression.

We adopted the use of collagen matrix graft (duragen, Intra Life Sciences, USA), which was easy to maneuver, is soft and pliable, thus decreasing the risk of injuring any critical structures as we tuck the graft to overlap the surrounding dural edges of the defect. Duragen is an absorbable and sutureless collagen onlay indicated as dura substitute for the repair of dura mater. We eliminated the routine use of lumbar drains and reserved them for high-risk situations or secondary repairs.

The latest intervention to decrease CSF leaks employs vascularized mucosal flaps which hastens the healing process, especially in patients with prior radiation therapy and make patients more suitable for early postoperative radiation therapy. Hadad and Bassagasteguy from Argentina developed the nasoseptal flap, supplied by the posterior nasoseptal arteries

which are branches of the posterior nasal artery. A mucoperichondrial/mucoperiosteal flap pedicle on the posterior nasal arteries provides a long flap that has a wide arc of rotation and a potential for area of coverage that is superior to any other flap previously described(Fig 47). The flap may be harvested to cover the entire anterior skull base from the frontal sinus to the sella or cover a clival defect from the sella to second cervical vertebra (C2). Use of this flap has to be anticipated in advance, since a posterior septectomy and a wide large sphenoidotomy removes the vascular pedicle. This flap is very reliable and is typically positioned over a fascial graft or fat graft and held in place with fibrin glue and a balloon catheter. We have not observed any significant donor site morbidity with the use of this flap and the septum becomes remucosalized within several months of surgery

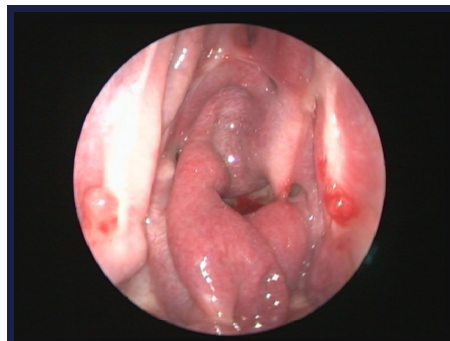
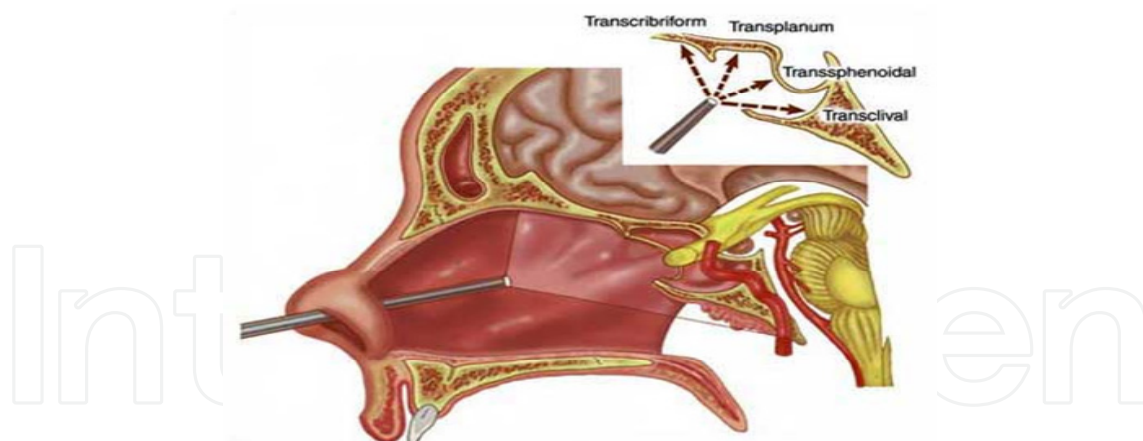


Fig. 47. Endoscopic view of a healed nasoseptal flap repair at 3 months post surgery for a pituitary macroadenoma with evidence of CSF fistula

8. Recent advances in technology and its application to anterior and ventral skull base lesions

There is an ongoing revolution in multiple surgical specialties with the introduction of minimally invasive techniques. A natural extension of ESS has been the application of endoscopic techniques for the surgical treatment of pathologic conditions of the cranial base. This has been driven by the ongoing development of endoscopic technology increasing consumer demand. Furthermore, as the limits of ESS is tested, the possibilities for cranial base surgery are expanded. Truly, it is a maximally invasive endoscopic surgery than minimally invasive surgery.

The Expanded Endo-nasal Approach(EEA) to the ventral skull base provides endoscopic access from the frontal sinus to C2 in the sagittal plane and from the midline to the jugular foramen, internal acoustic canal(IAC) and lateral mass of C2 in the coronal plane (Fig 48). Potential advantages of the EEA not only include improved cosmesis but more importantly, the potential for much less neurovascular manipulation in well selected cases. In pediatric patients, preservation of facial skeleton avoids disruption of growth centers and development of facial asymmetry with further growth. In contrast to an intracranial approach, an endo-nasal approach avoids the need for any brain retraction and may result in less damage to brain tissue. Improved visualization and better access to difficult sites may result in improved oncological outcomes.



Slide Courtesy of the Pittsburgh Otolaryngologists & Neurosurgical team

Fig. 48. Expanded endonasal approaches to base of skull

Advances in cranial base surgery over the last two decades have only been possible with the collaboration of multiple surgical specialties (Kassam et al, 2007). This is more obvious with endoscopic skull base surgery. Rather than working sequentially as is often done with open approaches, surgeons from different speciality work together simultaneously as a team: one person maintaining a view with the endoscope and the other working bimanually to dissect the tissues. The benefits of the two team surgery include improved visualization, increased efficiency and the ability to deal with a crisis such as vascular injury. There is added value of having a 'co-pilot' for problem solving, avoiding complications and modulating enthusiasm.

The primary advantage of the endoscope compared to other methods is improved visualization which accounts for an increased access to difficult to reach areas and may facilitate complete tumor resection and avoidance of complications due to poor visualization. Other potential benefits of endoscopic surgery include improved cosmesis and decreased morbidity from tissue trauma and manipulation of vessels and nerves. The consequences of decreased morbidity are a faster recovery, shortened hospitalization and decreased cost of medical care (Gendeh, 2009).

Familiarity with endoscopic anatomy, proper instrumentation, an experienced surgical team and adherence to endoscopic surgical principles are essential ingredients for avoiding severe complications. The basic principle of endoscopic cranial base surgery is internal debulking of tumor to allow extra-capsular dissection of tumor margin with early identification of neural and vascular structures. This principle is the same for open neurosurgical procedures and sharp dissection of tumor margins is performed without pulling on tumor. Adherence to these fundamental principles minimizes the risk of neural or vascular injury.

In the late 1970s and early 1980s, the combined effort between the Otolaryngologist and neurosurgeons worldwide, made significant strides in the surgical removal of tumors at the base of the skull and brain. These procedures were however disfiguring and painful for the patient. Furthermore, patients encountered long recovery periods and significant risk of complications because the procedures involved large incisions in the face and scalp and removal of parts of the skull to reach the abnormality at the cranial base.

In 1998, a group of Otolaryngologist and neurosurgeons at UPMC in Pittsburgh, USA initiated the first systemic approach to using the nose as a minimally invasive passageway to the brain. They began the extensive process of mapping anatomy and in collaboration with the medical device manufacturers, designed new instruments to make this idea a reality.

By 2000, the Pittsburgh team of doctors had developed the necessary tools and techniques to access tumors located inside the skull by the way of the nose known as EEA. In EEA, the surgeons use endoscopes with light source as well as other instruments especially designed, to treat various types of brain and spinal abnormality. Hence, today surgeons can take out baseball-sized growths without pulling on the brain or touching the normal tissue. This continued refinement of EEA now allows access to an expanded region of the brain, skull base and spine. The classification of endoscopic approaches to cranial base are listed in Table 3.

SAGGITAL PLANE

- Transfrontal
- Transcribriform
- Transplanum (Suprasellar/Subchiasmatic
- Transsphenoidal (Sellar/Medial transclavernous)
- Transclival
 - Posterior clinoid
 - Mid-clivus
 - Foramen magnum
- Transodontoid

CORONAL PLANE

- Transorbital
 - Petrous apex (Medial transpetrous)
 - Lateral transclavernous
 - Transpterygoid
 - Transpetrous
 - Superior
 - Inferior
 - Transcondylar
 - Parapharyngeal space
-

Snyderman CH.2007. Acquisition of surgical skills for endonasal skull base surgery: a training program. Laryngoscope 117(4): 699-705

Table 3. Classification of endoscopic approaches to cranial base

The collaborative effort has put the Otolaryngologist and the neurosurgeon to work closely via the nose using the two-nostril and four hand technique was first advocated by Prof. Dr Heinz Stammberger from Graz, Austria for endoscopic cranial base surgery.

Standardization of training and the adoption of modular, incremental training program are expected to facilitate the gradual training of endo-nasal surgeons in Otolaryngology and Neurosurgical disciplines. Stages of training are established for both surgical speciality based on level of technical difficulty, potential risk of vascular and neural injury and unfamiliar endoscopic anatomy. Mastery of each level is recommended before attempting procedures at higher level. Adherence to such a program during the growth phase of endoscopic skull base surgery may decrease the risk of complications as the surgeon's knowledge and surgical expertise develop (Snyderman et al, 2007).

Complications of EEA are the same as open approaches: neural and vascular injury, infection and CSF leak. Literature report of neural and vascular injury are fortunately rare accounting for 1% incidence. These can be avoided with attention to anatomical landmarks and proper dissection techniques. An experienced team can effectively control venous bleeding from the cavernous sinus or basilar plexus. Peri-operative antibiotic prophylaxis, multilayered repair of dural defects and aggressive management of postoperative CSF leaks are contributing factors. One of the biggest remaining challenges is repair of large dural defects and prevention of post-operative leaks. With the advent of the septal mucosal flap, the Pittsburgh group suggest an incidence of 6% of CSF leak. Developments that have decreased the incidence of postoperative CSF leaks include a multilayered closure, direct suturing of grafts to dural edges, use of biological glues, coverage with vascularized septal mucosal flap and supporting the reconstruction with an intranasal balloon catheter.

9. Acknowledgements

I wish to acknowledge with gratitude the co-operation of the Departments of Otorhinolaryngology - Head and Neck Surgery, Neurosurgery, Endocrinology and Ophthalmology of the National University Malaysia Medical Faculty (UKMMC).

10. References

- Beasley N and Jones NS. 1995. The role of endoscopy in the management of mucocoeles. *American Journal of Rhinology* 9(5): 251-256
- Bolger WE, Parsons DS, Mair EA, Kuhn FA. 1992. Lacrimal drainage system injury in functional endoscopic sinus surgery: Incidence, analysis and preventions. *Archives of Otolaryngol Head Neck Surg* 118(11): 1179-1184
- Bolger WE and Mann CB. 2001. Analysis of the suprabullar and retrobullar recesses for endoscopic sinus surgery. *Annals of Otology, Rhinology and Laryngology* Supplement 186 110(5 part 2): 3-14
- Chow PI, Sadun A, Lee H. 1995. Vascular and morphometry of the optic canal and intracanalicular optic nerve. *J Neuroophthalmol* 15: 186-190
- Chow J and Stankiewicz. 1997. Powered instrumentation in orbital and optic nerve decompression. *Otolaryngol Clin North Am* 30: 467-478
- Conboy PJ and Jones. 2003. The place of endoscopic sinus surgery in the treatment of paranasal sinus mucocoeles. *Clin Otolaryngol* 28: 207-210

- Cook M, Levin L, Joseph M, Pinczower E. 1996. Traumatic optic neuropathy: a meta-analysis. *Arch Otolaryngol Head Neck Surg* 122: 389-392
- Eljamel MSM. 1993. The role of surgery and beta-2-transferrin in the management of cerebrospinal fluid fistula. *MD thesis*. University of Liverpool.
- Gendeh, B.S, Selladurai B.M, Selvapragasam T, Khalid B.A.K, Said H. 1998. The transseptal approaches to pituitary tumours: Technique, rhinologic functions and complications *Asian J Surgery* 21(4): 259-265
- Gendeh BS, Wormald PJ, Forer M, Goh BS, Misiran K. 2002. Endoscopic repair of spontaneous cerebro-spinal fluid rhinorrhoea: a report of 3 cases. *Med J Malaysia* 57(4): 503-508
- Gendeh BS, Mazita A, Selladurai BM, Jegan T, Jeevanan J, Misiran K. 2005. Endoscopic repair of Anterior Skull Base Fistula: The Kuala Lumpur Experience. *J Laryngol Otol* 119: 866-874
- Gendeh BS. 2006. Minimally invasive surgical approaches to the sphenoid sinus, sell, parasellar and clival region. Current and future perspectives. *Med J Malaysia* 61(3); 274-277
- Gendeh BS, Salina H, Selladurai B, Jagan T. 2007. Endoscopic assisted craniofacial resection: A case series and post-operative outcome. *Med J Malaysia* 62(3); 234-237
- Gendeh BS. 2010. Extended applications of endoscopic sinus surgery and its reference to cranial base and pituitary fossa. *Indian J Otolaryngol Head Neck Surg* 62: S 68-S 80.
- Gendeh BS, 2009. Advances in technology and its application to rhinology. In Gendeh BS Ed. *Clinical atlas of nasal endoscopy*. UKM Publication. Pg 114-117
- Hartstein ME, Kokoska M. Woog JJ. 2004. Endoscopic techniques in orbital fracture repair. In Woog JJ, ed *Manual of endoscopic lacrimal and orbital surgery*. Butterworth Heinemann, pp 175-182.
- Hehar SS and Jones NS. 1997. Fronto-ethmoidal osteoma: the place of surgery. *J Laryngol Otol* 111: 372-375
- Howe L and Jones NS. 2004. Guidelines for the management of periorbital cellulitis/abscess. *Clin Otolaryngol* 29: 725-728
- Ikeda K, Suzuki H, Oshima T, Tomonori T. 1999. Endoscopic endonasal repair of orbital floor fracture. *Arch Otolaryngology Head Neck Surg* 125; 59-63
- Jones NS. 1997. Visual evoked potentials in endoscopic and anterior skull base surgery. *Journal of Laryngol and Otology* 111: 513-516(OMIT)
- Jones NS, Bullock P, Hewitt s et al. 1997. Head injuries and the principles of craniofacial repair. In Jones NS, ed. *Craniofacial Trauma: An interdisciplinary approach*. Oxford: Oxford University Press, pp. 18-60
- Jones NS. 1998. Microendoscopy in rhinology. *Minimally Invasive Therapy and Allied Technologies* 7: 149-154
- Jones NS. 1999. Current concepts in the management of paediatric rhinosinusitis. *Journal of Laryngology and Otology* 113: 1-9
- Kassam A, Snyderman, CH and Carrau RL et el. 2007. Introduction, Conclusion. In *The Expanded Endonasal Approach to the Ventral Skull Base: Sagittal Plane*, edited by Snyderman CH. Tuttlingen: Endo-Press
- Kennedy DW. 1985. Functional endoscopic sinus surgery technique. *Arch Otolaryngol Head Neck Surgery* 111:643-649

- Kennedy DW, Josephson JS, Zinreich SJ, Mattox DE, Goldsmith MM. 1989. Endoscopic sinus surgery for mucoceles: a variable alternative. *Laryngoscope* 99:885-889
- Kennedy D.W, Goodstein M.L, Miller N.R, Zinreich. S.J. 1990. Endoscopic transnasal orbit decompression. *Archives of Otolaryngology Head and Neck Surgery*. 116: 275-282
- Khairullah A, Gendeh BS. 2011. Tube extrusion and cheese wiring 5 years post dacryocystorhinostomy: case report. *Phillipine Intn J of Otolaryngol* 26(2): 34-36
- Kountantakis S, Maillard A, El-Harazi S, Longhini L, Urso R. 2000. Endoscopic optic nerve decompression for traumatic blindness. *Otolaryngology Head Neck Surg* 123: 34-37
- Kuppersmith R, Alford E, Patrinely J, Lee A, Parke R, Holds J. 1997. Combined transconjunctival/intranasal endoscopic approach to the optic canal in traumatic optic neuropathy. *Laryngoscope* 107: 311-315
- Lang J. 1989. *Clinical anatomy of the nose, nasal cavity and paranasal sinuses*. Stuttgart: Georg Thieme Verlag
- Lee TS, Shin JC, Woog JJ. 2004. Endoscopic dacryocystorhinostomy: An eastern perspective. In Woog JJ, ed *Manual of endoscopic lacrimal and orbital surgery*. Butterworth Heinemann, pp 123-133.
- Lubben B, Stoll W, Grenzebach U. 2001. Optic nerve decompression in the comatose and conscious patients after trauma. *Laryngoscope* 111: 320-328
- Luxenberger W, Stammberger H, Jebeles J, Walch C. 1998. Endoscopic optic nerve decompression: The graz experience. *Laryngoscope* 108: 873-882
- Marshall A, Jones NS, Robertson IJA. 2001. CSF rhinorrhoea: a multidisciplinary approach to minimise patient morbidity. *British Journal of Neurosurgery* 15(1): 8-13
- Mason JDT, Haynes RJ, Jones NS. 1998. Interpretation of the dilated pupil during endoscopic sinus surgery *J of Laryngol and Otology* 112: 622-627
- Metson R, Dallow R, Shore J. 1994. Endoscopic orbital decompression. *Laryngoscope* 104: 950-957.
- Metson R, Gliklich RE. 1998. Clinical outcomes of endoscopic surgery for frontal sinusitis. *Otolaryngol Head Neck Surg* 124(10): 1090-1096
- Metson R, Samaha M. 2002. Reduction of diplopia following endoscopic orbital decompression: The orbital sling technique. *Laryngoscope* 112: 1753-1757
- Metson R, Samaha M. 2004. Endoscopic orbital decompression. In *Manual of endoscopic lacrimal and orbital surgery*. Editor Woog JJ. Butterworth Heinemann, Elsevier, pg 167-173
- Page EL, Wiatrak BJ. 1996. Endoscopic versus external drainage of orbital subperiosteal abscess. *Arch Otolaryngol Head Neck Surg* 122(7): 737-740
- Setliff R.C. 1994. The "Hummer": New instrumentation for functional endoscopic sinus surgery. *Am J Rhinol*. 8: 275-278.
- Sofferman B. 1995. The recovery potential of the optic nerve. *Laryngoscope* 105: 1-38
- Stafford JDB, Brenan P, Toland J, O'Dwyer AJ. 1996. Magnetic resonance imaging in the evaluation of cerebrospinal fluid fistula. *Clinical Radiology* 51:837-841
- Stammberger H. 1991. *Functional endoscopic sinus surgery: The Messerklinger Technique*. Philadelphia: Brian C Decker
- Steinsapir K, Goldberg R. 1994. Traumatic optic neuropathy. *Surv Ophthalmol* 38: 487-518
- Steinsapir K, Seiff S, Goldberg R. 2002. Traumatic optic neuropathy: where do we stand? *Ophthal Plast Reconstr Surg* 18: 232-234

- Snyderman CH, Kassam A and Carrau RL et al. 2007. Acquisition of Surgical Skills for Endonasal Skull Base Surgery: A Training Program. *Laryngoscope* 117: 699-705
- Tandon DA, Thakar A, Mahapatra AK, Ghosh P. 1994. Transethmoid optic nerve decompression. *Clin Otolaryngol* 19: 98-104
- Umapathy N, Kalra S, Skinner DW, Dapling RB. 2006. Long-term results of endonasal laser dacryocystorhinostomy. *Otolaryngol Head Neck Surgery* 135(1): 81-84
- Vrabac DP. 1994. The inverted Schneiderian papilloma: a 25 year study. *Laryngoscope* 104: 582-605
- Woog JJ. 2004. Endoscopic dacryocystorhinostomy and conjunctivodacryostorhinostomy. In Woog JJ, ed *Manual of endoscopic lacrimal and orbital surgery*. Butterworth Heinemann, pg 105-121.
- Wormald P, McDonough M. 1997. Bath plug technique for the endoscopic management of cerebrospinal fluid leaks. *J Laryngol Otol* 111: 1042-1046
- Wormald P.J. 2002. Powered endoscopic dacryocystorhinostomy. *Laryngoscope*. 112(1): 69-72.
- Wormald PJ and van Hasselt CA. 2003. Endoscopic removal of juvenile angiofibroma. *Otolaryngol Head Neck Surgery* 129: 684-691
- Wormald PJ, Ooi E, van Hasselt CA, Nair S. 2003. Endoscopic removal of sinonasal inverted papilloma including endoscopic medial maxillectomy. *Laryngoscope* 113: 867-873
- Wormald PJ. 2005. Endoscopic orbital decompression for exophthalmos, acute orbital hemorrhage and orbital subperiosteal abscess. In Wormald PJ, ed. *Endoscopic sinus surgery: Anatomy, three-dimensional reconstruction and surgical technique*. Thieme Medical Publishers, Inc, New York. Stuttgart, pg135-140

© 2012 The Author(s). Licensee IntechOpen. This is an open access article distributed under the terms of the [Creative Commons Attribution 3.0 License](https://creativecommons.org/licenses/by/3.0/), which permits unrestricted use, distribution, and reproduction in any medium, provided the original work is properly cited.

IntechOpen

IntechOpen