

We are IntechOpen, the world's leading publisher of Open Access books Built by scientists, for scientists

6,900

Open access books available

186,000

International authors and editors

200M

Downloads

Our authors are among the

154

Countries delivered to

TOP 1%

most cited scientists

12.2%

Contributors from top 500 universities



WEB OF SCIENCE™

Selection of our books indexed in the Book Citation Index
in Web of Science™ Core Collection (BKCI)

Interested in publishing with us?
Contact book.department@intechopen.com

Numbers displayed above are based on latest data collected.
For more information visit www.intechopen.com



Comparing Nomograms of Two Symmetric and Two Asymmetric Intacs® Segments Implantation for Treatment of Pellucid Marginal Degeneration

Luis A. Rodriguez and Anny E. Villegas*

*Corneal Clinic, Centro Medico Docente La Trinidad (CMDLT), Caracas
Venezuela*

1. Introduction

Non-inflammatory progressive corneal ectasia and thinning disease are among the most common abnormalities that refractive surgeons diagnose. Pellucid Marginal Degeneration (PMD) is another ectatic pathology that is rarely detected. PMD is a bilateral, non-inflammatory, progressive peripheral inferior corneal thinning disorder (1,2). Diagnosis is based on the presence of corneal thinning with ectasia characterized by a peripheral band of thinning of the inferior cornea with 1 to 2 mm of normal cornea between this area and the limbus (2,3). The area of thinning typically is epithelialized, clear, avascular, and without lipid deposit. Like keratoconus, PMD is a bilateral progressive disorder although eyes may be asymmetrically affected. Topographic examination is very useful to differentiate this ectatic disorder. The topographic appearance shows a classical “butterfly” pattern that demonstrates large amounts of against-the-rule astigmatism as measured by simulated keratometry and inferior thinning. PMD can also be diagnosed by performing a pachymetric map of the entire cornea, as well as by elevation corneal maps using placido-ring-based videokeratoscopy technology (1).

The etiology of PMD is not clear, and it is not known whether PMD, keratoconus and keratoglobus are distinct diseases or phenotypic variations of the same disorder (4). PMD is usually asymptomatic except for progressive deterioration in uncorrected visual acuity caused by irregular astigmatism (5). Slit-lamp examination shows a peripheral band of thinning with a protrusion (“beer-belly” contour) of the inferior cornea (6,7,8). Topographically, this protrusion in the peripheral inferior cornea has high keratometry powers, radiating toward the center from the inferior oblique meridians, typically in the inferior peripheral cornea. There is an area of flattening in the center of the cornea (5). In transmission electron microscopy of the cornea, abnormal fibrous long-spacing (FSL) collagen with a periodicity of 100 to 110 nm in PMD is revealed, which contrasts with 60 to 64 nm found in normal corneas (9). A study reported in 2002 describes associations with

* None of the authors has a financial or proprietary interest in any material or method mentioned in this article.

vernal keratoconjunctivitis, Marfan's syndrome, ocular hypertension, keratoconus, keratoglobus and hydrops (23).

In the early stages, spectacles and contact lenses are the usual treatment approaches; however, in patients who cannot be rehabilitated with these options, a surgical procedure is necessary (10). Different surgical options include crescentic wedge resection, crescentic lamellar keratoplasty, penetrating keratoplasty, epikeratophakia and thermokeratoplasty. However, all these techniques have disadvantages: unpredictability, irreversibility, long period of rehabilitation and significant complication rates (11-16). Authors suggest the use of intracorneal rings (ICR) in glasses/contact lens-intolerant patients affected by early and moderate PMD with against-the-rule astigmatism and inferior peripheral corneal thickness of >450 μ m (10). Since ICR mechanically lifts the inferior ectasia of PMD, flattens the soft ectatic corneal tissue, and decreases asymmetrical astigmatism, visual acuity is expected to improve following this procedure (17). Intacs® works on the principle of tissue addition. Peripheral distention is directly proportional to the degree of central corneal flattening, and by an arc-shortening effect it manages to change the shape and power of the central cornea in ectatic eyes without weakening the central or the paracentral cornea (17,18). The aspheric shape of the natural cornea reduces aberrations and minimizes refractive error fluctuations as the pupil changes its size, and therefore reduces visual disturbances such as glare and halos. It is important to observe that Intacs® maintains an aspheric cornea. After placement of ring segments, central cornea has been shown to maintain a prolate shape because Intacs® flattens the peripheral cornea more than the central cornea (19). The major objective of corneal ring segment inserts is to reshape the abnormality by neither removing corneal tissue nor touching the central cornea (20). Various reports have been published illustrating either the symmetrical (inserting two same-size segments) or the asymmetrical (inserting two different size segments) Intacs® implantation techniques for the management of PMD. Both these techniques have been independently shown to improve UCVA, BSCVA and topographic findings (9,10).

Intacs® are polymethylmethacrylate crescent-shaped segments with arc length of 150° and inner and outer diameters of 6.8 mm and 8.1 mm respectively. The ring segments are available in sizes ranging in thickness from 0.25 to 0.45 mm (Table 3).

2. Patients and methods

Symmetric ring segments were implanted in ten (10) eyes and asymmetric ring segments were implanted in nine (9) eyes. Swanson nomogram was used to calculate segment thickness in each eye.

De-Centered Cones (Posterior Float 50% outside the 3 mm optical zone)**		
Spherical Equiv	Inferior Intacs®	Superior Intacs®
+1.00 to -2.00	.250 mm	.300 mm
-2.00 to -3.00	.250 mm	.350 mm
-3.00 to -4.00	.300 mm	.400 mm*
-4.00 and -5.00	.300 mm	.450 mm*
-5.00 and higher	.350 mm	.450 mm*

**Keratoconus, Pellucid Marginal Degeneration or "Pellucid Like" Nomogram (24)

The election of using asymmetric and symmetric ring segments was based on spherical equivalent and was randomly chosen.

Besides the demographic details, key parameters evaluated during the preoperative and postoperative examination included: slitlamp microscopy, manifest refraction, spherical equivalent (SE), uncorrected visual acuity (UCVA), corneal pachymetry, tonometry, flat and steep keratometry readings and topography (Orbscan II). Postoperatively patients were evaluated at one month, three months, six months and one year.

3. Surgical procedure

Intacs® implantation was performed under topical anesthesia. After the patients were prepared through corneal hydration with balanced saline solution and sterile fields, the geometric center of the cornea was measured and marked. A radial 2 mm incision was performed in the steep corneal meridian with a diamond knife that was calibrated to 85% corneal depth. A vacuum centering guide - sloped shelf ring connected to a KV2000 vacuum system (Addition Technology® 155 Moffett Park Drive, Suite B-1 Sunnyvale, CA 94089-1330 U.S.A.) was positioned to stabilize the globe. Clockwise and counterclockwise stromal dissectors were introduced into the base of the incision to create stromal tunnels. Intacs® of selected thicknesses were placed in the stromal tunnels from each side of the incision. The incision site was closed with one interrupted 10-0 nylon suture. Post-operative medication included an antibiotic/steroid combination taken every six (6) hours for two (2) weeks. All procedures were uneventful and performed by the same surgeon, (LAR).

4. Statistical analysis

The two groups were analyzed for any bias with respect to age, size of segments, initial values of visual acuity, astigmatism, spherical equivalent, flat and steep keratometry readings. Both groups were found to be comparable.

Our study was descriptive and results were represented as averages and percentages (\pm standard deviations). Confidence intervals were set at 95%.

Paired t test was used to compare the two groups with respect to changes in the following parameters: visual acuity, astigmatism, spherical equivalent, keratometries (flat and steep readings). Visual acuity was expressed in log mar (Snellen equivalent). One-way Anova test was applied to compare the changes in values throughout time in both the symmetric and asymmetric groups. Bonferroni post test was applied in cases where the values were statistically significant. Any value of P less than or equal to 0.05 ($P > 0.05$) was considered statistically significant.

5. Results

Preoperative values in asymmetric group: UCVA 1.00 (log mar); astigmatism: -4.00D; SE: -2.90D, K (flat) 43.09 D; K (steep) 47.02D. (Table 1) UCVA 0.85 (log mar); astigmatism: -4.50D; SE: -2.74D; K (flat) 43.03 D; K (steep) 47.05D. (Table 2)

Tables 1 and 2 show an improvement in visual acuity, reduction in astigmatism, spherical equivalent and decrease in steep and flat keratometry post-op.

Parameter	Initial			Final		
	Mean	SE	CI 95%	Mean	SE	95% CI
Visual Acuity (LogMAR)	1.00	0.14	0.67 - 1.33	0.22	0.04	0.13 - 0.30
Astigmatism	-4.00	0.49	-5.13 - -2.88	-2.11	0.39	-5.25 - -0.55
Spherical Equivalent	-2.90	1.02	-3.08 - -0.06	-1.57	0.62	-3.08 - -0.06
Keratometry Flat	43.09	0.49	41.95 - 44.23	40.79	0.63	39.33 - 42.25
Keratometry Steep	47.02	0.6	45.63 - 48.40	44.51	1.06	42.07 - 46.96

SE: Standard Error; 95% CI: Confidence Interval of mean 95% (Lower - Upper)

Table 1. Initial and Final Values for Visual Acuity (LogMAR), Astigmatism, Spherical Equivalent and Keratometry (Flat and Steep) in Patients with Diagnosis of Pellucid Marginal Degeneration with Insertion Asymmetrical Intacs ® Segments

Parameter	Initial			Final		
	Mean	SE	CI 95%	Mean	SE	95% CI
Visual Acuity (LogMAR)	0.85	0.19	0.42 - 1.28	0.28	0.09	0.09 - 0.48
Astigmatism	-4.50	0.44	-5.5 - -3.5	-3.30	0.54	-4.53 - -2.07
Spherical Equivalent	-2.74	1.08	-5.17 - -0.3	-0.58	0.40	-1.49 - 0.33
Keratometry Flat	43.03	0.27	42.41 - 43.65	42.12	0.50	40.98 - 43.25
Keratometry Steep	47.05	0.79	45.27 - 48.84	45.07	0.48	43.98 - 46.15

SE: Standard Error; 95% CI: Confidence Interval of mean 95% (Lower - Upper)

Table 2. Initial and Final Values for Visual Acuity (LogMAR), Astigmatism, Spherical Equivalent and Keratometry (Flat and Steep) in Patients with Diagnosis of Pellucid Marginal Degeneration with Insertion Symmetrical Intacs ® Segments

The characteristics of the implanted segments were the following:

Asymmetric segments implanted: 300/250 (3), 450/300 (2), 350/250 (2), 450/250 (2).

Symmetric segments implanted: 450 (1), 400 (1), 350 (1), 300 (4), 250 (3).

The asymmetric group had an average age of 29.67 ± 3.42 years, and the symmetric group had an average age of 34.5 ± 3.42 years. The study showed a non-significant statistical difference between the groups (p=0.357).

Visual Acuity in the symmetric group was better than the asymmetric group. In order to compare the two groups and showed a non-significant statistical difference between the two groups (p=0.550). Figure 1

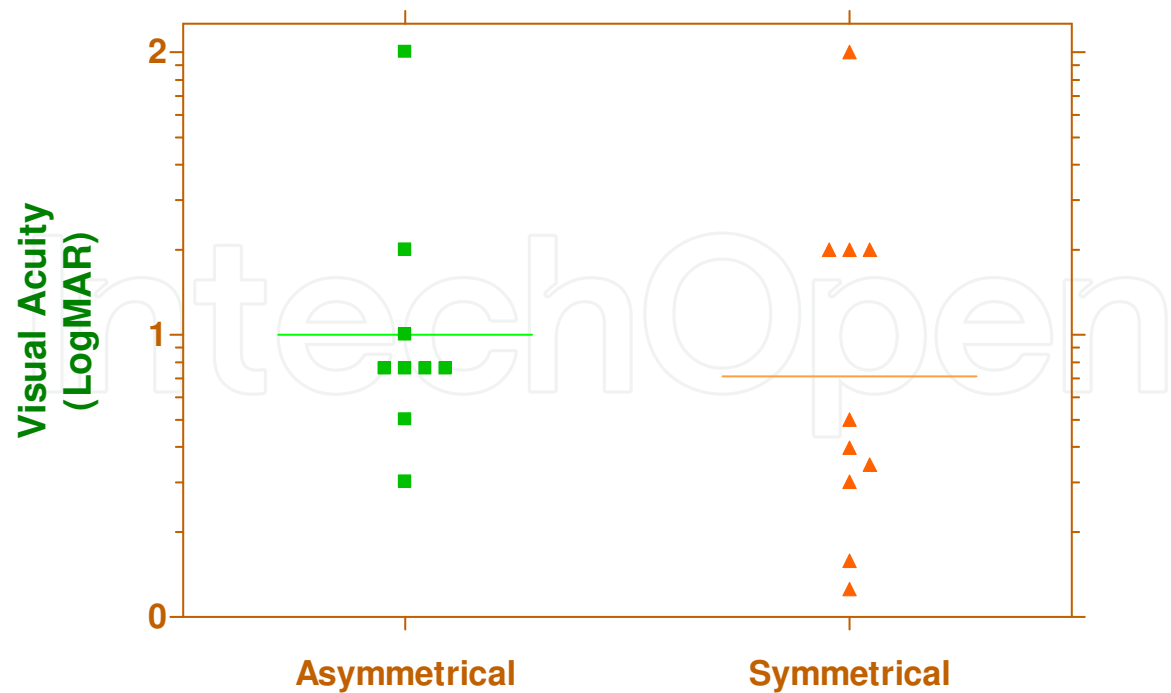


Fig. 1. Initial Values of Visual Acuity in Patients with Diagnosis of Pellucid Marginal Degeneration with Insertion of Symmetrical or Asymmetrical Intacs ® Segments

Spherical equivalent and steep keratometry showed no significant statistical difference in astigmatism between the two groups ($p=0.456$; $p=0.914$; $p=0.647$ respectively). Figure 2, 3 and 4

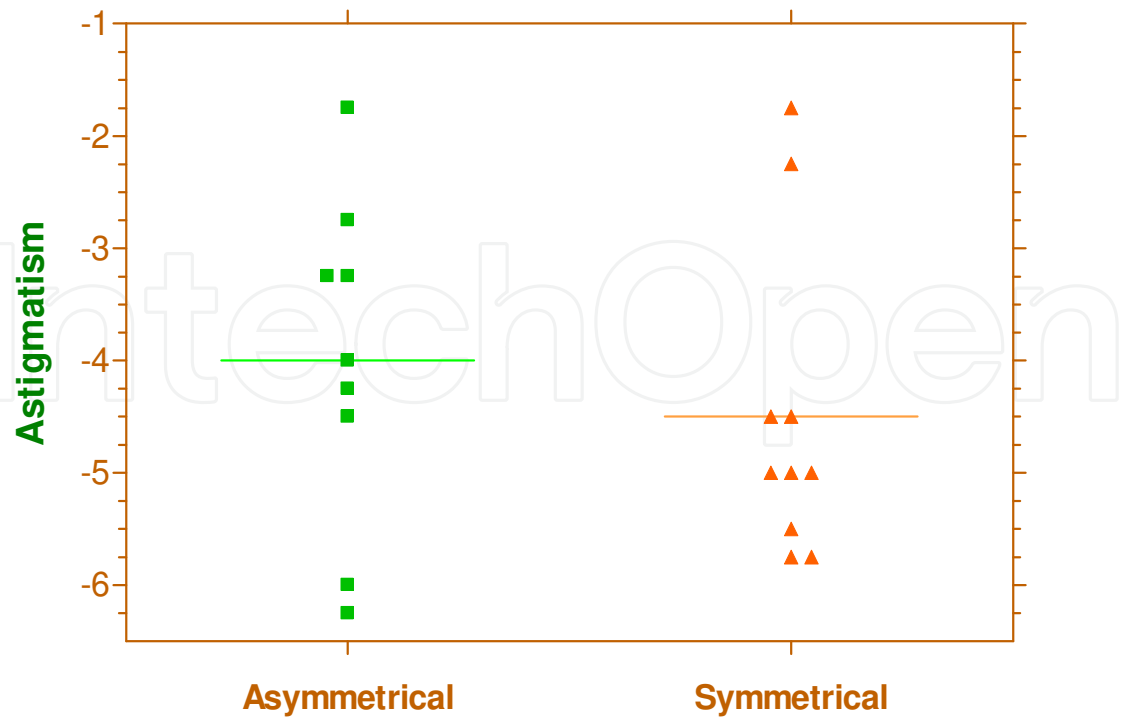


Fig. 2. Initial Values of Astigmatism in Patients with Diagnosis of Pellucid Marginal Degeneration with Insertion of Symmetrical or Asymmetrical Intacs ® Segments

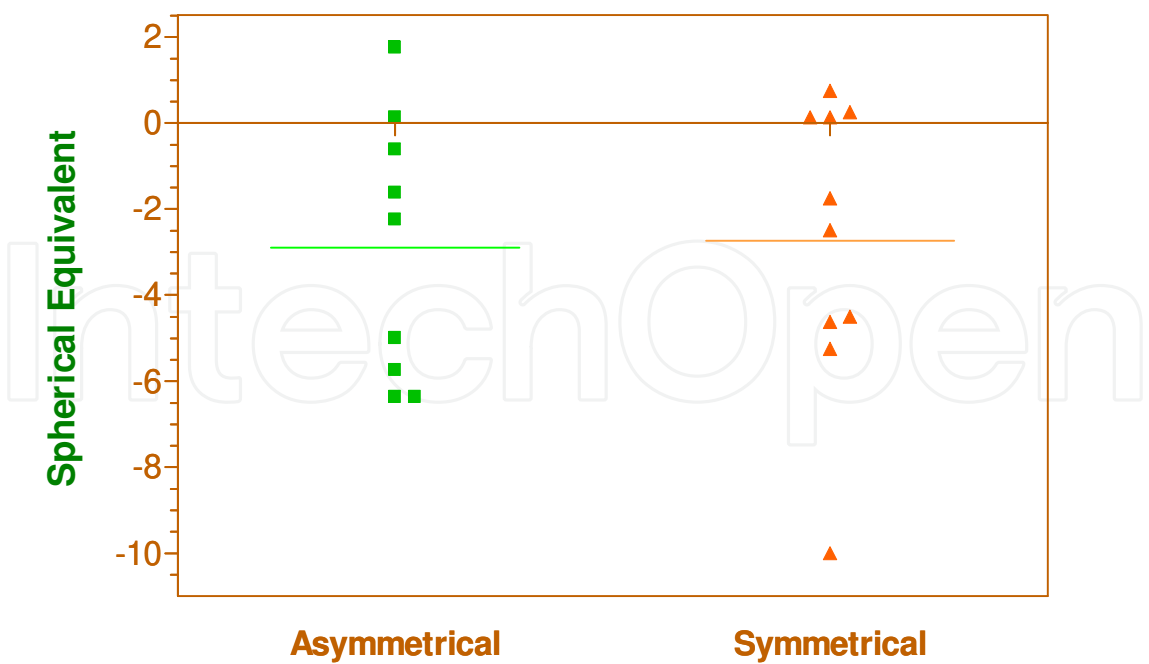


Fig. 3. Initial Values of Spherical Equivalent in Patients with Diagnosis of Pellucid Marginal Degeneration with Insertion of Symmetrical or Asymmetrical Intacs ® Segments

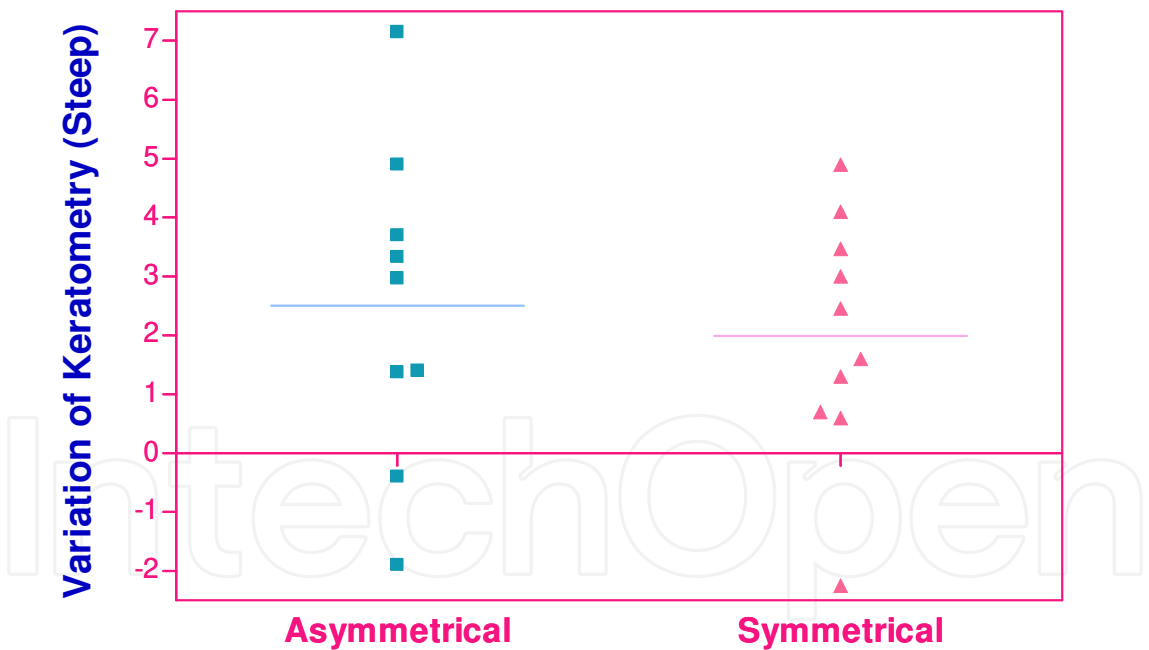


Fig. 4. Variation of Keratometry (Steep) in Patients with Diagnosis of Pellucid Marginal Degeneration with Insertion of Symmetrical or Asymmetrical Intacs ® Segments

After comparing the groups with flat keratometry, a significant statistical difference was found ($p=0.025$). This variation was greater in the asymmetric group. Figure 5

In Figure 6 and 7 the evolution of visual acuity for the asymmetric and symmetric group can be seen. After applying one-way Anova, a significant statistical difference was evidenced ($p<0.0001$ and $p=0.0003$). We subsequently applied the Bonferroni multiple comparison test

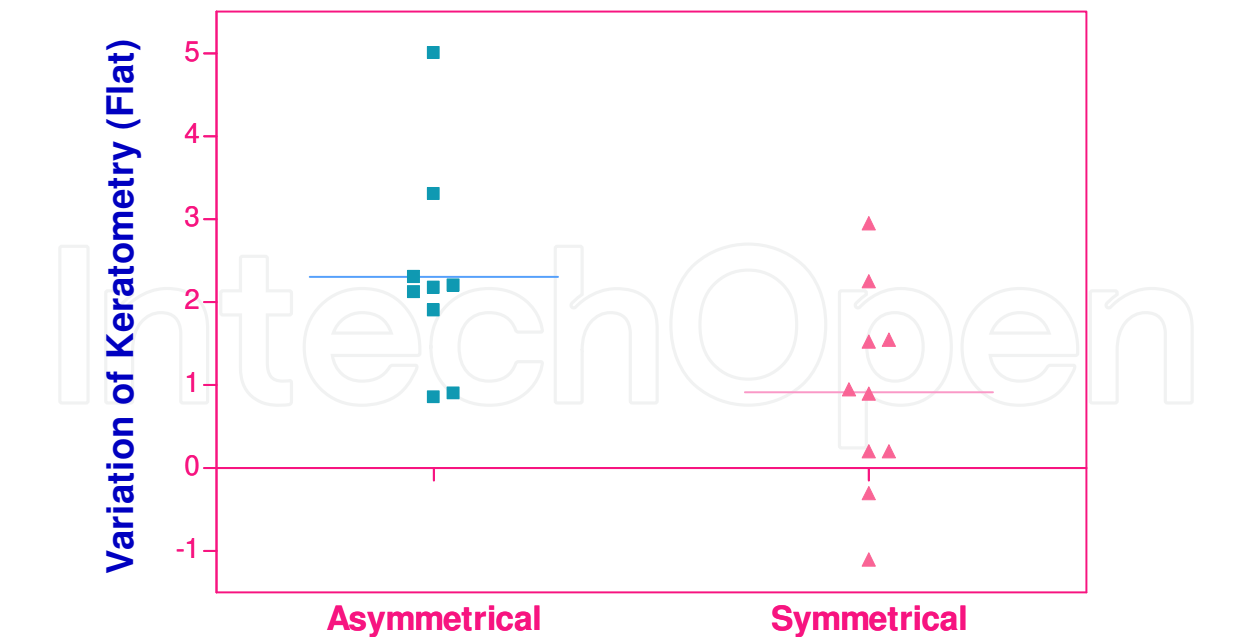


Fig. 5. Variation of Keratometry (Flat) in Patients with Diagnosis of Pellucid Marginal Degeneration with Insertion of Symmetrical or Asymmetrical Intacs ® Segments

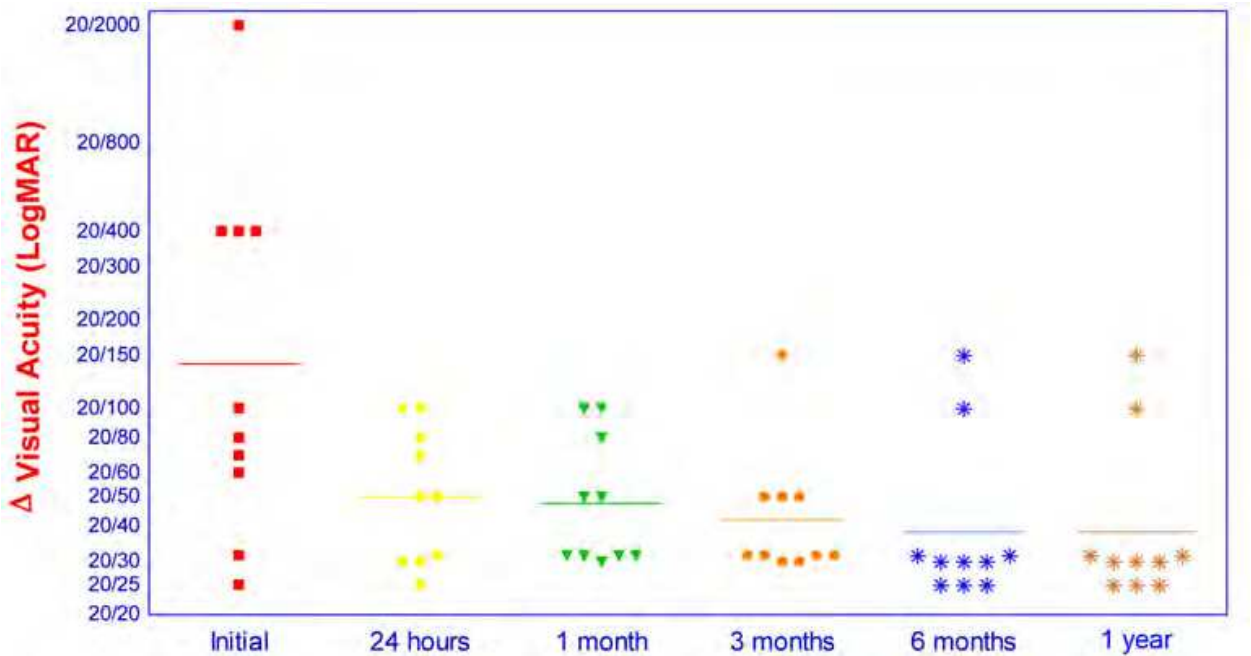


Fig. 6. Time Course of Visual Acuity (LogMAR) in Patients with Diagnosis of Pellucid Marginal Degeneration with Insertion of Asymmetrical Intacs ®

in order to compare each post-operative time period. No significant statistical differences were seen.

In Figure 8 and 9 the evolution of astigmatism for the asymmetric and symmetric group was shown. With the application of one-way Anova, a significant statistical difference was observed in asymmetric group ($p=0.031$) while no significant statistical difference was found postoperatively ($p =0.074$) in symmetric group. The Bonferroni multiple comparison test

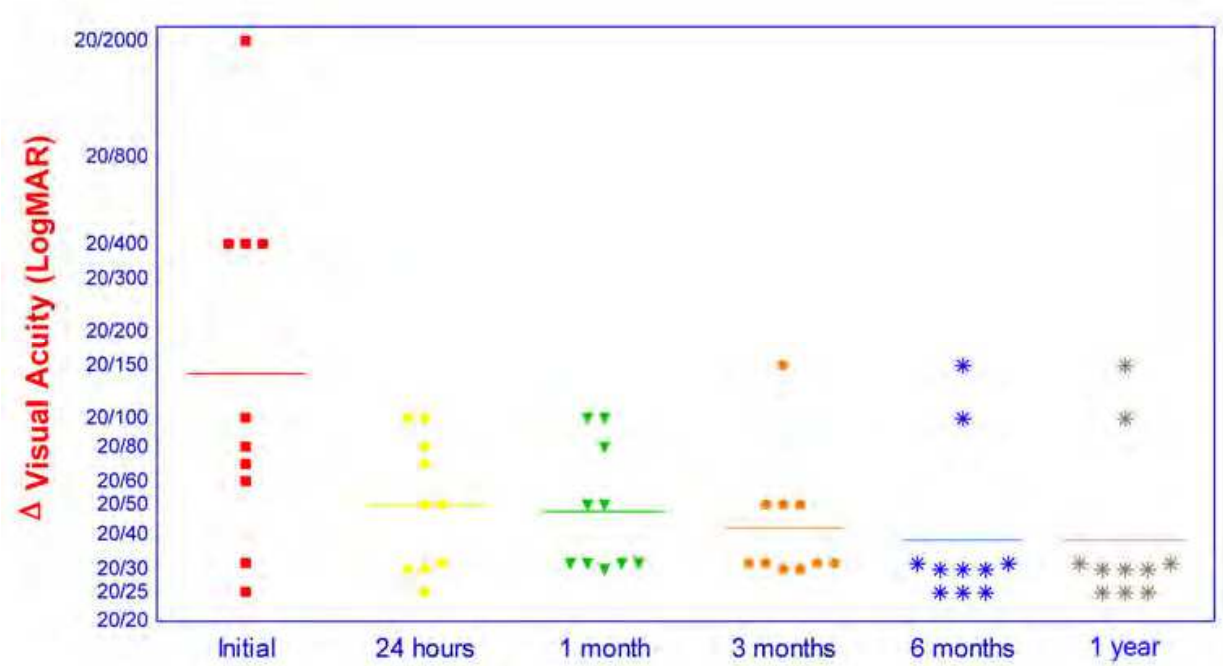


Fig. 7. Time Course of Visual Acuity (LogMAR) in Patients with Diagnosis of Pellucid Marginal Degeneration with Insertion of Symmetrical Intacs ®

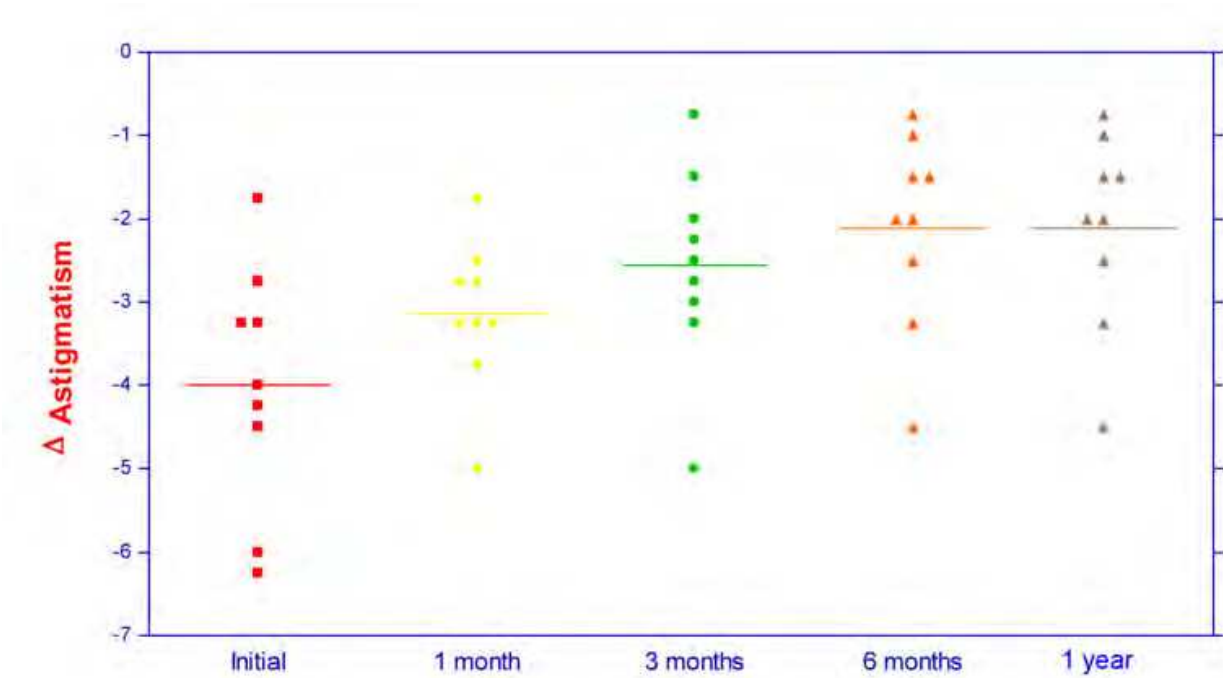


Fig. 8. Time Course of Astigmatism in Patients with Diagnosis of Pellucid Marginal Degeneration with Insertion of Asymmetrical Intacs ®

showed no significant statistical difference between initial and one month, and significant statistical differences between initial and three months and between initial, six months and one year respectively.

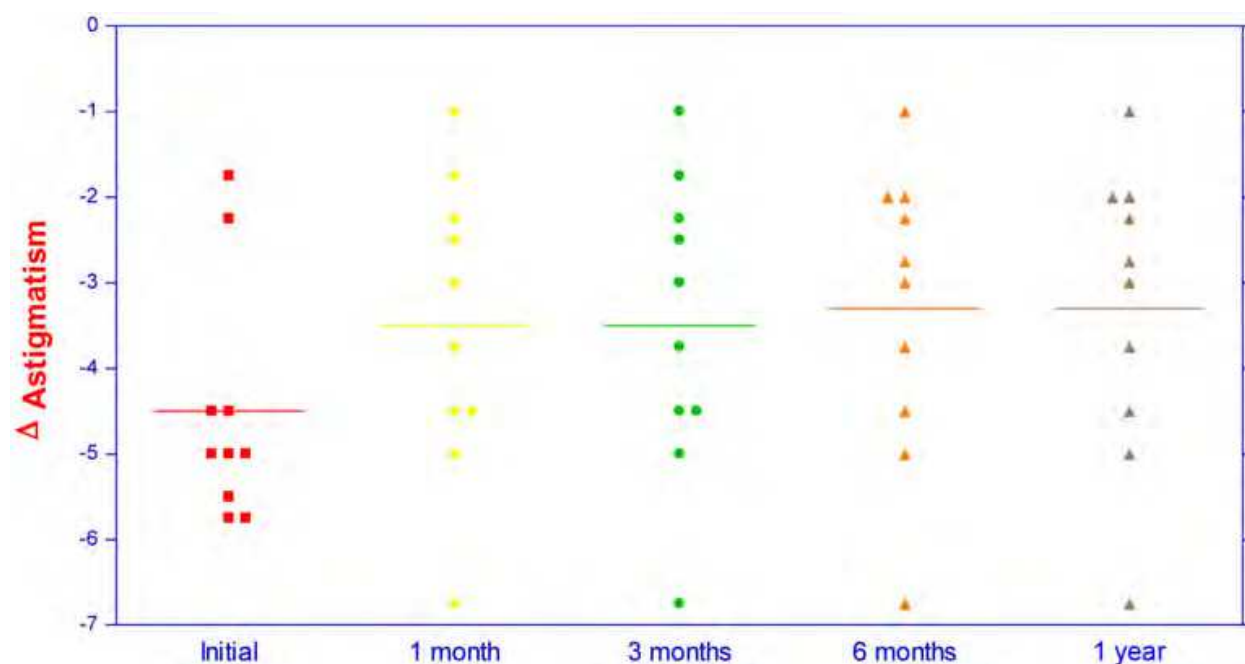


Fig. 9. Time Course of Astigmatism in Patients with Diagnosis of Pellucid Marginal Degeneration with Insertion of Symmetrical Intacs ®

Figures 10 and 11 analyzed the variation of spherical equivalent for the asymmetric and symmetric group. After applying one-way Anova, a significant statistical difference was observed in both groups ($p=0.030$; $p=0.020$). In addition we used the Bonferroni multiple comparison test in order to compare each time period and thereby established that the only difference was between initial and first month postoperatively in asymmetric group and initial with six month and first year in symmetric group.

In Figure 12 the evolution of flat keratometry in the asymmetric group is graphed. After the application of one-way Anova, a significant statistical difference was evidenced ($p=0.005$). We then applied the Bonferroni multiple comparison test in order to compare all the postoperative time periods. The difference found was observed in the comparison between the initial with three months and the initial with six months. No difference was found upon comparing initial with one month, nor when comparing the various time periods after initial (one month, three months, and six months) respectively. No significant statistical difference was observed in symmetric group ($p=0.543$) figure 13.

In Figure 14 the variation in steep keratometry in the asymmetric group was observed. After applying one-way Anova, a significant statistical difference was observed ($p=0.003$). In addition we applied the Bonferroni multiple comparison test in order to compare each time period, and the only difference found was when comparing initial with one month.

In Figure 15 we observed the evolution of steep keratometry in the symmetric group. No significant statistical difference was found when one-way Anova was applied ($p=0.080$).

With respect to the variation in visual acuity (log mar), astigmatism and spherical equivalent, when both groups were compared with the student's t test, no significant statistical difference was found between them ($p=0.366$; $p=0.412$; $p=0.344$ respectively). Figure 16, 17 and 18.

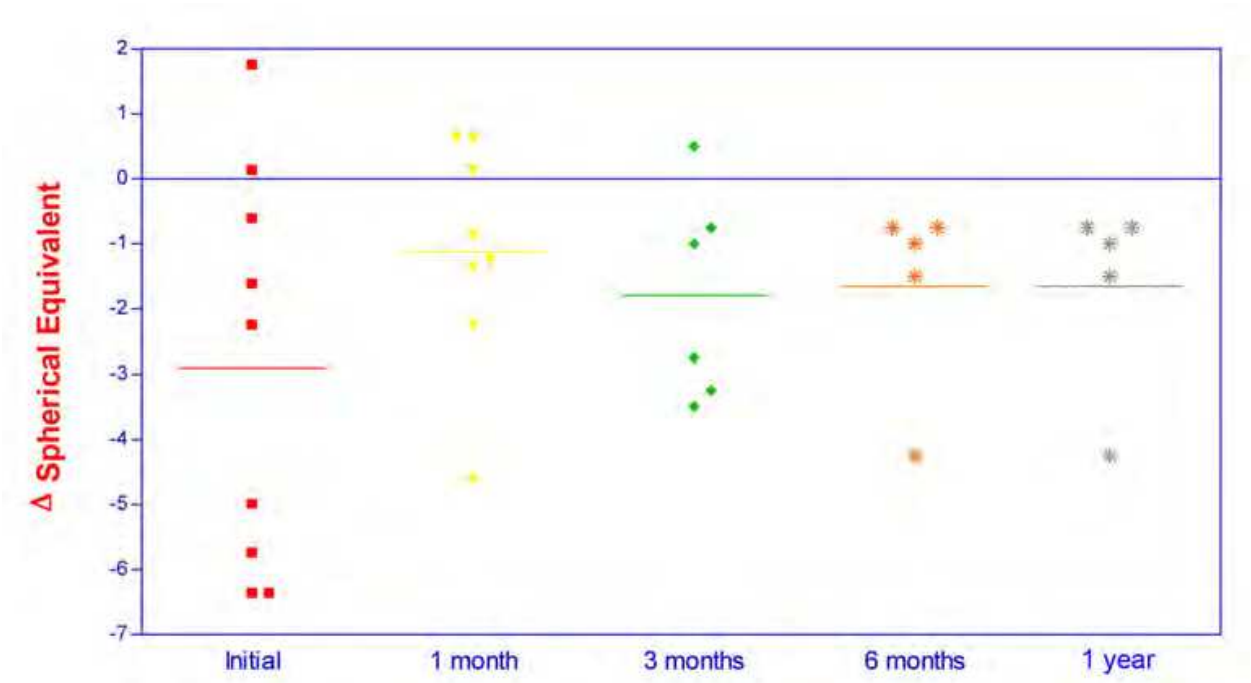


Fig. 10. Time Course of Spherical Equivalent in Patients with Diagnosis of Pellucid Marginal Degeneration with Insertion of Asymmetrical Intacs ®

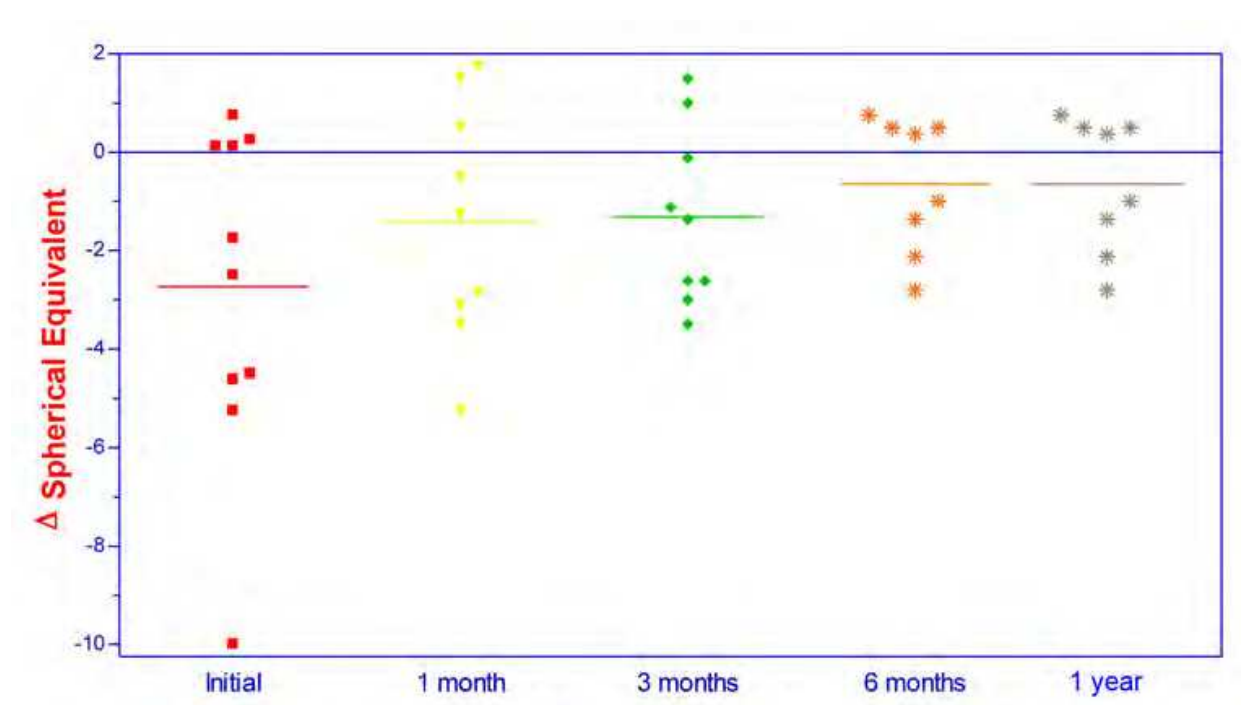


Fig. 11. Time Course of Spherical Equivalent in Patients with Diagnosis of Pellucid Marginal Degeneration with Insertion of Symmetrical Intacs ®

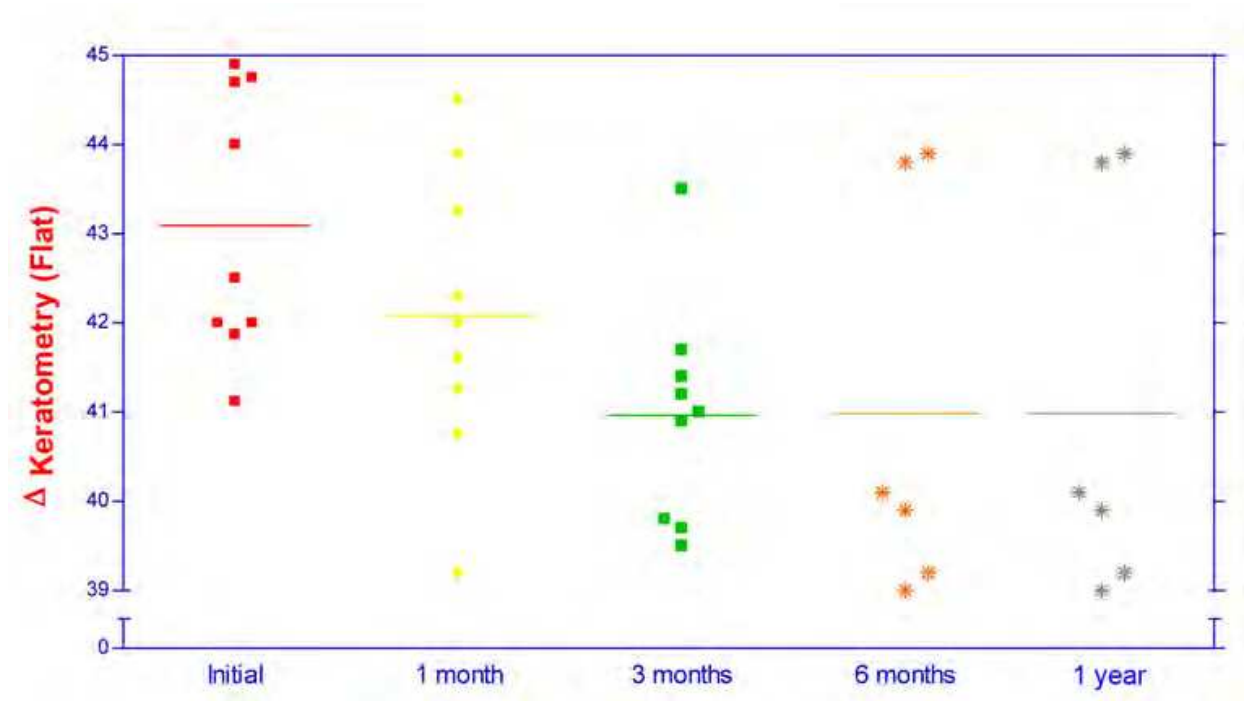


Fig. 12. Time Course of Keratometry (Flat) in Patients with Diagnosis of Pellucid Marginal Degeneration with Insertion of Asymmetrical Intacs ®

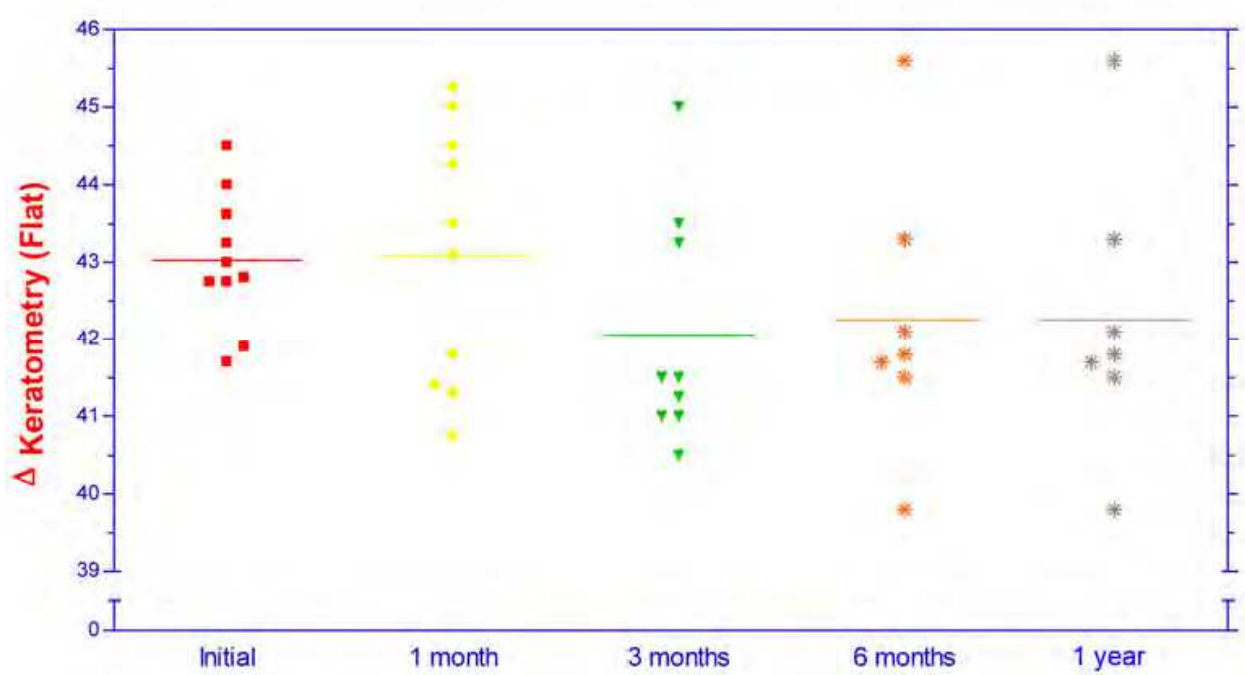


Fig. 13. Time Course of Keratometry (Flat) in Patients with Diagnosis of Pellucid Marginal Degeneration with Insertion of Symmetrical Intacs ®

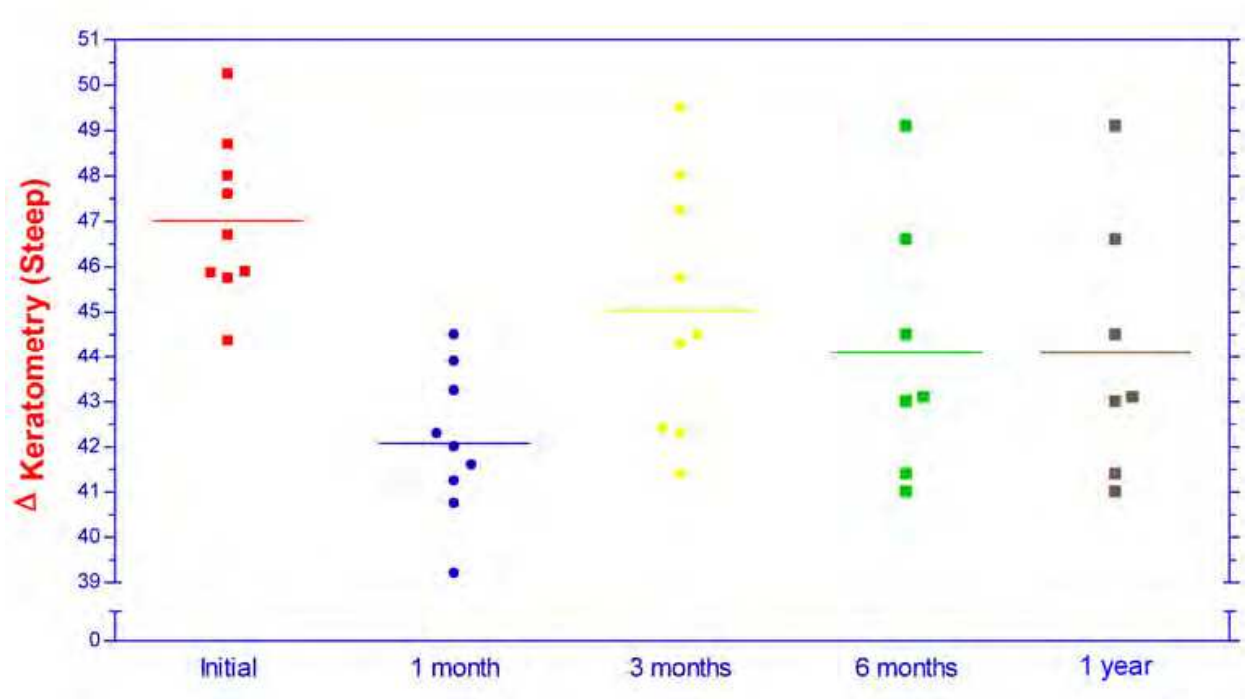


Fig. 14. Time Course of Keratometry (Steep) in Patients with Diagnosis of Pellucid Marginal Degeneration with Insertion of Asymmetrical Intacs ®

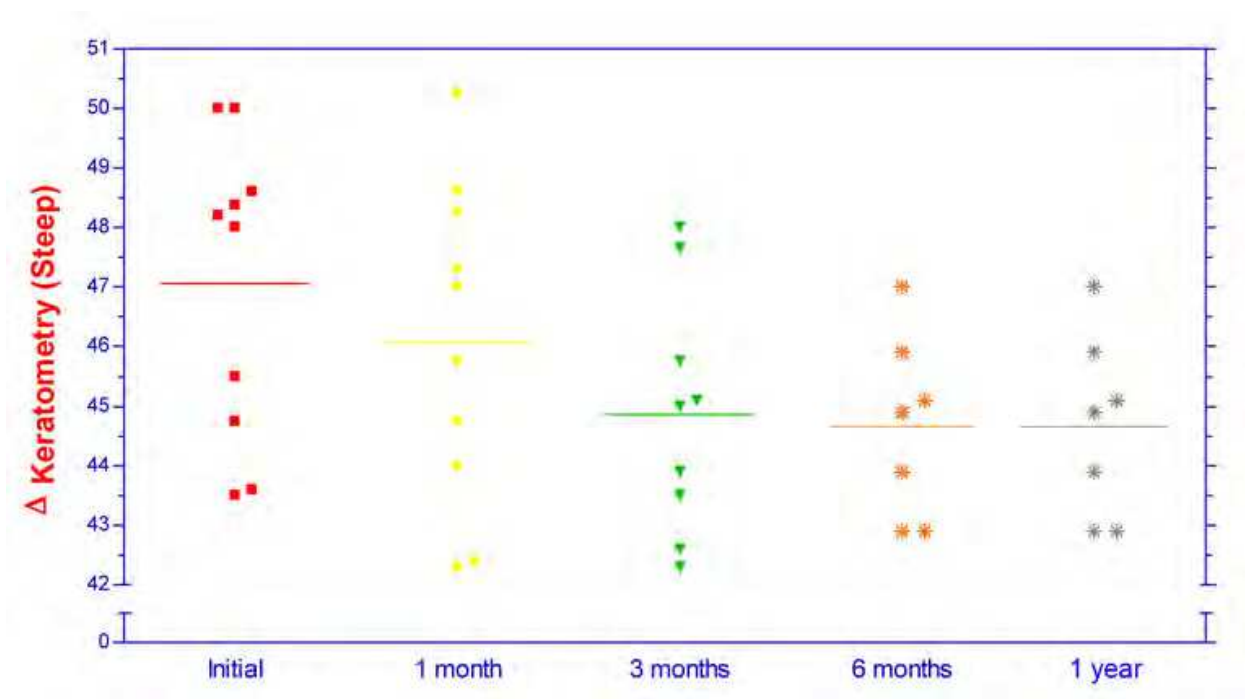


Fig. 15. Time Course of Keratometry (Steep) in Patients with Diagnosis of Pellucid Marginal Degeneration with Insertion of Symmetrical Intacs ®

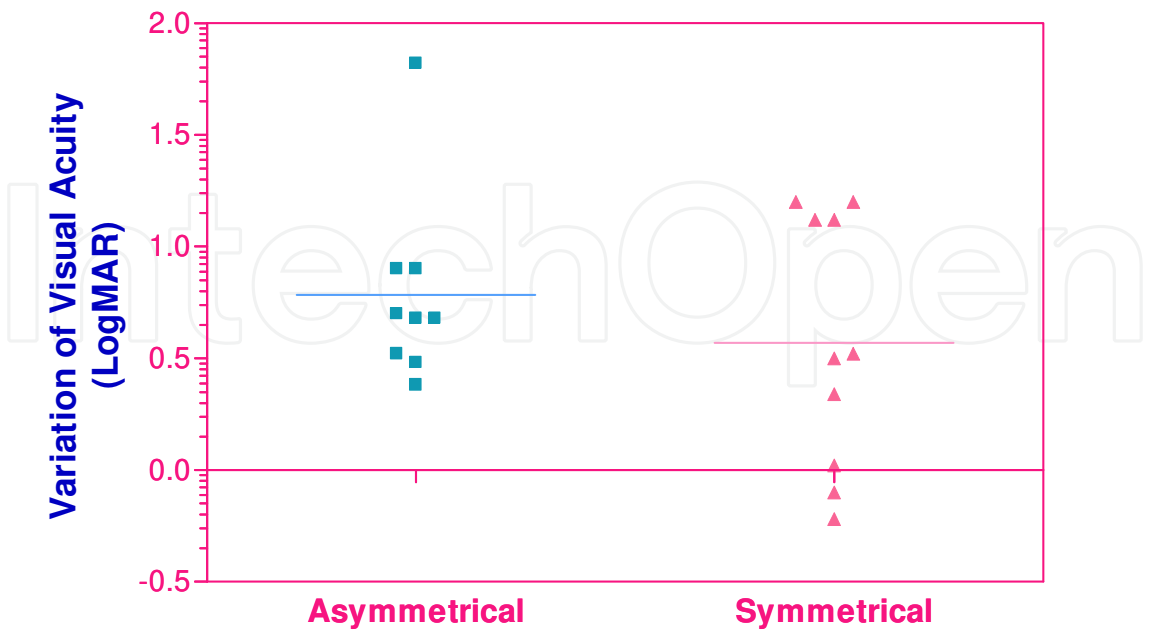


Fig. 16. Variation of Visual Acuity (LogMAR) in Patients with Diagnosis of Pellucid Marginal Degeneration with Insertion of Symmetrical or Asymmetrical Intacs ® Segments

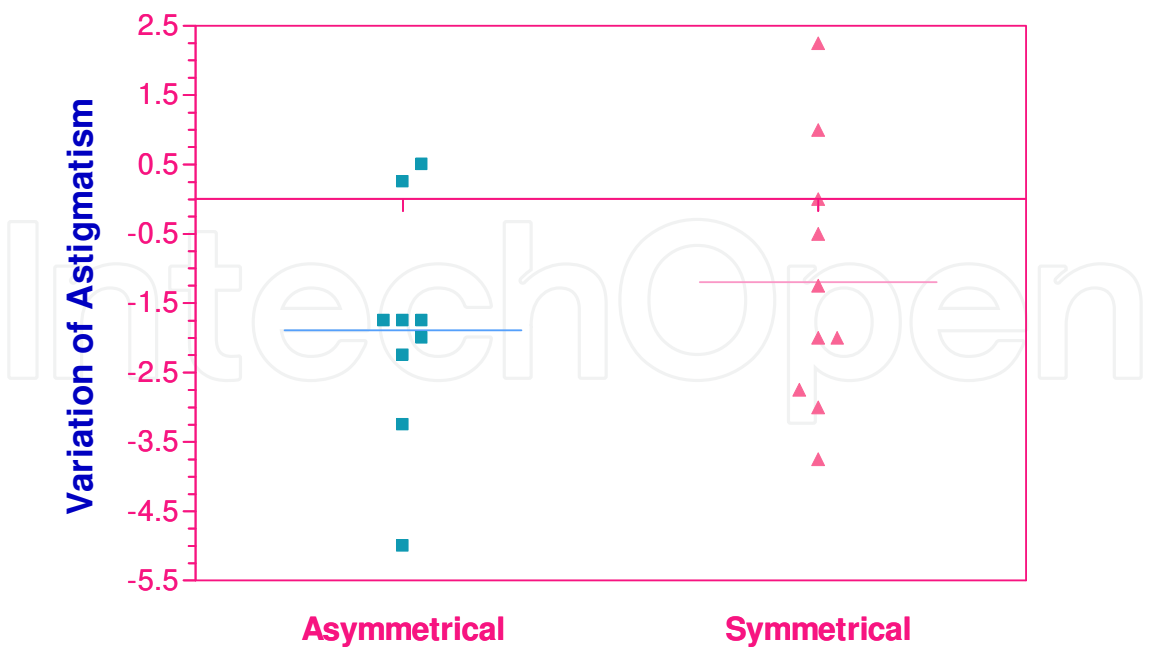


Fig. 17. Variation of Astigmatism in Patients with Diagnosis of Pellucid Marginal Degeneration with Insertion of Symmetrical or Asymmetrical Intacs ® Segments

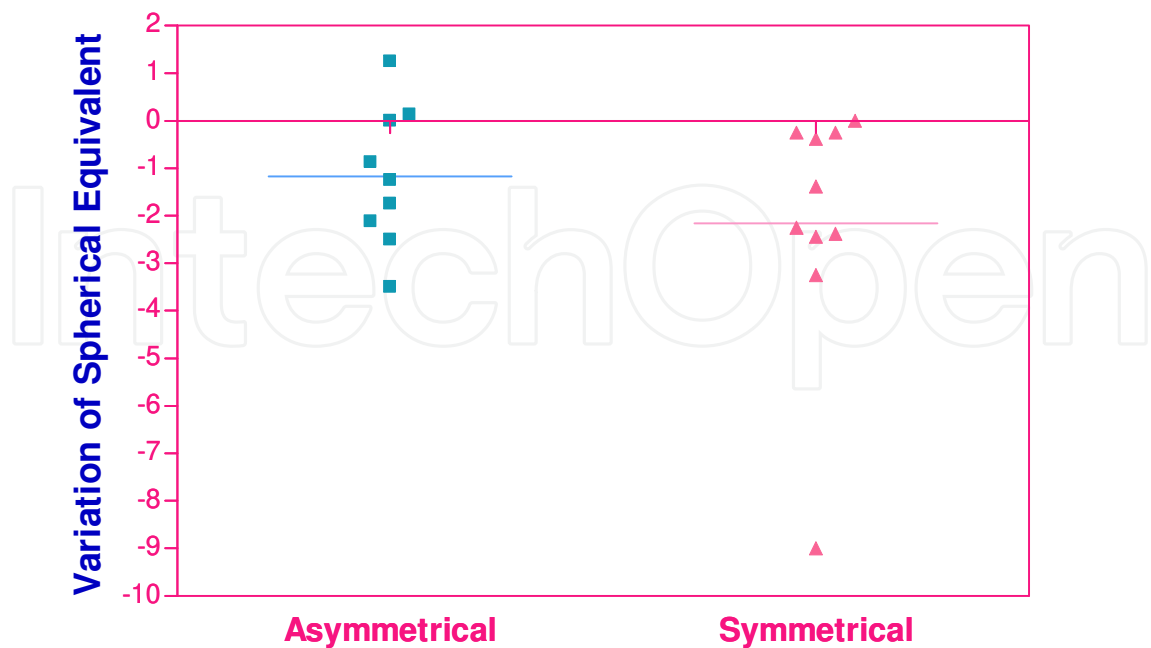


Fig. 18. Variation of Spherical Equivalent in Patients with Diagnosis of Pellucid Marginal Degeneration with Insertion of Symmetrical or Asymmetrical Intacs ® Segments

5.1 Results in asymmetric group

At the end of follow-up period (one year), mean UCVA was 0.22 log mar, ±0,04 (20/30) (95% IC=0.13-0.30). Statistically significant differences were noted throughout the follow-up period (p < 0.0001)

Astigmatism value at final follow-up was -2.11D ±0.39 (95% IC= -5.25 – 0.55). P values at all of the postoperative follow-up periods were statistically significant (p=0.001). The maximum improvement in astigmatism was at three months postoperative.

Spherical equivalent mean value was -1.57D ± 0.62 (95% IC=-3.08- 0.06). The changes in mean spherical equivalent during the follow-up period were statistically significant (p=0.030) with maximum improvement at one month postoperative.

Keratometry flat meridian was 40.79D±0.63 (95% IC= 39.33- 42.25). All the changes in mean readings in flat keratometry were statistically significant (p=0.005). Maximum improvement was between three and six months postoperative.

Keratometry steep meridian was 44.51D±1.06 (95% IC= 42.07 – 46.96). The changes in mean readings in steep keratometry were statistically significant (p=0.003) with maximum improvement at first month.

5.2 Results in symmetric group

Mean UCVA was 0.28 log mar, ±0.09 (20/40) (95% IC=0.09-0.48). Statistically significant differences were noted throughout the follow-up period (p < 0.0003)

Astigmatism value at final follow-up was $-3.30D \pm 0.54$ (95% IC= $-4.53 - 2.07$). At first year, the difference was not statistically significant ($p=0.074$).

Spherical equivalent mean values were $-0.58D \pm 0.40$ (95% IC= $-1.49 - 0.33$). The difference was statistically significant ($p=0.020$) with maximum improvement at six months postoperative.

Keratometry flat meridian value was $42.12D \pm 0.50$ (95% IC= $40.98 - 43.25$). At first year, the difference was not statistically significant ($p=0.543$).

Keratometry steep meridian was $45.07D \pm 0.48$ (95% IC= $43.98 - 46.15$). At first year postoperative the difference was not statistically significant ($p=0.080$).

5.3 Comparing results of both groups

Initial visual acuity values were not statistically different between both groups ($p=0.550$).

Astigmatism initial values were not statistically significant between both groups. ($p=0.456$). Spherical equivalent values were not statistically significant between both groups ($p=0.914$). Keratomeries (flat and steep) meridian initial values were not statistically significant between both groups ($p=0.905$ symmetric group), ($p=0.972$ asymmetric group).

UCVA was not statistically significant between the groups ($p=0.366$). The difference of final post-op values in astigmatism for the groups was not statistically significant. ($p=0.412$). The difference of spherical equivalent values at six months post-op between the groups was not statistically significant ($p=0.344$). The difference of keratometry flat values at six months post-op between the groups was significant ($p=0.025$) with a better result in the asymmetric group. Keratometry steep values at one year postoperatively in both groups were not statistically significant. ($p=0.647$).

6. Discussion

Pellucid marginal degeneration (PMD) is a disease with a complicated prognosis in patients who are intolerant to contact lenses (10). Different procedures have been used to treat PMD with unpredictable results. Symmetric and asymmetric Intacs® segments are relatively new devices that reinforce the cornea through the arc-shortening effect of the corneal lamellae that produces flattening of the central cornea. The goal of using Intacs® for PMD is to reshape the cornea without removing tissue by lifting the inferior ectasia, flattening the soft ectatic corneal tissue and decreasing astigmatism. With this treatment, tissue and endothelium is maintained with the benefit that an additive surgical approach is used that adds rigidity and reinforces the ectatic cornea, flattening the central area, and positioning the optical zone in the center of the pupil. This procedure is also reversible. Mularoni et al. proposed a treatment with two asymmetric intracorneal segments in patients with intolerance to contact lenses and early and moderate PMD. Results were great improvement in UCVA, BSCVA and topographical findings (10). Colin J. and Malet F. implanted two symmetric Intacs® segments and followed the progress for two years post operatively obtaining favorable results. The findings in this study indicated that Intacs® segments are an effective long-term treatment for keratoconus and associated ectasia (21). Kymionis et al. reported a case of PMD treated with Intacs® symmetric

segments which reported an improvement in corneal topographic pattern. ICR insertion can reduce the corneal steepening and astigmatism associated with PMD (9). Rodriguez Prats et al. reported a reduction of steepening and astigmatism associated with PMD by implanting one inferior segment (17). Sharma M. and Boxer Wachler noted that placement of inferior segment Intacs® alone was more suitable than double segments Intacs® insertion for peripherally located cones (22). Alió et al found that by implanting either one or two segments produced a similar effect in the reduction of the refractive cylinder and the keratometric readings (19). Both methods have similar results especially when concerning the visual acuity.

In our study, we compared implanting two segments in an asymmetric group to implanting two segments in a symmetric group, with a slightly better result in UCVA in the asymmetric group. When we evaluated BCVA, UCVA, spherical equivalent, astigmatism and keratometric readings, the differences between preop and postop values in all parameters were significantly reduced in both groups with statistically significant differences.

We noted that when analyzing nomograms of the symmetric and asymmetric groups, there were no statistically significant differences when comparing the results of both procedures. This is mainly due to similar spherical equivalent and showed that both nomograms were effective. Both groups tolerated spectacles and contact lenses well after the procedures.

In the asymmetric group we implanted intracorneal segments that were thicker in the protrusion area and thinner in the flatter area, taking spherical equivalent into account. This could possibly have led to an overcorrection with the implantation of the thicker segment. When implanting thicker segments in the thinner protrusion area, great skill was used so as not to perforate the cornea or extrude the segment. In the symmetric group we implanted two same thickness segments, also dependent on spherical equivalent. In symmetric implantations there are more articles available that reported success in keratoconus and other ectasias. By implanting thinner segments in the protrusion area, undercorrection was a possibility. The advantage of implanting two segments was that corneal prolate is maintained.

7. References


- [1] Sridhar MS, Mahesh S, Bansal AK, Nutheti R, Rao GN. Pellucid marginal corneal degeneration. *Ophthalmology* 2004; 1102-7
- [2] Rabinowitz YS, Keratoconus. *Surv Ophthalmology* 1998; 297-319
- [3] Karim Rasheed, Yaron Rabinowitz, MD, Pellucid Marginal Degeneration. *Emecine*
- [4] Santos RM, Bechara SJ, Kara-Jose N. Corneal topography in asymptomatic family members of a patient with pellucid marginal degeneration. *Am J Ophthalmology* 1999; 205-207.
- [5] Kymionis GD, Aslanides IM, Siganos CS, Pallikaris IG. Intacs® for early pellucid marginal degeneration. *J Cataract Refract Surg* 2004; 230-233
- [6] Schlaeppi V., La dystrophie marginale inferieure pellucid de la cornee. *Mod Probl Ophthalmology* 1957; 672-677

- [7] Maguire LJ, Klyce SD, McDonald ME, Kauffmann HE, Corneal topography of pellucid marginal degeneration. *Ophthalmology* 1987; 519-24
- [8] Maeda N, Klyce SD, Tano Y. Detection and classification of mild irregular astigmatism in patients with good visual acuity. *Surv Ophthalmology* 1998; 53-8
- [9] Rodriguez MM, Newsome DA, Krachmer JH. Pellucid marginal cornea degeneration: a clinical pathologic study of two cases. *Exp Eye Res* 1981; 277-288
- [10] Mularoni A, Torreggiani A, Di Biase A, Laffi GL, Tassinari G, Conservative Treatment of Early and Moderate Pellucid Marginal Degeneration. *Ophthalmology* 2005; 660-666
- [11] Rodriguez-Gonzales-Herrero ME, Gutierrez Ortega AR, De Imperial Mora-Figueroa Jm, Surgical treatment of pellucid marginal degeneration associated with cataract [letter]. *J Cataract Refract Surg* 2000; 309-11
- [12] Cameron JA, results of lamellar crescentic resection for pellucid marginal degeneration. *IS J Ophthalmology* 1992; 296-302
- [13] Kremer I, Sperber LT, Laibson PR. Pellucid marginal degeneration treated by lamellar and penetrating keratoplasty [letter]. *Arch Ophthalmology* 1993; 169-70
- [14] Colin J, Cochener B, Savary G, Malet f. Correcting keratoconus with intracorneal rings. *J Cataract Refract Surg* 2000; 1117-22
- [15] Holmes-Higgins DK, Burris TE, INTACS® Study Group. Corneal surface topography and associated visual performance with INTACS® for myopia. Phase III clinical trial results. *Ophthalmology* 2000; 2061-71
- [16] Kymionis GD, Siganos CS, Kounis G, et al. Management of post-LASIK corneal ectasia with Intacs® insert: one year results. *Arch Ophthalmology* 2003; 332-6.
- [17] Rodriguez-Prats J, Galal Ahmed, Garcia-Lledo Magdalena, et al. Intracorneal rings for the correction of pellucid marginal degeneration *Cataract Refract Surg* 2003; 1421-1424
- [18] Burris TE, Baker PC, Ayer CT, et al. Flattening of central corneal curvature with intrastromal corneal rings of increasing thickness: an eye-bank eye study. *J Cataract Refract Surg* 1993; 182-7.
- [19] J.L. Alió, A Artola, A. Hassanein, H Haroun, A Galal, One or two Intacs® segments for the correction of keratoconus. *J Cataract Refract Surg* 2005; 943-953
- [20] Colin J, Velou S, Implantation of Intacs® and a refractive intraocular lens to correct keratoconus. *J Cataract Refract Surg* 2003; 832-834
- [21] Colin J, Cochener B, Savary G, et al. Intacs® inserts for treating keratoconus: one-year results. *Ophthalmology* 2001; 1409-1414
- [22] Sharma M, Boxer Wachler BS. Comparison of single-segment and Double-segment Intacs® for keratoconus and post-LASIK ectasia. *Am J Ophthalmology* 2006; 891-895
- [23] M.S Sridhar, S Mahesh, A.K Bansal, Rishita Nutheti, G.N. Pellucid marginal corneal degeneration. International Center for Advancement of Rural Eye Care, L.V. Prasad Eye Institute, Hyderabad, India. Presented as a poster at: American Academy of Ophthalmology and Pan-American Association of Ophthalmology Joint Meeting, October 20-23, 2002; Orlando.

- [24] Swanson M. Developing Solutions for the Ectatic Cornea. Uploaded 2010. Available on web site: <http://www.swannkeratoconus.com/main/mnoms.html>

IntechOpen

IntechOpen



Advances in Ophthalmology

Edited by Dr Shimon Rumelt

ISBN 978-953-51-0248-9

Hard cover, 568 pages

Publisher InTech

Published online 07, March, 2012

Published in print edition March, 2012

This book focuses on the different aspects of ophthalmology - the medical science of diagnosis and treatment of eye disorders. Ophthalmology is divided into various clinical subspecialties, such as cornea, cataract, glaucoma, uveitis, retina, neuro-ophthalmology, pediatric ophthalmology, oncology, pathology, and oculoplastics. This book incorporates new developments as well as future perspectives in ophthalmology and is a balanced product between covering a wide range of diseases and expedited publication. It is intended to be the appetizer for other books to follow. Ophthalmologists, researchers, specialists, trainees, and general practitioners with an interest in ophthalmology will find this book interesting and useful.

How to reference

In order to correctly reference this scholarly work, feel free to copy and paste the following:

Luis A. Rodriguez and Anny E. Villegas (2012). Comparing Nomograms of Two Symmetric and Two Asymmetric Intacs(r) Segments Implantation for Treatment of Pellucid Marginal Degeneration, *Advances in Ophthalmology*, Dr Shimon Rumelt (Ed.), ISBN: 978-953-51-0248-9, InTech, Available from: <http://www.intechopen.com/books/advances-in-ophthalmology/comparing-nomograms-of-two-symmetric-and-two-asymmetric-intacs-segments-implantation-for-treatment-o>

INTECH
open science | open minds

InTech Europe

University Campus STeP Ri
Slavka Krautzeka 83/A
51000 Rijeka, Croatia
Phone: +385 (51) 770 447
Fax: +385 (51) 686 166
www.intechopen.com

InTech China

Unit 405, Office Block, Hotel Equatorial Shanghai
No.65, Yan An Road (West), Shanghai, 200040, China
中国上海市延安西路65号上海国际贵都大饭店办公楼405单元
Phone: +86-21-62489820
Fax: +86-21-62489821

© 2012 The Author(s). Licensee IntechOpen. This is an open access article distributed under the terms of the [Creative Commons Attribution 3.0 License](https://creativecommons.org/licenses/by/3.0/), which permits unrestricted use, distribution, and reproduction in any medium, provided the original work is properly cited.

IntechOpen

IntechOpen