

We are IntechOpen, the world's leading publisher of Open Access books Built by scientists, for scientists

6,900

Open access books available

185,000

International authors and editors

200M

Downloads

Our authors are among the

154

Countries delivered to

TOP 1%

most cited scientists

12.2%

Contributors from top 500 universities



WEB OF SCIENCE™

Selection of our books indexed in the Book Citation Index
in Web of Science™ Core Collection (BKCI)

Interested in publishing with us?
Contact book.department@intechopen.com

Numbers displayed above are based on latest data collected.
For more information visit www.intechopen.com



Functional and Aesthetic Reconstruction of the Defects Following the Hemiglossectomy in Patients with Oropharyngeal Cancer

Mutsumi Okazaki

*Department of Plastic and Reconstructive Surgery, Graduate School,
Tokyo Medical and Dental University, Tokyo
Japan*

1. Introduction

In the patients who undergo the hemiglossectomy and reconstruction with free flap transfer, remaining oropharyngeal tissue and function is relatively large, and majority of patients recover speech and eating function, which allow them to live a normal life. Actually, many reports have described that the functional results are generally good after the reconstruction with flaps following hemiglossectomy [1-9]. However, it is rather difficult to perform the reconstruction that makes the best of remaining tissue and function. In this chapter, we describe our reconstructive concept and procedures from the plastic surgeon's standpoint, together with presenting the unfavorable results.

2. Concept of reconstruction and operative procedure

We itemize our concepts for the reconstruction of the defects following hemiglossectomy. The schematic of our reconstructive procedures is shown in Fig.1 and 2.

1. Employ long but not-voluminous flap because the short and voluminous flap spoil the tongue movement.

The length of flap corresponded to "epiglottic vallecula ~ lingual apex" requires 15~17 cm. The short flap less than 14 cm restricts thrust function of the tongue because the transferred flap has a tendency to shrink longitudinally after the operation. On the other hand, the volume of the flap should not be so large. Because the volume of remaining tongue is preserved enough for the eating function in the patients with hemiglossectomy, voluminous flap does not help but spoil eating and speech function.

2. Restore mobile tongue with long, narrow, and thin flap (Fig. 1 (A)).

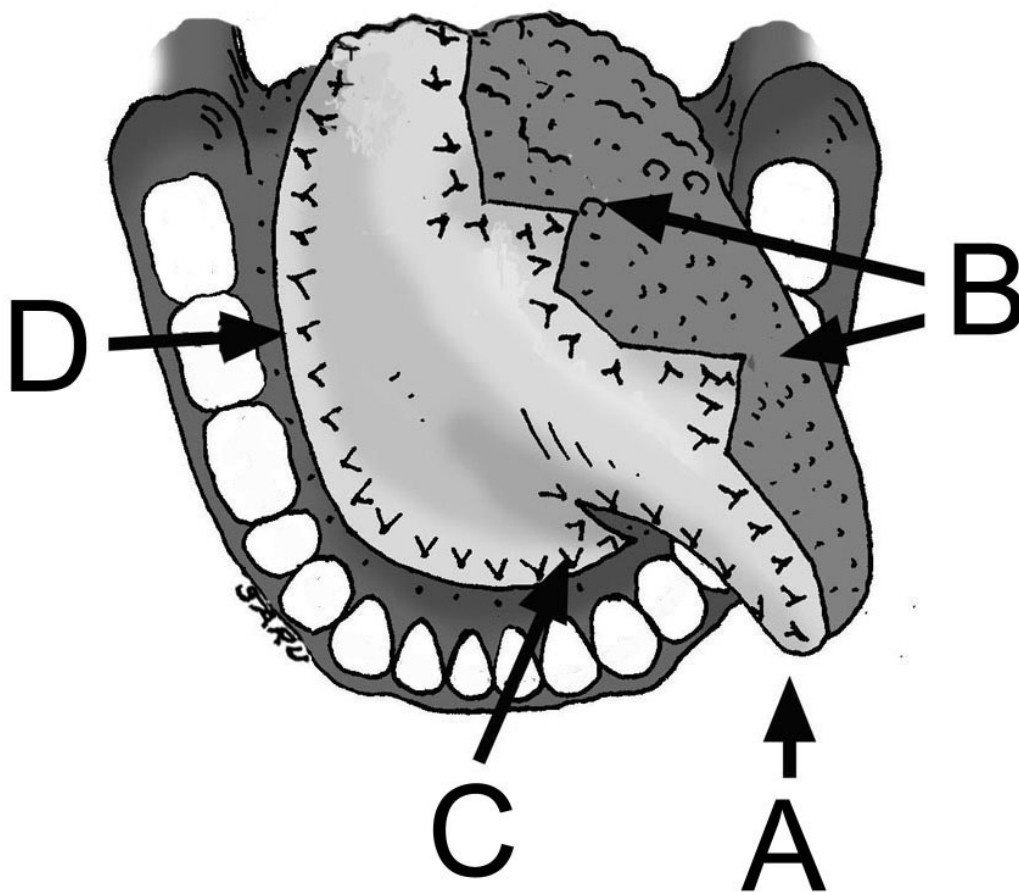
After hemiglossectomy, restoration of mobile tongue with a voluminous flap tends to result in spoilage of speech function because a remaining tongue is "burdened with heavy flap". We recommend that the mobile tongue should be restored with long, narrow and thin flap. Namely, the mobile tongue is intentionally restored as long as and thinner than original tongue. We consider this is the best balance of aesthetic and functional restoration.

3. Apply several z-plasties at the back of tongue (Fig. 1 (B)), and oral floor (Fig. 1 (C)).

We often see a postoperative scar contracture along the suture line between flap and remaining tongue, which consequently reduces a range of lingual mobility. From the plastic surgeon’s point of view, the occurrence of this scar contracture is inevitable, but it can be prevented to some extent by the application of several z-plasty (or insertion of triangle flap). We also see a contracture at the oral floor. To prevent this contracture, insertion of a triangle flap to the mucosa of oral floor at the ventral base of the tongue is effective (Fig. 1 (C)).

4. Filling dead space of oral floor not with muscle body but with adiposal tissue to avoid postoperative collapse of the oral floor and lingual root (Fig. 1 (D), Fig. 2)).

For the good eating function, appropriate reconstruction of the oral floor is mandatory. If the oral floor might be reconstructed with thin flap, the resultant oral floor would collapse, which occasionally causes the swallowing difficulty. Similarly, if the retro-mandibular dead space might be reconstructed with a muscle body, the muscle body would gradually become atrophic which causes collapse of oral floor. We recommend that the retro-mandibular space should be filled up with adiposal (deepithelized) flap (Fig. 2).



“A” indicates a long, narrow, and thin flap attached to the mobile tongue

“B” indicates the triangle flaps set to the back of tongue

“C” indicates the triangle flap set to the oral floor

“D” indicates the part

Fig. 1. Schematic of the reconstruction of the defects after hemiglossectomy

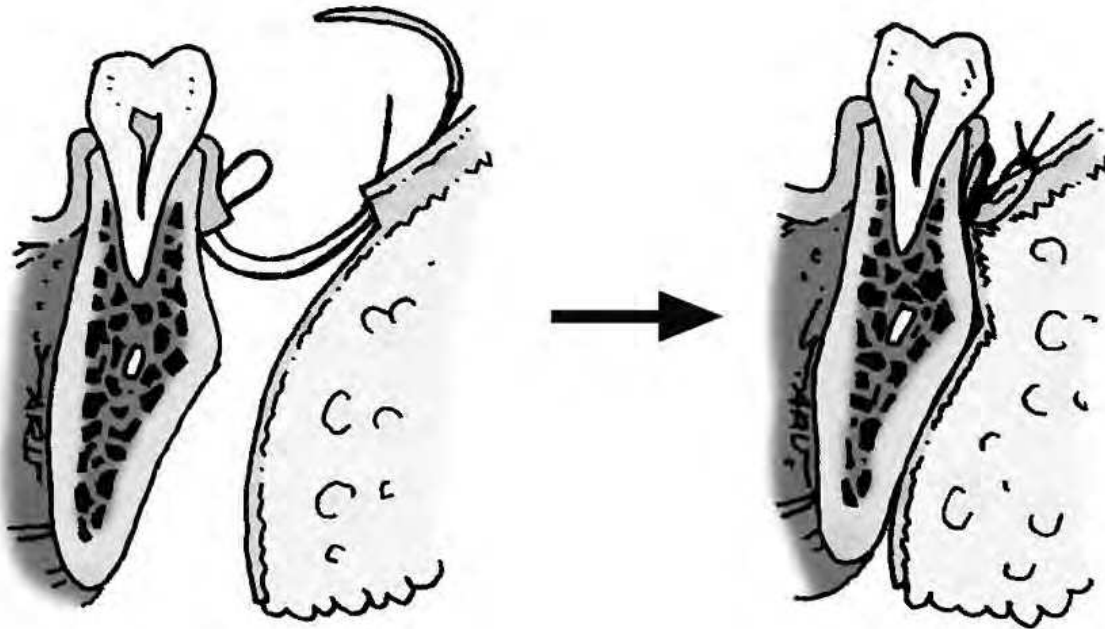


Fig. 2. Schematic of the reconstruction of the retro-mandibular space. A part of the flap is deepithelized and set at the retro-mandibular space attaching the dermis to the mandibular bone

5. Check whether residual tongue is in an appropriate position during flap transfer.

When a patient undergoes the operation under a general anesthesia, a tongue is placed in a glossoptotic position. So sewing of the flap on the tongue is performed pulling a remaining tongue out of a glossoptotic position.

6. Cover the great vessels (carotid artery and jugular vein) with the small muscle body if necessary.

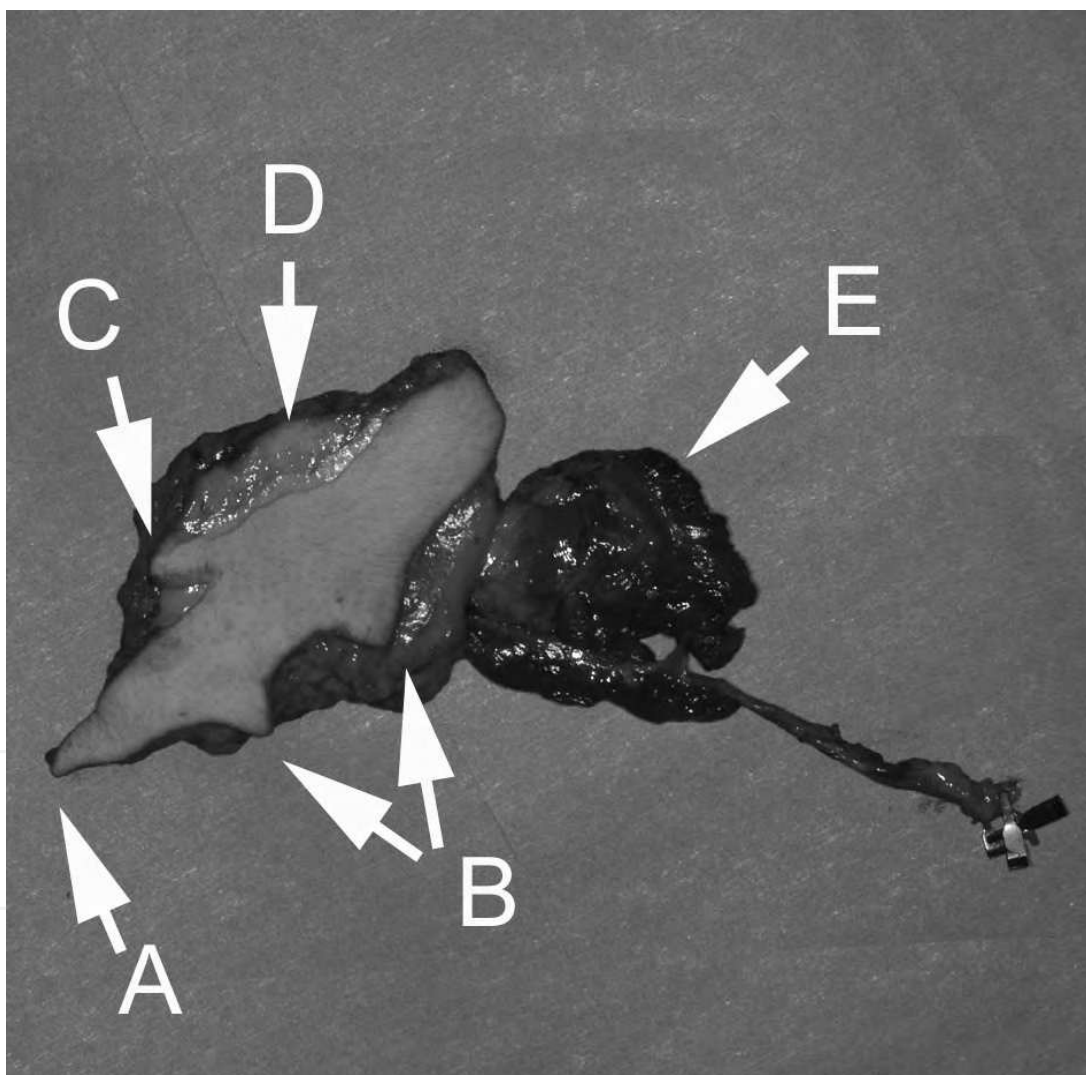
In the patients with high risk of infection or leakage (due to chemo-radiation therapy, diabetes mellitus, and so on), small muscle body is harvested together with a flap during flap elevation, and set on the great vessels to prevent a rupture of them due to a leakage and/or infection.

7. Select appropriate flap depending upon the oral defects and thickness of the fat layer of a patient (whether a patient is obese or slender). We choose an appropriate flap chiefly among the radial forearm, anterolateral thigh, and deep inferior epigastric flap.
8. Choose the appropriate recipient artery among the branches of external carotid or subclavian arteries (referred to as "branch artery" hereafter). Anastomose two flap veins to the internal and external jugular venous system respectively.

When an appropriate branch artery to serve as the recipient is unavailable (ex. in patients with previous operation and/or irradiation therapy), end-to-side anastomosis directly to the external carotid artery (ECA) is a good option. For safer transfer, we recommend that two flap veins (a comitant and a cutaneous vein in the forearm flap, two comittant veins in the anterolateral thigh and inferior epigastric flap) should be anastomosed to the internal and external jugular venous system separately.

3. Representative case

A 57-year-old male patient with the lingual cancer underwent hemiglossectomy and modified radical neck dissection. A deep inferior epigastric flap (15 × 6 cm) with 3 triangle lobe was harvested including small amount of muscle body (Fig.3a). A part of the flap (2 × 7 cm:) was deepithelized to fill the retro-mandibular dead space (Fig. 3a (D)). The flap was sutured to the remaining tongue (Fig. 3b). The inferior epigastric artery was anastomosed to the superior thyroid artery, and two comitant inferior epigastric veins were anastomosed to the internal and external jugular vein respectively. The small muscle body was set on the great vessels. At this point, the reconstructed tongue protruded about 3 cm from incisor line (Fig.3c). Postoperative course was uneventful. The patient recovered good eating and speaking function with aesthetically-satisfactory tongue (Fig. 3d).



"A" indicates a long, narrow, and thin flap attached to the mobile tongue.

"B" indicates the triangle flaps to be inserted into the back of tongue.

"C" indicates the triangle flap to be inserted into the oral floor at the ventral base of tongue.

"D" indicates the deepithelized flap to be set at the retro-mandibular space.

"E" indicates the muscle body to be set on the great vessels.

Fig. 3a. Harvested flap.

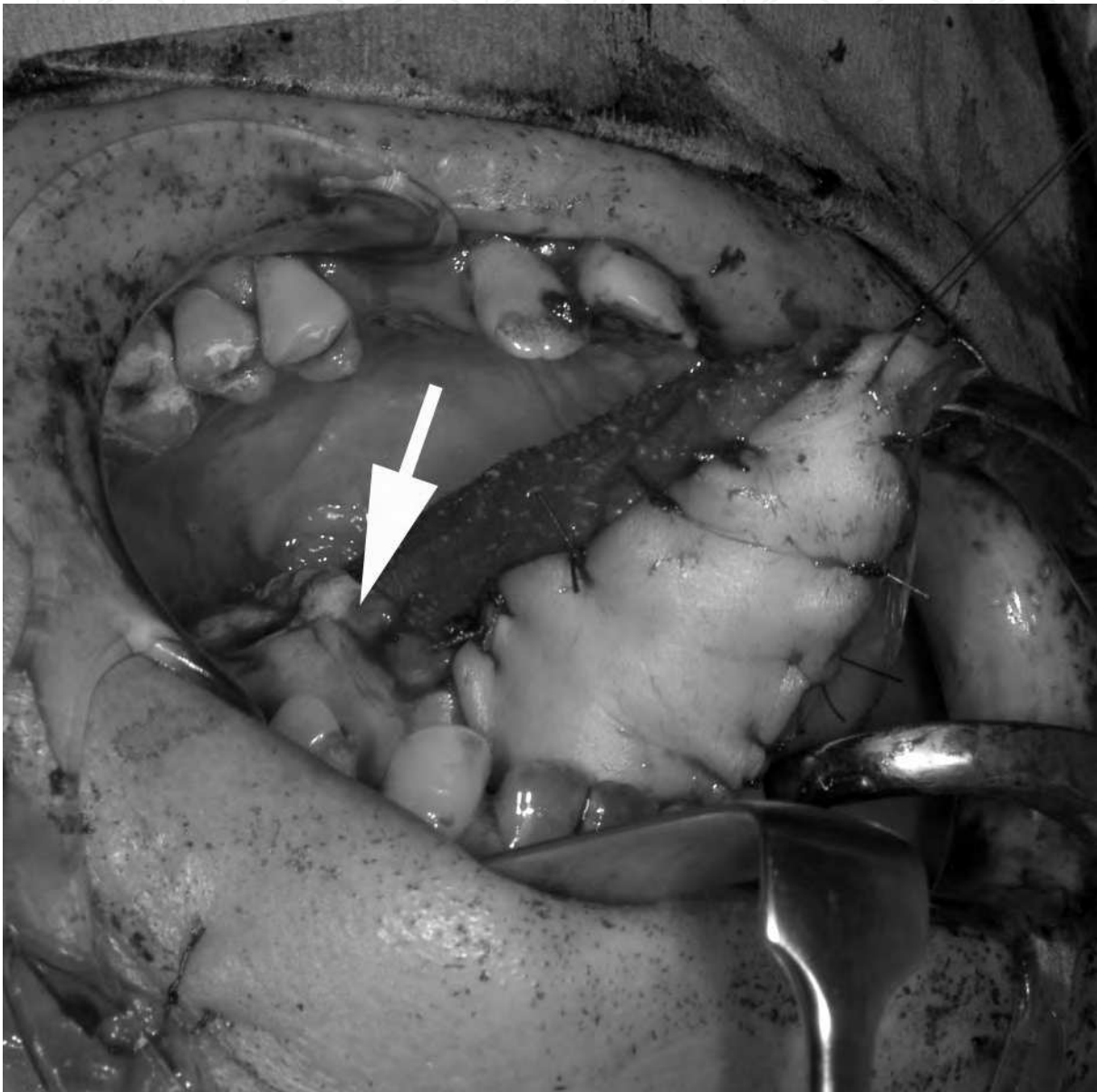


Fig. 3b. Reconstructed tongue. Arrow indicates a triangle flap inserted to the back of tongue.

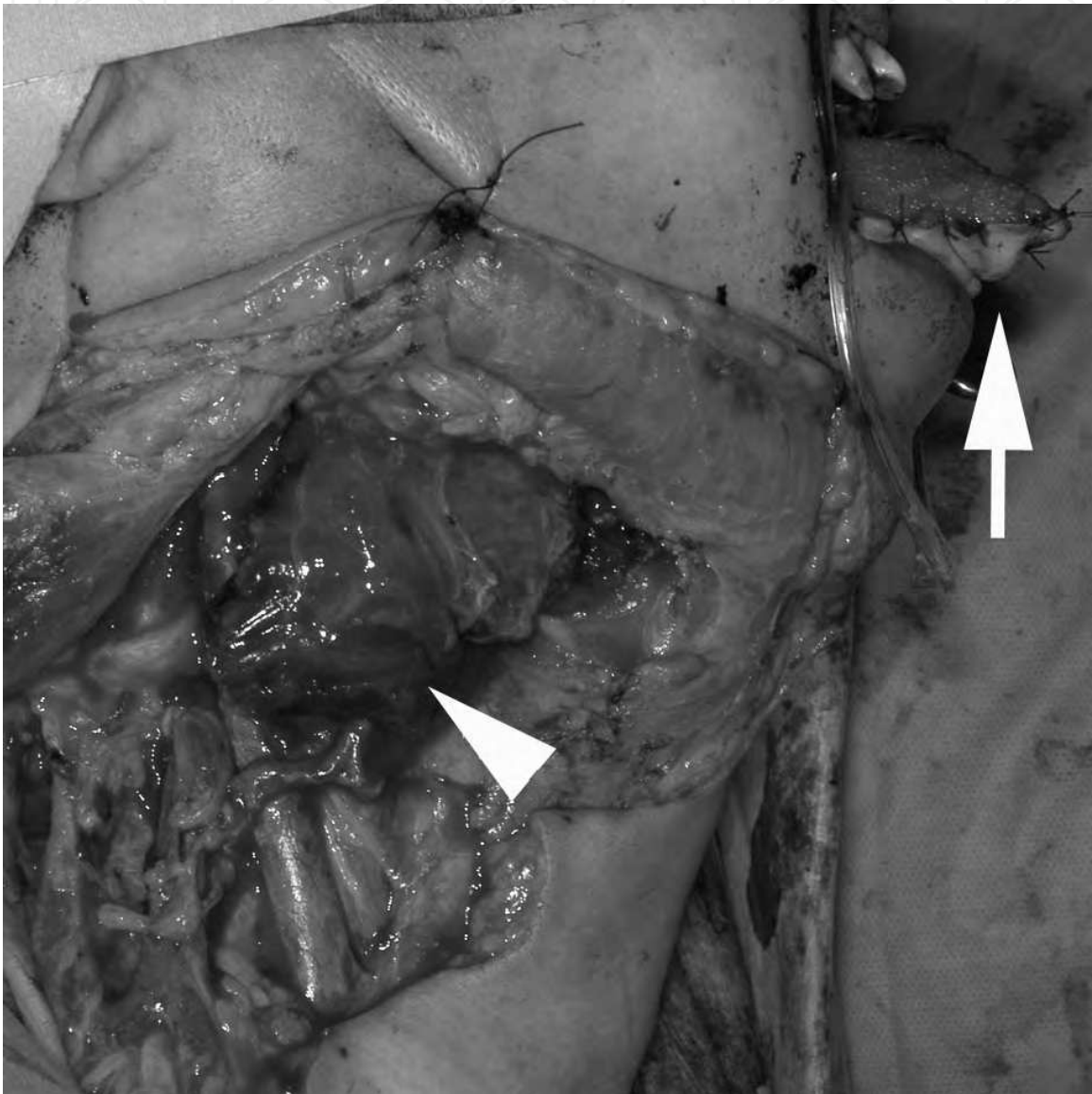


Fig. 3c. Findings of neck just after the vascular anastomosis. Muscle body covers the great vessels (arrowhead). Note the reconstructed tongue tip that protrudes beyond the incisors as it stands (arrow).

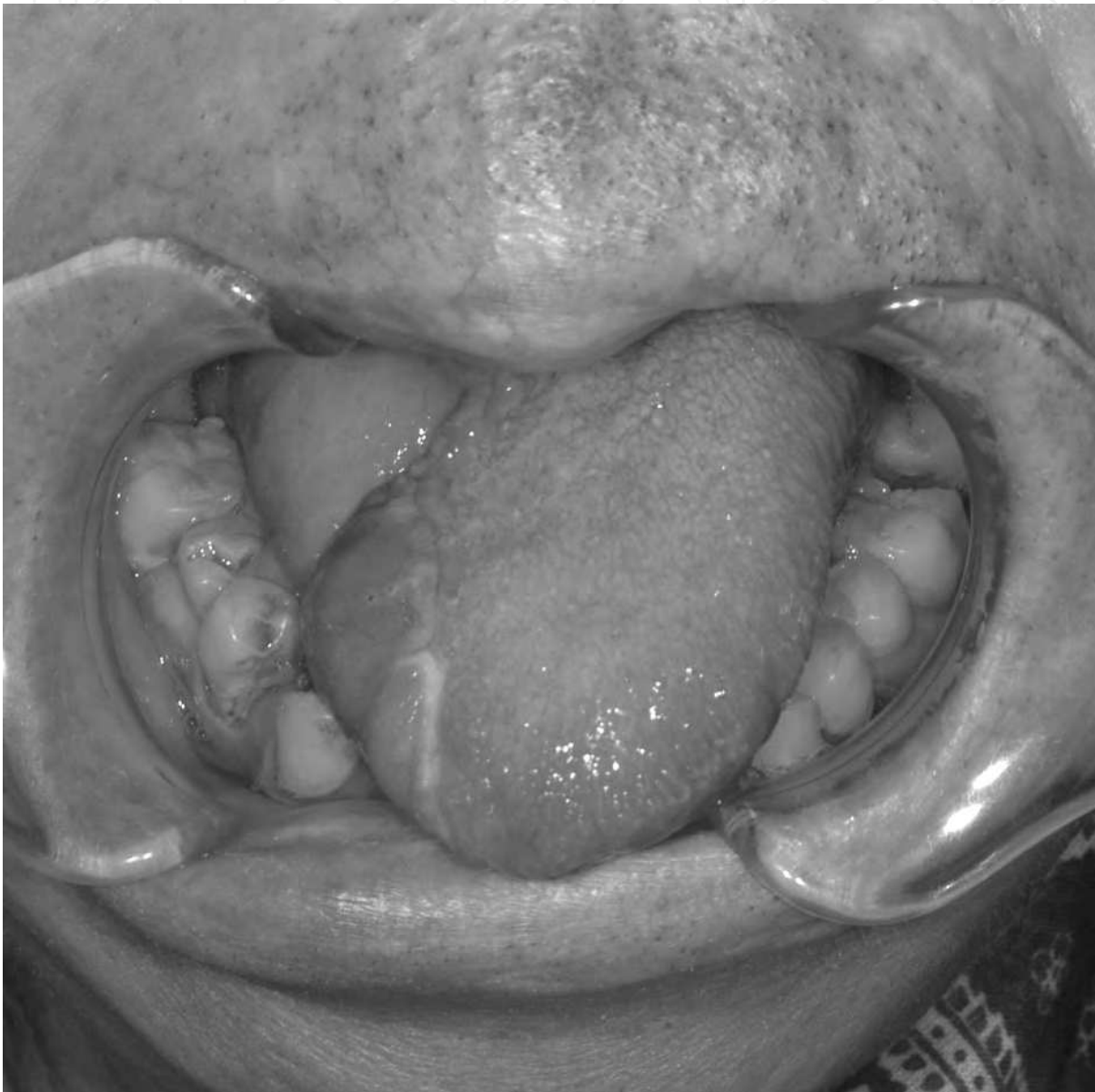

Fig. 3d. Postoperative findings. Although the size of reconstructed tongue is smaller than that of original tongue, the shape of tongue is natural. The eating and speaking function is excellent with wide range of mobility.

4. Discussion

Regarding the volume of the flap for the defects of hemiglossectomy, there was some reports that discuss whether the reconstruction with flap is necessary or not [10,11], but most papers describe that reconstruction with free flap provide good functional results [1-9]. The flaps seen in these papers are comparatively large, and the size of reconstructed tongues is as large as that of original tongue. However, the restoration of mobile tongue with a voluminous flap causes the spoilage of speech function because heavy flap hinders the motion of a remaining tongue (Fig.4a). We consider that the flap that restore the mobile part of the tongue (front half) should be long but thin and narrow.

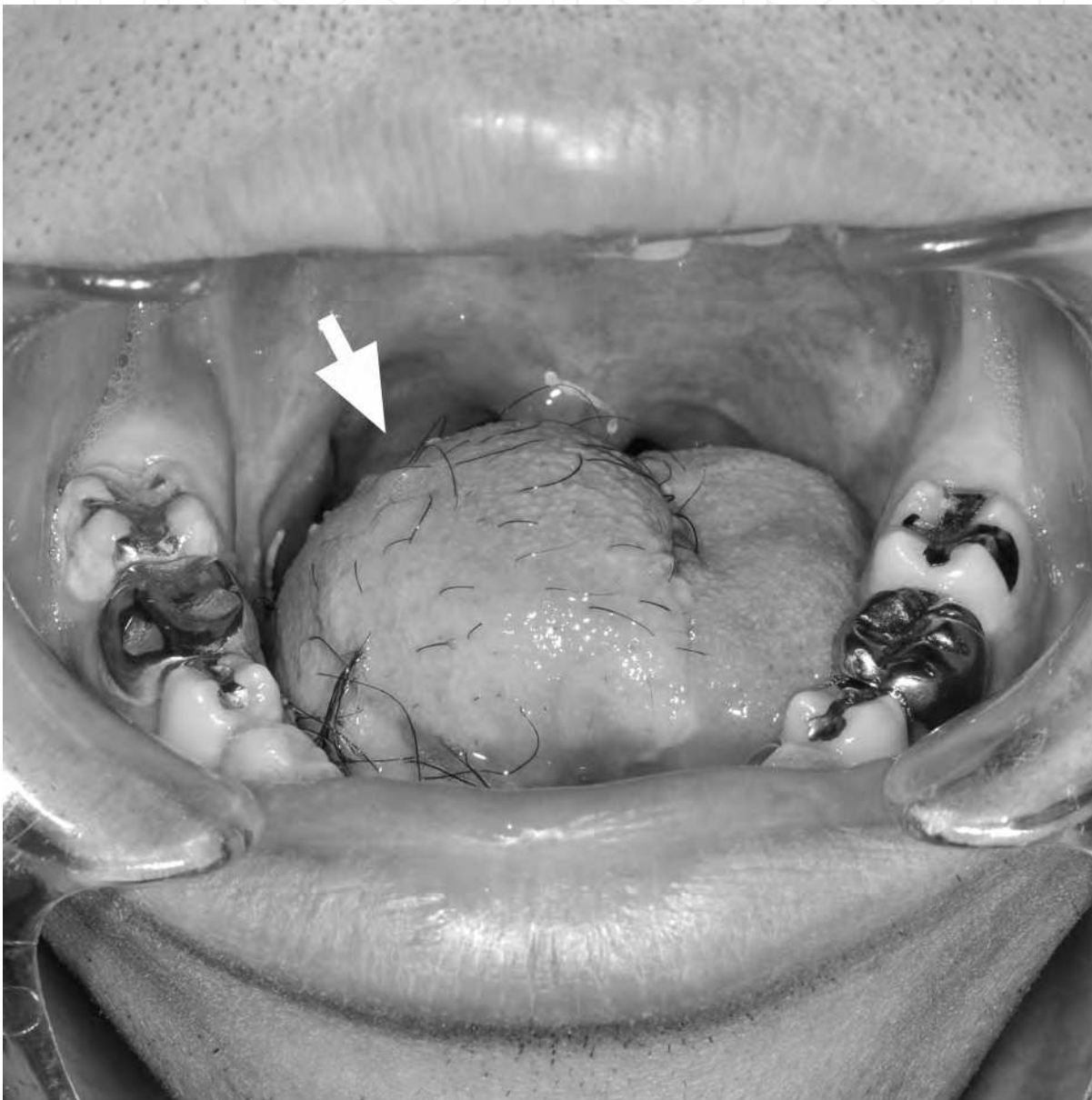


Fig. 4a. Examples of unfavorable results decreased mobility of tongue due to heavy voluminous flap (arrow) (Postoperative findings of a 32-year-old male with lingual cancer who underwent right hemiglossectomy and reconstruction with anterolateral thigh flap).

On the other hand, the lingual root requires some voluminous reconstruction to prevent miss-swallowing or dysphagia. It has been reported that the transferred muscle flap more decrease its volume postoperatively because of the interruption of muscle innervation compared with an adiposal flap [12,13]. So we recommend that lingual root and retro-mandibular space should be reconstructed with adipo-cutaneous tissue, not muscle. A part of the flap is deepithelized (Fig.3a (C)) and set at the retro-mandibular space attaching the dermis to the mandibular bone (Fig.2). We call this method “de-epithelialized flap overlapping method” which is useful also for the prevention of leakage in the flap-gingival suture [14].

Care should be taken whether residual tongue is in an appropriate position when the operators suture the flap to the tongue. Because the tongue is placed in a glossoptotic position under the general anesthesia, if the flap is sutured to the tongue as it stands, the tongue is fixed at the glossoptotic position. As a result, the patients have difficulty in deglutition and protrusion of their tongue. Chepeha and his colleagues [9] reported that tongue protrusion greater than 0.8 cm is associated with better swallowing results in the tongue reconstruction of the hemiglossectomy defect. So the operators should suture the flap to the tongue, pulling the tongue to the protruding position out of a glossoptotic position. By fixing a remaining tongue appropriately (protrusive position) to the mandible via flap, the larynx is consequently placed in an elevated position.

Insertion of a triangle flap to the oral floor at the ventral base of the tongue had been reported [8]. We observed that small triangle flap (less than 2 cm) shrunk postoperatively and was not so effective as was expected. So we recommend triangle flap with a size of more than 3 cm should be used. Applying several z-plasties at the back of tongue, to our knowledge, has not been reported up to now. In the majority of cases (not to say all cases), a postoperative scar contracture along the suture line between flap and remaining tongue occurs to a greater or lesser extent (Fig.4b). From the plastic surgeon's point of view, this inevitable contracture can be prevented by the application of several z-plasty (or insertion of triangle flap).

Concerning the question as to what is the best flap (radial forearm, anterolateral thigh, or deep inferior epigastric flap) for the reconstruction after hemiglossectomy, majority of recent papers suggest that the use of anterolateral thigh flap is the best option because the anterolateral thigh flap provide as good postoperative results as forearm flap whereas the former has less donor site morbidity than latter does [2-5]. We generally agree with them. The use of radial forearm flap may be the best in terms of not disturbing the movement of the tongue because the forearm flap is thin, soft and lithe compared with other two flaps. However, forearm flap is generally too thin for the adequate reconstruction of oral floor and its harvest leaves ugly scar on the forearm. So we recommend that the first choice is the anterolateral thigh flap while the deep inferior epigastric flap is indicated in patients with thin adiposal tissue in the thigh region.

We seldom have difficulties in the selection of appropriate recipient arteries for microvascular free flap transfer in the head and neck region because many sizable branches of the external carotid or subclavian artery are available. However, we occasionally encountered the lack of an appropriate recipient artery, especially in patients with recurrent

cancer after previous surgery and / or irradiation therapy. For these cases, we have preferentially employed the ECA trunk as the recipient artery and anastomosed in an end-to-side fashion, with uneventful results [15]. Careful creation of a hole on ECA for anastomosis is an important key to successful anastomosis. In such difficult cases, the tunica intima of the ECA is as damaged as that of branch arteries, and careless operation may cause irrecoverable injury of the intima. The skin biopsy trepan is useful to create a hole without injuring the intima.

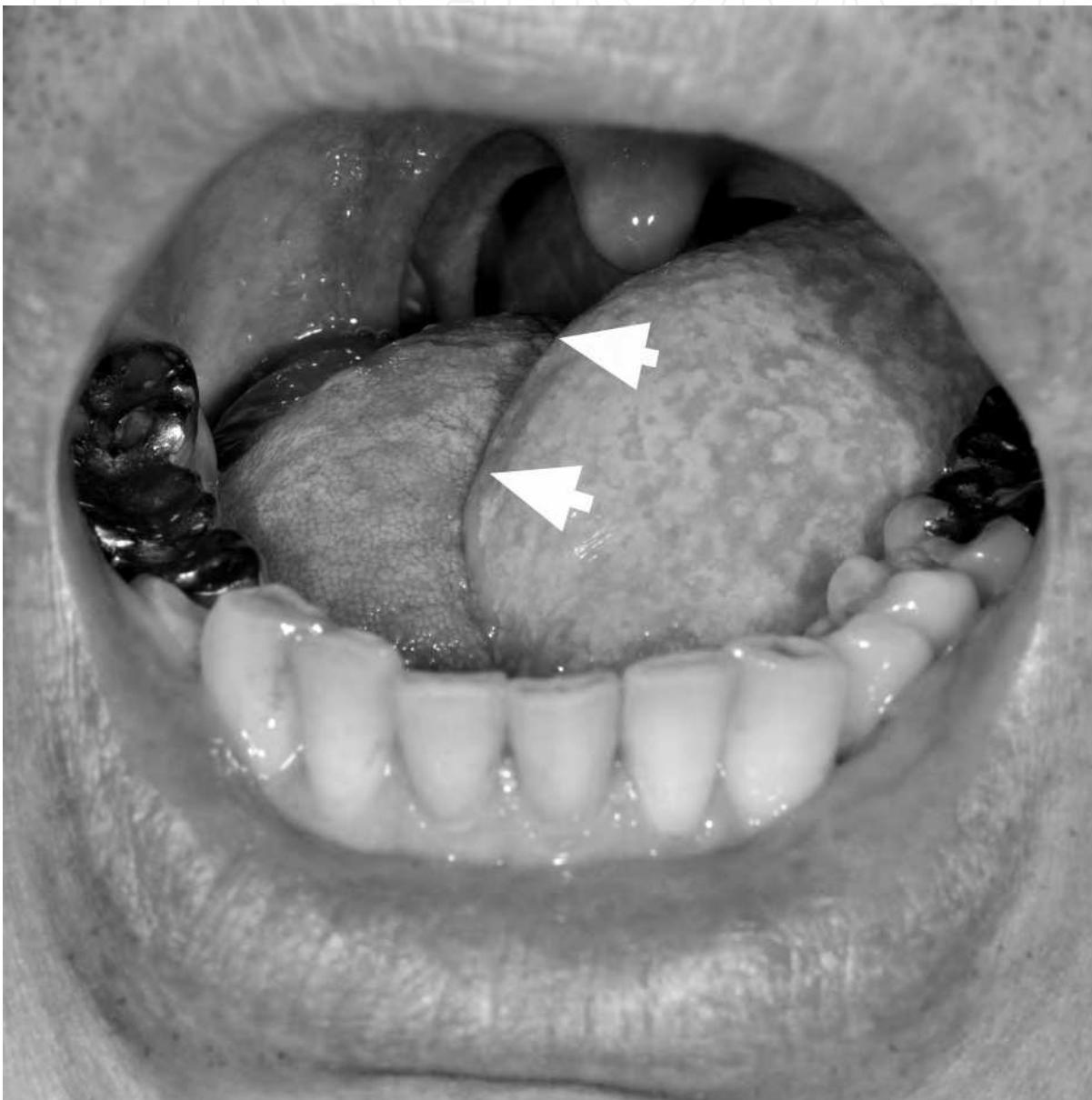


Fig. 4b. Examples of unfavorable results remarkable scar contracture along the straight suture line between the flap and remaining tongue (arrow) (Postoperative findings of a 51-year-old male with lingual cancer who underwent left hemiglossectomy and reconstruction with anterolateral thigh flap).

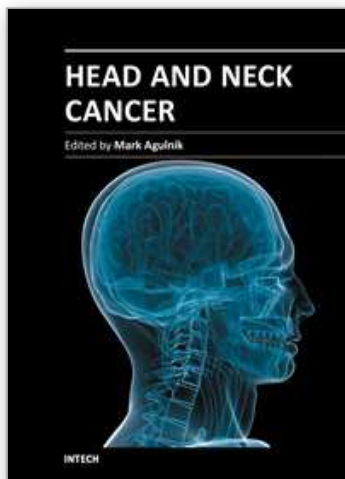
5. References

- [1] Urken ML, Biller HF. A new bilobed design for the sensate radial forearm flap to preserve tongue mobility following significant glossectomy. *Arch Otolaryngol Head Neck Surg* 120: 26-31, 1994
- [2] de Vicente JC, de Villalaín L, Torre A, Peña I. Microvascular free tissue transfer for tongue reconstruction after hemiglossectomy: a functional assessment of radial forearm versus anterolateral thigh flap. *J Oral Maxillofac Surg* 66: 2270-5, 2008
- [3] Huang CH, Chen HC, Huang YL, et al. Comparison of the radial forearm flap and the thinned anterolateral thigh cutaneous flap for reconstruction of tongue defects: an evaluation of donor-site morbidity. *Plast Reconstr Surg* 114: 1704-10, 2004
- [4] Hsiao HT, Leu YS, Liu CJ, et al. Radial forearm versus anterolateral thigh flap reconstruction after hemiglossectomy: functional assessment of swallowing and speech. *J Reconstr Microsurg* 24: 85-8, 2008
- [5] Camaioni A, Loreti A, Damiani V, et al. Anterolateral thigh cutaneous flap vs. radial forearm free-flap in oral and oropharyngeal reconstruction: an analysis of 48 flaps. *Acta Otorhinolaryngol* 28: 7-12, 2008
- [6] Haughey BH, Taylor SM, Fuller D. Fasciocutaneous flap reconstruction of the tongue and floor of mouth: outcomes and techniques. *Arch Otolaryngol Head Neck Surg* 128: 1388-95, 2002
- [7] Engel H, Huang JJ, Lin CY, et al. A strategic approach for tongue reconstruction to achieve predictable and improved functional and aesthetic outcomes. *Plast Reconstr Surg* 126: 1967-77, 2010
- [8] Koshima I, Hosoda M, Moriguchi T, et al: New multilobe "accordion" flaps for three-dimensional reconstruction of wide, full-thickness defects in the oral floor. *Ann Plast Surg* 45: 187-192, 2000
- [9] Chepeha DB, Teknos TN, Shargorodsky J, et al: Rectangle tongue template for reconstruction of the hemiglossectomy defect. *Arch Otolaryngol Head Neck Surg* 134: 993-998, 2008
- [10] McConnel FM, Pauloski BR, Logemann JA, et al: Functional results of primary closure vs flaps in oropharyngeal reconstruction: a prospective study of speech and swallowing. *Arch Otolaryngol Head Neck Surg.* 124: 625-30, 1998
- [11] Hsiao HT, Leu YS, Chang SH, et al: Swallowing function in patients who underwent hemiglossectomy: comparison of primary closure and free radial forearm flap reconstruction with videofluoroscopy. *Ann Plast Surg.* 50: 450-5, 2003
- [12] Wolff KD, Stiller D. Functional aspects of free muscle transplantation: Atrophy reinnervation, and metabolism. *J Reconstr Microsurg* 8: 137-14, 1992.
- [13] Yla-Kotola TM, Kauhanen MS, Koskinen SK, et al: Magnetic resonance imaging of microvascular free muscle flaps in facial reanimation. *Br J Plast Surg* 58: 22-27, 2005.
- [14] Okazaki M, Asato H, Takushima A, et al : Reconstruction with rectus abdominis myocutaneous flap for total glossectomy with laryngectomy. *J Reconstr Microsurg.* 23: 243-9, 2007

- [15] Okazaki M, Asato H, Sarukawa S, et al: Availability of end-to-side arterial anastomosis to the external carotid artery using short-thread double-needle micro-suture in free-flap transfer for head and neck reconstruction. *Ann Plast Surg*, 2006; 56: 171-175.

IntechOpen

IntechOpen



Head and Neck Cancer

Edited by Dr. Mark Agulnik

ISBN 978-953-51-0236-6

Hard cover, 440 pages

Publisher InTech

Published online 14, March, 2012

Published in print edition March, 2012

Head and Neck Cancer provides an interesting and comprehensive overview of all aspects of head and neck cancer including overviews of the disease, basic science aspects pertaining to the disease, diagnosis, treatment and outcomes for patients with this disease. The chapters written by world renowned experts cover the entire discipline of head and neck oncology and include discussions of regional disparity is, advances in basic science understanding, advances in her radiotherapy, chemotherapy and targeted agents as well as a focus on reconstruction, prostheses, and aspects of quality of life and health outcomes. The book is designed to be both practical and comprehensive for every physician treating his complex disease.

How to reference

In order to correctly reference this scholarly work, feel free to copy and paste the following:

Mutsumi Okazaki (2012). Functional and Aesthetic Reconstruction of the Defects Following the Hemiglossectomy in Patients with Oropharyngeal Cancer, Head and Neck Cancer, Dr. Mark Agulnik (Ed.), ISBN: 978-953-51-0236-6, InTech, Available from: <http://www.intechopen.com/books/head-and-neck-cancer/functional-and-esthetic-reconstruction-of-the-defects-following-the-hemiglossectomy-in-patients-with>

INTECH
open science | open minds

InTech Europe

University Campus STeP Ri
Slavka Krautzeka 83/A
51000 Rijeka, Croatia
Phone: +385 (51) 770 447
Fax: +385 (51) 686 166
www.intechopen.com

InTech China

Unit 405, Office Block, Hotel Equatorial Shanghai
No.65, Yan An Road (West), Shanghai, 200040, China
中国上海市延安西路65号上海国际贵都大饭店办公楼405单元
Phone: +86-21-62489820
Fax: +86-21-62489821

© 2012 The Author(s). Licensee IntechOpen. This is an open access article distributed under the terms of the [Creative Commons Attribution 3.0 License](https://creativecommons.org/licenses/by/3.0/), which permits unrestricted use, distribution, and reproduction in any medium, provided the original work is properly cited.

IntechOpen

IntechOpen