

We are IntechOpen, the world's leading publisher of Open Access books Built by scientists, for scientists

6,900

Open access books available

185,000

International authors and editors

200M

Downloads

Our authors are among the

154

Countries delivered to

TOP 1%

most cited scientists

12.2%

Contributors from top 500 universities



WEB OF SCIENCE™

Selection of our books indexed in the Book Citation Index
in Web of Science™ Core Collection (BKCI)

Interested in publishing with us?
Contact book.department@intechopen.com

Numbers displayed above are based on latest data collected.
For more information visit www.intechopen.com



Coronary Artery Disease and Systemic Vasculitis: Case Report and Review

Damianos Eleftheriadis and Nikolaos Eleftheriadis

*Aristotle's University of Thessaloniki,
Cardiology Department, 'Bodosakio' Hospital,
Ptolemaida
Greece*

1. Introduction

Chronic systemic inflammation and immune dysregulation, as a consequence of primary or secondary vasculitis, has been emphasized in pathogenesis of coronary artery disease. (Gasparyan & Ugurlucan, 2008; Mukhtyar et al., 2009; Turesson et al., 2008). Severe coronary artery disease in absence of obvious serious risk factors, especially in young age, remains a challenge to modern cardiology. In these cases, possible relation of ischemic heart disease to systemic vasculitis or thrombophilic predisposition should be also examined. (Kaplan 2009; Knockaert 2007; Tenedios et al., 2006).

Henoch-Schonlein Purpura is a rare disease characterized by systemic vasculitis (Agraharkar et al., 2000; Satoh et al., 1991). It is rarely related with acute myocardial infarction or multivessel disease. (Abdel-Hadi et al., 1981; Eleftheriadis, 2007a; Lutz et al., 2009; Osman & McCreery, 2000). (Table 1)

An atypical presentation of severe acute myocardial infarction in a young male with Henoch-Schonlein Purpura in remission and no other risk factors for coronary artery disease is reported and discussed. After meticulous investigation, including complete blood examinations for thrombophilic diathesis, antiphospholipid antibodies and autoimmunity, it was concluded that severe acute myocardial infarction in this case was a consequence of latent systemic vasculitis in the setting of Henoch-Schonlein Purpura.

The relation of coronary artery disease with primary or secondary vasculitides is also reviewed. Early suspicion and recognition of vasculitis in atypical cases and early initiation of appropriate treatment, including corticosteroids and immunosuppressives, may become the only optional strategy for prevention of vasculitis-related coronary lesions and life-threatening infarctions on the ground of undiagnosed systemic vasculitis.

Key Words: coronary artery disease, acute myocardial infarction, coronary aneurysms, systemic vasculitis, Henoch-Schonlein Purpura, Kawasaki disease, polyarteritis nodosa, systemic lupus erythematosus, Wegener's granulomatosis, antiphospholipid syndrome, polyangiitis overlap syndrome, Churg-Strauss syndrome, Takayasu arteritis.

2. Severe coronary artery disease in the setting of Henoch-Schoenlein purpura: Case report

2.1 Case report

A 49-year-old male with acute myocardial infarction and Henoch-Schoenlein purpura in remission for 10-years, is reported. The patient was admitted with chest pain. Laboratory examination showed elevation of cardiac enzymes, while the 12-lead electrocardiogram demonstrated ST elevation (up to five mm) in leads II, III, and aVF.

He had a previous history of acute glomerulonephritis for ten-years, which was finally attributed to Henoch-Schonlein Purpura, after detailed clinico-laboratory investigation in tertiary center. At that time, total immunological examination did not reveal any other autoimmune disease, neither systemic lupus erythematosus nor other known vasculitis. Thereafter, he was totally asymptomatic with normal renal function. During ten-year follow-up, he had no other admissions, used no medications and had no personal or family history of thrombotic events.

Except for b-blockers use for arterial hypertension, he reported no other medications, smoking or alcohol use. All other personal and family history was negative for coronary artery disease.

Clinical examination revealed: blood pressure: 120/80 mmHg, heart rate 50/1min. Urine examination showed mild haematuria. Laboratory examination showed: urea 42mg/dl, creatinin 1.1mg/dl (normal<1.3), cholesterol: 197mg/dl, (normal<200mg/dl), LDL 135mg/dl (normal <150), triglycerides 96mg/dl (normal <150mg/dl), HDL 47mg/dl (normal >35mg/dl), ESR 54/1h (normal <8/1h), CRP 16.22 mg/dl, (normal <0.8). All other hematological, blood chemistry results and thorax photo were normal.

The patient was successfully treated in intensive care unit for acute myocardial infarction, while no thrombolysis was given due to delay arrival. Angiography showed three-vessel disease (right coronary artery 100%, middle circumflex artery 75% and left anterior descending artery 50%) and angioplasty was performed in two vessels.

Blood examinations for thrombophilic diathesis were performed. All known risk factors associated with increased risk of thrombosis, such as antiphospholipid antibodies, coagulation factors, protein C, protein S, factor V Leiden, mutation G20210A of prothrombin [PTHR A(20210)], and mutation TT677 of methylenetetrahydrofolate reductase [MTHFR C677-->T]), were within normal.

Thereafter, the patient is under continuous combined anticoagulation with low dose aspirin plus clopidogrel. During five-year follow-up post-infarction the patient is totally asymptomatic and he is under continuous antianginal agents. No corticosteroids or immunosuppressive drugs were administered.

2.2 Discussion

Henoch-Schonlein Purpura is a rare disease, characterized by systemic vasculitis of the skin and other abdominal organs (Agraharkar et al., 2000; Satoh et al., 1991). It has good prognosis, except if it is complicated by severe glomerular disease (Watanabe et al., 2003).

Although, it has been extensively studied in children, its natural history in adults is less known, with outcome worse in adults than in children. (Pillebout et al., 2002). Correlation with acute myocardial infarction or multivessel disease has been rarely reported (Abdel-Hadi et al., 1981; Eleftheriadis, 2007; Lutz et al., 2009; Osman & McCreery, 2000). (Table 1)

An interesting finding of the present case, is the discrepancy between absence of serious risk factors for coronary artery disease in a young patient and severity of infarction (three-vessel disease), which was also reported in two similar cases, with thrombotic thrombocytopenic purpura. (Dhawan & Tak, 2004; Hasper et al., 2006).

Only the previous history of Henoch-Schoenlein purpura and its vasculitis-related coronary lesions, could explain the premature infarction of this case. However, Henoch-Schonlein purpura and its nephritis regressed and stabilized the last ten years, which is also another interesting finding of the present case.

Co-existence of other predisposing factors for ischemic heart disease, such as thrombophilic disorders or potential superimposition of other systemic vasculitis, could also be a possible explanation of the unusual severe premature infarction, in the present case. (Eleftheriadis, 2007b; Shin & Lee, 2007).

Antiphospholipid syndrome should be excluded in cases of Henoch-Schonlein Purpura, and antiphospholipid antibodies should be measured to determine whether prophylactic antithrombotic measures are needed to prevent additional thrombotic manifestations. (Espinosa & Gervera, 2010; Monastiri et al. 2002; Sullivan et al., 1999).

However, repeated and meticulous examinations for thrombophilic diathesis, including antiphospholipid antibodies, as well as immunological examinations for other secondary systemic vasculitis, did not reveal any additional diagnosis in this case. (Eleftheriadis, 2007b). Moreover, the possibility of polyangitis overlap syndrome was also excluded.

Although vasculitis is classified according to the size of involved vessels, some patients do not belong to a single disease entity and show the symptoms seen in more than two diseases. (Tanimoto, 1994; Zaidi et al, 2008).

The incidence of polyangitis overlap syndrome in patients with cardiac vasculitis is unknown, because this overlap has often been diagnosed by postmortem autopsy. (Freddo et al., 1999; Kimura et al, 2011; Kumar et al., 2002; Wegner & Schneider, 1996). Therefore, when a patient presents with atypical presentation of Henoch-Schonlein Purpura, the overlap of other vasculitis should also be examined to prevent unexpected fatal situations. (Watanabe et al., 2003; Zaidi et al., 2008).

Latent vasculitis in the setting of Henoch-Schoenlein purpura was the only obvious cause for the severe infarction in this case. No other alarm symptoms for years and no previous signs of active vasculitis were reported, which could had lead to preventive measures for coronary thrombosis.

In conclusion, this case is of interest due to rarity of Henoch-Schonlein Purpura as a cause of severe coronary artery disease and the atypical presentation with latent course of Purpura-related vasculitis.

3. Coronary artery disease and primary systemic vasculitis

Primary systemic vasculitides are a group of autoimmune conditions characterized by occlusion, stenosis or aneurysmal dilatation of blood vessels, including coronary arteries, secondary to intramural inflammation. Increased prevalence of premature cardiovascular disease has been observed in chronic inflammatory disorders, such as systemic vasculitis. Coronary abnormalities may also be the only manifestations of many vasculitides. (Bijl, 2003; Kaplan, 2009; Knockaert, 2007; Mukhtyar et al., 2009; Nabatian et al., 2006; Reinhold-Keller et al, 2005).

Skin biopsy, showing mural fibrin deposition in arterioles or venules and angiocentric inflammatory cell infiltration, in cases with suspicion of vasculitis, is important for early diagnosis. (Magro & Crowson, 1999). (Figure 1)

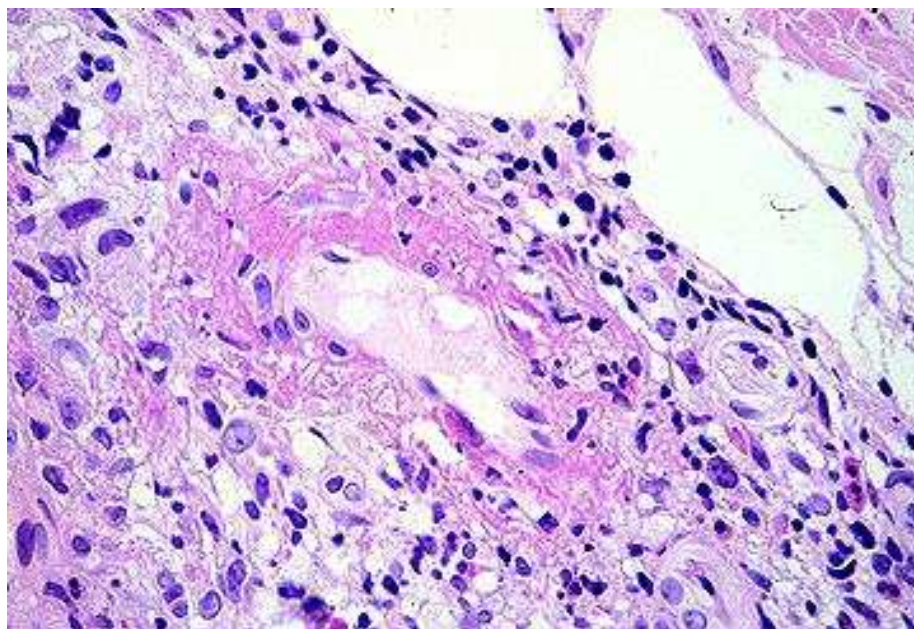


Fig. 1. Skin biopsy from a patient with leukocytoclastic vasculitis showing mural fibrin deposition in a venule and angiocentric mixed neutrophilic and lymphocytic infiltration. (Magro & Crowson, 1999).

Although the mechanisms of accelerated atherosclerosis in systemic vasculitis have not been fully clarified and may differ in the different vasculitic syndromes, direct injury to arteries, arterial intimal-media calcification, pro-atherogenic changes in lipid and fibrin metabolism, and systemic hypertension due to alterations in carotid baroreceptor sensitivity, as a consequence to vasculitis, have been proposed. (Agarwal et al., 2010; Donald et al., 1976; Kane & Keogh, 2009; Mukhtyar, et al., 2009).

Endothelial cell activation through autoantibodies, resulting in endothelial cell dysfunction, complement-dependent and antibody-dependent cytotoxicity, cytokines and direct effect of adhesion molecules have all been also implicated in vasculitis-related premature atherosclerosis. (Bijl, 2003; Savage, 2002).

Current therapy has changed the natural history of these diseases from death or severe morbidity to a remitting-relapsing condition in most instances. However, despite major

immunosuppressive care, systemic vasculitis may lead to potential fatal complications and death, through diffuse vessel fibrinoid necrosis and interstitial hemorrhages, attaching multiple organs. (Andersson, 2000; Bossert, et al. 2011; Eberhardt & Dhadly, 2007; Freddo et al., 1999; Lin, et al., 2007; Osman & McCreery, 2000; Wegner & Schneider, 1996).

What is more, longer survival, relapsing course and complications related to chronic corticosteroid therapy (hypertension, diabetes mellitus and change in lipid profile), may further contribute to an increase in cardiovascular events and morbidity. (Lin et al., 2007; Mukhtyar et al., 2009).

On the other hand, there is evidence that glycocorticoid therapy in combination with immunosuppressive may improve endothelial dysfunction and prevent myocardial ischemia as a consequence of vasculitis in some cases. (Cocco & Gasparyan, 2010; Gonzalez-Juanatey et al., 2006; Lutz et al., 2009; Oates-Whitehead, et al. 2003).

Primary systemic vasculitides are categorized according to the vessel size, into large-vessel and medium- to small-vessel vasculitis, while the mode and incidence of cardiac involvement vary within the different vasculitic syndromes. (Agarwal et al., 2010; Hata & Onouchi, 2009; Hewins & Jane, 2010; Kane & Keogh, 2009; Mukhtyar et al., 2009). The relation of coronary artery disease with different categories of primary vasculitides are reviewed.

3.1 Cardiovascular involvement in large vessel vasculitis

3.1.1 Coronary artery disease and giant cell arteritis

Giant cell arteritis is a relatively common large vessel vasculitis, which affects, predominantly cranial nerves, especially temporal artery, occasionally aorta and rarely coronary arteries or other visceral or peripheral arteries. (Andersson, 2000). Stroke, aortic aneurysm or dissection, and even aortic rupture, visual loss due to ischemic optic neuropathy, secondary to temporal arteritis, are tragic manifestations of giant cell arteritis. (Andersson, 2000; Eberhardt & Dhadly, 2007; Lin et al., 2007).

Coronary artery disease is most commonly occurred in the long-term course, but it is also reported at disease presentation, in atypical cases. (Bossert et al., 2011; Eberhardt & Dhadly, 2007; Kimura et al., 2011; Lin, et al., 2007). Giant cell-related early myocardial infarction, often with fatal outcome, is more commonly reported than previously appreciated. (Freddo et al., 1999; Lin et al., 2007; Bossert et al., 2011; Wegner & Schneider, 1996).

Although, most of the complications of giant cell arteritis can be effectively prevented by early initiation of corticosteroid treatment, severe myocardial infarction, even fatal, can still occur despite high-dose corticosteroid therapy. (Andersson, 2000; Bossert et al., 2011; Eberhardt & Dhadly, 2007; Freddo et al., 1999; Lin et al., 2007; Wegner & Schneider, 1996).

Furthermore, in unusual cases of coronary giant arteritis, precise diagnosis was done antemortem at autopsy. (Freddo, T., et al., 1999; Kimura, T., et al. 2011; Kumar, P., et al., 2002; Wegner, M., & Schneider, J. 1996).

Modern imaging techniques, including positron emission tomography and magnetic resonance imaging should be considered in atypical cases of giant cell aortitis and coronary

giant arteritis, which are more common than previously thought. (Bossert et al., 2011; Kimura et al., 2011; Lin et al., 2007; Mavrogeni et al., 2009). Directional coronary atherectomy can also be an alternative diagnostic method for coronary giant arteritis. (Saito et al., 1994).

3.1.2 Coronary artery disease and Takayasu arteritis

Takayasu arteritis is a large vessel vasculitis that usually involves the large cardiac vessels, predominantly the aorta and its main branches. Approximately 10% of cases are associated with ostial or proximal coronary artery stenosis, necessitating bypass. (Amano & Suzuki, 1992; Ouali et al., 2011; Park et al., 2010; Sheikhzadeh et al., 2002).

Angiographically Takayasu arteritis was classified as cervicobrachial (I), thoracoabdominal (II), peripheral type (III) and generalized type (IV), which was the most frequent. (Sheikhzadeh, A. et al. 2002). Atypical presentation of Takayasu arteritis, with acute myocardial infarction in young patients, which could not be fully classified, was also reported. (Araszkiewicz et al., 2007).

Coronary artery disease as a consequence of Takayasu arteritis, is relatively rare, resulting however in severe life-threatening complications. It is also associated with aneurysmal dilation of other arteries such as carotid, vertebral and renal arteries. (Amano & Suzuki, 1992; Araszkiewicz et al., 2007; Ouali et al., 2011; Sheikhzadeh et al., 2002).

3.2 Cardiovascular involvement in medium and small vessel vasculitis

Coronary vasculitis is an uncommon but catastrophic clinical presentation of small and medium vessel vasculitis. Inflammation and damage of the coronary arteries lead to aneurysm formation and subsequently to stenosis and coronary thrombosis. (Agarwal et al., 2010; Hata & Onouchi, 2009; Hewins & Jayne, 2010; Kane & Keogh, 2009).

Prompt diagnosis and early treatment with corticosteroid and immunosuppressives in combination to anti-anginic therapy is usually effective and reduced the frequency of cardiovascular complications. However, vasculitis relapse although rare, may result in an increased risk of cardiovascular disease later in life despite aggressive therapy. (Hewins & Jayne, 2010; Kane & Keogh, 2009).

3.2.1 Coronary artery disease and Kawasaki disease

Kawasaki disease is an acute systemic vasculitis of childhood, of unknown origin, that particularly affects the coronary arteries. It is complicated by coronary arterial aneurysms (Figure 2) and stenosis in approximately 20 to 25% of untreated patients and subsequently can lead to myocardial infarction and/or sudden death. (De Castro et al., 2009; La Pellegrin et al., 2011; Tsuda et al., 2011; Wood & Tulloh, 2009).

Kawasaki disease has an incidence of approximately 8 per 100000 children in the western countries, while it is more frequent in Japan. (Fukazawa & Ogawa, 2009; Hata & Onouchi, 2009). It is considered one of the most common causes of acquired heart disease in children in developed countries. (Caballero-Mora et al., 2011; De Castro et al. 2009; Fukazawa & Ogawa, 2009; La Pellegrin et al., 2011; Tsuda et al., 2011; Wood & Tulloh, 2009).

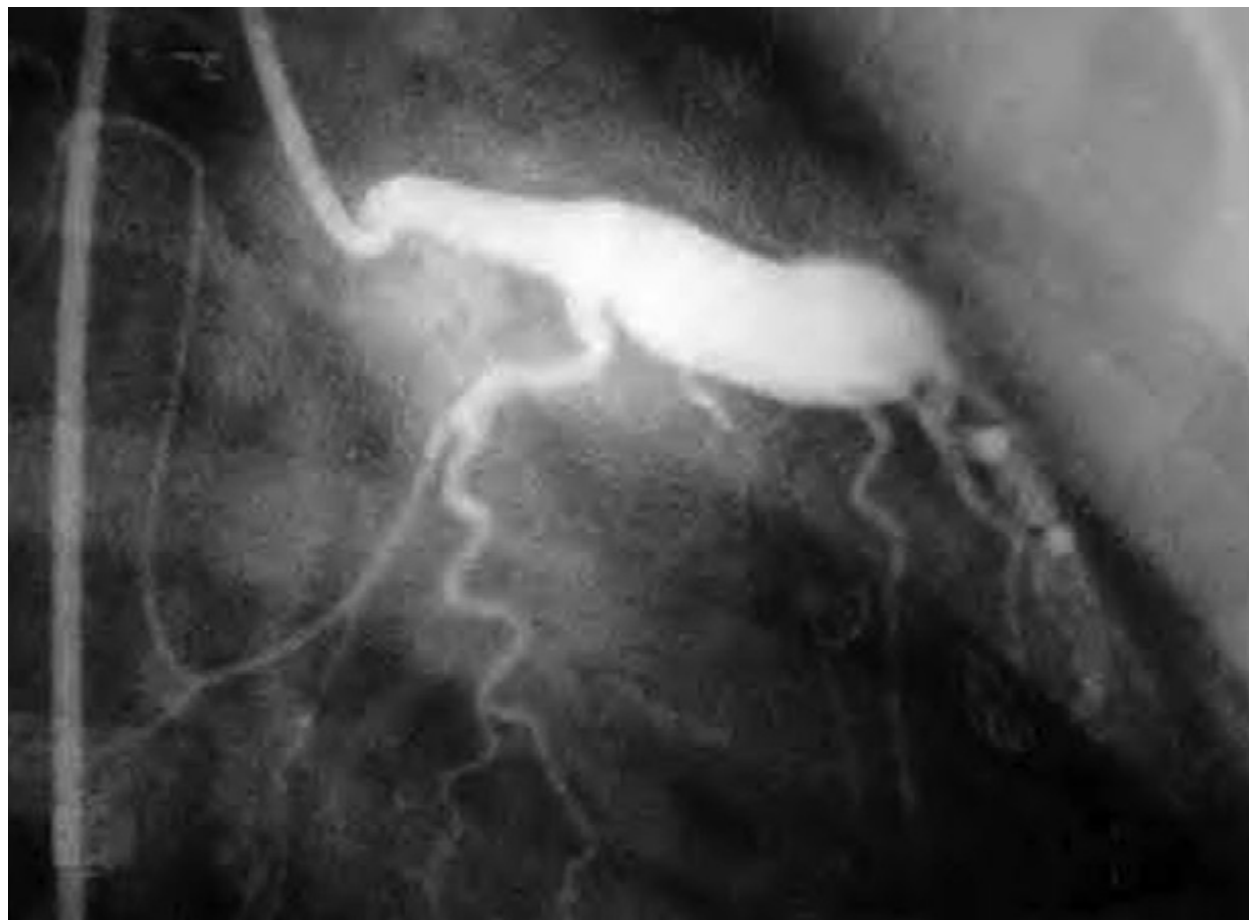

Fig. 2. Coronary-artery aneurysm in a patient with Kawasaki disease (Hewins & Jayne, 2010).

Despite treatment of acute phase with intravenous immunoglobulin and aspirin, up to 5% of Kawasaki disease patients, still continued to develop serious cardiac life-threatening complications, mainly giant coronary aneurysms and thrombotic stenoses, resulted in myocardial infarction and/or death. (Caballero-Mora et al., 2011; De Castro et al., 2009; Hata & Onouchi, 2009; LaPellegrin et al., 2011; Lin et al., 2011; Tsuda et al., 2011; Wood & Tulloh, 2009).

Atypical presentation or incomplete form is presented in one third of all Kawasaki disease patients, characterized by an older age at onset and diagnostic delay. (La Pellegrin et al., 2011; Gomard-Mennesson et al., 2010).

Acute coronary syndrome in adults caused by Kawasaki disease is rarely reported. (LaPellegrin et al., 2011, Tsuda E et al., 2011). Older age, male sex, higher C-reactive protein levels, urticarial exanthema, lack of response to the first intravenous immunoglobulin (IVIg) infusion and IVIg dosage < 2 g/kg, were reported as risk factors for the development of atherosclerosis in adults with Kawasaki disease. (La Pellegrin et al., 2011, Caballero-Mora et al 2011). C-reactive protein, oxidative stress, and inflammatory cytokines, are also increased in the remote phase of Kawasaki disease (Fukazawa & Ogawa, 2009).

Despite intensive research the cause remains unknown. It is generally accepted that an as yet undefined infectious trigger in a genetically predisposed individual results in Kawasaki disease. (Eleftheriou et al., 2009).

A strong genetic influence on Kawasaki disease susceptibility has been indicated from epidemiological studies. (Hata & Onouchi, 2009). Advances in molecular genetic analysis, have permitted the identification of inositol 1,4,5-triphosphate 3-kinase C (ITPKC), as a predisposing gene associated with Kawasaki disease. (Eleftheriou et al., 2009; Hata & Onouchi, 2009; Lin et al., 2011; Rowley, 2011).

Early detection and initiation of therapy is substantial for good outcome in Kawasaki patients with coronary lesions. The combination of aspirin, corticosteroids and/or intravenous immunoglobulin, started early after the onset of symptoms, has reduced the frequency of coronary artery aneurysms in Kawasaki disease. (Oates-Whitehead et al., 2003; Wooditch & Aronoff, 2005).

Although there are no clear specific recommendations regarding thrombolytic therapy in Kawasaki pediatric patients, there are reports of the use of all known thrombolytics, in children with myocardial infarction related to Kawasaki disease. (Paredes et al., 2000). Close collaboration between pediatric cardiologists and coronary interventional cardiologists is necessary. (Akagi, 2011).

3.2.2 Coronary artery disease and Henoch Schoenlein Purpura

Henoch Schoenlein Purpura is one of the most common forms of leukocytoclastic vasculitis in children, which is self-limited in the majority of cases. (Lutz et al., 2009; Pillebout et al., 2002; Polizzotto et al., 2006; Zaidi et al., 2008).

Infectious triggers are still implicated in the aetiopathogenesis of Henoch-Schoenlein purpura, while several genetic polymorphisms have been described that may be relevant in disease predisposition or development of disease complications. (Eleftheriou et al., 2009; Lutz et al., 2009). In adults clinical presentation of Henoch Schoenelin purpura is severe, with relatively poor outcome, worse than in children, which is mainly related to renal impairment and glomerulonephritis. (Eleftheriou et al., 2009; Lutz et al., 2009).

Coronary artery disease in adults with Henoch Schoenelin purpura is rarely reported as main manifestation and only in case reports. (Table 1). It should be distinguished from secondary Henosch Schoenelin purpura caused for example by rheumatic fever. (Lutz et al., 2009; Pillebout et al., 2002).

Patient Sex/Age (y)	Cardiac Involvement	Treatment	Outcome
Male/71 (Polizzotto, M.N., et al., 2006)	Complete atrioventricular block, no myocardial necrosis	Methylprednisolone, pulse therapy	Complete resolution
Male/69 (Carmichael, P. et al., 2002)	Creatinine kinase increase, left bundle branch block	Methylprednisolone	Death within 11 d
Male/63 (Agraharkar, M., et al 2000)	Escape rhythm and myocardial infarction	Methylprednisolone	Death within 10 d
Male/14 (Osman, A., 2000)	Junctional rhythm, troponin T increase	Prednisone, azathioprine, ventricular pacemaker	Death within a few days

Patient Sex/Age (y)	Cardiac Involvement	Treatment	Outcome
Male/24 (Kereiakes DJ, et al., 1984)	Congestive heart failure (biopsy-proven immunoglobulin A deposits in myocardium)	Prednisone, cyclophosphamide	Persistent congestive heart failure with low ejection fraction (18%)
Male/29 (Abdel-Hadi, O., et al., 1981)	Myocardial infarction without macroangiopathy	—	Persistent apical dyskinesia
Male/11 (Lecutier, M.A., 1952)	Myocardial necrosis, likely secondary HSP	Penicillin	Death 1 mo after first admission
Male/64 (Sato, M., et al., 1991)	Cardiac dysfunction and dilatation	—	Unknown
Male/9 (Guven, H., et al., 2006)	Mobitz type 2 atrioventricular block, likely secondary HSP	Salicylate, penicillin	Complete resolution
Male/13 (Kalyoncu, M., et al., 2006)	Severe mitral insufficiency with dilatation of the left ventricle, likely secondary HSP	Methylprednisolone, cyclophosphamide	Death 1 mo after admission from cardiac arrest
Male/17 (Zaidi, M., et al., 2008)	Left ventricular dilatation, likely secondary HSP	Methylprednisolone pulse therapy	Kidney function normal at 3-mo follow-up, cardiac outcome unknown
Male/19 (Lutz, H., et al., 2009)	Myocardial involvement, arrhythmia (atrioventricular blocking type 2)	Methylprednisolone pulse therapy, Cyclophosphamide pulse therapy	Complete resolution
Male/49 (Eleftheriadis, D., 2007)	Acute myocardial infarction	Salicylate, antianginal therapy	Complete resolution

Abbreviation: HSP, Henoch-Schönlein purpura.

Table 1. Published case reports of coronary artery disease related to Henoch-Schoenlein Purpura. (Lutz et al., 2009).

Although immunosuppressive therapy, mainly with steroids and/or cyclophosphamide, is reported to be insufficient in diminishing the incidence of renal insufficiency, they may prevent infarction and deleterious outcome. (Lutz et al., 2009). Different immunosuppressive medications and newer therapeutic approaches such as biologic agents have been also reported as alternative options for better management. (Eleftheriou et al., 2009; Lutz et al., 2009; Pillebout et al., 2002;).

3.2.3 Coronary artery disease and antineutrophilic cytoplasmic antibodies (anca) associated vasculitis

Wegener's granulomatosis, microscopic polyangiitis and Churg-Strauss syndrome are small-to medium vessel vasculitides, with strong association with the presence of anti-neutrophil cytoplasm antibodies (ANCA). There are several reports of extensive myocardial infarction in young patients, as a consequence of coronary aneurysms, related to an ANCA-positive vasculitis. (Mukhtyar et al., 2009; Musuruana et al., 2011). According to similar reported cases early treatment with high doses of immunosuppressives such as corticosteroids and cyclophosphamide, resulted in aneurysm resolution and may prevent myocardial infarction. (Musuruana et al., 2011).

Churg-Strauss syndrome is a vasculitis associated with asthma and eosinophilia. There are two subsets of patients with different pathogenetic mechanisms, with ANCA mediated process in ANCA positive patients and tissue infiltration by eosinophils in ANCA negative patients. Heart diseases related to Churg-Strauss syndrome include coronary vasculitis, myocarditis, valvular heart abnormalities, congestive heart failure and pericarditis. Coronary artery disease is significantly more common in ANCA-negative cases and is the leading cause of mortality in Churg-Strauss syndrome. (Churg & Strauss, 1951; Keogh & Specks, 2003; Sable-Fourtassou et al., 2005; Sinico & Bottero, 2009).

3.2.3.1 Coronary artery disease and Wegener granulomatous disease

Wegener's granulomatosis is one of the most common small-and medium sized necrotizing vasculitis that mainly affects the respiratory tract and kidneys. Cardiac manifestations, although they are increasingly recognized, are relatively rare and in most cases silent. Coronary arteries, pericardium, myocardium, endocardium, valves, conduction system and great vessels may be involved. (Korantzopoulos et al., 2004; Suppiah et al., 2011).

According to substantially increased number of reports Wegener's vasculitis can manifest as myocardial ischemia and infarction. Cardiovascular complications without previous history will be also reported in 14% of patients within five years of newly diagnosed Wegener's granulomatosis. (Suppiah et al., 2011). The presence of proteinase 3 (PR3) antineutrophil cytoplasmic antibodies (ANCA) is associated with reduced cardiovascular risk in patients with vasculitis. (Phillip & Luqmani, 2008; Suppiah et al., 2011).

Coronary angiography failed to reveal atherosclerotic disease or thrombotic occlusion in some reported cases. In similar cases magnetic resonance imaging with adenosine test may become the alternative examination to reveal myocardial ischemia, especially subendocardial ischemia. (Cocco & Gasparyan, 2010).

Immunosuppressive therapy with steroids and cyclophosphamide resulted in disappearance of myocardial ischemia in reported cases. (Cocco & Gasparyan, 2010; Phillip & Luqmani, 2008; Suppiah et al., 2011).

3.2.4 Coronary artery disease and polyarteritis nodosa

Polyarteritis nodosa is an ANCA-negative medium and small vessel vasculitis that commonly affects kidneys, gastrointestinal tract, skin, nerves, joints and muscles. There are no specific serological markers and diagnosis depends on clinical presentation, angiography and tissues biopsy. It can pursue a relapsing course, although treatment with corticosteroids and immunosuppressive is usually effective. It is now rarely associated with hepatitis B infection. (Hewins & Jayne, 2010).

Premature coronary artery disease, presenting multiple progressive coronary lesions and necessitating repeated percutaneous interventions and/or bypass, has been described in several case reports in the context of polyarteritis nodosa. (Maillard-Lefebvre et al., 2008; Yanagawa et al., 2010; Yuce et al., 2011).

4. Coronary artery disease and secondary systemic vasculitis

Coronary artery disease as a consequence of secondary systemic vasculitis on the ground of autoimmune diseases such as systemic lupus erythematosus, rheumatoid arthritis, primary antiphospholipid syndrome etc is the leading cause of morbidity and mortality in these cases. It may occur in younger age, it is often asymptomatic and it may be clinically silent in early phases. (Caracciolo et al., 2004; Salmon & Roman, 2008; Sitia et al., 2009; Yildiz, 2010; Yiu et al., 2011). Arterial compliance and arterial distensibility may be altered via systemic inflammation and may lead to accelerated atherosclerosis in secondary systemic vasculitis. (Yildiz, 2010).

Although coronary angiography remains the gold standard for diagnosing coronary stenosis, non invasive and more reliable methods, such as magnetic resonance imaging and PET scan, have been proposed in order to detect subclinical microcirculation abnormalities. (Pennell, & Keenan, 2011; Sitia et al., 2009).

4.1 Coronary artery disease and systemic lupus erythematosus

Systemic lupus erythematosus is a chronic autoimmune disease involving multiple organ systems, characterizing by flares and remissions and presence of antinuclear autoantibodies. Early symptoms most frequently involve the skin and joints. (Kalunian & Merrill, 2009).

Severe lupus morbidity and mortality however, is usually associated with cardiovascular events and major organ damage, particularly kidneys. Coronary artery disease was found to be the main cause of death in systemic lupus erythematosus in all studies. (Caracciolo et al., 2004; Gilboe, 2008; Kalunian & Merrill, 2009).

Improved understanding of systemic lupus erythematosus pathogenesis and immunology has lead to target treatments, such as this provided by biologic agents, which resulted in disease stabilization or even reverse of the disease course. (Kalunian & Merrill, 2009;).

4.2 Coronary artery disease and rheumatoid arthritis

Secondary vasculitis in the setting of rheumatoid arthritis can affect small as well as large vessels, contributing to renal, neurological, gastrointestinal and cardiac complications. High

rheumatoid factor levels and cryoglobulins were associated with multi-organ complications of rheumatoid vasculitis. (Albada-Kuipers et al., 1986; Solomon, et al., 2003).

Chronic systemic inflammation contributed to accelerated atherosclerosis in rheumatoid arthritis. (Ku et al., 2009; Solomon et al., 2003). Coronary rheumatoid vasculitis although rare, is increasingly recognized, can be subclinical, has high mortality rate and in some cases can be found only post-mortem. (Abu-Fadel et al., 2011; Albada-Kuipers et al., 1986; Jeffery, 2010; Solomon et al., 2003). Rapid progression from an ectatic to an aneurysmatic coronary artery leading to acute coronary syndrome in rheumatoid vasculitis has been also reported and only in case reports. (Abu-Fadel et al., 2011; Wang, K.Y., et al., 1999).

Other cardiac manifestations of rheumatoid arthritis reported, were valvular disease, pericarditis and rarely myocarditis and aortitis. (Solomon, 2003; Abu-Fadel et al., 2011).

Early diagnosis and prompt initiation of immunosuppressive therapy in coronary rheumatoid vasculitis, is crucial in prevention of further coronary aneurysmal expansion and rupture. (Abu-Fadel et al., 2011; Wang, K.Y., et al., 1999). According to recent reports, a comprehensive cardiac magnetic resonance imaging is considered an effective and less-invasive method for assessing the microvascular and/or subendocardial ischemic lesions of asymptomatic patients with rheumatoid vasculitis. (Kobayashi, Y., et al., 2010; Mavrogeni et al., 2009).

4.3 Coronary artery disease and antiphospholipid syndrome

Antiphospholipid syndrome is an autoimmune disorder characterized by hypercoagulability, arterial and venous thrombosis, recurrent fetal loss and the presence of antiphospholipid antibodies. (Kaynar et al., 2007; Benzarouel et al., 2007; Levine et al., 2000; Silbiger, 2009).

It may be primary, without other signs of autoantibodies, besides antiphospholipid antibodies or secondary in the setting of underlying disease e.g. malignancy or autoimmune diseases, mainly systemic lupus erythematosus. (Kaynar et al., 2007; Sullivan et al., 1999). Antiphospholipid antibodies also include the lupus anticoagulant and anticardiolipin antibody. (Sullivan et al., 1999; Espinosa & Gervera, 2010).

Coronary artery disease, especially myocardial infarction in young patients, even silent, has been reported in antiphospholipid syndrome, with or without systemic lupus erythematosus. (Kaynar et al., 2007; Benzarouel et al., 2007). In similar cases simultaneous multiple organ thrombotic signs, including renal vein thrombosis, portal vein thrombosis, pulmonary emboli and myocardial infarction, must be excluded by tomographic angiography. (Kaynar et al., 2007; Levine et al., 2000; Silbiger, 2009; Tenedios et al., 2006). Transesophageal echocardiography is also important for detection of leaflet thickening, vegetations and intramural thrombosis in patients with antiphospholipid syndrome and vasculitis. (Silbiger, 2009).

In all cases of coronary artery disease and vasculitis, especially in young patients with no other risk factors for heart disease, hypercoagulability should be excluded, mainly antiphospholipid syndrome. (Eleftheriadis, D., 2007a; Shin & Lee, 2007; Sullivan et al., 1999). Intensive anticoagulation therapy in combination with immunosuppressives is the therapy of choice in antiphospholipid syndrome and vasculitis-related thrombosis. This strategy

results in disease stabilization and prevention of recurrent thrombotic events. (Kaynar et al., 2007; Sullivan et al., 1999).

5. Conclusions

Primary or secondary systemic vasculitides, although rare and diverse chronic inflammatory diseases, resulted in severe and often life-threatening complications, with coronary artery disease being the leading cause of morbidity and mortality in these cases. Chronic inflammation related to vasculitis resulted in coronary aneurysms, coronary stenosis, intramural thrombosis and microcirculation abnormalities, with subsequent cardiovascular events, which may occur at younger age and they are often silent in early phases.

In some reported cases the exact diagnosis can be only made postmortem. Severe acute myocardial infarction and/or sudden death could also be the first manifestation of coronary artery disease related to undiagnosed vasculitis.

Although coronary angiography remains the gold standard for diagnosing coronary lesions, modern non-invasive and more reliable sophisticated imaging techniques, including MRI with adenosine test and PET scan, have been introduced into clinical practice. In order to detect subclinical intramural thrombosis, coronary micro-aneurysms and microcirculation abnormalities, these imaging techniques should be recommended in evaluation of vasculitis-related cardiovascular disease.

Early diagnosis of vasculitis and immediate initiation of therapy with corticosteroids and immunosuppressives, in addition to intensive anticoagulation, is the only optional strategy for good outcome, prevention of further vasculitis progression, regression of early lesions and prevention of further thrombotic events. However, despite intensive therapy in some reports the coronary lesions could not be regressed.

The close collaboration between cardiologist, rheumatologist, pediatrician and radiologist is essential for optional outcome in atypical cases of coronary artery disease related to vasculitis.

6. References

- Abdel-Hadi, O., Greenstone, M.A., Hartley, R.B., & Kidner, P.H. (1981). Myocardial infarction - a rare complication in Henoch-Schonlein purpura. *Postgraduate Medical Journal*, Vol.57, No.668, (1981), pp. 390-392, ISSN: 00325473.
- Abu-Fadel, M.S., Pappy, R., Wayangankar, S., & Kalapura, T. (2011). Rapidly evolving coronary aneurysm in a patient with rheumatoid arthritis. *Cardiology Research and Practice*, Vol. 1, No. 1, (February 2011), article number:659439, ISSN: 20900597.
- Agarwal, M.P., Dwivedi, S., Chaudhary, S.C., Khanna, S., & Agarwal, S. (2010). Small vessel vasculitis associated with myocardial infarction. *Journal, Indian Academy of Clinical Medicine*, Vol.11, No.1, (January 2010), pp. 54-58, ISSN:09723560.
- Agraharkar, M., Gokhale, S., Le, L., Rajaraman, S., & Campbell. G.A. (2000). Cardiopulmonary manifestations of Henoch-Schonlein purpura. *American Journal of Kidney Diseases*, Vol.35, No.2, (2000), pp. 319-322, ISSN: 02726386.

- Akagi, T. (2011). Catheter interventions for Kawasaki disease : Curent concepts and future directions. *Korean Circulation Journal*, Vol.41, No.2, (February 2011), PP. 53-57, ISSN: 17385520.
- Albada-Kuipers, G.A., Bruijn, J.A, Westedt, M.-L., Breedveld, F.C. &Eulderink, F. (1986). Coronary arteritis complicating rheumatoid arthritis. *Annals of the Rheumatic Diseases*, Vol.45, No. 11, (November 1986), pp. 963-965, ISSN: 00034967.
- Amano, J., & Suzuki, A. (1992). Surgical treatment of cardiac involvement in Takayasu Arteritis. *Heart and Vessels*, Vol. 7, No. 7 suppl., (1992), pp 168-178. ISSN: 09108327.
- Andersson, R. (2000). Giant cell arteritis as a cause of death. *Clinical and Experimental Rheumatology*, Vol. 18, No. suppl. 20, (2000), pp. S27-S28. ISSN: 0392856X.
- Araszkiewicz, A., Prech, M., Hrycaj, P., Lesiak, M., Grajek, S., Cieslinski, A. (2007). Acute myocardial infarction and rapid development of coronary aneurysms in a young woman-Unusual presentation of Takayasu arteritis? *Canadian Journal of Cardiology*, Vol.23, No. 1, (January 2007). Pp. 61-63, ISSN: 0828282X.
- Benzarouel, D., Benyass, A., Rabhi, M., Chaari, J., Boukili, A., & Hamani, A. (2007). Silent myocardial infarction and antiphospholipid antibody syndrome. *Annales de Cardiologie et d'Angiologie*, Vol.56, No. 6, (December 2007), pp. 313-315, ISSN: 00033928.
- Bijl, M. (2003). Endothelial activation, endothelial dysfunction and premature atherosclerosis in systemic autoimmune disease. *Netherlands Journal of Medicine*, Vol.61, No.9, (September 2003), pp.273-277, ISSN: 03002977.
- Bossert, M., Clement, P., Balblanc, J.-C., Lohse, A., & Wendling, D. (2011). Aortic involvement in giant cell arteritis: Current data. *Joint Bone Spine*, Vol. 78, No.3, (May 2011), pp. 246-251, ISSN: 1297319X.
- Caballero-Mora, F.J., Alonso-Martin, B., Tamariz-Martel-Moreno, A., Cano-Fernandez, J., & Sanchez-Bayle, M. (2011).Kawasaki disease in 76 patients. Risk factors for coronary artery aneurysms. *Anales de Pediatría*, Vol.74, No.4, (April 2011), pp. 232-238, ISSN: 16954033.
- Caracciolo, E.A, Marcu, C.B., Chantous, A., Donohue, T.J., Hutchinson, G. (2004). Coronary vasculitis with acute myocardial infarction in a young woman with systemic lupus erythematosus. *Journal of Clinical Rheumatology*, Vol. 10, No.2, (april 2004), pp. 66-68, ISSN: 10761608.
- Carmichael, P., Brun, E., Jayawardene, S., Abdulkadir, A., & O'Donnell, P.J. (2002). A fatal case of bowel and cardiac involvement in Henoch-Schonlein Purpura. *Nephrology Dialysis Transplantation*, Vol.17, No.3, (2002), pp.497-499, ISSN: 09310509.
- Churg, J., & Strauss, J. (1951). Allergic granulomatosis, allergic angiitis and periarteritis nodosa. *The American Journal of Pathology*, Vol. 27, No.2, (March 1951), pp. 277-301, ISSN: 00029440.
- Cocco, G., & Gasparyan, A.Y. (2010). Myocardial ischemia in Wegener's granulomatosis: Coronary atherosclerosis versus vasculitis. *Open Cardiovascular Medicine Journal*, Vol.4, No.1, (specific issues 2010), pp.57-62, ISSN: 18741924.
- De Castro, P.A, Urbano, L.M.F., & Costa, I.M.C. (2009). Kawasaki disease. *Anais Brasileiros de Dermatologia*, Vol.84, No.4, (July 2009), pp. 317-329, ISSN: 03650596.
- Dhawan, S., & Tak, T. (2004). Myocardial infarction in a patient with thrombotic thrombocytopenic purpura. *International Journal of Cardiology*, Vol.95, No.(2-3), (June 2004), pp.339-341, ISSN: 01675273.

- Donald, K.J., Edwards, R.L., & McEvoy, J.D. (1976) An ultrastructural study of the pathogenesis of tissue injury in limited Wegener's granulomatosis. *Pathology*, Vol.8, No.2, (April 1976), pp.161-169, ISSN: 00313025.
- Eberhardt, R.T., & Dhadly, M. Giant cell arteritis: Diagnosis, management and cardiovascular implications. *Cardiology in Review*, Vol.15, No.2, (March 2007), pp. 55-61, ISSN: 10615377.
- Eleftheriadis, D. (2007a). Severe coronary artery disease in the setting of Henoch-Schoenlein Purpura. *International Journal of Cardiology*, Vol.118, No. 2, (May 2007), pp. 262-263, ISSN: 01675273.
- Eleftheriadis, D. (2007b). Severe coronary artery disease in the setting of Henoch-Schoenlein Purpura: Superimposition of antiphospholipid or polyangitis overlap syndrome?. *International Journal of Cardiology*, Vol.122, No. 2, (November 2007), pp. 184, ISSN: 01675273.
- Eleftheriou, D., Dillon, M.J., & Brogan, P.A. (2009). Advances in childhood vasculitis. *Current Opinion in Rheumatology*, Vol.21, No.4, (July 2009), pp.411-418, ISSN:10408711.
- Espinosa, G., & Gervera, R. (2010). Cardiac and pulmonary manifestations in the antiphospholipid syndrome. *Current Rheumatology Reviews*, Vol.6, No.1, (February 2010), pp. 3-11, ISSN: 15733971.
- Freddo, T., Price, M., Kase, C., & Goldstein, M.P. (1999). Myocardial infarction and coronary artery involvement in giant cell arteritis. *Optometry and Vision Science*, Vol.76, No.1, (January 1999), pp. 14-18, ISSN: 10405488.
- Fukazawa, R., & Ogawa, S. (2009). Long-term prognosis of patients with Kawasaki disease: At risk for future atherosclerosis? *Journal of Nippon Medical School*, Vol.76, No.3, (June 2009), pp. 124-133, ISSN: 13454676.
- Gasparyan, A.Y., & Ugurlucan, M. The emerging issue of cardiovascular involvement in familial Mediterranean fever. *Archives of Medical Science*, Vol. 4, No.4, (2008), pp. 465-467, ISSN: 17341922.
- Gilboe, J-M. (2008). The epidemiology of systemic lupus Erythematosus. *Norsk Epidemiologi*, Vol. 18, No.1, (February 2008), pp.31-36, ISSN: 08032491.
- Gomard-Mennesson, E., Landron, C., Dauphin, C., Epaulard, O., Petit, C., Green, L., Roblot, P., Lusson, J.R., Broussolle, C., & Seve, P. (2010). Kawasaki disease in adults: report of 10 cases. *Medicine*, Vol.89, No. 3, (May 2010), pp. 149-158, ISSN::00257974.
- Gonzalez-Juanatey, C., Llorca, J., Garcia-Porrúa, C., Sanchez-Andrade, A., Martin, J., & Gonzalez-Gay, M.A. (2006). Steroid therapy improves endothelial function in patients with biopsy-proven giant cell arteritis. *Journal of Rheumatology*, Vol.33, No.1, (January 2006), pp. 74-78, ISSN: 0315162X.
- Güven, H., Özhan, B., Bakiler, A.R., Salar, K., Kozan, M., & Bilgin, S. (2006). A case of Henoch-Schönlein purpura and rheumatic carditis with complete atrioventricular block. *European Journal of Pediatrics*, Vol. 165, No.6, (June 2006), pp.395-397, ISSN:03406199.
- Hasper, D., Schrage, D., Niesporek, S., Knollmann, F., Barckow, D., & Oppert, M. (2006). Extensive coronary thrombosis in thrombotic-thrombocytopenic purpura. *International Journal of Cardiology*, Vol.106, No.3, (January 2006), pp. 407-409, ISSN:01675273.

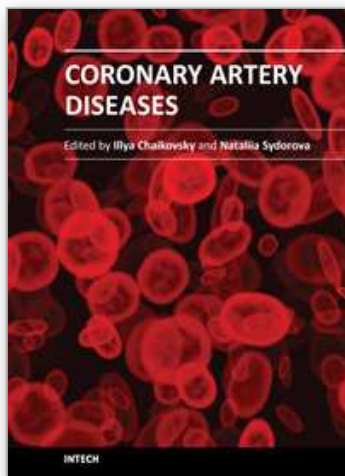
- Hata, A., & Onouchi, Y. (2009). Susceptibility genes for Kawasaki disease: Toward implementation of personalized medicine. *Journal of Human Genetics*, Vol.54, No.2, (February 2009), pp. 67-73, ISSN: 14345161.
- Hewins, P., & Jayne, D. (2010). Medium vessel vasculitis. *Medicine*, Vol. 38, No.2, (February 2010), pp.93-96, ISSN:13573039.
- Jeffery, R.C. (2010). Clinical features of rheumatoid arthritis. *Medicine*, Vol.38, No.4, (April 2010), pp. 167-171, ISSN: 13573039.
- Kalunian, K., & Merrill, J.T. (2009). New directions in the treatment of systemic lupus erythematosus. *Current Medical Research and Opinion*, Vol.25, No.6, (June 2009), pp.1501-1514, ISSN: 03007995.
- Kalyoncu, M., Cakir, M., Erduran, E., & Okten, A. (2006) Henoch-Schönlein purpura: A case with atypical presentation. *Rheumatology International*, Vol. 26, No.7, (May 2006), pp.669-671, ISSN: 01728172.
- Kane, G.C., & Keogh, K.A. (2009). Involvement of the heart by small and medium vessel vasculitis. *Current Opinion in Rheumatology*, Vol.21, No.1, (January 2009), pp. 29-34, ISSN:10408711.
- Kaplan, M.J. (2009). Management of cardiovascular disease risk in chronic inflammatory disorders. *Nature Reviews Rheumatology*, Vol. 5, No.4, (April 2009), pp. 208-217, ISSN: 17594804.
- Kaynar, K., Ulusoy, S., Gul, S., Kilicarslan, F., Oztuna, F., Ahmetoglou, A., & Omay, S.B. (2007). Antiphospholipid syndrome with lupus erythematosus presenting with myocardial infarction. *Scottish Medical Journal*, Vol. 52, No.2, (May 2007), ISSN: 00369330.
- Keogh, K.A., & Specks, U. (2003). Churg-Strauss syndrome. Clinical presentation, antineutrophil cytoplasmic antibodies and leukotriene receptor antagonists. *American Journal of Medicine*, Vol. 115, No.4, (September 2003), pp. 284-290, ISSN:00029343.
- Kereiakes, D.J., Ports, T.A., & Finkbeiner, W. (1984). Endomyocardial biopsy in Henoch-Schönlein purpura. *American Heart Journal*, Vol. 107, No.2, (1984), pp. 382-385, ISSN:00028703.
- Kimura, T., Komura, M., & Okubo, Y. (2011). Atypical giant cell arteritis predominantly involving intramural coronary arteries: a case showing refractory dialysis-related hypotension. *Heart and Vessels*, (2011), pp.1-5. ISSN: 09108327, (article in press).
- Knockaert, D.C. (2007). Cardiac involvement in systemic inflammatory diseases. *European Heart Journal*, Vol.28, No. 15, (August 2007), pp. 1797-1804, ISSN: 0195668.
- Korantzopoulos, P., Papaioannides, D., & Siogas, K. (2004). The heart in Wegener's granulomatosis. *Cardiology*, Vol. (102), No.1, (2004), pp. 7-10, ISSN: 00086312.
- Kobayashi, Y., Giles, J.T., Hirano, M., Yokoe, I., Nakajima, Y., Bathon, J.M., Lima, J.A.C., & Kobayashi, H. (2010). Assessment of myocardial abnormalities in rheumatoid arthritis using a comprehensive cardiac magnetic resonance approach: A pilot study. *Arthritis Research & Therapy*, Vol.12, No. 5, (September 2010), pp.R171, ISSN: 14786354.
- Ku, I.A., Imboden, J.B., Ysue, P.Y., & Ganz, P. (2009). Rheumatoid arthritis-A model of systemic inflammation driving atherosclerosis. *Circulation Journal*, Vol.73, No.6, (June 2009), pp. 977-985, ISSN:13469843.
- Kumar, P., Velissaris, T., Sheppard, M.N., & Pepper, J.R. (2002). Giant cell arteritis confined to intramural coronary arteries. *Journal of Cardiovascular Surgery*, Vol. 43, No. 5, (October 2002), pp. 647-649, ISSN: 00219509.

- Lecutier, M.A. (1952). A case of the Schönlein-Henoch syndrome with myocardial necrosis. *Journal of Clinical Pathology*, Vol.5, No.4, (November 1952), pp. 336-338, ISSN:00219746.
- Levine, J.S., Branch, D.W., & Rauch, J. (2002). The antiphospholipid syndrome. *The New England Journal of Medicine*, Vol. 346, No. 10, (March 2000), pp. 752-763, ISSN: 00284793.
- Lin, L.-W., Wang, S.-S., & Shun, C.T. (2007). Myocardial infarction due to giant cell arteritis: A case report and literature review. *Kaohsiung Journal of Medical Sciences*, Vol. 23, No. 4, (April 2007), pp. 195-198, ISSN: 1607551X.
- Lin, M.-T., Wang, J.-K., Yeh, J.-I., Sun, L.-C., Chen, P.-L., Wu, J.-F., Chang, C.-C., Lee, W.-L., Shen, C.-T., Wang, N.-K., Wu, C.-S., Yeh, S.-Z., Chen, C.-A., Cjiu, S.-N., & Wu, M.-H. (2011). Clinical implication of the C allele of the ITPKC gene SNP rs28493229 in Kawasaki disease: Association with disease susceptibility and BCG scar reactivation. *Pediatric Infectious Disease Journal*, Vol.30, No.2, (February 2011), pp. 148-152, ISSN:08913668.
- Lutz, H., Ackermann, T., Krombach, G.A., Groene, H.-J., Rauen, T., Floege, J., Mertens, P.R. (2009). Henoch-Schönlein Purpura complicated by cardiac involvement: Case report and review of the literature. *American Journal of Kidney Diseases*, Vol.54, No.5, (November 2009), pp. e9-e15, ISSN: 02726386.
- Magro, C.M., & Crowson, A.N. (1999). A clinical and histologic study of 37 cases of immunoglobulin A-associated vasculitis. *American Journal of Dermatology*, Vol. 21, No.3, (June 1999), pp. 234-240, ISSN: 01931091.
- Maillard-Lefebvre, H., Launay, D., Mouquet, F., Gaxotte, V., Hachulla, E., De Groote, P., Lambert, M., Queyrel, V., Morell-Dubois, S., Beregi, J.-P., Bauters, C., Hatron, P.-Y. (2008). Polyarteritis nodosa-related coronary aneurysms. *Journal of Rheumatology*, Vol. 35, No. 5, (May 2008), pp. 933-934, ISSN: 0315162X.
- Mavrogeni, S., Manoussakis, M.N., Karagiorga, T.C., Douskou, M., Panagiotakos, D., Bournia, V., Cokino, D.V., & Moutsopoulos, H.M. (2009). Detection of coronary artery lesions and myocardial necrosis by magnetic resonances in systemic necrotizing vasculitides. *Arthritis Care and Research*, Vol.61, No.8, (August 2009), pp.1121-1129, ISSN: 00043591.
- Monastiri, K., Selmi, H., Tabarki, B., Yacoub, M., Mahjoub, T., & Essoussi, A.S. (2002). Primary antiphospholipid syndrome presenting as complicated Henoch-Schönlein purpura. *Archives of Disease in Childhood*, Vol.86, No.2, (month 2002), pp. 132-133, ISSN:00039888.
- Mukhtyar, C., Brogan, P., & Luqmani, R., (2009). Cardiovascular involvement in primary systemic vasculitis. *Best Practice and Research Clinical Rheumatology*, Vol.23, No. 3, (June 2009), pp. 419-428, ISSN: 15216942.
- Musuruana, J.L., Cavallasca, J.A., Berduc, J., & Vicario, J. (2011). Coronary artery aneurysms in Wegener's granulomatosis. Case report. *Joint Bone Spine*, Vol.78, No.3, (May 2011), pp. 309-311, ISSN:1297319X.
- Nabatian, S., Quinn, P., DuBrow, I., Rosenberg, M., & Lakier, J. (2006). Suspected vasculitis in an adolescent female with cardiomyopathy, myocardial infarction and heart failure requiring heart transplantation. *Journal of Adolescent Health*, Vol. 38, No.1, (January 2006), pp. 60-64. ISSN:1054139X.

- Oates-Whitehead, R.M., Baumer, J.H., Haines, L., Love, S., Maconochie, I.K., Gupta, A., Roman, K., Dua, J.S., & Flynn, I. (2003). Intravenous immunoglobulin for the treatment of Kawasaki disease in children. *Cochrane Database Syst Review*, Vol. 4, (2003), CD004000.
- Osman, A., & McCreery, C.J. (2000). Cardiac vasculitis in Henoch-Schönlein purpura. *Circulation*, Vol.101, No.5, (February 2000), pp. E69-E70, ISSN 0009-7322. Online ISSN: 1524-4539.
- Ouali, S., Kacem, S., Fradj, F.B., Gribaa, R., Naffeti, E., Remedi, F., Laaoueni, S., & Boughzela, E. (2011). Takayasu arteritis with coronary aneurysms: Causing acute myocardial infarction in a young man. *Texas Heart Institute Journal*, Vol. 38, No.2, (2011), pp. 183-186. ISSN: 07302347.
- Paredes, N., Mondal, T., Brandao, L.R., & Chan, A.K. (2010). Management of myocardial infarction in children with Kawasaki disease. *Blood Coagulation & Fibrinolysis*, Vol.21, No.7, (October 2010), pp. 620-631, ISSN: 09575235.
- Park, J.-S., Lee, H.C., Lee, S.-K., Kim, S.-P., Kim, Y.D., Ahn, M.S., & Hong, T.J. (2009). Takayasu's arteritis involving the ostia of three large coronary arteries. *Korean Circulation Journal*, Vol. 39, No. 12, (December 2009), pp.551-555, ISSN: 17385520.
- Pellegrin, M.C., Taddio, A., Ventura, A., & Lepore, L. (2011). Kawasaki disease: A retrospective study on 45 patients. *Medico e Bambino*, Vol.30, No.4, (April 2011), pp. 236-241, ISSN: 15913090.
- Pennel, D.J., & Keenan, N.G. (2011). Coronary microvascular dysfunction in systemic lupus erythematosus identified by CMR imaging. *JACC: Cardiovascular Imaging*, Vol.4, No.1, (January 2011), pp.34-36, ISSN:1936878X.
- Pilletout, E., Thervet, E., Hill, G., Alberti, C., Vanhille, P., Nochy, D. (2002). Henoch-Schoenlein Purpura in adults: outcome and prognostic factors. *Journal of the American Society of Nephrology*, Vol.13, No.5, (May 2002), pp. 1271-1278, ISSN: 10466673.
- Phillip, R., & Luqmani, R. (2008). Mortality in systemic vasculitis: A systematic review. *Clinical and Experimental Rheumatology*, Vol. 26, No. 5 suppl, (September 2008), pp. S94-S104, ISSN: 0392856X.
- Polizzotto, M.N., Gibbs, S.D., Beswick, W., & Seymour, J.F. (2006). Cardiac involvement in Henoch-Schönlein purpura. *Internal Medicine Journal*, Vol.36, No. 5, (May 2006), pp.328-331, ISSN:14440903.
- Reinhold-Keller, E., Herlyn, K., Wagner-Bastmeyer, R., & Gross, W.L. (2005). Stable incidence of primary systemic vasculitides over five years: results from the German vasculitis register. *Arthritis Rheum*, Vol.53, No.1, (February 2005), pp. 93-99, ISSN: 0003-4969.
- Rowley, A.H. (2011). Kawasaki disease: Novel insights into etiology and genetic susceptibility. *Annual Review of Medicine*, Vol.62, No.18, (February 2011), pp. 69-77, ISSN:00664219.
- Sable-Fourtassou, R., Cohen, P., Mahr, A., Pagnoux, C., Mouthon, L., Jayne, D., Blockmans, D., Cordier, J.-F., Delaval, P., Puechal, X., Lauque, D., Viallard, J.-F., Zoulim, A., Guillemin, L. (2005). Antineutrophil cytoplasmic antibodies and the Churg-Strauss syndrome. *Annals of Internal Medicine*, Vol.143, No.9, (November 2005), pp.632-638, ISSN :00034819.
- Saito, S., Arai, H., Kim, K. & Aoki, N. (1994). Acute myocardial infarction in a young adult due to solitary giant cell arteritis of the coronary artery diagnosed antemortally by primary directional coronary atherectomy. *Catheterization and Cardiovascular Diagnosis*. Vol. 33, No. 3, (1994), pp. 245-249, ISSN: 00986569.

- Salmon, J.E. & Roman, M.J. (2008). Subclinical atherosclerosis in rheumatoid arthritis and systemic lupus erythematosus. *American Journal of Medicine*, Vol.121, No. 10 suppl 1, (October 2008), pp. S3-S8, ISSN:00029343.
- Satoh, M., Mikuniya, A., Mikami, M., Higashiyama, A., Sasaki, N., Tahkahashi, M., Fukushi, K., Onodera, K., & Oike, Y. (1991). A case of Schönlein -Henoch purpura with myocardial complications. *Respiration and Circulation*, Vol.39, No.3, (March 1991), pp. 273-277, ISSN:04523458.
- Savage, C.O.S. (2002). The evolving pathogenesis of systemic vasculitis. *Clinical Medicine*, Vol.2, No.5, (September 2002), pp. 458-464, ISSN:14702118.
- Sheikhzadeh, A., Tettenborn, I., Eftekhazadeh, M., Schnabel, A. (2002). Occlusive thromboasoropathy (Takayasu Disease): Clinical and angiographic features and a brief review of literature. *Angiology*, Vol.53, No.1, (2002), pp. 29-40, ISSN: 00033197.
- Shin, J.I., & Lee J.S. (2007). Severe coronary artery disease in Henoch-Schoenlein purpura: superimposition of antiphospholipid or polyangitis overlap syndrome? *International Journal of Cardiology*, Vol.122, No. 2, (November 2007), pp. 182-183, ISSN:01675273.
- Silbiger, J.J. (2009). The cardiac manifestations of antiphospholipid syndrome and their echocardiographic recognition. *Journal of the American Society of echocardiography*, Vol. 22, No.10, (October 2009), pp.1100-1108, ISSN: 08947317.
- Sinico, R.A., & Bottero, P. (2009). Churg-Strauss angiitis. *Best Practice & Research: Clinical Rheumatology*, Vol.23, No.3 (June 2009), pp.355-366, ISSN:15216942.
- Sitia, S., Atzeni, F., Sarzi-Puttini, P., Di Bello, V., Tomasoni, L., Delfino, L., Antonini-Canterin, F., Di Salvo, G., De Gennaro Colonna, V., La Carrubba, S., Carerj, S., & Turiel, M. (2009). Cardiovascular involvement in systemic autoimmune diseases. *Autoimmunity Reviews*, Vol. 8, No.4, (February 2009), pp. 281-286, ISSN:15689972.
- Solomon DH, Karlson EW, Rimm EB, Cannuscio, C.C., Mandl, L.A., Manson, J.E., Stampfer, M.J., & Curhan, G.C. (2003). Cardiovascular morbidity and mortality in women diagnosed with rheumatoid arthritis. *Circulation*, Vol. 107, No.9, (March 2003), pp.1303-1397, ISSN:00097322.
- Sullivan, M.A., De Pasquale, N.P., & Coplan, N.L. (1999). Antiphospholipid antibodies and coronary arterial thrombosis. *Cardiovascular Reviews and Reports*, Vol. 20, No. 6, (June 1999).pp. 315+325+335, ISSN: 01973118.
- Suppiah, R., Judge, A., Batra, R., Flossman, O., Harper, L., Höglund, P., Javaid, M.K., Jayne, D., Mukhtyar, C., Westman, K., Davis Jr., J.C., Hoffman, G.S., McCune, W.J., Merkel, P.A., StClar, E.W., Seo, P., Spiera, R., Stone, J.H. Luqmani, R. (2011). A model to predict cardiovascular events in patients with newly diagnosed Wegeners's granulomatosis and microscopic polyangiitis. *Arthritis Care & Research*, Vol. 63, No.4, (April 2011), pp. 588-596, ISSN: 21514658.
- Tanimoto, K. (1994). Polyangiitis overlap syndrome. *Nippon Rinsho, Japanese Journal of Clinical Medicine*, Vol.52, No.8, (August 1994), pp. 2123-2126, ISSN:00471852.
- Tenedios, F., Erkan, D., & Lockshin, M.D. (2006). Cardiac manifestations in the antiphospholipid syndrome. *Rheumatic Disease Clinics of North America*, Vol. 32, No.3, (August 2006), pp.491-507, ISSN:0889857X.
- Tsuda, E., Abe, T., & Tamaki, W. (2011). Acute coronary syndrome in adult patients with coronary artery lesions caused by Kawasaki disease: Review of case reports. *Cardiology in Young*, Vol.21, No.1, (February 2011), pp. 74-82, ISSN: 10479511.

- Turesson, C., Jacobsson, L.T., Matteson, E.L. (2008). Cardiovascular comorbidity in rheumatic diseases. *Vascular Health and Risk Management*, Vol. 4, No.3, (2008), pp.605-614, ISSN: 11766344.
- Wang, K.-Y., Ting, C.-T., Sutton, M.St.J., & Chen, Y.T. (1999). Coronary artery aneurysms: A 25-patient study. *Catheterization and Cardiovascular Interventions*, Vol.48, No.1, September 1999), pp.31-38, ISSN: 15221946.
- Watanabe, K., Abe, H., Mishima, T., Ogura, G., & Suzuki, T. (2003). Polyangitis overlap syndrome: a fatal case combined with adult Henoch-Schonlein purpura and polyarteritis nodosa. *Pathology International*, Vol.53, No.8, (August 2003), pp. 569-573, ISSN : 13205463.
- Wenger, M., & Schneider, J. (1996). Coronary infarction due to giant cell arteritis. *Vasa-Journal of Vascular Diseases*, Vol.25, No.4, (1996), pp. 373-377, ISSN:03011526.
- Wood, L.E., & Tulloh, R.M.R. (2009). Kawasaki disease in children. *Heart*, Vol.95, No.10, (May 2009), pp. 787-792, ISSN:13556037.
- Wooditch, A.C. & Aronoff, S.C. (2005). Effect of initial corticosteroid therapy on coronary artery aneurysm formation in Kawasaki disease: a meta-analysis of 862 children. *Pediatrics*, Vol.116, No. 4, (December 2005), pp. 989-995, ISSN:00314005.
- Yanagawa, B., Kumar, P., Tsuneyoshi, H., Kachel, E., Massad, F., Moussa F., Cohen, G.N. (2010). Coronary artery bypass in the context of polyartiritis nodosa. *Annals of Thoracic Surgery*, Vol. 89, No 2, (February 2010, pp. 623-625, ISSN: 00034975.
- Yildiz, M. (2010). Arterial distensibility in chronic inflammatory rheumatic disorders. *Open Cardiovascular Medicine Journal*, Vol.4, No.1, (February 2010), pp. 83-88, ISSN 18741924.
- Yiu, K.-H, Wang, S., Mok, M.-Y., Ooi, G.-C., Khong, P.-L., Lau, C.-S., Tse, H.-F. (2011). Relationship between cardiac valvular and arterial calcification in patients with rheumatoid arthritis and systemic lupus erythematosus. *Journal of Rheumatology*, Vol.38, No. 4, (April 2011), pp.621-627, ISSN: 0315162X.
- Yuce, M., Davutoglu, V., Sari, I., Onat, A.M., (2011). Polyarteritis nodosa with multiple coronary aneurysms presenting as acute myocardial infarction. *The American Journal of the Medical Sciences*, Vol.341, No. 5, (May 2011), pp. 409, ISSN: 15382990.
- Zaidi, M., Singh, N., Kamran, M., Ansari, N., Nasr, S.H., Acharya, A. (2008). Acute onset of hematuria and proteinuria associated with multiorgan involvement of the heart, liver, pancreas, kidneys, and skin in a patient with Henoch-Schönlein purpura. *Kidney International*, Vol. 73, No.4, (February 2008), pp.503-508, ISSN: 00852538.
- Zaidi, M., Singh, N., Kamran, M., Ansari, N., Nasr, S.H., Acharya, A. (2008). Response to multiorgan involvement of vasculitis: Henoch-Schönlein Purpura or polyangiitis overlap syndrome. *Kidney International*, Vol. 74, No.6, (September 2008), pp.828-829, ISSN: 00852538.



Coronary Artery Diseases

Edited by Dr. Illya Chaikovsky

ISBN 978-953-51-0238-0

Hard cover, 332 pages

Publisher InTech

Published online 07, March, 2012

Published in print edition March, 2012

This book has "wide geography" both literally and figuratively. First of all, this book brings together contributions from around the world, both from post-industrial countries and developing world. This is natural, because coronary artery disease is becoming pandemic worldwide. CAD is the single most frequent cause of death in developed countries, causes about 1 in every 5 deaths. Mortality from cardiovascular disease is predicted to reach 23.4 million in 2030. Moreover, in the developing world, cardiovascular disease tends to affect people at a younger age and thus could negatively affect the workforce and economic productivity. The morbidity, mortality, and socioeconomic importance of CAD make its diagnosis and management fundamental for all practicing physicians. On another hand, the book widely represents "geography" of CAD itself, i.e. many various aspects of its pathophysiology, epidemiology, diagnosis, treatment are touched in this book. This book does not pretend on complete and integral description of the Coronary artery disease. Rather, it contains selected issues on this complex multifactorial disease. Nevertheless, we hope that readers will find Coronary Artery Disease useful for clinical practice and further research.

How to reference

In order to correctly reference this scholarly work, feel free to copy and paste the following:

Damianos Eleftheriadis and Nikolaos Eleftheriadis (2012). Coronary Artery Disease and Systemic Vasculitis: Case Report and Review, Coronary Artery Diseases, Dr. Illya Chaikovsky (Ed.), ISBN: 978-953-51-0238-0, InTech, Available from: <http://www.intechopen.com/books/coronary-artery-diseases/coronary-artery-disease-and-systemic-vasculitis>

INTECH
open science | open minds

InTech Europe

University Campus STeP Ri
Slavka Krautzeka 83/A
51000 Rijeka, Croatia
Phone: +385 (51) 770 447
Fax: +385 (51) 686 166
www.intechopen.com

InTech China

Unit 405, Office Block, Hotel Equatorial Shanghai
No.65, Yan An Road (West), Shanghai, 200040, China
中国上海市延安西路65号上海国际贵都大饭店办公楼405单元
Phone: +86-21-62489820
Fax: +86-21-62489821

© 2012 The Author(s). Licensee IntechOpen. This is an open access article distributed under the terms of the [Creative Commons Attribution 3.0 License](https://creativecommons.org/licenses/by/3.0/), which permits unrestricted use, distribution, and reproduction in any medium, provided the original work is properly cited.

IntechOpen

IntechOpen