

We are IntechOpen, the world's leading publisher of Open Access books Built by scientists, for scientists

6,900

Open access books available

186,000

International authors and editors

200M

Downloads

Our authors are among the

154

Countries delivered to

TOP 1%

most cited scientists

12.2%

Contributors from top 500 universities



WEB OF SCIENCE™

Selection of our books indexed in the Book Citation Index
in Web of Science™ Core Collection (BKCI)

Interested in publishing with us?
Contact book.department@intechopen.com

Numbers displayed above are based on latest data collected.
For more information visit www.intechopen.com



Endovascular Therapies in Acute DVT

Jeff Tam and Jim Koukounaras
*The Alfred Hospital
 Australia*

1. Introduction

Deep venous thrombosis of the lower limb is a common disease with an incidence of 80 per 10000 (Patel et al 2011) and has potential fatal consequences in the form of pulmonary embolism.

It is usually seen in patients undergoing major surgery particularly orthopaedic surgery, trauma, prolonged immobilisation or hypercoagulable states (such as in the context of malignancy). There are associations with drugs such as the oral contraceptive pill and hormone replacement therapy (tamoxifen) that predispose to hypercoagulability.

2. Pathology and clinical presentation

Deep venous thrombosis of the lower extremity can occur anywhere from the ankle to the IVC, however it is those that occur between the IVC and femoral veins that most often lead to venous hypertension, resulting in the more severe symptoms. They are also more likely to recur (Vendatham 2006).

The clinical spectrum can range from being completely asymptomatic to post thrombotic syndrome: ulceration, pain, and intractable oedema.

Traditionally, DVTs have been treated with the use of oral anticoagulation medication (such as warfarin) for a period of 6 months. However, this is associated with a high risk for recurrent thrombosis, and approximately one third will develop post thrombotic syndrome despite treatment (Prandoni et al 1996). The recurrence of DVT is thought to be related to damage to the venous valves during an episode of thrombosis and the low rate of recanalisation particularly in caval/iliac/femoral venous thrombosis, which leads to obstruction and venous hypertension. It has been suggested that anticoagulation therapy alone may be inadequate to prevent the damage to the venous valves in the setting of caval/iliac/femoral DVT. Moreover, it has been shown that early thrombus removal is associated with a lower incidence of symptoms related to post thrombotic syndrome (Sharafuddin 2003). These factors have prompted use of invasive techniques such as catheter directed thrombolysis and mechanical thrombectomy, particularly in the acute setting, for thrombus removal.

There are currently two large randomised controlled trials (TORPEDO and ATTRACT) underway investigating the efficacy of these invasive techniques and early results suggest

that early intervention in the setting of acute DVT is associated with lower recurrence rates, lower incidence of post thrombotic syndrome and lower rates of fatal PE.

Pending the results of these trials however, clinicians should assess the need for invasive measures on a case by case basis, based on the timing of the DVT, associated risk factors for development of DVT, risk factors for thrombolysis related bleeding, age and prognosis of the patient.

3. Endovascular techniques

The goals of endovascular treatment of acute DVT include: prevention of PE, early symptom relief, and prevention of post thrombotic syndrome (Vendatham 2006).

The endovascular techniques available to achieve these goals include catheter directed thrombolysis, mechanical/rheolytic thrombectomy and stent placement. IVC filters can theoretically be used in conjunction with these techniques to reduce the rate of PE during therapy, although this is controversial.

These techniques require knowledge of, and skills in, ultrasound guided needle punctures, wire and catheter manipulation, thrombolysis drug administration, placement of endovascular stents, and familiarity with the use of various mechanical/rheolytic thrombectomy devices. The specific equipment will vary according to their availability and preference.

3.1 Catheter directed thrombolysis

Thrombolytic agents activate plasminogen which leads to the breakdown of clot. Systemic thrombolysis results in better short and long term clinical results (Comerota & Aldridge 1993; Gallus AS 1998; Schweizer J, et al 2000; Wells PS 2001) when compared with anticoagulation, but this is at the expense of an increase in serious bleeding and PEs.

Catheter directed thrombolysis (CDT) has developed in response, in an effort to reduce the dose of systemic thrombolytic by delivering the agent at the site of thrombosis, allowing a relative higher concentration to reach the thrombus with a lower systemic dose. This also reduces the duration of the therapy and complication rates. In addition, this technique allows the simultaneous treatment of underlying lesions that are often the cause of the thrombosis itself.

Indications for CDT should focus on patients who ideally are young and active and have a normal life expectancy. In older patients, CDT should be performed in cases of an acutely threatened limb. Both these groups should have acute symptomatic DVT or severe clot burden that involves the IVC. Threshold for thrombolysis in iliofemoral DVT should be lower than that for femoro-popliteal DVT, due to the higher risk of developing post thrombotic syndrome in the former group (discussed in previous sections). Patients who have propagation of clot despite anticoagulation should also be considered for treatment. CDT is most effective when instituted within 4 weeks of thrombosis.

Contraindications are similar to thrombolysis of any site, and include recent major surgery, recent cerebrovascular bleed, recent CPR, pregnancy or coagulopathy. In cases of

phlegmasia cerulea dolens with contraindications to thrombolysis, surgical thrombectomy may be considered (Sharafuddin 2003).

In order to effectively deliver the thrombolytic agent, the location and extent of the affected vessels must be elucidated, and this can be performed with ultrasound in the lower extremity. For the central venous system or the peripheral system, a venogram using CT, MRI or angiography can be used, which give a better appreciation of the extent and location of the clot.

Once the inflow and outflow of the occluded segment is elucidated, the access site can be selected. Early experience with access sites centred on the internal jugular vein (Grosman & Macpherson 1999). However this has technical disadvantages such as the longer route of access causing catheter migration, catheters stimulating cardiac arrhythmias, and difficulty crossing venous valves. In the past, some authors also used the brachial vein and contralateral common femoral vein, which have also fallen out of favour. The ipsilateral popliteal access later became the route of choice for most authors, being easily punctured with ultrasound guidance, having less problems with venous valves, and providing direct access to the thrombosed segment (Grossman, 1998; Sharafuddin 2003). Other common access routes include the common femoral vein (used in ilio caval disease) and posterior tibial vein (for infrapopliteal disease). Occasionally, antegrade and retrograde access is simultaneously used, with the catheters crossed, to treat both up and downstream disease (Molina et al 1992, Raju et al 1998, Tarry et al 1994). In extensive and severe disease, particularly in the calf, selection of the smaller veins with the catheter is extremely difficult, and sometimes impossible, which leads to poor inflow and higher rates of rethrombosis. Comerota (1993) described infusion through the ipsilateral femoral artery to push the thrombolytic agent through the capillary bed and into the small veins of the calf, and potentially improving clearance of thrombosis in those very small veins.

The equipment required in CDT includes:

- Ultrasound machine and sterile probe cover
- Local anaesthesia
- Micropuncture set
- 0.035in J-wire
- Vascular sheath (usually 6 Fr or larger to accommodate infusion catheters, stents and mechanical thrombectomy devices)
- 0.035in glidewire
- Angiographic catheters (according to clinician's preference such as Davis, Angled tapered, Bern)
- Infusion catheters
- Thombolytic agent
- Heparin
- IV Infusion sets

Once access is achieved, usually via ultrasound guided micropuncture (Cook Inc, Bloomington, IN) of the popliteal vein, a vascular sheath is inserted (6Fr or larger to allow

passage of an infusion catheter), and a diagnostic venogram performed either via the sheath or via a catheter. This may or may not be sufficient to visualise the extent of thrombosis. In either case, this is followed by a wire and angiographic catheter (usually 0.035in system, such as glidewire (Terumo, Somerset NJ) and a 5Fr angled tapered glidecatheter), which traverses the occluded segment. A venogram past the level of the occlusion is performed, usually in the IVC, to confirm intraluminal position, and absence of more centrally located clot.

The thrombolytic agent is usually injected at this point, and a number of different thrombolytic strategies have been described. At our institution, we would lase the length of the thrombosed segment using 200,000IU of Urokinase as the diagnostic catheter is being retracted. An infusion catheter with an infusion length that covers the occluded segment is then selected, and is inserted over a wire. The active infusion segment of the catheter is placed over the thrombosed segment of vein, which allows direct delivery of thrombolytic agent throughout the length of the thrombus. An infusion of Urokinase would then be commenced, at a rate of between 100,000-150,000 IU per hour. A Heparin infusion through the vascular sheath side arm is also commenced. The infusion is continued overnight, and patient nursed in a High Dependency Unit or Intensive Care Unit with one to one nursing. If the case arrives early in the morning, the infusion is left running until the mid afternoon. The patient will then return to the angiography suite for a venogram to reassess the degree of thrombosis and treat any underlying lesions.

If significant thrombus remains after the initial infusion, the infusion can be continued if it is felt that the clot will continue to disintegrate. However, this increases the dose and the duration of therapy with the associated increased risks of thrombolysis. It also increases the length of hospital stay and potentially increases the costs of treatment. Currently, CDT combined with mechanical thrombectomy is the preferred treatment (Sharaffudin 2003).

3.2 Mechanical thrombectomy

Mechanical thrombectomy devices disturb and break up the thrombus and allow rapid clearance of a large clot burden without the risks of pharmacological thrombolysis. They can be used alone, in situations where rapid debulking of thrombus is crucial, without the need for pharmacological therapy. However, adjunctive use of mechanical thrombectomy with thrombolysis is the preferred option. They can be used before, after or both before and after thrombolytic therapy.

The mechanism employed in the device can be divided into rotational devices and rheolytic devices.

Rotational devices include the Amplatz Thrombectomy Device (Microvena, White Bear Lake, MN), and Trerotola Percutaneous Thrombectomy Device (Arrow International, Reading, PA). These employ a high-velocity rotating helix or nitinol cage to macerate thrombus. The Trellis device (Trellis-8; Bacchus Vascular, Santa Clara, California, USA) employs a sinusoidal nitinol wire to disintegrate thrombus and with thrombolytic agent

between proximal and distal balloons for control and to prevent PE. Rotational devices have direct contact with the endothelium and subsequently have the potential for endothelial damage. However there have been no studies to analyse their efficacy compared with rheolytic devices.

Rheolytic devices include the Angiojet (Possis, Minneapolis, MN). The device uses high-pressure saline jets to fragment the thrombus. The jets also create a negative pressure zone which draws the fragmented thrombus toward the catheter where it is aspirated and removed. A possible advantage of the Angiojet device is that there is no contact of the maceration component of the device with the vessel wall. However, its use of high-pressure saline jets carries a theoretical risk of haemolysis and the release of adenosine and potassium. (Zhu, 2008) This has been linked to the incidence of bradyarrhythmia in cardiac applications of the device (Lee et al, 2005) or haemoglobinuria.

Ultrasound enhanced devices include the EKOS Endowave (EKOS Corporation, Bothell, WA, USA) and Omniwave (Omnisonics Medical Technologies, Wilmington, MA, USA). These are catheters that contain multiple ultrasound transducers, which radially emit high-frequency, low-energy ultrasound energy. The ultrasonic energy expands and thins the fibrin component of thrombus, exposing plasminogen receptor sites, and the ultrasound forces thrombolytic into the clot and keeps it there (Francis et al, 1995). This technique may be associated with fewer haemolytic effects than rheolytic thrombectomy (Lang et al, 2008) and has a lower potential for endothelial damage than rotational thrombectomy devices.

We prefer the use of the Angiojet system at our institution, as an adjunctive modality to CDT. The timing of its use is dependent on the case, and preference of the interventionist. However, the method is the same in either situation. The Angiojet catheters come in a range of sizes and lengths, we prefer the 5 and 6Fr systems. The device is passed several times across the thrombosed segment over a wire and under fluoroscopic visualisation. In order to minimise the risk of haemolysis, each pass is limited to 30 seconds with 10 second rests in between.

The potential added benefit of the Angiojet system is the ability of the catheters to 'pulse spray' thrombolytic agent using high pressure jets into the thrombus itself, improving delivery.

4. Results

4.1 Catheter directed thrombolysis

To date, the largest DVT thrombolytic database is the venous registry (Mewissen 1999), which is a prospective registry of patients with a DVT who underwent CDT with urokinase. 473 patients were enrolled with 287 patients followed up at 1 year. 83% of patients had thrombolysis >50%. There was also a strong relationship between early thrombus removal and 1- year patency (primary patency rate of 60%). Major bleeding complications occurred in 11%, most often at the puncture site. 1% of patients developed a PE. Two patients (<1%) died (one from PE and one from intracranial haemorrhage).

Grunwald and Hofmann (2004) retrospectively analysed 74 patients who underwent CDT for DVT and compared Urokinase, Alteplase and Reteplase. They found that there was no statistical difference between infusion times, success rates and complication rates between the three agents. However, they did find that the new recombinant agents are significantly less expensive than Urokinase in the United States.

No RCTs have been published looking at CDT in acute DVT. However, currently the TORPEDO trial is underway which is a large scale RCT looking at the efficacy of CDT vs anticoagulation in treatment of DVT. Mid term results show that CDT is superior to anticoagulation therapy alone in the prevention of recurrence of DVT, reduction in PTS, and reduction of hospital stays.

Similarly the ATTRACT Trial is currently underway looking at the efficacy of CDT.

4.2 Mechanical thrombectomy

No large randomised control studies have been published looking at mechanical thrombectomy in DVT.

An analysis by Karthikesalingam et al (2011) on 16 retrospective case series on the use of mechanical thrombectomy in DVT, with a total of 481 patients, looked at its efficacy. They found successful thrombolysis (>50% lysis) in 83-100% of patients. Bleeding complications requiring transfusion were seen in 7.5%. Symptomatic PE was seen in <1%. No procedure related deaths or strokes were seen. Of the studies that did look at mid term follow up, 75-98% of patients demonstrated significant improvement of symptoms and similar improvement in radiological findings.

5. Adjunctive procedures

DVT, particularly in the ilio caval system, can be associated with chronic venous obstruction, which can lead to valvular insufficiency and consequently venous hypertension. This in turn is associated with a higher incidence of post thrombotic syndrome (PTS). There are multiple other causes of venous obstruction, which include May Thurner syndrome, external compression (e.g. cancer, lymphocoeles) and retroperitoneal fibrosis. Very frequently, thrombolysis and thrombectomy can uncover the underlying lesion which precipitated the venous thrombosis. Failure to identify and treat these lesions, despite successful thrombolysis, can result in higher rates of recurrence, and the development of PTS.

The advantage of CDT as compared with anticoagulation therapy alone in the treatment of acute DVT, is that it allows the opportunity to treat the underlying lesion and restore flow in most cases. Obviously, non mechanical underlying issues must also be addressed, such as underlying prothrombotic syndromes.

The objective is to restore flow and the measures employed usually involve angioplasty and stenting of the lesion. Angioplasty and stenting in the setting of obstruction has been shown to improve quality of life and improve symptoms (Hartung et al 2005, Neglen P et al 2005, Raju S et al 2002;). The lesions treated usually lie within the IVC, iliac and femoral veins. It has not been shown that angioplasty and stenting of lesions below this

level is of any benefit. However, chronic lesions do benefit as well as acute obstructions (Titus 2011).

The procedure is similar to angioplasty of the arterial system. Once access is achieved, heparin is given if anticoagulation has not been already instituted. A wire is passed across the lesion, followed by a catheter. Any wire can be used however 0.035in wires are preferred. This is usually not too difficult in an acute thrombus, which is soft, and has not had time to organise. Contrast is injected beyond the lesion to ensure intraluminal position. The catheter is then exchanged for a balloon which is usually sized approximately 20% greater than the expected calibre of the vein. Angioplasty of the venous system is different from the arterial system, in that the balloons can be oversized to a greater extent than in the arteries. There is also a greater propensity for veins to have elastic recoil, such that even with aggressive angioplasty using high pressure balloons, the veins collapse back to their obstructed state. In other cases there is persistent stenosis in the vein post angioplasty. When this is the case, stenting is performed. These are also oversized in relation to the vein.

6. Use of IVC filters

The use of CDT and mechanical thrombectomy devices carry the theoretical increased risk of pulmonary embolisation. This has not been proven in any large scale study, and it is unclear based on current data whether this is true. In a review study by Grossman 1998, 2 out of 263 (0.7%) patients developed a PE post CDT. This is compared to the incidence of PE in patients treated with heparin alone for DVT ranging from 0-56% for symptomatic emboli, and 0-8% for asymptomatic emboli (Leizorovicz et al 1994, Sirgusa et al 1996, Levine et al 1995, Piccioli et al 1996).

In addition, no large studies are available that looks at whether IVC filters reduce the incidence of PE following CDT or mechanical thrombectomy. Given the lack of data on their use, prophylactic IVC filters prior to commencement of CDT and/or mechanical thrombectomy has been debated.

In a systematic review (Karthikesalingam et al 2011) of mechanical thrombectomy between 1999 and 2009, the use of prophylactic IVC filters was variable between the various authors. Almost all authors report 0% PE on follow up CTPA whether IVC filters were inserted or not. One author (Arko et al 2007) reports a 17% PE rate, all asymptomatic, in patients where no IVC filter was placed. In those that had a filter, Arko found no PE. All deaths were unrelated to the thrombectomy (either myocardial infarct or cancer) and no patients died of PE.

The role IVC filters therefore is not known and there are no current recommendations regarding their use. However they are not without risk, albeit small. Filter migration, filter fracture, break through PE have all been described, as well as complications associated with their retrieval.

Placement of IVC filters remain at the discretion of the interventionist. In the presence of free-floating IVC thrombus or in patients with limited cardiopulmonary reserve who are unlikely to tolerate minor embolic events, IVC filtration may be appropriate with use of permanent (Tarry WC Ann Vasc Surg 1994) or temporary filters (Lorch et al 2000).

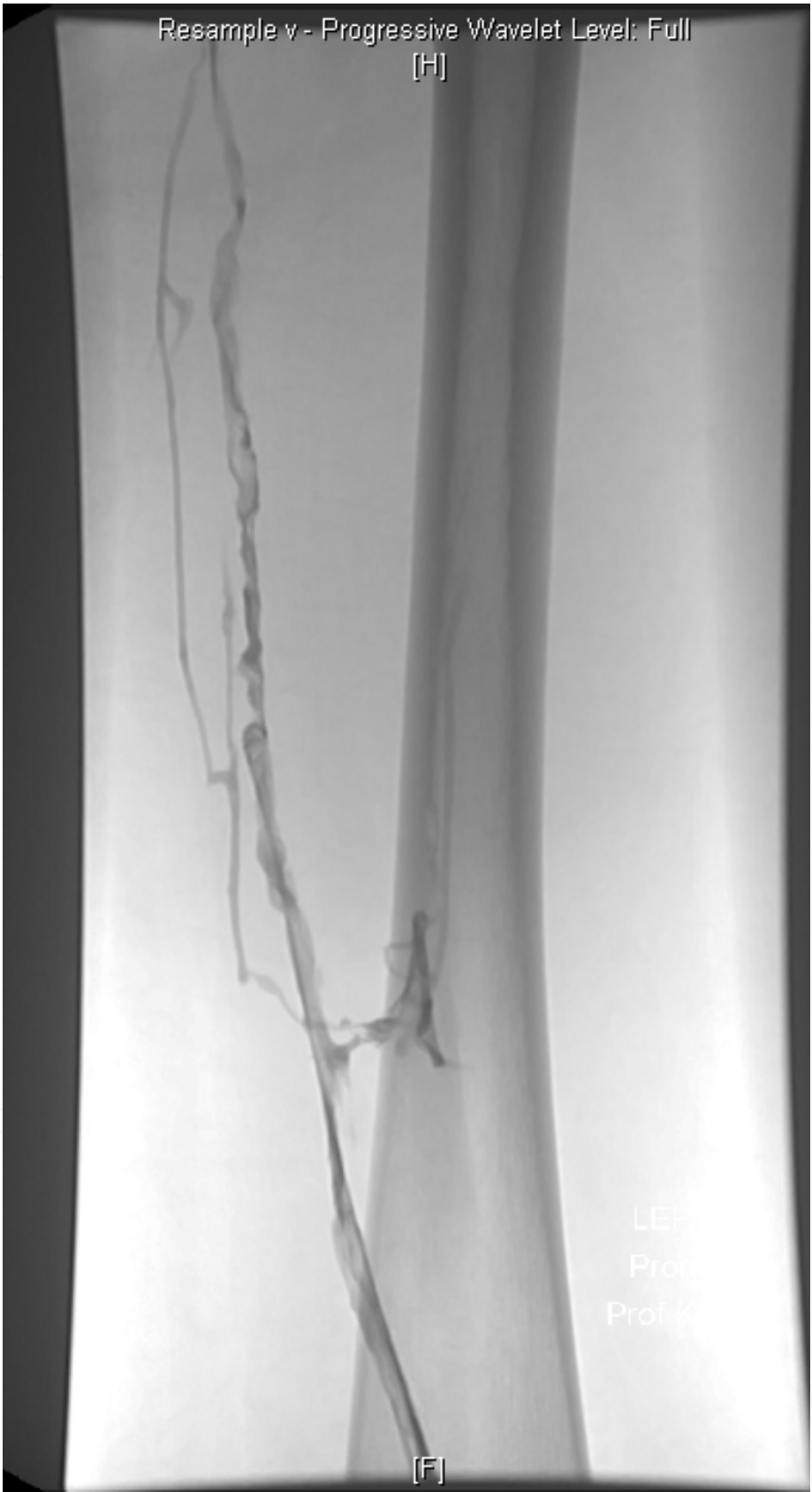

Fig. 1. 20 y.o. girl with acute DVT and swollen, dusky leg. Popliteal access has been achieved and venogram demonstrates thrombus in the femoral vein.

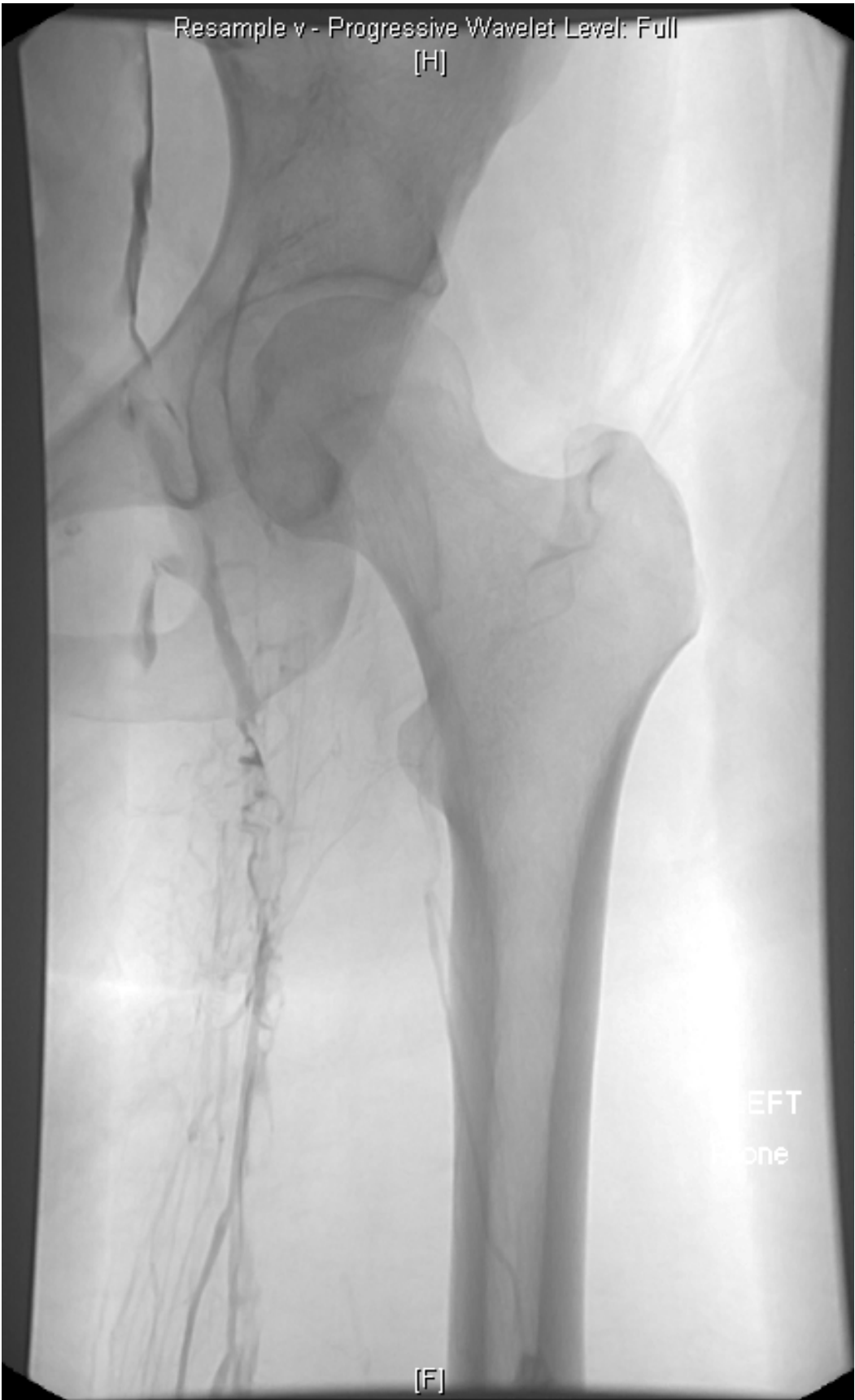

Fig. 2. Same patient. Thrombus extends into common femoral vein.

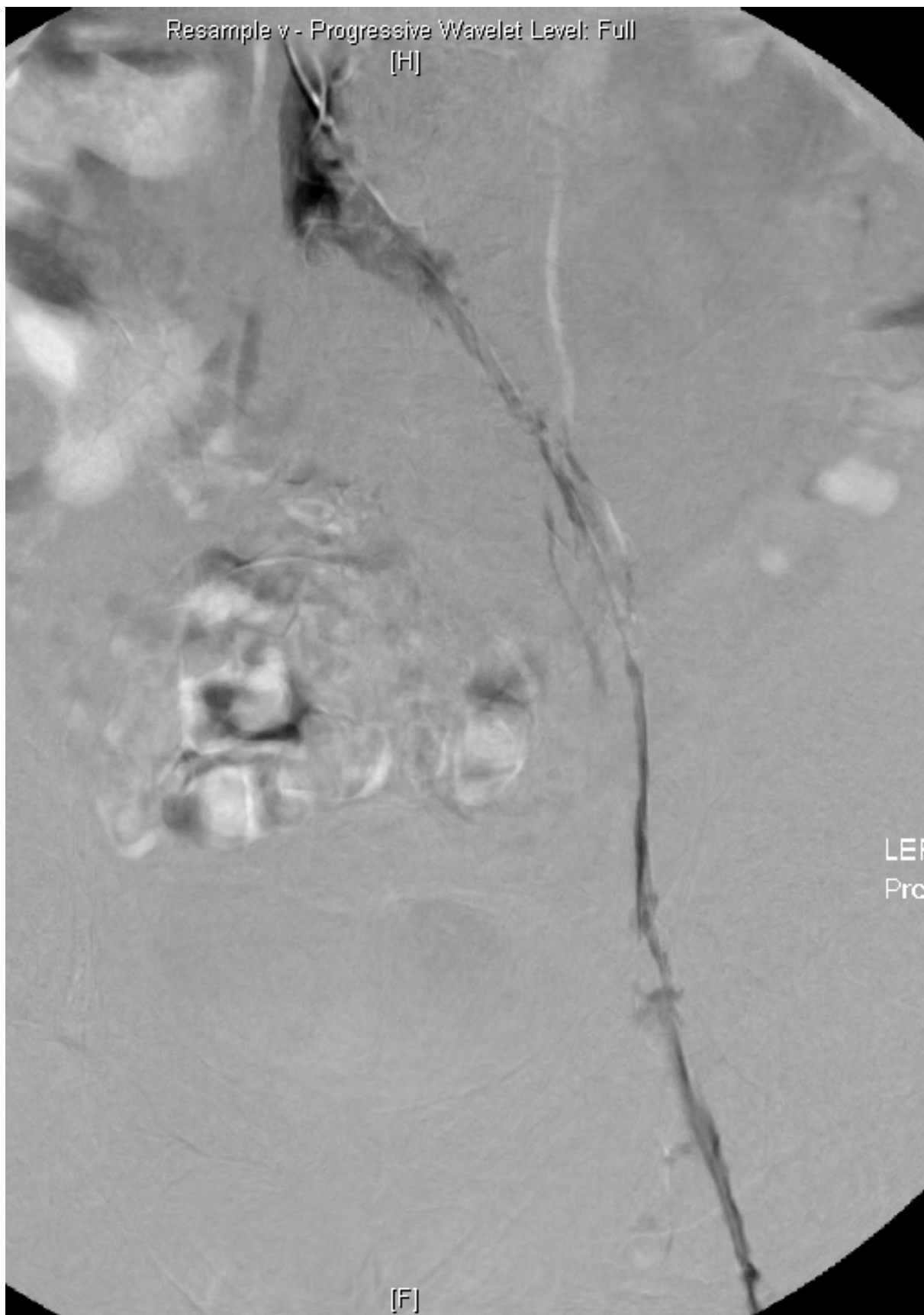


Fig. 3. Same patient. Thrombus extending into iliac veins.

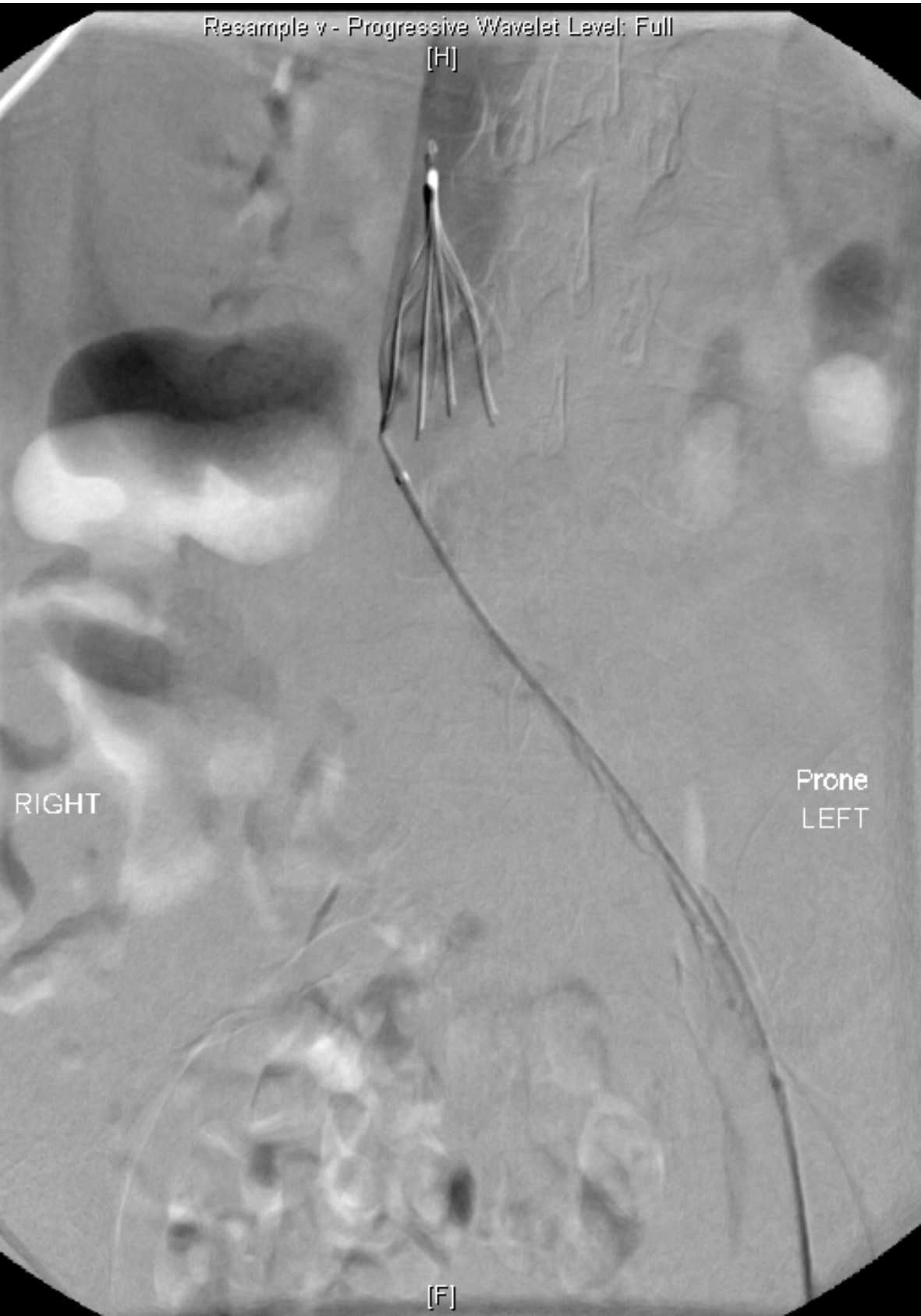


Fig. 4. Same patient. IVC filter placed prior to commencement of procedure. Infusion catheter placed through the thrombus and Urokinase infusion commenced.

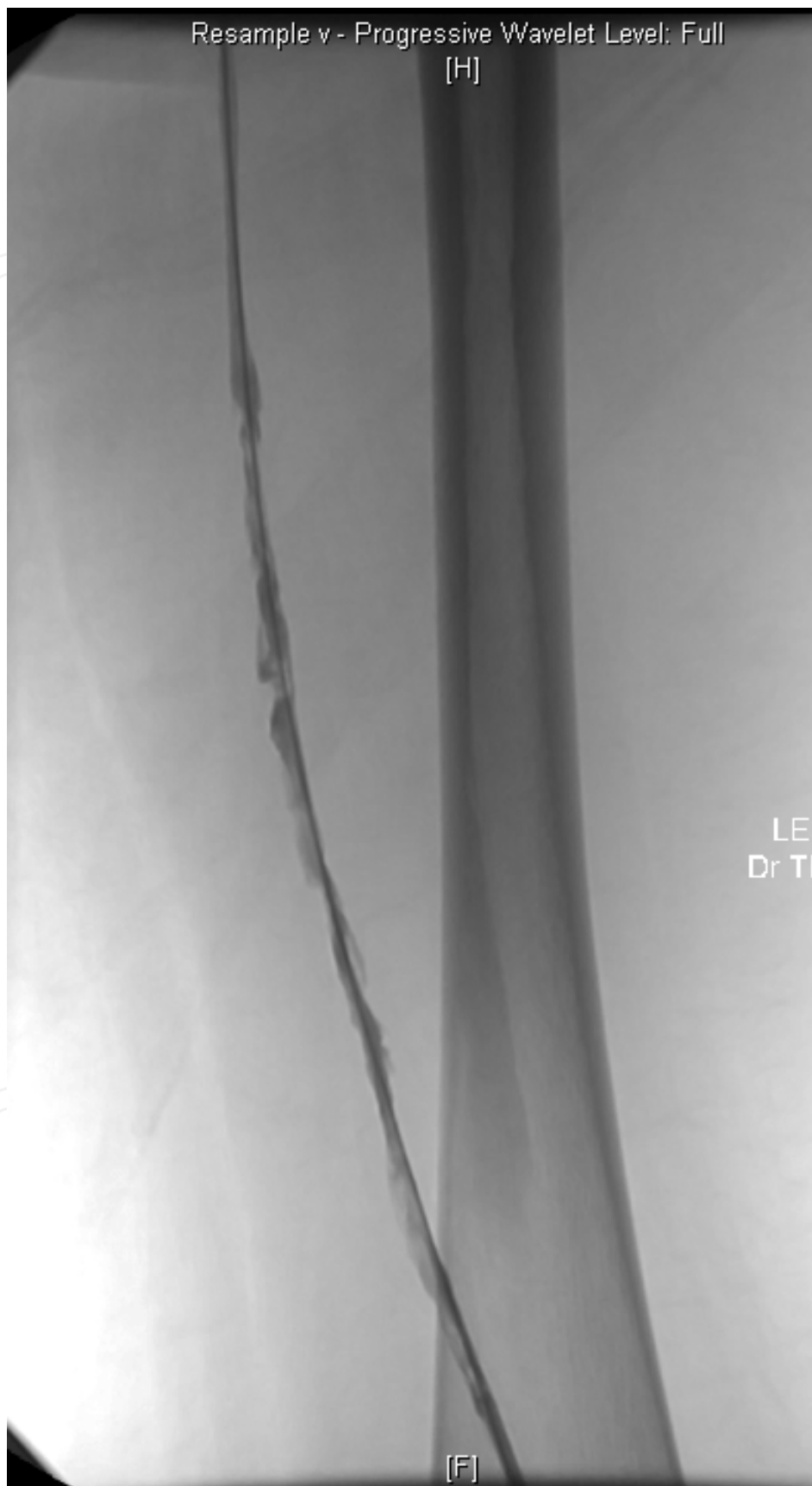


Fig. 5. Post 18 hours CDT. Thrombus still present in femoral vein.

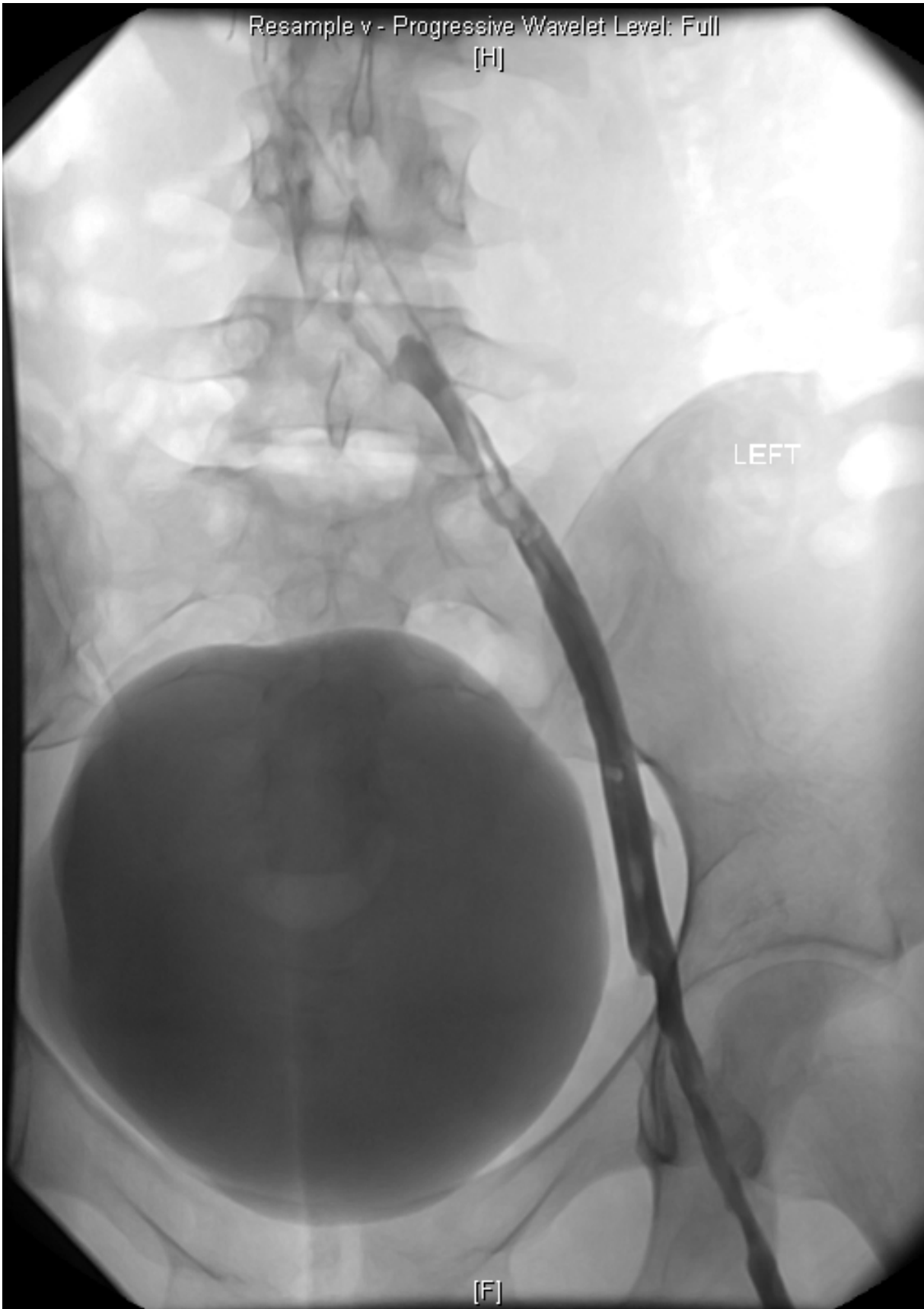

Fig. 6. Post 18 hours CDT. Persistent thrombus in iliac veins.

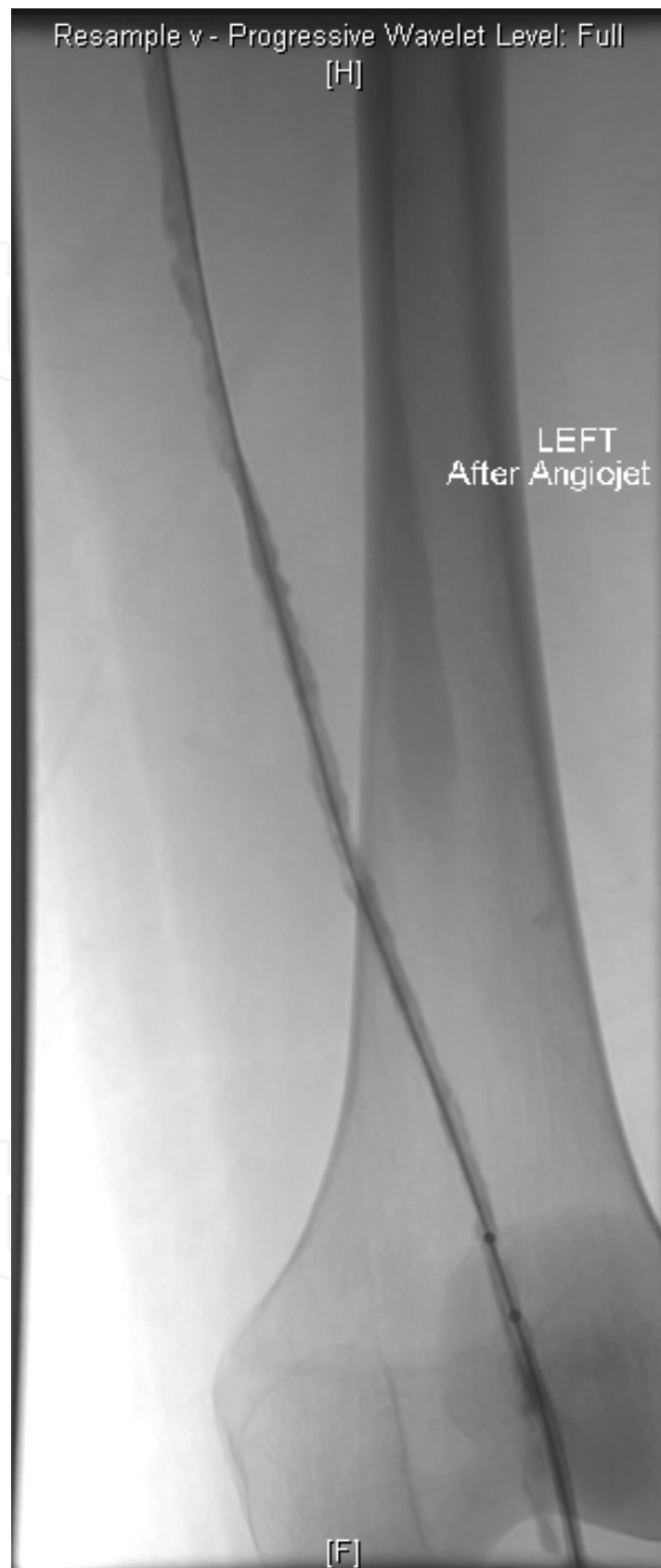


Fig. 7. Post mechanical thrombectomy with Angiojet system demonstrates clearance of thrombus.

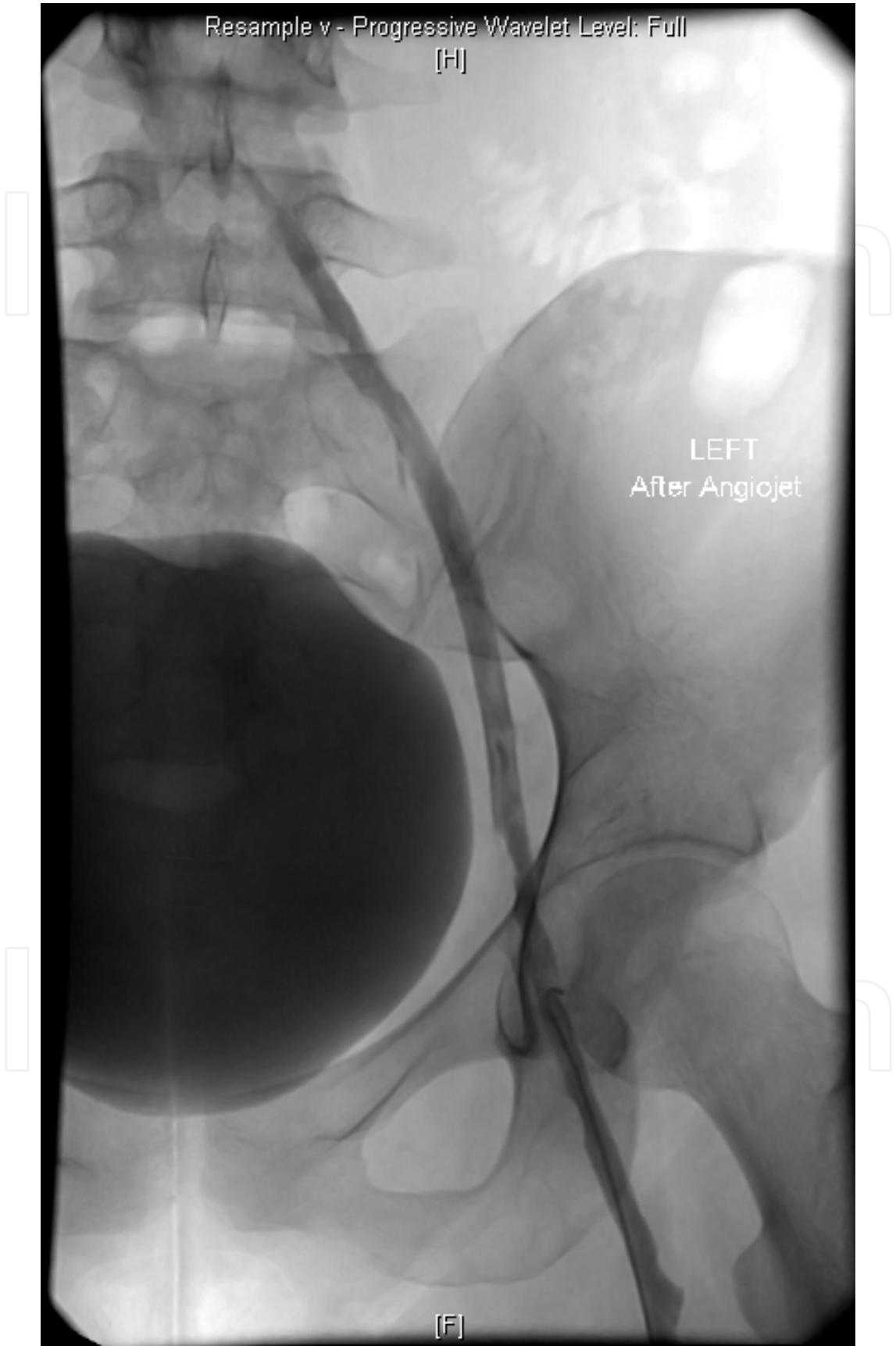

Fig. 8. Improvement of thrombus in iliac veins post Angiojet.

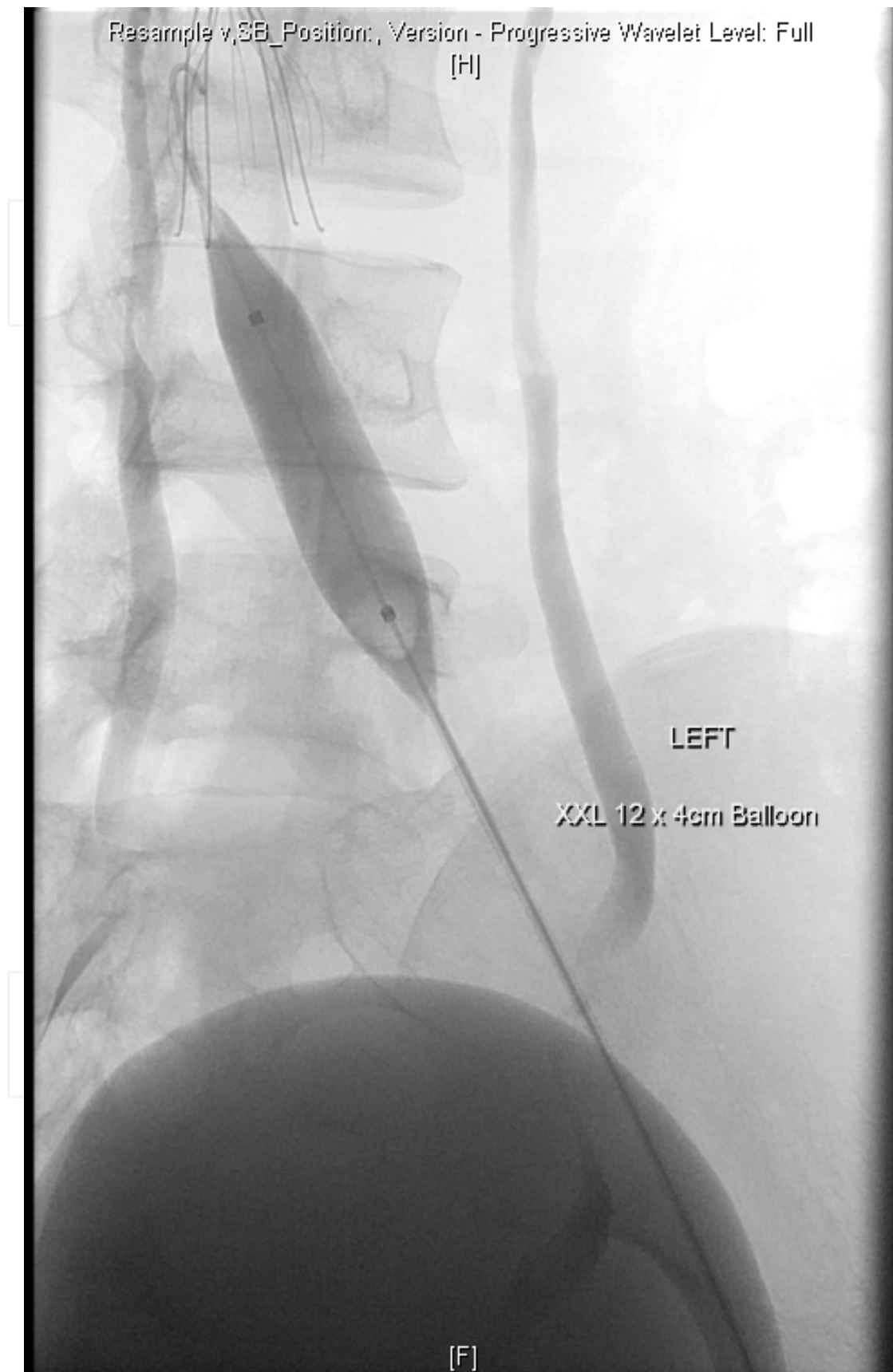


Fig. 9. Angioplasty of the common iliac vein

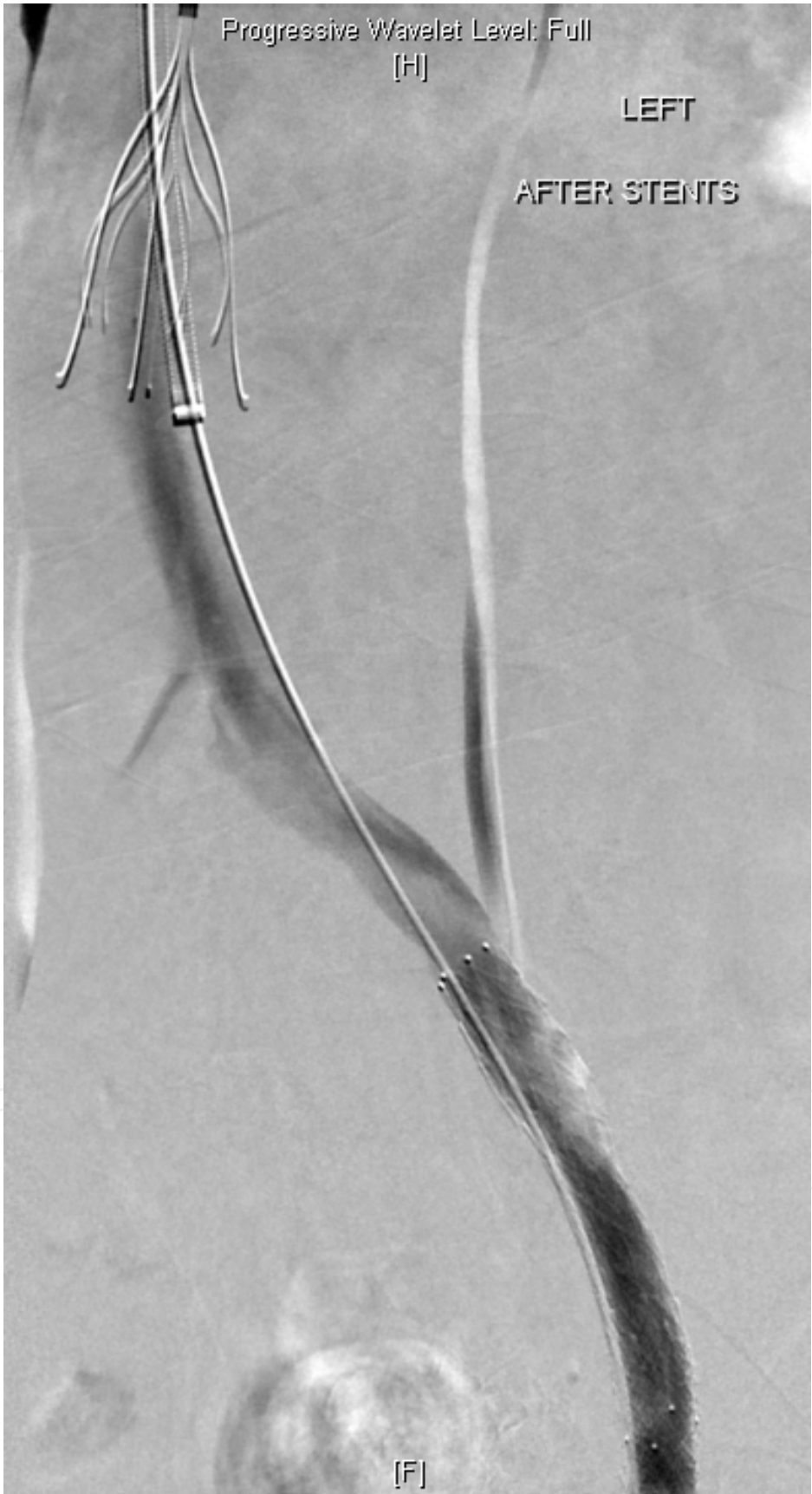

Fig. 10. Stent deployed in the left iliac vein with good flow through the vessel.

7. Conclusion

Endovascular techniques are important therapeutic options in the prevention of limb loss, recurrence and post thrombotic syndrome related to acute DVT, and have been shown to be superior to anticoagulation therapy alone. It also is advantageous in uncovering and treating underlying lesions that contribute to the DVT.

No guidelines are available currently in terms of patient selection, techniques and the use of IVC filters and at present these decisions are made on a case by case basis at the discretion of the interventionist. Large randomized controlled trials underway currently will hopefully be able to shed more insight on these issues.

8. References

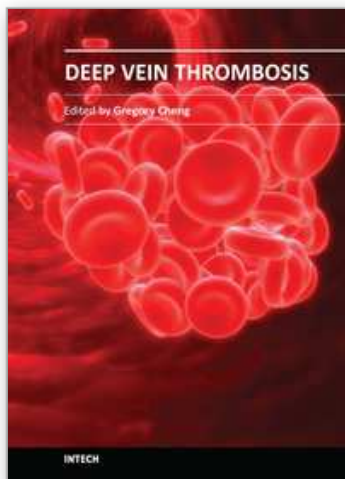
- Arko FR, Davis CM, Murphy EH, et al. 2007. Aggressive Percutaneous Mechanical Thrombectomy of Deep Venous Thrombosis. *Archives of Surgery*. 142 (6):513-519
- Comerota AJ & Aldridge SC. 1993. Thrombolytic therapy for deep venous thrombosis: a clinical review. *Can J Surg*. 36(4): 359-64.
- Francis CW, Blinc A, Lee S, Cox C. 1995. Ultrasound accelerates transport of recombinant tissue plasminogen activator into clots. *Ultrasound Med Biol*;21(3):419e24
- Gallus AS, 1998. Thrombolytic therapy for venous thrombosis and pulmonary embolism. *Clin Haematol*. 11(3):663-73.
- Grosman C & McPherson S. 1999. Safety and efficacy of catheter directed thrombolysis for iliofemoral venous thrombosis. *Am J Roentgenol*. 172: 667-672.
- Grunwald MR and Hofmann LV. 2004. Comparison of UK, Alteplase, and reteplase for CDT of DVT. *Journal Vasc Interv Radiol*; 15:347-352
- Hartung O, Otero A, Boufi M, et al. 2005. Mid term results of endovascular treatment of symptomatic chronic non-malignant ilio caval venous occlusive disease. *J Vasc Surg*. 42(6):1138-44.
- Karthikesalingam, EL Young, RJ Hinchliffe, et al. 2011. A systematic review of percutaneous Mechanical thrombectomy in the treatment of DVT. *Eur J Vasc endovasc Surgery*, 41: 554-565
- Lang EV, Kulis AM, Villani M, et al. 2008. Hemolysis comparison between the OmniSonics OmniWave endovascular system and the Possis AngioJet in a porcine model. *J Vasc Interv Radiol*;19(8):1215e21
- Lee MS, Makkar R, Singh V et al. 2005. Pre-procedural administration of aminophylline does not prevent AngioJet rheolytic thrombectomy-induced bradyarrhythmias. *J Invasive Cardiol*;17(1):19e22
- Leizorovicz A, Simonneau G, Decousus H et al. 1994. Comparison of efficacy and safety of low molecular weight heparins and unfractionated heparin in initial treatment of deep venous thrombosis: a meta analysis. *BMJ*. 309 (6950): 299-304.
- Lensing AW, Prins MH, Davidson BL, et al. 1995. Treatment of deep venous thrombosis with low-molecular-weight heparins: a meta-analysis. *Arch Intern Med*; 155:601-607.

- Lorch H, Welger D, Wagner V, et al. 2000. Current practice of temporary vena cava filter insertion: a multicenter registry. *J Vasc Interv Radiol*. 11(1): 83-8.
- Mewissen. 1999. CDT for lower extremity Deep venous thrombosis: report of a national multicenter registry, *Radiology*; 211:39-49
- Molina JE, Hunter DW & Yedlicka JW. Thrombolytic therapy for iliofemoral venous thrombosis. 1992. *Vasc Surg*. 26:630-637.
- Neglen P, Raju S. 2005. *Endovascular treatment of chronic occlusions of the iliac veins and the inferior vena cava*. Rutherford RB, editor. *Vascular Surgery*. 6th ed. Philadelphia: Elsevier Saunders;. pp 2321-32.
- Patel K, Basson MD, Borsa JJ, et al, May 2011. Deep Venous Thrombosis. In: *Emedicine*. Available from:
<http://emedicine.medscape.com/article/1911303-overview>
- Piccioli A, Prandoni P Goldhaber S. Epidemiologic characteristics, management and outcome of deep venous thrombosis in a tertiary-care hospital: The Brigham and Women's Hospital DVT registry. 1996. *American Heart Journal*. 132(5).
- Prandoni P, Lensing A, Cogo A, et al. 1996. The Long-Term clinical course of Acute Deep Venous Thrombosis. *Annals of Internal Medicine*. 125:1-7.
- Raju S, Fountain T & McPherson SH. 1998. Catheter directed thrombolysis for deep venous thrombosis. *J Miss State Med Assoc*. 39(3):81-4.
- Raju S, Owen S Jr, Neglen P. 2002. The clinical impact of iliac venous stents in the management of chronic venous insufficiency. *J Vasc Surg*; 35:8-15.
- Schweizer J, Kirch W, Koch R, et al. 1998. Short and long term results after thrombolytic treatment of deep venous thrombosis. *J Am Coll Cardiol*. 36:1336-1343.
- Sharafuddin MJ, Sun S, Hoballah JJ, et al. 2003. Endovascular management of venous thrombotic and occlusive diseases of the lower extremities. *J Vasc Interv Radiol*. 14(4):405-23.
- Sirgusa S, Cosmi B, Piovella F, et al. 1996. Low molecular weight heparins and unfractionated heparin in the treatment of patients with acute venous thromboembolism: results of a meta analysis. *The American Journal of Medicine*. 100(3): 269-277.
- Tarry WC, Makhoul RG, Tisnado J, et al. 1994. Catheter directed thrombolysis following ven cava filtration for severe deep venous thrombosis. *Ann Vasc Surg*. 8(6):583-590.
- Titus JM, Moise MA, Bena J, et al. 2011. Ilioifemoral stenting for venous occlusive disease. *J Vasc Surg*. 53(3): 706-712.
- Vedantham S, Millward S, Cardella J, et al. 2006. Society of Interventional Radiology Position Statement: Treatment of Acute Iliofemoral deep Vein Thrombosis with use of Adjunctive Catheter directed Intrathrombus Thrombolysis. *J Vasc Interv Radiol*. 17:613-616.
- Wells PS & Forster AJ. Thrombolysis in deep vein thrombosis: is there still an indication? 2001 *Thromb Haemost*. 86 (1):499-508.

Zhu DW. The potential mechanisms of bradyarrhythmias associated with AngioJet thrombectomy. 2008.*J Invasive Cardiol*; 20 (8 Suppl. A):2Ae4A

IntechOpen

IntechOpen



Deep Vein Thrombosis

Edited by Dr. Gregory Cheng

ISBN 978-953-51-0225-0

Hard cover, 184 pages

Publisher InTech

Published online 07, March, 2012

Published in print edition March, 2012

This book provides a comprehensive review of deep vein thrombosis. There are chapters on risk factors for DVT, post thrombotic syndrome and its management, vena cava malformation as a new etiological factor and thrombosis in the upper limbs. DVT is usually seen in patients undergoing major surgeries. The guidelines for thrombo-prophylaxis in orthopaedic patients, radical pelvic surgeries, laparoscopic operations and risks versus benefits in regions with a low prevalence of DVT are thoroughly addressed. Cancer and its treatment are recognized risk factors for VTE and extended prophylaxis in ambulatory cancer patients is reviewed. The role of imaging and endovascular therapies in acute DVT, hypercoagulability in liver diseases and the challenges in developing countries are discussed.

How to reference

In order to correctly reference this scholarly work, feel free to copy and paste the following:

Jeff Tam and Jim Koukounaras (2012). Endovascular Therapies in Acute DVT, Deep Vein Thrombosis, Dr. Gregory Cheng (Ed.), ISBN: 978-953-51-0225-0, InTech, Available from:
<http://www.intechopen.com/books/deep-vein-thrombosis/interventions-in-acute-deep-vein-thrombosis>

INTECH
open science | open minds

InTech Europe

University Campus STeP Ri
Slavka Krautzeka 83/A
51000 Rijeka, Croatia
Phone: +385 (51) 770 447
Fax: +385 (51) 686 166
www.intechopen.com

InTech China

Unit 405, Office Block, Hotel Equatorial Shanghai
No.65, Yan An Road (West), Shanghai, 200040, China
中国上海市延安西路65号上海国际贵都大饭店办公楼405单元
Phone: +86-21-62489820
Fax: +86-21-62489821

© 2012 The Author(s). Licensee IntechOpen. This is an open access article distributed under the terms of the [Creative Commons Attribution 3.0 License](https://creativecommons.org/licenses/by/3.0/), which permits unrestricted use, distribution, and reproduction in any medium, provided the original work is properly cited.

IntechOpen

IntechOpen