

We are IntechOpen, the world's leading publisher of Open Access books Built by scientists, for scientists

6,900

Open access books available

185,000

International authors and editors

200M

Downloads

Our authors are among the

154

Countries delivered to

TOP 1%

most cited scientists

12.2%

Contributors from top 500 universities



WEB OF SCIENCE™

Selection of our books indexed in the Book Citation Index
in Web of Science™ Core Collection (BKCI)

Interested in publishing with us?
Contact book.department@intechopen.com

Numbers displayed above are based on latest data collected.
For more information visit www.intechopen.com



The Plica: Is a New Aetiological Factor in the Knee Osteoarthritis?

Ahmet Guney* and Ibrahim Kafadar

From the Department of Orthopaedics, Erciyes University Medical Faculty, Kayseri, Turkey

1. Introduction

Osteoarthritis is one of the most important diseases in the field of orthopedics worldwide. The disease is characterized by progressive loss of articular cartilage and formation of osteophytes, which lead to chronic pain and functional restrictions in the affected joints.

Different factors can be involved in the development of osteoarthritis including traumatic events, genetic predisposition, defective position of joints, and ageing and malnutrition.

The plica is the generic name of the ruins or folds of the synovial membrane in the knee joint. The incidence of the plicas in the knee joint is between 18,5-87 %. These plicas are named and classified according to their settlements in the knee joint (1-6).

The plicas sometimes come to a pathologic state, which gains clinical importance and causes the plica syndrome (7). When plica is symptomatic, the condition is called plica syndrome. The plicas are considered to be one of the potential causes of the complaints around the knee joint (8).

It is known that medial plica causes to degeneration of cartilage around the medial femoral condyle of the knee joint and / or the medial pole of the patella (2,8-14). Owing to the anatomic location of the medial plica, a loss of normal elasticity can cause it to impinge on the femoral medial condyle or the medial facet of the patella during flexion-extension motion of the knee. This kind of repetitive contact may result in a chondral lesion of varying severity, sometimes referred to as an impingement lesion (2,7,8,14-18).

It has also been suggested that normal-looking medial plica, not impinging on the articular surfaces, could be symptomatic as well. This is supported by recent findings which have demonstrated an increase in the amount of nerve endings in the plica after trauma or overuse, indicating increased pain sensitivity and sensation of pain (19,20).

The anatomy of the plicas or synovial folds was first described by Mayeda in 1918. In 1939, Lino first described the appearance of arthroscopic synovial folds in the cadaveric knees. In 1950 and 1971, Pipkin reported that the plicas should be distinguished from adhesions in the knee joint and those might cause clinical symptoms (21,22).

*Corresponding author

2. Embryology

The knee embryologically develops from mesoderm in several development stages. At the first weeks of the fetal development, the mesenchymal originated intra-articular knee joint membrane separates the knee joint into three compartments, the medial and lateral tibiofemoral compartment, and the suprapatellar bursa. This membrane is usually resorbed between the weeks of 9.5 and 12. Later on, these compartments coalesce to form a single large cavity. However, if this membrane is not completely resorbed, membranous structure forms in different locations in the knee joint. These membranous structures, when persist as normal folds of synovial membrane in the knee joint, are termed as plica (10,22,23).

3. Anatomy, classification and incidence

Generally plicas have been classified into three predominant types based on their anatomical location; the infrapatellar plica or ligamentum mucosum, the suprapatellar plica and the medial patellar plica or the medial shelf. Lateral plica have also been described but are considered a much more rare entity. These can vary in morphology and can exist in combinations. Arthroscope is a boon in visualizing intra-articular anatomy and pathology, and it also allows precise assessment and dynamic examination of the plica (24).

3.1 Suprapatellar plica

This type of plica takes origin from the inferior face of tendon of quadriceps and lies transversely in the suprapatellar pouch and attaches to the superomedial and lateral walls of the knee joint. Different anatomical variations of the suprapatellar plica have been described. According to Kim and colleagues there are different types, such as; absence of plica, vestigial shaped, medially cited, laterally cited, arch shaped, hole shaped and total septum. The most seen type of this group is medial suprapatellar plica (1,2).

Most arthroscopic studies have reported an incidence of some form of plica between 70% and 91%. Dandy in a study of 500 knees attempted to classify the suprapatellar plica arthroscopically. He described 10 variations with an overall incidence of 91% (1,2,4).

3.2 Mediopatellar plica

The medial plica has been given many names as it may reflect many variations of size, configurations, and attachments: Plica synovialis mediopatellaris, mediopatellar plica, medial shelf, Lino's band, Aoki's ledge, plica alaris elongata, medial intra-articular band meniscus of patella (2,8,12).

It originates on the medial wall of the knee joint and may or may not cross the suprapatellar plica passing obliquely, from the medial side of patella through to the distal, downward in the coronal plane to insert into the synovium surrounding the infrapatellar fat pad (1,2,7).

Lino first described four types of plica in 1939. And then Sakibara arranged these four types such as; Type A is a cord like structure in the synovial wall that can be traced to the fat

pad. Type B has a shelf like appearance but does not cover the femoral condyle. Type C has a large shelf like structure and can be seen to cover the anterior surface of the medial femoral condyle. Type D is a variation in which two insertions into the medial wall can be seen. There is a defect of plica that covers the whole medial femoral condyle (16).

Dandy reported difficulty in creating a classification to describe the medial patella plica and settled for a classification based upon the maximum width and position along with the incidence of each.

Dandy classification: type A, absence of any medial plica; type B, a narrow ridge at the medial wall of the knee joint; type C, width of the plica < 1 cm; type D, width of the plica 1–2 cm; type E, width of the plica >2 cm; type F, presence of a defect within the plica; type G, plica is high type but not contacting the medial femoral condyle; and type H, the plica is reduplicated (4).

There are large variations in the reported incidence of medial plica ranging from 17 to 75%.

The incidence of the medial patella plica is difficult to define as different interpretations of its presence have been used with some authors considering a small fold of synovium as a plica and others indicating this as absent. The more recent arthroscopic studies where a fold of tissue was considered a plica give an overall incidence of 92% and 72% (1,4,25).

The medial plica is considered the most problematic by many authors (Muse et al, 1985; Patel, 1986; Kim and Choe, 1996; Dupont, 1997) due to its close proximity to the medial border of the patella and medial femoral condyle where it can be 'impinged' (1,2,24,26).

3.3 Infrapatellar plica

The infrapatellar plica is more commonly known as the ligamentum mucosum. It originates from the intercondylar notch, spreads parallel to the anterior cruciate ligament and inserts into the synovium around the infrapatellar fat pad.

The infrapatellar plica is a common finding at knee arthroscopy with Kim and Choe reporting an overall incidence of 86%. Kim et al. have been the first to describe an arthroscopic classification of the infrapatellar plica and used its relation to the ACL and morphology to classify it (1,25,27).

According to this classification;

Absent: no synovial fold between the condyles of the femur.

Separated: A complete synovial fold that was separate from the anterior cruciate ligament (ACL).

Split : Synovial fold that is separate from the ACL but is also divided into two or more cords.

Vertical septum: A complete synovial fold that is attached to the ACL and divided the joint into medial and lateral compartments.

Fenestra: A vertical septum pattern that contains a hole or defect.

3.4 Lateral plica

The lateral plica is considered to be rare. Overall incidence was found 1,3% by Kim and colleagues. It originates from the lateral wall of the knee above the popliteal hiatus and inserts into the synovium around the infrapatellar fat pad (1,2).

4. Pathophysiology

Normally plica exists as thin flexible soft tissue structures, mainly composed of elastic and areolar tissue. Due to this property, it changes its shape and length with knee movements (7). Inflammation of the synovial tissue makes plica edematous and thickened, and in chronic cases, it loses its inherent elastic nature and becomes thick and fibrosed. And even

it hyalinize and rarely becomes calcified. Then plica can cause secondary mechanical synovitis around the femoral condyles. Mediopatellar plica is trapped between the anteromedial portion of the medial femoral condyle and the medial pole of the patella with flexion of the knee. This pathologic thickness of plica causes articular cartilage degeneration the anteromedial portion of the medial femoral condyle and the medial pole of the patella by the continuity of knee movements (2,9,28-32).

Plica become pathological when thickening and fibrosis occurs giving rise to relative inelasticity that can lead to it snapping over the femoral condyle causing synovitis, chondral damage and pain. The plica syndrome was described by Hardaker and defined as a painful impairment of knee function in which the only finding was the presence of a thickened, hypertrophic plica (7).

Generally, direct injury to the knee leading to synovial hematoma and post-traumatic transient synovitis is one of the commonest factors coupled with the development of pathological medial plica (24). In some cases, repetitive and overuse of knee as per task-specific demands or athletic activities associated with minor irregularities of knee mechanics cause progressive inflammation with recurrent synovitis, edema, thickening, and fibrosis of plica (33).

It can also get involved in any primary disorder of knee capable of producing synovitis such as torn meniscus, loose bodies, and osteochondritis dissecans. Many authors accept that wider plicas are more often symptomatic and more frequently demonstrate pathologic changes at histological analysis than thinner plica (34). Normally, medial plica slides smoothly over medial femoral condyle in flexion and extension, and it remains in contact with the condyle during whole range of motion. Thus, pathological plica, with movement of knee may generate some shearing force acting on the condyle, has a role in the pathogenesis of degeneration of the cartilage on the medial femoral condyle (35).

Being in close proximity to medial femoral condyle, plica may provoke secondary mechanical synovitis about the margins of condyle. The fibrotic plica can bowstring across the trochlea and condyle or can get impinged between the patella and medial femoral condyle, altering the patello-femoral mechanics (32,36).

However, this aberrant mechanics is directly related to degeneration of articular cartilage of patello-femoral joint. And there are high incidences of chondromalacia reported in pathological medial plica involving medial femoral condyle and medial patellar facet (37,38).

The severity of the degeneration was positively correlated with the severity of the medial plica and patients' age (15).

In the arthroscopy study of Christoforakis and Strachan on 1,000 patients, a total of 319 mediopatellar plicas were identified, and cartilage degeneration was found at medial femoral condyle and/or medial pole of patella in 24.7% of these cases (13).

In that study, isolated patellofemoral cartilage degeneration was present in 15.5% of knees not having mediopatellar plica. Authors concluded that mediopatellar plica leads to patellofemoral joint degeneration.

In another study, cartilage degeneration was found in higher degrees patients at medial femoral condyle and medial pole of patella. Significant clinical and functional improvements were observed early after plica excision in patients with mediopatellar plica and associated cartilage degeneration. Pain score, physical function score, total score and the mean score of WOMAC were all decreased at 6 weeks compared to baseline (39).

Excessive exercises, sports activities and the chronic hyperflexion of the knee due to life style can cause the plica syndrome.

Even if plica does not touch the bone structures, it may disrupt the function of quadriceps tendon due to its tension and may cause pain by applying traction to the synovium and fat pad.

The function of plica has not been fully understood. However, plicas have neural elements according to some studies.

Quadriceps atrophy can occur in up to 45% of patients with a pathological plica. This concurs with the current view that atrophy is caused by chondromalacia and develops soon after the plica irritation (6,7).

In the case of medial plica trauma, biomechanical factors may cause it to enlarge, resulting in impingement between the medial border of the trochlea's medial facet and the medial facet of the patella. Impingement occurs during flexion of the knee between 40° and 80° when the gap between the patella and femoral joint is at its closest. Continued impingement of the plica with repeated flexion may cause chondromalacia, groove formation within the articular cartilage and a thickening of the plica. This is associated with a clicking or loud snapping sound on flexion/extension of the knee (2,26,40).

5. Clinical signs and symptoms

The most frequent complaint is pain (8). Most common presentation of medial plica syndrome is anteromedial knee pain. The pain is usually in front of the knee but it may also be on the the antero-medial and anterior-lateral, medial and lateral joint space. The pain is usually intermittent, and occurs with activity. Pain is significant while climbing stairs like other patellofemoral problems (10).

The cinema sign is positive. The increase of the pain when the knee is flexed for a long time, and then a relief by extension of the knee is described as positive cinema sign.

A pathological plica produces popping or catching in knee by snapping across patella or medial femoral condyle. Other symptoms associated with anteromedial pain include swelling of knee, feeling of tightness, and stiffness (7,24,36,37).

Sometimes pain and clicking of previously asymptomatic medial plica starts as a result of tear, due to rubbing of torn portion of plica over medial femoral condyle. Thus, one cause of anterior knee pain can be tear of plica along with thickening and fibrotic changes. A very rare presentation, hemarthrosis, caused by large medial plica has also been reported (41,42).

In physical examination when the knee is in extension posture, pain with the palpation of the medial lower pole of patella is specific. Sensitivity can be found in the medial joint space when the knee is in flexion.

Examination remains unreliable in most patients but common findings are quadriceps wasting, effusion, medial condyle tenderness, crepitus and decreased range of motion (26,37).

Provocative tests for meniscal tears are often positive but have poor specificity. Signs for patellofemoral pathology are also often positive but again offer poor specificity (8). It is occasionally possible to palpate the thickened plica as a tight band mostly superomedially which will be tender to palpate and can be felt to click or catch with movement (43).

A number of provocative tests for pathological plica have been described.

Plica can be rolled over medial femoral condyle as it is thickened and fibrosed. A palpable or sometimes audible snap is present when knee passes from 30° to 60° of flexion (7,24).

Pipkin has described the pop that occurs, as the knee is extended from 90° of flexion with foot internally rotated and the patella pressed medially, between 60° and 45° of flexion of knee (22).

Two provocative tests described by Koshino and Okamoto are helpful in diagnosing pathological medial plica. Rotation valgus test is elicited by flexing the knee and applying a valgus force on internally and externally rotating the tibia while simultaneously attempting to displace the patella medially. The other one is holding test, done by attempting to flex the knee against active resistance. If either test elicits pain, with or without a click, it is considered positive (32,44).

Kim et al. named his the medial patella plica test or MPP test (45). It is performed by applying a manual force to the infero-medial portion of the patellofemoral joint. Whilst maintaining the force the knee is flexed to 90 degrees. A positive test occurs when the patient experiences pain in extension but this is eliminated at 90 degrees of flexion.

Other provocative tests have previously been described by Pipkin, but this test relied upon no effusion being present and was often found to be negative later in the day, it therefore became dubbed the 'morning test' (22).

Shetty et al. in their prospective study over 66 knees, devised a system to diagnose symptomatic medial plica based on history and clinical examination. It includes five essential and four desirable criteria. Essential criteria are as follows: [1]. history of anteromedial knee pain, [2]. Pain primarily over medial femoral condyle, [3]. visible or palpable plica, [4]. tenderness over palpable plica, [5]. Exclusion of other causes of anteromedial knee pain. Desirable criteria are as follows: [1] onset blunt or trivial trauma, [2] Duvet test (use of a duvet placed between knees to prevent pain while sleeping, [3] audible snap during active range of motion, and [4] palpable snap during flexion. This system has diagnostic accuracy of 91.7%, sensitivity of 100%, and positive predictive value of 91.7% (32,38).

Diagnosis with routine blood tests may often be unhelpful as inflammatory markers almost invariably are normal. Radiographs of the knee do not demonstrate a plica but help to exclude other pathology. Double contrast arthrograms have historically been used and are able to demonstrate plica reliably but are unable to distinguish between pathological and non-pathological plica. It had been hoped that the advent of MRI would be useful in aiding the diagnosis of a pathological plica. Although it has been able to demonstrate plica reliably, it has not been able to predict the necessity of excision of that plica at arthroscopy, which limits its use as a screening tool (46-51).

Arthroscopy is still the gold standard modality to diagnose pathological medial plica.

Definitive diagnosis can only be made by arthroscopy, and it allows precise assessment of plica including dynamic examination. The normal plica is thin, pink, and pliable, whereas pathological plica is white, thickened, and fibrotic (7,32).

6. Treatment

6.1 Conservative treatment

In all cases, conservative treatment should be tried first (2,7-9). Rest and nonsteroidal anti-inflammatory drugs are used to resolve the pain and, after the removal of acute painful period rehabilitation program starts. Physical therapy is given in the form of local heat, ultrasound, short-wave diathermy, along with quadriceps and hamstring stretching exercises.

The basis of rehabilitation program includes quadriceps and hamstring strengthening and stretching exercises (3,28).

Objective of physiotherapy is to increase the structural flexibility of tissues and decrease compressive forces on the knee.

The response taken from the case determines the duration of the conservative treatment. Even if the improvement is visible partially with the treatment for two or three months, conservative treatment should be continued. If there is no reduction in pain, surgical treatment should be started. With the increase of pain in patients, early surgical treatment could be planned (3).

In addition injection of local anesthetic and corticosteroid can be given into the plica and surrounding synovial tissues. Rovere et al. reported overall success rate of 73% and poor results were obtained in chronic fibrotic plica (52).

Patients who do not respond to conservative therapy or have recurrence of symptoms are essentially the candidates for arthroscopic examination of knee joint.

6.2 Surgical treatment

The medial patella plica is most commonly associated with symptoms and is frequently considered to be pathological. There are very few reports in the literature of the infrapatellar plica being pathological. On the other hand, the suprapatellar plica has been implicated more commonly in pathology. Kyung Bae reported a series of 30 complete type suprapatellar plicae with 90% of the patients reporting good or excellent results following arthroscopic excision (53).

Patients who do not respond to conservative treatment, surgical treatment is applied. If a plica causes friction on medial femoral condyle or pinches between the patella and medial femoral condyle, it should be excised. But arthrotomy should not be done for excision.

According to Patel's surgical indications are as follows;

1. Palpation of clinically painful and sensitive band
2. Determination of thickened and subluxated mediopatellar plica existence with or without cartilage lesions at patella or femur
3. If arthroscopy is performed under local anesthesia, stretching plica with a hook causes complaints of patient
4. Without the determination of other pathologies clinically and arthroscopically (2,3).

For arthroscopic surgery, usually standard portals like antero-medial, antero-lateral are used. Brief et al. described superolateral approach as a better arthroscopic portal for medial plica, and it offers a sweeping, unobstructed view of entire plica, and also good visualization of patello-femoral joint (7,54).

Visualisation of all the compartments of the knee and probing of the menisci should also be performed to ensure no other pathological cause of pain is present within the knee.

Accessory portals can be created to allow better visualisation of the patellofemoral and suprapatellar compartments. If any other pathology is found, it needs to be treated appropriately (32).

Arthroscopic excision of medial plica is carried out as a day procedure. Complete resection of pathological plica to the capsular attachment is advisable. Many studies reported good to excellent results with this procedure (8,24,36-38). However, extensive excision of medial plica can lead to patellar subluxation (55,56).

During the medial plica surgery, knee should be in full extension. Mild flexion of the knee complicates the surgery.

The amount of excision is controversial. The main operations in the literature are; the division of the plica just as band, total excision and segmental resection. The division of the

plica may cause recurrences. The radical resection may lead to formation of tense fibrotic tissue through the capsule and subcutaneous fat tissue. A thin peripheric edge is left in the procedure of subtotal resection. In this way capsule and synovium is not traumatised and because of this formation of fibrous tissue is not seen. As described by Dandy, segmental resection may be insufficient for large and hard plicas (4,9,28,29,36,37).

The normal or asymptomatic plicas should not be excised which are detected incidentally.

Some researchers suggest the excision of plicas to prevent the complaints in the future except thin and distant plicas from bony structures.

Plicas have copious blood supply around the synovial attachments, and thus it is necessary to achieve hemostasis to prevent complications of intra-articular bleed post-operatively (10,54).

Post-operatively, compression bandage is applied over the joint. Mobilization is started on same day with the help of physical therapist, and early knee physiotherapy is encouraged to prevent stiffness and scarring of plica (7,10,55).

Plicas around the knee are common findings at arthroscopy but are rarely pathological. The plica syndrome is a cause of anterior knee pain and can be debilitating for patients. Inflammation and synovitis causes fibrosis and thickening of the plica. And then plica starts to behave like a bowstring causing to impingement and cartilage damage.

If a thickened and hypertrophic pathological plica is found at arthroscopy and completely excised good results from the artroscopical excision can be expected in the majority of the patients.

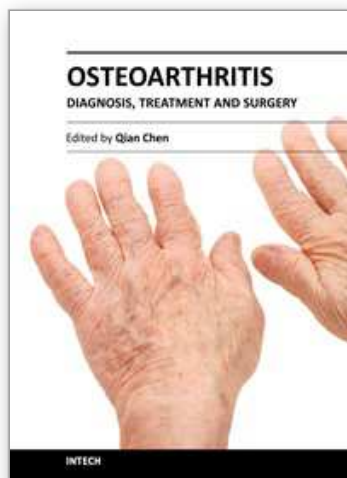
Surgical excision of mediopatellar plica associated with cartilage degeneration appears to result in substantial clinical improvement, thus representing an effective treatment modality for this group of patients.

7. References

- [1] Kim SJ, Choe WS. Arthroscopic findings of the synovial plicae of the knee. *Arthroscopy* 1997;13:33-41.
- [2] Patel D. Plica as a cause of anterior knee pain. *Orthop Clin North Am*. 1986;17 :273-7
- [3] Pinar H. Plica Syndrome a case of anterior knee pain. *Acta Orthop Traumatol Turc* 1988;22:268
- [4] Dandy DJ. Anatomy of the medial suprapatellar plica and medial synovial shelf. *Arthroscopy*. 1990;6:79-85.
- [5] Alturfan A, Pinar H, Taşer Ö. Mediopatellar plika sendromunun tanı ve tedavisinde artroskopinin önemi. *Acta Orthop Traumatol Turc* 1991;25: 294
- [6] Ammatuzzi MM, Fazzi A, Varella MH. Pathologic synovial plica of the knee. Results of conservative treatment. *Am J Sports Med* 1990; 18:466-9
- [7] Hardaker WT, Whipple TL, Bassett FH III. Diagnosis and treatment of the plica syndrome of the knee. *J Bone Joint Surg* 1980; 62:221-5
- [8] Tindel NL, Nisonson B. The plica syndrome. *Orthop Clin North Am* 1992;23:613
- [9] Munzinger U, Ruckstuhl J, Scherrer H, Gschwend N. Internal derangement of the knee joint due to pathologic synovial folds: the mediopatellar plica syndrome. *Clin Orthop Relat Res* 1981;155:59-64
- [10] Schindler OS. Synovial plicae of the knee. *Current Orthopaedics* 2004; 18: 210-9
- [11] Sung-Jae K, Jae-Hoon J, Young-Min C, Sang-Wook R. MPP test in the diagnosis of the medial patellar plica syndrome. *The Journal of the Arthroscopic and Related Surg* 2004;20 :10101-3
- [12] Vaughan-Lane T, Dandy DJ. The synovial shelf syndrome. *J Bone Joint Surg* 1982; 64: 475

- [13] Christoforakis JJ, Strachan RK. Internal derangements of the knee associated with patellofemoral joint degeneration. *Knee Surg Sports Traumatol Arthrosc.* 2005 ;13:581-4
- [14] Christoforakis JJ, Ballester J, Hunt N, Thomas R, Strachan RK. Synovial shelves of the knee: association with chondral lesions. *Knee Surg Sports Traumatol Arthrosc.* 2006 ;14:1292-8
- [15] Lyu SR, Hsu CC. Medial plicae and degeneration of the medial femoral condyle. *Arthroscopy* 2006;22:17-26.
- [16] Sakibara J. Arthroscopic study on Iinos's band (plica synovialis mediopatellaris) [In Japanese]. *Nippon Seikeigekai Gakkai zasshi.* 1976;513-22.
- [17] Dorchak JD, Barrack RL, Kneisl JS, Alexander AH. Arthroscopic treatment of symptomatic synovial plica of the knee. Long-term followup. *Am J Sports Med* 1991;19:503-7.
- [18] Hansen H, Boe S. The pathological plica in the knee. Results after arthroscopic resection. *Arch Orthop Trauma Surg* 1989;108:282-4.
- [19] Irha E, Vrdoljak J. Medial synovial plica syndrome of the knee: a diagnostic pitfall in adolescent athletes. *J Pediatr Orthop B* 2003;12:44-8
- [20] Farkas C, Hargitai Z, Gaspar L, Kuki A, Csernatony Z, Szepesi K. Histological changes in the symptomatic mediopatellar plica. *Knee* 2004;11:103-8.
- [21] Aglietti P, Buzzzi R, Insall JN. Disorders of the patellofemoral joint. In: Insall JN, Scott WN. (eds), *Surgery of the knee* (3rd ed) Curchill Livingstone, Pennsylvania 2001, 913-1043
- [22] Pipkin G. Knee injuries: the role of the suprapatellar plica and suprapatellar bursa insimulating internal derangements. *Clin Orthop Relat Res.* 1971;74:161-76.
- [23] Ogata S, Uhthoff HK. The development of synovial plicae in human knee joints: an embryologic study. *Arthroscopy.* 1990;6:315-21.
- [24] Dupont JY Synovial plicae of the knee. Controversies and review. *Clin Sports Med* 1997;16(1):87-122
- [25] Kent M, Khanduja V. Synovial plicae around the knee. *Knee.* 2010; 17(2):97-102.
- [26] Muse, G, Grana, W and Hollingsworth, S. Arthroscopic treatment of medial shelf syndrome. *Journal of Arthroscopy.* 1985;1,63-7.
- [27] Kim SJ, Min BH, Kim HK. Arthroscopic anatomy of the infrapatellar plica. *Arthroscopy* 1996; 12(5):561-4.
- [28] Pınar H: Dizde sinovyal patolojiler ve plika sendromları. In: Tandoğan RN, Alpaslan M (ed), *Diz cerrahisi, Haberal Eğitim Vakfı, Ankara* 1999, 283-98.
- [29] Kinnard P, Levesque RY. The plica syndrome. A syndrome of controversy. *Clin Orthop Relat Res.* 1984 ;183:141-3.
- [30] Barry BP. Arthroscopy of lower extremity. In: Canale ST (ed), *Campbell's Operative Orthopaedics* (10th ed) Mosby, Pennsylvania 2003, 2515-2612
- [31] Dorchak JD, Barrack RL, Kneisl JS, Alexander AH. Arthroscopic treatment of symptomatic synovial plicae of the knee . Long -term follow up. *Am J Sports Med.* 1991;19(5):503-7.
- [32] Nigam A, Shetty VD. The medial plica: a clinical perspective. *Eur J Orthop Surg Traumatol.* 2011
- [33] Blok A, Weiss W, Dolata T, Szczepaniec M Medial synovial plica. *Ortop Traumatol Rehabil.* 2005;7(4):397-40
- [34] Zidorn T Classification of the suprapatellar septum considering ontogenetic development. *Artroscopy.* 1992;8:459-64

- [35] Lyu SR Relationship of medial plica and medial femoral condyle during flexion. Clin Biomech (Bristol,Avon).2007;22(9):1013-16
- [36] Broom MJ, Fulkerson JP The plica syndrome: a new perspective. Orthop Clin North Am.1986;17(2):279-81
- [37] Richmond JC, McGinty JB Segmental arthroscopic resection of the hypertrophic mediopatellar plica. Clin Orthop Relat Res.1983;178:185-89
- [38] Shetty VD, Vowler SL, Krishnamurthy S, Halliday AE Clinical diagnosis of medial plica syndrome of the knee: a prospective study. J Knee Surg.2007;20(4):277-80
- [39] Guney A,Bilal O, Oner M, Halici M, Turk Y, Tuncel M. Short- and mid-term results of plica excision in patients with mediopatellar plica and associated cartilage degeneration.Knee Surg Sports Traumatol Arthrosc. 2010; 18(11):1526-31.
- [40] Aprin, H, Shapiro, J and Gerschwind, M. Arthrography (plica views). Clinical Orthopaedics and Related Research. 1983; 68,1,90-5.
- [41] Kerimoglu S, Citlak A, Cavusoglu S, Turhan AU Bucket handle tear of medial plica. Knee. 2005;12(3):239-41
- [42] Yamamoto Z, Fujita A, Minami G, Ishida R, Abe M Atraumatic hemarthrosis caused by a large mediopatellar plica. Arthroscopy.2001;17(4):415-17
- [43] Kim SJ, Lee DH, Kim TE. The relationship between the MPP test and arthroscopicallyfound medial patellar plica pathology. Arthroscopy 2007;23(12):1303–8.
- [44] Koshino T, Okamoto R Resection of painful shelf (plica synovialis mediopatellaris) under arthroscopy. Arthroscopy. 1995;11(6):738
- [45] Kim SJ, Jeong JH, Cheon YM, Ryu SW. MPP test in the diagnosis of medial patellar plica syndrome. Arthroscopy 2004; 20(10):1101–3.
- [46] Laissy JP, Schouman-Claeys E, Lacombe P, Dupont JY, Halimi P, Frija G. Value and limits of arthrography in the study of pathological mediopatellar plicae of the knee; a comparison with arthroscopy. Eur J Radiol 1990;11(2):93–7
- [47] Lupi L, Bigli S, Cervi PM, Limone GL, Massari L. Arthrography of the plica syndrome and its significance. Eur J Radiol 1990;11(1):15–8.
- [48] Boles CA, Butler J, Lee JA, Reedy ML, Martin DF. Magnetic resonance characteristics of medial plica of the knee: correlation with arthroscopic resection. J Comput Assist Tomogr 2004;28(3):397–401
- [49] Kobayashi Y, Murakami R, Tajima H, Yamamoto K, Ichikawa T, Mase Y, et al. Direct MR arthrography of plica synovialis mediopatellaris. Acta Radiol 2001; 42 (3):286–90.
- [50] Nakanishi K, Inoue M, Ishida T, Murakami T, Tsuda K, Ikezoe J, et al. MR evaluation of mediopatellar plica. Acta Radiol 1996;37(4):567–71
- [51] Jee WH, Choe BY, Kim JM, Song HH, Choi KH. The plica syndrome: diagnostic value of MRI with arthroscopic correlation. J Comput Assist Tomogr 1998;22(5):814–8
- [52] Rovere GD, Adair DM. Medial synovial shelf plica syndrome. Treatment by intrapical steroid injection.Am J Sports Med. 1985;13:382-6
- [53] Bae DK, Nam GU, Sun SD, Kim YH. The clinical significance of the complete type of suprapatellar membrane. Arthroscopy 1998;14(8):830–5
- [54] Brief LP, Laico JP The superolateral approach: a beter view of the medial patellar plica. Arthroscopy.1987;3(3):170-72
- [55] Johnson DP, Eastwood DM, Witherow PJ Symptomatic synovial plicae of the knee. J Bone Joint Surg Am.1993; 75(10):1485-96
- [56] Limbird TJ. Patellar subluxation following plica resection. Orthop Rev. 1988;17:282-85



Osteoarthritis - Diagnosis, Treatment and Surgery

Edited by Prof. Qian Chen

ISBN 978-953-51-0168-0

Hard cover, 404 pages

Publisher InTech

Published online 02, March, 2012

Published in print edition March, 2012

Osteoarthritis is one of the most debilitating diseases affecting millions of people worldwide. However, there is no FDA approved disease modifying drug specifically for OA. Surgery remains an effective last resort to restore the function of the joints. As the aging populations increase worldwide, the number of OA patients increases dramatically in recent years and is expected to increase in many years to come. This is a book that summarizes recent advance in OA diagnosis, treatment, and surgery. It includes wide ranging topics from the cutting edge gene therapy to alternative medicine. Such multifaceted approaches are necessary to develop novel and effective therapy to cure OA in the future. In this book, different surgical methods are described to restore the function of the joints. In addition, various treatment options are presented, mainly to reduce the pain and enhance the life quality of the OA patients.

How to reference

In order to correctly reference this scholarly work, feel free to copy and paste the following:

Ahmet Guney and Ibrahim Kafadar (2012). The Plica: Is a New Aetiological Factor in the Knee Osteoarthritis?, Osteoarthritis - Diagnosis, Treatment and Surgery, Prof. Qian Chen (Ed.), ISBN: 978-953-51-0168-0, InTech, Available from: <http://www.intechopen.com/books/osteoarthritis-diagnosis-treatment-and-surgery/the-plica-is-a-new-aetiological-factor-in-the-knee-osteoarthritis->

INTech
open science | open minds

InTech Europe

University Campus STeP Ri
Slavka Krautzeka 83/A
51000 Rijeka, Croatia
Phone: +385 (51) 770 447
Fax: +385 (51) 686 166
www.intechopen.com

InTech China

Unit 405, Office Block, Hotel Equatorial Shanghai
No.65, Yan An Road (West), Shanghai, 200040, China
中国上海市延安西路65号上海国际贵都大饭店办公楼405单元
Phone: +86-21-62489820
Fax: +86-21-62489821

© 2012 The Author(s). Licensee IntechOpen. This is an open access article distributed under the terms of the [Creative Commons Attribution 3.0 License](https://creativecommons.org/licenses/by/3.0/), which permits unrestricted use, distribution, and reproduction in any medium, provided the original work is properly cited.

IntechOpen

IntechOpen