

# We are IntechOpen, the world's leading publisher of Open Access books Built by scientists, for scientists

6,900

Open access books available

186,000

International authors and editors

200M

Downloads

Our authors are among the

154

Countries delivered to

TOP 1%

most cited scientists

12.2%

Contributors from top 500 universities



WEB OF SCIENCE™

Selection of our books indexed in the Book Citation Index  
in Web of Science™ Core Collection (BKCI)

Interested in publishing with us?  
Contact [book.department@intechopen.com](mailto:book.department@intechopen.com)

Numbers displayed above are based on latest data collected.  
For more information visit [www.intechopen.com](http://www.intechopen.com)



# Surgical Management of Skull Base Meningiomas – An Overview

Bernhard R. Fischer and Benjamin Brokinkel

*Department of Neurosurgery, University Hospital of Münster  
Germany*

## 1. Introduction

Meningiomas as extra axial tumours, developing from arachnoid cap cells may occur from all dural structures, cranial and spinal and rarely outside of these structures (Whittle et al. 2004). The skull base is an area with multiple neural structures as well as brain supplying adjacent arteries and veins. Meningiomas, growing on or within the skull can thus be very challenging for the neurosurgeon. In consequence, complete tumour removal without neural impairment is not always possible (Seifert 2010; Yasargil 1980) and surgery in this area, especially in petro-clival meningiomas, hazardous. Advances in microsurgical technique, development of new approaches and advancement of adjuvant therapies allow for reducing or removing meningiomas as well as a sufficient control of residual or recurrent tumours.

## 2. Epidemiology

Meningioma is considered the most primary intracranial neoplasm, representing 14.3-19.0% of all intracranial tumours. Hence, estimated prevalence is approximately 100/100.000 with an age adjusted, sex dependent incidence rate of 8.4 and 3.6/100.000 a year.

According to the current WHO classification, the vast majority of these tumours are classified as grade I (aka benign meningioma, approximately 80-90%). With a distinct increase of recurrence and mortality, about 4.7 up to 20% of meningiomas are characterized as grade II (aka atypical) meningioma, while grade III (aka anaplastic) tumours occur in 1.0-2.8% of all meningiomas (Louis et al. 2007). Although meningioma appears presumably in all groups of age with even infants being affected, incidence peaks markedly in the fourth and sixth decade (Chohan et al. 2011; Rockhill et al. 2007). Sex distribution depicts female pre-dominance among all groups of age with a distinct apex of almost 2:1 in the 30s and 40s (Rockhill et al. 2007; Whittle et al. 2004; Wiemels et al. 2010).

## 3. Etiology

Although most meningiomas occur presumably spontaneously and therefore independently of neither endogenous nor exogenous factors, high and low-dose ionizing cranial radiation could be shown to induce especially meningiomas of higher grades of malignancy (Louis et

al. 2007; Wiemels et al. 2010). Pronounced female predominance among patients in the fertile decades and various expression of progesterone, estrogen and androgen receptors suggest impact of sex hormones on tumour genesis and growth. Subsequently, a relation between the administration of oral contraceptives/ exogenous hormones (hormone replacement therapy, HRT) and an increased risk of meningioma development was observed (Michaud et al. 2010). Hence, these observations remain controversial and the role of sex hormones in tumour genesis needs to be determined in further analyses.

About 20% of meningiomas in adults occur in patients suffering from neurofibromatosis type 1 (Wiemels et al. 2010).

#### 4. Locations

Approximately one third of meningiomas are classified as typical skull base meningioma, subsuming tumours arising from the arachnoids of the olfactory groove (< 10%), the tuberculum sellae (12.8%), the foramen magnum (<4%) and the sphenoid ridge (17%). The least includes meningiomas arising from either the medial, clinoidal, alar or outer, temporal/pterional portion of the sphenoid ridge (30.1%, 6.9% and 16% of all meningiomas involving the sphenoid ridge, respectively) (Honig et al. 2010; Mendenhall et al. 2004; Condra et al. 1997; Rockhill et al. 2007).

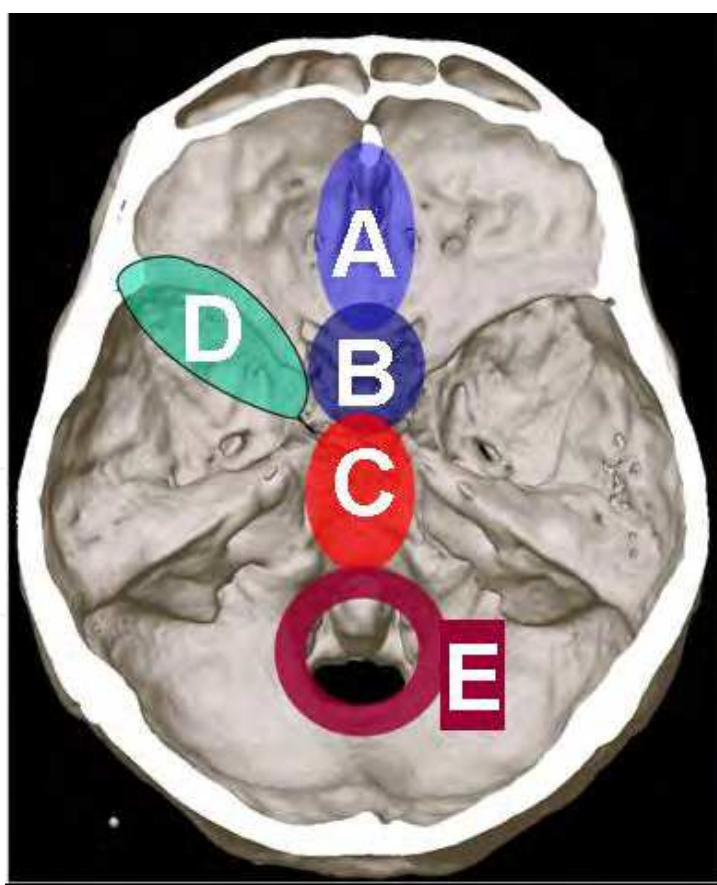


Fig. 1. Computed tomography of the skull base with marked areas of meningioma occurrence, A: olfactory groove, B: para- , suprasellar, C: petro-clival, D: sphenoid wing, E: foramen magnum.

## 5. Symptoms

In general, unspecific symptoms like headache might occur years before a correct diagnosis. Contrarily to tumours of the convexity, seizures are rarely seen in skull base meningiomas. Amongst skull base meningiomas seizures mostly happen in cases of sphenoid wing tumours.

### 5.1 Frontal skull base

Meningiomas developing at the frontal skull base, especially in the olfactory groove can be of grotesque size (Fig. 2) before diagnosed, due to the fact that hypo- or anosmia, may occur very slowly and thus might not impact the patients' life quality immediately. When spreading along the midline and reaching the tuberculum sellae other neurological symptoms may occur. Affection of the fronto-basal lobe can induce incontinence as well as psychotic disturbances, e.g. personality changes, psycho-motor disabilities and cognitive impairment. Visual disturbances occur due to compression of the optic nerve (reduction of vision, blindness) or affection of the chiasm (bitemporal hemianopsia). Furthermore, the compression of the pituitary stalk and/or the hypothalamus can induce endocrinological disturbances.

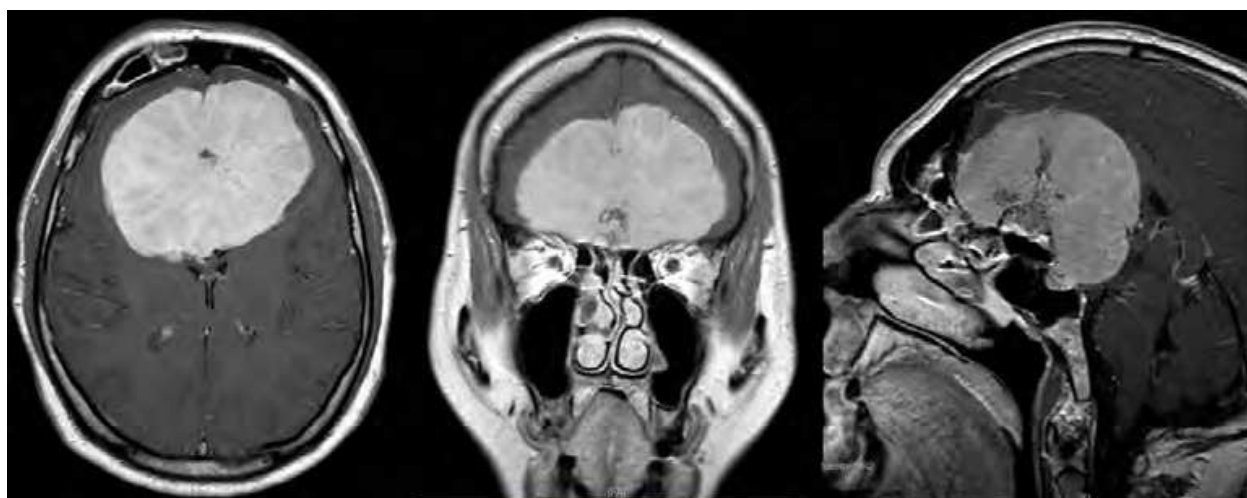


Fig. 2. T1-weighted triplanar magnetic resonance tomography after application of gadolinium, revealing a huge tuberculum sellae meningioma with homogenous contrast enhancement

### 5.2 Sphenoid ridge

Tumour growth along the sphenoid wing can cause a range of different neurological symptoms. When spreading into the middle skull groove, affecting the basal temporal lobe, seizures may be the first symptoms of the tumour. Furthermore, affection of the optic nerve can induce visual disturbance. Diplopia may occur due to compression of eye movement nerves (CN III, IV, VI), trigeminal nerve impairment may induce dysesthesia and/or loss of sensibility and ultimately even lead to a keratitis.

Especially bone invading sphenoid wing meningiomas might cause hyperostosis (Bikmaz et al. 2007).

### 5.3 Petro-clival

Tumour extension along the clivus may affect cranial nerves (CN V, VII-XI). According to the tumour mass and location (Fig. 3) occlusive hydrocephalus may occur as well as symptoms of brain stem compression (mono- or hemiparesis, paresthesia).

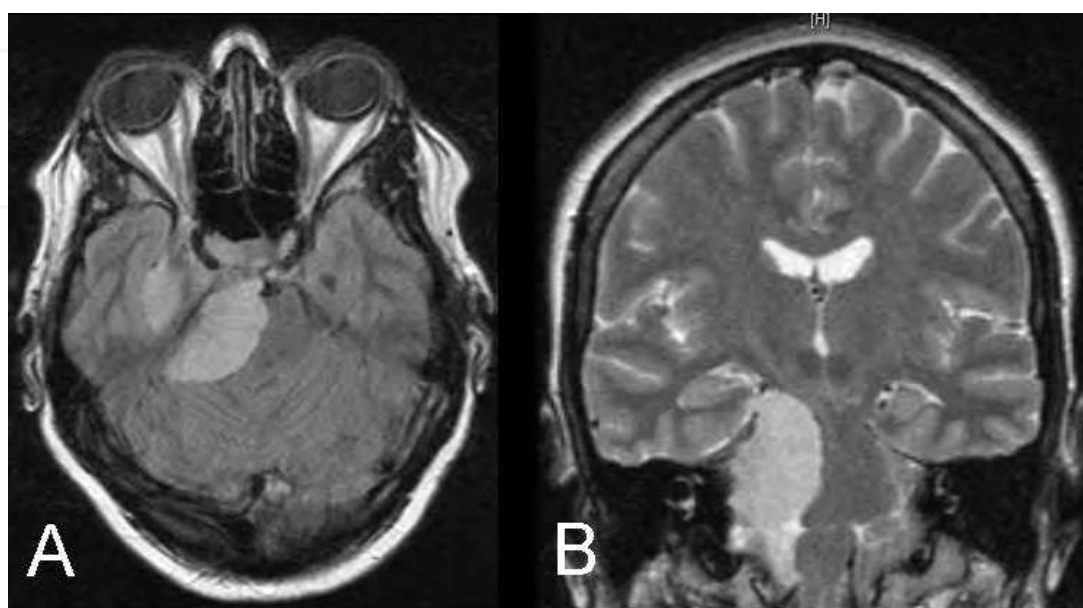


Fig. 3. Magnetic resonance tomography (A: T1 weighted, B: T2 weighted, both after application of gadolinium), showing a right sided petro-clival meningioma.

### 5.4 Foramen magnum

Meningiomas growing within the foramen magnum, ventral, lateral or dorsal, may affect especially the lower CN as well as brain stem functions. In addition to that occlusive hydrocephalus due to compression of the aqueduct may occur. Furthermore, meningioma within the posterior fossa, growing from the tentorium may compress and/or invade the cerebral sinus or arteries.

All tumours within the posterior fossa may irritate cerebellar functions, inducing ataxia, dysmetria, tremor and vertigo.

## 6. Pre-operative management

### 6.1 Neuro-imaging

In most patients with acute symptoms like seizures, a native computed tomography will be performed. In case of suspected intracranial or intracerebral mass and in absence of contraindications, a contrast-CT can be added. While classical indications as calcifications, surrounding edema and hyperostosis are revealed by native CT, tumour extension is well documented by a contrast-CT (Fig. 4). Performing an angio-CT may reveal the correlation between meningioma and vessels (Fischer et al. 2009). Assuming a sinus invasion more information can be gathered by angiography, especially in a venous phase.



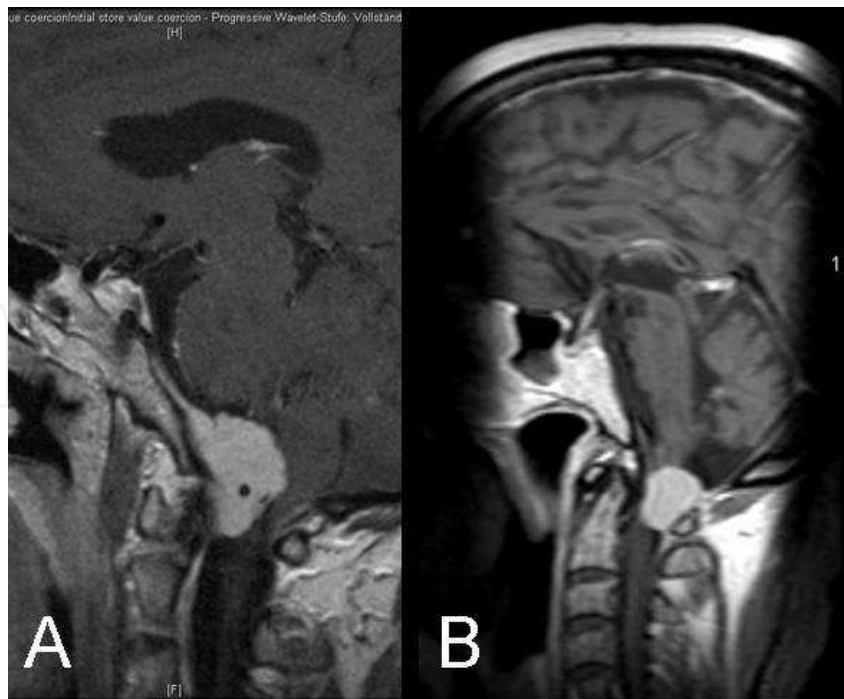

Fig. 4. Magnetic resonance tomography (coronar, T1-weighted, after application of gadolinium), showing A: a ventro-lateral and B: a dorso-lateral foramen magnum meningioma.

Magnetic resonance tomography including T1- and T2- weighted sequences, before and after contrast application, should be best practice in pre-operative meningioma diagnostic (Fig. 5).

In highly vascularized meningioma the demonstration of vascular architecture, e.g. by digital subtraction angiography, might be indicated to prevent vascular damage (Dowd et al. 2003). In special cases embolization of feeding arteries reduces the risk of disproportional intra-operative bleeding. Yet, there is no distinct data stating a definite duration between embolization and surgery, preventing re-opening of arteries as well as vascular genesis, which can sweep off the embolization effect (Dowd et al.2003).

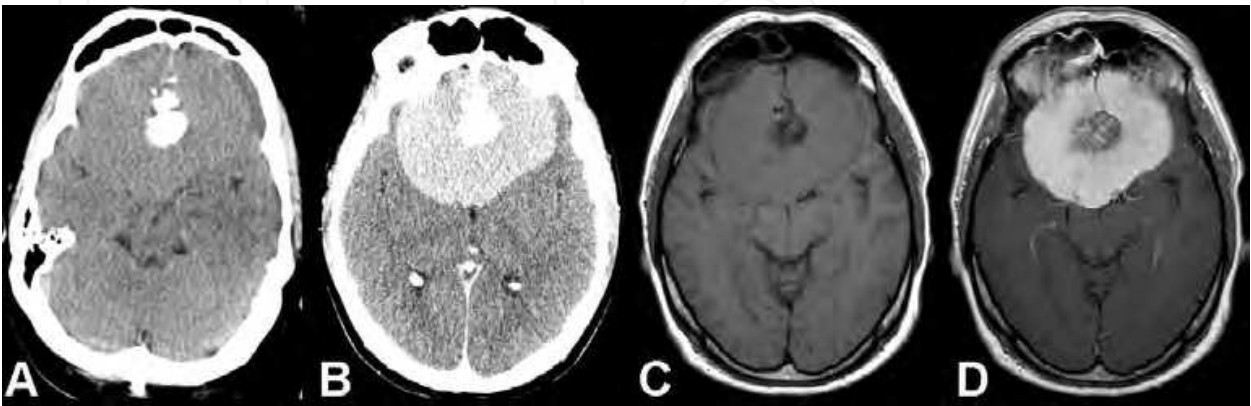


Fig. 5. Computed tomography (A: native and B: with contrast) and magnetic resonance imaging, T1 weighted (C before and D after gadolinium ) revealing a huge tuberculum sellae meningioma with central calcification and homogenous contrast enhancement (B, D).

### 6.1.1 Neuro-navigation

Technical innovations, such as neuro-navigation and intraoperative ultrasound led to more efficient planning of the surgical approach, due to smaller skin incision and bone resection. As ultrasound may show subcortical tumour localisation and vascularitiy and especially the course of larger vessels and tumour extension can be detected more easily. Other than in patients with sub-cortical tumours, in skull base meningiomas no brain shift occurs since the tumour is fixed at dural or osseous structures. In consequence, neuro-navigation may show the size of the residual tumour and the distance to vascular, neural and osseous structures.

For neuro-navigation 1 mm thick cranial CT-slices, scanned without gantry overturning, can be fused with MRI scans. This combination not only shows tumour mass, but also evidences vascular and neural structures as well as the extension within the osseous skull base.

Depending on tumour location and encasement of each cranial nerve, patients should be informed thoroughly about potential transient or persisting postoperative cranial nerve dysfunction. Appropriation of blood products (erythrocytes, thrombocytes) should be managed preoperatively.

### 6.2 Medication

- Steroids (e.g. dexamethasone 4mg q 8 hrs) are recommended to reduce peri-tumoural brain edema and edema-induced neurological symptoms
- Pre-operative application of anti-convulsive drugs is only indicated in patients with seizures and cannot be recommended prophylactically (Lieu&Howng 2000; Sughrue et al. 2011)
- Due to the possible distinct vascularization, impaired coagulation (e.g. pharmacologically by platelet aggregation inhibitors or coumarins) should not be present at time of surgery (Sughrue et al. 2011)

## 7. Approaches

In most cases of skull base meningiomas surgery is the first choice treatment. The success of surgical intervention depends substantially on the right approach to the tumour and thus substantially on the localization of the tumour.

Technical and medical advancement allow for the treatment of even deep or central seated meningiomas with low risk for peri-operative morbidity and mortality.

Since there are no strict recommendations on how to get access to the tumour, knowing the location of adjacent eloquent brain areas, run of cranial nerves, arteries and veins is essential to determine the most efficient and safe approach.

In this chapter we will describe some efficient approaches for treating skull base meningiomas of all kinds of localisations surgically. Anyways, best advice remains: “use the approaches you are familiar with”.

In general, administration of hyperosmolaric fluids 30 min before skin incision, is recommended to all patients with skull base meningiomas unless there is no contraindication.

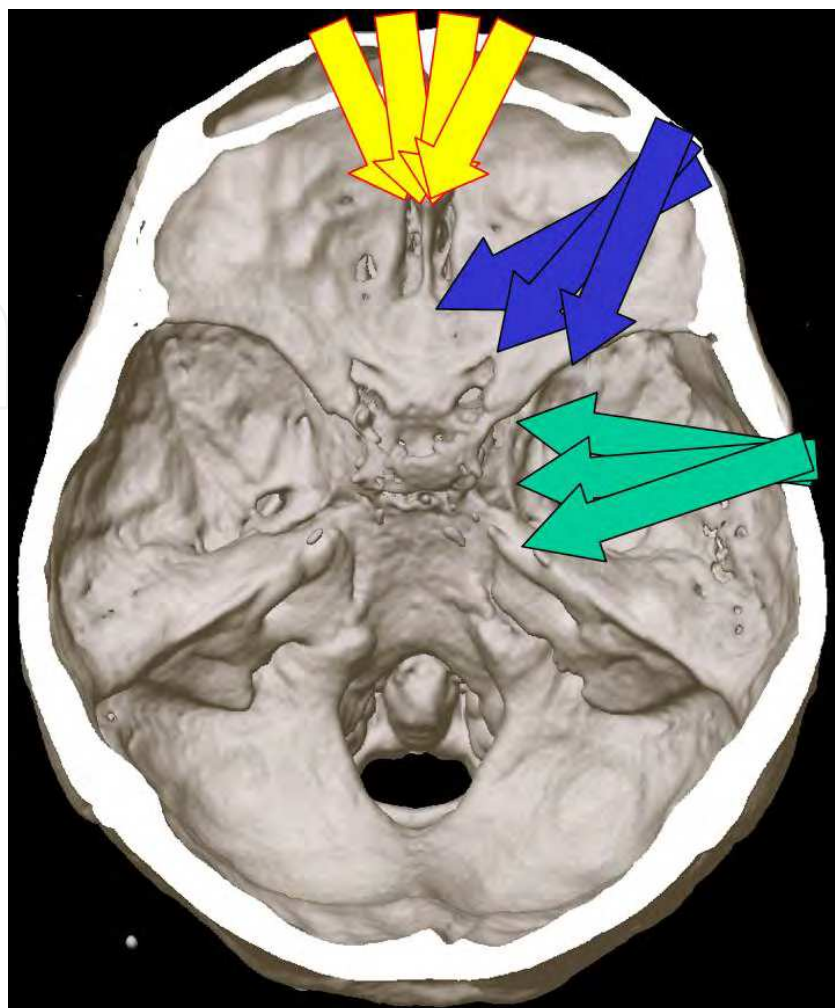


Fig. 6. Drawing of main approaches to meningiomas located in the olfactory groove, planum sphenoidale, para- and supra-sellar, sphenoid wing

### 7.1 Olfactory groove-, tuberculum sellae- meningiomas

In patients with olfactory groove meningiomas a fronto-basal craniotomy, mono- or bifrontal, and interhemispheric subfrontal approach is sufficient (Nakamura et al. 2006, 2008). For an interhemispheric approach occlusion of the superior sagittal sinus is sometimes necessary. In most cases this occlusion is without sequelae if performed in the frontal third. A pre-operative CT-scan or digital subtraction angiography can reveal bridging veins, leading to the superior sagittal sinus, which should be preserved.

Dura opening should be semicircular with fronto-basal base.

### 7.2 Tuberculum sellae-, planum sphenoidale- meningiomas

Even though tuberculum sellae meningiomas are midline skull base tumours, the craniotomy for these tumours is placed supra-orbital reaching the tumour sub-frontally (Samii & Gerganov 2008). After dura opening, basal cisterns should be opened and CSF can be aspirated. Thus, by additional use of hyperosmolaric fluids and aspirating CSF the tumours can be reached with only slight retraction of the frontal lobe.



### 7.3 Sphenoid wing meningiomas

For small medial sphenoid wing meningiomas a supra-orbital craniotomy or a subfrontal approach are mostly used. Due to the extension of the tumour the supra-orbital craniotomy can be expanded to a orbito-zygomatic or a fronto-temporal craniotomy (Mahmoud et al. 2010; Seckin et al. 2008). Dura opening and CSF leakage should be performed like shown above.

Tuberculum sellae as well as sphenoid wing meningiomas sometimes invade the optic canal. In all cases of tumour extension into the optic canal, revealed by neuro-imaging pre-operatively, the nerve should be unroofed and tumour mass removed (Mahmoud et al. 2010). Otherwise swelling of residual tumour mass within the canal after closure of tumour vessels, especially veins, may deteriorate the visual faculty.

### 7.4 Petro-clival meningiomas

A multiplicity of approaches has been developed and is used today, depending on the extension of the tumour, the clinical status of the patient and especially the surgeon's experience. These approaches not only involve pterional and orbitozygomatic craniotomies but also sub-occipital approaches, sometimes in combination with a petrosal approach (Bambakidis et al. 2007; Kandenwein et al. 2009; Samii & Gerganov 2008; Seifert 2010).

In order to reach petroclival meningiomas, we recommend a sub-occipital craniotomy. Depending on tumour localization (ventral, lateral or dorsal) and size, these tumours often affect lower cranial nerves and/or the brain stem. To avoid cranial nerve and brain stem damage and get a better overview, the approach can be extended to a "far lateral approach".

For surgery of the posterior skull base, e.g. for suboccipital craniotomies, the patient is bedded in "parkbench-position" (Fig. 7). The endo-tracheal tube is combined with an electrode monitoring motor vagal nerve function.

In case of dorsal foramen magnum meningioma a partial laminectomy of the atlas is performed, if necessary with partial resection of the lamina of the axis.

In the pictures below craniotomy involves the foramen magnum as well as a partial resection of C1 in terms of partial laminectomy and mobilization of the vertebral artery (Fig. 8). Dura opening can be stretched across the complete cranio- and laminectomy. By preparing and opening of basal cisterns CSF can be withdrawn by suction.

A recently published comprehensive review on the outcome after surgery of petroclival meningiomas, stated no significant differences to the approach used (DiLuna & Bulsara 2010).

## 8. Intra-operative management

Skull base meningiomas often involve cranial nerves, brain arteries and might furthermore compresses the brain stem and/ or the spinal cord (DiLuna & Bulsara 2010). To avoid nerve and/or spinal cord injury, monitoring of nerve and spinal cord function is essential. In order to preserve motor cranial nerves electromyography should be recorded, furthermore visual, auditory, somato-sensory or motor evoked potentials should be monitored to avoid the nerve conduction (Topsakal et al. 2008). In all cases the efficiency of neuro-monitoring depends mainly on the kind of anaesthesia, therefore total intravenous anaesthesia should be used.

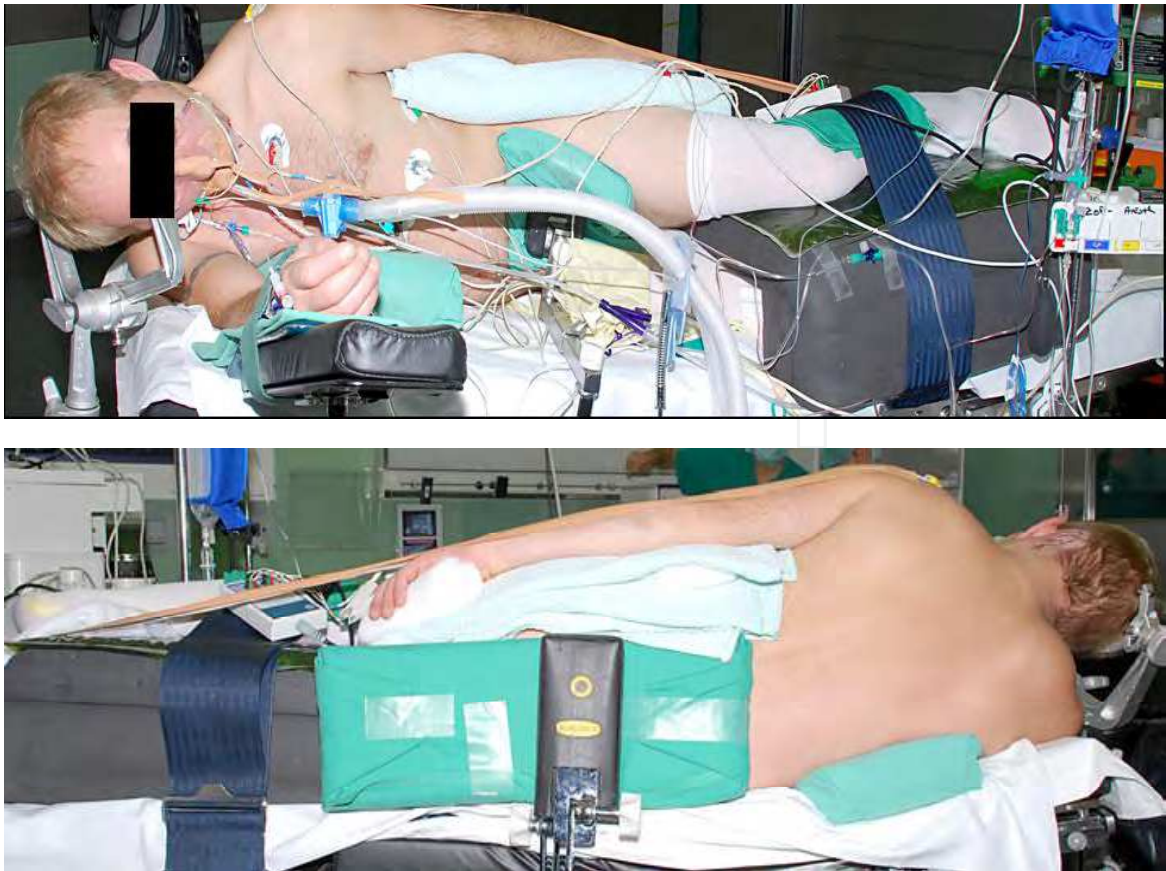


Fig. 7. For suboccipital approaches patients are bedded in park-bench position.

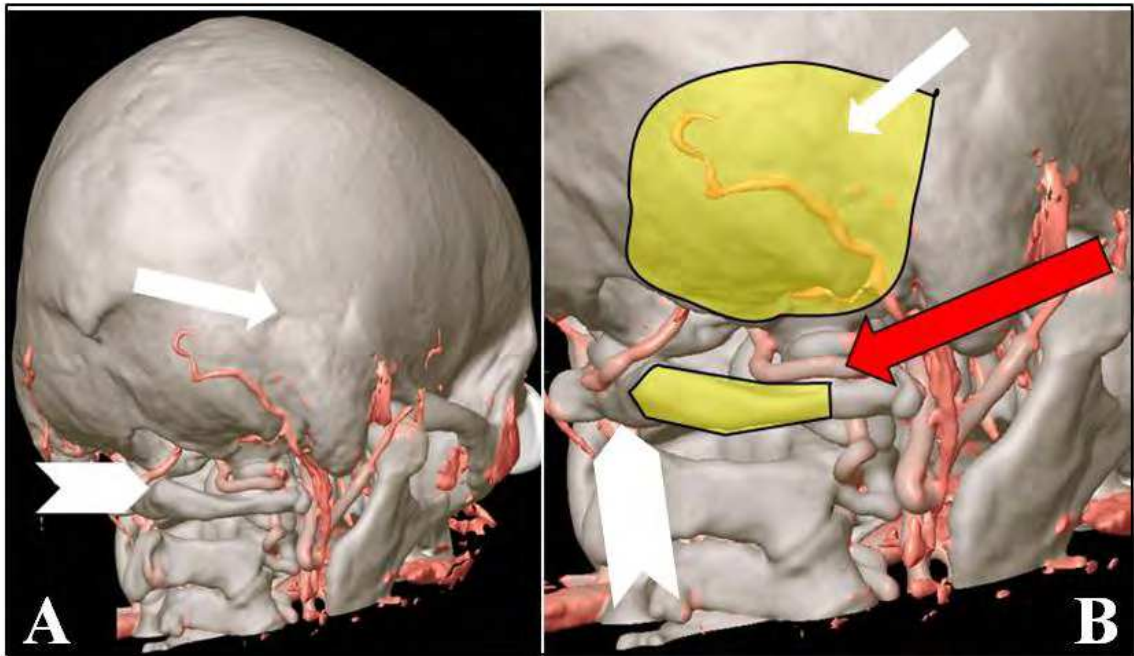


Fig. 8. Reconstruction of cranial computed tomography demonstrating the far lateral approach, **B** is an excerpt of **A**. Yellow areas highlight the extend of craniotomy and hemilaminectomy of the atlas (open arrow), after mobilization of the vertebral artery (red arrow). The keyhole for suboccipital craniotomy is placed on the asterion (closed white arrow).

### 8.1 Tumourresection

Since nervefibres may run within the capsule, in tumours affecting cranial nerves, these should be identified by neurostimulation to prevent neural deficit. Resection of the tumour then starts with opening of the tumour capsule and intracapsular debulking. To avoid damage of neural function due to traction and compression by manipulation, an ultrasound aspirator system is used. In many cases vascular supply of the tumour comes from arteries at the tumour basis and can not be cut off in the beginning of tumour resection. Furthermore, especially in petroclival meningiomas blood supplying arteries arising from different vascular territories have to be prepared carefully to prevent cerebellar or brain stem ischemia. Finally the capsule, after separation of nerves and vessels can be resected (Fig. 9).

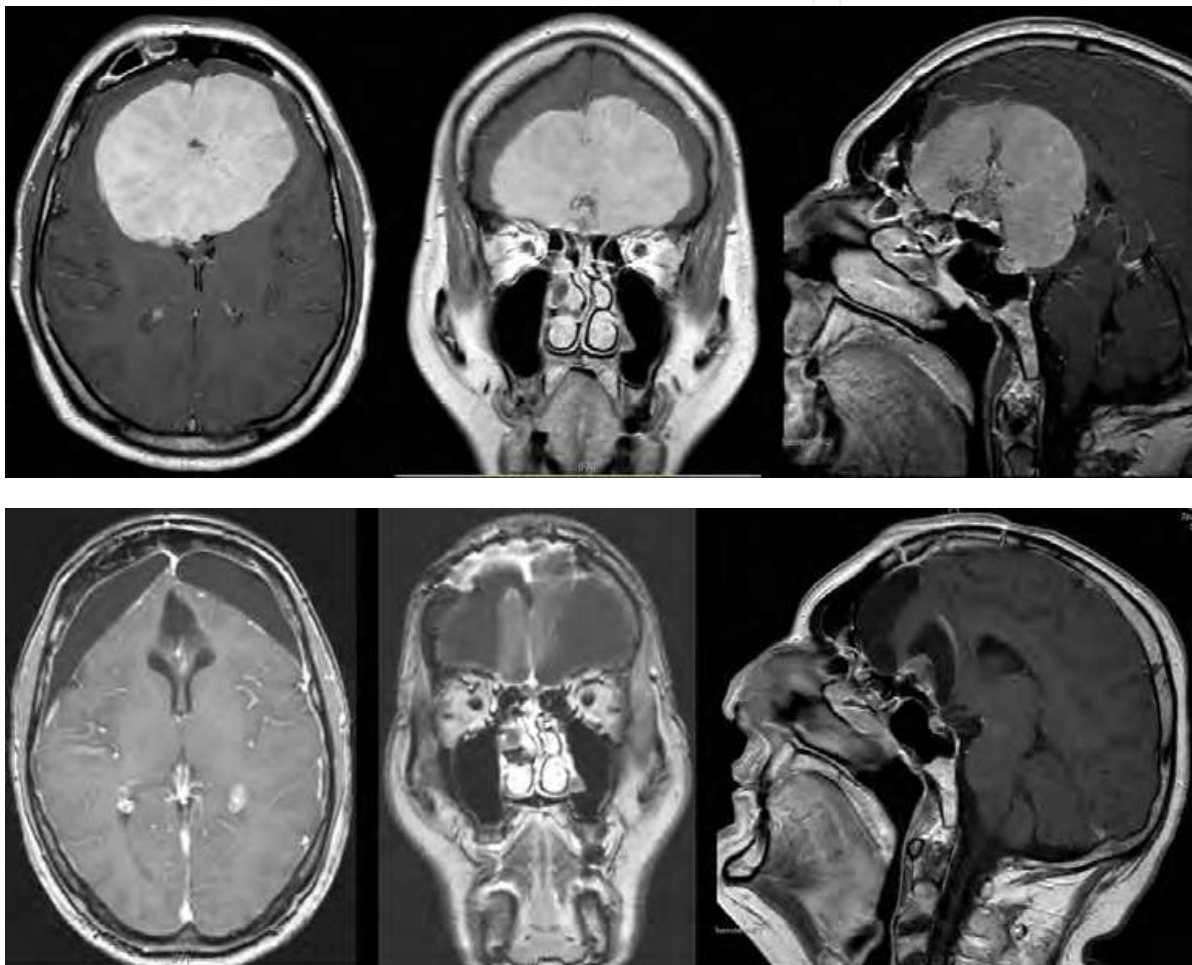


Fig. 9. Tri-planar, T1-weighted magnetic resonance imaging after gadolinium application, revealing nearly complete tumour removal (panel below) of the huge tuberculum sellae meningioma.

Whenever cranial nerves as well as vessels hinder tumour overview, new technical tools such as endoscopy may help to identify tumour residuals, especially in petro-clival meningiomas (Samii & Gerganov 2008). In selected patients, especially with frontal and tuberculum sellae meningiomas, endoscopic tumour removal with extended transnasal, transsphenoidal surgery, or with small craniotomy, can be successfully performed (Rachinger et al. 2010; Wang et al. 2010).



Similar to non skull base meningiomas, the grade of tumour resection is classified by the Simson grading system

Grade	Degree of removal
I	Macroscopically complete resection, excision of adjacent abnormal dura or bone
II	Macroscopically complete resection, coagulation of adjacent abnormal dura or bone
III	Macroscopically complete resection, no coagulation or excision of adjacent abnormal dura or bone
IV	Partitial removal
V	Decompression

Table 1. The Simpson grading system for removal of meningiomas (modified after Simpson 1957).

In different approaches, frontal, orbital, orbito-zytomatic as well as suboccipital, opening of frontal sinus or mastoid cells may occur. In such cases, mucosa has to be removed and the sinus as well as mastoid cells should be sealed with muscle or fat tissue and fixed with glue to avoid CSF leakage as well as inflammation.

Dural closure should be waterproof to prevent CSF leakage and re-operation. If dura was resected because of tumour invasion, dura plastic should be performed in an optimal way with autologous material such as galeal-periosteal flap.

9. Post-operative management

Post-operatively patients should be observed on an intense care unit where frequent neurological examination and optional mechanical ventilation is assured.

According to the extension of peri-tumoural edema steroid application should be continued for a few days, e.g. dexamethasone which is applicated 4mg q 8 hours the day of surgery and subsequently halved each following day.

Up to 25 % of meningioma patients develop seizures and antiepileptic drugs might be present in a large number of patients. Since intraoperative mechanical manipulation of the tumour surrounding brain tissue might even provoke further cortical epileptic activity, preoperatively onset antiepileptic drugs should be pursued for a few weeks postoperatively as well (Lieu & Howng 2000; Sughrue et al. 2011; van Breemen et al. 2007).

10. Adjuvant therapy

10.1 Radiation therapy

In patients with residual tumours as well as in patients with atypical or anaplastic meningiomas additional therapeutic options (radiotherapy, radiosurgery, e.g.) may help to control tumour growth and extension (Davidson et al. 2007; Minniti et al. 2009). With conventional fractionated radiotherapy, 50 – 55 Gy, admitted in 30 – 33 sessions, a local control rate is observed in about 80%, additionally tumour shrinking is seen in up to 25%



(Minniti et al. 2009). In cases of incomplete resected meningioma WHO grade I, adjuvant radiation therapy should be started if tumour re-growth is documented, whereas primary postoperative radiation therapy with 55 - 60 Gy should be initiated in patients with higher grade meningiomas, independent of resection grade.

The kind of used radiation technique depends on tumour size and localization and the distance between tumour and neural structures as for example the optic system. In meningioma greater than 4 ml and with a distance of more than 2 mm between tumour and neural structures fractionated stereotactic radiotherapy seems to be more efficient for tumour control than radiosurgery (Deinsberger & Tidstrand 2005).

Radiotherapy, e.g. radiosurgery, as first choice of treatment, may be indicated in patients not eligible for surgery due to co-morbidities, a tumour size less than 3 cm and/or tumour localization with high risk of intra- or post-operative vascular or neural damage (Davidson et al. 2007).

## 10.2 Chemotherapy

Medical therapy in patients with residual, inoperative or recurrent meningiomas has been subject of intense research. Due to the fact that meningiomas express progesterone receptors in up to 67% and somatostatin receptors in up to 100 %, chemotherapeutical studies focus on the development of receptor antagonists to stop tumor growth (Wen et al. 2010; Whittle et al. 2004). Yet, trials of various drugs have not been very successful (Norden et al. 2009, Schulz et al. 2011). Anyway, some data from ongoing and recently closed studies are still lacking, e.g. hydroxyurea (Norden et al. 2009; Newton et al. 2007). For additional therapeutic options such as receptor antagonists (vascular, angiogenesis, growth factor, hormones e.g.) the efficiency has to be revealed in clinical studies as well (Norden et al. 2009).

In all patients neuro-imaging controls should be performed periodically, at its best by MRI, the first one 3 month after surgery.

## 11. Outcome

In one study 5 year post-operative survival of meningioma patients was specified up to 91.3%. Anyway, recurrence rates and mortality are considerably affected by extent of surgical resection and histological grading. Analyses showed that WHO grade of skull base meningiomas is significantly lower as compared to their non skull base counterparts (Kane et al. 2011). Anyway, due to anatomical conditions resection of skull base meningioma still remains a surgical challenge and outcome is additionally affected by skills and experience of the treating surgeon as well as by exact tumour location and relation to adjacent anatomic structures. Subsequently, researching the literature reveals wide spreading postoperative morbidity and mortality rates.

In a current series of 73 sphenoid ridge meningiomas (Honig et al. 2010), rates of perioperative morbidity and mortality were 7% and 3%, respectively, with 11 patients (15%) developing tumour recurrence (mean follow-up 29.8 months). In another series of 117 foramen magnum meningiomas, perioperative mortality was 1.8%, recurrence rate among the 93 followed up patients was calculated for 1.1% (Wu et al. 2009). Concerning

meningiomas of the ventro-medial skull base, analyses revealed gross total resection (simpson I and II) in approximately 90% with a perioperative mortality of 2.8% and recurrence rates 4.9% for both olfactory groove and tuberculum sellae meningiomas (Nakamura et al. 2006, 2008; Spektor et al. 2005). Additionally, table 2 gives an overview depicting morbidity and mortality following surgery for skull base meningiomas basing on a review of Chen et al. which mainly included outcome reports published from 2000 to the present (Chen et al. 2011) .

Location	Rate of total excision	Recurrence	Morbidity	Mortality
Anterior fossa	85-100%	0-4.9, mean follow-up of 2-5.28 years	0-31.3%	0-4.9%
Tuberculum sellae	76.4- 93%	1.4-4.2%, mean follow-up of 2.5-4.3 years	25-45%	0-8.7%
Medial sphenoid ridge	58-87%	0-9%, mean follow-up of 3.1-12.8 years	5.7-13%	0
Clinoidal	54.5- 86.7%	3.8-15%, mean follow-up of 3.1-4.5 years	4-29%	0
Middle fossa, Cavernous sinus	0	5-5.7%, mean follow-up of 2.3-3.8 years	7.5-15%	0
Posterior fossa, Petroclival	0-48%	5-29%, mean follow-up of 3.9-8.5 years	20.3-47%	0-0.7%
Cerebellopontine angle	82-86.1%	3.9-7.5%, mean follow-up of 3.0-6.0 years	10.4-35.7%	0-5%
Foramen magnum	67-96%	0-5.5%, mean follow-up of 3.6- 6.1 years	5.9-27%	0-4.9%
Jugular foramen	50-100%	0-16.6%, mean follow-up of 2.5-6.5 years	30-61.5%	0-20%
Tentorial	77-91.3%	0-8.6%, mean follow-up of 4.5-5.9 years	9.7-55%	0-3.7%

Table 2. Outcome after surgical resection of skull base meningiomas of different locations (modified after Chen et al. 2011).

In order to estimate risk of meningioma surgery preoperatively, studies showed several predictors like patients’ age, co-morbidity, preoperative neurological deficit, tumour size and location (Caroli et al. 2005; Joung & Lee 2008). Considering skull base lesions, Adachi et al. developed an ABC Surgical Risk Scale introducing a scoring system including previous radiation or tumour surgery, tumour attachment size, arterial involvement, brainstem contact, central cavity location and cranial nerve group involvement as predictors for a worse neurological outcome (table 2). Thus, score reaches from 0 to 12 points, which was subsequently graduated into low (0-4), moderate (5-7) and high (8-12 points) risk group compared to extend to surgical resection and patients’ outcome (Tabl. 3, Adachi et al. 2009). Although estimation of perioperative risk might still remain individual in most instances, this considerably depicts necessity of adequate preoperative imaging.

		Points		
		0	1	2
A	Attachment size	<2cm	2-4cm	>4cm
	Arterial involvement	None	Single	Multiple
B	Brainstem contact	CSF space visible	No CSF space visible	Perifokal edema
C	Central Cavity	Outside	Partitial involvement	Inside
	Cranial nerve group involvement	None	One	≥2

Table 3. The ABC Surgical Risk Scale for skull base meningioma CSF=Cerebrospinal fluid (modified after Adachi et al. 2009).

12. Future directions

Knowledge in underlying genetic alterations as well as in epigenetic pathologies is increasing and may help to identify genetic risk factors for tumour recurrence and malignancy (Bethke et al. 2008; Norden et al. 2009). Within the last years, new target therapy options such as hormone receptor antagonists and anti-angiogenetic drugs (e.g. bevacizumab) could be evaluated in meningioma therapy with partially results (Norden et al., Newton et al. 2007). Anyways, the role of such a specified target therapy remains unclear and needs to be determined in further investigations. Additionally, as compared to malignant gliomas, fluorescence-supported resection techniques might increase extend of tumour resection especially in cases of wide spreading dural and/ or bony infiltration with diffuse tumor borders. Depending on the varying fluorescence of meningiomas and its medicamentous persuasibility intraoperative, photodynamic therapy (PDT) might become a new therapeutic option especially for tumors of complex anatomical location like the skull base.

13. Summary and conclusion

Skull base meningiomas are no longer an unsolvable problem, due to technical advantages as well as new strategies in radio- and chemotherapy. Surgery, using all available technical tools, e.g. neuro-imaging, neuro-monitoring, has become effective and safe in aggressive tumour reduction and simultaneously in preservation of neural function. Moreover, even in residual, recurrent or malignant meningioma, adjuvant radiotherapy and prospective chemotherapy results in tumour control and sometimes in tumour shrinking.

Many patients with benign skull base tumours rather accept a residual tumour in combination with an adjuvant therapy and a normal nerve function, than a radical tumour resection with the consequence of an impaired nerve function.

## 14. References

- Adachi, K.; Kawase, T.; Yoshida, K.; Yazaki, T. & Onozuka, S. (2009). ABC Surgical Risk Scale for skull base meningioma: a new scoring system for predicting the extent of tumor removal and neurological outcome. Clinical article. *J Neurosurg*, 111, 5, pp. 1053-1061, ISSN 0022-3085.
- Bambakidis, NC.; Kakarla, UK.; Kim, LJ.; Nakaji, P.; Porter, RW.; Daspit, CP. & Spetzler, RF. (2007). Evolution of surgical approaches in the treatment of petroclival meningiomas: a retrospective review. *Neurosurgery*, 61, 5 Suppl 2, pp. 202-209, ISSN 0148-396X
- Bethke L; Murray A; Webb E, et al. (2008). Comprehensive analysis of DNA repair gene variants and risk of meningioma. *J Natl Cancer Inst*, 100, pp. 270-276, ISSN 0027-8874
- Bikmaz, K.; Mrak, R. & Al-Mefty, O. (2007). Management of bone-invasive, hyperostotic sphenoid wing meningioma. *J. Neurosurg*, 107, 5, pp. 905-912, ISSN 0022-3085.
- Caroli, M.; Locatelli, M.; Prada, F.; Beretta, F.; Martinelli-Boneschi, F.; Campanella, R. & Arienta, C. (2005). Surgery for intracranial meningiomas in the elderly: a clinical-radiological grading system as a predictor of outcome. *J Neurosurg*, 102, 2, pp. 290-294, ISSN 0022-3085.
- Chen, CM.; APH.; Lu-Ting Kuo, LT. & Tu, YT. (2011). Contemporary surgical outcome for skull base meningiomas. *Neurosurg Rev*, 34, 3, pp. 281-296, ISSN 0344-5607.
- Chohan, MO.; Rehman, T.; Medina-Flores, R.; Clericuzio, C.; Heideman, R. & Marchand, E. (2011), 16 month-old female with intraventricular mass. *Brain Pathol*, 21, 3, pp. 349-50, ISSN 1015-6305.
- Condra KS; Buatti JM; Mendenhall WM; Friedmann, WA.; Marcus, RB. & Rhoton, AL. (1997). Benign meningiomas: primary treatment selection affects survival. *Int J Radiat Oncol Biol Physiol*, 7, 39, pp. 427-436, ISSN 0360-3016.
- Davidson, L.; Fishback, D.; Russin, JJ.; Weiss, MH.; Yu, C.; Pagnini, PG.; Zelman, V.; Apuzzo, ML. & Giannotta, SL. (2007). Postoperative Gamma Knife surgery for benign meningiomas of the cranial base. *Neurosurg Focus* 23, 4, E6, ISSN 1092-0684.
- Deinsberger, R. & Tidstrand, J. (2005). Linac radiosurgery as a tool in neurosurgery. *Neurosurg Rev*, 28, 2, pp. 79-88, ISSN 0344-5607.
- Diluna, ML. & Bulsara, KR. (2010). Surgery for petroclival meningiomas: a comprehensive review of outcomes in the skull base surgery era. *Skull Base*, 20, 5, pp. 337-342, ISSN 1531-5010.
- Dowd, CF.; Halbach, VV. & Higashida RT. (2003). Meningiomas: the role of preoperative angiography and embolization. *Neurosurg Focus*, 15, 1, E10, ISSN 1092-0684.
- Fischer, BR.; Palkovic, S.; Holling, M.; Niederstadt, T.; Jeibmann, A. & Wassmann, H. (2009). Coexistence of cerebral aneurysm and meningioma--pure accident? *Clin Neurol Neurosurg*, 111, 8, pp. 647-654, ISSN 0303-8467.
- Honig, S.; Trantakis, C.; Frerich, B.; Sterker, I.; Kortmann, RD. & Meixensberger, J. (2010). Meningiomas involving the sphenoid wing outcome after microsurgical treatment-a clinical review of 73 cases. *Cen Eur Neurosurg*, 71, 4, pp. 189-98, ISSN 18684912.




- Joung, H & Lee, BS. (2008). The novel “class” algorithmic scale for patient selection in meningioma surgery. In: Lee JH (ed) *Meningiomas: diagnosis, treatment, and outcome*. Springer, Berlin
- Kandenwein, JA.; Richter, HP. & Antoniadis, G. (2009). Foramen magnum meningiomas--experience with the posterior suboccipital approach. *Br J Neurosurg*, 23, 1, pp. 33-39, ISSN 0268-8697.
- Kane, AJ.; Sughrue, ME.; Rutkowski, MJ.; Shangari, G.; Fang, S.; McDermott, MW.; Berger, MS. & Parsa, AT. (2011). Anatomic location is a risk factor for atypical and malignant meningiomas. *Cancer*, 117, 6, pp.1272-1278, ISSN 1097-0142.
- Lieu, AS. & Howng, SL. (2000). Intracranial meningiomas and epilepsy: incidence, prognosis and influencing factors. *Epilepsy Res* 38, 1, pp. 45-52, , ISSN 0920-1211.
- Louis, DN.; Ohgaki, H.; Wiestler, OD.; Cavenee, WK.; Burger, PC.; Jouvett, A.; Scheithauer, BW. & Kleihues, P. (2007), The 2007 WHO classification of tumours of the central nervous system. *Acta Neuropathol*, 114, 5, pp. 97-109, ISSN 0001-6322.
- Mahmoud, M.; Nader, R. & Al-Mefty O. (2010). Optic canal involvement in tuberculum sellae meningiomas: influence on approach, recurrence, and visual recovery. *Neurosurgery* 67, 3 Suppl, pp. 108-118, ISSN 0148-396X.
- Mendenhall, WM.; Friedmann, WA.; Amdur, RJ. & Foote, KD. (2004). Management of benign skull base meningiomas: a review. *Skull Base*, 14, 1, pp. 53-60, ISSN: 1531-5010.
- Michaud, DS.; Gallo, V.; Schlehofer, B.; Tjønneland, A.; Olsen, A.; Overvad, K.; Dahm, CC.; Kaaks, R.; Lukanova, A.; Boeing, H.; Schütze, M.; Trichopoulou, A.; Bamia, C.; Kyrozi, A.; Sacerdote, C.; Agnoli, C.; Palli, D.; Tumino, R.; Mattiello, A.; Buenode-Mesquita, HB.; Ros, MM.; Peeters, PHM.; van Gils, CH.; Lund, E.; Bakken, K.; Gram, IT.; Barricarte, A.; Navarro, C.; Dorronsoro, M.; Sánchez, MJ.; Rodríguez, L.; Duell, EJ.; Hallmans, G.; Melin, BS.; Manjer, J.; Borgquist, S.; Khaw, KT.; Wareham, N.; Allen, NE.; Tsilidis, KK.; Romieu, I.; Rinaldi, S.; Vineis, P. & Riboli, E. (2010). Reproductive factors and exogenous hormone use in relation to risk of glioma and meningioma in a large European cohort study. *Cancer Epidemiol Biomarkers Prev*, 19, 10, pp. 2562-2569, ISSN 1055-9965.
- Minniti, G.; Amichetti, M. & Enrici, RM. (2009). Radiotherapy and radiosurgery for benign skull base meningiomas. *Radiat Oncol* 14, 4, 42, ISSN 1748-717X.
- Nakamura, M.; Roser, F.; Struck, M.; Vorkapic, P. & Samii, M. (2006). Tuberculum sellae meningiomas: clinical outcome considering different surgical approaches. *Neurosurgery*, 59, 5, pp. 1019-1028, ISSN 0148-396X.
- Nakamura, M.; Struck, M.; Roser, F.; Vorkapic, P. & Samii, M. (2008). Olfactory groove meningiomas: clinical outcome and recurrence rates after tumour removal through the frontolateral and bifrontal approach. *Neurosurgery*, 62, 6 Suppl 3, pp.1224-1232, ISSN 0148-396X.
- Newton, HB. (2007). Hydroxyurea chemotherapy in the treatment of meningiomas. *Neurosurg Focus*, 23, 4, E11, ISSN 1092-0684.
- Norden, AD. Drappatz, J. & Wen, PY. (2009). Advances in meningioma therapy. *Curr Neurol Neurosci Rep*, 9, 3, pp. 231-240, ISSN 1528-4042.

- Rachinger, W.; Grau, S. & Tonn JC. (2010). Different microsurgical approaches to meningiomas of the anterior cranial base. *Acta Neurochir*, 152, 6, 931-9, ISSN 0001-6268.
- Rockhill, J.; Mrugala, M. & Chamberlain, MC. (2007). Intracranial meningiomas: an overview of diagnosis and treatment. *Neurosurg Focus*, 23, 4, E1, ISSN 1092-0684.
- Samii, M. & Gerganov, VM. (2008). Surgery of extra-axial tumors of the cerebral base. *Neurosurgery*, 62, 6 Suppl 3, pp. 1153-1166, ISSN 0148-396X.
- Schulz, C.; Mathieu, R.; Kunz, U. & Mauer, UM. (2011). Treatment of unresectable skull base meningiomas with somatostatin analogs. *Neurosurg Focus*, 30, 5, E11, ISSN 1092-0684.
- Seckin, H.; Avci, E.; Uluc, K.; Niemann, D. & Baskaya, MK.(2008). The work horse of skull base surgery: orbitozygomatic approach. Technique, modifications, and applications. *Neurosurg Focus*, 25, 4,E4, ISSN 1092-0684.
- Seifert, V. (2010). Clinical management of petroclival meningiomas and the eternal quest for preservation of quality of life. *Acta Neurochir*, 152; 7, pp. 1099-1116, ISSN 0001-6268.
- Simpson, D. (1957). The recurrence of intracranial meningiomas after surgical treatment. *J Neurol Neurosurg Psychiat*, 20, 1, pp. 22–39, ISSN 0022-3050.
- Spektor, S.; Valarezo, J.; Fliss, DM.; Gil, Z.; Cohen, J.; Goldman, J. & Umansky, F. (2005). Olfactory groove meningiomas from neurosurgical and ear, nose, and throat perspectives: approaches, techniques, and outcomes. *Neurosurgery*, 57, 4 Suppl, pp. 268-280, ISSN 0148-396X.
- Sughrue, ME.; Rutkowski, MJ.; Shangari, G.; Chang, HQ.; Parsa, AT.; Berger, MS. & McDermott, MW. (2011) Risk factors for the development of serious medical complications after resection of meningiomas. *J Neurosurg*, 114, 3, pp. 697-704, ISSN 0022-3085.
- Topsakal, C.; Al-Mefty, O.; Bulsara, KR. & Williford, VS. (2008). Intraoperative monitoring of lower cranial nerves in skull base surgery: technical report and review of 123 monitored cases. *Neurosurg Rev*, 31, 1, pp. 45-53, ISSN 0344-5607.
- Van Breemen, MS.; Wilms, EB. & Vecht, CJ. (2007). Epilepsy in patients with brain tumours: epidemiology, mechanisms, and management. *Lancet Neurol*, 6, 5, pp. 421-430, ISSN 1474-4422.
- Wang, Q.; Lu, XJ.; Ji, WY.; Yan, ZC.; Ding, YS. & Zhang, J. (2010). Visual outcome after extended endoscopic endonasal transsphenoidal surgery for tuberculum sellae meningiomas. *World Neurosurg*, 73, 6, 694-700, ISSN 1878-8750.
- Wen, PY.; Quant, E.; Drappatz, J.; Beroukhir, R. & Norden AD. (2010). Medical therapies for meningiomas. *J Neurooncol*, 99, 3, pp. 356-378, ISSN 0167-594X
- Whittle, IR.; Smith, C.; Navoo, P. & Collie, D. (2004). Meningiomas. *Lancet*, 363, 9420, 1535-1543, ISSN 0140-6736.
- Wiemels, J.; Wrensch, M. & Claus, EB. (2010). Epidemiology and etiology of meningioma. *J Neurooncol*, 99, 3, pp. 307-314, ISSN 0167-594X.

- Wu, Z.; Hao, S.; Zhang, J.; Zhang, L.; Jia, G.; Tang, J.; Xiao, X.; Wang, L. & Wang, Z. (2009). Foramen magnum meningiomas: experiences in 114 patients at a single institute over 15 years. *Surg Neurol*, 72, , pp. 376-382 ISSN 1879-3339.
- Yasargil, G. (1980). Meningiomas of the basal posterior cranial fossa. *Adv Tech Stand Neurosurg*, 7, pp. 1-115, ISSN 0095-4829.

IntechOpen

IntechOpen



## **Meningiomas - Management and Surgery**

Edited by Dr. Daniel Monleon

ISBN 978-953-51-0175-8

Hard cover, 136 pages

**Publisher** InTech

**Published online** 02, March, 2012

**Published in print edition** March, 2012

This book is aimed at neurosurgeons with an interest in updating their knowledge on the latest state of meningiomas surgery and management. The book is focused at performing a portrait of that what is state of the art in management of meningiomas. All the chapters have been developed with high quality and including the most modern approaches for the different aspects they deal with. The book concentrates on those problems that, although perhaps less common in the day to day routine of the average neurosurgeon, when present pose a special challenge. This is neither a "how to" book nor a book about meningioma biology. It presents some of the most relevant aspects in the latest developments for meningioma surgery and management in a clear and professional manner.

### **How to reference**

In order to correctly reference this scholarly work, feel free to copy and paste the following:

Bernhard R. Fischer and Benjamin Brokinkel (2012). Surgical Management of Skull Base Meningiomas – An Overview, Meningiomas - Management and Surgery, Dr. Daniel Monleon (Ed.), ISBN: 978-953-51-0175-8, InTech, Available from: <http://www.intechopen.com/books/meningiomas-management-and-surgery/surgical-management-of-skull-base-meningiomas-an-overview->

**INTech**  
open science | open minds

### **InTech Europe**

University Campus STeP Ri  
Slavka Krautzeka 83/A  
51000 Rijeka, Croatia  
Phone: +385 (51) 770 447  
Fax: +385 (51) 686 166  
[www.intechopen.com](http://www.intechopen.com)

### **InTech China**

Unit 405, Office Block, Hotel Equatorial Shanghai  
No.65, Yan An Road (West), Shanghai, 200040, China  
中国上海市延安西路65号上海国际贵都大饭店办公楼405单元  
Phone: +86-21-62489820  
Fax: +86-21-62489821



© 2012 The Author(s). Licensee IntechOpen. This is an open access article distributed under the terms of the [Creative Commons Attribution 3.0 License](https://creativecommons.org/licenses/by/3.0/), which permits unrestricted use, distribution, and reproduction in any medium, provided the original work is properly cited.

IntechOpen

IntechOpen