

We are IntechOpen, the world's leading publisher of Open Access books Built by scientists, for scientists

6,900

Open access books available

186,000

International authors and editors

200M

Downloads

Our authors are among the

154

Countries delivered to

TOP 1%

most cited scientists

12.2%

Contributors from top 500 universities



WEB OF SCIENCE™

Selection of our books indexed in the Book Citation Index
in Web of Science™ Core Collection (BKCI)

Interested in publishing with us?
Contact book.department@intechopen.com

Numbers displayed above are based on latest data collected.
For more information visit www.intechopen.com



Decreased Cerebral Perfusion in Carotid Artery Stenosis, Carotid Angioplasty and Its Effects on Cerebral Circulation

Antenor Tavares and José Guilherme Caldas
*Universidade de São Paulo; São Paulo,
 Brazil*

1. Introduction

Cervical carotid artery stenosis frequently causes ischemia by embolic phenomena, but stenosis can also induce ischemia via a reduction in blood flow. Cerebral perfusion failure can be caused by reductions in blood flow arising from a stenosis or an occlusive vascular lesion (Bokkers et al., 2008; Wilkinson et al., 2003).

Two major mechanisms are involved in cerebral ischemia (Mohr et al., 1997). Cerebral perfusion failure may occur as the result of flow reduction mediated by stenosis or occlusive vascular damage such as that arising from atheroma plaques that affect the carotid bulb. Perfusion failure affects the distal territories, and it is known as a watershed infarction. The second mechanism of cerebral ischemia is artery-to-artery embolism, which is considered to be the main cause of ischemia associated with plaques in the larger arteries. There are thrombosis in situ and embolic infarctions associated with these plaques, which usually involve the occlusion of intracranial distal vessels.

Ischemia is the physiological term indicating a blood flow that is insufficient for the normal functioning of cells, whereas infarction is the pathological term denoting permanent tissue damage caused by ischemia (Jensen et al., 2005). Classically, atherosclerotic infarctions, particularly those in major arteries, are caused by the formation of thrombosis at the atheroma plaque site or from an embolism that originates from the same plaque. The most common location of plaques in the cerebrovascular circulation is at the carotid bifurcation involving the distal common carotid artery and the first 2 cm of the internal carotid artery.

Treatment options for atherosclerotic carotid artery stenosis include drug therapy and surgical treatment (Mas et al., 2006; NASCET, 1991; Ringleb et al., 2006; Yadav et al., 2004). Clinical treatment includes antiplatelet aggregation agents and statins, along with the control of risk factors such as arterial hypertension, dyslipidemia, hyperglycemia and tobacco use (Bates et al., 2007). Two relevant studies comparing clinical and surgical treatments showed a significant reduction of cerebral infarction risk in the group of patients selected for surgical intervention. In the NASCET (North American Symptomatic Carotid Endarterectomy Trial) study, the stroke risk was significantly reduced by surgery (9% in the surgical group versus 26% in the clinical treatment group) (NASCET, 1991). In another

classic trial with asymptomatic patients, the prognosis also improved with surgical treatment (4.8% versus 10.6% with drug treatment) (ACAS Trial investigators, 1995).

Endovascular surgical treatment consists of carotid angioplasty and stenting (CAS), a procedure in which the stenosis is approached through a natural passage inside the vessels themselves. In this technique, a flexible guidewire and catheter are inserted into the arterial system through a peripheral puncture site. The guidewire and catheter are then directed to the site of the stenosis, where the stent and the balloon open the narrowing.

CAS was designed as a less invasive method to treat carotid artery stenosis, and the Carotid Revascularization Endarterectomy Versus Stenting Trial (CREST) showed that angioplasty was as effective as endarterectomy for the prevention of stroke (Bates et al., 2007; Caldas, 2006; Chaturvedi & Yadav, 2006; Gurm et al., 2008; Menon & Stafinski, 2006). CAS is also advantageous because it most often uses a local anesthetic, maintains a constant blood flow to the brain and allows an earlier hospital discharge (Menon & Stafinski, 2006).

Initially, the “status” of cerebral perfusion in patients with carotid artery stenosis, or the changes that occur after angioplasty, was not well known. Research suggesting that the modification of cerebral blood flow following angioplasty possibly induces cerebral reperfusion syndrome (Fukuda et al., 2007) is relatively recent. The course of other diseases can be potentially altered after carotid angioplasty.

Recent publications show cognitive dysfunction in some patients with carotid artery stenosis (Takaiwa et al., 2009; Takaiwa et al., 2006; Turk et al., 2008). Takaiwa et al. observed cognitive improvement in elderly patients after CAS (Takaiwa et al., 2009).

2. Cerebral ischemia and carotid artery stenosis

Carotid artery stenosis is present in 7% of men and 5% of women aged 65 years or older (O'Leary et al., 1992). Severe carotid artery stenosis is a leading cause of cerebral infarction and transitory ischemic attack. The estimated risk of ipsilateral carotid artery infarction in a 5-year period is 4% in the population without carotid artery stenosis, 18% in asymptomatic patients with stenosis of over 75% and 27% in symptomatic patients with stenosis of over 75% (Inzitari et al., 2000).

3. Poor cerebral perfusion in carotid artery stenosis

Cerebral infarction resulting from hypotension, which is the result of cerebral blood flow that is insufficient to comply with metabolic demands, represents about 0.7 to 3.2% of cerebral infarctions. The terms “border-zone” and “watershed” are used synonymously to describe this condition in everyday clinical practice. The appearance of these infarcts varies but can include wedge-shaped lesions with their base on the surface of the cortex, exhibiting a border-zone irrigation topography. There may be a string-of-pearls presentation of the infarcts where there are three or more lesions in the deep white matter within the centrum semiovale, with a linear orientation parallel to the lateral ventricle. These ischemic lesions are identified on magnetic resonance imaging (MRI) studies (Ogata et al., 2005) and on CT scan (Del Sette et al., 2010). This appearance can be unilateral when there is ipsilateral carotid artery stenosis or bilateral when there is a severe and global hemodynamic event or bilateral arterial stenosis (Hamilton, 2005). Regarding pathology, infarctions arising from

hypotension occur in border zones and result in encephalomalacia and ulegyria (Hamilton, 2005).

The etiology of infarctions in watershed areas is varied and includes global cerebral injury resulting from perfusion or oxygenation disorders such as prolonged severe hypotension, cardiac arrest with resuscitation, asphyxia and carbon monoxide inhalation. Carotid artery stenosis or occlusion is another etiology that predisposes subjects to border-zone infarctions during episodes of hemodynamic compromise, often with rosary-like patterns. Carotid artery disease infarctions can occur in the cortical and watershed areas as well (Krogias et al., 2010; Momjian-Mayor & Baron, 2005). Although embolisms can occur in the border zones, they are difficult to identify with precision by imaging (Hamilton, 2005; Marks, 2002; Yamada et al., 2010).

In addition to Perfusion-Weighted Imaging (PWI) by MRI, brain perfusion can be evaluated by several techniques including parenchymography, perfusion by helicoidal tomography, perfusion by multislice tomography, transcranial Doppler, intracarotid xenon injection and MRI volume flow quantification analysis. Transcranial doppler studies have the advantage of being non-invasive, but the technique is usually limited to an analysis of a single vessel, usually the middle cerebral artery ipsilateral to the carotid artery stenosis. Doppler studies can also be impaired by cardiac arrhythmias, which make the recorded velocity on the spectral trace unreliable (Kleiser & Widder, 1992; Niesen et al., 2004). Perfusion by tomography has attained a level of technical refinement; however, its application is still restricted to small slices or only one slice per examination (Jongen et al., 2010; Roberts et al., 2000; Waaijer et al., 2007). Evaluation by intracarotid xenon has been limited to research (Bando et al., 2001).

3.1 Digital subtraction angiography

Parenchymography, as described by Theron et al., is an innovative and simple method to evaluate cerebral perfusion. The research on parenchymography included an analysis by angiography with modified windowing to allow the preferential study of the brain blood supply (Theron et al., 1996). Angiography has the capacity to directly assess the degree of carotid artery stenosis and, with the addition of parenchymography, the hemodynamic effects between the brain and its blood supply (Theron et al., 1996).

During the angiographic study of many of our patients, we observed (Figure 1 A) a poor opacification of the anterior and middle cerebral arteries when ipsilateral severe cervical carotid artery stenosis was present.

3.2 Cerebral perfusion by MRI (PWI)

Although perfusion evaluation by MRI is semi-quantitative, its advantages are that MRI is a non-invasive method of evaluating cerebral blood flow that is available in most large centers, avoids ionizing radiation and retains good spatial resolution and good correlation with SPECT (Single-photon emission computed tomography) (Bokkers et al., 2008; Martin, A. J. et al., 2005; Rasmussen et al., 2010; Rohl et al., 2001; Tavares et al., 2010; Van Laar et al., 2007).

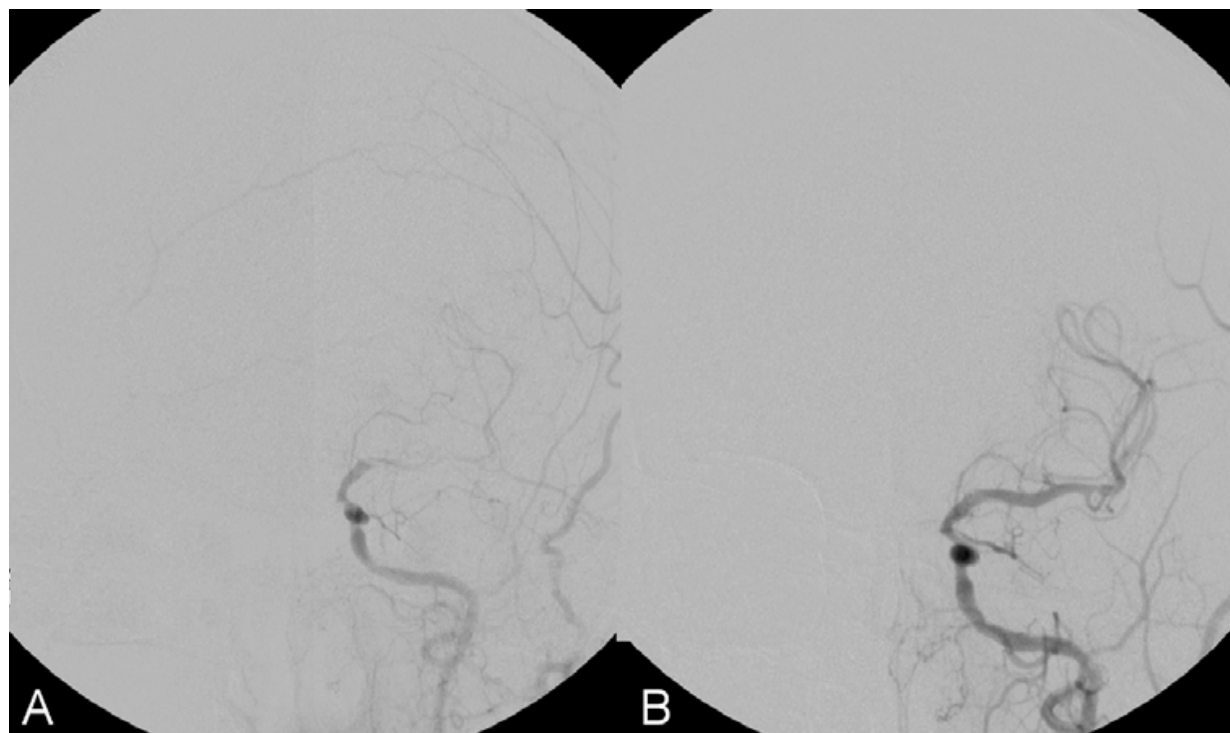


Fig. 1. A 61-year-old patient with severe left cervical carotid artery stenosis. Angiography of the left carotid artery in PA position before angioplasty with stenting shows the slight opacification of the middle cerebral artery (A). Angiography of the left carotid artery in PA after angioplasty with stenting shows the normal opacification of the left middle cerebral artery (B).

A recent study of PWI by MRI in patients with carotid artery stenosis investigated the relative values of cerebral blood volume (CBV), mean transit time (MTT) and time to peak (TTP). A reduction in the CBV and a time-to-peak delay in the middle cerebral artery territory ipsilateral to the cervical carotid artery stenosis were noted (Tavares et al., 2010). The intracranial blood supply was shown to be compromised by a timing delay (increase in the TTP) of the contrast peak in the territory fed by the middle cerebral artery ipsilateral to the cervical carotid artery stenosis. There was less signal loss (negative wave) in the area analyzed (reduction in CBV), which indicated a lower regional blood volume in the middle cerebral artery territory (Tavares et al., 2010).

The TTP delays in the middle cerebral artery ipsilateral to the cervical stenosis compared with the contralateral territory have also been observed by Gauvrit et al. (2004).

Teng et al. showed that analysis of the TTP is a valuable tool for the assessment of the hemodynamic changes in carotid artery stenosis that correlates well with the mean transit time (MTT) parameter (Teng et al., 2001).

An earlier study of cerebral perfusion in patients with carotid artery stenosis showed MTT prolongation ipsilateral to the carotid artery stenosis and stated that this finding was due to hemodynamic compensation between the cerebral hemispheres (Bozzao et al., 2002).

Even when the perfusion damage is limited, the timing parameters (TTP and MTT) are delayed, but these ischemic alterations are not sufficiently significant to be detected by

diffusion MRI. Delayed perfusion parameters indicate infarction risk, whereas alterations in diffusion indicate an already-established lesion.

4. Modification of the cerebral flow after carotid angioplasty with stenting

4.1 Digital subtraction angiography

The analysis of cerebral perfusion by parenchymography has revealed an improvement in cerebral hemodynamic flow achieved by carotid angioplasty (Theron 1996). We observed restored intradural artery opacification (Figure 1 B) and a significant improvement in parenchymography results following CAS.

4.2 PWI

Several authors observed cerebral blood flow modifications after angioplasty (Bozzao et al., 2002; Martin, A. J. et al., 2005; Van Laar et al., 2007; van Laar et al., 2006)

A recent publication by our team that assessed patients with carotid artery stenosis used PWI by MRI to show that there was a discrete increase in rCBV ($p=0.940$) and important reductions in dMTT ($p<0.001$) resulting from the reduction in MTT at the site of the angioplasty.

However, during the evaluation before CAS, we observed a delay in the TTP in the middle cerebral artery (MCA) territory ipsilateral to the carotid stenosis when compared to the contralateral artery. After CAS, there was a remarkable reduction in dTTP ($p=0.019$) and the TTP was earlier at the site of the stent than in the contralateral territory (Tavares et al., 2010).

Timing parameters such as the MTT proved to be the most sensitive and the most reproducible in measuring cerebral hemodynamic alterations (Soinne et al., 2003; Waaijer et al., 2007; Wintermark et al., 2006).

The variations in relative CBV, MTT and TTP are illustrated in Figure 2, where patient improvement is shown through the imaging parameters of PWI by MRI after CAS (Figure 2).

Laar et al. found an increase in cerebral blood flow (CBF) on the side of carotid stenosis, after treatment of the stenosis with CAS or EAC; this increased rate of CBF became similar value to the CBF of the control group (Van Laar et al., 2007).

In our study, we observed an increase in CBV in the cerebral territory ipsilateral to the CAS as well as in the contralateral territory (Tavares et al., 2010). Other authors have documented this same phenomenon in the intracranial territory on the healthy side (Hino et al., 2005; Ko et al., 2005). The treatment of the carotid artery stenosis cannot explain this phenomenon based solely on hemodynamics (Ko et al., 2005). Other unknown factors must play an important role in the perfusion modifications before and after the treatment of carotid artery stenosis. This increased flow in the contralateral hemisphere may occur via collateral circulation through the anterior communicating artery (Tavares et al., 2010) or from the leptomeningeal anastomosis (Matsubara et al., 2009).

Thus, the benefits and eventual risks resulting from an increase in cerebral blood flow may occur in both the ipsilateral and contralateral hemispheres during the treatment of carotid artery stenosis.

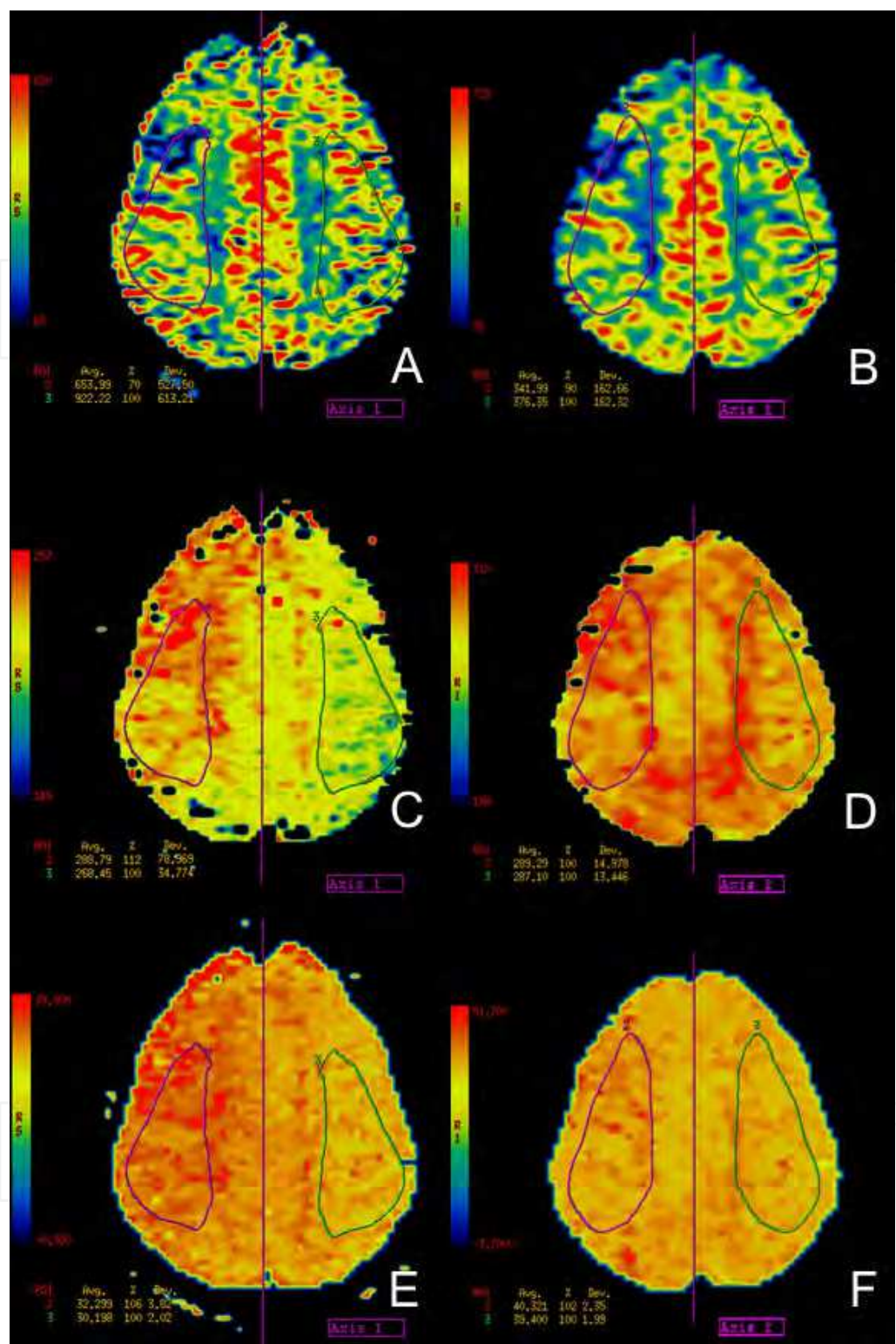


Fig. 2. A 56-year-old patient with severe right cervical carotid artery stenosis evaluated by digital angiography (not shown). Perfusion by MRI was performed in a section above the lateral ventricles. Before carotid angioplasty, the cerebral blood volume (CBV) of the right ACM territory was reduced by 30% compared with the contralateral (A), the mean transit time (MTT) was delayed by 12% (C) and the time to peak (TTP) was delayed by 6% (E). In the same axial plane after CAS, perfusion studies show improved parameters: the right side CBV

became less reduced (10%) compared with the contralateral (**B**), there was no difference in the MTT compared with the left side (**D**) and the TTP delay was lessened to 2% (**F**).

The improvement in cerebral perfusion after CAS, as documented by imaging technologies (Ko et al., 2005; Martin, A. J. et al., 2005; Tavares et al., 2010; Van Laar et al., 2007), has also been documented through questionnaires for dementia that show clinical improvement in scores after CAS (Moftakhar et al., 2005; Takaiwa et al., 2009; Turk et al., 2008).

According to Takaiwa, patients with carotid artery stenosis who scored below average on the questionnaire prior to carotid angioplasty and endarterectomy showed an improvement in cognitive function after the procedures (Takaiwa et al., 2009). Scores were decreased temporarily at 1 week after carotid endarterectomy (CEA), but not after CAS (Takaiwa et al., 2009).

Moftakhar concluded that the improvement in the perfusion parameters shown by MRI is predictive of cognitive improvement after angioplasty (Moftakhar et al., 2005).

These data together suggest that CAS not only prevents stroke but also improves cognitive function (Takaiwa et al., 2009).

In addition to carotid angioplasty, intracranial angioplasty is also associated with perfusion improvement as shown by MRI (Bendok et al., 2010).

According to Takaiwa, rapid improvement in cognitive function occurs following CAS (Takaiwa et al., 2009). Some studies, however, showed a worsening of cognitive function following CEA, which may be associated with hypoperfusion during the cross-clamping of the internal carotid artery (Costin et al., 2002; Heyer et al., 1998; Takaiwa et al., 2009).

Endarterectomy may interrupt the cerebral blood flow at several moments during the procedure, and it certainly does so during the construction of the bypass. However, the treatment of carotid artery stenosis by CAS with cerebral protection filters does not interrupt the cerebral blood flow, which avoids momentary deficits in cerebral perfusion.

Complex self-regulatory mechanisms may be set in motion by severe stenosis and may include microcirculatory vasodilatation or a direct response from the central nervous system. Therefore, it is theoretically possible that the microcirculatory condition that results from long-standing severe proximal stenosis might excite a state of microcirculatory vasodilatation after CAS, causing some blood volume reduction in the ipsilateral territory. This tends to occur during a reduction in the MTT. The equation $CBF = CBV / MTT$ expresses the flow equilibrium (Kluytmans et al., 1998).

5. The risks of the immediate increase in cerebral perfusion following carotid angioplasty

5.1.1 Reperfusion syndrome

Because CAS induces changes in cerebral perfusion, it has the inherent although low risk of complications related to increased cerebral blood flow such as reperfusion syndrome (Matsubara et al., 2009; Morrish et al., 2000; Tavares et al., 2010) and even fatal hemorrhagic complications (Hartmann et al., 2004; Morrish et al., 2000). Patients who receive endarterectomies are exposed to similar risks (Bodenant et al., 2010).

Signal alteration, especially as seen with FLAIR sequence imaging, has been reported and is located in the spaces of the cortical convolutions that occur unilaterally after CAS. This finding may be related to modifications in perfusion that are clinically difficult to correlate (Martin, A. J. et al., 2005; Michel et al., 2001; Wilkinson et al., 2003).

Through MRI studies before and after conventional angioplasty with stenting, we observed hypersignal areas in the subarachnoid space of some of our patients in the FLAIR sequence after CAS. These areas showed gadolinium enhancement in the T1-weighted sequence and did not show signs of ischemia or neurological symptoms upon diffusion (Figure 3).

Wilkinson et al. called this finding “unilateral leptomeningeal enhancement” (Wilkinson et al., 2003). Although they stated that there was no definite cause, it is possible that there is an increase in flow to the territory of the MCA ipsilateral to the stent, and this greater flow might contribute to the leptomeningeal enhancement, especially because the enhancement occurred in the areas fed by the MCA that experienced transit time reductions (Wilkinson et al., 2003). Martin et al. showed similar images ipsilateral to the CAS in the liquor space of the ipsilateral cerebral sulcus in the watershed area (Martin, A. J. et al., 2005).

This asymmetric appearance is not fully understood and may be related to factors such as the leakage of the contrast agent or the possible alteration of the partial pressure of oxygen following treatment (Braga et al., 2003; Michel et al., 2001).

Patients who showed a signal increase on FLAIR in the subarachnoid space ipsilateral to the CAS experienced isolated symptoms (headache, transitory neurological deficit or mental confusion) in the series of Grunwald et al. (2009). These authors also reported that the signal increase on FLAIR is temporary and disappears within 3 to 5 days.

Thurley et al. (2009) described a similar unilateral leptomeningeal enhancement in a patient exhibiting headache, vomiting, seizure and hypertension after endarterectomy.

We believe that the finding described by Grunwald et al. (2009) and Thurley et al. (2009) may be related to a clinical syndrome of hyperperfusion that is not complicated by intracranial hemorrhage. Our patients with leptomeningeal enhancement after CAS (Figure 3) did not exhibit the classical symptoms of cerebral hyperperfusion, such as transitory focal deficit, unilateral migraine and seizures.

Nevertheless, we believe that areas with chronic ischemia have increased perfusion after CAS and that there is some degree of poor hematoencephalic barrier regulation. This notion is grounded on the pattern of dural/sulcal enhancement in border zones.

However, because of the reduction in the timing parameters of perfusion following CAS (Tavares et al., 2010) without a reduction in CBV, cerebral hyperflow with possible complications such as hyperperfusion syndrome can theoretically exist (Ko et al., 2005; Niesen et al., 2004; Wilkinson et al., 2003). This concept follows the equation of hemodynamic equilibrium, where cerebral blood flow is proportional to CBV and inversely proportional to the timing parameter MTT (Kluytmans et al., 1998; Waaijer et al., 2007; Wilkinson et al., 2003).

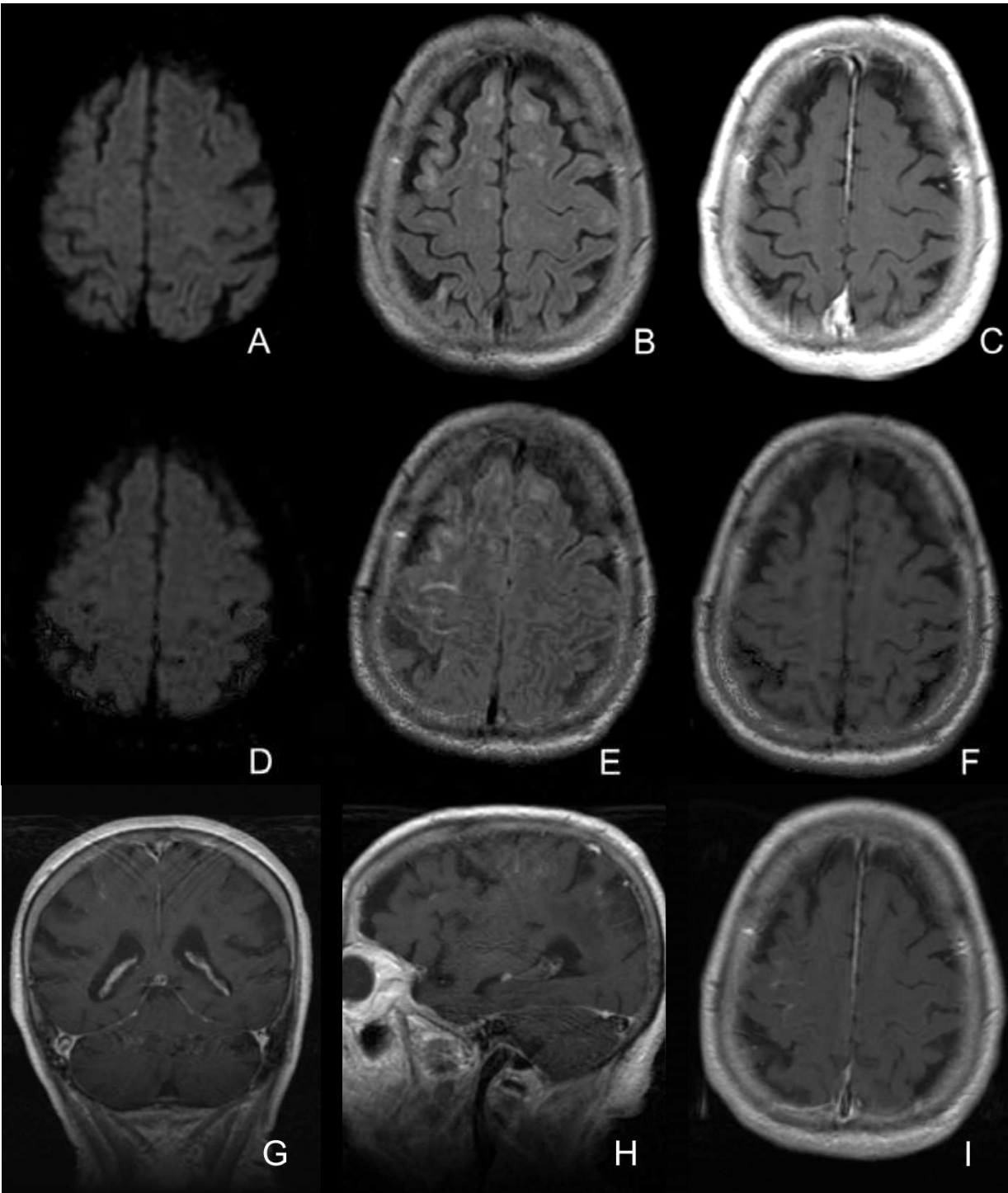


Fig. 3. An 87-year-old patient with right carotid artery stenosis. MRI in diffusion sequence before CAS: DWI (A), FLAIR (B) and T1 with gadolinium (C). Conventional angioplasty of the carotid artery was performed (not shown), and the patient was asymptomatic after endovascular treatment. A new MRI study was performed 12 hours after CAS (D,E,F,G,H,I): note the hypersignal in the central and precentral sulcus of the FLAIR sequence (E) without expression in DWI (D) or T1 without gadolinium (F). T1 sequences with coronal (G), sagittal (H) and axial (I) contrast after CAS: enhancement in the sulcal (pial) space in the right posterior frontal area.

5.1.2 Carotid stenting without postdilatation

Some authors hold that cerebral circulation is somehow altered when there is severe carotid artery stenosis by a “plegic vasodilatation” induced by chronic ischemia (Abou-Chebl et al., 2004; Hartmann et al., 2004; Matsubara et al., 2009).

The study of CBF by intracarotid xenon injection or photon emission tomography showed that patients with a two-fold increase in CBF after endarterectomy were at a greater risk of developing hyperperfusion syndrome (Bando et al., 2001; Henderson et al., 2001).

According to Hirooka et al. (2008), cerebral hyperperfusion after CEA is defined as a 100% increase in CBF in PWI by MRI.

Hosoda et al. based on SPECT data obtained before and after CEA, noted that the abrupt restoration of cerebral perfusion pressure immediately after the surgical correction of a tight carotid stenosis could not be quickly compensated for by vasoconstriction (Hosoda et al., 2001). However, the arterioles presumably contracted to normal size over the long term, thus reducing the CBV.

Matsubara et al. (2009) postulated that after the treatment of carotid stenosis, if the vascular walls of the arterioles were damaged and permeability increased, cerebral edema and convulsions could occur.

Furthermore, rapidly increased CBF and CBV (Matsubara et al., 2009) and a reduction in MTT by CAS (Tavares et al., 2010) and CEA may be risk factors for reperfusion syndrome after the treatment of carotid stenosis (Fukuda et al., 2007).

The technique of CAS has not been standardized, and there are technical variations among different institutions and neurointerventionists. The CAS technique that we call conventional has already been described in the literature (Caldas, 2006; Tavares et al., 2010). Briefly, the procedure is performed in an angiography suite and includes transfemoral access under local anesthesia, sedation and full heparinization (70 U/kg). All patients receive double anti-aggregation agents 5 days before CAS. The activated coagulation time (ACT) is not routinely checked. We initially establish access up to the common carotid artery with a 6F wired sheath or 8F guiding catheter. Next, a cerebral protection system is delicately placed in the internal carotid artery distal to the stenosis. We usually use filter protection because it affords intraprocedural safety against emboli without flow interruption. Most often, the protection filter is advanced without predilatation. Balloon dilatation before stenting is only employed when the filter or the stent cannot pass by the stenosis. Next, a self-expandable stent is advanced over the filter guide and released so as to cover the atheroma plaque. At this point, the stent is able to perform the partial or the subtotal opening of most stenoses and to reduce the friction of the blood flow against the plaque. Thus, the stent protects against emboli. The next step is to utilize balloon angioplasty within the stent to mold and widen the internal diameter of the stent or to continue to reduce the size of the residual stenosis to less than 30%.

Despite the lack of clear standards, we believe that the consensus is to achieve a post-stenting stenosis of less than 30%. The CREST study, which compared CAS and endarterectomy, required a final stenosis of less than 30% at the end of each procedure.

The CAS variation that we employ is a simplification of the technique described above, and it does not employ any pre-stenting or post-stenting balloons. By not fully opening the stent at the procedure, we seek to avoid the instantaneous increase of carotid flux that occurs during conventional angioplasty.

Because carotid angioplasty is most often indicated to avoid atheroembolic ischemic events rather than to correct hemodynamic effects, there is no need for complete stent expansion immediately during angioplasty (Bussiere et al., 2008). The restoration of a normal lumen diameter should be considered a secondary goal.

To avoid an abrupt increase in cerebral perfusion as well as the risks of reperfusion syndrome with its serious complications, we started a case series in which the release of the self-expandable stent was performed without the use of the balloon to completely open the stent (Figure 4). In this group, intra-stent angioplasty (post-dilatation balloon) was used only when the residual stenosis post-stenting did not change compared with the degree of stenosis before the stent placement; intra-stent angioplasty was also used when the residual stenosis was greater than 30%. The force of a self-expanding stent alone can dilate severely stenosed carotid (Lownie et al., 2005), and as the dilation is gradual, it may function protectively against hemorrhagic reperfusion (Maynar et al., 2007).

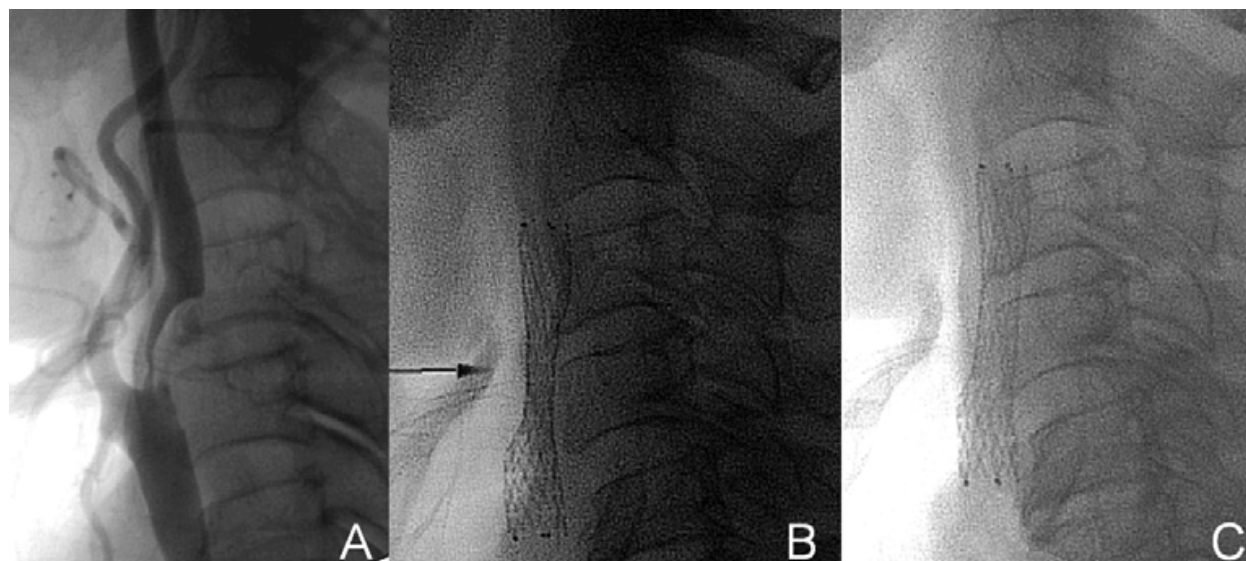


Fig. 4. A 78-year-old patient with severe aortic valve insufficiency and chronic obstructive pulmonary disease who exhibited an episode of amaurosis fugax of the right eye. Angiography showed severe (80%) right internal carotid artery stenosis (A). A 7 X 40 mm self-expandable stent (arrow) (Protégé®, eV3 Inc., Plymouth, Minnesota, USA) for stenting without balloon angioplasty; the immediate result after placement of the stent showed a small residual stenosis of about 30% (b). Lateral radiography 1 month later (C) showed complete expansion of the stent.

In a manner similar to that employed by Baldi et al. (2011), our group followed patients after the placement of the self-expandable stent with cervical radiographic studies at 3, 6 and 12 months. These studies showed a tendency for the stents to completely open. Baldi et al. showed an average reduction of stenosis from 82% to 30% immediately after stenting. In follow-up, however, 14.8% of the patients exhibited restenosis (Baldi et al., 2011).

In the patients who received CAS without balloon inflation, we also noticed the absence of intraprocedural bradycardia and hypotension induced by the compression of the balloon on the carotid baroreceptors. This effect was also observed by Rebellino et al. (Rebellino et al., 2010). This factor may contribute to shorter hospitalizations and increased periprocedural safety.

Each step of an angioplasty procedure includes the risk of thromboembolic events. The procedure with the highest risk of embolism is balloon angioplasty (Martin, J. B. et al., 2001; Men et al., 2002; Vitek et al., 2000). The use of the simplified technique (without balloon dilatation) may reduce such periprocedural risks and improve the clinical results (Jin et al., 2010; Men et al., 2002). The simplified technique may work especially well in cases with soft plaques that can easily rupture and form a large number of emboli.

We consider accentuated calcification, as shown by ultrasound or other imaging methods before angioplasty, to be a relative contraindication for the angioplasty without balloon that we used in our case series.

Other technical variations of CAS have been described in the literature. Maynar et al. (2007) published a series of 100 cases where neither the protection system nor balloon angioplasty was used. They demonstrated an average reduction of stenosis from 79% to 21% immediately after stent release, and in some cases, there was an almost complete opening of the stent. In most cases, however, the stent opening occurred gradually over time with an average final stenosis of 15% at the 6-month radiographic evaluation (Maynar et al., 2007).

Bussière published the results of a series of endovascular treatments of carotid stenosis in which 79% of the patients received a stent-only procedure (Bussiere et al., 2008). The risk of intra-stent restenosis (mostly asymptomatic) was higher than in conventional angioplasty, and residual stenosis below 30% occurred in only 25% of the cases at the end of the procedure. Bussière stated that plaques with circumferential calcification or very severe stenosis (>90%) must be treated with conventional CAS (with postdilatation).

Jin et al. used a 3-to-5-mm balloon after placement of the protection system (Jin et al., 2010). They used predilatation balloons with diameters similar to the luminal caliber of the internal carotid artery distal to the stenosis. After the placement of the stent, the arterial lumen exhibited minimal residual stenosis in about 70% of cases, which indicates that the use of the postdilatation balloon was unnecessary. We find the technique described by Jin et al. (2010) to be inadequate because we believe that the stent has a stabilizing action on the plaque that reduces embolic phenomena. Because the balloon has the potential to induce plaque rupture, it seems contradictory to use the balloon before stenting.

None of the protection systems now in use can perfectly prevent the occurrence of embolism. Emboli have been detected by diffusion MRI when using most of the protection systems described in the literature (Angelini et al., 2002; du Mesnil de Rochemont et al., 2006; Kastrup et al., 2008; Maleux et al., 2006; Muller-Hulsbeck et al., 2003; Schnaudigel et al., 2008; Vos et al., 2005; Yamada et al., 2010).

Indeed, other risk factors for reperfusion syndrome that might be involved include hypertension, severe carotid stenosis (>90%), severe stenosis of the contralateral carotid artery and recent cerebral ischemic or infarction events. The use of anticoagulants and antiplatelet agents may also play a role in this syndrome (Abou-Chebl et al., 2004).

Thus, new studies are required to establish whether or not CAS without postdilatation is a positive factor in clinical results.

5.2.1 The association of carotid stenosis with cerebral aneurysms

Cerebral aneurysms are incidentally found in 5% of adults by autopsy (McCormick & Schochet, 1976). The development of neuroimaging techniques has allowed to increasingly detect unruptured aneurysms *in vivo*. The overall risk of hemorrhage from incidental aneurysms was initially described as 1% per year by the ISUIA study (ISUIA, 1998). The incidence of unruptured, intracranial aneurysms that are present along with carotid artery stenosis is 3 to 5% (Suh et al., 2011). In most cases, this association involves unruptured aneurysms (Navaneethan et al., 2006). Some risk factors, such as hypertension and tobacco use, influence the development of both carotid artery stenosis and cerebral aneurysms (NASCET Trial Investigators, 1991; Wiebers et al., 2003).

Endarterectomy and conventional carotid artery angioplasty can induce an abrupt increase in cerebral perfusion. Additionally, any angioplasty technique that employs antiplatelet agents and heparin makes subsequent use of surgical correction by craniotomy and clipping immediately after CAS impossible. A further complication is that patients with carotid artery stenosis are usually greater than 50 years of age and frequently exhibit hypertension and diabetes, which are complicating factors in craniotomy and clipping according to the results of the ISUIA trial and other studies (Chen et al., 2004; Cowan et al., 2007; Wiebers et al., 2003; Xu et al., 2011).

Some studies have reported on the stability of small unruptured aneurysms after stenting or endarterectomy (Ladowski et al., 1984; Stern et al., 1979; Suh et al., 2011). These studies, however, do not describe with any uniformity the dimensions of the aneurysms (some studies describe aneurysms as large as 4 mm or 7 mm) or the treatments employed to control hypertension and to achieve hemodynamic stability; furthermore, the periods of observation are short. These studies have a relatively small sample size and include only a single center (Kang et al., 2007; Suh et al., 2011). Because only 3 to 5% of the patients have both lesions (Kappelle et al., 2000; Suh et al., 2011), 2,000 to 3,334 cases must be included to reach the statistically significant number of approximately 100 cases in which patients have both carotid artery stenosis and a cerebral aneurysm.

Stern et al. (1979) reported on one case of a fatal rupture of a cerebral aneurysm after EAC. They suggested that the risk of subarachnoid hemorrhage during endarterectomy might be increased in patients with aneurysms (Stern et al., 1979).

The analysis of the NASCET trial data (1991) by Kapelle et al. (2000) identified one case of a fatal subarachnoid hemorrhage that occurred 6 days after endarterectomy among 25 patients, which, according to the authors, increased the risk of rupture to 4% in this population (Kappelle et al., 2000).

Al-Mubarak et al. (2001) reported on the case of one patient with 90% symptomatic right carotid artery stenosis who developed a massive and fatal intracerebral and subarachnoid hemorrhage (arising from the left sylvian fissure) that occurred immediately after CAS. In this case, there was an occlusion of the left carotid artery.

Cheung et al. (2003) reported a case of a fatal subarachnoid hemorrhage after endarterectomy. The patient had two 4-mm ipsilateral intracranial aneurysms. The authors reported, however, that the autopsy failed to identify areas of rupture in these aneurysms.

Hartmann et al. (2004) reported a case of a fatal subarachnoid hemorrhage after the treatment of carotid artery stenosis. Their report did not include the complete angiography of the four main cerebral arteries. However, we believe that CAS increases the cerebral blood flow in the treated territory and in the other intracranial territories via the polygon collateral circulation. Hartmann et al. (2004) further reported that necropsy could not definitively rule out saccular aneurysms.

Riphagen et al. reported a case of one patient with an occlusion of the left carotid artery and symptomatic stenosis of the right carotid artery that was treated with endarterectomy. This patient developed a 6-mm aneurysm in the anterior communicating artery 10 days after endarterectomy with subarachnoid and intraventricular hemorrhage. The patient underwent a craniotomy and clipping (Riphagen & Bernsen, 2009). The annual risk of rupture from incidental aneurysms smaller than 7 mm in the anterior circulation is close to 0% in the ISUIA 2003 study (Wiebers et al., 2003). The case described by Riphagen et al. thus represents a negative shift in the natural course of this type of aneurysm.

Although hypertension is a classic factor that contributes to the rupture of cerebral aneurysms (Obray et al., 2003; Vlak et al., 2011), there is no consensus concerning the effects of CAS on the course of unruptured intracranial aneurysms. However, intracranial hemorrhages are associated with high morbidity and high mortality during the treatment of carotid artery stenosis (Cheung et al., 2003; Hartmann et al., 2004). We therefore conclude that there should be no delay in the treatment of cerebral aneurysms in hypertensive patients during the treatment of carotid stenosis. Theoretically, conditions such as hypertension and increased cerebral blood flow may contribute to the rupture of aneurysms. Other factors inherent to CAS can also worsen the course of hemorrhage, such as the use of antiplatelet agents and the non-reversal of heparin after the CAS.

Badrudin et al. (2010) suggested that intracranial aneurysms might be partially protected by the reduced flow and pressure in the intracranial arteries when there is carotid artery stenosis (Badrudin et al., 2010). Another author suggested that the intentional partial occlusion of the carotid artery might protect cerebral aneurysms, and a reduction of intracranial aneurysms has been observed (Cronqvist et al., 1964)

5.2.2 Minimally invasive treatments for carotid stenosis and cerebral aneurysm

Because of the potential risk for aneurysm rupture after carotid revascularization surgery (endarterectomy or stenting) arising from the increase in cerebral blood flow (Hartmann et al., 2004; Suh et al., 2011) and because there is a minimally invasive and safe technique for endovascular treatment (coiling) of cerebral aneurysms (Cowan et al., 2007; Higashida et al., 2007; Molyneux et al., 2009; Raja et al., 2008; Spelle & Pierot, 2008; van Rooij et al., 2006; van Rooij & Sluzewski, 2006), we believe that patients must be immediately protected by performing embolization (coiling) consecutively after CAS.

In patients for whom carotid artery stenosis is initially diagnosed and further investigation reveals an incidental aneurysm, the treatment of the aneurysm is based upon its rupture

risk, which is calculated by the diameter and localization of the aneurysm and the age of each patient (Wiebers et al., 2003). However, most neuroradiology interventionists believe that aneurysms that are 3 mm or larger must be treated by coiling when it can be safely performed (Fang 2009). The decision to treat aneurysms is also based on the geometry of the lesion (including the neck-dome ratio) and on the availability of experienced specialists in interventionist neuroradiology.

In patients where a cerebral aneurysm was initially diagnosed and further investigation revealed asymptomatic severe carotid stenosis, the ACAS trial showed that treatment of asymptomatic carotid stenosis is beneficial (ACAS Trial investigators, 1995).

We prefer to treat these patients during a single procedure. We treat the carotid artery stenosis before the cerebral aneurysm to avoid the crossing of the stenosis by the endovascular materials that are necessary for the treatment of the aneurysm and that cause the iatrogenic embolism of parts of the cervical plaque (Figure 5). In such patients, we use antiplatelet agents by the oral route (or nasogastric tube) just one hour before angioplasty (clopidogrel 300 mg and aspirin 300 mg). We employ intravenous heparin to maintain an ACT between 200 and 300 seconds.

We perform the angioplasty with a closed-cell stent, since access of catheters to the intracranial carotid seems to us easier. We do not routinely use a post-dilatation balloon (intra-stent before removing the embolic protection device) because we want to limit the increase of the blood flow towards the intracranial territory. However, if the arterial lumen is too small for catheters up to 6F (3 mm) to pass, we perform a stent dilatation with a 4- or 5-mm balloon. After completion of the angioplasty, a 6F guide catheter is placed in the common carotid artery below the stent followed by a microcatheter and micro-guide that are carefully advanced through the stent and into the internal carotid artery distal to the stent. The microcatheter and micro-guide are then advanced up to the aneurysm, and coiling is performed according to the conventional embolization technique. Alternatively, the guide catheter can be carefully advanced over the microcatheter through the stent to the internal carotid distal to the stent. In cases where we employed CAS immediately followed by coiling, the aneurysm was on the same side as the carotid stenosis.

Aneurysms located outside of the circulation subjected to CAS also received increased blood flow after CAS, probably via the Willis polygon (Tavares et al., 2010). Theoretically, then, these aneurysms have an increased risk of rupture and can also be treated by CAS and coiling together.

Navaneethan et al. (2006) reported a case of bilateral carotid stenosis and a 25-mm aneurysm in the left middle cerebral artery. They performed an angioplasty of the left carotid artery and coiling in one single procedure. They believe that craniotomy and clipping of the aneurysm may reduce the cerebral blood flow and thus worsen the eventual hypoflow resulting from the concomitant carotid artery stenosis (Navaneethan et al., 2006).

Iwata et al. reported the case of a patient with 60% asymptomatic stenosis of the left cervical carotid artery with a 6-mm unruptured aneurysm in the ipsilateral intracranial carotid artery. They treated the aneurysm first by coiling, and 1 month later, they performed the CAS (Iwata 2008). A disadvantage of this approach to treatment arises from the potential risks due to the general anesthesia required for the cooling of the patient to reduce the

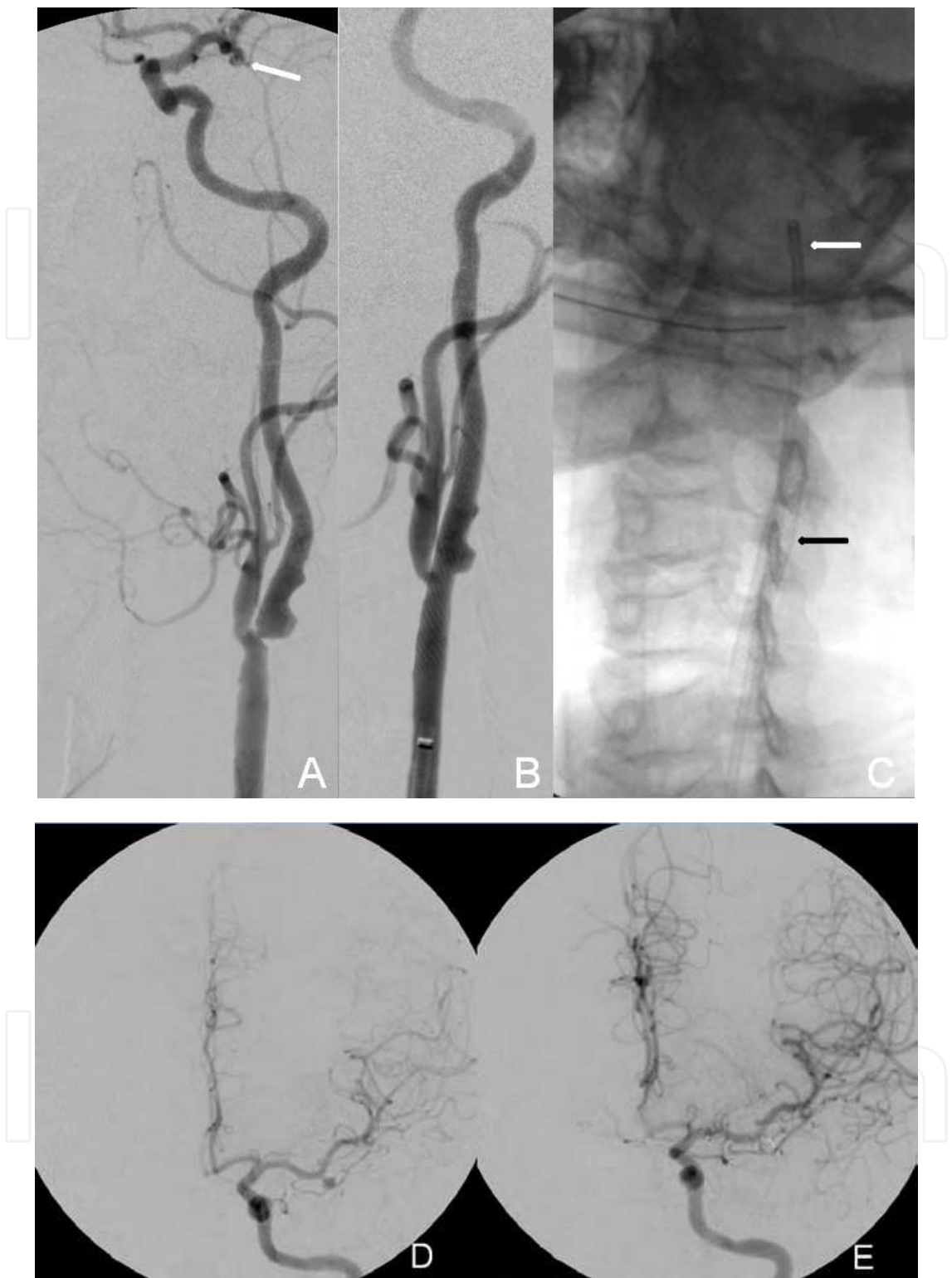


Fig. 5. A 52-year-old patient with a family history of deaths (brother and mother) from subarachnoid hemorrhage presented with an unruptured saccular aneurysm with a narrow neck in the left middle cerebral artery and severe ipsilateral cervical carotid artery stenosis. Left oblique incidence angiography showed (A) severe (70%) left cervical carotid artery stenosis by plaque with ulcers and an aneurysm in the same intracranial territory (arrow). Treatment with a self-expandable stent under anesthetic sedation employing a 6F sheath

resulted in the satisfactory opening of the stenosis (B). During the same procedure, the patient was subjected to general anesthesia, and a 6F guide catheter (white arrow) was advanced through the stent (black arrow, C) to the petrous segment of the carotid artery. Full embolization of the aneurysm was completed (F).

cerebral blood flow (Kappelle et al., 2000; Ladowski et al., 1984). This approach to treatment decreases the stenotic lumen generated by the atheroma plaque during embolization because of the passage of embolization materials through the stenosis, which can hinder the cerebral blood flow. We further note that during coiling, the patient was unnecessarily exposed to the risk of embolism because of the crossing of embolization materials over the cervical atheroma plaque. The authors employed antiplatelet agents, but the additional use of statins might afford higher protection.

The risk of hematoma in the inguinal area of coiling is avoided by use the puncture of the femoral artery for CAS. The single femoral approach is safe, and it decreases the risks inherent to each separate procedure.

The technique we described above has some limitations. The use of antiplatelet agents in carotid stenting might increase the risk if accidental rupture of the aneurysm occurs during coiling. Because the treatment of the carotid artery stenosis is performed first, a sudden increase in cerebral perfusion might theoretically increase the risk of aneurysm rupture; therefore, special efforts are required to diminish the interval between CAS and coiling. For these reasons, we believe that CAS and coiling should be performed exclusively by experienced neuroradiologists. A further risk of the combined CAS and coiling technique is the increase in exposure to ionizing radiation and contrast. However, experienced physicians are agile and employ less contrast, thus reducing the exposure to radiation and the risk of kidney damage.

Finally, in addition to aneurysms, angiographically hidden micro MAVs may theoretically cause intracranial hemorrhages for unknown reasons (Berker et al., 2003; Cheung et al., 2003; Hartmann et al., 2004) after treatment of the carotid artery stenosis. These patients may benefit from the treatment of carotid stenosis without the angioplasty balloon to prevent intracranial hemorrhages.

6. Conclusion

Although angioplasty was initially designed as a minimally invasive therapeutic approach to prevent ischemic events, several reports mention its ability to restore cerebral perfusion (Tavares et al., 2010).

The endovascular technique for the treatment of carotid artery stenosis is still being developed. Stent placement without post-dilatation by balloon allows the gradual dilatation of the stenosis and may reduce the risk of reperfusion syndrome and possibly also reduce the embolic load to the protection system. Confirmation of this hypothesis requires further studies.

Although the relationship with the possible rupture of aneurysms after treatment of carotid stenosis is not clear, it seems safe to us to suggest that cases with simultaneous carotid stenosis and cerebral aneurysm should be treated by endovascular techniques (CAS and

coiling) in a single procedure to avoid the increase in cerebral flow, which is a risk factor for aneurysm bleeding. Again, further studies are required to confirm this hypothesis.

7. Acronyms

ACT - achieve activated clotting time

CAS - carotid angioplasty and stenting

CBF- regional cerebral blood flow

CBV - regional cerebral blood volume

CEA - carotid endarterectomy

Coiling – endovascular treatment of cerebral aneurysms

CREST - Carotid Revascularization Endarterectomy Versus Stenting Trial

DWI - Diffusion -Weighted Imaging

FLAIR - Fluid Attenuated Inversion Recovery

MCA - middle cerebral artery

MRI – magnetic resonance imaging

MTT - regional mean transit time

NASCET - North American Symptomatic Carotid Endarterectomy Trial

PWI - perfusion weighted images or cerebral perfusion by MRI

PWI - Perfusion-Weighted Imaging

SPECT - Single-photon emission computed tomography

TTP- regional time to peak

8. References

- Abou-Chebl, A., Yadav, J.S., Reginelli, J.P., Bajzer, C., Bhatt, D. & Krieger, D.W. (2004). Intracranial Hemorrhage and Hyperperfusion Syndrome Following Carotid Artery Stenting: Risk Factors, Prevention, and Treatment. *Journal of the American College of Cardiology*, Vol. 43, No. 9, (Epub 2004/05/04), pp. 1596-1601, ISSN 0735-1097 (Print) 0735-1097 (Linking).
- ACAS Trial investigators. (1995). Endarterectomy for Asymptomatic Carotid Artery Stenosis. Executive Committee for the Asymptomatic Carotid Atherosclerosis Study. *JAMA : the journal of the American Medical Association*, Vol. 273, No. 18, (Epub 1995/05/10), pp. 1421-1428, ISSN 0098-7484 (Print) 0098-7484 (Linking).
- Angelini, A., Reimers, B., Della Barbera, M., Sacca, S., Pasquetto, G., Cernetti, C., Valente, M., Pascotto, P. & Thiene, G. (2002). Cerebral Protection During Carotid Artery Stenting: Collection and Histopathologic Analysis of Embolized Debris. *Stroke; a*

- journal of cerebral circulation*, Vol. 33, No. 2, (Epub 2002/02/02), pp. 456-461, ISSN 1524-4628 (Electronic) 0039-2499 (Linking).
- Badraddin, A., Teleb, M.S., Abraham, M.G., Taqi, M.A. & Zaidat, O.O. (2010). Safety and Feasibility of Simultaneous Ipsilateral Proximal Carotid Artery Stenting and Cerebral Aneurysm Coiling. *Frontiers in neurology*, Vol. 1, No. (Epub 2011/01/06), pp. 120, ISSN 1664-2295 (Electronic) 1664-2295 (Linking).
- Baldi, S., Zander, T., Rabellino, M., Gonzalez, G. & Maynar, M. (2011). Carotid Artery Stenting without Angioplasty and Cerebral Protection: A Single-Center Experience with up to 7 Years' Follow-Up. *AJNR. American journal of neuroradiology*, Vol. 32, No. 4, (Epub 2011/02/26), pp. 759-763, ISSN 1936-959X (Electronic) 0195-6108 (Linking).
- Bando, K., Satoh, K., Matsubara, S., Nakatani, M. & Nagahiro, S. (2001). Hyperperfusion Phenomenon after Percutaneous Transluminal Angioplasty for Atherosclerotic Stenosis of the Intracranial Vertebral Artery. Case Report. *Journal of neurosurgery*, Vol. 94, No. 5, (Epub 2001/05/17), pp. 826-830, ISSN 0022-3085 (Print) 0022-3085 (Linking).
- Bates, E.R., Babb, J.D., Casey, D.E., Jr., Cates, C.U., Duckwiler, G.R., Feldman, T.E., Gray, W.A., Ouriel, K., Peterson, E.D., Rosenfield, K., Rundback, J.H., Safian, R.D., Sloan, M.A. & White, C.J. (2007). Accf/Scai/Svmb/Sir/Asitn 2007 Clinical Expert Consensus Document on Carotid Stenting: A Report of the American College of Cardiology Foundation Task Force on Clinical Expert Consensus Documents (Accf/Scai/Svmb/Sir/Asitn Clinical Expert Consensus Document Committee on Carotid Stenting). *Journal of the American College of Cardiology*, Vol. 49, No. 1, (Epub 2007/01/09), pp. 126-170, ISSN 1558-3597 (Electronic) 0735-1097 (Linking).
- Bendok, B.R., Sherma, A.K., Hage, Z.A., Das, S., Naidech, A.M., Surdell, D.L., Adel, J.G., Shaibani, A., Batjer, H.H., Carroll, T.J. & Walker, M. (2010). Periprocedural MRI Perfusion Imaging to Assess and Monitor the Hemodynamic Impact of Intracranial Angioplasty and Stenting for Symptomatic Atherosclerotic Stenosis. *Journal of Clinical Neuroscience: Official Journal of the Neurosurgical Society of Australasia*, Vol. 17, No. 1, (Epub 2009/12/17), pp. 54-58, ISSN 1532-2653 (Electronic) 0967-5868 (Linking).
- Berker, M., Ulus, A., Palaoglu, S., Soylemezoglu, F., Ay, H. & Cekirge, S. (2003). Intracranial Haemorrhage Probably Due to an Angiographically Occult Avm after Carotid Stenting. A Case Report. *Interventional neuroradiology : journal of peritherapeutic neuroradiology, surgical procedures and related neurosciences*, Vol. 9, No. 3, (Epub 2003/09/30), pp. 315-320, ISSN 1591-0199 (Print) 1591-0199 (Linking).
- Bodenant, M., Leys, D. & Lucas, C. (2010). Isolated Subarachnoidal Hemorrhage Following Carotid Endarterectomy. *Case reports in neurology*, Vol. 2, No. 2, (Epub 2010/07/31), pp. 80-84, ISSN 1662-680X (Electronic) 1662-680X (Linking).
- Bokkers, R.P., van Laar, P.J., van de Ven, K.C., Kapelle, L.J., Klijn, C.J. & Hendrikse, J. (2008). Arterial Spin-Labeling Mr Imaging Measurements of Timing Parameters in Patients with a Carotid Artery Occlusion. *AJNR. American journal of neuroradiology*, Vol. 29, No. 9, (Epub 2008/08/15), pp. 1698-1703, ISSN 1936-959X (Electronic) 0195-6108 (Linking).

- Bozzao, A., Floris, R., Gaudiello, F., Finocchi, V., Fantozzi, L.M. & Simonetti, G. (2002). Hemodynamic Modifications in Patients with Symptomatic Unilateral Stenosis of the Internal Carotid Artery: Evaluation with Mr Imaging Perfusion Sequences. *AJNR. American journal of neuroradiology*, Vol. 23, No. 8, (Epub 2002/09/12), pp. 1342-1345, ISSN 0195-6108 (Print) 0195-6108 (Linking).
- Braga, F.T., da Rocha, A.J., Hernandez Filho, G., Arikawa, R.K., Ribeiro, I.M. & Fonseca, R.B. (2003). Relationship between the Concentration of Supplemental Oxygen and Signal Intensity of Csf Depicted by Fluid-Attenuated Inversion Recovery Imaging. *AJNR. American journal of neuroradiology*, Vol. 24, No. 9, (Epub 2003/10/17), pp. 1863-1868, ISSN 0195-6108 (Print) 0195-6108 (Linking).
- Bussiere, M., Pelz, D.M., Kalapos, P., Lee, D., Gulka, I., Leung, A. & Lownie, S.P. (2008). Results Using a Self-Expanding Stent Alone in the Treatment of Severe Symptomatic Carotid Bifurcation Stenosis. *Journal of neurosurgery*, Vol. 109, No. 3, (Epub 2008/09/02), pp. 454-460, ISSN 0022-3085 (Print) 0022-3085 (Linking).
- Caldas, J.G. (2006). Angioplastie Carotidienne Avec Stent Et Protection Cérébrale. *e-mémoires de l'Académie Nationale de Chirurgie*, Vol. 5, No. 4, pp. 1-4.
- Chaturvedi, S. & Yadav, J.S. (2006). The Role of Antiplatelet Therapy in Carotid Stenting for Ischemic Stroke Prevention. *Stroke; a journal of cerebral circulation*, Vol. 37, No. 6, (Epub 2006/04/22), pp. 1572-1577, ISSN 1524-4628 (Electronic) 0039-2499 (Linking).
- Chen, P.R., Frerichs, K. & Spetzler, R. (2004). Current Treatment Options for Unruptured Intracranial Aneurysms. *Neurosurgical focus*, Vol. 17, No. 5, (Epub 2005/01/07), pp. E5, ISSN 1092-0684 (Electronic) 1092-0684 (Linking).
- Cheung, R.T., Eliasziw, M., Meldrum, H.E., Fox, A.J. & Barnett, H.J. (2003). Risk, Types, and Severity of Intracranial Hemorrhage in Patients with Symptomatic Carotid Artery Stenosis. *Stroke; a journal of cerebral circulation*, Vol. 34, No. 8, (Epub 2003/06/28), pp. 1847-1851, ISSN 1524-4628 (Electronic) 0039-2499 (Linking).
- Costin, M., Rampersad, A., Solomon, R.A., Connolly, E.S. & Heyer, E.J. (2002). Cerebral Injury Predicted by Transcranial Doppler Ultrasonography but Not Electroencephalography During Carotid Endarterectomy. *Journal of neurosurgical anesthesiology*, Vol. 14, No. 4, (Epub 2002/10/03), pp. 287-292, ISSN 0898-4921 (Print) 0898-4921 (Linking).
- Cowan, J.A., Jr., Ziewacz, J., Dimick, J.B., Upchurch, G.R., Jr. & Thompson, B.G. (2007). Use of Endovascular Coil Embolization and Surgical Clip Occlusion for Cerebral Artery Aneurysms. *Journal of neurosurgery*, Vol. 107, No. 3, (Epub 2007/09/25), pp. 530-535, ISSN 0022-3085 (Print) 0022-3085 (Linking).
- Cronqvist, S., Lundberg, N. & Troupp, H. (1964). Temporary or Incomplete Occlusion of the Carotid Artery in the Neck for the Treatment of Intracranial Arterial Aneurysms. *Neurochirurgia*, Vol. 7, No. (Epub 1964/08/01), pp. 146-151, ISSN 0028-3819 (Print) 0028-3819 (Linking).
- Del Sette M., Eliasziw M., Streifler J.Y., Hachinski V.C., Fox A.J., Barnett H.J. (2000). Internal borderzone infarction: a marker for severe stenosis in patients with symptomatic internal carotid artery disease. For the North American Symptomatic Carotid Endarterectomy (NASCET) Group. *Stroke*, Vol.31, No 3, (Epub 1999/28/12) pp. 631-636, ISSN 0039-2499 (Print) 1524-4628 (Linking).

- du Mesnil de Rochemont, R., Schneider, S., Yan, B., Lehr, A., Sitzler, M. & Berkefeld, J. (2006). Diffusion-Weighted Mr Imaging Lesions after Filter-Protected Stenting of High-Grade Symptomatic Carotid Artery Stenoses. *AJNR. American journal of neuroradiology*, Vol. 27, No. 6, (Epub 2006/06/16), pp. 1321-1325, ISSN 0195-6108 (Print) 0195-6108 (Linking).
- Fukuda, T., Ogasawara, K., Kobayashi, M., Komoribayashi, N., Endo, H., Inoue, T., Kuzu, Y., Nishimoto, H., Terasaki, K. & Ogawa, A. (2007). Prediction of Cerebral Hyperperfusion after Carotid Endarterectomy Using Cerebral Blood Volume Measured by Perfusion-Weighted Mr Imaging Compared with Single-Photon Emission Ct. *AJNR. American journal of neuroradiology*, Vol. 28, No. 4, (Epub 2007/04/10), pp. 737-742, ISSN 0195-6108 (Print) 0195-6108 (Linking).
- Gauvrit, J.Y., Delmaire, C., Henon, H., Debette, S., al Koussa, M., Leys, D., Pruvo, J.P. & Leclerc, X. (2004). Diffusion/Perfusion-Weighted Magnetic Resonance Imaging after Carotid Angioplasty and Stenting. *Journal of neurology*, Vol. 251, No. 9, (Epub 2004/09/17), pp. 1060-1067, ISSN 0340-5354 (Print) 0340-5354 (Linking).
- Grunwald, I.Q., Politi, M., Reith, W., Krick, C., Karp, K., Zimmer, A., Struffert, T., Roth, C., Kuhn, A.L., Haass, A. & Papanagiotou, P. (2009). Hyperperfusion Syndrome after Carotid Stent Angioplasty. *Neuroradiology*, Vol. 51, No. 3, (Epub 2008/12/24), pp. 169-174, ISSN 1432-1920 (Electronic) 0028-3940 (Linking).
- Gurm, H.S., Nallamothu, B.K. & Yadav, J. (2008). Safety of Carotid Artery Stenting for Symptomatic Carotid Artery Disease: A Meta-Analysis. *European heart journal*, Vol. 29, No. 1, (Epub 2007/09/21), pp. 113-119, ISSN 0195-668X (Print) 0195-668X (Linking).
- Hamilton, E.B. (2005). Intracranial Atherosclerosis, Atherosclerosis, Acute Cerebral Ischemia- Infarction, Hypotensive Cerebral Infarction, In: *Diagnostic Imaging Brain*, A.G. Osborn, S. Blaser and K. Salzman, pp. I-4-24 to I-24-35 and I-24-76 to I-24-99, Amirsys / Elsevier Saunders,
- Hartmann, M., Weber, R., Zoubaa, S., Schranz, C. & Knauth, M. (2004). Fatal Subarachnoid Hemorrhage after Carotid Stenting. *Journal of neuroradiology. Journal de neuroradiologie*, Vol. 31, No. 1, (Epub 2004/03/18), pp. 63-66, ISSN 0150-9861 (Print) 0150-9861 (Linking).
- Henderson, R.D., Phan, T.G., Piepgras, D.G. & Wijedicks, E.F. (2001). Mechanisms of Intracerebral Hemorrhage after Carotid Endarterectomy. *Journal of neurosurgery*, Vol. 95, No. 6, (Epub 2002/01/05), pp. 964-969, ISSN 0022-3085 (Print) 0022-3085 (Linking).
- Heyer, E.J., Adams, D.C., Solomon, R.A., Todd, G.J., Quest, D.O., McMahon, D.J., Steneck, S.D., Choudhri, T.F. & Connolly, E.S. (1998). Neuropsychometric Changes in Patients after Carotid Endarterectomy. *Stroke; a journal of cerebral circulation*, Vol. 29, No. 6, (Epub 1998/06/17), pp. 1110-1115, ISSN 0039-2499 (Print) 0039-2499 (Linking).
- Higashida, R.T., Lahue, B.J., Torbey, M.T., Hopkins, L.N., Leip, E. & Hanley, D.F. (2007). Treatment of Unruptured Intracranial Aneurysms: A Nationwide Assessment of Effectiveness. *AJNR. American journal of neuroradiology*, Vol. 28, No. 1, (Epub 2007/01/11), pp. 146-151, ISSN 0195-6108 (Print) 0195-6108 (Linking).

- Hino, A., Tenjin, H., Horikawa, Y., Fujimoto, M. & Imahori, Y. (2005). Hemodynamic and Metabolic Changes after Carotid Endarterectomy in Patients with High-Degree Carotid Artery Stenosis. *Journal of stroke and cerebrovascular diseases : the official journal of National Stroke Association*, Vol. 14, No. 6, (Epub 2007/10/02), pp. 234-238, ISSN 1532-8511 (Electronic) 1052-3057 (Linking).
- Hirooka, R., Ogasawara, K., Sasaki, M., Yamadate, K., Kobayashi, M., Suga, Y., Yoshida, K., Otawara, Y., Inoue, T. & Ogawa, A. (2008). Magnetic Resonance Imaging in Patients with Cerebral Hyperperfusion and Cognitive Impairment after Carotid Endarterectomy. *Journal of neurosurgery*, Vol. 108, No. 6, (Epub 2008/06/04), pp. 1178-1183, ISSN 0022-3085 (Print) 0022-3085 (Linking).
- Hosoda, K., Kawaguchi, T., Shibata, Y., Kamei, M., Kidoguchi, K., Koyama, J., Fujita, S. & Tamaki, N. (2001). Cerebral Vasoreactivity and Internal Carotid Artery Flow Help to Identify Patients at Risk for Hyperperfusion after Carotid Endarterectomy. *Stroke; a journal of cerebral circulation*, Vol. 32, No. 7, (Epub 2001/07/07), pp. 1567-1573, ISSN 1524-4628 (Electronic) 0039-2499 (Linking).
- Inzitari, D., Eliasziw, M., Gates, P., Sharpe, B.L., Chan, R.K., Meldrum, H.E. & Barnett, H.J. (2000). The Causes and Risk of Stroke in Patients with Asymptomatic Internal-Carotid-Artery Stenosis. North American Symptomatic Carotid Endarterectomy Trial Collaborators. *The New England journal of medicine*, Vol. 342, No. 23, (Epub 2000/06/08), pp. 1693-1700, ISSN 0028-4793 (Print) 0028-4793 (Linking).
- ISUIA. (1998). Unruptured Intracranial Aneurysms--Risk of Rupture and Risks of Surgical Intervention. International Study of Unruptured Intracranial Aneurysms Investigators. *The New England journal of medicine*, Vol. 339, No. 24, (Epub 1998/12/29), pp. 1725-1733, ISSN 0028-4793 (Print) 0028-4793 (Linking).
- Jensen, M.C., Brant-Zawadki, M.N. & Jacobs, B.C. (2005). Isquemia, In: *Ressonância Magnética*, D.D. Stark and W.G. Bradley Jr, pp. 1255-1276, Revinter, Rio de Janeiro.
- Jin, S.C., Kwon, O.K., Oh, C.W., Jung, C., Han, M.G., Bae, H.J., Lee, S.H., Jung, Y.S., Han, M.H. & Kang, H.S. (2010). A Technical Strategy for Carotid Artery Stenting: Suboptimal Pre-stent Balloon Angioplasty without Poststenting Balloon Dilatation. *Neurosurgery*, Vol. 67, No. 5, (Epub 2010/09/28), pp. 1438-1442; discussion 1442-1433, ISSN 1524-4040 (Electronic) 0148-396X (Linking).
- Jongen, L.M., Hendrikse, J., Moll, F.L., Mali, W.P. & van der Worp, H.B. (2010). Cerebral Perfusion Affects the Risk of Ischemia During Carotid Artery Stenting. *Cerebrovascular diseases*, Vol. 29, No. 6, (Epub 2010/04/09), pp. 538-545, ISSN 1421-9786 (Electronic) 1015-9770 (Linking).
- Kang, H.S., Han, M.H., Kwon, O.K., Kwon, B.J., Kim, S.H. & Oh, C.W. (2007). Intracranial Hemorrhage after Carotid Angioplasty: A Pooled Analysis. *Journal of endovascular therapy : an official journal of the International Society of Endovascular Specialists*, Vol. 14, No. 1, (Epub 2007/02/13), pp. 77-85, ISSN 1526-6028 (Print) 1526-6028 (Linking).
- Kappelle, L.J., Eliasziw, M., Fox, A.J. & Barnett, H.J. (2000). Small, Unruptured Intracranial Aneurysms and Management of Symptomatic Carotid Artery Stenosis. North American Symptomatic Carotid Endarterectomy Trial Group. *Neurology*, Vol. 55, No. 2, (Epub 2000/07/26), pp. 307-309, ISSN 0028-3878 (Print) 0028-3878 (Linking).

- Kastrup, A., Groschel, K., Nagele, T., Riecker, A., Schmidt, F., Schnaudigel, S. & Ernemann, U. (2008). Effects of Age and Symptom Status on Silent Ischemic Lesions after Carotid Stenting with and without the Use of Distal Filter Devices. *AJNR. American journal of neuroradiology*, Vol. 29, No. 3, (Epub 2007/12/11), pp. 608-612, ISSN 1936-959X (Electronic) 0195-6108 (Linking).
- Kleiser, B. & Widder, B. (1992). Course of Carotid Artery Occlusions with Impaired Cerebrovascular Reactivity. *Stroke; a journal of cerebral circulation*, Vol. 23, No. 2, (Epub 1992/02/01), pp. 171-174, ISSN 0039-2499 (Print) 0039-2499 (Linking).
- Kluytmans, M., van der Grond, J., Eikelboom, B.C. & Viergever, M.A. (1998). Long-Term Hemodynamic Effects of Carotid Endarterectomy. *Stroke; a journal of cerebral circulation*, Vol. 29, No. 8, (Epub 1998/08/26), pp. 1567-1572, ISSN 0039-2499 (Print) 0039-2499 (Linking).
- Ko, N.U., Achrol, A.S., Chopra, M., Saha, M., Gupta, D., Smith, W.S., Higashida, R.T. & Young, W.L. (2005). Cerebral Blood Flow Changes after Endovascular Treatment of Cerebrovascular Stenoses. *AJNR. American journal of neuroradiology*, Vol. 26, No. 3, (Epub 2005/03/12), pp. 538-542, ISSN 0195-6108 (Print) 0195-6108 (Linking).
- Krogias, C., Hennebohl, C., Geier, B., Hansen, C., Hummel, T., Meves, S., Lukas, C. & Eyding, J. (2010). Transcranial Ultrasound Perfusion Imaging and Perfusion-MRI--a Pilot Study on the Evaluation of Cerebral Perfusion in Severe Carotid Artery Stenosis. *Ultrasound in medicine & biology*, Vol. 36, No. 12, (Epub 2010/10/19), pp. 1973-1980, ISSN 1879-291X (Electronic) 0301-5629 (Linking).
- Ladowski, J.S., Webster, M.W., Yonas, H.O. & Steed, D.L. (1984). Carotid Endarterectomy in Patients with Asymptomatic Intracranial Aneurysm. *Annals of surgery*, Vol. 200, No. 1, (Epub 1984/07/01), pp. 70-73, ISSN 0003-4932 (Print) 0003-4932 (Linking).
- Lownie, S.P., Pelz, D.M., Lee, D.H., Men, S., Gulka, I. & Kalapos, P. (2005). Efficacy of Treatment of Severe Carotid Bifurcation Stenosis by Using Self-Expanding Stents without Deliberate Use of Angioplasty Balloons. *AJNR. American journal of neuroradiology*, Vol. 26, No. 5, (Epub 2005/05/14), pp. 1241-1248, ISSN 0195-6108 (Print) 0195-6108 (Linking).
- Maleux, G., Demaerel, P., Verbeken, E., Daenens, K., Heye, S., Van Sonhoven, F., Nevelsteen, A. & Wilms, G. (2006). Cerebral Ischemia after Filter-Protected Carotid Artery Stenting Is Common and Cannot Be Predicted by the Presence of Substantial Amount of Debris Captured by the Filter Device. *AJNR. American journal of neuroradiology*, Vol. 27, No. 9, (Epub 2006/10/13), pp. 1830-1833, ISSN 0195-6108 (Print) 0195-6108 (Linking).
- Marks, M.P. (2002). Cerebral Ischemia and Infarction, In: *Magnetic Resonance Imaging of the Brain and Spine*, S.W. Atlas, pp. 919-980, Lippincott Williams & Wilkins, Philadelphia.
- Martin, A.J., Saloner, D.A., Roberts, T.P., Roberts, H., Weber, O.M., Dillon, W., Cullen, S., Halbach, V., Dowd, C.F. & Higashida, R.T. (2005). Carotid Stent Delivery in an Xmr Suite: Immediate Assessment of the Physiologic Impact of Extracranial Revascularization. *AJNR. American journal of neuroradiology*, Vol. 26, No. 3, (Epub 2005/03/12), pp. 531-537, ISSN 0195-6108 (Print) 0195-6108 (Linking).

- Martin, J.B., Pache, J.C., Treggiari-Venzi, M., Murphy, K.J., Gailloud, P., Puget, E., Pizzolato, G., Sugiu, K., Guimaraens, L., Theron, J. & Rufenacht, D.A. (2001). Role of the Distal Balloon Protection Technique in the Prevention of Cerebral Embolic Events During Carotid Stent Placement. *Stroke; a journal of cerebral circulation*, Vol. 32, No. 2, (Epub 2001/02/07), pp. 479-484, ISSN 1524-4628 (Electronic) 0039-2499 (Linking).
- Mas, J.L., Chatellier, G., Beyssen, B., Branchereau, A., Moulin, T., Becquemin, J.P., Larrue, V., Lieve, M., Leys, D., Bonneville, J.F., Watelet, J., Pruvo, J.P., Albucher, J.F., Viguiier, A., Piquet, P., Garnier, P., Viader, F., Touze, E., Giroud, M., Hosseini, H., Pillet, J.C., Favrole, P., Neau, J.P. & Ducrocq, X. (2006). Endarterectomy Versus Stenting in Patients with Symptomatic Severe Carotid Stenosis. *The New England journal of medicine*, Vol. 355, No. 16, (Epub 2006/10/20), pp. 1660-1671, ISSN 1533-4406 (Electronic) 0028-4793 (Linking).
- Matsubara, S., Moroi, J., Suzuki, A., Sasaki, M., Nagata, K., Kanno, I. & Miura, S. (2009). Analysis of Cerebral Perfusion and Metabolism Assessed with Positron Emission Tomography before and after Carotid Artery Stenting. Clinical Article. *Journal of neurosurgery*, Vol. 111, No. 1, (Epub 2009/03/24), pp. 28-36, ISSN 0022-3085 (Print) 0022-3085 (Linking).
- Maynar, M., Baldi, S., Rostagno, R., Zander, T., Rabellino, M., Llorens, R., Alvarez, J. & Barajas, F. (2007). Carotid Stenting without Use of Balloon Angioplasty and Distal Protection Devices: Preliminary Experience in 100 Cases. *AJNR. American journal of neuroradiology*, Vol. 28, No. 7, (Epub 2007/08/19), pp. 1378-1383, ISSN 0195-6108 (Print) 0195-6108 (Linking).
- McCormick, W.F. & Schochet, S.S. (1976). *Atlas of Cerebrovascular Disease*, Saunders, ISBN 0721658962, Philadelphia.
- Men, S., Lownie, S.P. & Pelz, D.M. (2002). Carotid Stenting without Angioplasty. *The Canadian journal of neurological sciences. Le journal canadien des sciences neurologiques*, Vol. 29, No. 2, (Epub 2002/05/31), pp. 175-179, ISSN 0317-1671 (Print) 0317-1671 (Linking).
- Menon, D. & Stafinski, T. (2006). Cerebral Protection Devices for Use During Carotid Artery Angioplasty with Stenting: A Health Technology Assessment. *International journal of technology assessment in health care*, Vol. 22, No. 1, (Epub 2006/05/06), pp. 119-129, ISSN 0266-4623 (Print) 0266-4623 (Linking).
- Michel, E., Liu, H., Remley, K.B., Martin, A.J., Madison, M.T., Kucharczyk, J. & Truwit, C.L. (2001). Perfusion Mr Neuroimaging in Patients Undergoing Balloon Test Occlusion of the Internal Carotid Artery. *AJNR. American journal of neuroradiology*, Vol. 22, No. 8, (Epub 2001/09/18), pp. 1590-1596, ISSN 0195-6108 (Print) 0195-6108 (Linking).
- Moftakhar, R., Turk, A.S., Niemann, D.B., Hussain, S., Rajpal, S., Cook, T., Geraghty, M., Aagaard-Kienitz, B., Turski, P.A. & Newman, G.C. (2005). Effects of Carotid or Vertebrobasilar Stent Placement on Cerebral Perfusion and Cognition. *AJNR. American journal of neuroradiology*, Vol. 26, No. 7, (Epub 2005/08/11), pp. 1772-1780, ISSN 0195-6108 (Print) 0195-6108 (Linking).
- Mohr, J.P., Albers, G.W., Amarenco, P., Babikian, V.L., Biller, J., Brey, R.L., Coull, B., Easton, J.D., Gomez, C.R., Helgason, C.M., Kase, C.S., Pullicino, P.M. & Turpie, A.G. (1997). American Heart Association Prevention Conference. Iv. Prevention and

- Rehabilitation of Stroke. Etiology of Stroke. *Stroke; a journal of cerebral circulation*, Vol. 28, No. 7, (Epub 1997/07/01), pp. 1501-1506, ISSN 0039-2499 (Print) 0039-2499 (Linking).
- Molyneux, A.J., Kerr, R.S., Birks, J., Ramzi, N., Yarnold, J., Sneade, M. & Rischmiller, J. (2009). Risk of Recurrent Subarachnoid Haemorrhage, Death, or Dependence and Standardised Mortality Ratios after Clipping or Coiling of an Intracranial Aneurysm in the International Subarachnoid Aneurysm Trial (Isat): Long-Term Follow-Up. *Lancet neurology*, Vol. 8, No. 5, (Epub 2009/03/31), pp. 427-433, ISSN 1474-4422 (Print) 1474-4422 (Linking).
- Momjian-Mayor, I. & Baron, J.C. (2005). The Pathophysiology of Watershed Infarction in Internal Carotid Artery Disease: Review of Cerebral Perfusion Studies. *Stroke; a journal of cerebral circulation*, Vol. 36, No. 3, (Epub 2005/02/05), pp. 567-577, ISSN 1524-4628 (Electronic) 0039-2499 (Linking).
- Morrish, W., Grahovac, S., Douen, A., Cheung, G., Hu, W., Farb, R., Kalapos, P., Wee, R., Hudon, M., Agbi, C. & Richard, M. (2000). Intracranial Hemorrhage after Stenting and Angioplasty of Extracranial Carotid Stenosis. *AJNR. American journal of neuroradiology*, Vol. 21, No. 10, (Epub 2000/12/08), pp. 1911-1916, ISSN 0195-6108 (Print) 0195-6108 (Linking).
- Muller-Hulsbeck, S., Jahnke, T., Liess, C., Glass, C., Grimm, J. & Heller, M. (2003). Comparison of Various Cerebral Protection Devices Used for Carotid Artery Stent Placement: An in Vitro Experiment. *Journal of vascular and interventional radiology : JVIR*, Vol. 14, No. 5, (Epub 2003/05/23), pp. 613-620, ISSN 1051-0443 (Print) 1051-0443 (Linking).
- NASCET. (1991). Beneficial Effect of Carotid Endarterectomy in Symptomatic Patients with High-Grade Carotid Stenosis. North American Symptomatic Carotid Endarterectomy Trial Collaborators. *The New England journal of medicine*, Vol. 325, No. 7, (Epub 1991/08/15), pp. 445-453, ISSN 0028-4793 (Print) 0028-4793 (Linking).
- NASCET Trial Investigators. (1991). Clinical Alert: Benefit of Carotid Endarterectomy for Patients with High-Grade Stenosis of the Internal Carotid Artery. National Institute of Neurological Disorders and Stroke Stroke and Trauma Division. North American Symptomatic Carotid Endarterectomy Trial (Nascet) Investigators. *Stroke; a journal of cerebral circulation*, Vol. 22, No. 6, (Epub 1991/06/01), pp. 816-817, ISSN 0039-2499 (Print) 0039-2499 (Linking).
- Navaneethan, S.D., Kannan, V.S., Osowo, A., Shrivastava, R. & Singh, S. (2006). Concomitant Intracranial Aneurysm and Carotid Artery Stenosis: A Therapeutic Dilemma. *Southern medical journal*, Vol. 99, No. 7, (Epub 2006/07/27), pp. 757-758, ISSN 0038-4348 (Print) 0038-4348 (Linking).
- Niesen, W.D., Rosenkranz, M., Eckert, B., MeISSner, M., Weiller, C. & Sliwka, U. (2004). Hemodynamic Changes of the Cerebral Circulation after Stent-Protected Carotid Angioplasty. *AJNR. American journal of neuroradiology*, Vol. 25, No. 7, (Epub 2004/08/18), pp. 1162-1167, ISSN 0195-6108 (Print) 0195-6108 (Linking).
- O'Leary, D.H., Polak, J.F., Kronmal, R.A., Kittner, S.J., Bond, M.G., Wolfson, S.K., Jr., Bommer, W., Price, T.R., Gardin, J.M. & Savage, P.J. (1992). Distribution and Correlates of Sonographically Detected Carotid Artery Disease in the

- Cardiovascular Health Study. The Chs Collaborative Research Group. *Stroke; a journal of cerebral circulation*, Vol. 23, No. 12, (Epub 1992/12/11), pp. 1752-1760, ISSN 0039-2499 (Print) 0039-2499 (Linking).
- Obray, R., Clatterbuck, R., Olvi, A., Tamargo, R., Murphy, K.J. & Gailloud, P. (2003). De Novo Aneurysm Formation 6 and 22 Months after Initial Presentation in Two Patients. *AJNR. American journal of neuroradiology*, Vol. 24, No. 9, (Epub 2003/10/17), pp. 1811-1813, ISSN 0195-6108 (Print) 0195-6108 (Linking).
- Ogata, J., Yonemura, K., Kimura, K., Yutani, C. & Minematsu, K. (2005). Cerebral Infarction Associated with Essential Thrombocythemia: An Autopsy Case Study. *Cerebrovascular diseases*, Vol. 19, No. 3, (Epub 2005/02/11), pp. 201-205, ISSN 1015-9770 (Print) 1015-9770 (Linking).
- Rabellino, M., Garcia-Nielsen, L., Baldi, S., Zander, T., Casasola, C., Estigarribia, A., Llorens, R. & Maynar, M. (2010). Non-Protected Carotid Artery Stent without Angioplasty in High-Risk Patients with Carotid and Coronary Artery Disease Undergoing Cardiac Surgery. *Minimally invasive therapy & allied technologies : MITAT : official journal of the Society for Minimally Invasive Therapy*, Vol. 19, No. 3, (Epub 2010/02/16), pp. 184-188, ISSN 1365-2931 (Electronic) 1364-5706 (Linking).
- Raja, P.V., Huang, J., Germanwala, A.V., Gailloud, P., Murphy, K.P. & Tamargo, R.J. (2008). Microsurgical Clipping and Endovascular Coiling of Intracranial Aneurysms: A Critical Review of the Literature. *Neurosurgery*, Vol. 62, No. 6, (Epub 2008/10/01), pp. 1187-1202; discussion 1202-1183, ISSN 1524-4040 (Electronic) 0148-396X (Linking).
- Rasmussen, M., Juul, N., Christensen, S.M., Jonsdottir, K.Y., Gyldensted, C., Vestergaard-Poulsen, P., Cold, G.E. & Ostergaard, L. (2010). Cerebral Blood Flow, Blood Volume, and Mean Transit Time Responses to Propofol and Indomethacin in Peritumor and Contralateral Brain Regions: Perioperative Perfusion-Weighted Magnetic Resonance Imaging in Patients with Brain Tumors. *Anesthesiology*, Vol. 112, No. 1, (Epub 2009/12/03), pp. 50-56, ISSN 1528-1175 (Electronic) 0003-3022 (Linking).
- Ringleb, P.A., Allenberg, J., Bruckmann, H., Eckstein, H.H., Fraedrich, G., Hartmann, M., Hennerici, M., Jansen, O., Klein, G., Kunze, A., Marx, P., Niederkorn, K., Schmiedt, W., Solymosi, L., Stinge, R., Zeumer, H. & Hacke, W. (2006). 30 Day Results from the Space Trial of Stent-Protected Angioplasty Versus Carotid Endarterectomy in Symptomatic Patients: A Randomised Non-Inferiority Trial. *Lancet*, Vol. 368, No. 9543, (Epub 2006/10/10), pp. 1239-1247, ISSN 1474-547X (Electronic) 0140-6736 (Linking).
- Riphagen, J.H. & Bernsen, H.J. (2009). Rupture of an Intracerebral Aneurysm after Carotid Endarterectomy: A Case Report. *Acta neurologica Belgica*, Vol. 109, No. 4, (Epub 2010/02/03), pp. 314-316, ISSN 0300-9009 (Print) 0300-9009 (Linking).
- Roberts, H.C., Dillon, W.P. & Smith, W.S. (2000). Dynamic Ct Perfusion to Assess the Effect of Carotid Revascularization in Chronic Cerebral Ischemia. *AJNR. American journal of neuroradiology*, Vol. 21, No. 2, (Epub 2000/03/01), pp. 421-425, ISSN 0195-6108 (Print) 0195-6108 (Linking).

- Rohl, L., Ostergaard, L., Simonsen, C.Z., Vestergaard-Poulsen, P., Andersen, G., Sakoh, M., Le Bihan, D. & Gyldensted, C. (2001). Viability Thresholds of Ischemic Penumbra of Hyperacute Stroke Defined by Perfusion-Weighted MRI and Apparent Diffusion Coefficient. *Stroke; a journal of cerebral circulation*, Vol. 32, No. 5, (Epub 2001/09/06), pp. 1140-1146, ISSN 1524-4628 (Electronic) 0039-2499 (Linking).
- Schnaudigel, S., Groschel, K., Pilgram, S.M. & Kastrup, A. (2008). New Brain Lesions after Carotid Stenting Versus Carotid Endarterectomy: A Systematic Review of the Literature. *Stroke; a journal of cerebral circulation*, Vol. 39, No. 6, (Epub 2008/04/05), pp. 1911-1919, ISSN 1524-4628 (Electronic) 0039-2499 (Linking).
- Soinne, L., Helenius, J., Tatlisumak, T., Saimanen, E., Salonen, O., Lindsberg, P.J. & Kaste, M. (2003). Cerebral Hemodynamics in Asymptomatic and Symptomatic Patients with High-Grade Carotid Stenosis Undergoing Carotid Endarterectomy. *Stroke; a journal of cerebral circulation*, Vol. 34, No. 7, (Epub 2003/06/14), pp. 1655-1661, ISSN 1524-4628 (Electronic) 0039-2499 (Linking).
- Spelle, L. & Pierot, L. (2008). [Endovascular Treatment of Non-Ruptured Intracranial Aneurysms: Critical Analysis of the Literature]. *Journal of neuroradiology. Journal de neuroradiologie*, Vol. 35, No. 2, (Epub 2008/05/10), pp. 116-120, ISSN 0150-9861 (Print) 0150-9861 (Linking).
- Stern, J., Whelan, M., Brisman, R. & Correll, J.W. (1979). Management of Extracranial Carotid Stenosis and Intracranial Aneurysms. *Journal of neurosurgery*, Vol. 51, No. 2, (Epub 1979/08/01), pp. 147-150, ISSN 0022-3085 (Print) 0022-3085 (Linking).
- Suh, B.Y., Yun, W.S. & Kwun, W.H. (2011). Carotid Artery Revascularization in Patients with Concomitant Carotid Artery Stenosis and Asymptomatic Unruptured Intracranial Artery Aneurysm. *Annals of vascular surgery*, Vol. 25, No. 5, (Epub 2011/05/03), pp. 651-655, ISSN 1615-5947 (Electronic) 0890-5096 (Linking).
- Takaiwa, A., Hayashi, N., Kuwayama, N., Akioka, N., Kubo, M. & Endo, S. (2009). Changes in Cognitive Function During the 1-Year Period Following Endarterectomy and Stenting of Patients with High-Grade Carotid Artery Stenosis. *Acta neurochirurgica*, Vol. 151, No. 12, (Epub 2009/06/18), pp. 1593-1600, ISSN 0942-0940 (Electronic) 0001-6268 (Linking).
- Takaiwa, A., Kuwayama, N., Hayashi, N., Kubo, M., Matsui, M. & Endo, S. (2006). [Cognitive Function in Patients with Severe Carotid Stenosis--Evaluation of Rbans, Wais-R and Nart before Treatment of Carotid Revascularization--]. *No to shinkei = Brain and nerve*, Vol. 58, No. 8, (Epub 2006/09/22), pp. 681-686, ISSN 0006-8969 (Print) 0006-8969 (Linking).
- Tavares, A., Caldas, J.G., Castro, C.C., Puglia, P., Jr., Frudit, M.E. & Barbosa, L.A. (2010). Changes in Perfusion-Weighted Magnetic Resonance Imaging after Carotid Angioplasty with Stent. *Interventional neuroradiology : journal of peritherapeutic neuroradiology, surgical procedures and related neurosciences*, Vol. 16, No. 2, (Epub 2010/07/21), pp. 161-169, ISSN 1591-0199 (Print) 1591-0199 (Linking).
- Teng, M.M., Cheng, H.C., Kao, Y.H., Hsu, L.C., Yeh, T.C., Hung, C.S., Wong, W.J., Hu, H.H., Chiang, J.H. & Chang, C.Y. (2001). Mr Perfusion Studies of Brain for Patients with Unilateral Carotid Stenosis or Occlusion: Evaluation of Maps of "Time to Peak" and "Percentage of Baseline at Peak". *Journal of computer assisted*


- tomography*, Vol. 25, No. 1, (Epub 2001/02/15), pp. 121-125, ISSN 0363-8715 (Print) 0363-8715 (Linking).
- Theron, J.G., Payelle, G.G., Coskun, O., Huet, H.F. & Guimaraens, L. (1996). Carotid Artery Stenosis: Treatment with Protected Balloon Angioplasty and Stent Placement. *Radiology*, Vol. 201, No. 3, (Epub 1996/12/01), pp. 627-636, ISSN 0033-8419 (Print) 0033-8419 (Linking).
- Thurley, P.D., Altaf, N., Dineen, R., MacSweeney, S. & Auer, D.P. (2009). Pial Vasodilation and Moderate Hyperaemia Following Carotid Endarterectomy: New MRI Diagnostic Signs in Hyperperfusion/Reperfusion Syndrome? *Neuroradiology*, Vol. 51, No. 6, (Epub 2009/04/25), pp. 427-428, ISSN 1432-1920 (Electronic) 0028-3940 (Linking).
- Turk, A.S., Chaudry, I., Haughton, V.M., Hermann, B.P., Rowley, H.A., Pulfer, K., Aagaard-Kienitz, B., Niemann, D.B., Turski, P.A., Levine, R.L. & Strother, C.M. (2008). Effect of Carotid Artery Stenting on Cognitive Function in Patients with Carotid Artery Stenosis: Preliminary Results. *AJNR. American journal of neuroradiology*, Vol. 29, No. 2, (Epub 2007/11/09), pp. 265-268, ISSN 1936-959X (Electronic) 0195-6108 (Linking).
- Van Laar, P.J., Hendrikse, J., Mali, W.P., Moll, F.L., van der Worp, H.B., van Osch, M.J. & van der Grond, J. (2007). Altered Flow Territories after Carotid Stenting and Carotid Endarterectomy. *Journal of vascular surgery : official publication, the Society for Vascular Surgery [and] International Society for Cardiovascular Surgery, North American Chapter*, Vol. 45, No. 6, (Epub 2007/06/05), pp. 1155-1161, ISSN 0741-5214 (Print) 0741-5214 (Linking).
- van Laar, P.J., van der Grond, J., Moll, F.L., Mali, W.P. & Hendrikse, J. (2006). Hemodynamic Effect of Carotid Stenting and Carotid Endarterectomy. *Journal of vascular surgery : official publication, the Society for Vascular Surgery [and] International Society for Cardiovascular Surgery, North American Chapter*, Vol. 44, No. 1, (Epub 2006/05/30), pp. 73-78, ISSN 0741-5214 (Print) 0741-5214 (Linking).
- van Rooij, W.J., de Gast, A., Sluzewski, M., Nijssen, P.C. & Beute, G.N. (2006). Coiling of Truly Incidental Intracranial Aneurysms. *AJNR. American journal of neuroradiology*, Vol. 27, No. 2, (Epub 2006/02/18), pp. 293-296, ISSN 0195-6108 (Print) 0195-6108 (Linking).
- van Rooij, W.J. & Sluzewski, M. (2006). Procedural Morbidity and Mortality of Elective Coil Treatment of Unruptured Intracranial Aneurysms. *AJNR. American journal of neuroradiology*, Vol. 27, No. 8, (Epub 2006/09/15), pp. 1678-1680, ISSN 0195-6108 (Print) 0195-6108 (Linking).
- Vitek, J.J., Roubin, G.S., Al-Mubarek, N., New, G. & Iyer, S.S. (2000). Carotid Artery Stenting: Technical Considerations. *AJNR. American journal of neuroradiology*, Vol. 21, No. 9, (Epub 2000/10/20), pp. 1736-1743, ISSN 0195-6108 (Print) 0195-6108 (Linking).
- Vlak, M.H., Rinkel, G.J., Greebe, P., van der Bom, J.G. & Algra, A. (2011). Trigger Factors and Their Attributable Risk for Rupture of Intracranial Aneurysms: A Case-Crossover Study. *Stroke; a journal of cerebral circulation*, Vol. 42, No. 7,

- (Epub 2011/05/07), pp. 1878-1882, ISSN 1524-4628 (Electronic) 0039-2499 (Linking).
- Vos, J.A., van den Berg, J.C., Ernst, S.M., Suttorp, M.J., Overtom, T.T., Mauser, H.W., Vogels, O.J., van Heesewijk, H.P., Moll, F.L., van der Graaf, Y., Mali, W.P. & Ackerstaff, R.G. (2005). Carotid Angioplasty and Stent Placement: Comparison of Transcranial Doppler Us Data and Clinical Outcome with and without Filtering Cerebral Protection Devices in 509 Patients. *Radiology*, Vol. 234, No. 2, (Epub 2004/12/24), pp. 493-499, ISSN 0033-8419 (Print) 0033-8419 (Linking).
- Waaijer, A., van Leeuwen, M.S., van Osch, M.J., van der Worp, B.H., Moll, F.L., Lo, R.T., Mali, W.P. & Prokop, M. (2007). Changes in Cerebral Perfusion after Revascularization of Symptomatic Carotid Artery Stenosis: Ct Measurement. *Radiology*, Vol. 245, No. 2, (Epub 2007/09/13), pp. 541-548, ISSN 0033-8419 (Print) 0033-8419 (Linking).
- Wiebers, D.O., Whisnant, J.P., Huston, J., 3rd, Meisner, I., Brown, R.D., Jr., Piepgras, D.G., Forbes, G.S., Thielen, K., Nichols, D., O'Fallon, W.M., Peacock, J., Jaeger, L., Kassell, N.F., Kongable-Beckman, G.L. & Torner, J.C. (2003). Unruptured Intracranial Aneurysms: Natural History, Clinical Outcome, and Risks of Surgical and Endovascular Treatment. *Lancet*, Vol. 362, No. 9378, (Epub 2003/07/18), pp. 103-110, ISSN 1474-547X (Electronic) 0140-6736 (Linking).
- Wilkinson, I.D., Griffiths, P.D., Hoggard, N., Cleveland, T.J., Gaines, P.A., Macdonald, S., McKevitt, F. & Venables, G.S. (2003). Short-Term Changes in Cerebral Microhemodynamics after Carotid Stenting. *AJNR. American journal of neuroradiology*, Vol. 24, No. 8, (Epub 2003/09/19), pp. 1501-1507, ISSN 0195-6108 (Print) 0195-6108 (Linking).
- Wintermark, M., Flanders, A.E., Velthuis, B., Meuli, R., van Leeuwen, M., Goldsher, D., Pineda, C., Serena, J., van der Schaaf, I., Waaijer, A., Anderson, J., Nesbit, G., Gabriely, I., Medina, V., Quiles, A., Pohlman, S., Quist, M., Schnyder, P., Bogousslavsky, J., Dillon, W.P. & Pedraza, S. (2006). Perfusion-Ct Assessment of Infarct Core and Penumbra: Receiver Operating Characteristic Curve Analysis in 130 Patients Suspected of Acute Hemispheric Stroke. *Stroke; a journal of cerebral circulation*, Vol. 37, No. 4, (Epub 2006/03/04), pp. 979-985, ISSN 1524-4628 (Electronic) 0039-2499 (Linking).
- Xu, K., Wang, H., Luo, Q., Li, Y. & Yu, J. (2011). Endovascular Treatment of Bilateral Carotid Artery Occlusion with Concurrent Basilar Apex Aneurysm: A Case Report and Literature Review. *International journal of medical sciences*, Vol. 8, No. 3, (Epub 2011/04/14), pp. 263-269, ISSN 1449-1907 (Electronic) 1449-1907 (Linking).
- Yadav, J.S., Wholey, M.H., Kuntz, R.E., Fayad, P., Katzen, B.T., Mishkel, G.J., Bajwa, T.K., Whitlow, P., Strickman, N.E., Jaff, M.R., Popma, J.J., Snead, D.B., Cutlip, D.E., Firth, B.G. & Ouriel, K. (2004). Protected Carotid-Artery Stenting Versus Endarterectomy in High-Risk Patients. *The New England journal of medicine*, Vol. 351, No. 15, (Epub 2004/10/08), pp. 1493-1501, ISSN 1533-4406 (Electronic) 0028-4793 (Linking).

Yamada, K., Kawasaki, M., Yoshimura, S., Enomoto, Y., Asano, T., Minatoguchi, S. & Iwama, T. (2010). Prediction of Silent Ischemic Lesions after Carotid Artery Stenting Using Integrated Backscatter Ultrasound and Magnetic Resonance Imaging. *Atherosclerosis*, Vol. 208, No. 1, (Epub 2009/07/21), pp. 161-166, ISSN 1879-1484 (Electronic) 0021-9150 (Linking).

IntechOpen

IntechOpen



Advances in the Treatment of Ischemic Stroke

Edited by Dr. Maurizio Balestrino

ISBN 978-953-51-0136-9

Hard cover, 246 pages

Publisher InTech

Published online 02, March, 2012

Published in print edition March, 2012

In recent years research on ischemic stroke has developed powerful therapeutic tools. The novel frontiers of stem cells therapy and of hypothermia have been explored, and novel brain repair mechanisms have been discovered. Limits to intravenous thrombolysis have been advanced and powerful endovascular tools have been put at the clinicians' disposal. Surgical decompression in malignant stroke has significantly improved the prognosis of this often fatal condition. This book includes contributions from scientists active in this innovative research. Stroke physicians, students, nurses and technicians will hopefully use it as a tool of continuing medical education to update their knowledge in this rapidly changing field.

How to reference

In order to correctly reference this scholarly work, feel free to copy and paste the following:

Antenor Tavares and José Guilherme Caldas (2012). Decreased Cerebral Perfusion in Carotid Artery Stenosis, Carotid Angioplasty and Its Effects on Cerebral Circulation, *Advances in the Treatment of Ischemic Stroke*, Dr. Maurizio Balestrino (Ed.), ISBN: 978-953-51-0136-9, InTech, Available from: <http://www.intechopen.com/books/advances-in-the-treatment-of-ischemic-stroke/cerebral-perfusion-and-interaction-with-carotid-angioplasty>

INTECH
open science | open minds

InTech Europe

University Campus STeP Ri
Slavka Krautzeka 83/A
51000 Rijeka, Croatia
Phone: +385 (51) 770 447
Fax: +385 (51) 686 166
www.intechopen.com

InTech China

Unit 405, Office Block, Hotel Equatorial Shanghai
No.65, Yan An Road (West), Shanghai, 200040, China
中国上海市延安西路65号上海国际贵都大饭店办公楼405单元
Phone: +86-21-62489820
Fax: +86-21-62489821

© 2012 The Author(s). Licensee IntechOpen. This is an open access article distributed under the terms of the [Creative Commons Attribution 3.0 License](https://creativecommons.org/licenses/by/3.0/), which permits unrestricted use, distribution, and reproduction in any medium, provided the original work is properly cited.

IntechOpen

IntechOpen