

We are IntechOpen, the world's leading publisher of Open Access books Built by scientists, for scientists

6,900

Open access books available

185,000

International authors and editors

200M

Downloads

Our authors are among the

154

Countries delivered to

TOP 1%

most cited scientists

12.2%

Contributors from top 500 universities



WEB OF SCIENCE™

Selection of our books indexed in the Book Citation Index
in Web of Science™ Core Collection (BKCI)

Interested in publishing with us?
Contact book.department@intechopen.com

Numbers displayed above are based on latest data collected.
For more information visit www.intechopen.com



Mechanical Embolectomy

Jiří Lacman and František Charvát
*Central Military Hospital Prague
 Czech Republic*

1. Introduction

After heart attack and cancer, cerebrovascular accident (CVA) is the third leading cause of death in the industrialized part of the world and the leading cause of long-term disability. Having suffered a stroke, 15% to 30% of patients are incapable of independent existence without help of others. After the first ischemic stroke, 10 to 15% of patients die within the first 30 days, 20% within 6 months, and this percentage increases to 25 - 30% within one year. CVA is a serious problem both in terms of significant disability of the population and very high costs of treatment. In addition to the high incidence, which increases with the increasing age of patients, also the fact that the cerebrovascular accidents affect younger age groups more and more often is serious. Thus, even accidents in patients between 30 - 40 years of age may occur.

The aim of treatment of ischemic CVA (iCVA) is to intervene as soon as possible and to achieve reperfusion of the affected area. Therefore, the time of recanalization plays a crucial role.

The only causal and potentially effective treatment for iCVA due to the occlusion of cerebral arteries is an attempt at recanalization. The first treatment introduced was intravenous administration of a thrombolytic agent, in the following years possibilities of intra-arterial recanalization using a thrombolytic agent or intra-arterial mechanical embolectomy have gradually been introduced and technologically improved.

2. IV thrombolysis

Experience with intravenous thrombolysis (IVT) of coronary and peripheral arteries have led to the introduction of intravenous thrombolysis also in acute occlusions of the major cerebral arteries. However, the method of IVT in the coronary and peripheral bloodstream has been abandoned with the passing because of the higher risk of overall complications and less pronounced local effect.

A good final effect of intravenously administered thrombolytic agent in acute CVA has been shown in the NINDS study (National Institute of Neurological Disorders and Stroke) (NINDS Stroke Study Group, 1995). This study randomized a set of 624 patients with occlusions of larger and smaller arteries not verified by angiography, the time interval from the CVA occurrence to the beginning of administration was 3 hours. Recombinant tissue plasminogen activator (rt-PA) was used, administered at a dose of 0.9 mg/kg up to a maximum dose of 90

mg, 10% bolus, the rest administered in course of 60 minutes. The study showed a better clinical outcome in the group treated with IVT (30% of patients had no or minor neurological deficit according to the modified Rankin scale $mRS \leq 1$). Mortality after three months was 17% (versus 21% in placebo-treated patients). Based on the results of this study, the FDA in the U.S. approved in 1996 the use of IVT in clinical practice. In Europe, IVT with rt-PA was approved in 2002. Safety and efficacy of routinely administered rt-PA in clinical practice has been confirmed once more by the SITS-MOST monitoring study (SITS-MOnitoring STudy) based on the data from European registries (Wahlgren et al., 2007).

The ECASS I, II, and ATLANTIS studies have not shown significant benefit to the patient in case of use of an intravenous thrombolytic agent (rt-PA) in the time-window of 3 to 6 hours after the onset of symptoms. The number of patients with no or minimal neurological deficit ($mRS \leq 1$) has not improved, but the number of disabled patients ($mRS \leq 2$) has decreased (Clark et al., 1999; Hacke et al., 1995, 1998). The efficacy in the ECASS studies depended on the selection of patients with moderate to severe neurological deficit and without extended infarctsigns on the initial CT scan. These studies did not support use of intravenous thrombolysis after the 3-hour time window.

The recently published ECASS III study evaluating safety and efficacy of IVT in the time window of 3 - 4.5 hours has showed improvement of the clinical condition in patients after 3 months compared to placebo (mRS 0-1 52.4% vs. 45.2%). Intracranial hemorrhage occurred more often in the group treated with the thrombolytic agent: 27% vs. placebo 17.6%. Mortality in both groups did not significantly differ after 3 months (7.7% vs 8.4%) (Hacke et al., 2008). The results of this study have led to redefinition of the recommended procedure for IVT and the therapeutic window has increased to 4.5 hours.

The advantage of IVT is its widespread availability and the possibility of its early initiation. This treatment does not even require the specialized know-how that is needed to insert and navigate a catheter into the cerebral circulation. Unfortunately, experimental studies have shown that this treatment is less and less effective as the thrombus grows larger and larger. (Zivin et al., 1985). More than 50% of patients treated with intravenous rtPA fail to achieve a favorable clinical outcome (Papadakis & Buchan, 2006; Qureshi et al., 2001).

3. IA thrombolysis

The basic study on intra-arterial thrombolysis (IAT) was a randomized multicenter study ProAct (Prolyse in Acute Cerebral thromboembolism), ongoing in phase I and II (del Zoppo et al., 1998; Furlan et al., 1999). In this study, recombinant pro-urokinase (r-proUK) was compared to placebo. As a placebo, intra-arterial administration of saline solution with heparin was used. The first 16 patients received a 100-IU/kg bolus followed by a 1000 IU/h constant infusion ("high heparin") for 4 hours. Thereafter, on the recommendation of the External Safety Committee, the heparin regimen was altered to a 2000 IU bolus and 500 IU/h infusion ("low heparin") for the remaining patients. In both groups, the end of the microcatheter was placed in the proximal third of the thrombus. Passing through the thrombus or mechanical action on it was not allowed. If partial recanalisation occurred after 2 hours, the catheter was introduced more distally into the proximal third of the remaining thrombus. The time window was 6 hours, patients with middle cerebral artery occlusion (MCA) were indicated for the treatment.

In phase I of the PROACT study, 46 patients were randomized, the maximum total dose was 6 mg of r-proUK in course of 2 hours, recanalization occurred in 57.7% (compared to 14.3% in controls), whereas in the group with higher dose of heparin it was in 81.8% and in the group with lower dose of heparin it was in 40.0%. Serious cerebral bleeding in the first 24 hours after thrombolysis occurred on average in 15.4% compared to 7.1% in the control group, in the group with the higher administered dose of heparin it was more frequent (27.3%), after dose reduction it occurred only in 6.7%. Clinical condition was evaluated after 3 months according to mRS, 19.2% of patients were stage 0-2 (versus 7.1% of controls).

In phase II of the study, 180 patients were randomized, the total dose of r-proUK was increased to 9 mg, heparin was decreased to 2000 units. The percentage of recanalization was 66% in the r-proUK group compared to 18% in the placebo group for TIMI 2-3 and 19% in the r-proUK group compared to 2% in the placebo group for TIMI 3. The resulting morbidity after 3 months was more favorable by 60% compared to the control group (mRS 0-2 in 40% r-proUK treated patients in contrast to 25% in the control group), also mortality was slightly lower (24% compared to 27% in the control group); the number of symptomatic hemorrhage was significantly higher in the first 24 hours (35% versus 13% in the control group) but was not significantly different by 10 days (68% in the r-proUK group versus 57%, $p=0.23$); for comparison, in the NINDS study with IVT the ICH rate was 6.5%.

In phase II of the study with a higher dose of the thrombolytic agent and a lower dose of heparin, a higher number of recanalizations and a significant decrease in the number of hemorrhages was achieved, leading to better clinical results. However, FDA has not granted its approval to use IAT in clinical practice, and so IAT has remained reserved for use in studies only.

Also a number of nonrandomized studies with smaller numbers of patients, a number of case studies and meta-analyses have been published, which generally show a higher percentage of recanalizations and favorable clinical outcome after intra-arterial administration of a thrombolytic agent (Wardlaw et al., 1997; Gönner et al., 1998; Higashida et al., 2003).

In recent years, new antiplatelet medicines acting on the inhibitory IIb / IIIa platelet receptors, have been developed, which are highly effective and relatively safe even when administered intravenously. They act selectively on platelet thrombi, preventing their formation and growth. In the brain arteries they have been used so far mainly to treat thromboembolic complications of endovascular procedures, however, several papers on their use in acute iCVA has already been published (The Abciximab in Ischemic Stroke Investigators, 2000).

Compared to intravenous thrombolysis, intra-arterial thrombolysis has the advantage of achieving higher concentration of the thrombolytic agent at the site of the occlusion with lower total dose. This reduces the risk of systemic complications. Also results of a number of other studies showing a higher percentage of recanalization and better clinical results despite a slightly increased percentage of bleeding complications confirm this (Barnwell et al., 1994).

Opinion of the ASITN Executive Committee (American Society of Interventional and Therapeutic Neuroradiology), published in the AJNR in 2001, states that although the

results of the PROACT study have not led the FDA to grant the approval, IAT is regarded, based on the experience gained so far, as a beneficial and acceptable method of treatment at the centers experienced in vascular diagnostic and interventional procedures. Indication for the IAT must be considered on an individual basis, with careful assessment of risks and benefits (Executive of the American Society of Interventional & Therapeutic Neuroradiology [ASITN], 2001).

In 2003, new guidelines of the ASA (American Stroke Association) and EUSI (European Stroke Initiative) were published, which indicate that EUSI acknowledges that the IAT performed within 6 hours after development of the CVA improves its course (Klijn & Hankey, 2003).

Thus, IAT is currently an appropriate method of iCVA treatment in patients within the time window of 3-6 hours (or 4.5 - 6 hours with regard to the results of the ECASS III study) in specialized centers. Intra-arterial thrombolysis may also be used to deal with acute embolic complications developed during endovascular procedures and last, but not least, an IA thrombolytic agent may be administered after unsuccessful response to its IV administration.

4. Combined IV / IA thrombolysis

Pursuit of a fast and simple administration of a thrombolytic agent together with angiographic monitoring of the treatment effect and the possibility of local intervention led to the IMS study (International Management of Stroke Trial) (IMS study investigators, 2004). Patients were treated with intravenous administration of a thrombolytic agent and in the case of angiographic confirmation of persisting arterial occlusion they were given the thrombolytic agent also locally. The treatment led to a partial or complete recanalization of the artery in 56% of patients, the percentage of bleeding was low (6.3%), as well as mortality was (16%). A subsequent study, IMS II (IMS II Trial Investigators, 2007; Tomsick et al., 2008), put together combined IVT and IAT with the use of a special micro-infusion catheter Ekos-MicroLysUS (Ekos, Washington, USA) or a standard microcatheter. The Ekos catheter allows simultaneous infusion of a thrombolytic agent and administration of low-energy ultrasound waves transmitted by a probe at the end of the micro-catheter. The median dose of the intravenously administered rt-PA in the study was 46.4 mg and that of the intra-arterial dose was 12 mg. The percentage of hemorrhage, compared to IMS I, increased to 9.9%, recanalization increased to 73% with 16% mortality. Favorable clinical outcome was achieved in 46% of patients. Currently, IMS III is being conducted, comparing the results of combined treatment with IVT, IAT, and the Ekos catheter with the MERCI apparatus (Khatri et al., 2008) and Synthesis-Expansion trial is comparing the IVT and IAT (Ciccone et al., 2011).

There are also other publications reporting improvement of the angiographic and clinical finding in different combinations of methods (Burns et al., 2008).

5. Mechanical embolectomy

After IAT has been introduced within the framework of clinical studies, first positive experience with mechanical disruption of the thrombus were reported, with the use of a

guide wire or special instrumentation increasing the thrombus surface by means of its fragmentation and thus accelerating the effect of thrombolytic agent. For this purpose, micro-guide wire, extraction loops and baskets to capture foreign bodies were used (Sarimachi et al., 2004; Krajina et al., 2005).

Mechanical treatment reduces the need for a thrombolytic agent, reducing the risk of ICH (intracerebral hemorrhage) and has been used up to 8 hours after stroke, since it is still an experimental time window. Mechanical devices are able to recanalize the occluded artery faster and may be more effective in removing mature thrombi, cholesterol or calcified thrombi, and atherosclerotic plate emboli.

Mechanical embolectomy plays a role even in patients contraindicated for pharmacological treatment with a thrombolytic agent, usually because of recent surgery.

The disadvantage of mechanical embolectomy is often a difficult access to cerebral arteries, due to the anatomical relations of the arteries in the neck and brain, and the possibility of perforation or dissection of the artery or distal embolization of the parts of the thrombus into the so far unaffected bloodstream. However, the advantages of mechanical intervention outweigh the disadvantages and risks.

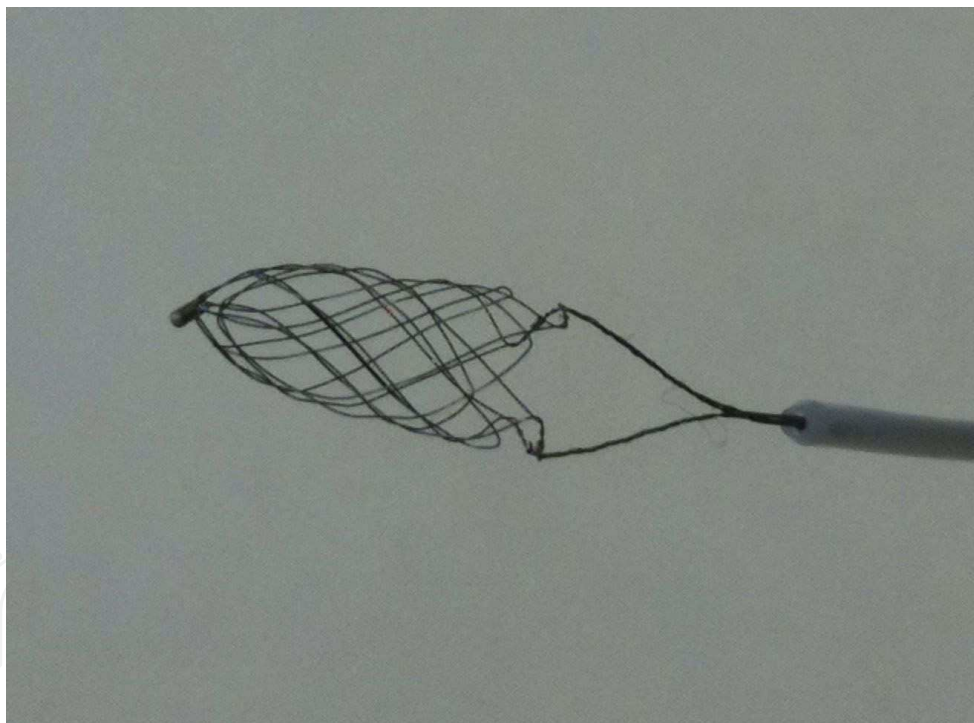


Fig. 1. Catch retriever

Mechanical devices vary depending on the site from where they act upon the thrombus. The approach is either a proximal one with aspiration of the thrombus or with a device "grasping" the thrombus or devices for distal access capturing the thrombus into a basket or snare. A study comparing the effectiveness of these approaches, using the Vasco35 micro-catheter and the Catch retriever (both by Balt Extrusion, France) has demonstrated that the use of the micro-catheter allows rapid and repeated use with a low percentage of thromboembolic events (3% versus 26%) but also significantly lower success rate as regards

thrombus removal compared to the Catch retriever (39% vs. 83%). The percentage of embolic events may be reduced by the use of a proximal occlusion balloon (Gralla et al., 2006). In a recent retrospective case series, the Catch device again appears effective for recanalization and improving 90-day outcome in patients with acute ischemic stroke (Mourand et al., 2011).

5.1 Merci retriever

In 2004 the FDA approved the first extraction device for stroke treatment - Merci Retrieval system (by Concentric Medical, Calif., USA). It is a flexible nitinol guide wire, the distal end of which has shape memory and, being pushed out of the micro-catheter, it forms into a helix. Newer types have the end surrounded by a braided tangle of filaments to better capture the thrombus.

Using the micro-catheter, the system is introduced behind thrombus, it is expanded and then retracted under the vacuum in the balloon guide catheter. Merci Retrieval system was first used in a small multicenter study in 28 patients with NIHSS ≥ 10 with occlusion of a major cerebral artery documented by angiography (Gobin et al., 2004). Occlusion of intracranial ICA (internal carotid artery) was present in 5 patients (18%), occlusion of MCA (medial cerebral artery) in 18 patients (64%), common occlusion of both ICA and MCA in 3 patients (11%) and occlusion of basilar artery in 2 patients (7%). Successful recanalization (TIMI 2-3) was achieved when using the retriever alone in 12 patients (43%) and when combining it with IA rtPA in 18 patients (64%). In 12 patients, an asymptomatic ICH developed after the procedure. After one month, clinical improvement was achieved in 9 patients (32%). 10 patients died within 30 days (36%).

Another study investigating the effectiveness of the Merci Retrieval system was the MERCI study (Mechanical Embolus Removal in Cerebral Ischemia) (Smith et al., 2005). The aim of the MERCI study was to broaden the possibilities of treatment for patients contraindicated for IVT or for those who have passed the time window for IVT or in whom IVT was not successful. The therapeutic window was extended to 8 hours after the onset of complaints. IA thrombolytic agents were either not used at all or only in small doses. 151 patients were enrolled in the study, the average age was 67 years of age and the NIHSS score was 20. The inclusion criteria were: age over 18 years, the clinical picture of stroke with NIHSS ≥ 8 , time window between 3 to 8 hours after the onset of complaints or 0 to 3 hours in the case of contraindicated IV rtPA, and artery occlusion confirmed by angiography. Patients with an ICH, significant mass effect with a midline shift, or with a hypodensity exceeding 1/3 of the MCA supply area were excluded from the study. In 90% of cases, the occlusion affected the anterior supply area. Recanalization was achieved in 48% of patients, in the case of combination with thrombolytic therapy it was in 60%. Symptomatic complications of the procedure, such as perforation, dissection, distal embolism occurred in 7.1%, symptomatic hemorrhage occurred in 7.8% and was partly due to artery perforation (4.3%). Conclusions of the first phase of the study showed good clinical results (mRS $\leq 0-2$) in 27.7% of the total number of patients, i.e. in 46% of patients from the successful recanalization group.

In the MERCI multicenter study (Smith et al., 2008), the second generation of the retriever-type L5 was used. Inclusion and exclusion criteria did not differ from those in the previous study. 177 of patients were enrolled in the study, in 164 patients the Merci Retrieval system

could be used. The average age was 68 years, and NIHSS score was 19. In 92% of cases, the occlusion affected the anterior supply area. 48 patients (29%) were given IV rtPA before the procedure, 57 patients received IA rtPA during the procedure. Recanalization was achieved using the Merci system alone in 57% of treated arteries, in the case of combination with IA thrombolytic and mechanical treatment it was in 69.5%. After 90 days, a good result was achieved in the whole group in 36% of patients (mRS 0-2), symptomatic hemorrhage occurred in 9.8%. 90-day mortality was 34%.




Fig. 2. Merci retriever, type L5

5.2 Neuronet

Neuronet (Abbott Vascular, Calif., USA) is a nitinol basket-shaped device attached to a micro-guide wire. The basket is opened distal to the embolus and the embolus is captured in it when the basket is pulled back.

Neuronet was successfully used for the removal of emboli in the cerebral arteries (Mayer et al., 2002a; Nesbit et al., 2004) and prospectively evaluated in a small study Neuronet Evaluation in Embolic Stroke Disease (Mayer et al., 2002b). This study evaluated 5 patients, treated with the Neuronet device. The device was used without flow control in the first 2 patients and with flow reversal in the basilar artery in the last 3 patients during retraction by transiently blocking both vertebral arteries or the left subclavian artery or both vertebral arteries with coaxial catheters. Patients 1, 2, and 4 were also administered recombinant tissue plasminogen activator (rtPA) intra-arterially. In the first 2 patients the deployment of the device was unsuccessful. Two of the remaining patients were recanalised using mechanical thrombolysis only and one patient required additional fibrinolysis.

5.3 Penumbra system

Another device for thrombus removal is the Penumbra system (Penumbra, Calif., USA), which combines mechanical disruption of the thrombus with aspiration of its fragments. The system consists of a reperfusion micro-catheter connected to an aspiration pump and of a drop-like separator at the end of the micro-guide wire. The thrombus is fragmented and

aspirated by the reperfusion micro-catheter, whereas the separator also fragments the thrombus and prevents micro-catheter clogging. This mechanical device is capable to restore the passage through the vessel without the use of a thrombolytic agent, the entire system is designed as a minimally invasive one, acting on the embolus from its proximal end. High flexibility and a wide spectrum of sizes (0.26 - 0.54 inch) of reperfusion micro-catheters enable their successful use even in smaller branches, such as M2 and A2.

The Penumbra system was first used in a European study in 20 patients (21 treated arteries) with ICA occlusion in 7 patients, MCA occlusion in 5 patients, and BA occlusion in 9 patients (Bose et al., 2008). The average NIHSS score was 21, patients were treated within 8 hours after the onset of complaints. Successful recanalization (TIMI 2 and 3) was achieved in 100%. Nine patients received IA rtPA after the embolectomy. Clinical improvement (mRS ≤ 2) within 30 days occurred in 45% of patients. Mortality reached 45%. In 8 patients, ICH occurred, two of these were symptomatic. The use of IA rtPA resulted in a higher incidence of bleeding.

In another multicenter prospective study (Penumbra Stroke Trial) 125 patients were treated in 24 centers in Europe and the USA (Penumbra Pivotal Stroke Trial Investigators, 2009). Inclusion and exclusion criteria were the same as in the MERCI and Multi MERCI studies. The average age of patients was 63 years, average NIHSS score was 17, median time from the onset of symptoms until the procedure was started was 4.1 hours. The occluded arteries were: ICA in 18%, M1 or M2 in 70%, vertebrobasilar artery in 9% and others in 3%. Complete or partial recanalization (TIMI 2 to 3) occurred in 81.6% of occluded arteries. Major complication of the procedure occurred in 4 patients. Symptomatic ICH occurred in 14 patients (11.2%) and asymptomatic ICH in 21 patients (16.8%). Good clinical outcome (mRS ≤ 2) after 90 days was achieved in 25% of patients. 90-day mortality was 32.8%. Just as in the MERCI and Multi MERCI studies, there was a marked improvement of neurological status (29% vs. 9%) and mortality (29% vs. 48%) in patients with successful recanalization. Based on this study, FDA consented to the use of this system in the treatment of ischemic stroke in 2007.



Fig. 3. Penumbra system

5.4 Stent solitaire

Stent Solitaire (Solitaire AB, EV3, USA) is a demountable retractable stent originally designed for intracranial bloodstream vessels where it served as a remodeling stent during coiling of wide neck aneurysms. It is a self-expanding closed cell nitinol stent, which allows for its pulling completely back into the microcatheter after having it fully inserted in the vessel. Using the device for demounting GDC embolization spirals, the stent may be electrolytically detached by the same mechanism as the GDC coils (Stryker, USA) and left at the site of the artery occlusion to help restore brain perfusion. Stent diameter expanded at maximum is 4 mm, the length is 15 mm or 20 mm. The stent is introduced through a microcatheter with an internal lumen of 0.021 inches. Its advantageous use even as a mechanical embolectomy device was demonstrated by a prospective study in 20 patients with an acute ischemic stroke in the time window up to 8 hours (Castaño et al., 2010). In 18 patients (90%) the thrombus was successfully removed by the stent and the affected brain tissue revascularized (TICI 2b-3); after 90 days, 45% of patients achieved the final mRS ≤ 2 .




Fig. 4. Solitaire stent

5.5 Bonnet retriever

It is a novelty by Phenox company (Bochum, Germany), which launched Phenox Clot Retriever to the market already several years ago. It is a "self-expanding nitinol braiding with polyamide filaments." Larger surface helps better fixation of the thrombus and increases the chance for its extraction. Retriever is firmly connected to the micro-guide wire, it has contrast marks on both ends. It may be introduced distal to the thrombus or opened in the thrombus. By pulling it back slowly, the thrombus is captured in the braiding and extracted from the artery.




Fig. 5. Bonnet retriever

6. Conclusion

Endovascular treatment of ischemic cerebral strokes is still developing. There are advances both in the field of pharmacology and in the field of mechanical devices. New medicines improve the safety of the procedure and together with more and more perfect and efficient devices markedly improve the clinical condition of patients.

Currently, mechanical embolectomy is not merely an auxiliary treatment method but has become the method of choice in given indications. Mechanical recanalization has helped not only to investigate a longer therapeutic time window, but may also help reducing the percentage of bleeding associated with pharmacological thrombolytic therapy. The indicated option of mechanical embolectomy in patients with occlusion of a major cerebral artery is capable of improving brain perfusion and thus ameliorate the clinical condition of the patient and protect him/her from a disabling affliction.

7. References

- Barnwell, SL., Clark, WM., Nguyen, TT., O'Neill, OR., Wynn ML, & Coull BM. (1994) Safety and efficacy of delayed intraarterial urokinase therapy with mechanical clot disruption for thromboembolic stroke. *AJNR*, Vol. 15, No. 10, pp. 1817-1822, ISSN: 0195-6108
- Bose, A., Henkes, H., Alfke, K., Reith, W., Mayer, TE., Berlis, A., Branca, V., Sit, SP., & Penumbra Phase 1 Stroke Trial Investigators. (2008) The Penumbra System: a mechanical device for the treatment of acute stroke due to thromboembolism. *AJNR*, Vol. 29, No. 7, pp. 1409-1413, ISSN: 0195-6108
- Burns, TC., Rodriguez, GJ., Patel, S., Hussein, HM., Georgiadis, AL., Lakshminarayan, K., & Qureshi, AI. (2008) Endovascular Interventions following Intravenous Thrombolysis May Improve Survival and Recovery in Patients with Acute Ischemic Stroke: A Case-Control Study. *AJNR*, Vol. 29, No. 10, pp. 1918 - 1924, ISSN: 0195-6108
- Castañó, C., Dorado, L., Guerrero, C., Millán, M., Gomis, M., Perez de la Ossa, N., Castellanos, M., García, MR., Domenech, S., & Dávalos, A. (2010) Mechanical thrombectomy with the Solitaire AB device in large artery occlusions of the

- anterior circulation: a pilot study. *Stroke*, Vol. 41, No. 8, pp. 1836–1840, ISSN: 1747-4930
- Ciccone, A., Valvassori, L., Nichellatti, M., SYNTHESIS Expansion investigators. (2011) SYNTHESIS Expansion: design of a nonprofit, pragmatic, randomized, controlled trial on the best fast-track endovascular treatment vs. standard intravenous alteplase for acute ischemic stroke. *Int J Stroke*, Vol. 6, No. 3, pp.259-265, ISSN: 1747-4949
- Clark, WM., Wissman, S., Albers, GW., Jhamandas, JH., Madden, KP., & Hamilton, S. (1999) For the ATLANTIS Study Investigators. Recombinant Tissue-Type Plasminogen Activator (Alteplase) for Ischemic Stroke 3 to 5 Hours After Symptom Onset. The ATLANTIS Study: A Randomized Controlled Trial. *JAMA*, Vol. 282, No. 21, pp. 2019-2026, ISSN: 0098-7484
- del Zoppo, GJ., Higashida, RT., Furlan, AJ., Pessin, MS., Rowley, HA., & Gent, M. (1998) PROACT: A Phase II Randomized Trial of Recombinant Pro-Urokinase by Direct Arterial Delivery in Acute Middle Cerebral Artery Stroke. *Stroke*, Vol. 29, No. 1, pp. 4-11, ISSN 0039-2499
- Executive of the ASITN. (2001) Intraarterial thrombolysis: Ready for Prime Time? *AJNR*, Vol. 22, pp. 55-58, ISSN: 0195-6108
- Furlan, A., Higashida, R., Wechsler, L., Gent, M., Rowley, H., Kase, C., Pessin, M., Ahuja, A., Callahan, F., Clark, WM., Silver, F., & Rivera F. (1999) Intra-arterial prourokinase for acute ischemic stroke. The PROACT II study: a randomised controlled trial. Prolyse in Acute Cerebral Thromboembolism. *JAMA*, Vol. 282, No. 21, pp. 2003-2011, ISSN: 0098-7484
- Gobin, YP., Starkman, S., Duckwiler, GR., Grobelny, T., Kidwell, CS., Jahan, R., Pile-Spellman, J., Segal, A., Vinuela, F., & Saver, JL. (2004) MERCI 1: a phase 1 study of Mechanical Embolus Removal in Cerebral Ischemia. *Stroke*, Vol. 35, No. 12, pp. 2848–2854, ISSN: 1747-4930
- Gönnér, F., Remonda, L., Mattle, H., Sturzenegger, M., Ozdoba, C., Lövblad, KO., Baumgartner, R., Bassetti, C., & Schroth, G. (1998) Local intra-arterial thrombolysis in acute ischaemic stroke. *Stroke*, Vol. 29, No. 9, pp. 1894 – 1900, ISSN 0039-2499
- Gralla, J., Schroth, G., Remonda, L., Nedeltchev, K., Slotboom, J., & Brekenfeld, C. (2006) Mechanical Thrombectomy for Acute Ischemic Stroke: Thrombus-Device Interaction, Efficiency, and Complications In Vivo. *Stroke*, Vol. 37, No. 12, pp. 3019–3024, ISSN: 1747-4930
- Hacke, W., Kaste, M., Fieschi, C., Toni, D., Lesaffre, E., von Kummer, R., Boysen, G., Bluhmki, E., Höxter, G., & Mahagne, MH. (1995) Intravenous thrombolysis with recombinant tissue plasminogen activator for acute hemispheric stroke. The European Cooperative Acute Stroke Study (ECASS). *JAMA*, Vol. 274, No. 13, pp. 1017-1025, ISSN: 0098-7484
- Hacke, W., Kaste, M., Fieschi, C., von Kummer, R., Davalos, A., Meier, D., Larrue, V., Bluhmki, E., Davis, S., Donnan, G., Schneider, D., Diez-Tejedor, E., & Trouillas, P. (1998) Randomised double-blind placebo-controlled trial of thrombolytic therapy with intravenous alteplase in acute ischemic stroke (ECASS II). Second European-


- Australasian Acute Stroke Study Investigators. *Lancet*, Vol. 352, No. 9136, pp. 1245-1251, ISSN:0140-6736
- Hacke, W., Kaste, M., Bluhmki, E., Brozman, M., Dávalos, A., Guidetti, D., Larrue, V., Lees, KR., Medeghri, Z., Machnig, T., Schneider, D., von Kummer, R., Wahlgren, N., Toni, D., & ECASS Investigators. (2008) Trombolysis with alteplase 3 to 4.5 hours after acute ischemic stroke. *N Engl J Med*, Vol. 359, No. 13, pp. 1317-1329, ISSN 0028-4793
- Higashida, RT., Furlan, AJ., Roberts, H., Tomsick, T., Connors, B., Barr, J., Dillon, W., Warach, S., Broderick, J., Tilley, B., Sacks, D., Technology Assessment Committee of the American Society of Interventional and Therapeutic Neuroradiology., & Technology Assessment Committee of the Society of Interventional Radiology. (2003) Trial Design and Reporting Standards for Intra-Arterial Cerebral Thrombolysis for Acute Ischemic Stroke. *Stroke*, Vol. 34, No. 8, pp. e109-e137, ISSN 0039-2499
- IMS study investigators. (2004) Combined intravenous and intra-arterial recanalization for acute ischemic stroke: the Interventional Management of Stroke study. *Stroke*, Vol. 35, No. 4, pp. 904-911, ISSN 0039-2499
- IMS II The IMS II Trial Investigators. (2007) The Interventional Management of Stroke (IMS) II Study. *Stroke*, Vol. 38, No. 7, pp. 2127-2135, ISSN 0039-2499
- Khatiri, P., Hill, MD., Palesch, YY., Spilker, J., Jauch, EC., Carrozzella, JA., Demchuk, AM., Martin, R., Mauldin, P., Dillon, C., Ryckborst, KJ., Janis, S., Tomsick, TA., Broderick, JP., & Interventional Management of Stroke III Investigators. (2008) Methodology of the Interventional Management of Stroke III Trial. *Int J Stroke*, Vol. 3, No. 2, pp. 130-137, ISSN: 1747-4930
- Klijn, CJM. & Hankey, GJ. (2003) Management of acute ischemic stroke: new guidelines from American Stroke Association and European Stroke Initiative. *Lancet Neurol*, Vol. 2, No. 11, pp. 698-701, ISSN: 1474-4422
- Krajina, A., Krajickova, D., Sprinar, Z., Nikolov, DH., Parizkova, R., & Lojik M. (2005) Percutaneous mechanical extraction of emboli in acute ischemic stroke: a case report and literature survey. *Cesko Slov Neurol N*, Vol. 65, No. 101, pp. 51-57, ISSN 1802-4041
- Mayer, TE., Hamann, GF., & Brueckmann, H. (2002a) Mechanical extraction of a basilar-artery embolus with the use of flow reversal and a microbasket. *N Engl J Med*, Vol. 347, No. 10, pp. 769-770, ISSN 0028-4793
- Mayer, TE, Hamann, GF, & Brueckmann, H. (2002b) Treatment of Basilar Artery Embolism With a Mechanical Extraction Device. Necessity of Flow Reversal. *Stroke*, Vol. 33, No. 9, pp. 2232-2235, ISSN: 0039-2499
- Mourand, I., Brunel, H., Constalat, V., Riquelme, C., Lobotesis, K., Milhaud, D., Héroum, C., Arquizan, C., Moynier, M., & Bonafé, A. (2011) Mechanical Thrombectomy in Acute Ischemic Stroke: Catch Device. *AJNR*, Vol. 32, No. 8, pp. 1381-1385, ISSN: 0195-6108
- Nesbit, GM., Luh, G., Tien, R., & Barnwell, SL. (2004) New and future endovascular treatment strategies for acute ischemic stroke. *J Vasc Interv Radiol*, Vol. 15, pp. 103-110, ISSN: 1051-0443

- NINDS rt-PA Stroke Study Group. (1995). Tissue plasminogen activator for acute ischemic stroke. *N Engl J Med*, Vol. 333, No. 24, pp. 1581-1587, ISSN 0028-4793
- Papadakis, M. & Buchan, AM. (2001) Translational vehicles for neuroprotection. *Biochem Soc Trans*, Vol. 34, pp. 1318-1322, ISSN 0300-5127
- Penumbra Pivotal Stroke Trial Investigators. (2009) The penumbra pivotal stroke trial: safety and effectiveness of a new generation of mechanical devices for clot removal in intracranial large vessel occlusive disease. *Stroke*, Vol. 40, No. 8, pp. 2761-2768, ISSN: 1747-4930
- Qureshi, AI., Ali, Z., Suri, MF., Kim, SH., Shatla, AA., Ringer, AJ., Lopes, DK., Guterman, LR., & Hopkins LN. (2001) Intra-arterial third generation recombinant tissue plasminogen activator (reteplase) for acute ischemic stroke. *Neurosurgery*, Vol. 49, No. 1, pp. 41-48, discussion 48-50, ISSN 0148-396X
- Sarimachi, T., Fujii, Y., Tsuchiya, N., Nashimoto, T., Harada, A., Ito, Y., & Tanaka, R. (2004) Recanalization by mechanical embolus disruption during intraarterial thrombolysis in the carotid territory. *AJNR*, Vol. 25, No. 8, pp. 1391-1402, ISSN: 0195-6108
- Smith, WS., Sung, G., Starkman, S., Saver, JL., Kidwell, CS., Gobin, YP., Lutsep, HL., Nesbit, GM., Grobelny, T., Rymer, MM., Silverman, IE., Higashida, RT., Budzik, RF., Marks, MP., & MERCI Trial Investigators. (2005) Safety and efficacy of mechanical embolectomy in acute ischemic stroke: results of MERCI trial. *Stroke*, Vol. 36, No. 7, pp. 1432-1438, ISSN: 1747-4930
- Smith, WS., Sung, G., Saver, J., Budzik, R., Duckwiler, G., Liebeskind, DS., Lutsep, HL., Rymer, MM., Higashida, RT., Starkman, S., Gobin, YP., Multi MERCI Investigators, Frei, D., Grobelny, T., Hellinger, F., Huddle, D., Kidwell, C., Koroshetz, W., Marks, M., Nesbit, G., & Silverman, IE. (2008) Mechanical thrombectomy for acute ischemic stroke: final results of the Multi MERCI trial. *Stroke*, Vol. 39, No. 4, pp. 1205-1212, ISSN: 1747-4930
- The Abciximab in Ischemic Stroke Investigators. (2000) Abciximab in acute ischemic stroke: a randomized, double-blind, placebo-controlled, dose-escalation study. *Stroke*, Vol. 31, No. 3, pp. 601-609, ISSN 0039-2499
- Tomsick, T., Broderick, J., Carrozella, J., Khatri, P., Hill, M., Palesch, Y., Khoury, J., & Interventional Management of Stroke II Investigators. (2008) Revascularization Results in the Interventional Management of Stroke II Trial. *AJNR*, Vol. 29, pp. 582-587, ISSN: 0195-6108
- Wahlgren, N., Ahmed, N., Davalos, A., Ford, GA., Grond, M., Hacke, W., Hennerici, MG., Kaste, M., Kuelkens, S., Larrue, V., Lees, KR., Roine, RO., Soinne, L., Toni, D., Vanhooren, G., & SITS-MOST investigators. (2007) Thrombolysis with alteplase for acute ischemic stroke in the Safe Implementation of Thrombolysis in Stroke-Monitoring Study (SITS-MOST): an observational study. *Lancet*, Vol. 369, No. 9558, pp. 275-282, ISSN: 0140-6736
- Wardlaw, JM., Warlow, CP., & Counsell C. (1997) Systemic review of evidence on thrombolytic therapy for acute ischaemic stroke. *Lancet*, Vol. 350, No. 9078, pp. 607-614, ISSN: 0140-6736

Zivin, JA., Fisher, M., De Girolami, U., Hemenway, CC., & Stashak JA. (1985) Tissue plasminogen activator reduces neurological damage after cerebral embolism. *Science*, Vol. 230, No. 4731, pp. 1289–1292, ISSN 0036-8075

IntechOpen

IntechOpen



Advances in the Treatment of Ischemic Stroke

Edited by Dr. Maurizio Balestrino

ISBN 978-953-51-0136-9

Hard cover, 246 pages

Publisher InTech

Published online 02, March, 2012

Published in print edition March, 2012

In recent years research on ischemic stroke has developed powerful therapeutic tools. The novel frontiers of stem cells therapy and of hypothermia have been explored, and novel brain repair mechanisms have been discovered. Limits to intravenous thrombolysis have been advanced and powerful endovascular tools have been put at the clinicians' disposal. Surgical decompression in malignant stroke has significantly improved the prognosis of this often fatal condition. This book includes contributions from scientists active in this innovative research. Stroke physicians, students, nurses and technicians will hopefully use it as a tool of continuing medical education to update their knowledge in this rapidly changing field.

How to reference

In order to correctly reference this scholarly work, feel free to copy and paste the following:

Jiří Lacman and František Charvát (2012). Mechanical Embolectomy, *Advances in the Treatment of Ischemic Stroke*, Dr. Maurizio Balestrino (Ed.), ISBN: 978-953-51-0136-9, InTech, Available from:
<http://www.intechopen.com/books/advances-in-the-treatment-of-ischemic-stroke/mechanical-embolectomy>

INTECH
open science | open minds

InTech Europe

University Campus STeP Ri
Slavka Krautzeka 83/A
51000 Rijeka, Croatia
Phone: +385 (51) 770 447
Fax: +385 (51) 686 166
www.intechopen.com

InTech China

Unit 405, Office Block, Hotel Equatorial Shanghai
No.65, Yan An Road (West), Shanghai, 200040, China
中国上海市延安西路65号上海国际贵都大饭店办公楼405单元
Phone: +86-21-62489820
Fax: +86-21-62489821

© 2012 The Author(s). Licensee IntechOpen. This is an open access article distributed under the terms of the [Creative Commons Attribution 3.0 License](https://creativecommons.org/licenses/by/3.0/), which permits unrestricted use, distribution, and reproduction in any medium, provided the original work is properly cited.

IntechOpen

IntechOpen